

We are IntechOpen, the world's leading publisher of Open Access books Built by scientists, for scientists

4,800

Open access books available

122,000

International authors and editors

135M

Downloads

Our authors are among the

154

Countries delivered to

TOP 1%

most cited scientists

12.2%

Contributors from top 500 universities



WEB OF SCIENCE™

Selection of our books indexed in the Book Citation Index
in Web of Science™ Core Collection (BKCI)

Interested in publishing with us?
Contact book.department@intechopen.com

Numbers displayed above are based on latest data collected.
For more information visit www.intechopen.com



Fracture Repair: Its Pathomechanism and Disturbances

Grzegorz Szcześniey

Additional information is available at the end of the chapter

<http://dx.doi.org/10.5772/intechopen.76252>

Abstract

Healing of the bone fracture is a biological process that is based on various cell lineages recruited, activated and regulated by molecular mediators, namely chemokines, growth factors, and cytokines, cooperating in a cascade of events aimed to fill the fracture gap with callus. Remodeling of the callus rebuilds the microarchitecture to the mature bone— cancellous or compact, depending on the type of the bone that was primarily at the fracture gap. Restitution of the bone continuity requires activation of mesenchymal stem cells that transform into osteoblasts and mature into osteocytes. It is activated and regulated by molecules released from blood platelets from posttraumatic hematoma, traumatized tissues, nerve endings, and inflowing inflammatory cells. The significance of the inflammatory cells in this process is inappreciable, as they eradicate pathogens, remove wound debris, and supply the fracture gap with molecules regulating forthcoming cellular events. They also provide immune regulation of the healing. To proceed uneventfully, healing requires an adequate bone contact and biomechanical environment, proper oxygenation, and nutrition. Unfortunately, up to 15% of bone fractures show some kinds of disturbances that may result in cessation of reparative processes leading to non-union. Factors, responsible for that, are brought to date based on current literature and clinical observations.

Keywords: fracture repair, bone fracture, non-union, mechanical, infection, iatrogenic, mesenchymal stem cells (MSCs), immune control, pharmaceuticals, nutrition

1. Background

Healing of the bone fracture is a biological process that restores its continuity, mechanical properties, and structure. It bases on various cell lineages recruited, activated and regulated by molecular mediators, namely chemokines, growth factors, and cytokines, cooperating in a cascade of events aimed to fill the fracture gap with callus, which later on is remodeled into

mature bone. Thus, this process is, in fact, a regeneration, not healing, as its goal is to restore not only the bone's continuity but also its structure.

Clinically, healing manifests with remission of pain corresponding with gradually increasing stiffness enabling transduction of mechanical loads. Radiographically-with formation and remodeling of the callus in-between its gap. Monitoring of this process indicates the advance of the reparative processes.

2. Cellular aspects of fracture healing

From the histological point of view, restitution of the bone continuity proceeds due to accumulation and activation of mesenchymal stem cells (MSCs) that, transforming into osteoblasts and maturing into osteocytes, synthesize and release proteins forming the extracellular matrix (ECM).

In the vast majority of cases, MSCs that settle hematoma differentiate into chondrocytes. But revascularization, due to the ingrowth of blood vessels from the vasculature of the adjacent tissues, improves local oxygenation enabling the transformation of newly inflowing progenitors into osteoblasts that, maturing into osteocytes, initiate ossification forming bone cuff around the fracture gap. Starting from its periphery, it moves toward the center replacing the soft callus with woven bone [1, 2]. Later on, it's remodeling rebuilds the microarchitecture to the mature bone-cancellous or compact, depending on the type of the bone that was primarily at the fracture gap.

The described above process, the endochondral ossification, proceeds in ca. 97–98% of all fractures, whereas remaining 2–3% heal due to the direct osteonal growth in the process called primary bone healing basing on the intramembranous ossification [3]. The latter one is possible, when the volume of the fracture's gap is minimal, thus in non-displaced or impacted fractures only. In those cases, the short distance between bone fragments enables osteonal remodeling toward the fracture gap restoring its vascularization and mineralizing it.

MSCs reside several tissues, including bone marrow, endosteum, and periosteum. They are abundantly represented in adipose tissue surrounding the extremity with subcutaneous fat and form a subpopulation of its leukocytes in peripheral blood as well [4]. Thus, extravasated into posttraumatic hematoma and recruited from adjacent tissues they form a population of precursors for reparative processes.

Their accumulation proceeds due to chemotactic stimulation. Stromal-derived factor-1 (SDF-1; also known as CXC-motif chemokine 12: CXCL12) is one of the most potent attractants of MSCs. Widely distributed in bone marrow, it splits in-between neighboring tissues, when bone continuity is broken, recruiting progenitors that accumulate at the sites of its highest concentration, the fracture gap. Inflowing cells multiply under the mitogenic stimulation of platelet-derived growth factor (PDGF) [5].

MSCs are precursors of various cells of mesenchymal origin, including chondrocytes, fibroblasts, adipocytes, neurons, and myocytes. The direction of their differentiation depends upon molecular regulation and local physicochemical conditions. When stimulated improperly or

under unfavorable conditions, they may differentiate into, unwanted from the point of view of the fracture healing, cellular population forming cartilaginous or fibrous pseudoarthrosis.

Hypoxia, hypercapnia, and acidosis that characterize deprived of vasculature posttraumatic hematoma, promote their differentiation into chondrocytes, whereas higher oxygen tension and reduced acidosis-into osteoblasts [6].

3. Molecular stimulators of fracture repair

Four sources of molecular stimulators and regulators of bone healing could be distinguished:

1. Extravasated blood forming the posttraumatic hematoma
2. Traumatized bone and tissues neighboring it
3. Nerve endings at the adjacent tissues
4. Inflowing inflammatory cells

Platelets are the abundant source of molecular substances of blood origin. Released from granules into a posttraumatic hematoma, those substances activate, together with mediators released from nerve endings, and cellular events proceeding in the fracture gap.

Platelets participate in various reparative processes, being involved in the restoration of traumatized mucous and epithelia, healing various soft tissues (i.e. muscle) and the bone, and restoration of the vascularity in the process of angiogenesis. An influence of other hematoma products, including fibrin clot and activated clotting factors, hemoglobin, complement cascade and subcellular structures such as subcellular fragments of blood cells increases, giving an insight into a complex role of several hematoma compounds in the healing [7].

Traumatized tissues provide molecular stimuli that are released in response to injury. Damage-associated molecular pattern molecules (DAMPs) are the most potent activators of the sterile, traumatic inflammation ("first hit"), whereas the later one ("second hit") mostly depends on molecules provided by the inflowing immune cells. Those molecules activate immune system directly through toll-like receptors (TLRs) [8]. So far, several DAMPs have been distinguished, including heat-shock proteins (HSPs), high-mobility group box 1 (HMGB-1), monosodium urate, heparan sulfate, adenosine triphosphate (ATP), polysaccharides, proteoglycan, phospholipids, and deoxyribonucleic acid (DNA). Similar capabilities possess hyaluronian fragments released from disintegrated ECM [9, 10].

Nerve endings provide neuromediators that participate in fracture repair, including calcitonin gene-related peptide and neuropeptide-Y [11]. Released in response to mechanical (injury) and physicochemical (hypoxia, acidosis) stimuli, they participate in the molecular regulation of cellular events during the reparative phase and callus mineralization [12]. However, they were also found to control remodeling [13].

The later abundant source of molecular stimulators are leukocytes originating from the blood-forming hematoma and inflowing from the peripheral circulation. Granulocytes are the first

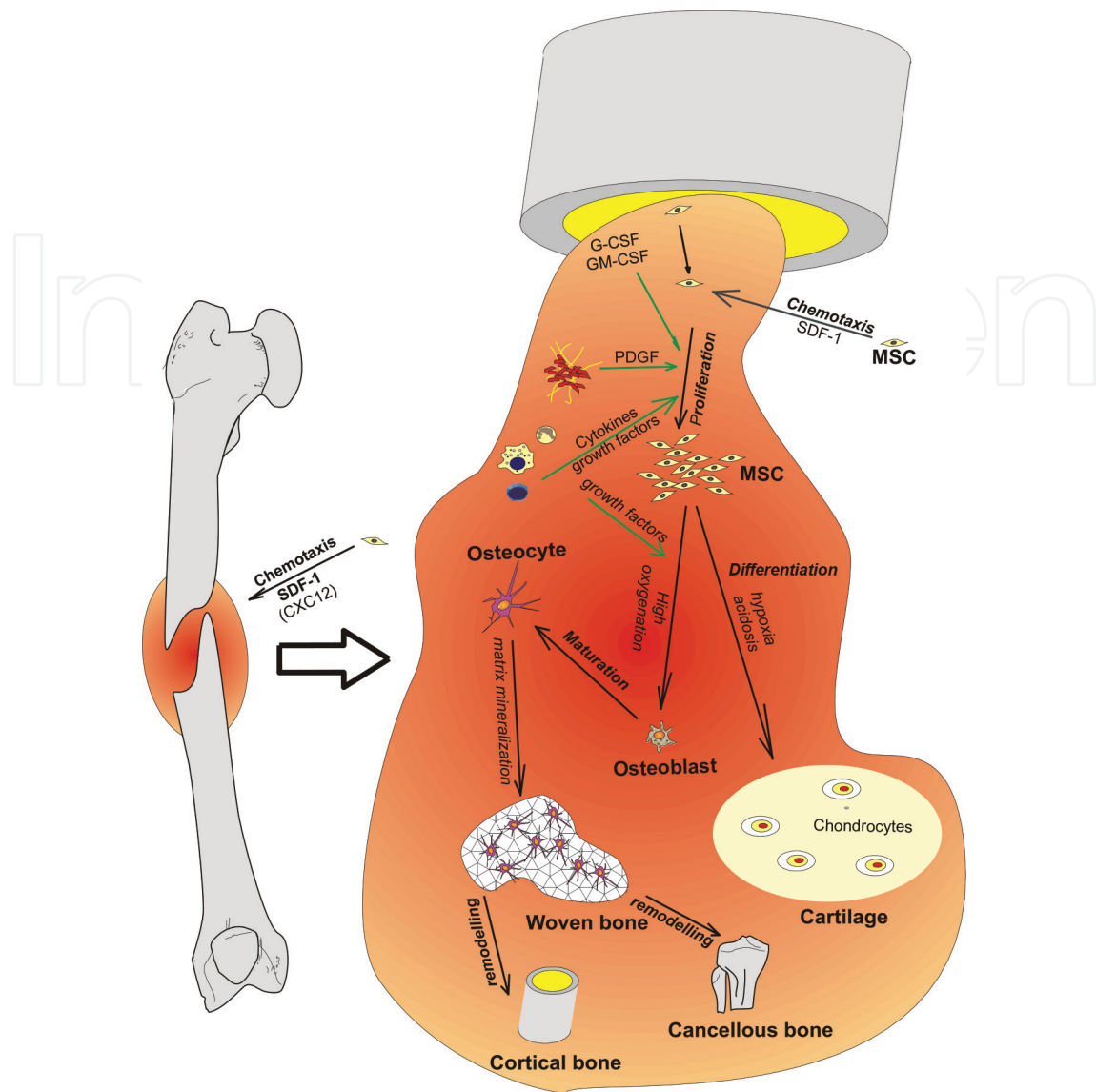


Figure 1. Schematic representation of recruitment, proliferation, multiplication, and differentiation of MSCs into osteoblasts or chondroblasts.

cellular population that actively populates the fracture gap. Those cells infiltrate the wound as early as at the sixth hour after injury providing its innate immune protection against pathogens, but also participating in reparative processes [14]. Being followed by lymphocytes and monocytes/macrophages they form an inflammatory phase of the healing cascade.

The significance of the inflammatory cells for the reparative processes is inappreciable, as they eradicate pathogens, remove wound debris and, partially, foreign bodies, but also supply the fracture gap with molecules regulating forthcoming cellular events. They also provide immune regulation of the healing, as the response of the lymph node draining the fracture gap was shown to reflect its cellular and molecular processes [35]. This mechanism seems to depend on regulatory B and T lymphocytes (B_{regs} and T_{regs}), as they were shown to participate in fracture healing. B_{regs} were presented to suppress the inflammatory phase secreting anti-inflammatory cytokines IL-10 (interleukin-10) and TGF- β (transforming growth factor- β), and enhancing maturation of T_{regs} [15]. At the early phase of the reparative processes, they

probably prevent from auto aggression against infiltrating progenitors, thus enabling them to proliferate and differentiate into bone forming cells. Depletion of B_{reg} cells, analogically to splenectomy, results in the delay of the fracture healing [16, 17]. Moreover, T cells were shown to promote maturation of the osteoblasts [18].

Immune cells are an ample source of several molecular substances, including cytokines (i.e. IL-6 and IL-8) and growth factors (PDGF, fibroblast growth factor; FGF, TGF- β , and bone morphogenetic proteins—BMPs) [19]. Together with molecules released from nerve endings and bone marrow, they regulate cellular events stimulating proliferation and differentiation of MSCs.

The most effective MSCs stimulators are the granulocyte colony-stimulating factor (G-CSF) and granulocyte-macrophage-colony-stimulating factor (GM-CSF), cytokines (IL-1, IL-3, IL-7, IL-8, and IL-12), stem cell factor (SCF), Flt3 (fms like tyrosine kinase 3) ligand, macrophage inflammatory protein-1 (MIP-1) and the chemokines GRO β (growth-regulated oncogene β ; also known as CXC-2) and SDF-1 [20, 21]. Each of them evokes the unique effect promoting migration, division, activating synthesis, and release of molecules forming an appropriate environment or fulfilling the specialized biological function. They enable migration, multiplication, and differentiation of progenitors into desired cell lineage. The most potent stimulators of MSCs differentiation into, according to the local physicochemical environment, chondrocytes, or osteoblasts are TGF- β , several BMPs (2, 4, 6, 7, 13, and 14), IGF-1 (insulin-like growth factor), and FGF [22, 23]. The final outcome in the form of fracture healing results from the convergent actions of numerous factors influencing the target cells in an appropriate time sequence and place (**Figure 1**).

4. Extracellular matrix mineralization

Mineralization of the ECM restores mechanical properties of the gap bringing back its ability to carry body weight. Briefly, it consists in the deposition of calcium and phosphate precipitates, hydroxyapatite, around the mesh of ECM proteins, namely collagens [24]. The process takes place in matrix vesicles; subcellular structures of approx. 20–200 nm in diameter that contains a number of compounds, including annexins (annexin V), alkaline phosphatase, calbindin-D9k, pyrophosphatases, carbonic anhydrase, AMP-ases, bone sialoprotein-1 (BSP-1), osteonectin, osteocalcin, and several growth factors [25].

Matrix vesicles concentrate inorganic substrates for mineralization due to annexin-formed calcium channels and Na/Pi phosphate transporters (NPT3/Pit1; natrium-phosphate transporter 3/POU domain class 1 transcription factor 1). High concentration of those ions results in their spontaneous precipitation to amorphous octa-Ca/Pi crystals that later on, when released from the vesicles, are converted by osteonectin, osteocalcin, and bone sialoprotein-1 (BSP-1) into hydroxyapatite. Hydroxyapatite crystals are deposited into the ECM at the outer and inner surface of the collagen fibrils [26]. In consequence, the collagen forming ECM being responsible for bone elasticity also serves as a scaffold for inorganic substances [27]. Their remodeling by matrix metalloproteinases sets the direction of trabecular bone remodeling, creating it is three-dimensional structure according to the direction of mechanical loads, and thus optimizing its micro-architecture for the most effective resistance [28, 29]. Finally, remodeling restores the structure of the primary callus to the mature bone identical to that primarily present at the fracture gap.

5. Remodeling

Remodeling proceeds in consequence of osteolysis and forthcoming osteogenesis. In the beginning, a group of activated osteoclasts, acidifying ECM, dissolve the osteoid and enzymatically (MMPs) digest its proteins. In consequence, resorptive (Howship) lacuna is formed.

Released molecules that are stored in the latent form bound to ECM heparan sulfate (BMPs, Vascular endothelial growth factor (VEGF), FGF, and EGF) activate proliferation and folding into three-dimensional structures of endothelial cells originating from neighboring blood vessels [30]. Those form vascular loops (sprouts) in-growing into the lacunae, providing its blood supply. Inflowing MSCs differentiate into osteoblasts that repopulate lacunae as osteocytes excreting ECM proteins and mineralizing them.

Osteoclasts at the top (cutting cone) gradually move across the bone as far as they reach its borderline (osteoclastic tunneling; remaining as Haversian canal), and finally undergo apoptosis. Passing across the fracture, they restore bone continuity (osteonal fracture healing), but only when the distance between bone fragments does not exceed 1 mm [31]. If the distance is higher, each bone fragment is remodeled alone and the fracture gap remains intact, that is not healed.

6. Uneventful and disturbed fracture healing

From the clinical point of view, the fracture is considered to be healed, when its mechanical properties are restored allowing carrying the body weight. Thus, the main indicators of successful healing are lack of the pathological mobility corresponding with a resolution of pain and restored the ability to carry mechanical loads confirmed by radiographic images showing callus mineralization and remodeling.

It was estimated that up to 15% of fractures display some kind of healing disturbances [32]. Depending on the severity of the pathological changes, it ranges from slow fracture healing (slow union), delayed union or non-union, if complete inhibition of the reparative processes occurs. The lack of union and the resultant non-union (pseudoarthrosis) are diagnosed when callus was not formed in-between bone fragments in an assumed period of time and all regenerative processes have stopped.

According to the recommendations of the food and drug administration, a non-union could be diagnosed, when the fracture is not healed in the 9th post-injury month, or any evidence of the healing progress could be observed on X-rays during the three consecutive months. However, the number of orthopedists that diagnose non-union as early as at the 6th post-fracture month implementing procedures that improve reparative processes increases. However, it is also believed that the time of the healing of a given bone should be determined arbitrarily, based on the clinical experience [33].

The varying opinions that concern the definition of disturbed fracture healing come from the lack of diagnostic tools that could demonstrate the moment of cessation of regenerative processes. The very important flaw of radiographic monitoring is the possibility to assess the status of the healing after a sufficiently long period of follow-up. Moreover, it does not allow predicting the final result.

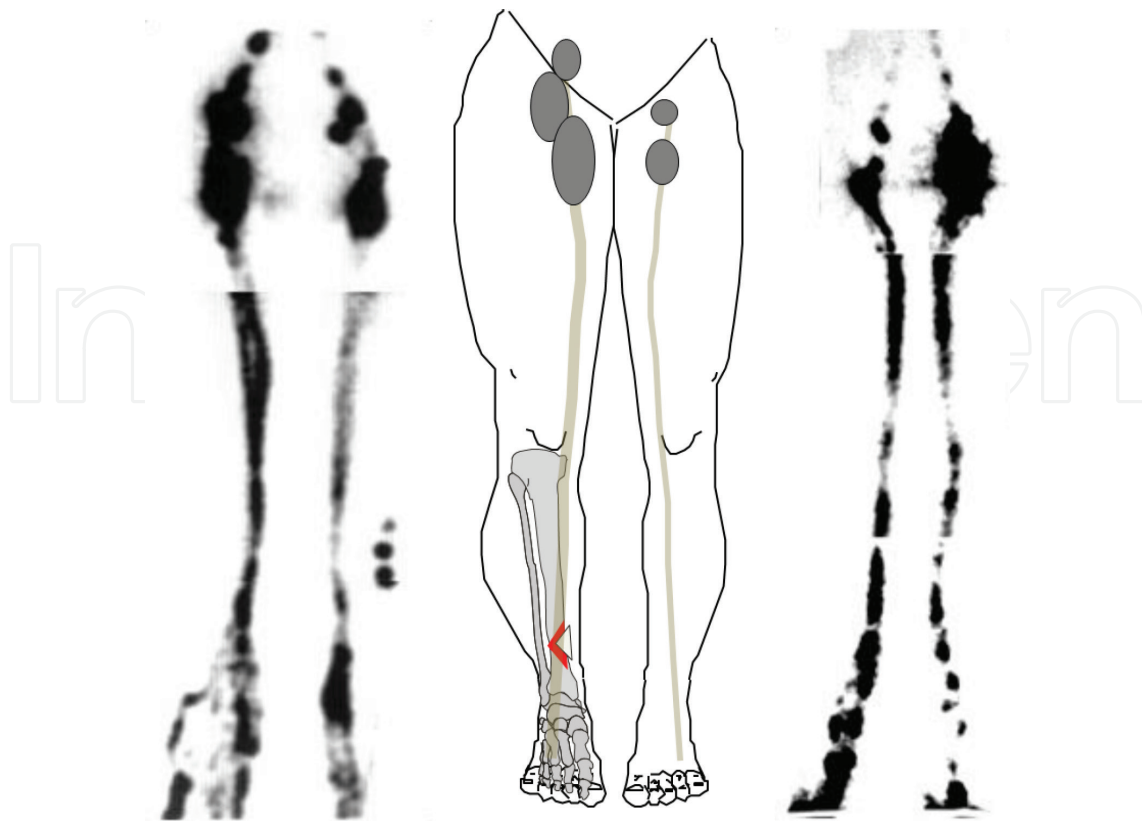


Figure 2. Lymphoscintigrams of the uneventful (left) and disturbed (right) healings of the fractures of the right extremities. Uneventful healing is characterized by enlarged regional lymph nodes and lymphatic outflow, when compared with contralateral limb. If the healing is disturbed, decreased lymph outflow, and regional lymph nodes, are observed.

The only examination that may be useful in the monitoring of the healing process and predicting its outcome is limb lymphoscintigraphy [34]. Observation of the lymphatic system showed that regional lymph node draining the fracture is a subject of molecules released from its gap. Thus, increased lymph drainage and enlargement of the lymph node (accumulation of cells) reflect molecular and cellular events taking place at the fracture gap that may be used as an indicator of the quality of reparative processes (**Figure 2**).

Uneventful healing may be divided into three phases:

1. Reactive- colonization of posttraumatic hematoma by inflammatory cells,
2. Reparative-replacement of hematoma with cartilaginous tissue and its endochondral ossification (primary callus),
3. Remodeling-formation of mature bone with the structure analogous to that prior to the fracture.

The first phase lasts up to several (3–7) days, the second up to 4 weeks and the third may last up to 2 (or even more) years after the fracture. However, the advance of the healing may differ even in adjacent areas; especially, when proceeds in comminuted fractures. In consequence, remodeling already proceeding in between some bone fragments may coexist with early, reactive phase between others.

Histologically, uneventful healing is characterized by soft callus filling the fracture gap in the 2nd week after injury (soft callus). In the 4th week, the callus should already be replaced by spongy bone (hard callus), and in the 8th week, the callus should be a subject of remodeling. Non-union is characterized by the lack of ossification at the 4th post-fracture week, despite the fact that similarly to uneventful healing, the fracture's gap is filled with an excess of cartilage "flowing" out of it. In the 8th week, young fibrous tissue with scarce and loose foci of cartilaginous tissue is observed and finally, the pseudoarthrosis is formed [35].

On a molecular level, there are no differences in the expression of PDGF, TGF- β , and FGF-2 in the 1st week after the fracture in both uneventfully and healing with delay fracture gaps. But in the 8th week, in contrary to uneventful healing, whose osteocytes express all these factors, none of them is expressed [36]. It was proved that lack of the mentioned above molecular stimuli leading to non-union could also be produced surgically removing tissues from the fracture gap that may result from repeated debridement or rinsing drainage [37].

7. Factors disturbing healing of the fracture

As the goal of reparative events is to fill the fracture gap with cells possessing osteogenic potential, the participation of their precursors, the MSCs, is crucial. As MSCs are widely distributed in the body, the risk of their deficiency is rather not feasible. Nevertheless, those cells exert some specific features that may reduce their number and activity.

First of all, they are very sensitive to unfavorable conditions, distinctly responding to inordinate mechanical stimuli, hypoxia, and malnutrition [38]. They are also very prone to injury, regardless of its mechanism: mechanical, thermal (burns, frostbites), chemical (acids, bases, toxins), electric, or radiative. Thus, massive traumatization of tissues neighboring the fracture deprives them of progenitors resulting in cessation of reparative processes. Moreover, their loss, exposing the bone to the outer environment, favors its drying that promotes intravascular coagulation depriving the fracture of blood supply. Also, iatrogenic injuries, including vast surgical approach, wide periosteal stripping, excessive cauterization, or just brutal operative technique, superimpose traumatic changes impairing the healing.

Second of all, removal or drainage of hematoma or cellular infiltrates from the fracture, especially, when performed repeatedly, deprives it of molecular regulators [7].

Third of all, under hypoxia MSCs have been shown to differentiate into chondrocytes, instead of osteoblasts. This process, being natural at early stages of reparative processes, when prolonged, results in the formation of cartilaginous pseudoarthrosis. The problem usually occurs, when the fracture is immobilized inadequately or is not immobilized at all, as excessive movements between bone fragments disrupt newly formed vasculature depriving it of blood supply [39].

An especially unappreciated is the contribution of the shock in the cessation of fracture gap perfusion. Centralizing the circulation to protect the circulation of vital organs, it deprives the perfusion of peripheral tissues, including the fractured gap and surrounding it tissues [40]. When prolonged, shock aggravates tissue injury, impairs the healing, and increases the risk of

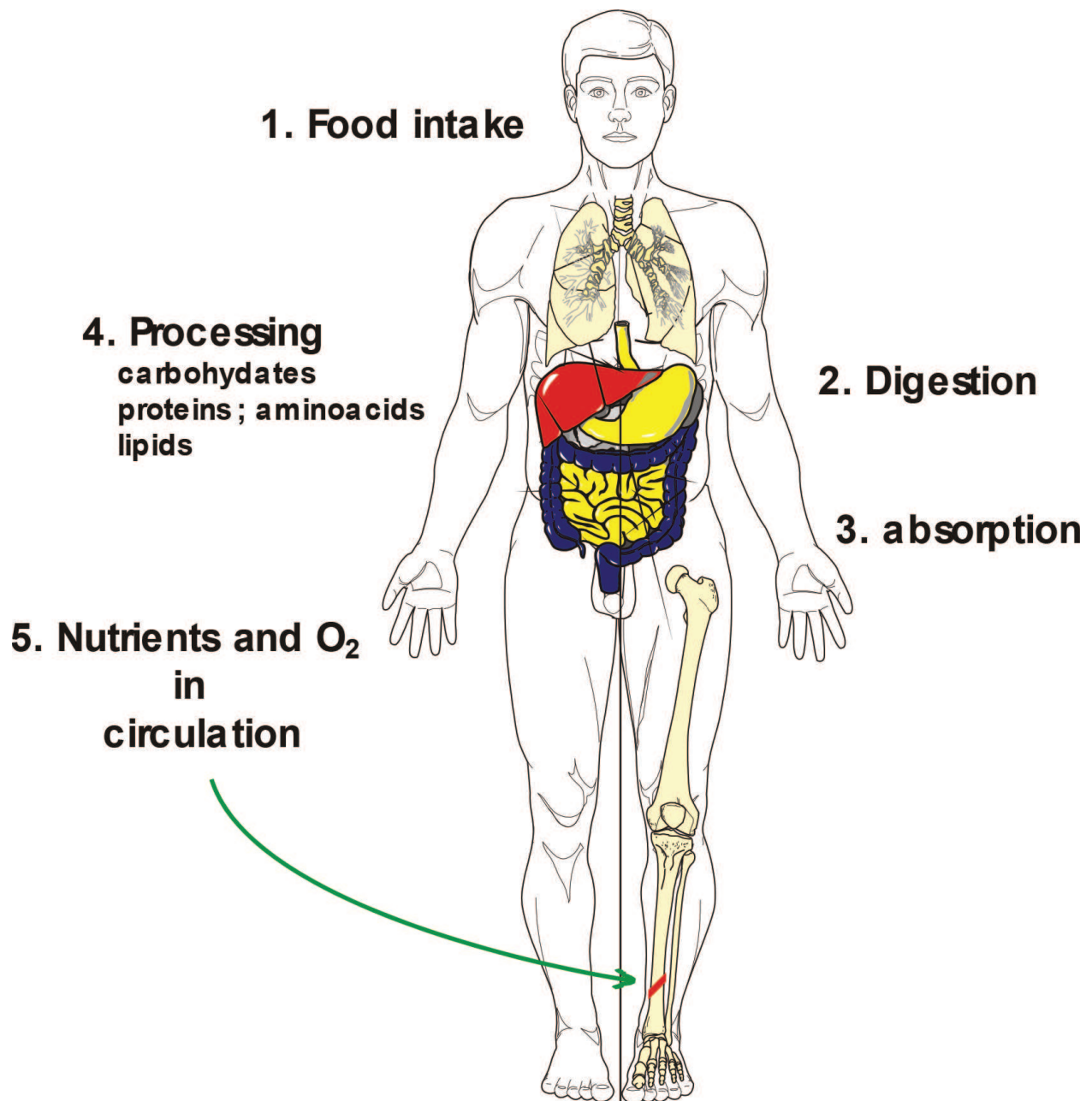


Figure 3. Oxygenation and nourishment of the fracture gap.

infection [41, 42]. An inadequate blood supply may also originate from central cardiovascular (stroke, cardiac arrest) insufficiency and peripheral vascular (i.e. atherosclerosis, venous thrombosis) diseases [43] (**Figure 3**).

Satisfactory healing requires an appropriate oxygenation and nutrition. Bone fracture corresponds with the disruption of its vasculature leading to the necrosis of 5 to 10 mm-width bone fragments adjacent to the fracture gap [44]. The area of necrosis may spread on the damage of the neighboring soft tissues, cardiovascular insufficiency (decompensated heart failure, arterial damage, or occlusion, venous thrombosis), anemia, or infection [45, 46]. Hypothermia also exerts an impact on local circulation constricting blood vessels [47].

Properly balanced diet provides all the nutrients, vitamins, and minerals that are necessary for healing. In case of bone fracture, an attention has to be paid over calcium, phosphates (osteoid formation), proteins (source of amino acids for collagen synthesis), and vitamin D₃ that may, in some cases, require supplementation.

Starvation is nowadays relatively seldom in developed societies, whose overweight and obese population alarmingly increases. Nevertheless, it could not be forgotten that it pertains only ca one-fourth of the Earth's population, whereas the next three-fourth suffers from hunger. Moreover, starvation and malnutrition may result from other than just a food shortage, reasons.

At the risk are especially elder, handicapped (also mentally) persons, drugs or alcohol abused, patients suffering from anorexia, and all others suffering from disturbed food intake, digestion, absorption, or processing. Thus, at risk are all those suffering from various digestive disorders, including short bowel syndrome, Hirschsprung's or Crohn's diseases, liver cirrhosis, pancreatitis and many others. Diabetes also leads to some type of starvation, as intracellular hypoglycemia deprives cells of glucose, the most important source of energy [48].

An increasing number of population implementing restrictive diet to reduce the body weight may present various nutritional deficiencies. Nevertheless, so far any religious (i.e. exclusion from the diet some kind of a meat) nor ideological (i.e. growing population of vegetarians and vegans) dietary restrictions nor customs were reported to influence bone healing. However, their negative insult, especially on young individuals, should be considered [49].

7.1. Habits disturbing healing of the fracture

Several habits affect the healing. Entering hundreds of detrimental substances, including highly toxic and carcinogenic ones, smoking impairs the function of progenitor cells, impairs local circulation, and reduces hemoglobin oxygenation disturbing reparative processes [50]. Alcohol was also shown to evoke its negative impact, but in small quantities may be beneficial supporting the fracture energetically and improving its perfusion [51, 52].

Several other addictions, including opioids, cannabinoids, and psychostimulants, indirectly influence the healing trajectories degrading the patient's psychosomatic status, and thus resulting in poverty, homelessness, malnourishment, and increased susceptibility to infections and additional injuries. Addicted persons have also limited access to health services, both due to social and economic reasons, and their irrational behavior. Moreover, some of them are not interested in successful treatment at all, as complications, when occur ease them to obtain social support.

7.2. Mechanical aspects of fracture healing

Immobilization and stabilization of bone fragments after their anatomical repositioning provide an optimal mechanical environment for the healing. Thus, casts splints, and orthopedic implants are the most effective methods of treatment.

They provide an optimal, biomechanical environment to the fracture gap, as excessive interfragmentary movements disrupt callus' vasculature. Newly formed blood vessels, built with the single layer of endothelial cells only, are very fragile. Irrespective of the direction (by side,

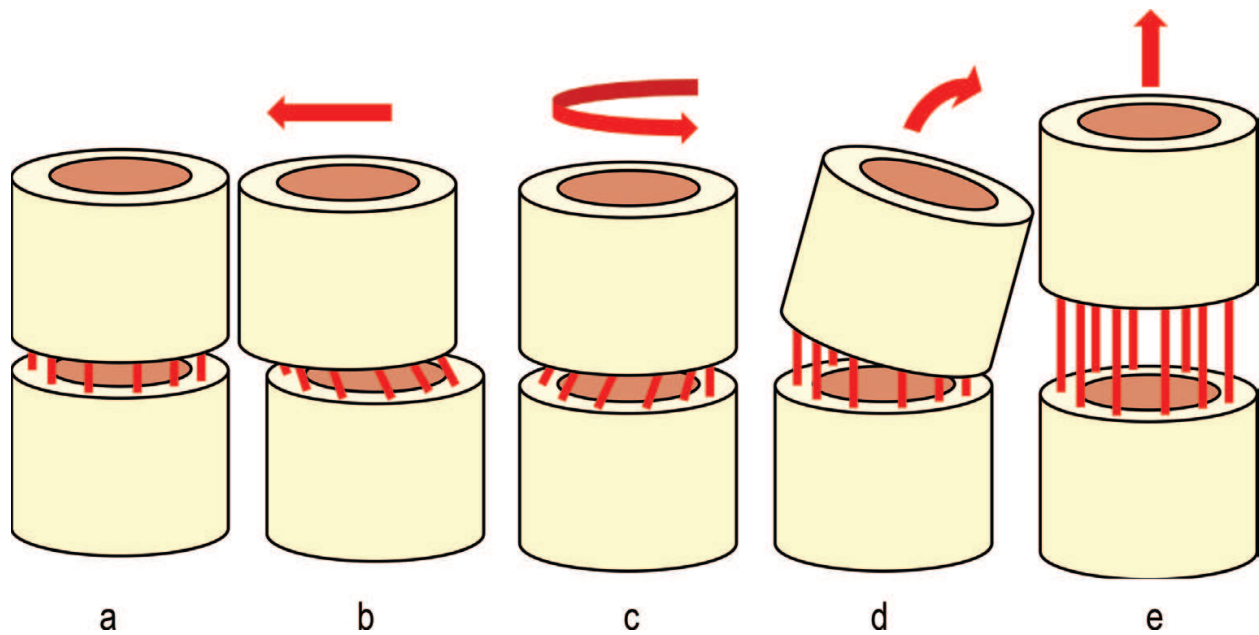


Figure 4. Fracture gap and its newly formed vasculature (red lines; a) dislocated by-side (b), rotation (c), angulation (d) and controlled axial movements (e).

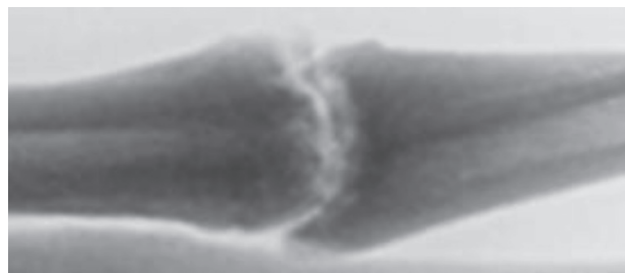


Figure 5. Hypertrophic non-union of the non-stabilized fracture.

angular, rotation or distraction), displacements disrupt the microvasculature that deprives the fracture of blood supply arresting the healing at the phase of cartilage ossification (**Figure 4**). In consequence, the cartilaginous pseudoarthrosis is formed presenting an abundant callus formation, the hypertrophic non-union [53]. It is usually observed in not immobilized fractures, but may also occur in stabilized ones due to implant's destruction (**Figure 5**).

However, rigid fixation precluding movements between bone fragments deprives them of mechanical stimuli that promote osteoblastogenesis [54]. Optimal amplitude of axial movements is below 1 mm, as those are beneficial for osteogenesis, but do not disrupt the blood supply. Other dislocations are detrimental.

It was shown that an excessive distance between bone fragments leads to the cessation of reparative processes leading to non-union [55]. The contact between bone fragments is reduced by a half when translocation reaches 6% of the bone's diameter or five degrees of angulation. Moreover, decreasing cortical thickness that characterizes osteoporotic bone aggravates the loss of interfragmentary contact (**Figure 6a-c**). That leads to the conclusion that fractures require accurate repositioning, especially osteoporotic ones [56].

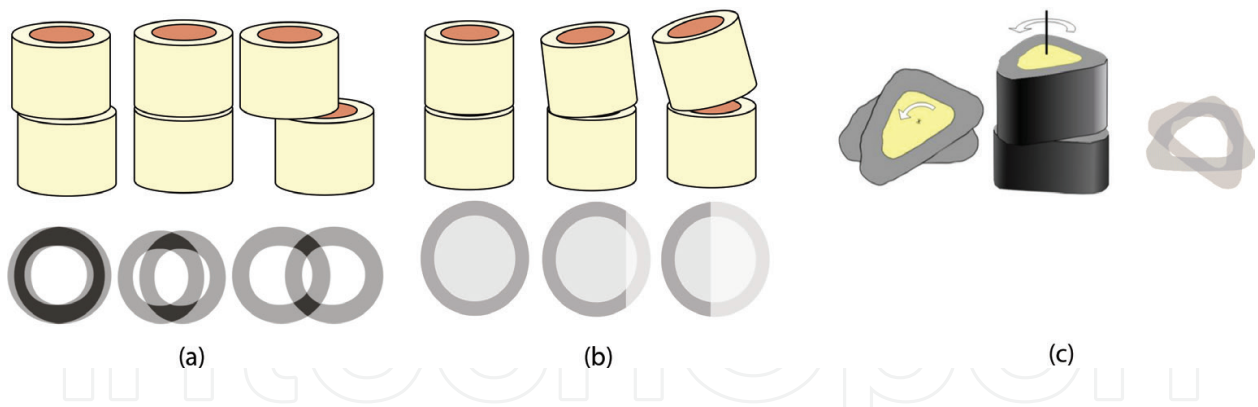


Figure 6. (a) An influence of by-side dislocations between bone fragments on bone contact. (b) An influence of angular dislocations between bone fragments on bone contact. (c) An influence of rotation between bone fragments on bone contact.

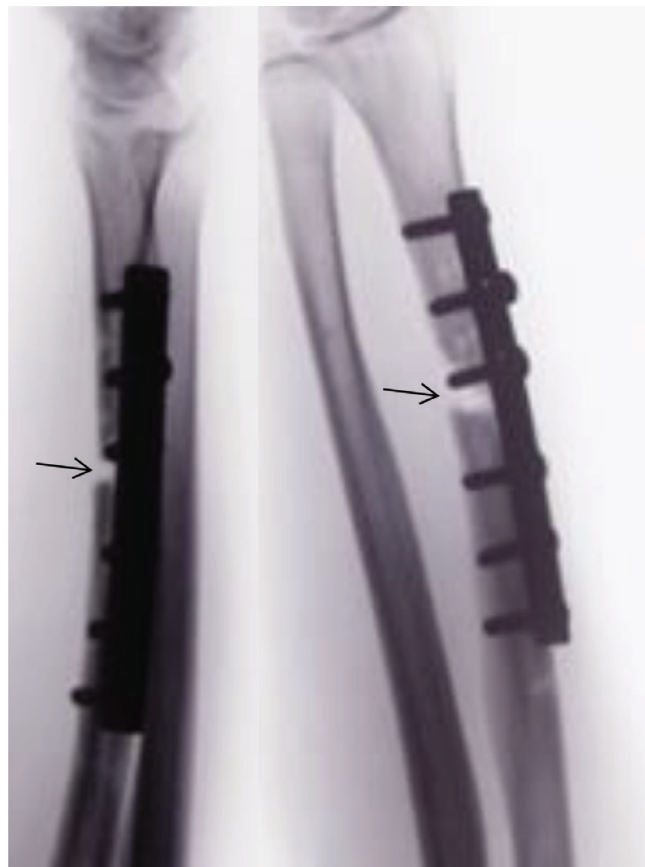


Figure 7. An inappropriate reduction of the fracture; Lack of the contact between bone fragments and screw situated in-between the fracture gap (arrows) disturb the healing.

To enable healing, the maximal distance between bone fragments should not exceed 1 mm, although the minimal is the best (**Figure 7**). Compression, shortening the distance between bone fragments, is nowadays implemented under several treatment modalities including

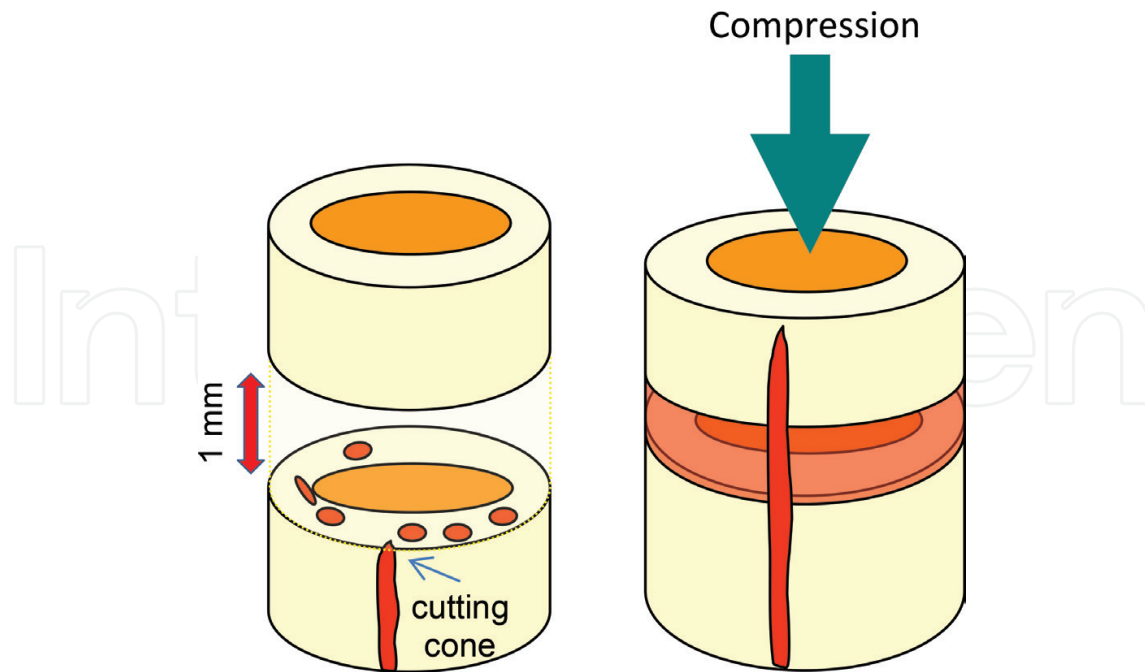


Figure 8. Schematic representations showing the role of compression of the fracture gap in bone healing.

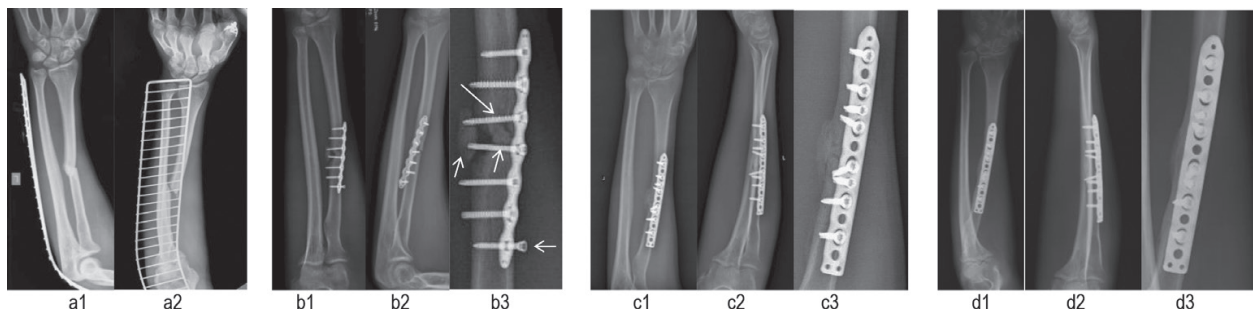


Figure 9. Disturbed healing due to an inadequate stabilization of the comminuted fracture of the left radius shaft in 26-years-old male. The fracture (a1 and a2) was primarily stabilized with the interlocking plate (b1 and b2), but lack of the contact between one of its intermediate fragments precluded the healing. Moreover, mechanical stability was not obtained, as both proximal and distal fragments were stabilized practically with two screws only. The third and the fourth screws situated in-between the fracture gap, were mechanically inefficient and foreclosing the healing; the seventh' was not screwed in at all (b3). Five months later, due to the lack of the progress of the healing (b), the fracture was revised, the fibrous scar was removed and marrow cavity was refreshed, bone fragments were reduced anatomically and stabilized with interlocking plate using four screws for each main fragment. Uneventful healing was observed on X-rays made on the 7th (c) and 12th (d) months after reoperation. Progressive healing (c3) and satisfactory remodeling (d3) were being observed.

compression screws and plates, pre-bending of Arbeitsgemeinschaft für Osteosynthesefragen (AO) plates, intramedullary and external stabilizations and so on [57]. Moreover, it mechanically stimulates osteogenesis (**Figure 8**).

Interposition of soft tissues or foreign material in-between bone fragments forms the barrier that precludes restoration of bone's continuity (**Figure 9**).

7.3. Pharmacotherapy

The negative impact of several pharmaceuticals on healing processes was reported, including chemotherapeutics, antimicrobial drugs, steroids, heparins and antiresorptive drugs.

Chemotherapeutics are toxic to MSCs, reducing their number and activity and thus, depriving the fracture of osteoblastic progenitors. Their influence is aggravated by radiotherapy that is regularly used to treat neoplasms. Together with changed metabolism evoked by the tumor itself, those impair the healing.

Antibiotics were reported to affect the healing despite their beneficial capabilities to control infection. Tetracyclines were shown to impair ossification, thus arresting skeletal growth and fracture healing. Moreover, their negative impact prolongs for years, as bound with osteoid they impair bone remodeling decreasing its mechanical strength and thus, increase the risk of forthcoming fractures. Beta-lactams and cephalosporins, as well as ciprofloxacin, clindamycin, rifampicin, macrolides, and many others, and also evoke their negative impact. Their usage is justified as far as the positive antimicrobial effect is rationalized, that is weighed against negative influence on the reparative processes [58].

Corticosteroids, used in asthma, rheumatoid and dermatologic diseases, demineralize skeleton resulting in steroid-induced osteoporosis. In consequence, increased susceptibility to fractures, but also their impaired healing and remodeling, occur. Moreover, their chronic use threatens the bone viability bringing the risk of steroid-induced osteonecrosis [59]. Nevertheless, those unwanted side effects could easily be controlled modifying the route of administration and reducing their doses [60]. Analogically, nonsteroidal, anti-inflammatory drugs (NSAIDs), widely used analgesics, disturb reparative processes, usually expressing their negative influence, when chronically used at high doses [51]. Antihistamines were also reported to affect the healing [61].

Heparins, regularly used in trauma surgery for antithrombotic prophylaxis, are known to bind several growth factors including TGF- β and BMPs, FGF and EGF, decreasing their bioavailability for reparative processes [30]. Bisphosphonates, antiresorptive drugs dedicated for treatment of osteoporosis and prevention of fragility fractures, impair bone remodeling and healing, but also bring the risk of atypical fractures [62].

Other drugs were also shown to evoke negative impact on the bone union, including those used in the treatment of hypertension. Captopril, for instance, hinders angiogenesis and collagen deposition [63] and beta blockers affect wound healing through disturbed fibroblast proliferation [64].

7.4. Infection

Pathogens, colonizing the fracture gap, compete with its cells for nutrients, oxygen, and growth regulators depriving them of substances that are necessary for reparative processes. Moreover, hypoxia turns progenitor's differentiation into chondroblastic cell lineage, and pathogen-associated molecular patterns activate immune response aggravating the risk of non-union [65].

Unfortunately, eradication of microbes from the fracture gap is very hard, at least due to limited blood perfusion and poor antibiotic penetration. Moreover, they produce biofilms that protect them from recognition and counteraction by the immune system and antibiotics [66].

8. Final remarks

Healing of the bone fracture is a biological process that proceeds due to the cooperation of various cell lineages under the control of the molecular regulators. Since, it bases on mechanisms that were validated during skeletogenesis, everyone, who developed the skeleton properly, possess the mechanisms that enable him to heal the fracture. Thus, our role is just to provide optimal conditions for those natural mechanisms (**Figure 10**).

From the clinical point of view, an adequate supply of oxygen, nutrients, minerals, and vitamins under an appropriate biomechanical environment are the most important, as they enable those natural, biological mechanisms, to proceed uneventfully. Thus, fracture immobilizations or stabilizations, rational nourishment, improving circulation and local blood perfusion, withholding smoking, reducing alcohol intake, and rationalizing pharmaceutical medication are among the most effective activities that improve the healing. Factors that positively and negatively affect it were discussed above giving the clear suggestions for effective treatment. Unfortunately, several of them could not be corrected or just are above our limits. Nevertheless, in the vast majority of cases, one can introduce the treatment that could reduce of the risk non-union.

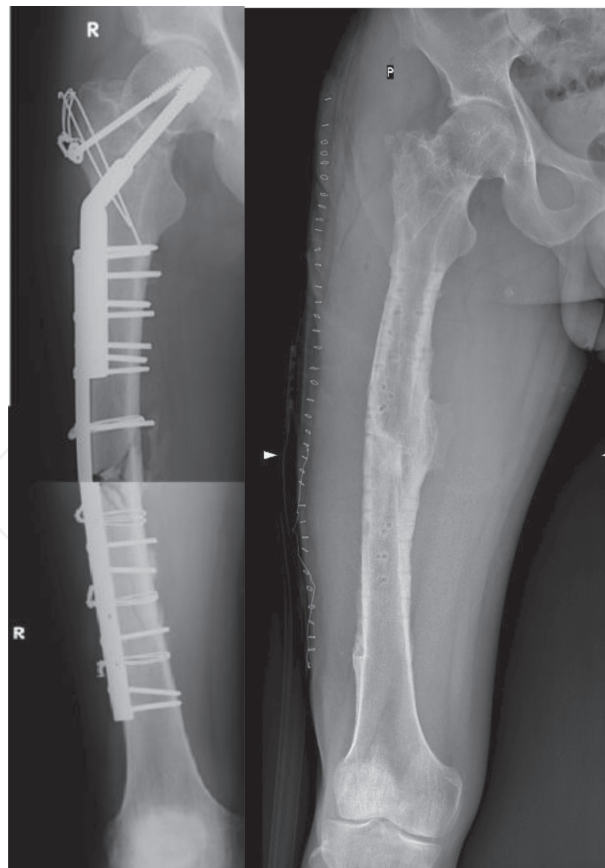

Figure 10. Comminuted, multiple-level fractures of the right femur in 41-years-old male (femoral neck, trochanteric, and the shaft) anatomically reduced and stabilized operatively. The final result (36 months) showing satisfactory bone union at all fractures after implants removal.

Author details

Grzegorz Szczyński

Address all correspondence to: 501167475@orange.pl

Department of Orthopedic Surgery and Traumatology, Medical University, Warsaw, Poland

References

- [1] Kolar P, Gaber T, Perka C, Duda GN, Buttgerit F. Human early fracture hematoma is characterized by inflammation and hypoxia. *Clinical Orthopaedics and Related Research*. 2011;**469**(11):3118-3126
- [2] Grayson WL, Zhao F, Bunnell B, Ma T. Hypoxia enhances proliferation and tissue formation of human mesenchymal stem cells. *Biochemical and Biophysical Research Communications*. 2007;**358**:948-953
- [3] Thompson Z, Miclau T, Hu D, Helms JA. A model for intramembranous ossification during fracture healing. *Journal of Orthopaedic Research*. 2002;**20**(5):1091-1098
- [4] Wang X, Wang Y, Gou W, Lu Q, Peng J, Lu S. Role of mesenchymal stem cells in bone regeneration and fracture repair: A review. *International Orthopaedics*. 2013;**37**(12):2491-2498
- [5] Edderkaoui B. Potential role of chemokines in fracture repair. *Front Endocrinol (Lausanne)*. 2017;**8**:39
- [6] Shang J, Liu H, Li J, Zhou Y. Roles of hypoxia during the chondrogenic differentiation of mesenchymal stem cells. *Current Stem Cell Research & Therapy*. 2014;**9**(2):141-147
- [7] Shiu HT, Leung PC, Ko CH. The roles of cellular and molecular components of a hematoma at early stage of bone healing. *Journal of Tissue Engineering and Regenerative Medicine*. 2018;**12**(4):e1911-e1925
- [8] Piccinini AM, Midwood KS. DAMPening inflammation by modulating TLR signalling. *Mediators of Inflammation*. 2010;**2010**:672395. DOI: 10.1155/2010/672395
- [9] Yu L, Wang L, Chen S. Endogenous toll-like receptor ligands and their biological significance. *Journal of Cellular and Molecular Medicine*. 2010;**14**(11):2592-2603
- [10] Jiang D, Liang J, Noble PW. Hyaluronan in tissue injury and repair. *Annual Review of Cell and Developmental Biology*. 2007;**23**:435-461
- [11] Gu XC, Zhang XB, Hu B, Zi Y, Li M. Neuropeptide Y accelerates post-fracture bone healing by promoting osteogenesis of mesenchymal stem cells. *Neuropeptides*. 2016;**60**:61-66
- [12] Onuoha GN. Circulating sensory peptide levels within 24 h of human bone fracture. *Peptides*. 2001;**22**(7):1107-1110

- [13] Konttinen Y, Imai S, Suda A. Neuropeptides and the puzzle of bone remodeling. State of the art. *Acta Orthopaedica Scandinavica*. 1996;**67**(6):632-639
- [14] de Oliveira S, Rosowski EE, Huttenlocher A. Neutrophil migration in infection and wound repair: Going forward in reverse. *Nature Reviews Immunology*. 2016;**16**(6):378-391
- [15] Sun G, Wang Y, Ti Y, Wang J, Zhao J, Qian H. Regulatory B cell is critical in bone union process through suppressing proinflammatory cytokines and stimulating Foxp3 in Treg cells. *Clinical and Experimental Pharmacology & Physiology*. 2017;**44**(4):455-462
- [16] Yang S, Ding W, Feng D, Gong H, Zhu D, Chen B, Chen J. Loss of B cell regulatory function is associated with delayed healing in patients with tibia fracture. *APMIS*. 2015;**123**(11):975-985
- [17] Xiao W, Hu Z, Li T, Li J. Bone fracture healing is delayed in splenectomic rats. *Life Sciences*. 2017;**173**:55-61
- [18] Nam D, Mau E, Wang Y, Wright D, Silkstone D, Whetstone H, Whyne C, Alman B. T-lymphocytes enable osteoblast maturation via IL-17F during the early phase of fracture repair. *PLoS One*. 2012;**7**(6):e40044
- [19] Szczesny G. Molecular aspects of bone healing and remodeling. *Polish Journal of Pathology*. 2002;**53**(3):145-153
- [20] Fu S, Liesveld J. Mobilization of hematopoietic stem cells. *Blood Reviews*. 2000;**14**:205-218
- [21] Mayani H, Alvarado-Moreno JA, Flores-Guzma'n P. Biology of human hematopoietic stem and progenitor cells present in circulation. *Archives of Medical Research*. 2003;**34**:476-488
- [22] Yu D-A, Han J, Kim B-S. Stimulation of chondrogenic differentiation of mesenchymal stem cells. *International Journal of Stem Cells*. 2012;**5**(1):16-22
- [23] Birmingham E, Niebur GL, McHugh PE, Shaw G, Barry FP, McNamara LM. Osteogenic differentiation of mesenchymal stem cells is regulated by osteocyte and osteoblast cells in a simplified bone niche. *European Cells & Materials*. 2012;**23**:13-27
- [24] Nudelman F, Pieterse K, George A, Bomans PH, Friedrich H, Brylka LJ, Hilbers PA, de With G, Sommerdijk NA. The role of collagen in bone apatite formation in the presence of hydroxyapatite nucleation inhibitors. *Nature Materials*. 2010;**9**(12):1004-1009
- [25] Nahar NN, Missana LR, Garimella R, Tague SE, Anderson HC. Matrix vesicles are carriers of bone morphogenetic proteins (BMPs), vascular endothelial growth factor (VEGF), and noncollagenous matrix proteins. *The Journal of Bone and Mineral Metabolism*. 2008;**26**(5):514-519
- [26] Wuthier RE, Lipscomb GF. Matrix vesicles: Structure, composition, formation and function in calcification. *Frontiers in Bioscience*. 2011;**17**:2812-2902
- [27] Bala Y, Depalle B, Douillard T, Meille S, Clément P, Follet H, Chevalier J, Boivin G. Respective roles of organic and mineral components of human cortical bone matrix

- in micromechanical behavior: An instrumented indentation study. *Journal of the Mechanical Behavior of Biomedical Materials*. 2011;**4**(7):1473-1482
- [28] Mahamid J, Sharir A, Gur D, Zelzer E, Addadi L, Weiner S. Bone mineralization proceeds through intracellular calcium phosphate loaded vesicles: A cryo-electron microscopy study. *Journal of Structural Biology*. 2011;**174**(3):527-535
- [29] Golub EE. Role of matrix vesicles in biomineralization. *Biochimica et Biophysica Acta*. 1790;**2009**:1592-1598
- [30] Rider CC, Mulloy B. Heparin, heparan sulphate and the TGF- β cytokine superfamily. *Molecules*. 2017;**22**(5):713
- [31] Garcia P, Holstein JH, Maier S, Schaumlöffel H, Al-Marrawi F, Hannig M, Pohlemann T, Menger MD. Development of a reliable non-union model in mice. *The Journal of Surgical Research*. 2008;**147**(1):84-91
- [32] Einhorn TA, Lane JM. Significant advances have been made in the way surgeons treat fractures. *Clinical Orthopaedics and Related Research*. 1998;**355**:S2-S3
- [33] Gerstenfeld LC, Cullinane DM, Barnes GL, Graves DT, Einhorn TA. Fracture healing as a post-natal developmental process: Molecular, spatial, and temporal aspects of its regulation. *Journal of Cellular Biochemistry*. 2003;**88**:873-884
- [34] Szczęsny G, Olszewski WL, Górecki A. Lymphoscintigraphic monitoring of the lower limb lymphatic system response to bone fracture and healing. *Lymphatic Research and Biology*. 2005;**3**(3):137-145
- [35] Szczęsny G, Olszewski WL, Gewartowska M, Zaleska M, Górecki A. The healing of tibial fracture and response of the local lymphatic system. *The Journal of Trauma*. 2007;**63**(4):849-854
- [36] Brownlow HC, Reed A, Simpson AH. Growth factor expression during the development of atrophic non-union. *Injury*. 2001;**32**:519-524
- [37] Sang-Hyun P, Mauricio S, Won-Jong B, Harry MK, Lieberman Jay R. Effect of repeated irrigation and debridement on fracture healing in an animal model. *Journal of Orthopaedic Research*. 2002;**20**(6):1197-1204
- [38] Ejtehadifar M, Shamsasenjan K, Movassaghpour A, Akbarzadehlaleh P, Dehdilani N, Abbasi P, Molaeipour Z, Saleh M. The effect of hypoxia on mesenchymal stem cell biology. *Advanced Pharmaceutical Bulletin*. 2015;**5**(2):141-149
- [39] Reed AA, Joyner CJ, Isefuku S, Brownlow HC, Simpson AH. Vascularity in a new model of atrophic nonunion. *Journal of Bone and Joint Surgery. British Volume (London)*. 2003;**85**(4):604-610
- [40] Wichmann MW, Arnoczky SP, DeMaso CM, Ayala A, Chaudry IH. Depressed osteoblast activity and increased osteocyte necrosis after closed bone fracture and hemorrhagic shock. *The Journal of Trauma*. 1996;**41**(4):628-633

- [41] Dickson K, Katzman S, Delgado E, Contreras D. Delayed unions and nonunions of open tibial fractures correlation with arteriography results. *Clinical Orthopaedics and Related Research*. 1994;**302**:189-193
- [42] Hausman MR, Rinker BD. Intractable wounds and infections: The role of impaired vascularity and advanced surgical methods for treatment. *American Journal of Surgery*. 2004;**187**(5A):44S-55S
- [43] Zura R, Braid-Forbes MJ, Jeray K, Mehta S, Einhorn TA, Watson JT, Della Rocca GJ, Forbes K, Steen RG. Bone fracture nonunion rate decreases with increasing age: A prospective inception cohort study. *Bone*. 2017;**95**:26-32
- [44] Lane JM. *Fracture Healing*. New York: Churchill Livingstone; 1987
- [45] Gruson KI, Aharonoff GB, Egol KA, Zuckerman JD, Koval KJ. The relationship between admission hemoglobin level and outcome after hip fracture. *Journal of Orthopaedic Trauma*. 2002;**16**(1):39-44
- [46] Kirkeby OJ, Berg LT. Regional blood flow and strontium-85 incorporation rate in the rat hindlimb skeleton. *Journal of Orthopaedic Research*. 1991;**9**:862-868
- [47] Venjakob AJ, Vogt S, Stöckl K, Tischer T, Jost PJ, Thein E, Imhoff AB, Anetzberger H. Local cooling reduces regional bone blood flow. *Journal of Orthopaedic Research*. 2013;**31**(11):1820-1827
- [48] Gortler H, Rusyn J, Godbout C, Chahal J, Schemitsch EH, Nauth A. Diabetes and healing outcomes in lower extremity fractures: A systematic review. *Injury*. 2018;**49**(2):177-183
- [49] Ho-Pham LT, Vu BQ, Lai TQ, Nguyen ND, Nguyen TV. Vegetarianism, bone loss, fracture and vitamin D: A longitudinal study in Asian vegans and non-vegans. *European Journal of Clinical Nutrition*. 2012;**66**(1):75-82
- [50] Sloan A, Hussain I, Maqsood M, Eremin O, El-Sheemy M. The effects of smoking on fracture healing. *The Surgeon*. 2010;**8**(2):111-116
- [51] Richards CJ, Graf KW Jr, Mashru RP. The effect of opioids, alcohol, and nonsteroidal anti-inflammatory drugs on fracture union. *The Orthopedic Clinics of North America*. 2017;**48**(4):433-443
- [52] Gaddini GW, Turner RT, Grant KA, Iwaniec UT. Alcohol: A simple nutrient with complex actions on bone in the adult skeleton. *Alcoholism, Clinical and Experimental Research*. 2016;**40**(4):657-671
- [53] Jagodziński M, Krettek C. Effect of mechanical stability on fracture healing—An update. *Injury—International Journal of the Care of the Injured*. 2007;**38**S1:S3-S10
- [54] Wang J, Wang CD, Zhang N, Tong WX, Zhang YF, Shan SZ, Zhang XL, Li QF. Mechanical stimulation orchestrates the osteogenic differentiation of human bone marrow stromal cells by regulating HDAC1. *Cell Death & Disease*. 2016;**7**:e2221

- [55] Mehta M, Schell H, Schwarz C, Peters A, Schmidt-Bleek K, Ellinghaus A, Bail HJ, Duda GN, Lienau J. A 5-mm femoral defect in female but not in male rats leads to a reproducible atrophic non-union. *Archives of Orthopaedic and Trauma Surgery*. 2011;**131**(1):121-129
- [56] Szczyński G. Analysis of the influence of bone fragment displacement in long bone fractures on interfragmentary contact surface. *Polish Orthopedics and Traumatology*. 2012;**77**:151-155
- [57] Fisher WD, Hamblen DL. Problems and pitfalls of compression fixation of long bone fractures: A review of results and complications. *Injury*. 1978;**10**(2):99-107
- [58] Kallala R, Graham SM, Nikkiah D, Kyrkos M, Heliotis M, Mantalaris A, Tsiridis E. In vitro and in vivo effects of antibiotics on bone cell metabolism and fracture healing. *Expert Opinion on Drug Safety*. 2012;**11**(1):15-32
- [59] Kerachian MA, Séguin C, Harvey EJ. Glucocorticoids in osteonecrosis of the femoral head: A new understanding of the mechanisms of action. *The Journal of Steroid Biochemistry and Molecular Biology*. 2009;**114**(3-5):121-128
- [60] Boursinos LA, Karachalios T, Poultsides L, Malizos KN. Do steroids, conventional non-steroidal anti-inflammatory drugs and selective Cox-2 inhibitors adversely affect fracture healing? *Journal of Musculoskeletal & Neuronal Interactions*. 2009;**9**(1):44-52
- [61] Freedberg DE, Haynes K, Denburg MR, Zemel BS, Leonard MB, Abrams JA, Yang YX. Use of proton pump inhibitors is associated with fractures in young adults: A population-based study. *Osteoporosis International*. 2015;**26**(10):2501-2507
- [62] Kharwadkar N, Mayne B, Lawrence JE, Khanduja V. Bisphosphonates and atypical subtrochanteric fractures of the femur. *Bone and Joint Research*. 2017;**6**(3):144-153
- [63] Qiu JG, Factor S, Chang TH, Knighton D, Nadel H, Levenson SM. Wound healing: Captopril, an angiogenesis inhibitor, and *Staphylococcus aureus* peptidoglycan. *The Journal of Surgical Research*. 2000;**92**(2):177-185
- [64] Cunliffe I, McIntyre C, Rees R, Rennie I. The effect of topical beta-blocker medications on the proliferation and viability of human Tenon's capsule fibroblasts in tissue culture. *German Journal of Ophthalmology*. 1995;**4**(3):167-174
- [65] Blanchette KA, Prabhakara R, Shirtliff ME, Wenke JC. Inhibition of fracture healing in the presence of contamination by *Staphylococcus aureus*: Effects of growth state and immune response. *Journal of Orthopaedic Research*. 2017;**35**(9):1845-1854
- [66] Kumar A, Alam A, Rani M, Ehtesham NZ, Hasnain SE. Biofilms: Survival and defense strategy for pathogens. *International Journal of Medical Microbiology*. 2017;**307**(8):481-489