

# We are IntechOpen, the world's leading publisher of Open Access books Built by scientists, for scientists

4,800

Open access books available

122,000

International authors and editors

135M

Downloads

Our authors are among the

154

Countries delivered to

TOP 1%

most cited scientists

12.2%

Contributors from top 500 universities



WEB OF SCIENCE™

Selection of our books indexed in the Book Citation Index  
in Web of Science™ Core Collection (BKCI)

Interested in publishing with us?  
Contact [book.department@intechopen.com](mailto:book.department@intechopen.com)

Numbers displayed above are based on latest data collected.  
For more information visit [www.intechopen.com](http://www.intechopen.com)



---

# Hybrid Technique for Incisional Hernias

---

Monika Romanowska and Jacek Pawlak

Additional information is available at the end of the chapter

<http://dx.doi.org/10.5772/intechopen.76941>

---

## Abstract

Hernia is one of the most common complications post any laparotomy. Various techniques are used for the repair of incisional hernias. Hernioplasty with synthetic materials is worldwide standard, and indications to the simple suture methods are rare. Mini-invasive techniques for hernia repair have become popular since 1990 and carry many advantages. Some incisional hernias have a very large hernia sac with large loss of fascia, which makes an exclusive laparoscopic approach challenging. Moreover, some patients are found to have very dense adhesions, which makes laparoscopic approach unsafe, and almost impossible necessitating conversion from laparoscopic to open surgery. Then, the process is carried on until the safe implantation of mesh into abdominal cavity becomes possible. This has led to the birth of what is known as the hybrid technique for incisional hernia repair (laparoscopy, conversion, laparotomy, laparoscopy). Patients with large, complicated, and recurrent incisional hernias should primarily be qualified to hernioplasty with the hybrid technique, which combines the conventional open repairs (safe adhesiolysis, safe placement of laparoscopic tools into the abdominal cavity, closing the defect) with laparoscopic repair (intraperitoneal mesh placing).

**Keywords:** incisional hernia, hybrid techniques, synthetic materials

---

## 1. Introduction

Postoperative hernia is the most common complication of abdominal surgery and a big problem in clinical practice. Incisional hernias complicate in 2–20% of laparotomies and depend on wound complications during the postoperative period, the type of surgical technique, the method used to close the abdomen, and many factors connected with the patient (age, elevated body mass index, general condition) [1, 2]. High rate of recurrence in 20–50% of patients after the primary repair of a defect is another problem [3, 4]. Many complications after open

operation and technical progress, associated with innovations in synthetic materials which are covered by anti-adhesive substance of the ventral side, lead to the development of laparoscopic surgery [5, 6]. This method offers many advantages: minimal pain, shorter stay in the hospital, quicker return to activities, and the ability to identify additional defects in abdominal wall [7, 8]. However, the problem of recurrence after incisional hernia repair still exists, and its incidence rate ranges between 1.8 and 10% [9].

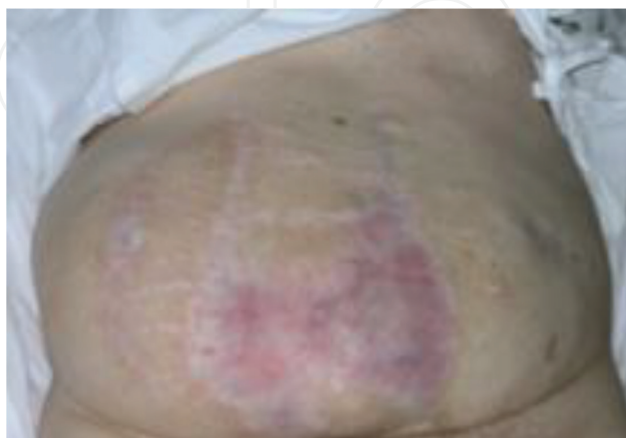As the hernias have become more complex, the management strategy has evolved as well. In some difficult cases, defects are very large, and then even after laparoscopic repair, patients are unhappy because of cosmetic appearance of their wound. Moreover, sometimes mini-invasive repair of complicated postoperative hernia is not so easy to perform due to massive adhesions after the primary operations which are especially dangerous during placing laparoscopic tools into abdominal cavity. Some surgeons are convinced that it is worth to combine the two techniques, open and laparoscopic, to maximize benefits of both methods.

## 2. Surgical technique

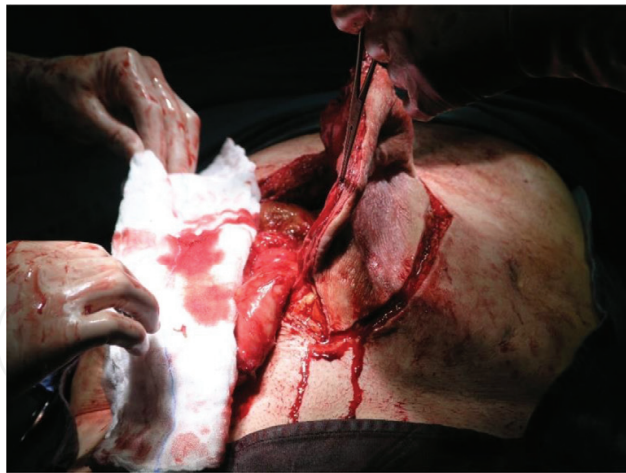Hybrid incisional repair can be performed by two techniques.

### 2.1. Standard combined laparoscopic technique

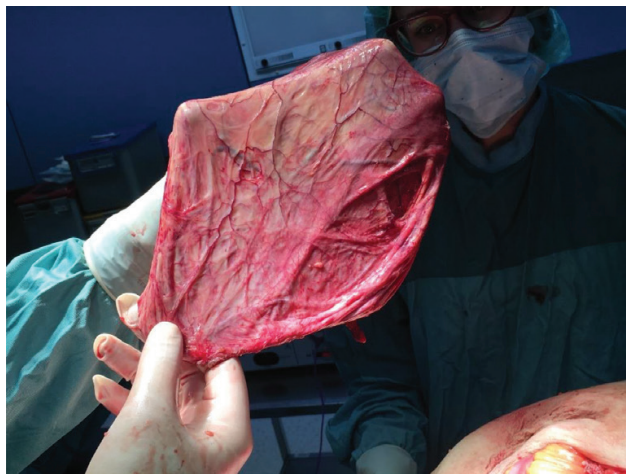
Fascial defect is exposed via incision over the previous surgical scar and hernia sac incised to access into the abdomen (**Figures 1** and **2**). Afterward during the next step of laparotomy, extensive and safe adhesiolysis can be ensured; reduction of the hernia sac (**Figure 3**) and proper placement of the laparoscopic trocars under direct vision are the other steps. Finally, the mesh can be laid into the peritoneal cavity (under the fascia defect) (**Figure 4**). Some researchers use Prolene sutures to fixate the mesh [10]. Then, mesh material is left in the abdomen, and fascial defect was primarily closed.



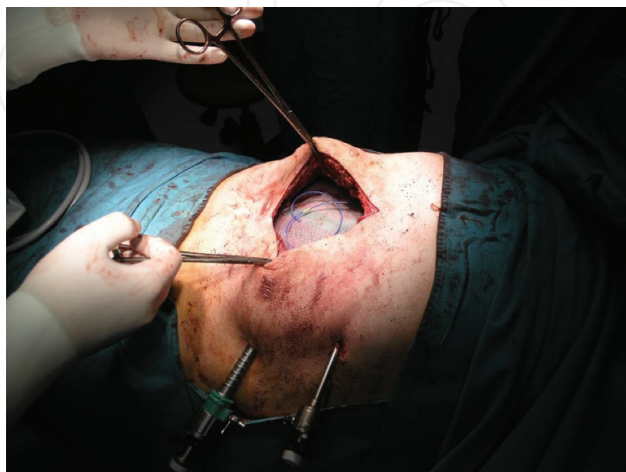**Figure 1.** Recurrent hernia with thin overlying skin after laparotomy and the primary suture repair complicated by wound infection.



**Figure 2.** Removal of surgical scar.



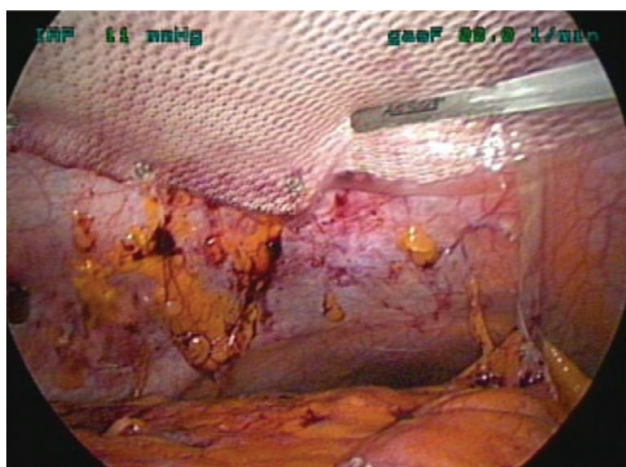
**Figure 3.** Prepared hernia sac.



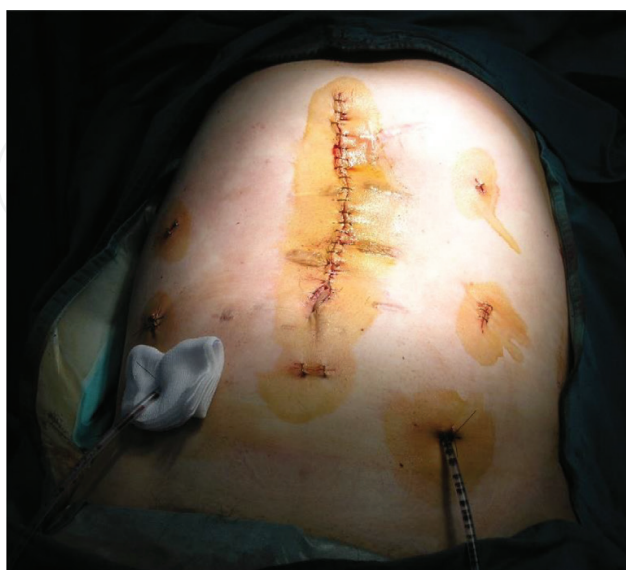**Figure 4.** The mesh placed into abdominal cavity.

The next step is the laparoscopic part of the procedure, intraperitoneal placement of the mesh after the reduction of the intraperitoneal pressure to 7–8 mm Hg. The mesh should have appropriate size, covering the actual hernia size edges for at least 5–7 cm, and then it is laparoscopically fixed with transfascial stay stitches (Protac, AbsorbaTack, or CapSure) (**Figure 5**). Desufflation and skin sutures finish the procedure (**Figure 6**).

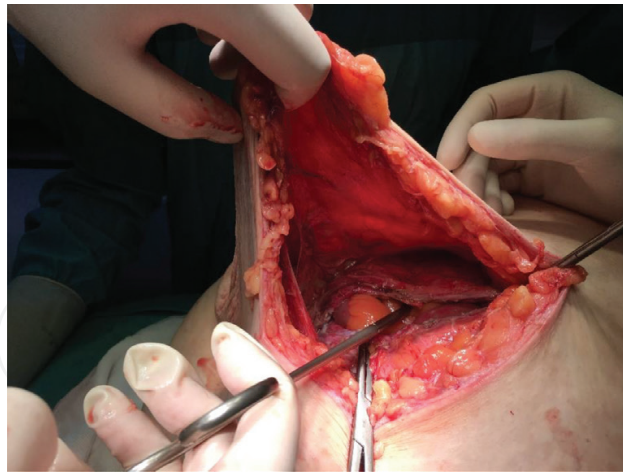
In case of large incisional hernia where primary closure of fascial defect is impossible, authors enlarge the abdominal wall surface by modified component separation technique. The dissection of adhesions between the peritoneum and small bowels is needed until rectus muscles are entirely exposed. The skin is elevated and dissected from the anterior surface of the rectus sheath to the exposure of external abdominal oblique muscles by 5 cm (**Figure 7**). At 2 cm, lateral from rectus sheath, the aponeurosis of the external abdominal oblique muscle is longitudinally



**Figure 5.** The mesh fixated laparoscopically.



**Figure 6.** Early postoperative view.

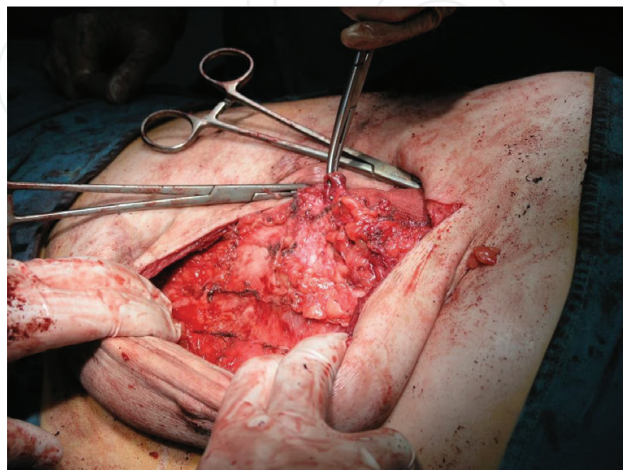


**Figure 7.** Dissection of the skin from anterior surface of rectus sheath.

transected (**Figure 8**), superiorly to the level of costal margin and inferiorly to the symphysis pubis. By releasing bilateral external abdominal oblique muscle attachment, a gap of 7–10 cm between rectus abdominis muscles could be bridged at the waistline [11]. Closure of abdominal wall defect can be achieved using continuous running sutures. Suction drains placed at the subcutaneous space are necessary. The laparoscopic part is the same as mentioned above.

## **2.2. Combined technique with early conversion**

The procedure starts with entering the peritoneal cavity by using a Veress needle, an open Hasson method, or an optical trocar allowing the view of the abdominal wall layers during penetration. The authors prefer the Veress needle entered under the left costal margin—the left upper quadrant as space where the least adhesions are expected. Three trocars are used, one 10 mm trocar and two 5 mm trocars, which are placed as laterally as possible on the abdominal wall, so they are at an adequate distance from the hernia orifice. The next step



**Figure 8.** The transection of the aponeurosis of external abdominal oblique muscle.

| Causes of conversion                                    | n-237 (%) |
|---|-----------|
| Massive adhesions                                       | 4.6       |
| Injury of small bowel during adhesiolysis               | 3         |
| Injury of small bowel during trocar placement           | 1.3       |
| Size of defect (too large to repair during laparoscopy) | 1.3       |
| Lack of progression of operation                        | 0.9       |
| Intraoperative bleeding                                 | 0.4       |

**Table 1.** Causes of conversion during IPOM procedure based on 237 cases.

of the operation is adhesiolysis. The adhesions in the abdomen are lysed using an electrocautery, an ultrasonic scalpel, or scissors. No cauterization should be done that may injure the bowel wall. Perforation of the intestine is the most serious injury associated with laparoscopic ventral hernia repair [12]. Thus, in selected cases, if extensive adhesiolysis is deemed to be particularly hazardous for enterotomy, the conversion should be done and division of omental and bowel adhesions to the anterior abdominal wall is performed through laparotomy. Other causes of conversion are bigger size of the fascial defect than it was primary expected but which was impossible to repair during laparoscopic procedure only, lack of progression of operation, and intraoperative bleeding. The authors analyzed the causes of conversion based on 237 patients primarily qualified to hernia repair with the IPOM procedure in our department between 2008 and 2016. In case of 27 patients (11.4%) from a group of 237 patients, it was necessary to change surgical approach from laparoscopic to open surgical approach. Respective causes of conversion are presented in **Table 1**.

Performance of open, safe adhesiolysis or repair of injuries is essential for graduating to another step of the procedure. Placement of the mesh into the abdominal cavity, closing the fascial defect and laparoscopic fixation of the mesh, should progress the same as in case of standard combined laparoscopic technique.

### 3. Indications for the hybrid technique

There are no objectively defined selection criteria of treatment of incisional hernias, but we selected some rules which may find helpful in making treatment decisions.

In our concept, hybrid surgical approach can be dedicated to patients with large, difficult incisional hernias, where extensive, dense adhesions are expected (e.g., patients with two or more recurrences of hernia, patients with history of successful treatment of gastrointestinal-cutaneous fistulas, patients after many laparotomies—three or more). Moreover, it may be prudent to offer hybrid repair for particularly large incisional hernias, where transverse separation of the fascial edges is >8–10 cm.

## 4. Contraindications for the hybrid technique

Obese patients (with BMI > 35 kg/m<sup>2</sup>) should be primarily qualified to laparoscopic hernia repair which gives them more benefits than the hybrid technique (e.g., less infection complications, earlier recovery).

Patients with giant incisional hernia with loss of abdominal domain are the most challenging ones and require an individual preoperative treatment. Loss of domain (LOD) occurs when an abdominal wall defect progresses to a size at which it may no longer accommodate the viscera, leading to protrusion outside of the abdominal wall and into the hernia sac [13]. Hernia defect area can be calculated from cross-sectional imaging using computed tomography (CT), and hernia sac volume (HSV) and peritoneal cavity volume (CV) are obtained from preoperative CT measurements. If the calculated volume ratio (VR = HSV/CV) is larger than 25%, loss of domain is observed [14]. In these cases the individual preoperative treatment includes pulmonary training, an installation of a pneumoperitoneum, or an implantation of an expander system to achieve a relaxation and stretching of the skin and muscles as well [15].

## 5. Postoperative complications

Complications after hybrid approaches to incisional hernia repair span a wide range of severities. To do it more comprehensibly, they were divided into early and long-term complications.

### 5.1. Early postoperative complications

Early postoperative complications are revealed during the operation or not longer than 30 days after the operation. Some of postoperative complications are composed of those common to all general surgery, for example, thromboembolism and superficial surgical site infection, and are typically managed no differently [16]. Unique to recovery from hernia surgery however can be increased pain after mesh placement, seroma related to large dissection planes, infections of the mesh, as well as pulmonary insufficiency due to changes or loss in abdominal domain.

An inadvertent enterotomy is a serious complication of adhesiolysis. Adhesions to the abdominal scar represent a significant problem during hybrid repair, with the risk of bowel injury around the neck of the hernia during dissection. Rudmik et al. [17] in their review calculated an overall risk of enterotomy of 2.1% when the laparoscopic approach is the first step of hybrid repair. Injury of a hollow organ is a very serious event and should be recognized and treated immediately. An incidental enterotomy may occur during initial trocar placement or may result from adhesiolysis. Two strategies are available to deal with such a situation. One option, which is particularly attractive when there is no enteric spillage, is to suture the perforation and proceed with hybrid repair, in conjunction with copious saline lavage of the peritoneal cavity and intravenous antibiotics. The second option is to complete adhesiolysis and repair the bowel



injury but to delay mesh placement (i.e., perform a “staged repair,” within a fairly short interval), in order to optimize bacterial clearance and minimize the risk of infection [18]. Colonic injury is a more serious concern; there is no substantial evidence base to guide decision-making. The optimal strategy in case of enteric injury needs to be decided on a case-by-case basis. A safe option, particularly if laparotomy has been undertaken because of the bowel injury, is to perform simply a suture repair of the hernia and accept that the risk of mesh infection has been exchanged for a higher risk of hernia recurrence. If the enterotomy remains unnoticed, it may result in an acute abdominal condition and sepsis within a few hours after surgery.

Authors have experiences based on 61 patients who underwent hybrid hernia repair in our department between 2008 and 2016. They were divided into two groups. Group 1 (n = 34) identifies patients operated with standard combined laparoscopic technique, whereas group 2 (n = 27) labels combined technique with early conversion. Both groups were compared in terms of early complications and shown in **Table 2**.

Serious complications include mesh infections and enterocutaneous fistula involving mesh, as well as the rare, but highly morbid mesh. Complications such as these likely require revisional surgery for resolution. Then, in our opinion, complete removal of the mesh is required, as well as drainage of subcutaneous surface and intravenous antibiotics.

Early postoperative abdominal pain is a fairly regular feature of the hybrid repair. In our concept, it is usual to anticipate a comfortable patient at 24–72 h after operation and remain within 6–7 on the Visual Analogue Scale. Mesh fixation with titanium tacks plays a key role in the development of acute postoperative pain. Conceptually, a 4-mm-long tack would be expected to penetrate only 2 mm into the abdominal wall, after allowing 1 mm for the thickness of the mesh and another 1 mm for the tack profile that projects on the surface of the mesh. Thus, in obese patients, the tack may be restricted to the extraperitoneal fat without purchase

| Postoperative early complications                           | Group 1 (n = 34) | Group 2 (n = 27) |
|---|------------------|------------------|
| Enterotomy during initial trocar or Veress needle placement | 0                | 3                |
| Enterotomy during laparotomy                                | 1                | 1                |
| Enterotomy during adhesiolysis                              | 5                | 7                |
| Injury of the bladder                                       | 1                | 0                |
| Acute postoperative pain                                    | 6                | 8                |
| Surgical site infection                                     | 6                | 8                |
| Enterocutaneous fistula                                     | 2                | 0                |
| Mesh infection  | 2                | 1                |
| Small bowel tied up into 12 mm trocar defect                | 1                | 0                |
| Left part of mesh fixing system                             | 1                | 0                |
| Total   | 25               | 28               |

**Table 2.** Postoperative early complications in both groups.

into the muscle. This theory explains why acute postoperative pain is the most frequently observed in young, slim females. Furthermore, some studies show that the use of multiple transparietal sutures is largely related to a perceived association with increased postoperative pain, perhaps due to muscular ischemia or entrapment neuropathy [19].

Patients with acute pain are initially treated with anti-inflammatory medications and continuous infusion of opioids during 24–48 h after hernia repair.

## 5.2. Long-term postoperative complications

Long-term complications are revealed more than 30 days after the operation and include chronic pain, chronic mesh infections, and enterocutaneous fistula involving mesh and hernia recurrence.

Chronic pain is defined as pain lasting more than 3 months. Evidence reveals that chronic pain is most likely multifactorial with an incidence ranging from 1 to 7% [20]. Major factors that have been identified as possible etiologies include the technique of mesh fixation. The authors' group noted severe postoperative pain with the use of a large number of tacks. Initial nonoperative management of chronic pain with oral analgesics and anti-inflammatory medications is the most conservative approach, but local injection of anesthetic and even mesh excision may be required.

Patients with complications carry a higher risk of developing a hernia recurrence. Most recurrences occur after mesh removal for postoperative infection. Some researchers found significant associations between recurrence and larger hernias, longer operative times, previous hernia repairs, morbid obesity, and higher complication rates [21]. Several studies compare open and laparoscopic approach in incisional hernia repair. These studies have not shown significant differences in recurrence rates for laparoscopic and open incisional hernia repair. Contrary to previous studies that reported recurrence rates up to 20% with mesh repair, there are some studies showing exceptionally low recurrence rates varying between 0 and 5% [22–24]. Only single-center reports show results of hybrid technique of incisional hernia repair based on a small group of patients and with a short follow-up periods (from 12 to 63 months). During these follow-up periods, no hernia recurrences occurred [25, 26]. Our results, although from a single institution, are based on average follow-up period of 27 months (3–96 months). Recurrence revealed in four patients including one case after biologic mesh implantation.

Long-term postoperative complications in authors' studied groups are shown in **Table 3**.

| Long-term complications | Group 1 (n = 34) | Group 2 (n = 27) |
|-------------------------|------------------|------------------|
| Hernia recurrence       | 2                | 2                |
| Chronic pain            | 2                | 4                |
| Total                   | 4                | 6                |

**Table 3.** Long-term complications in both groups.

The surgical treatment of incisional hernia has changed rapidly during the last decade with the increasing use of mesh technique and the introduction of laparoscopy. However, many questions concerning mesh type, mesh positioning, fixation method, and operation type still remain unanswered. Patients with incisional hernia are a heterogeneous population with patient-specific comorbidity and innate differences (e.g., collagen formation quality). This makes the choice of the technique most suitable for each patient even if it is more difficult.

The authors' retrospective study including 61 patients with large incisional hernias treated with hybrid technique has shown that the hybrid technique is an effective method confirmed by a low rate of recurrence. However, the hybrid technique is a complicated surgical method. Perfect knowledge of anatomy of the abdominal wall is required from a surgeon as well as expertly employed of open and laparoscopic surgical approach. Moreover, long-term multi-center studies comparing the results of hybrid technique are needed to establish its efficacy. For the time being, it is considered a good alternative to its open-only counterpart, at least in experienced hands.

## Author details

Monika Romanowska\* and Jacek Pawlak

\*Address all correspondence to: monika.meszka@gmail.com

Department of General Surgery, Specialist Western Hospital of Saint John Paul II in Grodzisk Mazowiecki, Poland

## References

- [1] Mackiewicz Z. The Modern Treatment of Ventral Hernias. Warsaw: PZWL; 2006. pp. 152-159
- [2] Jankins E, Yom V, Melman L, et al. Clinical predictors of operative complexity in laparoscopic ventral hernia repair: A prospective study. *Surgical Endoscopy*. 2010;**24**(8):1872-1877
- [3] Lee Y, Iqubal A, Vitamvas M, et al. Is it safe to perform laparoscopic ventral hernia repair with mesh in elderly patients? *Hernia*. 2008;**12**:239-242
- [4] Romańczuk M, Mitura K, Wróblewski T. A comparison of methods and results of ventral incisional hernia repair. *Videosurgery and Other Miniinvasive Techniques*. 2006; **1**(3):95-100
- [5] Wysocki A, Budzyński P. Implants in surgery of hernias. *Medycyna Praktyczna*. 2010;**1**:9
- [6] Janczak D, Litarski A, Merenda M. Use of synthetic mesh in abdominal wall hernias repair. *Polimery w Medycynie*. 2011;**41**(3):13-18
- [7] Carlson MA, Frantzides CT, Shostrom VK, et al. Minimally invasive ventral herniorrhaphy: An analysis of 6,266 published cases. *Hernia*. 2008;**12**:9-22

- [8] Sajid MS, Bokhari SA, Mallick AS, et al. Laparoscopic versus open repair of incisional/ventral hernia: A meta-analysis. *The American Journal of Surgery*. 2009;**197**:64-72
- [9] Millikan KW. Incisional hernia repair. *The Surgical Clinics of North America*. 2003;**83**:1223-12234
- [10] Ozturk G, Malya FU, Ersavas C, et al. A novel reconstruction method for giant incisional hernia: Hybrid laparoscopic technique. *Journal of Minimal Access Surgery*. 2015;**11**:267-270
- [11] Kim Z, Kim YJ. Components separation technique for large abdominal wall defects. *Journal of the Korean Statistical Society*. 2011;**80**(Suppl 1):S63-S66. DOI: 10.4174/jkss.2011.80.Suppl1.S63 PubMed
- [12] LeBlanc KA. Incisional hernia repair: Laparoscopic techniques. *World Journal of Surgery*. 2005;**29**:1073-1079
- [13] Azar FK, Crawford TC, Poruk KE, et al. Ventral hernia repair in patients with abdominal loss of domain: An observational study of one institution's experience. *Hernia*. 2017;**21**(2):245-252. DOI: 10.1007/s10029-017-1576-0
- [14] Tanaka EY, JH Y, Rodrigues AJ Jr, et al. A computerized tomography scan method for calculating the hernia sac and abdominal cavity volume in complex large incisional hernia with loss of domain. *Hernia*. 2010;**14**:63-69
- [15] Fortelny R. Loss of domain incisional hernia. *Chirurgische Praxis*. 2015;**79**(1):11-18
- [16] Bleier JIS, Resnick AR. Complications of incisional hernia repair. *Seminars in Colon and Rectal Surgery*. 2009;**20**(3):125-130
- [17] Rudmik LR, Schieman C, Dixon E. Laparoscopic incisional hernia repair: A review of the literature. *Hernia*. 2006;**10**:110-119
- [18] Sarela A. Controversies in laparoscopic repair of incisional hernia. *Journal of Minimal Access Surgery*. 2006;**2**(1):7-11
- [19] van't Riet M, de Vos van Steenwijk PJ, Kleinrensink GJ, et al. Tensile strength of mesh fixation methods in laparoscopic incisional hernia repair. *Surgical Endoscopy*. 2002;**16**:1713-1716
- [20] Snyder CW, Graham LA, Vick CC, et al. Patient satisfaction, chronic pain, and quality of life after elective incisional hernia repair: Effects of recurrence and repair technique. *Hernia*. 2010;**15**:123-129
- [21] Anthony T, Bergen P, Kim L, et al. Factors affecting recurrence following incisional herniorrhaphy. *World Journal of Surgery*. 2000;**24**:95-10
- [22] Eker HH, Hansson BME, et al. Laparoscopic vs open incisional hernia repair: A randomized clinical trial. *JAMA Surgery*. 2013;**148**(3):259-263. DOI: 10.1001/jamasurg.2013.1466
- [23] Awaiz A, Rahman F, Hossain MB, et al. Meta-analysis and systematic review of laparoscopic versus open mesh repair for elective incisional hernia. *Hernia*. 2015;**19**(3):449-463

- [24] Al Chalabi H, Larkin J, Mehigan B, et al. A systematic review of laparoscopic versus open abdominal incisional hernia repair, with meta-analysis of randomized controlled trials. *The International Journal of Surgery*. 2015;**20**:65-74
- [25] Stoikes N, Quasebarth M, Burnt LM. Hybrid ventral hernia repair: Technique and results. *Hernia*. 2013;**17**:627-632
- [26] Ji Y, Zhan X, Wang Y, Zhu J. Combined laparoscopic and open technique for the repair of large complicated incisional hernias. *Surgical Endoscopy*. 2013;**27**(5):1778-1783

IntechOpen