

We are IntechOpen, the world's leading publisher of Open Access books Built by scientists, for scientists

4,800

Open access books available

122,000

International authors and editors

135M

Downloads

Our authors are among the

154

Countries delivered to

TOP 1%

most cited scientists

12.2%

Contributors from top 500 universities



WEB OF SCIENCE™

Selection of our books indexed in the Book Citation Index
in Web of Science™ Core Collection (BKCI)

Interested in publishing with us?
Contact book.department@intechopen.com

Numbers displayed above are based on latest data collected.
For more information visit www.intechopen.com



“555 Manish Technique” for Mini TEP Repair

Manish Kumar Gupta

Additional information is available at the end of the chapter

<http://dx.doi.org/10.5772/intechopen.76356>

Abstract

TEP repair of inguinal hernia has gained popularity in last two decades. TEP repair has steep learning curve due to limited working space. The current Hasson trocar approach is the only technique known among laparoscopic surgeons. Creating pre-peritoneal space without injuring the peritoneum is again a challenging task in the initial part of surgery. Accidental pneumoperitoneum can further compromise the pre-peritoneal space which leads to difficult dissection and prolongation of operative time. Larger infra-umbilical incision for large cone of Hasson trocar has its own complications in terms of more pain, more SSI, incisional hernia, increased cost for morbidity management and suboptimal cosmetic result due to large scar below the belly button. We have innovated a “555 Manish Technique” which addresses the shortcomings of conventional TEP repair. We complete Mini TEP repair by all three 5 mm ports using “555 Manish Technique” with the help of an indigenous “Manish Retractor” which plays a key role. We have also innovated a simple technique to insert an adequate size light weight polypropylene mesh through 5 mm port using “Tail pull” technique. “555 Manish Technique” is simple, less invasive, less morbid, time saving, cost effective and having better cosmetic results and increased patient satisfaction.

Keywords: 555 Manish technique, Mini TEP repair, Manish retractor, TEP by all 5 mm ports, innovative technique for TEP repair

1. Background

Over the past 30 years, hernia surgery has become increasingly complex due to introduction of novel endoscopic, but also conventional techniques. The “Tailored Approach” is now used to describe the differentiated use of different techniques to decrease the risks in management of hernia [1]. The first revolution of open tension-free Lichtenstein Repair in 1989 significantly reduced the recurrence rate while the second revolution was the application of Laparoscopic

inguinal hernia repair in 1992. Laparoscopic inguinal hernia repair can be done either by trans abdominal pre-peritoneal (TAPP) or totally extra-peritoneal (TEP) approach. Laparoscopic inguinal hernia shows advantage over tension-free Liechtenstein repair in terms of less pain, early return to work, smaller scars and low recurrence rates. TEP repair of inguinal hernia has gained popularity in last two decades since 1st introduced by Dulucq in 1992 [2]. TEP repair of inguinal hernia is now a standard surgical technique [3]. It also avoids the chances of missing femoral, obturator and contralateral inguinal hernia and simultaneously give the operating surgeon an opportunity to repair at the same time [2, 4]. Fixing a mesh over the myopectineal orifice at the time of TEP or TAPP repair prophylactically prevents femoral or obturator hernia formation.

2. Current scenario of TEP repair

This technique requires specialized anatomical knowledge and good two hand dexterity for dissecting hernia sac and placement of mesh. Therefore, the acceptance and implementation of TEP have been slow in comparison to other laparoscopic procedures such as cholecystectomy. Laparoscopic inguinal hernia repair has steep learning curve especially in TEP repair and due to limited working space [5, 6]. Increased operative time and complication rates during the early learning curve are other drawbacks. Creating a pre-peritoneal space without injuring the peritoneum is again a challenging task in the initial part of surgery. Accidental pneumoperitoneum can further compromise the pre-peritoneal space which leads to difficult dissection and prolongation of surgical time [6]. The current Hasson trocar approach is the only way to create pre-peritoneal space and the only technique known among laparoscopic surgeons. There is always dependence over the wide Hasson trocar and its broader cone to create pre-peritoneal space. A larger infra-umbilical incision is required for dissecting up to the anterior rectus sheath with the help of “S Retractor” to fix the Hasson trocar with the anchoring sutures. The insertion of Hasson trocar is a relatively blind surgical step of TEP repair of inguinal hernia [7]. Cases of port site incisional hernia were also reported at the site of 12 mm port site used for insertion of mesh [2]. Exclusive use of Hasson trocar for TEP repair in current scenario ultimately reflects in surgical cost. Management of morbidities due to larger port site wound also adds to the financial burden over the patient. Large scar below the belly button is cosmetically suboptimal especially to females. Bigger wound not only leave scar on the body but over the mind & soul as well [6, 7].

3. Innovative approach of Mini TEP by “555 Manish Technique”

We have innovated a “555 Manish Technique” which addresses the shortcomings of the conventional TEP repair of inguinal hernia. In our technique, we complete Mini TEP repair by all three 5 mm ports. We do not use Hasson trocar to create pre-peritoneal space and innovated

a technique to access pre-peritoneal space by 5 mm Visiport using indigenously made simple retractor device. This retractor device was given the name "Manish Retractor" made by 2 ml sterile plastic syringe. This approach gives the advantage to insert the first trocar under complete vision which prevents any accidental injury to peritoneum at this stage. We have also innovated a simple technique to insert an adequate size light weight polypropylene mesh through 5 mm port using "Tail pull" technique.

4. Surgical steps of Mini TEP repair by "555 Manish Technique"

4.1. Instruments used in "555" technique

Three 5 mm Visiport (Endopath XCEL bladders trocar: Ethicon) (Figure 1).

Two milliliters plastic syringe to make "Manish Retractor".

Five millimeters 0 or 30-degree telescope.

Laparoscopic instruments (Maryland dissector, Grasper, scissors).

Silk thread No 1-0 on needle.

15 × 10 cm size, light weight polypropylene mesh (Ultrapro Mesh; Ethicon).

Tacker for mesh fixation.

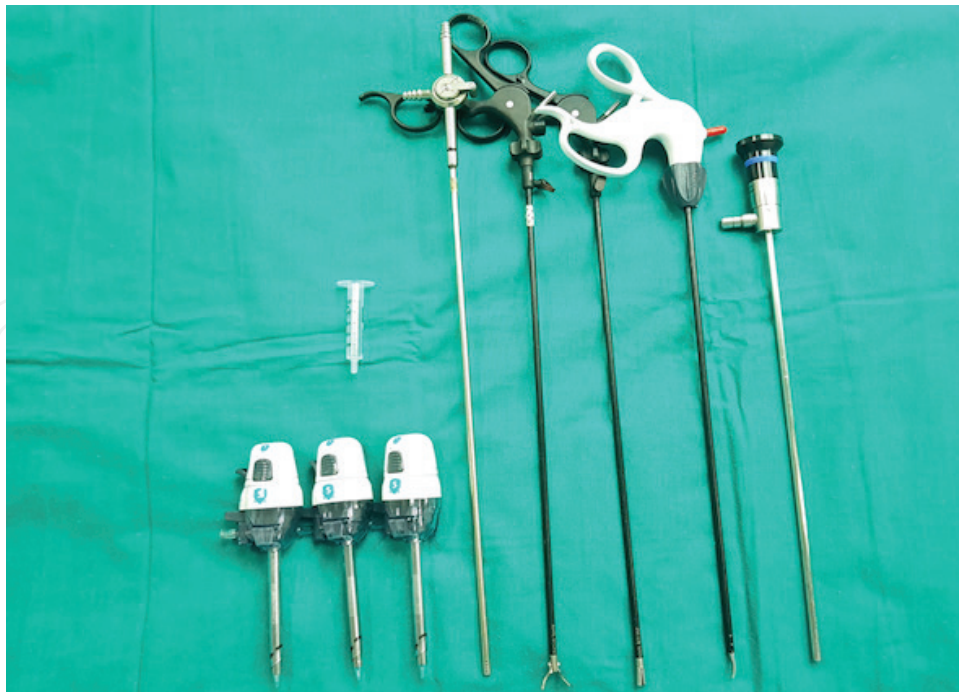

Figure 1. Instruments used in "555 Manish Technique".

5. Steps of “555 Manish Technique” for Mini TEP repair of inguinal hernia

1. Preparing the “Manish Retractor”.
2. Pre-peritoneal space access by “555 Manish Technique.”
3. Dissection of pre-peritoneal space and placement of working ports.
4. Dissection the hernia sac.
5. Insertion & placement of mesh by “Tail Pull” technique through 5 mm port.
6. Closure of all the infra-umbilical port site wounds.

5.1. Preparing the “Manish Retractor”

“Manish Retractor” is prepared using a 2 ml disposable plastic syringe. The hub of the syringe is divided to obtain a 4 cm length of the retractor. It is further slit along its full length with the help of a scissor and the resultant device is named “Manish Retractor” (Figures 2 and 3). Manish retractor replaces the use of large “S” retractor (need 12 mm skin incision) and provide the clear view of ARS through 5 mm skin incision. It retracts skin and subcutaneous fat up to the ARS. This being a cylindrical retraction device is less invasive & less traumatic. This indigenous retractor device plays the key role in accessing the PPS by 5 mm Visiport. This avoids the dependence over wide bore Hasson trocar which is must for current surgical technique [6].

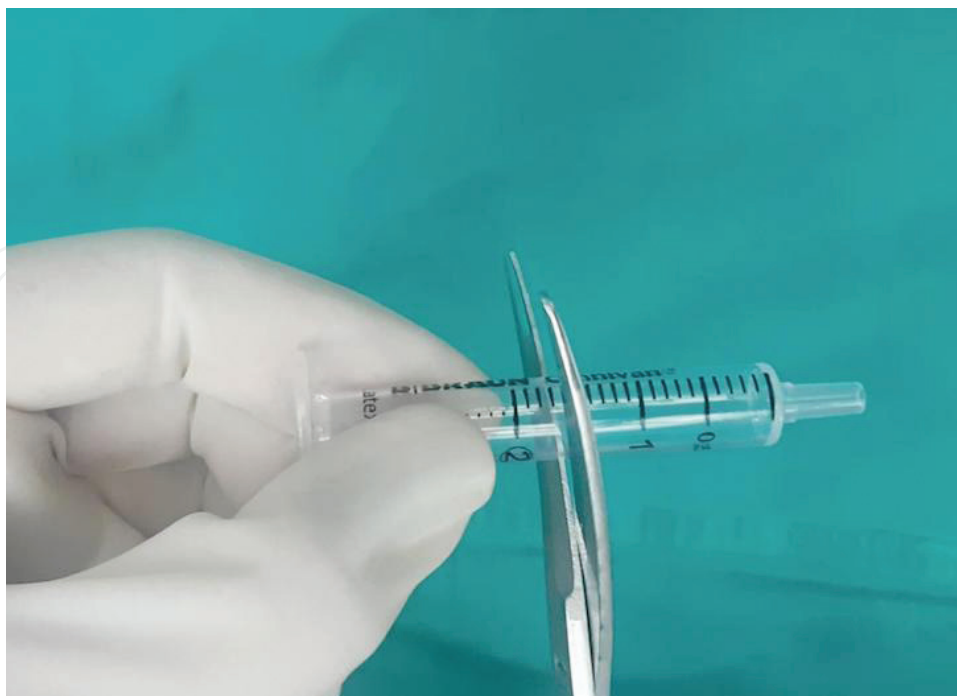

Figure 2. 2mL Syringe hub is divided to make “Manish Retractor”.

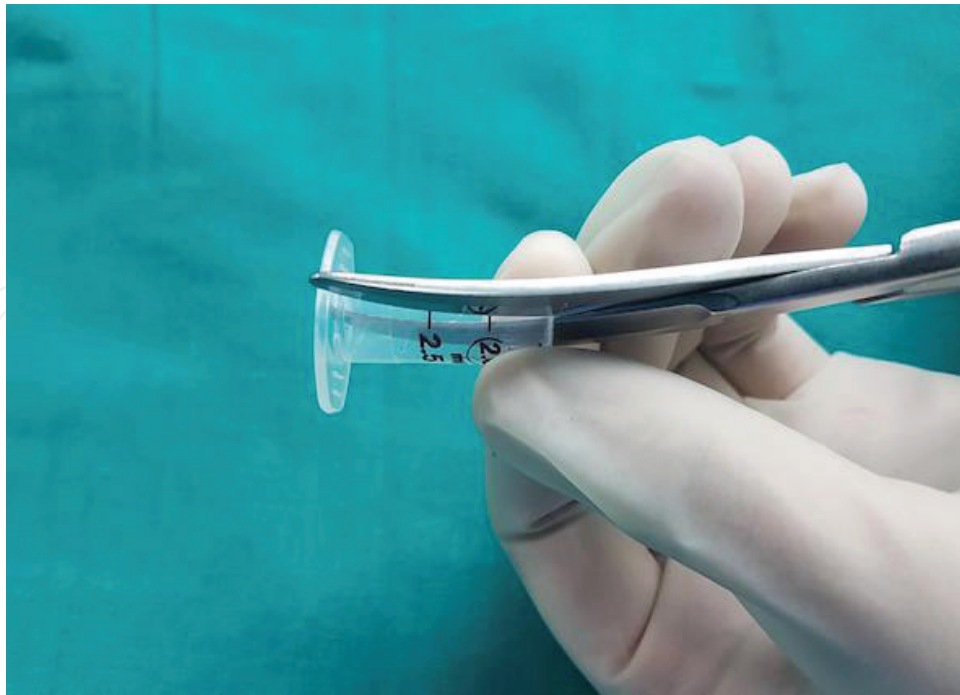


Figure 3. Divided syringe hub is slit along its full length to make "Manish Retractor"

5.2. Pre-peritoneal space access by "555 Manish Technique"

In order to reach the ARS, A 5 mm incision is made in the infra-umbilical region just lateral to midline (**Figure 4**). It is then deepened in the subcutaneous fat and the Manish retractor is inserted. The circumference of the 2 ml syringe is such that it snugly fits in the 5 mm incision. It aids in displacing the fat outwards so that the glistening ARS is clearly visible (**Figure 5**). Excess subcutaneous fat may be cleared by suction.

Next, using a No. 11 blade, a 5 mm transverse incision is made in the ARS and the underlying longitudinal muscle fibers of rectus muscle are seen (**Figures 6 and 7**). The 5 mm Visiport is mounted over a 5 mm, zero-degree telescope so as to enter into the pre-peritoneal space under vision (**Figure 8**). As the Visiport is progressed into the incision, one can appreciate the upper and the lower lip of the slit in ARS (**Figure 9**) followed by rectus muscle fibers laterally and linea alba medially (**Figure 10**). On further advancement of the trocar the arcuate line gets visible beyond which the posterior rectus sheath is deficient. Finally, after crossing the arcuate line the loose areolar tissue of the pre-peritoneal space gets visible (**Figures 11 and 12**). Then the Manish retractor is pulled out gently from the incision by sliding over the trocar. The slit in the retractor helps its easy and complete removal from the 5 mm trocar (**Figure 13**). CO₂ insufflation at 14 mm pressure is achieved after removing the telescope and leaving the cannula of trocar at its site. The trocar is snugly held by the skin, soft tissue and ARS without any need for anchoring sutures and chances of CO₂ leak.

Hasson trocar insertion in current technique of TEP repair is a relatively blind step because only the insertion of Hasson trocar in to the ARS is under vision while rest of the trocar

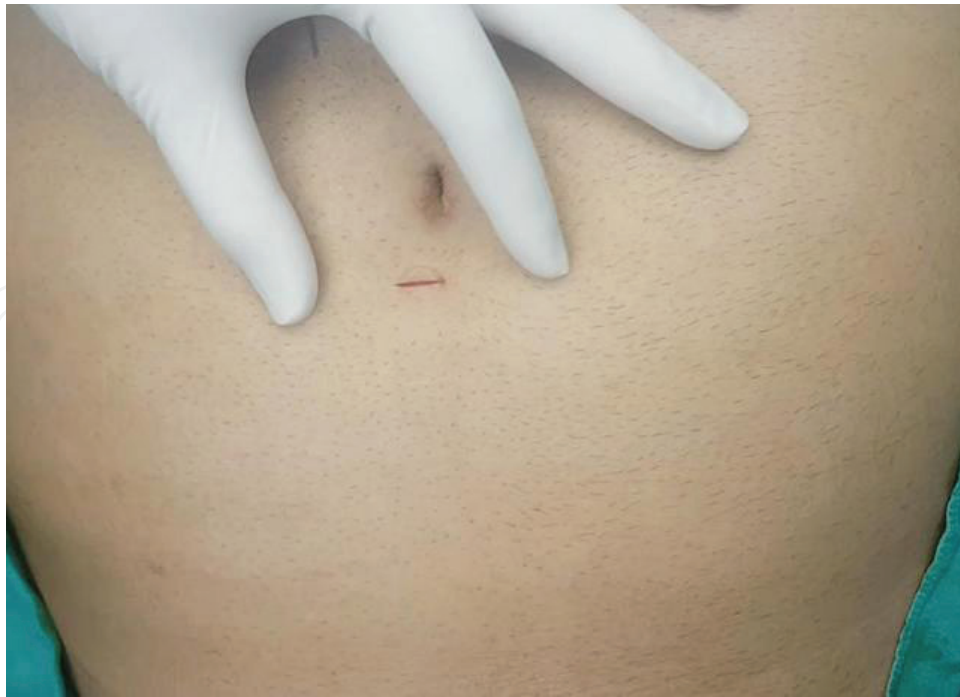

Figure 4. A 5 mm incision is made in the infra-umbilical region just lateral to midline.

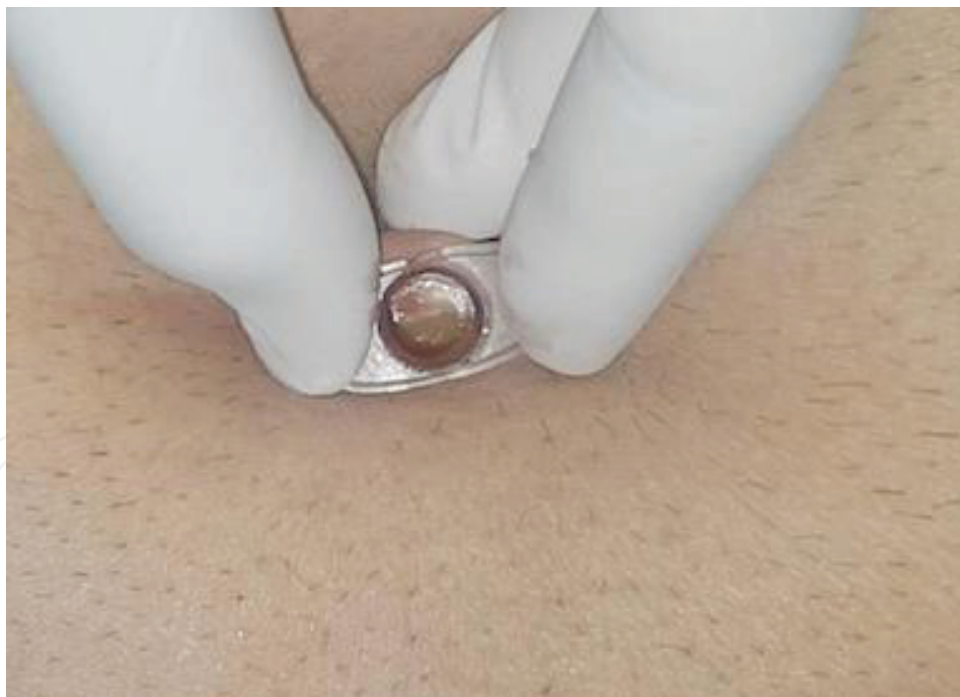

Figure 5. "Manish Retractor" provides a clear view of anterior rectus sheath by displacing fat outwards.

advancement up to the PPS is blind which can lead to accidental injury to peritoneum. The injury to peritoneum can lead to pneumoperitoneum. Pneumoperitoneum at this stage of surgery leads to difficult dissection and also prolongs the duration of surgery [8]. This is avoidable in our technique as one can see the track of the trocar up to the PPS. It also negates the need for

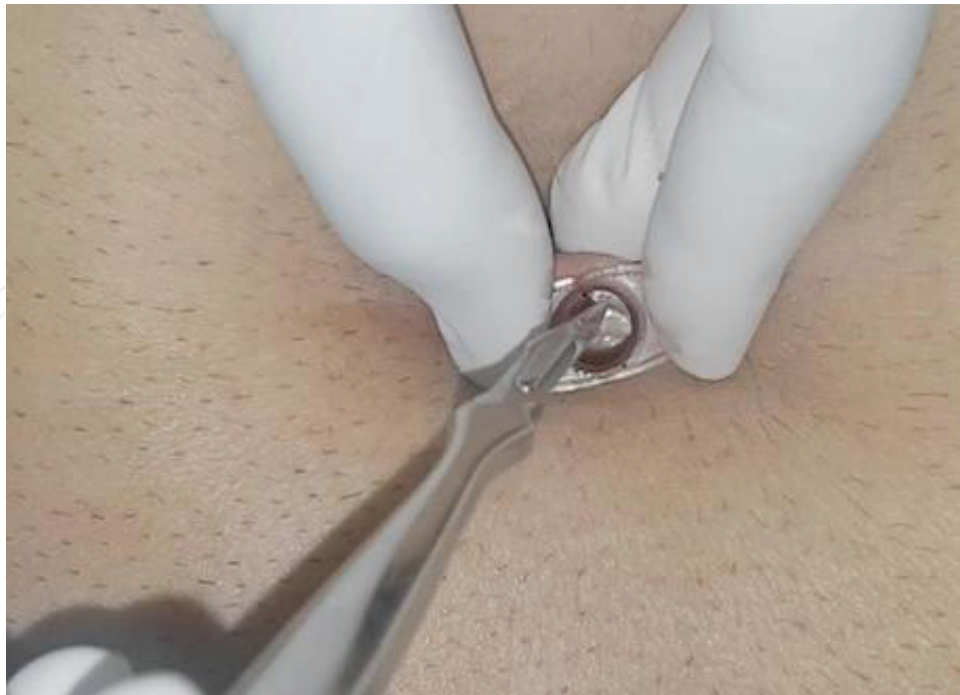

Figure 6. No. 11 blade is used to incise ARS.

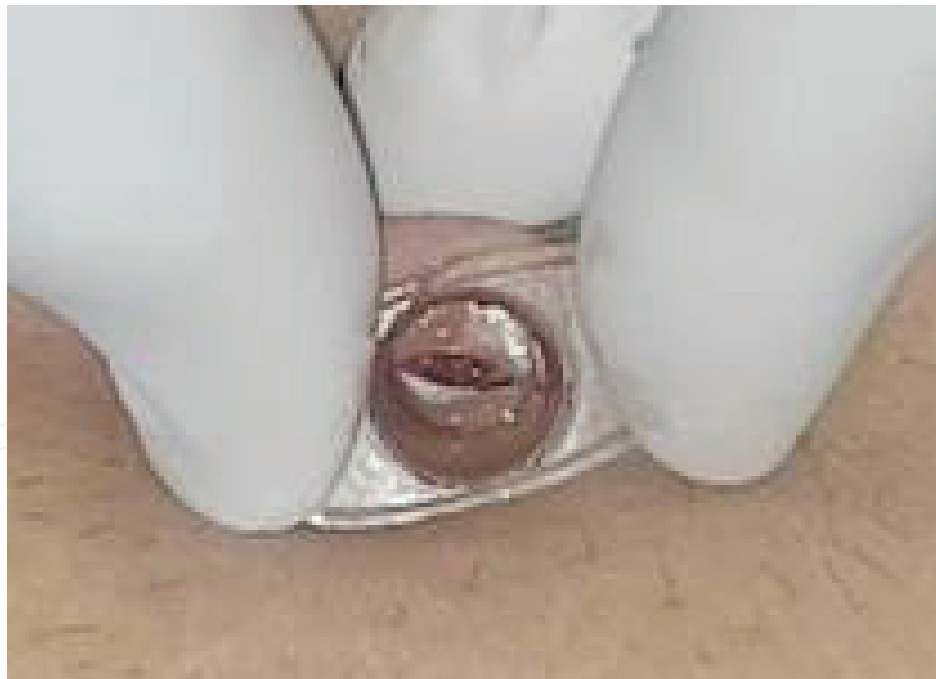

Figure 7. Longitudinal rectus muscle fibres are visible through the slit in ARS.

anchoring sutures over the anterior rectus sheath which is required to fix the large cone of the Hasson trocar [9]. The cone of the Hasson trocar further tears the fibers of ARS at the time of fixation to get a leak proof fixation of cone which needs to be repaired by absorbable sutures at the end of the procedure. Finally, the financial impact of using a Hasson's trocar is also

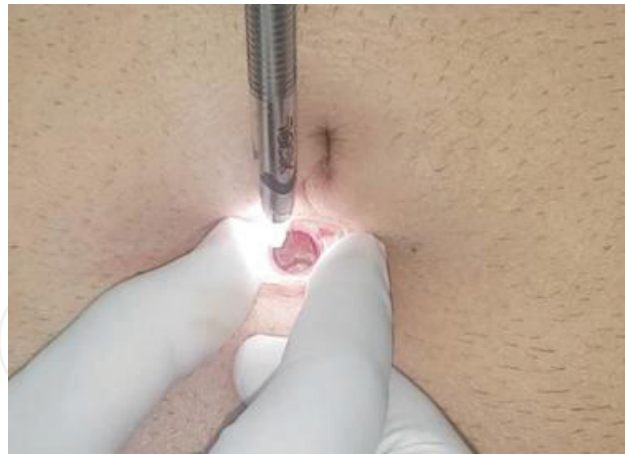


Figure 8. Visiport is mounted over 5 mm, zero-degree telescope and introduced through “Manish retractor” to reach PPS under vision.

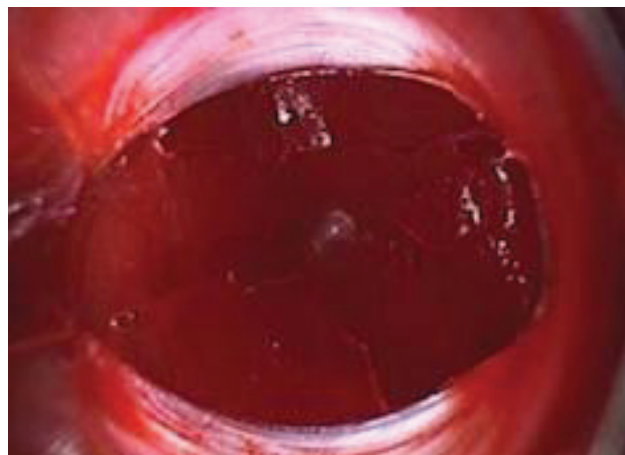


Figure 9. Upper and lower lips of slit in ARS.

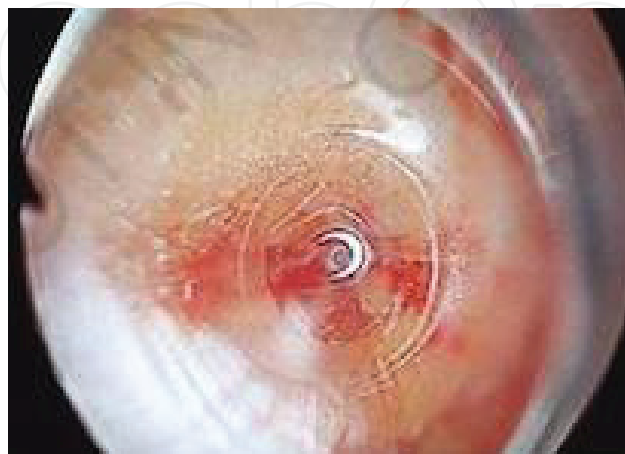

Figure 10. Linea alba is visible on the left side while rectus muscle fibre on the right side of figure.

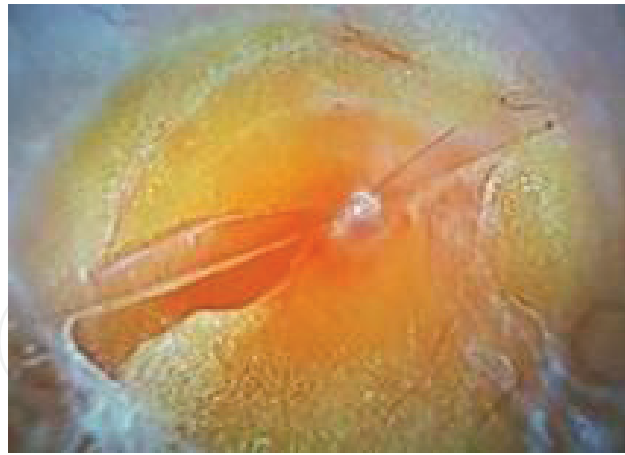

Figure 11. Pre-peritoneal fat becomes visible through visiport on reaching the PPS.

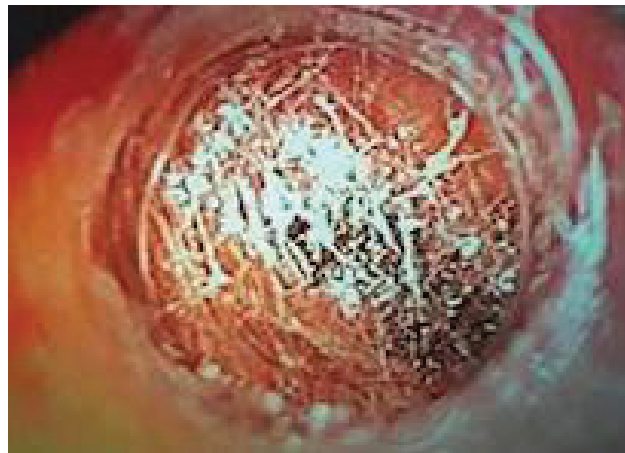


Figure 12. Loose areolar tissue in pre-peritoneal space.

alleviated. The placement of 1st trocar by "555 Manish Technique" takes 2.5 min of surgical time which is far less than average 7–10 min of time taken in placement of Hasson trocar. This technique of accessing the PPS is time saving, less traumatic and less invasive than Hasson trocar technique [5, 6].

5.3. Dissection of pre-peritoneal space and placement of working ports

Blunt dissection of loose areolar tissue is done by 5 mm, zero-degree telescope. CO₂ pneumo-insufflation at 14 mm Hg pressure and on high flow rate helps in creating the Space of Bogros & Space of Retzius. The dissection in PPS is beginning by dissecting the relatively avascular loose areolar tissue in midline till the pubic bone as the first landmark. Then the dissection is carried out laterally on the contralateral side to make the 5 mm working ports. We are trained in performing TEP repair via lateral approach. The first working port is placed just above and medial to ASIS and second one, 5 cm cranial to it. Lateral working port approach is not the part of "555 Manish Technique" and so the procedure can be done using midline working ports as well after insertion of 1st 5 mm infra-umbilical camera port.



Figure 13. Slit in “Manish retractor” helps in its complete removal without taking out the 5 mm trocar.

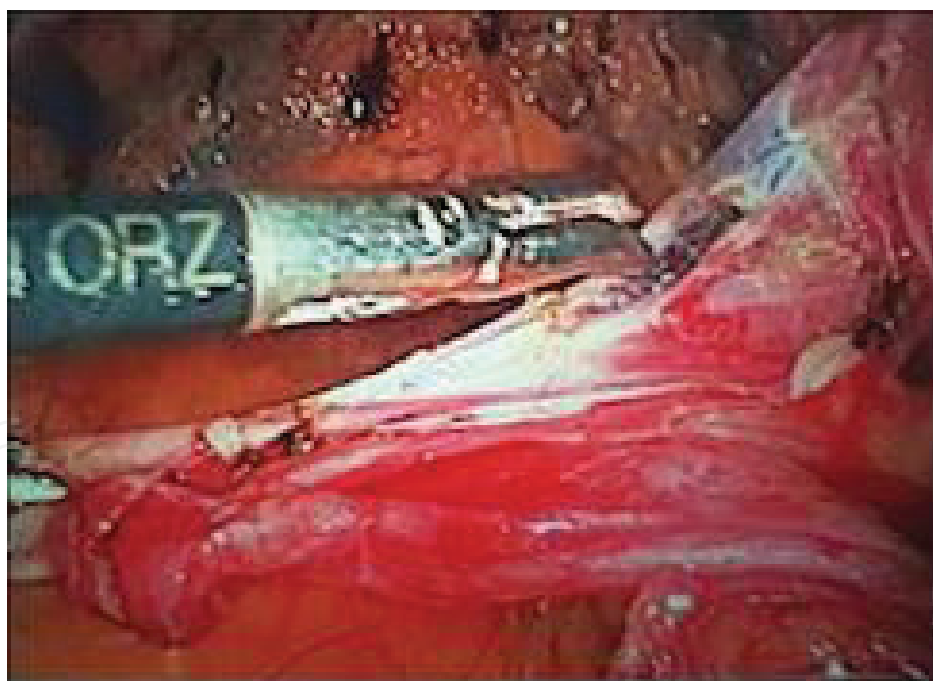

Figure 14. Indirect inguinal hernia sac is dissected from cord structures.

5.4. Dissection of hernia sac

Maryland dissector and a blunt grasper are used to reach up to the hernia sac and cord structures by gentle dissection. The sac is reduced and dissected off from the cord structure and

vas deferens using blunt and sharp dissection. Catgut loop is then tied at the base of the sac after complete parietalization of cord structures and vas deferens. 5 mm telescope provides a good vision and does not cause any problem in dissection (**Figure 14**).

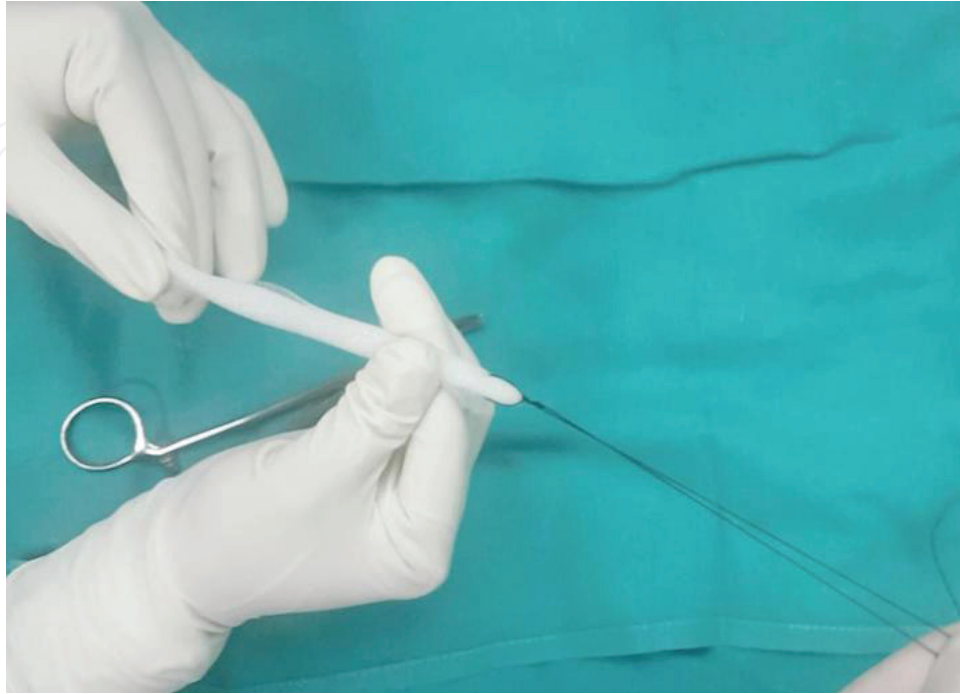

Figure 15. No. 1 silk thread is tied at one end of rolled mesh with 20 cm long tail.

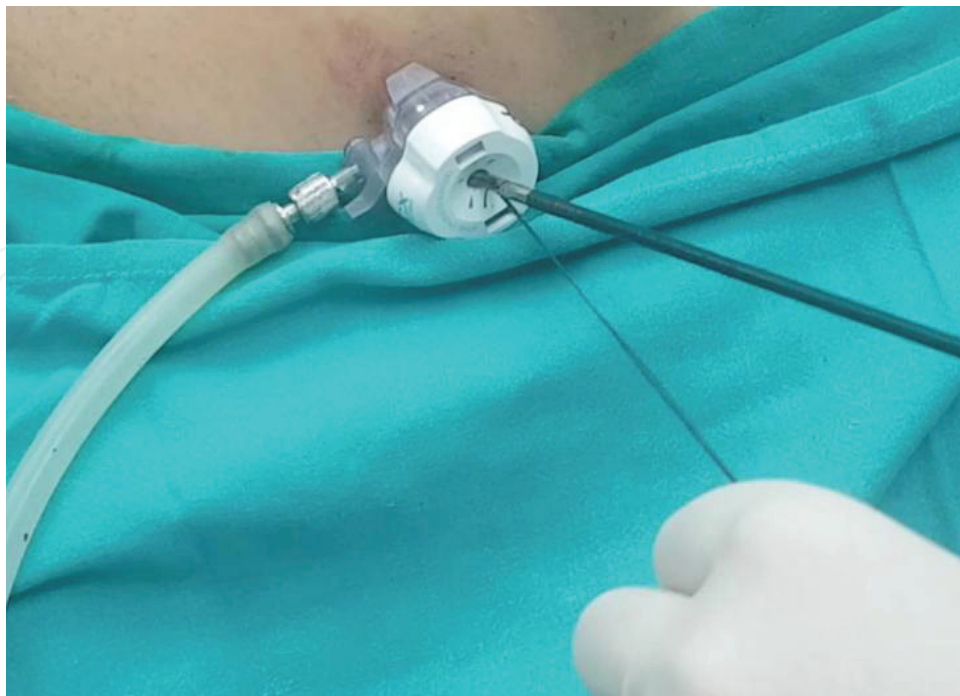

Figure 16. Silk thread tail is inserted through 5 mm trocar in to PPS.

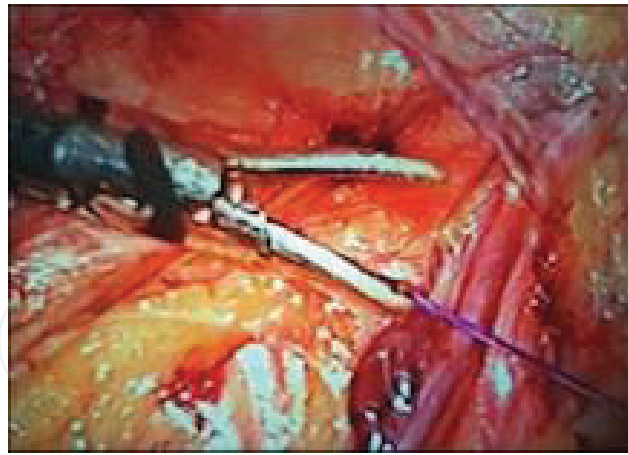


Figure 17. The end of long tail of silk thread is left inside the PPS.

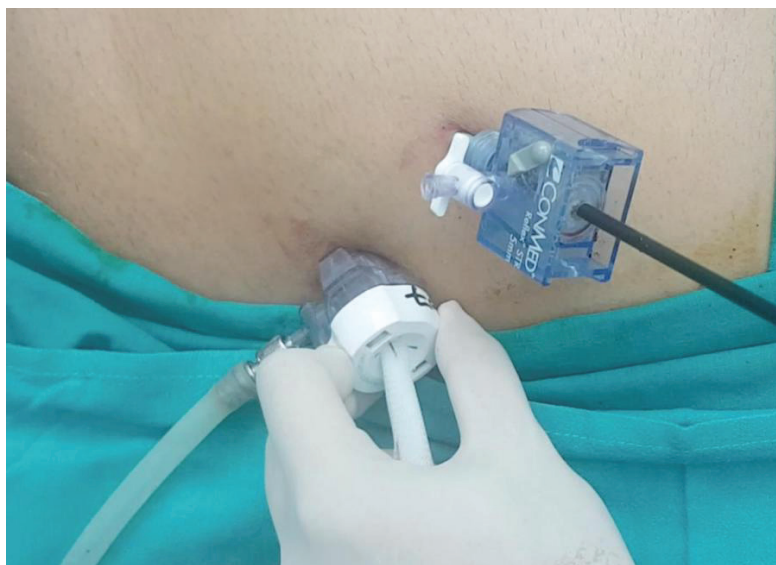

Figure 18. Light weight polypropylene mesh is pulled inside through 5 mm port.

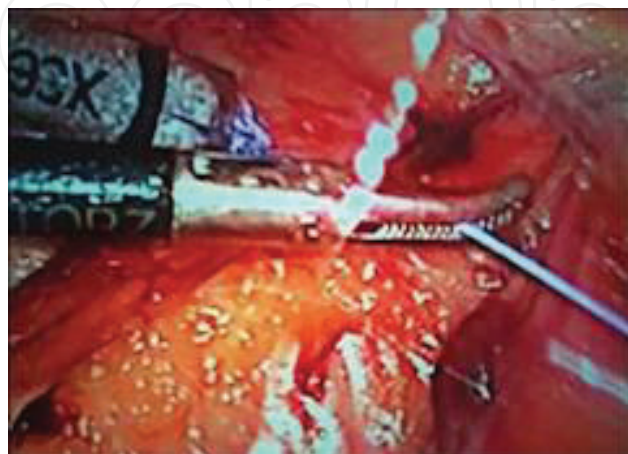

Figure 19. Rolled mesh is then pulled inside by holding and pulling the silk thread inside with grasper from another port.

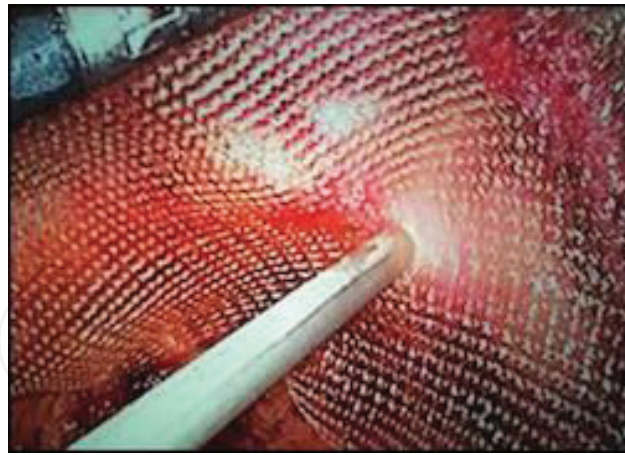


Figure 20. Adequate size light weight polypropylene mesh is unfolded over myopectineal orifices and fixed at cooper's ligament.

6. Insertion and placement of mesh by "Tail Pull" technique through 5 mm port

The "Tail Pull" technique is also innovated and used to insert the adequate size mesh. A light weight polypropylene mesh of 15×12 cm size is rolled to the thinnest possible thickness along its width. A No. 1 silk thread of 20 cm length is tied at one end of the rolled mesh (**Figure 15**). The long silk thread tail is grasped with Maryland dissector and then inserted through a 5 mm working port. Maryland dissector is then taken out leaving the end of the tail in the PPS (**Figures 16 and 17**). This end of tail is then grasped by inserting Maryland dissector through other working port. The tail is then pulled inside which facilitate the insertion of mesh in PPS through 5 mm port (**Figures 18 and 19**). The mesh is then unrolled inside after cutting the thread and placed over the myopectineal orifice (**Figure 20**). It is fixed with tackers over the cooper's ligament. This "Tail Pull" technique facilitate the insertion of mesh as only the mesh is traversing through the trocar cannula while conventionally the mesh is introduced along with a grasping instrument which need a bigger lumen to insert mesh, as mesh and instrument both occupy the space of lumen. The use of a lightweight mesh reduces complications of chronic pain, seroma formation, etc. [10].

7. Closure of all the infra-umbilical port site wounds

All 5 mm trocars are taken out after deflating the space. The small 5 mm size of the infra-umbilical ports does not need any repair of ARS or subcutaneous fat. Skin is stapled as all the wounds are of 5 mm in size. The 12 mm infra-umbilical skin incision in Hasson trocar technique ultimately gets wider due to fixation of the large cone and ultimately becomes a size of 2.5–3.0 cm. Even the ARS fibers got teared because of the tight fixation of the tip of the cone and needs to be repaired along with subcutaneous fat with Vicryl. Larger incisions are always more prone for SSI and more pain [11]. All these complications are prevented in "555 Manish Technique" as it is done by all three 5 mm ports without deviating from the principles of TEP repair.

8. Our experience

Since October 2014 we have operated 108 inguinal, 1 femoral & 1 obturator hernias. 109/110 cases were successfully completed by our technique. The average duration of first 5 mm port placement to access PPS was 2.5 min in comparison to Hasson trocar technique which takes 7–10 min on an average.

Pneumoperitoneum occurred in 23% cases that were managed by putting Veress needle. In all cases pneumoperitoneum occurred in later stages of surgery except one which was converted to TAPP because of adhesions due to past history of contralateral repair TEP repair of inguinal hernia. Thirteen cases of unilateral indirect inguinal hernias were irreducible and reduced during surgery by opening the sac. Ten cases of inguinal hernia patients underwent inguinal hernia repair of contralateral side. Three patients had recurrent inguinal hernia which were operated earlier by open mesh hernioplasty and subsequently repaired successfully by our innovative technique.

One patient had history of TEP repair for recurrent open inguinal hernia repair on the right side. This patient first presented in our outpatient department (OPD) with enterocutaneous fistula and mesh infection after TEP repair. Mesh removal along with disconnection of enterocutaneous fistula and laparoscopic repair of enterotomy after refreshing the margins was done. After complete healing of the wound by secondary intention, he was again subjected to TEP repair after 2 months and was successfully operated by our innovative technique.

One patient developed right side inguinal hernia 2 years after bilateral orchidopexy, which was successfully repaired by our technique.

In our technique pain was less in comparison to Hasson trocar technique as all the ports are of 5 mm size. We reported no, SSI, chronic pain, hernia recurrence, incisional hernia or any other complications other than seroma on 6 months follow up. Smaller scars are cosmetically better and always more acceptable to patients.

9. Conclusion

“555 Manish Technique” is simple, less invasive, less morbid, time saving, cost effective and having better cosmetic results with patient satisfaction. There is no dependence on Hasson Trocar & this technique does not compromise on the principles of current surgical procedure. “Manish Retractor” plays a key role in successful completion of surgery.

Acknowledgements

I am thankful to my teachers, my colleagues and my students who supported this work and guided me in need. I am grateful to my wife who is always there wherever I lack and to my son for always making me feel special.

Author details

Manish Kumar Gupta

Address all correspondence to: drmanishgupta2002@yahoo.com

Department of General and Laparoscopic Surgery, Sir Ganga Ram Hospital, New Delhi, India

References

- [1] Kockerling F, Schug-Pass C. Tailored approach in inguinal hernia repair—Decision tree based on the guidelines. *Frontiers in Surgery*. 2014;**1**:Article 20. DOI: 10.3389/fsurg.2014.00020
- [2] Dulucq JL, Wintringer P, Mahajna A. Laparoscopic totally extraperitoneal inguinal hernia repair: Lesson learned from 3,100 hernia repairs over 15 years. *Surgical Endoscopy*. 2009;**23**:482-486
- [3] Rajapandian S, Senthilan P, Gupta A, Gupta PD, Praveenraj P, Vaitheeswaran V, Palanivelu C. Laparoscopic totally extraperitoneal repair of inguinal hernia using two-hand approach—A gold standard alternative to open repair. *Journal of the Indian Medical Association*. 2010;**108**:652-654
- [4] Barrat C, Surlin V, et al BA. Management of recurrent inguinal hernias: A prospective study of 163 cases. *Hernia*. 2003;**7**:125-129
- [5] Hasbahceci M, Basak F, Acar A, Alimoglu O. A new proposal for learning curve of TEP inguinal hernia repair: Ability to complete operation endoscopically as a first phase of learning curve. *Minimally Invasive Surgery*. 2014;**2014**:528517
- [6] Gupta MK, Muley KK, Bethanbhatla MK, Nanavati JD, Manish K, Sarangi R. Mini totally extra-peritoneal repair of inguinal hernia with all 5 mm ports: An innovative "555 Technique". *Journal of Laparoendoscopic & Advanced Surgical Techniques*. 2017 Mar;**27**(3):295-303
- [7] Gupta MK, Bethanbhatla MK, Nanavati JD, Kumar M, Agarwal BB, Sarangi R. An innovative "555 Technique" for totally extra-peritoneal repair of inguinal hernia using all 5 mm ports. *Journal of Laparoendoscopic & Advanced Surgical Techniques Part B, Videoscopy*. 2016;**26**(4)
- [8] Lomanto D, Katara AN. Managing intra-operative complications during totally extra-peritoneal repair of inguinal hernia. *Journal of Minimal Access Surgery*. 2006;**2**:165-170
- [9] Hasson HM. Laparoscopic cannula cone with means for cannula stabilization and wound closure. *The Journal of the American Association of Gynecologic Laparoscopists*. 1998;**5**:183-185

- [10] Bittner R, Arregui ME, Bisgaard T, et al. Guidelines for laparoscopic (TAPP) and endoscopic (TEP) treatment of inguinal hernia [International Endohernia Society (IEHS)]. *Surgical Endoscopy*. 2011;**25**:2773-2743
- [11] Karthik S, Augustine AJ, Shibhumon MM, Pai MV. Analysis of laparoscopic port site complications: A descriptive study. *Journal of Minimal Access Surgery*. 2013;**9**:59-64

IntechOpen

IntechOpen