

We are IntechOpen, the world's leading publisher of Open Access books Built by scientists, for scientists

4,800

Open access books available

122,000

International authors and editors

135M

Downloads

Our authors are among the

154

Countries delivered to

TOP 1%

most cited scientists

12.2%

Contributors from top 500 universities



WEB OF SCIENCE™

Selection of our books indexed in the Book Citation Index
in Web of Science™ Core Collection (BKCI)

Interested in publishing with us?
Contact book.department@intechopen.com

Numbers displayed above are based on latest data collected.

For more information visit www.intechopen.com



Percutaneous Mechanical Circulatory Support Devices: Systems and Clinical Options

Antonio Loforte, Giuditta Coppola, Carlo Mariani, Gregorio Gliozzi, Francesco Grigioni and Giuseppe Marinelli

Additional information is available at the end of the chapter

<http://dx.doi.org/10.5772/intechopen.76925>

Abstract

Cardiogenic shock (CS) still remains a leading cause of hospital death. The adoption of percutaneous ventricular assist devices (pVADs) as treatment of CS is an option which continues to rise. Several types of pVADs have been developed by time to provide full cardiac support with few related complications and easy implantation settings. pVADs are used to support the failing heart as a bridge to recovery, decision, durable device or heart transplantation. None of these devices adopted in the clinical practice is ideal for all patients. Disadvantages may be related to the risk of limb/arm ischaemia or cerebral stroke or haemolysis. The most important choice is to identify the best device for each patient depending on haemodynamics, clinical scenario and patient anatomical/pathological issues. This chapter discusses the current pVAD options to treat CS patients.

Keywords: pVADs, IABP, ECMO, cardiogenic shock, refractory end-stage heart failure, bridge-to-bridge therapy

1. Introduction

Cardiogenic shock (CS) still remains a leading cause of hospital death [1–5]. So far the most common cause of CS is myocardial infarction. However, acute regurgitant valve failure, myocarditis, post-cardiotomy shock and acute on chronic heart failure also may present with end-organ dysfunction from hypoperfusion due to cardiac pump failure, the hallmark of this syndrome. The adoption of percutaneous ventricular assist devices (pVADs) as treatment of CS is an option which continues to rise [1–5]. Several types of pVADs have been developed by

time to provide full cardiac support with few related complications and easy implantation settings. There are only few randomized trials on pVADs, and the current use of them depends on single centre experience [1–5]. pVADs are used to support the failing heart as a bridge to recovery, decision, durable device or heart transplantation (Htx). Improvement in haemodynamic parameters by pVADs has clearly been demonstrated though without mortality benefit in the limited studies to date [1–5]. Early versus late implementation of support may prevent or ameliorate systemic inflammation and end-organ dysfunction in CS syndrome [1–5].

None of these devices used in the clinical practice is ideal for all patients. Disadvantages may be related to the risk of limb/arm ischaemia or cerebral stroke or haemolysis [1–5]. The most important choice is to identify the best device for each patient depending on haemodynamics, clinical scenario and patient anatomical/pathological issues.

This chapter discusses the current pVAD options to treat CS patients.

2. Intra-aortic balloon pump

The intra-aortic balloon pump (IABP) device has been available since 1968 [1–5], and it remains the most used pVAD in clinical practice. It consists of a cylindrical polyethylene balloon that is inserted through the femoral artery and placed into proximal descending aorta distal to the

Device	IABP	TandemHeart	Impella 2.5	Impella CP	Impella 5.0	Peripheral ECMO
Cannula size	7.9 Fr	21 Fr inflow; 15–17 Fr outflow	13 Fr	14 Fr	22 Fr	Centrifugal
Pump mechanism	Pneumatic	Centrifugal	Axial flow	Axial flow	Axial flow	Centrifugal
Insertion technique	Descending aorta via the femoral artery	21 Fr inflow cannula into the left atrium via the left femoral vein and transeptal puncture and 15–17 Fr outflow cannula into the femoral artery	12 Fr catheter placed retrograde across the aortic valve via the femoral artery	14 Fr catheter placed retrograde across the aortic valve via the femoral artery	22 Fr catheter placed retrograde across the aortic valve via a surgical cutdown of the femoral, axillary or subclavian artery	Inflow cannula into the right atrium via the femoral vein, outflow cannula into the femoral artery or axillary artery
Maximum haemodynamic support	0.5–1.0 L/min	4 L/min	2.5 L/min	3.7 L/min	5.0 L/min	>4.5 L/min
Implantation time	+	+++	++	++	++++	++
Risk of leg (or arm) ischaemia	+	+++	++	++	++	+++
Anticoagulation	+	+++	+	+	+	+++

Table 1. Comparison of percutaneous support devices [1–5].

subclavian artery. The balloon inflates during diastole and increases the perfusion of coronary arteries via retrograde flow. The antegrade displacement of the blood caused by the inflation of the balloon increases the mean arterial pressure (MAP) and the flow to the body. The onset of ventricular systole leads to a rapid deflation of the balloon with the drop of the pressure in the aorta and consequently the forward flow with a reduction in afterload, left ventricular end-diastolic pressure (LVEDP) and rise in stroke volume and cardiac output. The decrease of left ventricular wall tension, coronary microvascular resistance and LVEDP along with the rise of diastolic pressure reduces the oxygen consumption and therefore myocardial ischaemia [1–5]. It usually provides a marginal increase in cardiac output of up to 0.5 l/min (**Table 1**). The placement of the device is quite easy to perform. A radiopaque tip is inserted through the arterial access and placed under fluoroscopy, confirmed by the use of the X-ray. To be effective, it requires some level of left ventricular function of the patient and stable electrical rhythm. It should not be used in patients with more than mild aortic insufficiency because of the eventual increase of the diastolic retrograde flow. There are several potential complications due to the IABP placement like balloon rupture, leak or entrapment, infection, limb ischaemia and cerebral stroke. Rarely, it may be the cause of aortic dissection or rupture. The use of the IABP has been tested in several studies [6–9]. The SHOCK trial demonstrated a decrease of hospital mortality in patients with myocardial infarction associated with the thrombolytic therapy or early interventional/surgical revascularization [6, 7]. Nevertheless, there is an increased risk of complications like stroke and bleeding and no improvement in mortality in several meta-analyses when IABP is used for CS due to myocardial infarction [6, 7]. In spite of this, IABP use is widely common and has Class II indications in the current guidelines [8].

3. TandemHeart

The TandemHeart (CardiacAssist, Inc., Pittsburgh, PA) is a continuous-flow centrifugal assist device that was first studied by Thiele et al. [1–5, 9, 10] who randomized 41 patients with CS after acute myocardial infarction (AMI) to IABP or TandemHeart and showed an improvement in cardiac output, power index, pulmonary capillary wedge pressure and mean pulmonary arterial pressure in the second group. On the other side, there was an increased risk of limb ischaemia and coagulopathy [9, 10]. TandemHeart transfers oxygenated blood from the left atrium to the iliac arteries and perfuses the aorta retrogradely [1–5, 9–12]. It provides up to 5 L of haemodynamic support (**Table 1**). One cannula is introduced through the femoral vein up to the right atrium and by means of a transeptal puncture to the left atrium (**Figure 1**). Hence, the oxygenated blood from the left atrium is directed to the pump, and by means of a second cannula into the femoral artery, it can be delivered to the body. It requires very good expertise in transeptal puncture. Contraindications are aortic insufficiency, peripheral vascular diseases, the presence of thrombus in the right and left atrium and coagulopathy. The possible dangerous complications due to the placement of the device are cardiac perforation and tamponade, infection and embolic events including limb ischaemia and cerebral stroke. The TandemHeart device is approved for up to 6 hours of extracorporeal support for cardiopulmonary bypass [1–4, 9–12]. The placement of the device requires between 30 and 45 minutes with

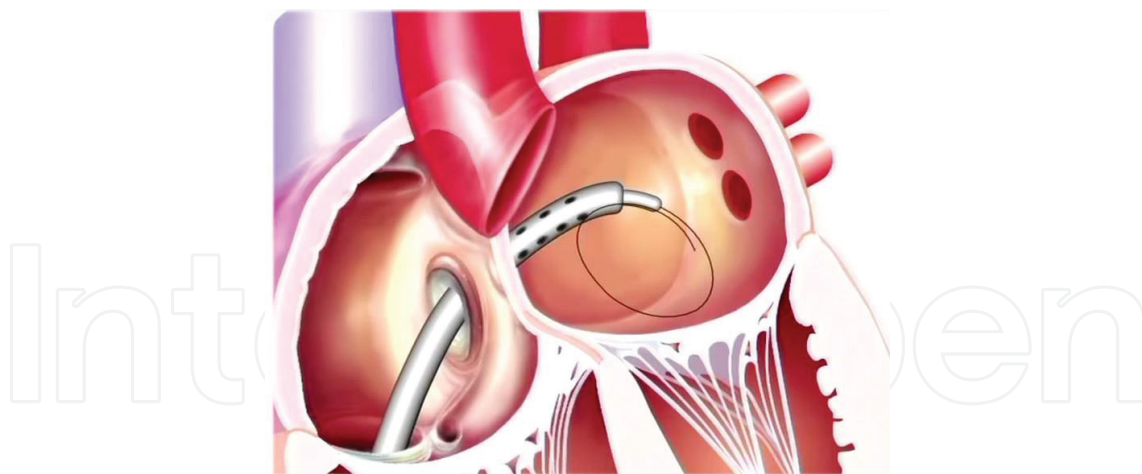


Figure 1. TandemHeart inflow cannula across the atrial septum.

full systemic heparinization [1–4, 9–12]. The left ventricle preload, the filling pressures and the wall stress are reduced, and the peripheral tissue perfusion is increased. Several studies demonstrate a better support and improved haemodynamics than the IABP, but the mortality benefit is the same [9–12]. The Texas Heart Institute experience analyzed 117 patients with severe CS refractory to pharmacological therapy and/or IABP and found a significant improvement in cardiac index and systolic blood pressure [11, 12]. In the 2015 Guidelines for Heart failure, the TandemHeart may be considered in severe left ventricle dysfunction or recent decompensated heart failure with associated technically challenging or prolonged percutaneous intervention (PCI) and continued deterioration of CS patient despite IABP and/or Impella [8].

4. Impella

The Impella Recover LP (Abiomed Inc., Danvers, MA) is a microaxial pump that moves the blood continuously from the LV to the ascending aorta [1–5] (**Figure 2**). There are three classes (**Table 1**) currently available—the Impella 2.5, Impella CP and Impella 5.0—depending on the level of LV support (2.5, 3.5 and 5 L/min, respectively). The Impella 2.5 and CP are the most commonly used [1–5]. The system is composed of three major components: catheter, purge system and automated controller. An impeller and the adjacent motor are positioned near the outlet area in the ascending aorta. Thanks to the rotation, the negative pressure draws the ventricular blood into the inlet area and through the cannula. The Impella 2.5 is used for up to 6 hours for high-risk PCI to prevent haemodynamic instability, while the CP model is indicated for up to 6 hours for partial circulatory support when the cardiopulmonary bypass is not required. Like the TandemHeart, the Impella devices have superior haemodynamics if compared to the IABP in patients with ischaemic cardiogenic shock [1–5]. The Impella 5.0 was developed initially for femoral artery, but nowadays it is positioned through the axillary or subclavian artery. There are two clinical effects provided by this device: the unloading of the cardiac ventricle and the increase in forward flow. The left ventricle wall tension and the

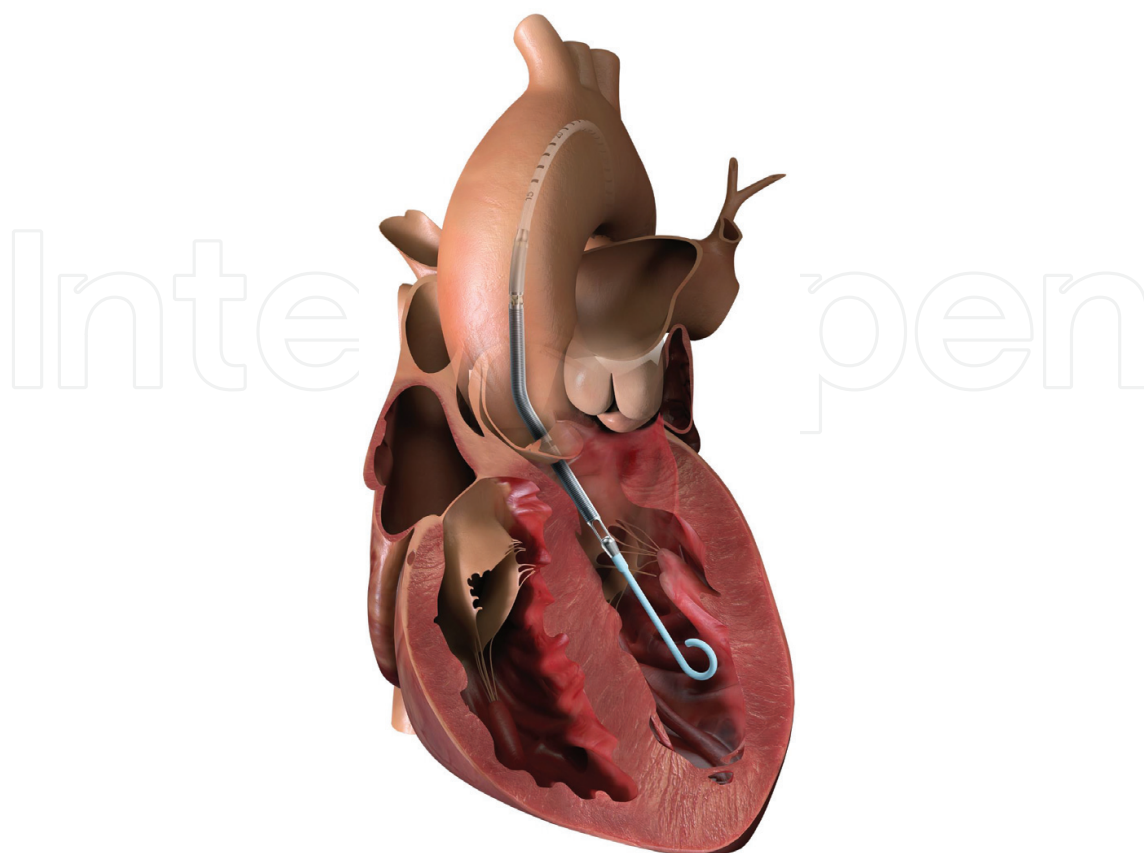


Figure 2. Impella recover left ventricular support.

myocardial oxygen demand are decreased. There is also evidence of improved coronary perfusion pressure and decrease of microvascular resistances [1–5]. The most important limitation of Impella adoption is the size of peripheral vessels to accommodate the large bore catheters. Anticoagulation is required, so the presence of coagulopathy or recent hemorrhage may prohibit the use of this device. Other contraindications to the use of Impella are the presence of a mechanical aortic valve prosthesis or a left ventricle (LV) mural thrombus. The improper positioning or inadequate LV volume may cause suction. Hence, the correct Impella position has to be confirmed with imaging. Case studies [1–5, 13–15] demonstrated successful use of the Impella 5.0 as bridge from ECMO to durable device, during acute rejection in Htx, LV support in RV failure as bridge to durable left ventricular assist device (LVAD), bridge to recovery in patients with myocarditis and bridge to heart transplantation. There are several potential complications due to the use of this device. They include bleeding, infection, vascular injury, stroke, haemolysis, cardiac tamponade and damage to the aortic valve. The PROTECT II trial randomized 452 symptomatic patients with complex multivessel disease or unprotected left main disease and severely depressed LV function, thus showing the superiority of IMPELLA compared with the IABP support [13–15]. Additionally, the catheter-based ventricular assist device (cVAD) registry, which is an observational, multicentre, retrospective registry of patients supported with Impella, reflects the device real-world use and suggests greater survival with pre-PCI Impella insertion than pre-PCI IABP and/or pharmacotherapy alone [13–15].

5. Extracorporeal membrane oxygenation

Extracorporeal membrane oxygenation (ECMO), as being a heparin-coated closed circuit, is a model of mechanical pulmonary or cardiopulmonary support that can be used for a prolonged period [1–5, 16–20]. There are two types of ECMO support: venovenous (VV) and venoarterial (VA). The first one provides only respiratory support since the blood is taken from the right atrium and then oxygenated and CO₂ removed prior to being returned to the right atrium. Both the inflow and the outflow cannulae are positioned through a venous access. It works only for gas exchange in a respiratory failure clinical scenario. The exception is when the outflow cannula is placed in the pulmonary artery to unload and support the right ventricle (RV). In contrast, the VA ECMO provides both haemodynamic/cardiac and respiratory supports. It is used during left ventricular or biventricular failure. The inflow cannula is placed into the right atrium or inferior vena cava, and the blood after gas exchange is delivered back into the arterial vascular system at either peripheral or central cannulation sites. It can provide flows up to 6 L/min without any intrinsic activity of the heart (**Table 1**). The components of ECMO system are drainage and perfusion cannulae, centrifugal or roller pump, membrane oxygenator and heart exchanger. ECMO is important in the case of the need of haemodynamic support for patients with CS or requiring a salvage treatment while on cardiac arrest. It decreases the preload of both right and left ventricles, increases the mean arterial pressure (MAP) and improves end-organ perfusion. Since it increases the LV afterload, the myocardial oxygen consumption is not reduced. The amount of flow depends on the size of the cannulae and the speed of the pump. Even ECMO requires full systemic heparinization [1–5, 16–19]. Contraindications are the presence of an irreversible clinical process, severe multiple organ failure, aortic dissection, peripheral arterial disease and aortic regurgitation. Potential complications are bleeding, injury of vascular vessels, limb or arm ischaemia and thromboembolic events. There are no large randomized trials on the use of ECMO. The Extracorporeal Life Support Organization (ELSO) registry demonstrated a 27% survival to hospital discharge [16, 20]. Recently, a 49% survival was reached with the use of other types of mechanical support systems plus ECMO in a bridge-to-bridge setting as treatment of CS [1–5, 16–20]. Current guidelines recommend the use of ECMO when concomitant hypoxaemia and RV failure are present [1–5, 8, 16–20].

6. Right ventricular assist devices

For several decades the volume administration to maintain RV preload, the vasodilators to decrease RV afterload and the inotropes to ameliorate RV contractility have been used in clinical practice [1–5, 21–27]. The in-hospital mortality is high in patients with RV failure that is refractory to maximal medical treatment [1–5, 21–27]. With the TandemHeart, the percutaneous right ventricular assist device (RVAD) support has become a reality [21]. The TandemHeart is used to provide RV support in such conditions as RV infarction and severe pulmonary hypertension and temporary RV support after placement of a long-term LVAD. In this version the TandemHeart cannulae are positioned into the right atrium and the pulmonary

artery [21]. One model of Impella device, the RP, is approved by the Food and Drug Administration (FDA) for humanitarian device exemption for patients who develop acute right heart failure or decompensation after LVAD implantation, AMI and Htx [22]. The device is implanted into the femoral vein for inflow through the inferior vena cava to reach the outlet area in the pulmonary artery (**Figure 3**). The RECOVER RIGHT trial was a prospective multicentre study that was conducted in 2014 to evaluate the safety and efficacy of the Impella RP [22]. There was successful implantation in 90% of patients who suffered from RV failure with an increase of cardiac index and 73% successful survival to either 30 days or to hospital discharge [22]. Contraindications to the use of this device include severe regurgitation, stenosis or replacement of the tricuspid or pulmonic valves, the presence of filter in the inferior vena cava or the presence of thrombus in the right atrium or in the inferior vena cava. Possible complications are tamponade, vascular injury, liver failure, injury to the tricuspid and pulmonic valves. The other extracorporeal devices used in the clinical practice are the Levitronix CentriMag (Abbott), currently, while the Rotaflow (Maquet) and the Abiomed AB 5000 (Abiomed), historically [23–27]. It is important to choose the adequate sizing for inflow and

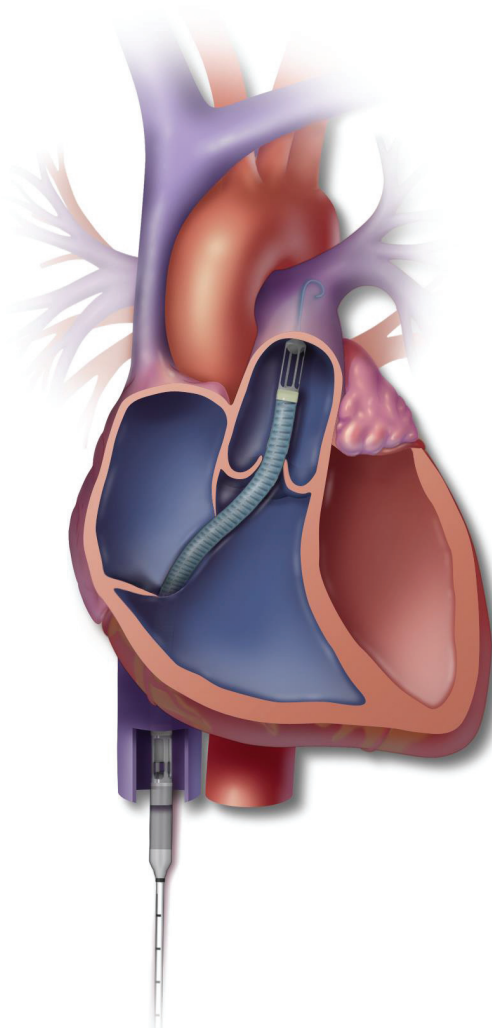


Figure 3. Impella RP setting.

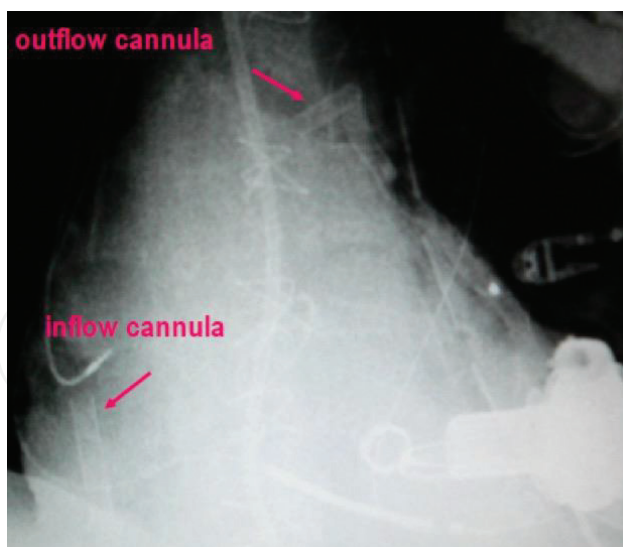


Figure 4. Percutaneous temporary right ventricular assist device placement post-long-term left ventricular assist device insertion.

outflow cannulae to achieve the proper venous drainage and maintain a flow up to 7–8 L/min. Several approaches for RVAD circuit setting arrangement exist nowadays [23–27]. The standard approach requires a full median sternotomy. The inflow cannula is positioned in the right atrium and the outflow in the main pulmonary artery, both secured by double purse-string sutures. The explantation of the device, at the time of RV recovery, requires a re-sternotomy approach. Additionally, alternative effective minimally invasive approaches for RVAD placement exist [23–27]. The one reported by Cohn et al. [25] needs vessel grafts with bedside removal because the cannulas are inserted from outside the chest of the patient and reach the right atrium and the pulmonary artery through the attached grafts. The grafts are firmly secured around their cannulas with heavy sutures. When RV support is no more necessary, the pump lines are clamped, the redundant portions from inside are exposed, the tapes are cut and the cannulas removed, without reopening the chest [25]. A modified transcutaneous technique has been described by Strauch et al. [26]. A minithoracotomy approach may be used in the case of post-LVAD RV failure [23, 24] (**Figure 4**). According to this Berlin technique, the main pulmonary artery cannula is located through a transthoracic needle under transesophageal echo (TEE) guidance. The venous cannula of RVAD is advanced through the inferior vena cava into the right atrium by Seldinger approach. This technique is difficult in the case of severe adhesions related to previous cardiothoracic surgery [23, 24].

Disclosures

No funding sources and relevant disclosures to declare.

Author details

Antonio Loforte*, Giuditta Coppola, Carlo Mariani, Gregorio Gliozzi, Francesco Grigioni and Giuseppe Marinelli

*Address all correspondence to: antonioloforte@yahoo.it

Department of Cardiothoracic, Transplantation and Vascular Surgery, S. Orsola Hospital, Bologna University, Bologna, Italy

References

- [1] Basra SS, Loyalka P, Kar B. Current status of percutaneous ventricular assist devices for cardiogenic shock. *Current Opinion in Cardiology*. 2011;**26**(6):548-554
- [2] Naidu SS. Novel percutaneous cardiac assist devices. *Circulation*. 2011;**123**:533-543
- [3] Ergle K, Parto P, Krim SR. Percutaneous ventricular assist devices: A novel approach in the management of patients with acute cardiogenic shock. *The Ochsner Journal*. 2016; **16**(3):243-249
- [4] Werdan K, Gielen S, Ebel H, Hochman JS. Mechanical circulatory support in cardiogenic shock. *European Heart Journal*. 2014;**35**(3):156-167
- [5] Touchan J, Guglin M. Temporary mechanical circulatory support for cardiogenic shock. *Current Treatment Options in Cardiovascular Medicine*. 2017;**19**(10):77
- [6] Sanborn TA, Sleeper LA, Bates ER, et al. Impact of thrombolysis, intra-aortic balloon pump counterpulsation, and their combination in cardiogenic shock complicating acute myocardial infarction: A report from the SHOCK Trial Registry. Should we emergently revascularize occluded coronaries for cardiogenic shock? *Journal of the American College of Cardiology*. 2000;**36**:1123-1129
- [7] Thiele H, Schueller G, Neumann FJ, et al. Intraaortic balloon counterpulsation in acute myocardial infarction complicated by cardiogenic shock: Design and rationale of the Intraaortic balloon pump in cardiogenic shock II (IABP-SHOCK II) trial. *American Heart Journal*. 2012;**163**(6):938-945
- [8] Rihal CS, Naidu SS, Givertz MM, et al. SCAI/ACC/HFSA/STS clinical expert consensus statement on the use of percutaneous mechanical circulatory support devices in cardiovascular care: Endorsed by the American Heart Association, the Cardiological Society of India, and Sociedad Latino Americana de Cardiologia Intervencion; affirmation of value by the Canadian Association of Interventional Cardiology-Association Canadienne de Cardiologie d'intervention. *Journal of the American College of Cardiology*. 2015, 2015;**65**(19):e7-e26

- [9] Thiele H, Sick P, Boudriot E, et al. Randomized comparison of intra-aortic balloon support with a percutaneous left ventricular assist device in patients with revascularized acute myocardial infarction complicated by cardiogenic shock. *European Heart Journal*. 2005; **26**(13):1276-1283
- [10] Burkhoff D, Cohen H, Brunckhorst C, O'Neill WW, the TandemHeart Investigators. A randomized multicenter clinical study to evaluate the safety and efficacy of the TandemHeart percutaneous ventricular assist device versus conventional therapy with intraaortic balloon pumping for treatment of cardiogenic shock. *American Heart Journal*. 2006; **152**(3):469 e1-8
- [11] Gregoric ID, Basra SS, et al. The percutaneous ventricular assist device in severe refractory cardiogenic shock. *Kar B, Journal of the American College of Cardiology*. 2011; **57**:688-696
- [12] Bruckner BA, Jacob LP, Gregoric ID, et al. Clinical experience with the TandemHeart percutaneous ventricular assist device as a bridge to cardiac transplantation. *Texas Heart Institute Journal*. 2008; **35**(4):447-450
- [13] O'Neill WW, Kleiman NS, Moses J, et al. A prospective, randomized clinical trial of hemodynamic support with Impella 2.5 versus intraaortic balloon pump in patients undergoing high-risk percutaneous coronary intervention: The PROTECT II study. *Circulation*. 2012; **126**:1717-1727
- [14] Dangas GD, Kini AS, Sharma SK, et al. Impact of hemodynamic support with Impella 2.5 versus intraaortic balloon pump on prognostically important clinical outcomes in patients undergoing high-risk percutaneous coronary intervention (from the PROTECT II randomized trial). *The American Journal of Cardiology*. 2014; **113**:222-228
- [15] Cohen MG, Ghatak A, Kleiman NS, et al. Optimizing rotational atherectomy in high-risk percutaneous coronary interventions: Insights from the PROTECT IotaIota study. *Catheterization and Cardiovascular Interventions*. 2014; **83**:1057-1064
- [16] Rouse N, Juthier F, Pincon C, et al. ECMO as a bridge to decision: Recovery, VAD, or heart transplantation? *International Journal of Cardiology*. 2015; **187**:620-627
- [17] Abrams D. Extracorporeal membrane oxygenation in cardiopulmonary disease in adults. *Journal of the American College of Cardiology*. 2014; **63**(25):2769-2778
- [18] Thiagarajan RR, Brogan TV, Scheurer MA, et al. Extracorporeal membrane oxygenation to support cardiopulmonary resuscitation in adults. *The Annals of Thoracic Surgery*. 2009; **87**:778-785
- [19] Takayama H, Truby L, Koekort M, et al. Clinical outcome of mechanical circulatory support for refractory cardiogenic shock in the current era. *The Journal of Heart and Lung Transplantation*. 2013; **32**(1):106
- [20] Abrams D, Garan AR, Abdelbary A, et al. International ECMO Network (ECMONet) and The Extracorporeal Life Support Organization (ELSO). Position paper for the organization

of ECMO programs for cardiac failure in adults. *Intensive Care Medicine*; 2018 Feb 15. DOI: 10.1007/s00134-018-5064-5. [Epub ahead of print]

- [21] Kapur NK, Paruchuri V, Korabathina R, et al. Effects of a percutaneous mechanical circulatory support device for medically refractory right ventricular failure. *The Journal of Heart and Lung Transplantation*. 2011;**30**(12):1360-1367
- [22] Anderson MB, Goldstein J, Milano C, et al. Benefits of a novel percutaneous ventricular assist device for right heart failure: The prospective RECOVER RIGHT study of the Impella RP device. *The Journal of Heart and Lung Transplantation*. 2015;**34**(12):1549-1560
- [23] Stepanenko A, Kukucka M, Vierecke J, et al. Right ventricular recovery induced by temporary right ventricular assist device support. *Thoracic and Cardiovascular Surgeon*. 2015;**63**(Suppl 1):88
- [24] Loforte A, Stepanenko A, Potapov EV, et al. Temporary right ventricular mechanical support in high-risk left ventricular assist device recipients versus permanent biventricular or total artificial heart support. *Artificial Organs*. 2013;**37**(6):523-530
- [25] Cohn WE, Gregoric ID, La Francesca S, Frazier OH. Bedside right ventricular assist device removal in the conscious patient. *The Annals of Thoracic Surgery*. 2007;**83**(4):1556-1557
- [26] Strauch JT, Franke UF, Madershahian N, Wahlers T. Right ventricular assist device implantation: A new transcatheter approach. *The Thoracic and Cardiovascular Surgeon*. 2004;**52**(6):378
- [27] Loforte A, Grigioni F, Marinelli G. The risk of right ventricular failure with current continuous-flow left ventricular assist devices. *Expert Review of Medical Devices*. 2017; **14**(12):969-983

