

We are IntechOpen, the world's leading publisher of Open Access books Built by scientists, for scientists

4,800

Open access books available

122,000

International authors and editors

135M

Downloads

Our authors are among the

154

Countries delivered to

TOP 1%

most cited scientists

12.2%

Contributors from top 500 universities



WEB OF SCIENCE™

Selection of our books indexed in the Book Citation Index
in Web of Science™ Core Collection (BKCI)

Interested in publishing with us?
Contact book.department@intechopen.com

Numbers displayed above are based on latest data collected.
For more information visit www.intechopen.com



Anterior Primary Total Hip Arthroplasty

Ulrich Bechler, Bernhard Springer and
Friedrich Boettner

Additional information is available at the end of the chapter

<http://dx.doi.org/10.5772/intechopen.76070>

Abstract

Total hip arthroplasty (THA) is the preferred treatment for end-stage osteoarthritis of the hip. The posterior, posterolateral, direct lateral, anterolateral, or the anterior approaches are the currently established surgical approaches for THA. Over the last decade, the anterior approach has gained increasing popularity. Its muscle-sparing nature and fluoroscopy-guided component positioning are the most important benefits. It has been suggested that postoperative recovery is facilitated by an anterior approach. Patients do not need to follow hip precautions, and can return to driving after 1 week. The anterior approach uses a muscle interval between the tensor fasciae latae and the rectus femoris to open the capsule without detachment of muscles. Especially, the external rotators and posterior capsule remain intact and reduce the risk of posterior dislocation. Accuracy of acetabular component positioning has an impact on postoperative dislocation rates, polyethylene wear, and impingement. When the operation is done in a supine position, fluoroscopy is available to check the acetabular component inclination and anteversion during THA as well as leg length and offset. The current chapter reports on the surgical approach, surgical technique, and results of anterior THA.

Keywords: primary total hip arthroplasty, minimally invasive surgery, anterior approach, osteoarthritis, intraoperative fluoroscopy, outcome

1. Introduction

THA is used to treat a variety of primary and secondary end-stage osteoarthritis, and has the primary goal to decrease pain, restore function, and increase joint mobility [1]. Depending on the specific patient there are various surgical techniques described to perform a THA. The

general goal is to have an accurate and reproducible procedure and to avoid complications. Younger and more active patients have increased functional demands during early recovery. Utilizing an intramuscular approach allows for a faster return to activities of daily living, reduced pain, shortened recovery, and reduced costs [1].

The various available approaches are characterized by their own distinct advantages and risks. Extensions to these approaches have been described and allow for more extensive exposure and revision procedures.

In the USA, the most frequently used approach is the posterior approach. It provides easy access to the hip joint and minimizes the trauma to the hip abductor muscles. However, detachment of external rotator muscles and a complete capsulectomy results in an increased dislocation rate [2, 3]. Therefore, the repair of the external rotators and the capsule is of great importance in posterior THA [4]. In addition, the posterior approach is associated with an increased variance of acetabular component positioning [5–7]. Poor component positioning increases the risk of dislocation, facilitates increased polyethylene wear, and impingement [5, 8, 9]. Variations in the lateral patient position and the lack of intraoperative fluoroscopy might explain the less predictable cup positioning [10].

The lateral approach (anterolateral) with the patient lying in a supine position is a popular approach in Europe. The posterior part of the gluteus medius insertion can be preserved. However, injury or release of its anterior portion can result in limping [11]. Fractures of the greater trochanter are more likely using the lateral approach compared to the posterior approach [12, 13]. Postoperative patient-reported limping occurs twice as often using the lateral approach compared to the anterior approach [14]. Limping may be caused by trochanteric pain, leg length discrepancy, lack of offset restoration, nerve injury, or insufficiency of the gluteal muscles [15].

The anterior THA is unique because of its intramuscular and internervous exposure of the hip joint. A release of major muscular stabilizers is not necessary for most patients. First described by Smith-Peterson in 1949, the anterior approach became more popular in the USA over the last decade [16]. Rapid recovery, decreased dislocation rate, fluoroscopy controlled restoration of leg length, and offset as well as component position are its main benefits.

2. History

In 1881, Carl Hueter was the first surgeon to describe the anterior approach for resection of the femoral head. Smith-Peterson further developed the approach and described the extended exposure of the pelvis to perform a hip replacement. In 1978, Wagner preferred the approach for hip resurfacing procedures due to its preservation of the femoral blood supply and intermuscular dissection [17]. In 1947, the Judet table was developed and predominantly used in France. Ten years later, a special table was developed to optimize and ease the positioning of the operated leg in order to decrease injury to muscles and bone.

In the US, the anterior approach was originally combined with a lateral incision to facilitate the insertion of the femoral component and was marketed by Zimmer Biomet (Warsaw, IN, USA) in conjunction with Richard Berger as a “two incision” THA [1, 18]. Because of the higher complication rate, especially on the femoral side (fracture), the approach fell out of favor in the beginning of the twenty-first century [19]. At the same time, Joel Matta promoted an anterior approach without a second incision [20]. Matta soon realized that a special table similar to the Judet table was needed to improve exposure of the femur and provide elevation of the femur. Since the Judet table was not available in the USA, he pursued the development of the Hana® table (Mizuho OSI, Union City, CA, USA).

In 2004, large studies [20, 21] showed encouraging outcomes with low dislocation rate (<1%) and improved component positioning, but above all faster recovery pushed the interest in the anterior approach.

3. Anatomy and approach

The anterior approach classically described as Smith-Peterson approach uses an incision proximal and distal to the anterior superior iliac spine (ASIS) along the tensor fasciae latae [16]. While the proximal portion of the Smith-Peterson approach facilitates exposure of the pelvis, the distal portion is used during a direct anterior THA to expose the hip joint. The groin area usually has less subcutaneous fat than the lateral thigh, and therefore an anterior approach often has a more direct access to the fascial layer. The ASIS and greater trochanter are used as bony landmarks to guide placement of the incision. The incision usually starts

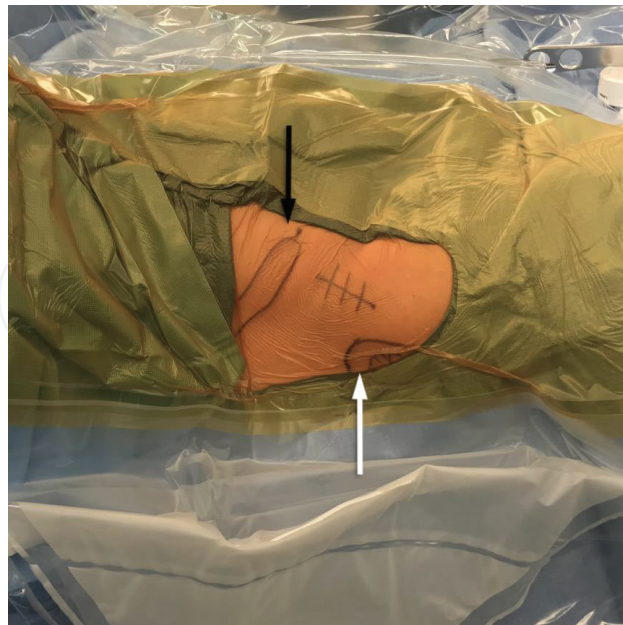

Figure 1. Patient in a supine position on a Hana® table. The skin incision, the anterior superior iliac spine (black arrow), and greater trochanter (white arrow) are marked.

two fingerbreadths lateral and distal of the ASIS and extends distally and posteriorly in line with the tensor fasciae latae muscle [20]. A slightly more lateral position can help to avoid the lateral femoral cutaneous nerve (LFCN) that enters the thigh medially to the ASIS (**Figure 1**).

The approach uses an intermuscular plane and does not require muscle releases. Medially, the interval borders to the Sartorius muscle (innervated by the femoral nerve) and laterally to the tensor fasciae latae muscle (innervated by the superior gluteal nerve) [22]. While the original Smith-Petersen approach entered between the sartorius muscle and the tensor fasciae latae, the modern anterior approach usually stays inside the fascia of the tensor fasciae latae to minimize the risk to injure the LFCN (**Figure 2**) [22]. Care should be taken not to confuse the medial located sartorius muscle and the more lateral tensor fasciae latae. Both can usually, easily be separated by the direction of the fibers. The tensor fasciae latae muscle fibers ran toward the lateral thigh in contrast to the sartorius muscle fibers, which run medially. After skin incision, the fascia of the tensor is split followed by deep finger dissection to separate the overlying fascia and the muscle belly of the tensor fasciae latae and progress toward its medial borders.

The deep intermuscular fat tissue between tensor and rectus femoris muscle contains the ascending branch of the lateral circumflex artery just proximal to the vastus lateralis muscle. At the level of the capsule, the interval is bordered by the gluteus medius (superior gluteal nerve) and medially by the rectus femoris muscle (femoral nerve). Ligations of the branches of the circumflex vessels are necessary to prevent perioperative bleeding and postoperative hematoma formation (**Figure 3**).

A Hohmann retractor is used to expose the anterior hip capsule. It is placed underneath the rectus muscle. A second blunt retractor is placed around the lateral femoral neck. The reflected head of the rectus femoris muscle is elevated and released to expose the capsule entirely. The released tendon can be marked to facilitate its identification and repair at the end of the procedure.

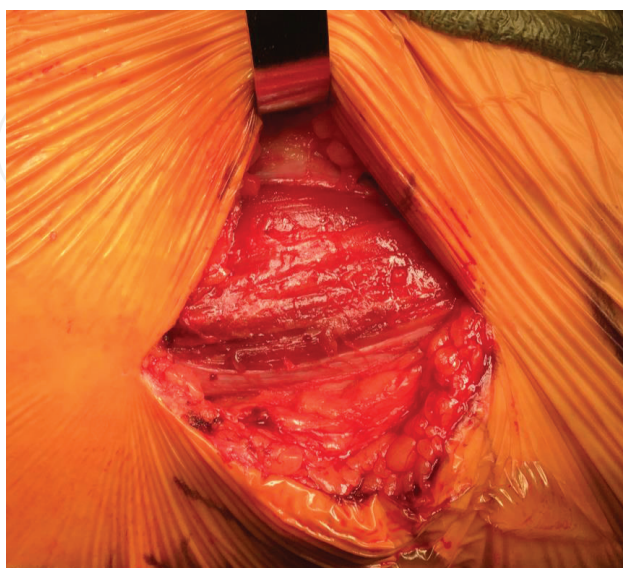

Figure 2. Incision of the fascia of the tensor fasciae latae muscle.

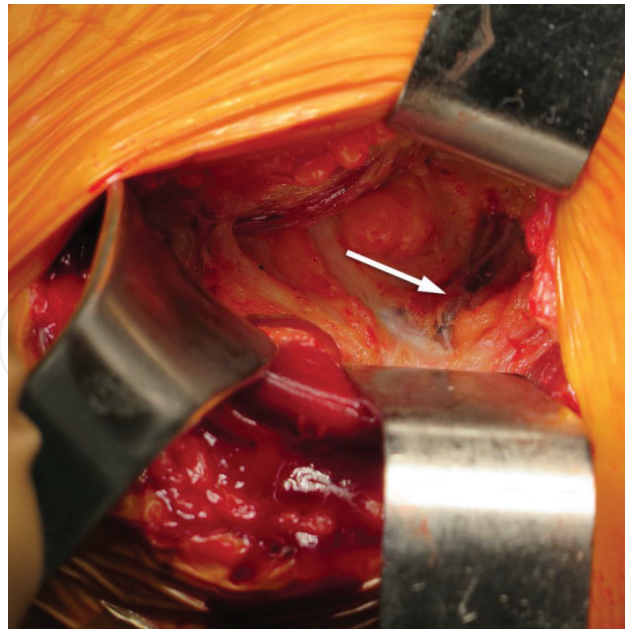


Figure 3. Image of the deep interval bordered laterally by the gluteus medius (superior gluteal nerve) and medially by the rectus femoris muscle (femoral nerve). The lateral femoral circumflex vessels (arrow) are visualized proximal to the vastus lateralis muscle.

4. Surgical technique

The procedure is performed under general or regional anesthesia. It can be performed with a standard operating table with an Omni-Tract® femur elevating system (Integra, Plainsboro, NJ, USA) or a specialized orthopedic table (Hana®, Mizuho OSI, Union City, CA, USA). The latter helps to control hip rotation, abduction, flexion, and traction of the affected extremity and facilitates exposure of the proximal femur for femoral component insertion. However, the costs, fracture risk, and limited ability to intraoperatively test the range of motion (ROM) are its main disadvantages. A number of alternative tables are currently available by other manufactures.

The authors recommend careful templating and implant selection. The primary goal of the templating is to guide acetabular reaming toward the most appropriate reamer size. On the femoral side, depending on the type of femur, shorter implants with less sizable distal dimensions might be preferred in a Dorr Type A Femur, while compression broaching for a longer implant with a collar might be preferred for a Dorr Type C femur [23]. In addition, careful planning of the femoral neck resection can help intraoperatively to restore the leg length.

The patient is lying supine on the table with a perineal post and both legs secured with the feet in boots. The pelvis and the nonsurgical hip are placed in a neutral position. After the standard anterior approach, as described above, a T-shaped capsulotomy is performed with medial and lateral extension at the level of the intertrochanteric ridge (**Figure 4**). The capsule can be tagged and preserved for later repair. Two Hohmann retractors are now placed within the capsule around the lateral and medial femoral neck. A napkin ring double osteotomy of the femoral neck is performed to ease removal of the head (**Figure 5**). The femoral head is removed with a corkscrew extractor. Additional traction and external rotation on the operated

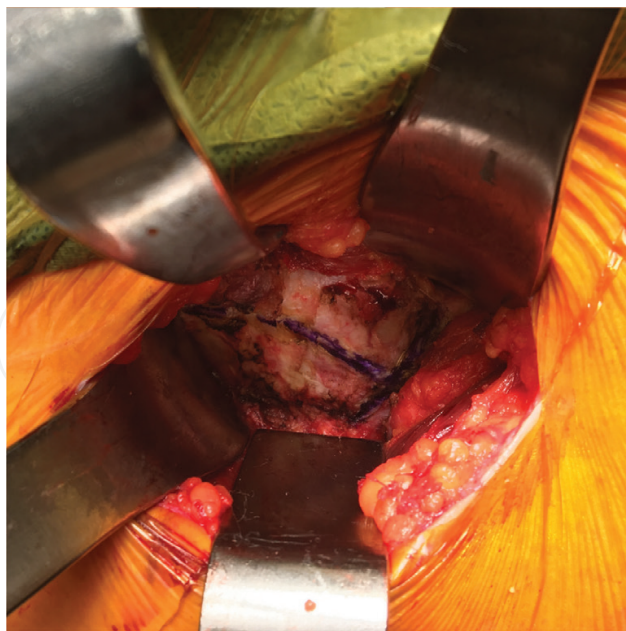


Figure 4. Markings for the T-shaped capsulotomy with medial and lateral extension.

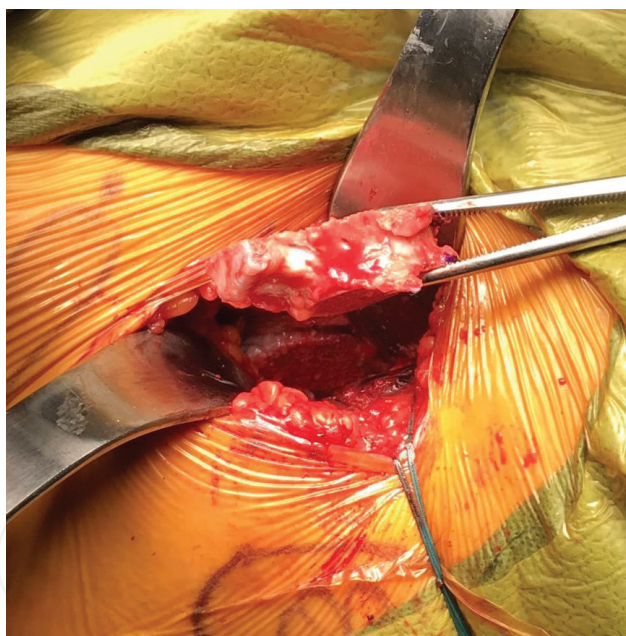


Figure 5. Photograph of a napkin ring double osteotomy of the femoral neck.

leg supports removal of the napkin ring and exposure of the acetabulum. Alternatively, to the *in situ* neck osteotomy, the hip can be dislocated using a corkscrew. The capsular releases are completed with the hip dislocated before the hip is reduced, the neck is cut, and the head removed (technique according to Matta et al. [20]).

Multiple retractors are used to facilitate acetabular exposure. First, an acetabular retractor is placed inferiorly to the fovea against the transverse acetabular ligament. This usually requires

a short incision of the medial capsule. This is, followed by an anterior retractor, placed between the anterior labrum and capsule. A posterior retractor can be placed between the posterior labrum and capsule. The foveal tissue and labrum are removed. The acetabulum is either reamed under direct visualization or under fluoroscopy guidance. A press fit cup is placed and impacted (**Figure 6**). To facilitate cup alignment under the anterior acetabular bone, an implant less hemispherical than 180° is preferred. It also helps to medialize the center of rotation in comparison to a hemispherical cup.

The C-arm is used to guide intraoperative component positioning. An alternative to this technique is the use of intraoperative navigation. Because of the supine position and easy access to the iliac crest intraoperative navigation is usually fairly straightforward in anterior THA. Other techniques available for optimized cup position are based on C-arm images and include software programs like Radlink® (Radlink, El Segundo, CA, USA) and Jointpoint® (Jointpoint Inc., Belleair Bluffs, FL, USA).

The C-arm is positioned in 90° to the supine patient and centered over the pelvis to make sure the pelvis is in a neutral position (**Figure 7**). A neutral pelvis position is the requirement for any of the described C-arm based algorithms. If no software is available, the cup inclination can be checked with the C-arm centered in the middle of the pelvis. After reaching the target inclination of the acetabular component, the C-arm is moved over the operated hip. After estimating the cup anteversion based on the opening ellipse, the cup anteversion can be determined based on the C-arm tilt angle described by Boettner et al. and Zingg et al. [6, 24] (**Figure 8**). When aligned perfectly the elliptical shape of the cup presents as a line. The tilt angle can be measured on the C-arm and used to calculate the acetabular anteversion. Following correct acetabular implant positioning, the final liner is inserted and osteophytes are removed.

Exposure of the proximal femur can be facilitated by a standard release to minimize traction forces on the greater trochanter. This prevents intraoperative complications like fractures

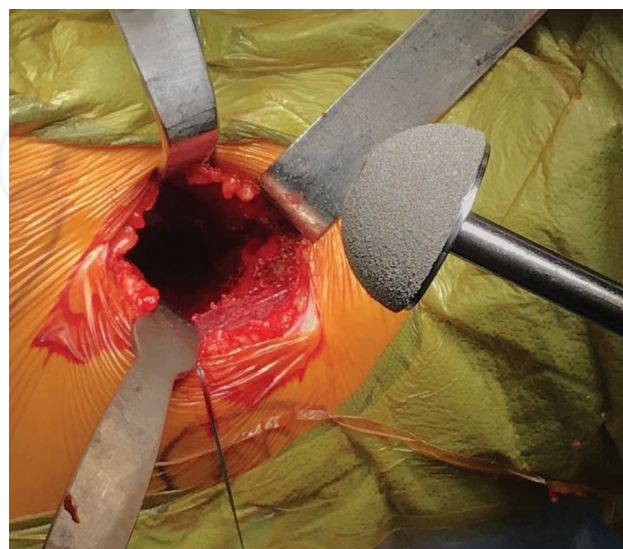


Figure 6. A press fit cup is placed and impacted into the reamed acetabulum.

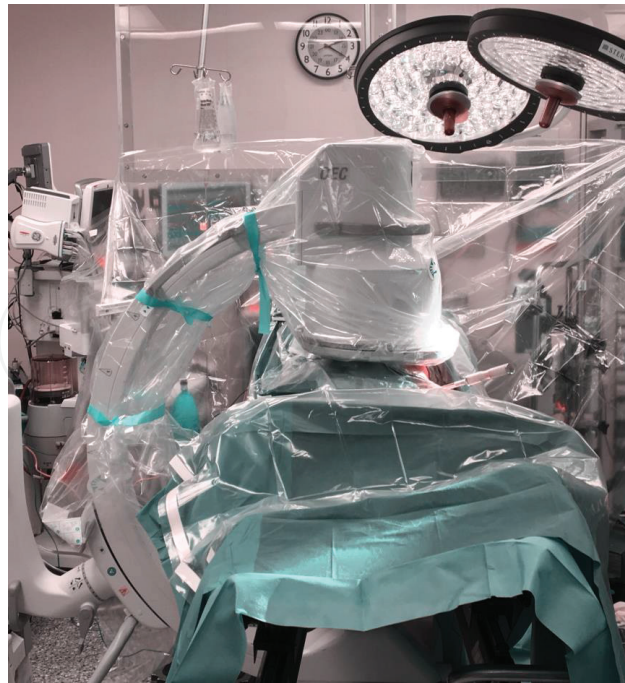


Figure 7. C-arm position in a 90° angle to the supine patient. The beam is centered over the neutral pelvis to assess inclination of the cup.

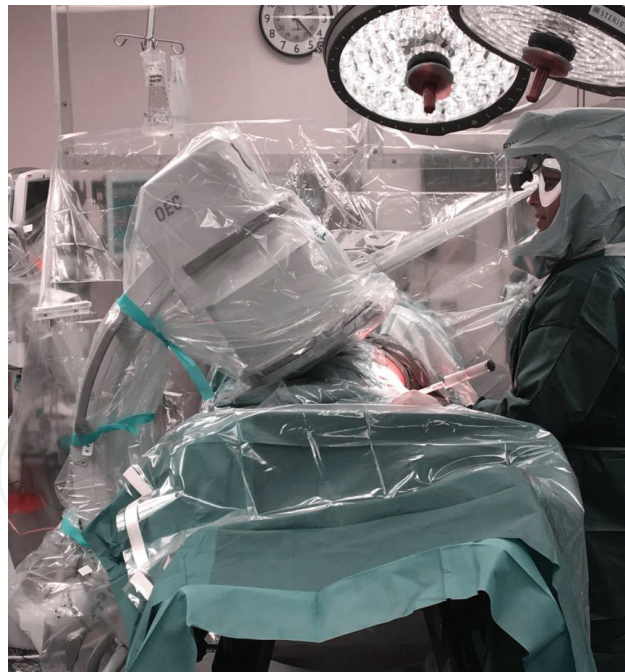

Figure 8. C-arm is tilted away from the operated hip until the ellipse of the positioned acetabular component is a straight line. The tilt angle is measured on the C-arm.

during anterior mobilization of the femur. The gluteus minimus muscle is elevated of the lateral capsule. The operated leg is positioned in extension, 90° external rotation and 20° adduction. In flexible patients adequate exposure might be possible without further releases;

however, the senior author favors the release of the conjoined tendon. The piriformis muscle insertion is preserved together with the posterior capsule, obturator externus muscle, and quadratus femoris muscle.

The Hana table® or Omni-tract® retractor provides a hook attached to a connector arm of the table. In combination with maximum extension of the leg, the hook elevates the femur anteriorly and provides better exposure for the preparation of the femoral component (**Figure 9**). Offset handles facilitate the broaching of the femur. Femoral preparation and broaching the femoral canal is done in a standardized fashion (**Figure 10**). The final trial stem is impacted into the femur with a trial head and neck.

Care should be taken not to injure the tensor fasciae latae. Good exposure to the femoral canal eases preparation and broaching. After adding the trial neck and head, the surgeon can reduce the dislocate hip with gentle traction and internal rotation. The surgeon guides the femoral head into the socket. Fluoroscopy can be used to assess leg length discrepancy, offset, and implant alignment.

For measurements of the leg length discrepancy, the inter-teardrop line is used as horizontal reference of the fluoroscopy image. The difference between the vertical distances from the reference line to the most prominent point on each lesser trochanter defines the leg length discrepancy with reference to the contralateral hip. Neutral pelvis position and equal leg abduction and rotation are required for accurate measurements. Alternatively, leg length and offset can be determined by overlaying two print-out images and comparing the contour of the operated hip to either the opposite normal or the preoperative image. Finally, the definite femoral component is implanted. The wound is irrigated and the anterior capsule closed using Vicryl #0 suture (**Figure 11**). The reflected head of the rectus can be repaired. Finally, the fascia of the tensor fasciae latae muscle is closed with #0 Vicryl sutures (**Figure 12**).

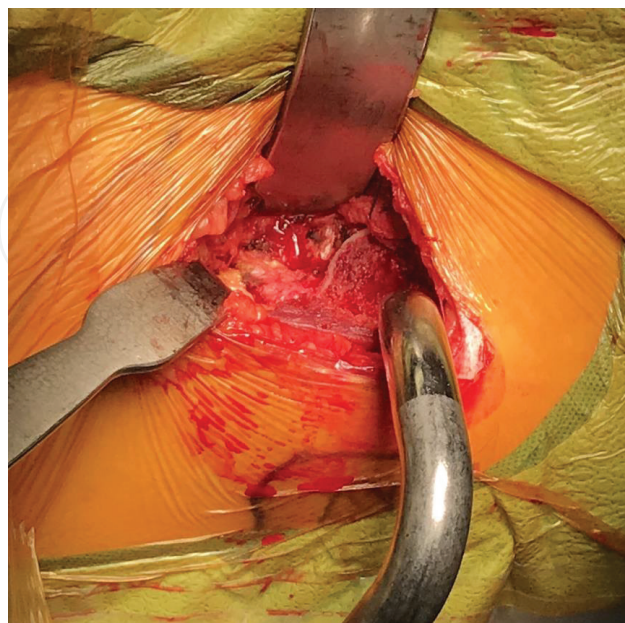


Figure 9. A hook attached to a connector arm of the table facilitates femoral exposure.

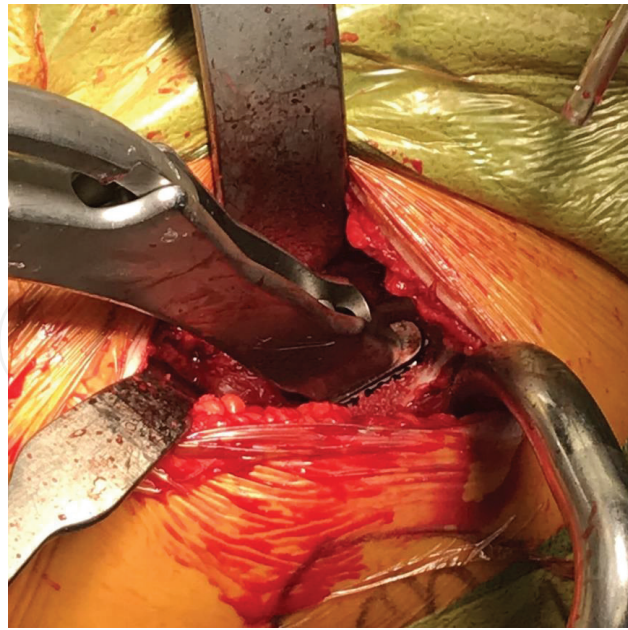

Figure 10. Photograph shows broaching of the femoral component.

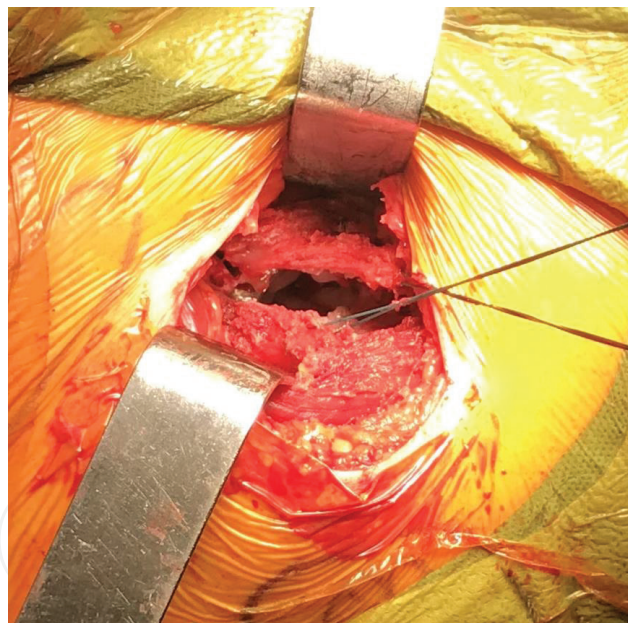


Figure 11. Tagging sutures in the medial and lateral capsular sleeve.

Many surgeons prefer a curved “Banana Type” stem for the anterior approach. Straight stem designs with a lateral shoulder require more aggressive releases including the piriformis tendon. There have been some concerns about increased femoral loosening rates and continued efforts are made to improve and develop femoral implant design. Due to the missing lateral shoulder, the curved stem provides no lateral support. As a result, lateralization and subsidence

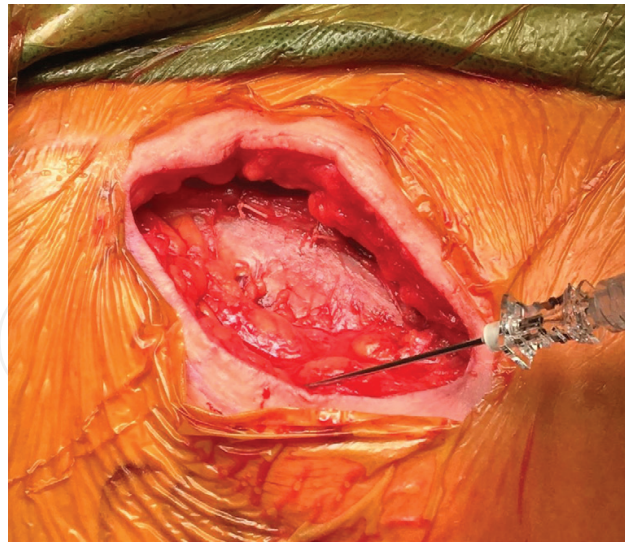


Figure 12. Photograph of the closed fascia of the tensor fasciae latae. A local anesthetic is injected into the subcutaneous layer.

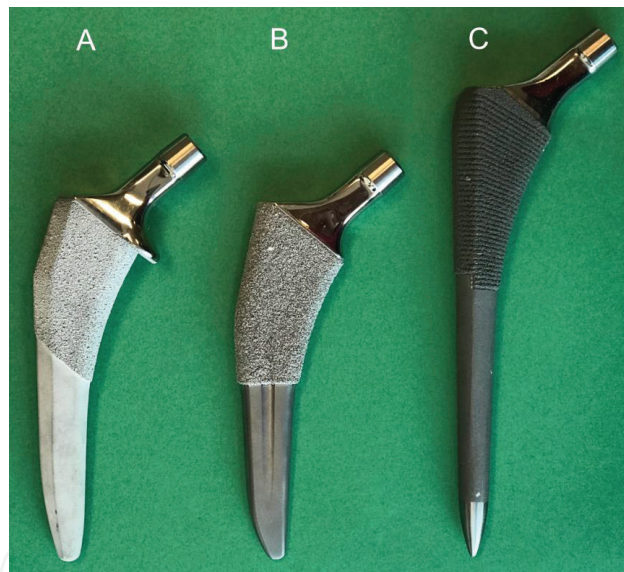


Figure 13. DePuy Synthes, Warsaw, IN, USA: (A) Medial collar and triple tapered ACTIS® Total Hip System. (B) Tapered-wedge TRI-LOCK® Bone Preservation Stem. (C) SUMMIT® Tapered Hip System.

with weight bearing can occur. The new stem designs often add a medial collar to augment primary stability for immediate weight bearing and reduced risk of subsidence (**Figure 13**).

To increase short and long-term stability, fully coated stems are preferred to achieve more reliable fixation. In addition, an overall more canal filling proximal stem design provides more proximal bone fixation compared to blade shaped medial-lateral implant fixation.

5. Standard table

Several advantages exist for the standard table in comparison to the Hana table. The ability to maneuver the legs allow for intraoperative assessment of leg length. The surgeon can directly manage the leg and no additional assistance is required to manage the table. In general, any operative table can be used that is radiolucent and allows for extension of the legs at the level of the hip joint. Regarding the surgical technique, there is no difference in the type of soft tissue releases between a standard or specialized table. The patient is positioned in a supine position with the hip joint at the level of the table break. It is necessary to hyperextend the operated hip during femoral preparation. Draping both lower extremities in a sterile fashion allows an intraoperative crossover of the operated leg for femoral exposure. The leg length discrepancy can be measured manually.

If an anterior retractor is used, the bone hook is inserted with the femur in neutral rotation. Afterward the leg is placed in a figure 4 position (external rotation) to release the medial capsule down to the lesser trochanter. There is no difference in the soft tissue release technique; however, the piriformis usually has to be released in heavy male patients. The distal part of the standard table is extended to 40° allowing hyperextension of the operated hip as well as adduction and external rotation while positioning the limb crossing under the contralateral side.

6. Outcome

Over the last couple of years, the anterior approach has become increasingly popular. Many advantages are described in comparison to the other approaches mentioned at the beginning of this chapter. Patients treated with the minimal invasive approach suffer less pain and consume fewer narcotics [25, 26]. This is usually explained by less soft-tissue damage while avoiding muscle splitting and detachment in comparison to the posterior or anterolateral approach.

An improved hip function and earlier return to normal gait are attributed to using an intermuscular and internervous interval [27, 28]. Rodriguez et al. have shown that patients reach certain milestones after an anterior THA earlier compared to a posterior THA. However, patients with a posterior approach had a similar result after 12 weeks [29].

The possibility of using intraoperative fluoroscopy when performing an anterior THA offers advantages over a posterior THA. The percentage of cup placed in the safe zone increases when using fluoroscopy routinely [6]. A higher precision and increased accuracy when implanting cup components can lead to a decreased dislocation rate [6, 21]. The anterior approach also improves relation of leg length and offset [7].

The majority of hip dislocations occur during the first 3 months after surgery. The healing of the posterior capsule and external rotator muscles release during a conventional posterior approach is considered the reason for early dislocation [30]. Hip precautions are recommended for 4–12 weeks to prevent any flexion and internal rotation after posterior THA [31].

The muscle sparing anterior approach avoids release of the piriformis and obturator externus tendon. No specific hip precautions are needed and the patient is able to return to his or her normal activities after surgery without limitations [32]. The dislocation rate for the anterior THA is described in literature ranges between 0.6 and 0.9% [20, 21]. It is lower in comparison to those reported for other approaches; however, comparative studies have failed to show a consistent benefit [33, 34]. The senior author has no reported dislocations at all after performing more than 500 THAs using an anterior approach.

7. Challenges with the anterior approach

Switching the surgical approach to an anterior THA is associated with a learning curve within the first 40–100 cases [35, 36]. Improvements in surgical and fluoroscopy times as well as differences in leg length have been reported during the learning curve [37, 38]. During the learning curve, it is recommended to carefully select patients. In general, preferred patients are thin and younger females with elongated femoral necks and a type B Dorr Femur.

The anterior approach has some specific complications. These include LFCN injury and greater trochanteric fracture. Injury of LFCN is most commonly encountered during exposure and retraction. The nerve is located in the intermuscular-internervous interval between the sartorius and tensor fasciae latae muscle and is at risk if the incision is extended distally. Its course varies in different branching patterns and is at risk in approximately one-third of the patients during an anterior approach [39]. The risk of an injury can be minimized when staying inside the tensor fascia rather than the interval between the tensor and sartorius muscle [40]. LCFN neurapraxia occurs in approximately 0–5% of patients [41, 42]. None of the patients experienced any hip-related functional limitations, while most symptoms resolving after 6–24 months [37, 43, 44].

Muscle damage has not been considered a major problem due to the intermuscular nature of the approach [45]. Nevertheless, incorrect placement or retraction may cause damage. During capsular exposure the rectus femoris muscle is elevated and at risk. Attention while placing the retractors or using specialized retractors developed for the anterior THA can reduce the risk of soft-tissue damage. During femoral exposure the tensor is at risk for injury as well.

Cup alignment is challenging when performing an anterior THA due to limited view of the anterior acetabular wall. When inserting the reamer into the acetabulum, the anterior aspect of the femur might block its entrance. This may lead to an anterior shift of the reamer and can violate the anterior wall. Careful retractor placement and use of intraoperative fluoroscopy can minimize the risk associated with reaming.

Fractures might occur during femoral preparation, while manipulating on a specialized table [20]. Aggressive extension and external rotation of the femur using the table can result in a fracture of the tip of the greater trochanter secondary to tension of the conjoined tendon. Calcar fractures are the results of medial force on the calcar during broaching and can be fixed with cerclages (**Figure 14**). A rare complication, which might only occur when using a specialized

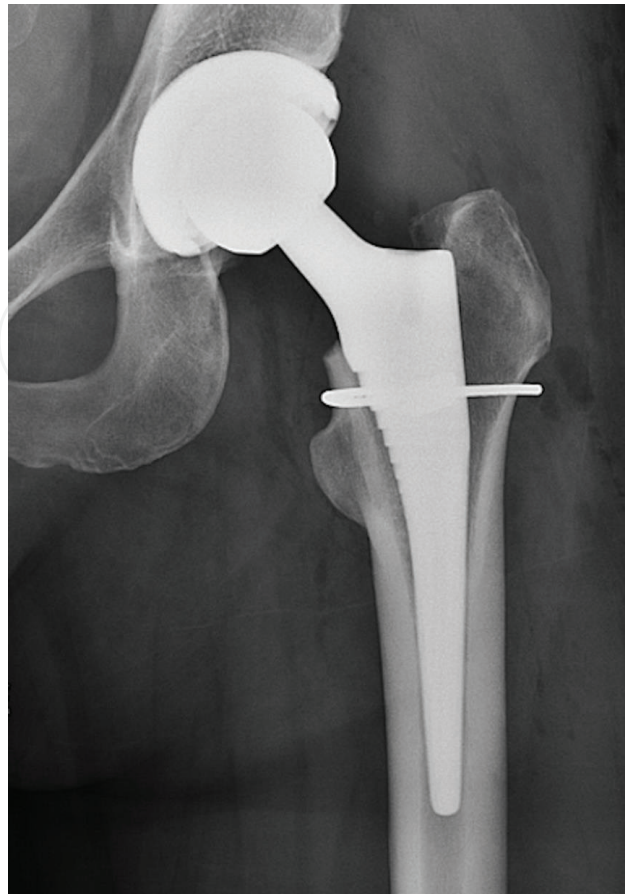


Figure 14. Intraoperative complication: calcar fracture fixed with two cerclages.

table, is a fracture of the ankle while performing external rotation in order to dislocate the operated hip. This is why close monitoring of the torque applied to the fixed leg is necessary.

In general, straight access to the femoral canal is limited in an anterior approach. The correct implant design and broaching instruments are essential and avoid malpositioning or fractures [46]. Perforation of the femur can occur when the direction of the femoral canal is not respected. The risk of postoperative complications in the hand of an experienced surgeon performing an anterior approach is comparable to other approaches.

The dislocation rate for the anterior THA is lower compared to the anterolateral and posterior approach [47]. Preserving the piriformis tendon, obturator externus tendon, and posterior capsule increases the stability when using the anterior approach. Therefore, the routine use of hip precautions for the anterior approach is not recommended [32].

The risk of postoperative hematoma can be minimized by routine exposure and proper ligation of the ascending branches of the lateral femoral circumflex vessels. The vessels are variable in number, location, and extend, but are usually found underneath the deep fascial layer of the tensor fasciae latae. At the end of the procedure, care should be taken for hemostasis. The risk of postoperative drainage can be reduced by meticulous capsular and tensor fasciae closure. Kasparek et al. describes the topical use of tranexamic acid (TXA) to reduce transfusion rates

and increase postoperative Hb-levels [48]. For all patients undergoing anterior THA, intravenous TXA should be used as part of blood management. The location of the wound in the groin close to a natural skin fold can result in wound dehiscence and infections in patients with a larger soft tissue pannus overlaying the incision.

8. Conclusion

The popularity of the anterior approach has increased in the last decade. Its soft tissue sparing nature results in a faster recovery and a more stable hip joint. Postoperative precautions are not routinely applied. The use of intraoperative fluoroscopy has improved cup positioning and restoration of the leg length and offset.

Contribution statement

I attest to the fact that all authors have participated in the research, read the manuscript, attest to the validity and legitimacy of the data and its interpretation, and agree to its submission.

Conflict of interest

Dr. Boettner reports personal fees and royalties from Smith & Nephew, personal fees and royalties from Ortho Development Corporation and personal fees from DePuy, outside the submitted work.

We certify that we have not signed any agreement with commercial interest related to this book chapter, which would in any way limit publication for any reason.

Author details

Ulrich Bechler, Bernhard Springer and Friedrich Boettner*

*Address all correspondence to: boettnerf@hss.edu

Adult Reconstruction and Joint Replacement Division, Hospital for Special Surgery,
New York, NY, USA

References

- [1] Berry DJ, Berger RA, Callaghan JJ, Dorr LD, Duwelius PJ, Hartzband MA, et al. Minimally invasive total hip arthroplasty. Development, early results, and a critical analysis. Presented at the Annual Meeting of the American Orthopaedic Association,

- Charleston, South Carolina, USA, June 14, 2003. *The Journal of Bone and Joint Surgery. American Volume*. 2003;**85-a**(11):2235-2246
- [2] Woolson ST, Rahimtoola ZO. Risk factors for dislocation during the first 3 months after primary total hip replacement. *The Journal of Arthroplasty*. 1999;**14**(6):662-668
 - [3] L'Hommedieu CE, Gera JJ, Rupp G, Salin JW, Cox JS, Duwelius PJ. Impact of anterior vs posterior approach for total hip arthroplasty on post-acute care service utilization. *The Journal of Arthroplasty*. 2016;**31**(9 Suppl):73-77
 - [4] Kwon MS, Kuskowski M, Mulhall KJ, Macaulay W, Brown TE, Saleh KJ. Does surgical approach affect total hip arthroplasty dislocation rates? *Clinical Orthopaedics and Related Research*. 2006;**447**:34-38
 - [5] Lewinnek GE, Lewis JL, Tarr R, Compere CL, Zimmerman JR. Dislocations after total hip-replacement arthroplasties. *The Journal of Bone and Joint Surgery. American Volume*. 1978;**60**(2):217-220
 - [6] Boettner F, Zingg M, Emara AK, Waldstein W, Faschingbauer M, Kasparek MF. The accuracy of acetabular component position using a novel method to determine anteversion. *The Journal of Arthroplasty*. 2016;**32**(4):1180-1185
 - [7] Lin TJ, Bendich I, Ha AS, Keeney BJ, Moschetti WE, Tomek IM. A comparison of radiographic outcomes after total hip arthroplasty between the posterior approach and direct anterior approach with intraoperative fluoroscopy. *The Journal of Arthroplasty*. 2016
 - [8] Little NJ, Busch CA, Gallagher JA, Rorabeck CH, Bourne RB. Acetabular polyethylene wear and acetabular inclination and femoral offset. *Clinical Orthopaedics and Related Research*. 2009;**467**(11):2895-2900
 - [9] Malik A, Maheshwari A, Dorr LD. Impingement with total hip replacement. *The Journal of Bone and Joint Surgery. American Volume*. 2007;**89**(8):1832-1842
 - [10] Rathod PA, Bhalla S, Deshmukh AJ, Rodriguez JA. Does fluoroscopy with anterior hip arthroplasty decrease acetabular cup variability compared with a nonguided posterior approach? *Clinical Orthopaedics and Related Research*. 2014;**472**(6):1877-1885
 - [11] Hardinge K. The direct lateral approach to the hip. *The Journal of Bone and Joint Surgery. British Volume*. 1982;**64**(1):17-19
 - [12] Nakai T, Liu N, Fudo K, Mohri T, Kakiuchi M. Early complications of primary total hip arthroplasty in the supine position with a modified Watson-Jones anterolateral approach. *Journal of Orthopaedics*. 2014;**11**(4):166-169
 - [13] Hendel D, Yasin M, Garti A, Weisbort M, Beloosesky Y. Fracture of the greater trochanter during hip replacement: A retrospective analysis of 21/372 cases. *Acta Orthopaedica Scandinavica*. 2002;**73**(3):295-297
 - [14] Amlie E, Havelin LI, Furnes O, Baste V, Nordsletten L, Hovik O, et al. Worse patient-reported outcome after lateral approach than after anterior and posterolateral approach

- in primary hip arthroplasty. A cross-sectional questionnaire study of 1,476 patients 1-3 years after surgery. *Acta Orthopaedica*. 2014;**85**(5):463-469
- [15] Sueyoshi T, Meding JB, Davis KE, Lackey WG, Malinzak RA, Ritter MA. Clinical predictors for possible failure after total hip arthroplasty. *Hip International: The Journal of Clinical and Experimental Research on Hip Pathology and Therapy*. 2016;**26**(6):531-536
- [16] Smith-Petersen MN. Approach to and exposure of the hip joint for mold arthroplasty. *The Journal of Bone and Joint Surgery. American Volume*. 1949;**31a**(1):40-46
- [17] Wagner H. Surface replacement arthroplasty of the hip. *Clinical Orthopaedics and Related Research*. 1978;**134**:102-130
- [18] Berger RA. Total hip arthroplasty using the minimally invasive two-incision approach. *Clinical Orthopaedics and Related Research*. 2003;**417**:232-241
- [19] Desser DR, Mitrick MF, Ulrich SD, Delanois RE, Mont MA. Total hip arthroplasty: Comparison of two-incision and standard techniques at an AOA-accredited community hospital. *The Journal of the American Osteopathic Association*. 2010;**110**(1):12-15
- [20] Matta JM, Shahrदार C, Ferguson T. Single-incision anterior approach for total hip arthroplasty on an orthopaedic table. *Clinical Orthopaedics and Related Research*. 2005;**441**:115-124
- [21] Siguier T, Siguier M, Brumpt B. Mini-incision anterior approach does not increase dislocation rate: A study of 1037 total hip replacements. *Clinical Orthopaedics and Related Research*. 2004;**426**:164-173
- [22] Unger AS, Stronach BM, Bergin PF, Nogler M. Direct anterior total hip arthroplasty. *Instructional Course Lectures*. 2014;**63**:227-238
- [23] McLaughlin JR, Lee KR. Long-term results of uncemented total hip arthroplasty with the Taperloc femoral component in patients with Dorr type C proximal femoral morphology. *The Bone & Joint Journal*. 2016;**98-b**(5):595-600
- [24] Zingg M, Boudabbous S, Hannouche D, Montet X, Boettner F. Standardized fluoroscopy-based technique to measure intraoperative cup anteversion. *Journal of Orthopaedic Research: Official Publication of the Orthopaedic Research Society*. 2017;**35**(10):2307-2312
- [25] Alecci V, Valente M, Crucil M, Minerva M, Pellegrino CM, Sabbadini DD. Comparison of primary total hip replacements performed with a direct anterior approach versus the standard lateral approach: Perioperative findings. *Journal of Orthopaedics and Traumatology: Official Journal of the Italian Society of Orthopaedics and Traumatology*. 2011;**12**(3):123-129
- [26] Miller LE, Gondusky JS, Bhattacharyya S, Kamath AF, Boettner F, Wright J. Does surgical approach affect outcomes in total hip arthroplasty through 90 days of follow-up? A systematic review with meta-analysis. *The Journal of Arthroplasty*. 2017;**33**(4):1296-1302
- [27] Mayr E, Nogler M, Benedetti MG, Kessler O, Reinthaler A, Krismer M, et al. A prospective randomized assessment of earlier functional recovery in THA patients treated

- by minimally invasive direct anterior approach: A gait analysis study. *Clinical Biomechanics*. 2009;**24**(10):812-818
- [28] Nakata K, Nishikawa M, Yamamoto K, Hirota S, Yoshikawa H. A clinical comparative study of the direct anterior with mini-posterior approach: Two consecutive series. *The Journal of Arthroplasty*. 2009;**24**(5):698-704
- [29] Rodriguez JA, Deshmukh AJ, Rathod PA, Greiz ML, Deshmane PP, Hepinstall MS, et al. Does the direct anterior approach in THA offer faster rehabilitation and comparable safety to the posterior approach? *Clinical Orthopaedics and Related Research*. 2014;**472**(2):455-463
- [30] Prietzel T, Hammer N, Schleifenbaum S, Adler D, Pretzsch M, Kohler L, et al. The impact of capsular repair on the dislocation rate after primary total hip arthroplasty: A retrospective analysis of 1972 cases. *Zeitschrift für Orthopädie und Unfallchirurgie*. 2014;**152**(2):130-143
- [31] Schmidt-Braekling T, Waldstein W, Akalin E, Benavente P, Frykberg B, Boettner F. Minimal invasive posterior total hip arthroplasty: Are 6 weeks of hip precautions really necessary? *Archives of Orthopaedic and Trauma Surgery*. 2015;**135**(2):271-274
- [32] Restrepo C, Mortazavi SM, Brothers J, Parvizi J, Rothman RH. Hip dislocation: Are hip precautions necessary in anterior approaches? *Clinical Orthopaedics and Related Research*. 2011;**469**(2):417-422
- [33] Maratt JD, Gagnier JJ, Butler PD, Hallstrom BR, Urquhart AG, Roberts KC. No difference in dislocation seen in anterior vs posterior approach total hip arthroplasty. *The Journal of Arthroplasty*. 2016;**31**(9 Suppl):127-130
- [34] Tamaki T, Oinuma K, Miura Y, Higashi H, Kaneyama R, Shiratsuchi H. Epidemiology of dislocation following direct anterior total hip arthroplasty: A minimum 5-year follow-up study. *The Journal of Arthroplasty*. 2016;**31**(12):2886-2888
- [35] de Steiger RN, Lorimer M, Solomon M. What is the learning curve for the anterior approach for total hip arthroplasty? *Clinical Orthopaedics and Related Research*. 2015;**473**(12):3860-3866
- [36] Goytia RN, Jones LC, Hungerford MW. Learning curve for the anterior approach total hip arthroplasty. *Journal of Surgical Orthopaedic Advances*. 2012;**21**(2):78-83
- [37] Seng BE, Berend KR, Ajluni AF, Lombardi AV Jr. Anterior-supine minimally invasive total hip arthroplasty: Defining the learning curve. *The Orthopedic Clinics of North America*. 2009;**40**(3):343-350
- [38] Masonis J, Thompson C, Odum S. Safe and accurate: Learning the direct anterior total hip arthroplasty. *Orthopedics*. 2008;**31**(12 Suppl 2):129-143
- [39] Rudin D, Manestar M, Ullrich O, Erhardt J, Grob K. The anatomical course of the lateral femoral cutaneous nerve with special attention to the anterior approach to the hip joint. *The Journal of Bone and Joint Surgery. American Volume*. 2016;**98**(7):561-567

- [40] Homma Y, Baba T, Kobayashi H, Desroches A, Ozaki Y, Ochi H, et al. Safety in early experience with a direct anterior approach using fluoroscopic guidance with manual leg control for primary total hip arthroplasty: A consecutive one hundred and twenty case series. *International Orthopaedics*. 2016;**40**(12):2487-2494
- [41] Lovell TP. Single-incision direct anterior approach for total hip arthroplasty using a standard operating table. *The Journal of Arthroplasty*. 2008;**23**(7 Suppl):64-68
- [42] Restrepo C, Parvizi J, Pour AE, Hozack WJ. Prospective randomized study of two surgical approaches for total hip arthroplasty. *The Journal of Arthroplasty*. 2010;**25**(5):671.e1-679.e1
- [43] Bhargava T, Goytia RN, Jones LC, Hungerford MW. Lateral femoral cutaneous nerve impairment after direct anterior approach for total hip arthroplasty. *Orthopedics*. 2010;**33**(7):472
- [44] Goulding K, Beaulé PE, Kim PR, Fazekas A. Incidence of lateral femoral cutaneous nerve neuropraxia after anterior approach hip arthroplasty. *Clinical Orthopaedics and Related Research*. 2010;**468**(9):2397-2404
- [45] Agten CA, Sutter R, Dora C, Pfirrmann CW. MR imaging of soft tissue alterations after total hip arthroplasty: Comparison of classic surgical approaches. *European Radiology*. 2017;**27**(3):1312-1321
- [46] Homma Y, Baba T, Ochi H, Ozaki Y, Kobayashi H, Matsumoto M, et al. Greater trochanter chip fractures in the direct anterior approach for total hip arthroplasty. *European Journal of Orthopaedic Surgery & Traumatology: Orthopedie Traumatologie*. 2016;**26**(6):605-611
- [47] Higgins BT, Barlow DR, Heagerty NE, Lin TJ. Anterior vs. posterior approach for total hip arthroplasty, a systematic review and meta-analysis. *The Journal of Arthroplasty*. 2015;**30**(3):419-434
- [48] Kasperek MF, Faschingbauer M, Waldstein W, Boettner CS, Boettner F. Topical tranexamic acid is equivalent to targeted preoperative autologous blood donation in total hip arthroplasty. *The Journal of Arthroplasty*. 2016;**32**(4):1176-1179

