

We are IntechOpen, the world's leading publisher of Open Access books Built by scientists, for scientists

4,800

Open access books available

122,000

International authors and editors

135M

Downloads

Our authors are among the

154

Countries delivered to

TOP 1%

most cited scientists

12.2%

Contributors from top 500 universities



WEB OF SCIENCE™

Selection of our books indexed in the Book Citation Index
in Web of Science™ Core Collection (BKCI)

Interested in publishing with us?
Contact book.department@intechopen.com

Numbers displayed above are based on latest data collected.
For more information visit www.intechopen.com



Regional Anesthesia for Hand Surgeries

Harsha Shanthanna and Manikandan Rajarathinam

Additional information is available at the end of the chapter

<http://dx.doi.org/10.5772/intechopen.76786>

Abstract

Anesthesia for hand surgeries is one of the domains of regional anesthesia, where it plays the role, not only as a viable alternative to GA but also as an adjunct to it. The efficacy and inherent advantages of regional anesthesia techniques are widely made use of by the hand and upper limb surgical centers across the world. There are a variety of established regional techniques ranging from major plexus blocks to local infiltration techniques and intra venous regional anesthesia for hand surgeries. The peripheral nerve blocks are recently being performed with ultrasound guidance which is undoubtedly the greatest influence till date in the practice of modern regional anesthesia. There is also a recent trend in the performance of certain minor hand surgeries (e.g., carpal tunnel release) under infiltrative techniques in office-like settings for rapid turnover. This chapter discusses concisely the selection and execution of such techniques in day-to-day practice.

Keywords: regional anesthesia, hand surgery, brachial plexus blocks

1. Introduction

Hand surgeries are amenable to regional anesthesia techniques which are often performed by the anesthesiologists. The ability to perform peripheral nerve blocks is a desirable skill to acquire by the anesthesiologists who provide anesthetics for upper limb surgeries. The advent of ultrasound guidance for these peripheral nerve and plexus blocks has revolutionized the practice of regional anesthesia in the past two decades. The enhanced accuracy and safety with ultrasound guidance offer higher success rate and reduced block latency, thereby improving the operator confidence.

2. Advantages and limitations of regional anesthesia

The practical advantages of regional anesthesia are faster postoperative recovery, better postoperative analgesia, avoidance of opioid-related side effects, and prevention of GA-related complications in patients with cardiovascular and respiratory comorbidities, e.g., sleep apnea, chronic obstructive pulmonary disease (COPD), coronary artery disease (CAD), etc. The perioperative patient satisfaction and hospital efficiency are readily perceptible with the use of these regional anesthesia techniques albeit the sparsity of data on long-term outcome following surgery. On the other hand, the availability of sophisticated equipment, specialized operator training, requirement of a dedicated block room, and protected block execution time are some of the limitations with routine practice of regional anesthetic techniques. Though the use of ultrasound as a nerve localization tool has shortened the learning curve and boosted operator comfort level with peripheral nerve blocks, it does not eliminate the procedure-related complications.

3. Techniques of regional anesthesia for hand surgeries

The understanding of the structure of the brachial plexus and the innervation of the upper extremity is paramount to choose the right approach of neural blockade to achieve successful surgical anesthesia or analgesia. Of the four major approaches to brachial plexus block, the axillary approach, infraclavicular approach, and supraclavicular approach are commonly used for anesthesia and analgesia for hand surgery, whereas the interscalene approach is mainly used for shoulder and upper arm surgery. The axillary block is popular with hand surgeries as it provides sufficient distal extremity blockade and is relatively simple to perform and devoid of serious complications. The supraclavicular and infraclavicular approaches provide better tourniquet tolerance and wider surgical anesthesia of the entire upper extremity by virtue of the proximal neural blockade. A recent systematic review concluded that the axillary, supraclavicular, and infraclavicular approaches had similar success rates when performed with ultrasound guidance and there was no difference in successful blockade irrespective of number of injections [1]. Further distal approaches like mid-humeral block and individual peripheral nerve blocks may offer sensory blockade and analgesia but may not cover the tourniquet discomfort. However, application of forearm tourniquet for hand and wrist surgeries may be more comfortable for patients receiving regional anesthesia [2, 3]. This will obviate the need for proximal brachial plexus blocks given primarily for tourniquet discomfort and will avoid disproportionately extensive and often prolonged sensory and motor blockade beyond that required for incisional analgesia.

3.1. Techniques of brachial plexus block

3.1.1. Axillary brachial plexus block

Axillary block is an excellent anesthetic option for elbow, forearm, and hand surgeries either as a sole anesthetic technique with or without sedation or as a supplement to GA. Axillary block targets the four major nerves of the upper limb (the radial nerve, ulnar nerve, median nerve, and musculocutaneous nerve) which are arranged around the axillary artery as a neurovascular bundle that is easily accessed through the axilla. The technique is relatively simpler using the axillary artery as the landmark around which the major nerves of the upper

limb can be localized using nerve stimulation or ultrasound. It is also devoid of complications like pneumothorax and hemi diaphragmatic paresis. The block performance time with axillary block is relatively longer than with the supraclavicular and infraclavicular blocks due to the higher needling time [4, 5]. Also multiple injection technique has higher success rate than single or double injection technique when a non-ultrasound-guided technique was used [6].

3.1.1.1. Technique

The patients' arm is abducted with elbow flexed and supported in this position to expose the axilla (**Figure 1a**). A high-frequency linear array transducer is used to obtain a cross-sectional view of the axillary artery just distal to the anterior axillary fold (**Figure 1b**). At this point the radial nerve is still in close proximity to the axillary artery above the conjoint tendon formed by the teres major and latissimus dorsi (**Figure 1c**). Distal to this level, the radial nerve exits posteriorly through the triangular space and is difficult to visualize (**Figure 1d** and **e**). The median nerve is often lateral or superior to the axillary artery, and the ulnar nerve lies medial or posterior to the artery. The musculocutaneous nerve usually exits brachial plexus earlier and is found lateral to the artery between the heads of coracobrachialis muscle or between biceps and coracobrachialis. Variations in the relations of these nerves can be very commonly seen, but the nerves can be identified by tracing their course distally [7].

After obtaining the image as shown in **Figure 1c**, the block needle can be inserted in plane with or without the nerve stimulation. The musculocutaneous nerve can be blocked first as it is located lateral to the artery and often encountered first while entering in plane. The nerves need to be surrounded by local anesthetic for the block to take effect satisfactorily. The radial, medial, and ulnar nerves can be subsequently blocked by redirecting the needle. The block can be performed with one needle entry occasionally requiring a second pass to target one of the nerves.

3.1.2. Infraclavicular block

Infraclavicular block is a brachial plexus block performed at the levels of the three cords of the brachial plexus which are arranged around the subclavian artery. The cords are named lateral, medial, and posterior cords based on their fairly consistent relation to the axillary artery (**Figure 2e**) [8]. With the exception of a few nerves that depart the brachial plexus at the level of roots and trunks, the cords comprise of most of the sensory and motor innervation of the upper extremity. Hence, this block is an excellent anesthetic technique for surgeries of the distal arm, forearm, elbow, and hand. This block is relatively easier to perform with the ultrasound as the neurovascular bundle is deeper making it difficult to perform with nerve stimulation technique. Though the risk of hemi diaphragmatic paralysis is very rare, the risk of pneumothorax is still present if the needle is directed blindly medially toward the pleura.

3.1.2.1. The technique

For this block the patients' arm needs not be abducted, but abduction may help with visualization of the neurovascular bundle by stretching the overlying muscles and also potentially displacing the neurovascular bundle away from the chest wall. Though a high-frequency linear array transducer often should suffice for this block, in obese or muscular patients, a low frequency curvilinear transducer may be required. The probe is placed in a parasagittal plane

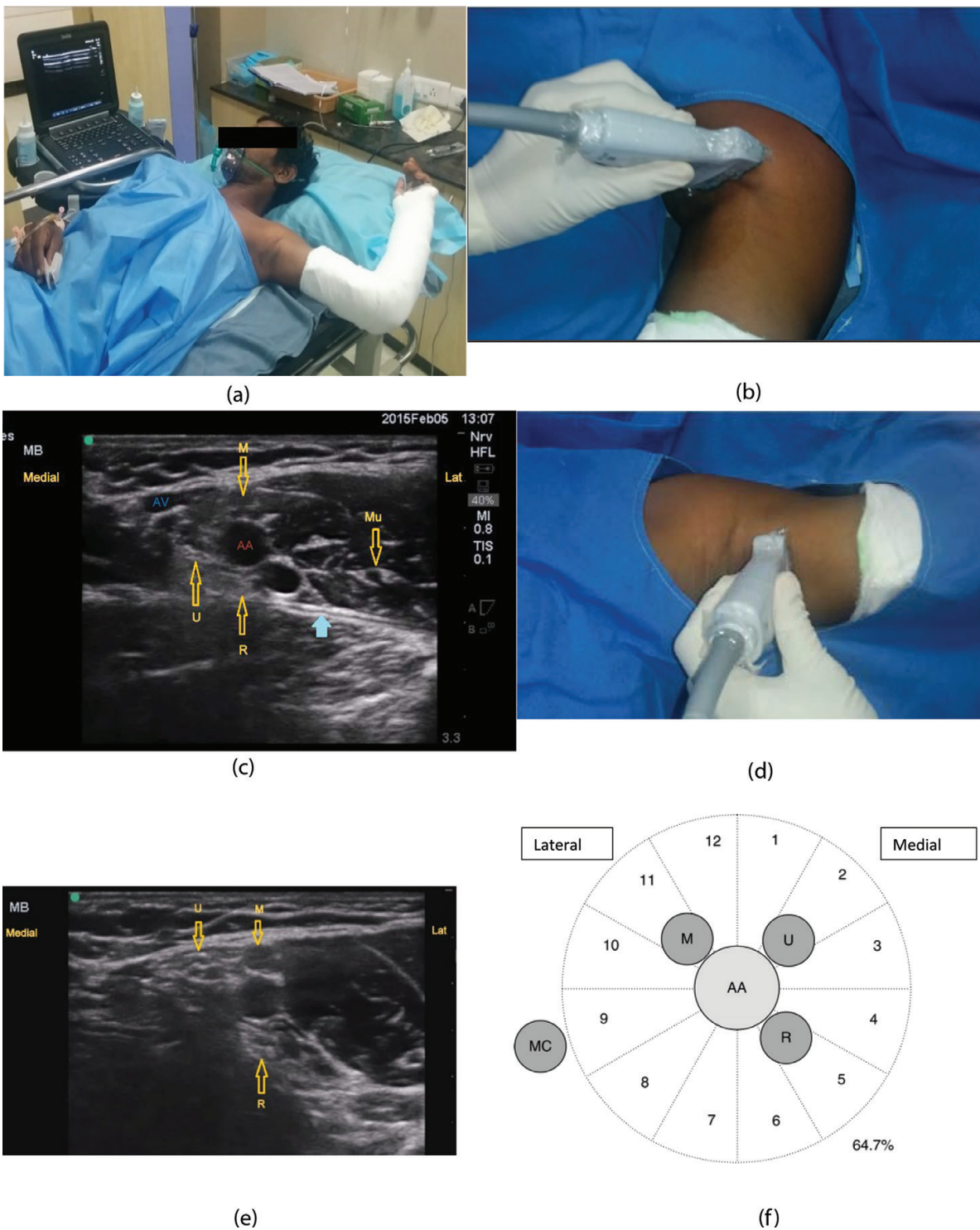


Figure 1. (a) Position of the upper limb with abduction of shoulder and elbow flexed to expose the axilla. (b, c) Linear probe placement close to the anterior axillary fold and the image obtained with the probe placed transversely across the neurovascular bundle higher up in the axilla where the conjoint tendon (solid arrow) is seen. The radial nerve is usually contained between the conjoint tendon and the axillary artery. Distal to this level, the radial nerve departs posteriorly and is difficult to visualize. AA, axillary artery; AV, axillary vein. (d, e) The image obtained with the probe transversely across the neurovascular bundle below the level of the conjoint tendon. The axillary vessels become brachial vessels below the level of the teres major. Note the ulnar, median, and radial nerves marked in the pictures with arrows. The radial nerve accompanies the profunda brachii artery and exits to the posterior compartment of the arm. BV, brachial vein; BA, brachial artery; M, median nerve; U, ulnar nerve; R, radial nerve. (f) The most common arrangement of the major four nerves around the axillary artery. Frequency of this pattern is 64.7%. Adapted from [7].

(**Figure 2a**) just medial to the deltopectoral groove to visualize the axillary artery in cross section and the circumferentially placed cords which are seen as hyperechoic structures (**Figure 2b**). After obtaining an optimal image, an 8 to 10 cm block needle is inserted in an inplane technique (**Figure 2c** and **d**) in a cephalocaudal direction aiming to place the needle tip posterior to the artery close to the posterior cord. A volume of 30 ml of local anesthetic can be injected to create a U-shaped local anesthetic spread around the axillary artery.

3.1.3. *Supraclavicular block*

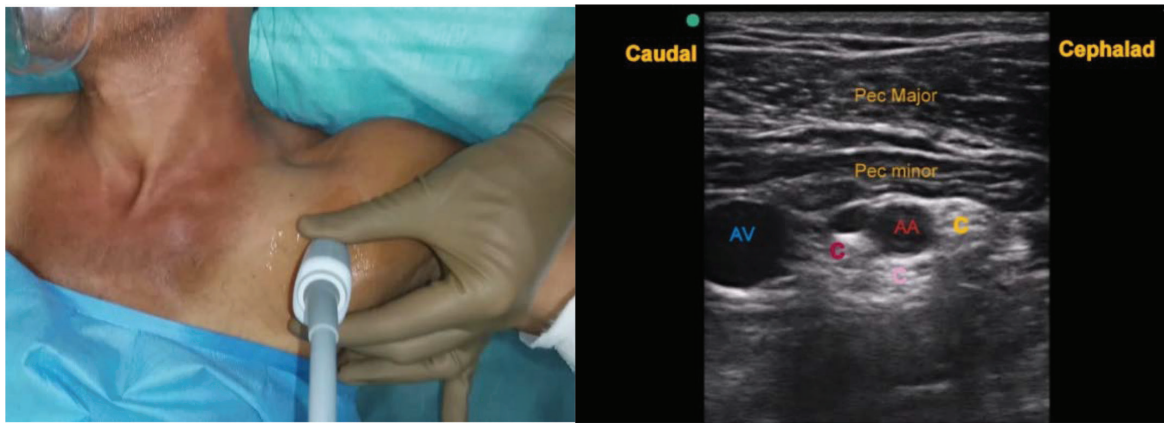
Supraclavicular block is a brachial plexus block performed at the midpoint of the clavicle posterolateral to the subclavian artery where the distal trunks and proximal divisions of the brachial plexus are compactly arranged abutting the artery (**Figure 3a** and **b**). Due to this compact arrangement of neural tissue, the local anesthetic block latency is short and leads to anesthesia of the entire arm below the shoulder rapidly. This is an ideal technique for a sole regional anesthetic techniques for most surgical procedures of the entire upper extremity below the level of the shoulder. Due to the proximity of the pleura, there is a risk of pneumothorax with this block especially when performed with blind techniques. Recently, ultrasound guidance has shown to reduce the incidence of this complication due to real-time visualization of the structures while performing the block. There is also the possibility of ipsilateral phrenic nerve block with this block which might be symptomatic in some patients.

3.2. Individual nerve blocks

Radial nerve can be visualized easily in the distal arm in the anterolateral part just above the elbow (**Figure 4a** and **b**). It emerges from the spiral groove of the humerus and appears anteriorly between the brachioradialis and brachialis muscles. The nerve can be blocked here with 3 to 5 ml of local anesthetic to block its terminal branches of which the anterior branch supplies cutaneous innervation to the dorsal skin of the hand and lateral three digits. The median nerve accompanies the brachial artery throughout the arm, lending itself to easy identification with ultrasound scanning distally from the axilla. The median nerve can be blocked in the upper forearm where it lies between the flexor digitorum superficialis and flexor digitorum profundus in the center of the forearm (**Figure 5a** and **b**). The median nerve provides cutaneous innervation to ventral aspect of the lateral hand and fingers excluding the medial half of the ring finger and the entire little finger. The ulnar nerve can be visualized with ultrasound from the distal part of the forearm lying medial to the ulnar artery. It can be traced proximally and can be blocked at the upper forearm where it moves away from the artery, thereby avoiding injury to the vessel (**Figure 6a** and **b**). Prior to the use of ultrasound guidance, a landmark-guided technique at the olecranon fossa was described. However, the potential of nerve injury is high in this location due to proximity to bone and being enclosed in a fibro-osseous tunnel. The ulnar nerve innervates the skin of the hypothenar eminence and the ventral aspect of the medial one and half fingers.

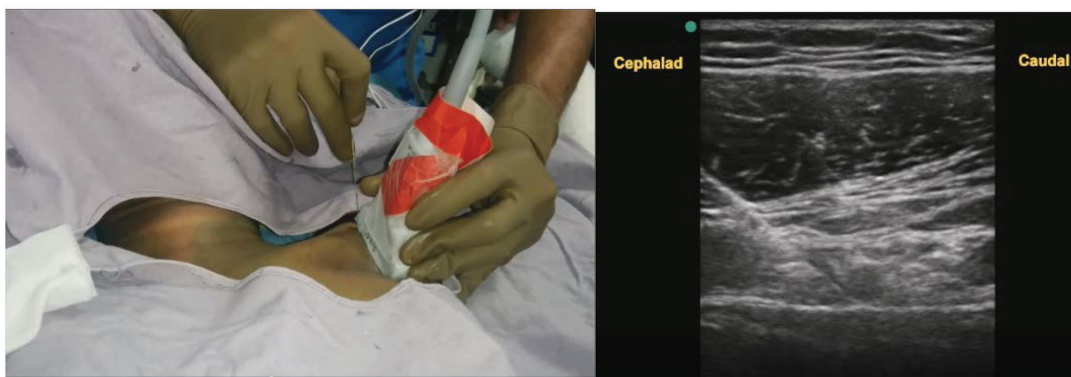
3.3. Alternate techniques

Intravenous regional anesthesia or Bier block is an alternate technique ideal for short surgeries in the hand and forearm. A regional block is achieved by injecting the local anesthetic



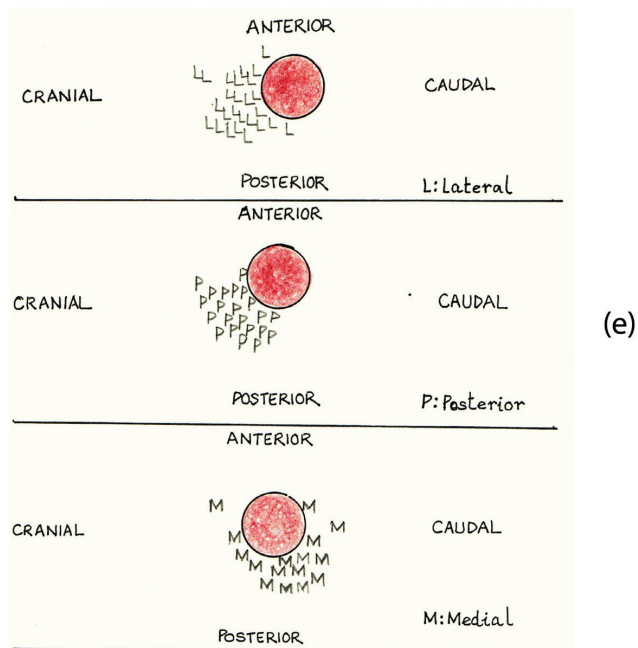
(a)

(b)



(c)

(d)



(e)

Figure 2. (a, b) Probe placement for infraclavicular block in the parasagittal plane in the deltopectoral groove. The axillary vessels are seen in cross section with the cords circumferentially arranged around the axillary artery. AV, axillary vein; AA, axillary artery; C, cords. (c, d) Needle inserted in plane in a cephalocaudal direction with the needle tip placed cephalo-posterior to the axillary artery. (e) The common arrangement of the cords around the axillary artery, adapted from [8].

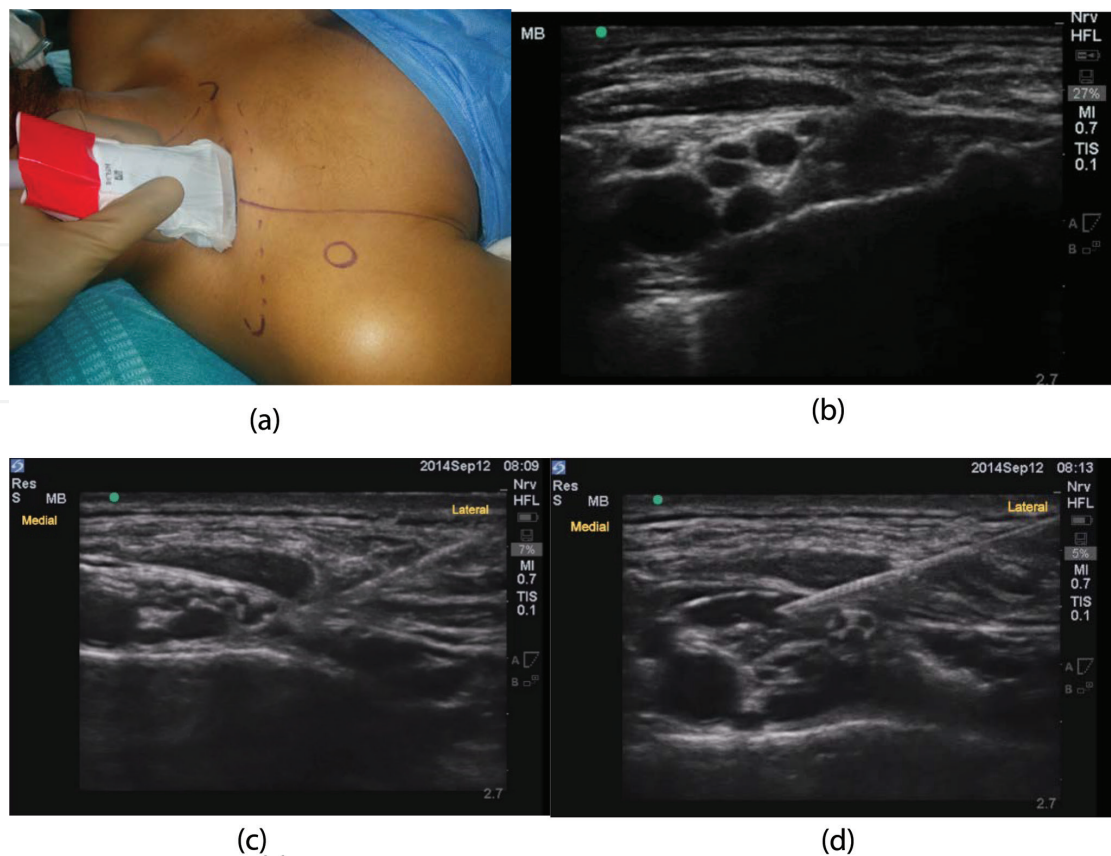


Figure 3. (a, b) Probe position for supraclavicular block and the resulting image showing the compact arrangement of divisions of the brachial plexus block abutting the subclavian artery and overlying the first rib. Note the pleura lying underneath the subclavian artery. (c, d) Performance of the supraclavicular block. The block needle is inserted inplane and directed between the first rib and the lower part of the plexus. The local anesthetic is also injected from above the plexus after redirecting the needle.

through the veins in the vicinity of the incisional site after application of an arm tourniquet and containing the local anesthetic distal to the tourniquet. The block is technically easy to perform, and the onset of the block is rapidly occurring within a few minutes.

3.3.1. Technique of IVRA

An additional temporary IV access is secured in the limb to be operated usually in the hand or wrist. Following this, exsanguination of the veins is done by elevating the arm and application of Esmarch bandage. After thoroughly exsanguinating the limb, a double-cuffed tourniquet with a proximal and distal cuff is wrapped around the arm. The distal tourniquet is first inflated followed by inflation of the proximal cuff. The distal cuff is then deflated leaving the proximal cuff inflated followed by slow local anesthetic injection in to the IV cannula. The block takes effect in a few minutes and usually lasts for an hour. If the patient complains of tourniquet discomfort, the distal cuff is inflated, and the proximal cuff is subsequently deflated. The tourniquet needs to remain inflated for at least 30 minutes till the local anesthetic fixes to the tissues even if the procedure is completed before this time. Due to the risk of systemic local anesthetic toxicity, lidocaine is the agent of choice due to its relatively low cardiac toxicity. Application of

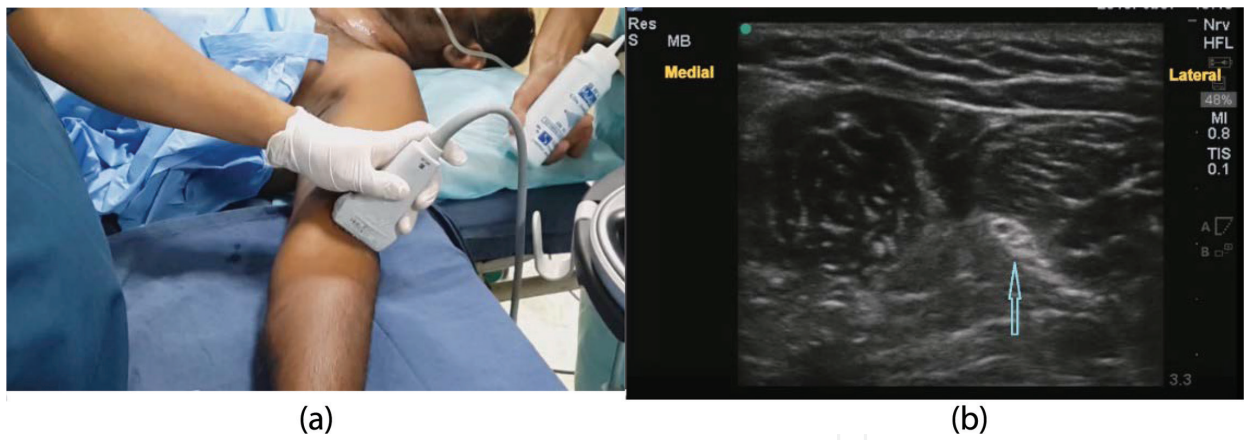

Figure 4. (a, b) Probe placement for visualization of radial nerve in the anterolateral surface of arm. The radial nerve is seen under the brachioradialis muscle.

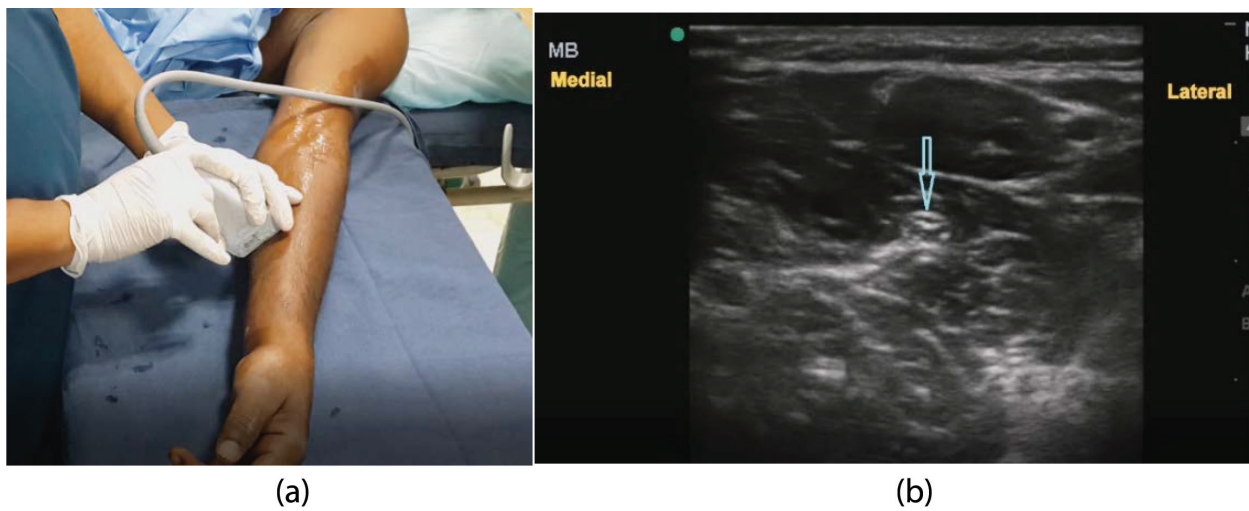


Figure 5. (a, b) Probe placement for visualization of the median nerve in the center of the anterior aspect of forearm. The median nerve is seen between the flexor digitorum superficialis and flexor digitorum profundus.

forearm tourniquet for hand or finger surgeries may be more comfortable for the patients and also can potentially reduce the amount of local anesthetic intravenously in IVRA [9].

3.3.2. Local infiltration techniques

As an alternate to the regional anesthetic techniques performed by anesthesiologists, some of the procedures can be performed by local anesthetic infiltration, wrist or digital nerve blocks by the operating surgeons.

4. Recent trends in hand surgeries

There is a recently increasing trend to perform some of the hand surgeries like carpal tunnel release, Dupuytren's release, trigger finger release, tendon repair, etc., to be performed under local anesthesia with no sedation/anesthesia and no tourniquet [10]. This improves hospital efficiency and

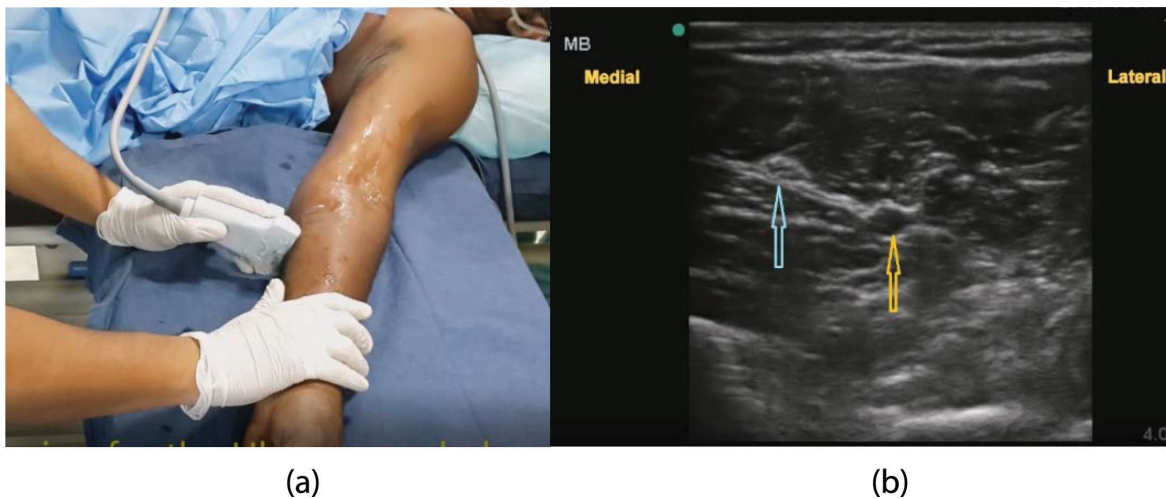


Figure 6. (a, b) Probe placement for visualization of the ulnar nerve in the upper medial surface of the forearm. The ulnar nerve will be seen accompanied by the ulnar artery laterally distal to the mid-forearm. The block is ideally performed when both structures are away from each other in the upper aspect of the forearm. The hyperechoic structure medially is the ulnar nerve, and the hypoechoic structure laterally is the ulnar artery which is approaching the nerve when traced distally.

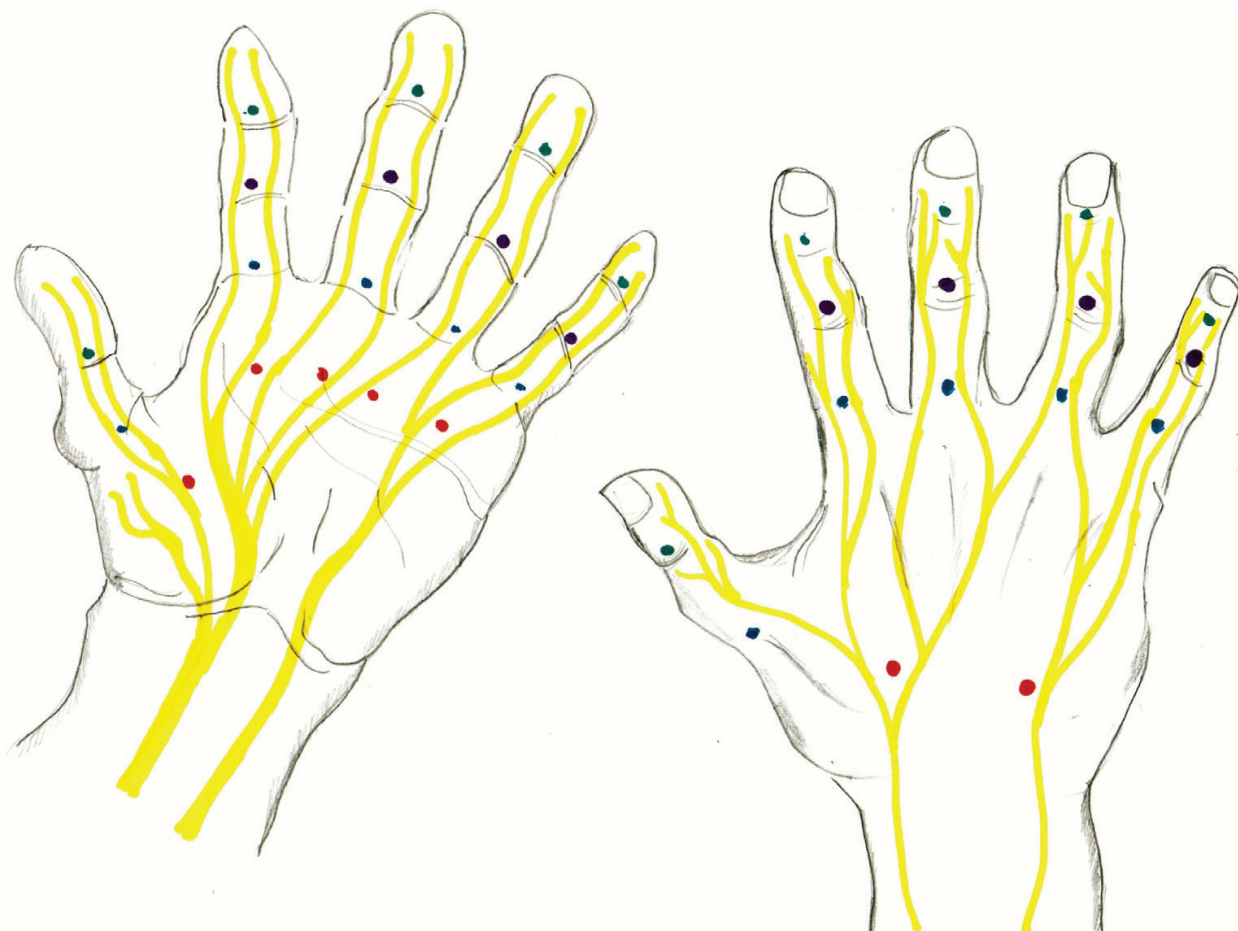


Figure 7. Illustration of volar and dorsal sites of injection of local anesthesia for finger and hand surgery. For only a sensory block of the finger, 2 ml is injected into the BLUE dot (third dot from the top) and is called the SIMPLE (single subcutaneous injection in the middle of the proximal phalanx with lidocaine and epinephrine) block. For local anesthesia and hemostasis of palmar finger surgery, 1% lidocaine with epinephrine 1: 100,000 is injected into the midline subcutaneous fat between the digital nerves at each area designated by a dot. From distal to proximal, the volume injected is 1 ml (first dot from the top), 2 ml (middle dots), and 5 ml at the red dots. Adapted from [11].

cost of surgery, reduces preoperative preparation/consultations, and helps fast tracking of these surgeries by performing in minor operating rooms. This also benefits certain procedures like tenolysis and tendon repairs allowing for monitoring of the finger range of movement intraoperatively. The technique typically involves subcutaneous injection of 1% lidocaine with 1:100000 epinephrine on the palmar and dorsal aspects of the finger (**Figure 7**) [11]. This type of wide-awake hand and wrist surgery is now popularly called (wide-awake local anesthesia and no tourniquet (WALANT) surgery [12]. The previous concerns of injecting epinephrine for hemostasis during hand and finger surgery for the fear of ischemic injury have been refuted recently by many investigators.

5. Conclusion

A multitude of approaches of local anesthetic blockade throughout the structure of brachial plexus and its branches are currently practiced to provide regional anesthesia and analgesia of distal upper extremity. The use of ultrasonography has not only revolutionized the conventional regional anesthesia techniques but also improved the access to the peripheral nerves at distal levels in the course of these neural structures. The major brachial plexus approaches like supraclavicular, infraclavicular, and axillary blocks have been shown to have equal success rates. Hence, the choice of the technique may be decided based on the experience of the practitioner, extent of the surgery, tourniquet use in the arm or forearm, and consideration of avoiding risks like pneumothorax, phrenic block, etc. For distal surgeries of short surgical duration, the IVRA and digital infiltration techniques can also be attractive options. Eliminating the tourniquet along with awake infiltration techniques can help fast track certain minor soft tissue procedures in nonoperating room settings.

Acknowledgements

Our sincere thanks go to Ganga Medical Centre and Hospitals, India from where the acquisition of clinical pictures was done during the time of one of the author's clinical work in that institution.

Conflict of interest

None.

Author details

Harsha Shanthanna^{1*} and Manikandan Rajarathinam²

*Address all correspondence to: harshamd@gmail.com

1 McMaster University, Hamilton, Ontario, Canada

2 Western University, London, Ontario, Canada

References

- [1] Albrecht E, Mermoud J, Fournier N, Kern C, Kirkham KR. A systematic review of ultrasound-guided methods for brachial plexus blockade. *Anaesthesia*. 2016;**71**:213-227. DOI: 10.1111/anae.13347
- [2] Ng ES, Ting JRS, Foo SL, Akram SA, Fadzlina AA, Alywiah JS, et al. The comparison of discomfort level between upper arm and forearm tourniquet. *The Medical Journal of Malaysia*. 2006;**61**:23-26
- [3] Harris PC, Scott S, Evans RA. A prospective, randomized, controlled trial of forearm versus upper arm tourniquet tolerance. *Journal of Hand Surgery*. 2002;**27**(B):359-360. DOI: 10.1054/jhsb.2002.0787
- [4] Tran DQH, Russo G, Muñoz L, Zaouter C, Finlayson RJ. A prospective, randomized comparison between ultrasound-guided supraclavicular, infraclavicular, and axillary brachial plexus blocks. *Regional Anesthesia and Pain Medicine*. 2009;**34**:366-371. DOI: 10.1097/AAP.0b013e3181ac7d18
- [5] Song IA, Gil NS, young CE, Sim SE, Min SW, Ro YJ, et al. Axillary approach versus the infraclavicular approach in ultrasound-guided brachial plexus block: Comparison of anesthetic time. *Korean Journal of Anesthesiology*. 2011;**61**:12-18. DOI: 10.4097/kjae.2011.61.1.12
- [6] Chin KJ, Cubillos JE, Alakkad H. Single, double or multiple-injection techniques for non-ultrasound guided axillary brachial plexus block in adults undergoing surgery of the lower arm. *Cochrane Database of Systematic Reviews*. 2016;(9). Artical No: CD003842. DOI: 10.1002/14651858.CD003842.pub5
- [7] Christophe JL, Berthier F, Boillot A, Tatu L, Viennet A, Boichut N, et al. Assessment of topographic brachial plexus nerves variations at the axilla using ultrasonography. *British Journal of Anaesthesia*. 2009;**103**:606-612. DOI: 10.1093/bja/aep207
- [8] Sauter AR, Smith HJ, Stubhaug A, Dodgson MS, Klaastad Ø. Use of magnetic resonance imaging to define the anatomical location closest to all three cords of the infraclavicular brachial plexus. *Anesthesia and Analgesia*. 2006;**103**(6):1574. DOI: 10.1213/01.ane.0000242529.96675.fd
- [9] Chiao FB, Chen J, Lesser JB, Resta-Flarer F, Bennett H. Single-cuff forearm tourniquet in intravenous regional anaesthesia results in less pain and fewer sedation requirements than upper arm tourniquet. *British Journal of Anaesthesia*. 2013;**111**:271-275. DOI: 10.1093/bja/aet032
- [10] Lalonde D, Eaton C, Amadio PC, Jupiter JB. Wide-awake hand and wrist surgery: A new horizon in outpatient surgery. *Instructional Course Lectures*. 2015;**64**:249-259
- [11] Lalonde D, Martin A. Epinephrine in local anesthesia in finger and hand surgery: The case for wide-awake anesthesia. *The Journal of the American Academy of Orthopaedic Surgeons*. 2013;**21**:443-447. DOI: 10.5435/JAAOS-21-08-443
- [12] Lalonde D. Wide awake local anaesthesia no tourniquet technique (WALANT). *BMC Proceedings*. 2015;**9**:A81. DOI: 10.1186/1753-6561-9-S3-A81

