

# We are IntechOpen, the world's leading publisher of Open Access books Built by scientists, for scientists

4,800

Open access books available

122,000

International authors and editors

135M

Downloads

Our authors are among the

154

Countries delivered to

TOP 1%

most cited scientists

12.2%

Contributors from top 500 universities



WEB OF SCIENCE™

Selection of our books indexed in the Book Citation Index  
in Web of Science™ Core Collection (BKCI)

Interested in publishing with us?  
Contact [book.department@intechopen.com](mailto:book.department@intechopen.com)

Numbers displayed above are based on latest data collected.  
For more information visit [www.intechopen.com](http://www.intechopen.com)



---

## Breijo Electrocardiographic Pattern

---

Francisco R. Breijo-Márquez

Additional information is available at the end of the chapter

<http://dx.doi.org/10.5772/intechopen.75446>

---

### Abstract

Breijo's electrocardiographic model is becoming better known to cardiologists every day. The decrease in the PR interval, together with the decrease of the QTc interval in the same ECG tracing, is the main and only cardiac electrical feature on the same individual. It can often go unnoticed, but many problems could be avoided if it was previously diagnosed, including sudden death.

**Keywords:** cardiac arrhythmias, Breijo pattern, sudden cardiac death, palpitations, tachycardia

---

### 1. Introduction

The decrease of the cardiac electrical systole—short PR and QTc intervals in the same electrocardiogram, also known as “Breijo electrocardiographic pattern”—is increasingly studied by several authors. The vast majority of the time it can be overlooked in an electrocardiogram tracing. More than 127 cases have been studied and cross-checked. Its diagnosis is essential in avoidance of the most heartbreaking consequence, that is, avoidable death. Despite the fact that for many authors, the cardiac electrical systole comprises only from the beginning of the Q wave to the end of the T wave, that is, depolarization and repolarization of the ventricles—the atria are also part of it. Therefore, the P wave, as well as the PR segment, must be a part of the electrical cardiac systole. When there is a shortening of the PR interval along with a shortening of the QT interval, we should talk about the *Decrease of cardiac electrical systole*. This peculiar electrocardiographic pattern is denominating the **Breijo pattern**: “A PR interval less than 0.120 s along with a QTc interval less than 0.360 s.” It is typical in this type of patients, carriers of the **Breijo pattern**, to have some common peculiarities in all of them. 1. Unspecific

symptoms that are considered mild, such as: Palpitations, usually nocturnal, which awaken the patient from the natural sleep. Profuse nocturnal sweating. Light-headedness feelings misinterpreted. 2. A feeling of chest pain very unspecified, not irradiated and whose electrocardiographic study is regarded, in the vast majority of cases, as nonspecific and atypical, since coronary alterations are not observed. 3. A personal background, in childhood, of seizures treated with antiepileptic drugs without the presence of an epileptic focus on the electroencephalogram. 4. Low levels of lythemia. 5. A preference for young age (up to 40) and male sex.

In 2008, Breijo-Marquez et al. [1–3] presented an electrocardiographic pattern, in which both the PR and QT intervals were shorter in milliseconds than what is regarded as acceptable limits.

They called this phenomenon as *Decrease of electrical cardiac systole* [1], since both, depolarization and repolarization, atrial and ventricular, are lower in their standard lengths (PR interval and QT interval).

It is well known that, in an electrocardiogram, there are different waves, intervals, and segments.

They are as follows:

- A. **Waves:** P, Q, R, S, T.
- B. **Intervals:** PR (for other PQ authors). QRS. QT.
- C. **Segments:** ST fundamentally.

In spite of the repeated repetition of the image, we put it below to gain a better understanding:

## 2. Normal electrocardiogram tracing

### 2.1. Waves: intervals and segments

The **P-wave** reflects atrial depolarization (contraction).

The **PR-interval** corresponds to the delay between the end of atrial depolarization (contraction) and the beginning of ventricular depolarization (contraction); its length must be between 0.120 s and 0.200 s.

The **Q wave** is a negative deflection in the ECG resulting at the beginning of ventricular depolarization (first wave in QRS complex).

The **T wave** is a reflection of ventricular repolarization.

The **QT interval** includes a complete ventricular depolarization and repolarization (full ventricular cycle); its length must be between 0.400 and 0.450 s (depending on authors and their conveniences since some authors have studied and published in different journals what the correct length of the QTc interval should be. Even they have not agreed with their different

conclusions. We agree to Gollop, these values may vary; for us and with a broader context, the standard QTc values are between 0.400 and 0.450 s in length).

There are many formulas to measure the amount of these ranges; the most used are *Bazett and Fridericia* yet (**Figure 1**).

Like the R-R interval, the QT interval is dependent on the heart rate in an obvious way (the faster the heart rate, the shorter the R-R Interval and QT interval) and may be adjusted to improve the detection of patients at increased risk of ventricular arrhythmia.

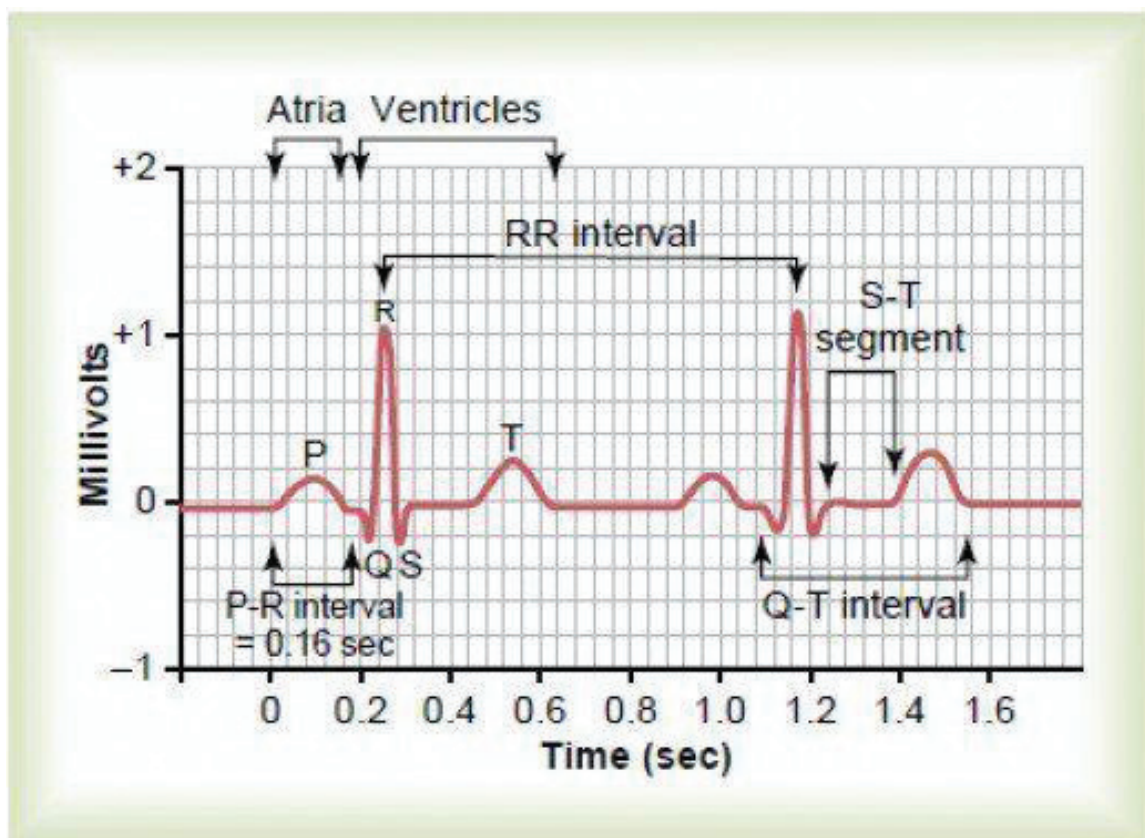
The length of the PR (or PQ) interval, of the QRS complex, of the ST segment and the corrected QT interval, are all-important and must be valued in all cases.

The PR interval must be greater than 120 ms and lower than 200 ms.

Otherwise, we would find a “**short PR**” if this is fewer than 120 ms.

If greater than 200 ms, it would be denominated like an *Auricle-ventricular block in any of its variants*.

The QRS complex should have a maximum length of 0.10 s. If it were longer lasting, we would be in front of a branch block in its different modalities (complete or incomplete).



**Figure 1.** Graphical representation of a normal heart cycle. Indicating the waves, segments and intervals in time (abscissa) and millivolts (ordinate).

The great controversy that persists to this date is about which should be considered as an average length of the QT interval since it is related to the heart rate, that is, the QT value is frequency—dependent.

Several formulas are used to correct the QT interval (QTc). The most used are those of *Bazett and Fridericia*.

However, for these authors, typical values would be between 0.40 and 0.44 s, regardless of the person's age and sex.

The discrepancies among the different authors about the typical values of corrected QT are immense. These controversies are producing an authentic catastrophe when it comes to cataloging when it is or not a short QTC [4–8].

For us, in accordance with Gollop [9]—any QT value corrected interval less than 0.360 s must be considered as “short QT.”

The most commonly used formulas are as follows (**Table 1**):

QT heart rate correction formulas	
<b>Exponential</b>	<b>Formula</b>
Bazett	$QT / RR^{1/2}$
Fridericia	$QT / RR^{1/3}$
<b>Linear</b>	<b>Formula</b>
Framingham	$QT + 0.154 (1-RR)$
Hodges	$QT + 1.75 (HR-60)$

**Table 1.** Formulas for QTc measure.

### 3. QT heart rate correction formulas

When the lengths of the different waves, intervals, and segments are greater or lesser than the values considered normal, the heart is much more vulnerable to arrhythmias. Any of these may be truly lethal, and accesses to ventricular fibrillation may develop.

As we have already mentioned, Breijjo et al. published a new electrocardiographic pattern consisting of a short PR and QT intervals in the same electrocardiogram tracing.

People who had this kind of electrocardiographic pattern had also suffered from a wide variety of symptoms. Nocturnal tachycardias, dizziness, seizures, and unexplained syncopal accesses were the main symptoms common to all patients. They were diagnosed as people with epilepsy and treated with specific drugs for epilepsy; the results of such treatment were null.

However, the electroencephalographic registers did not provide any visualization for epileptic focus in any of the assessed patients. The patient age ranged from 16 to 40 years. The male gender was predominant. All previous electrocardiographic studies were considered within normal ranges.

As we have previously mentioned, the typical features of the **Breijo pattern** are:

1. A PR interval of fewer than 120 ms (short PR).
2. A QTc interval fewer than 360 ms.

Both on the same electrocardiographic tracing.

As we have mentioned previously, we agree with Gollop et al. [9] on when the QTc interval duration ought to be considered as “short.”

Gollop et al. have written over 61 cases of Short QT Syndrome. Their cohort of 61 cases was predominantly male (75.4%) and had a mean QTc value of 0.306 s with values ranging from 0.248 to 0.381 s in symptomatic cases. For Gollop et al., the overall median age at clinical presentation was 21 years (adulthood) [IQR: 17–31.8 years) with a value of 20 years (IQR: 17–29 years) in males and 30 years (IQR: 19–44 years) in females].

These authors developed the ECG characteristics of the general population, and in consideration of clinical presentation, family history and genetic findings, a highly sensitive diagnostic using a scoring system.

This “scoring system” includes:

<b>QTc in ms</b>	
<370	1
<350	2
<330	3
<b>J point-T peak interval</b>	
<120	1
<b>Clinical history</b>	
Sudden cardiac arrest	2
Polymorphic VT or VF	2
Unexplained syncope	1
Atrial fibrillation	1
<b>Family history</b>	
First or second degree relative to SQTS	2
First or second degree relative to sudden death	1
Sudden infant death syndrome	1
<b>Genotype</b>	
Genotype positive	2
Mutation of undetermined significance in a culprit gene	1

Patients are deemed high probability ( $\geq 4$  points), intermediate probability (3 points) or low probability ( $\leq 2$  points).

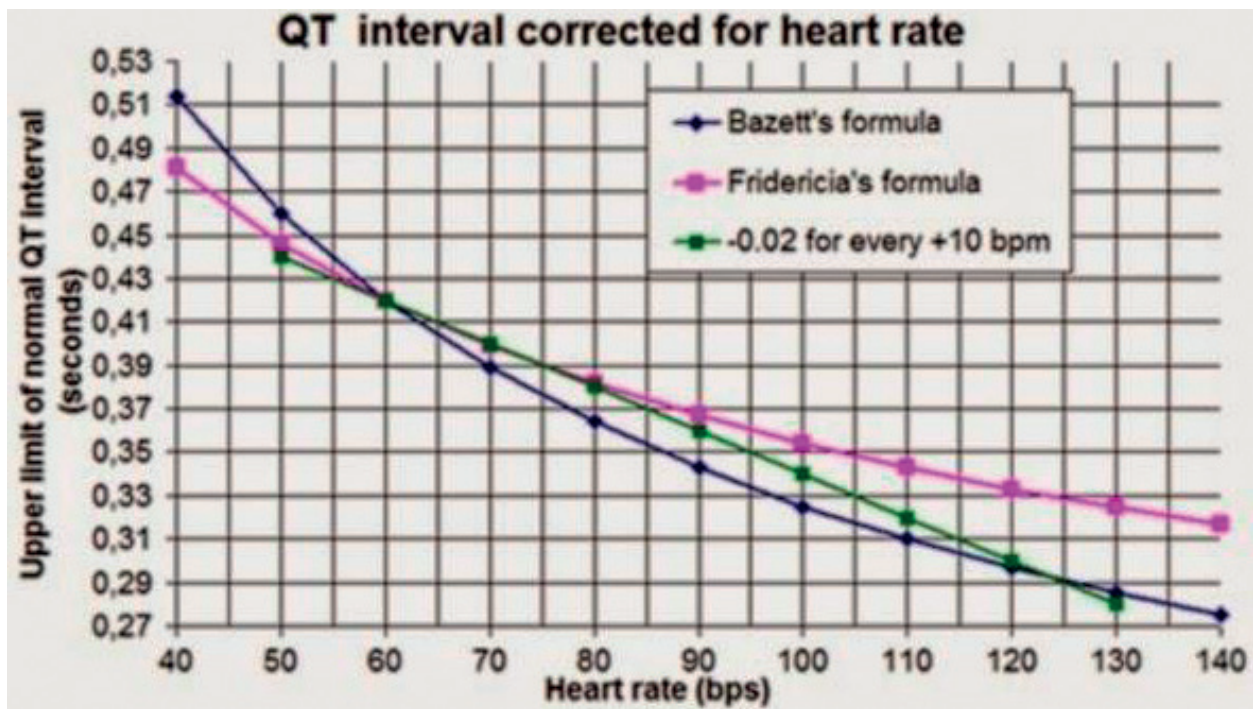


Figure 2. Boston Diagram.

Of all the current layouts, this is the one we consider as the most reliable and the most accurate. We have seen cases of a short QT interval ( $QT_c \leq 0.350$  s) in asymptomatic patients and without a positive family history thereto for congenital (and non-genetic) character.

We also think it is worthy to mention an interesting paradoxical ECG phenomenon called deceleration-dependent shortening of QT interval (shortening of QT interval associated with a decrease in heart rate); this should also be considered in a differential diagnosis [1–3].

In order to know precisely if the corrected QT value—by the different existing formulas—is in ranges, we use the **Boston diagram** (Figure 2).

#### 4. The Breijo pattern

As we have mentioned earlier, the first case of **Breijo pattern** was published in the International Journal of Cardiology in 2008.

The patient was a 37-year-old male, born in Mexico, D.F.

Since his childhood, he had suffered from tonic–clonic seizures and was treated with antiepileptic drugs (concretely with valproic acid) but without any epileptogenic focus showing up on his electroencephalogram.

Since then, the patient referred multiple accesses of nocturnal palpitations, accompanied by intense sweating that wet the pajamas. Feelings of gait instability. He liked to play sports, but at the minimum effort, he felt severe palpitations that impeded him from continuing with it.

The patient was anxious about his heart and visited numerous specialists in the field. He underwent a lot of diagnostic tests, and all of them were considered normal. The doctors believed him to be a patient with intense anxiety and hypochondriasis.

In two occasions, the patient suffered two syncope events that were considered vase-vagal etiology.

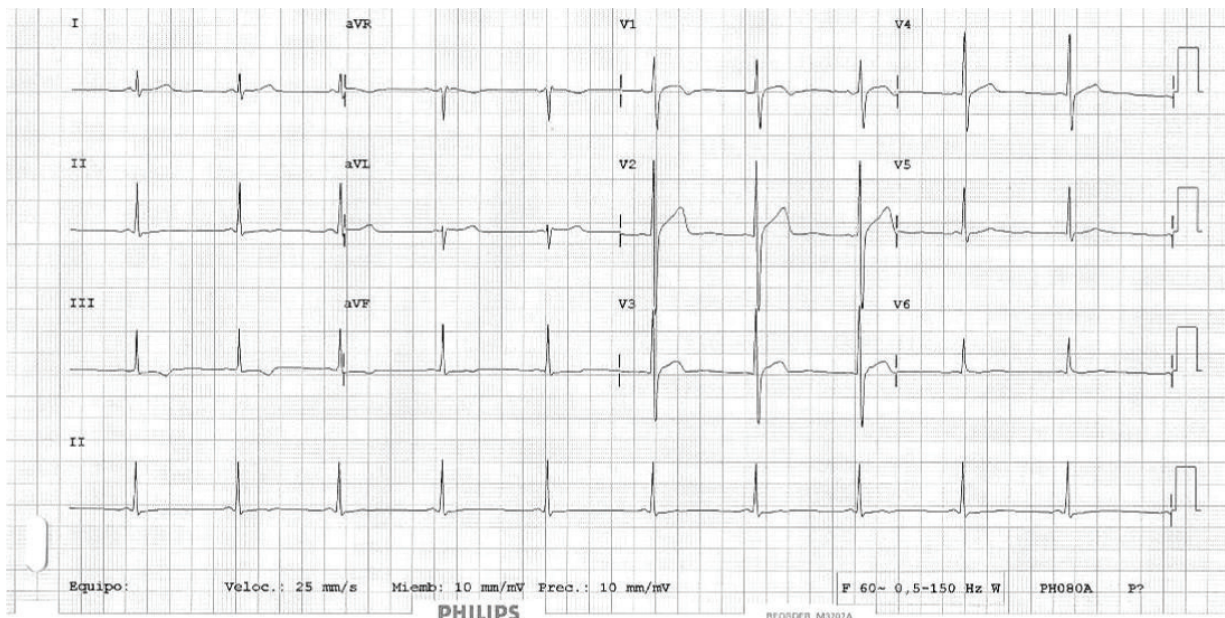
A thorough compilation of patients with this kind of symptoms such as infantile convulsions non-responders to conventional treatments, bouts of nocturnal tachycardia with sudden character, and syncopal events related to the effort.

An exhaustive study of personal antecedents, as well as your current clinical situation, was performed.

An exhaustive measurement of intervals, segments, and electrocardiographic waves. Measurement technique: MioLaserTool®, Pixruler® & Cardiacaliper®.

By way of example, we will expose the following case: A 37-year-old man with much nocturnal tachycardia crisis (since childhood) and three syncopal events observed and related to physical stress. In his family background, two sudden deaths were found: father died at age 55 of sudden cardiac, and a brother died at 22 months by sudden infant death.

He was diagnosed in his Reference Hospital (where he was transferred by emergency services) with supraventricular tachycardia to 195–200 beats/min (**Figure 3**), with narrow QRS



**Figure 3.** The full basal electrocardiogram tracing.



complexes. Severe diaphoresis, with the paleness of skin and mucous. A severe arterial hypotension to 90/50 mm Hg. Cardiac auscultation was in normal ranges but with a rapid rhythm. Tachypnea to 20 cycles/min. A grade Stuporous (Glasgow 15/15). The neurological examination was within normal ranges without focalizations. Central and peripheral pulses were palpable, symmetric, and synchronous in "frecuens". Supraventricular tachycardia disappeared using the administration of two doses of Adenosine i.v. in bolus, with six mgrs. Each one in 1 min (Figure 4). A hospital discharge was made after full stabilizing of acute process and patient was derived from your cardiologist outpatient, with the following diagnosis. A paroxysmal supraventricular tachycardia and Crisis of anxiety. The patient was transferred to our hospital because he had a similar event as the exposed, after the first visit with his outpatient cardiologist. There, the patient was adequately assessed with electrocardiogram, echocardiogram, blood levels of ions, and cardiac markers as well as electrophysiological study (EEF) (Figure 5). He was negative for high levels of Troponin (I-T), CK, CPK-MB; however, he was positive for low levels of lithium-ion ( $<0.1$  mEq/L).

Nevertheless, in an in-depth and careful study of his basal electrocardiogram, we were able to assess the existence of a short PR and QTc interval.

Below, we present the first electrocardiogram of the patient that we were able to assess.

(Despite the fact that we practice a full series of tests on the patient, the most significant in this exposure is the electrocardiography and the Holter studies).

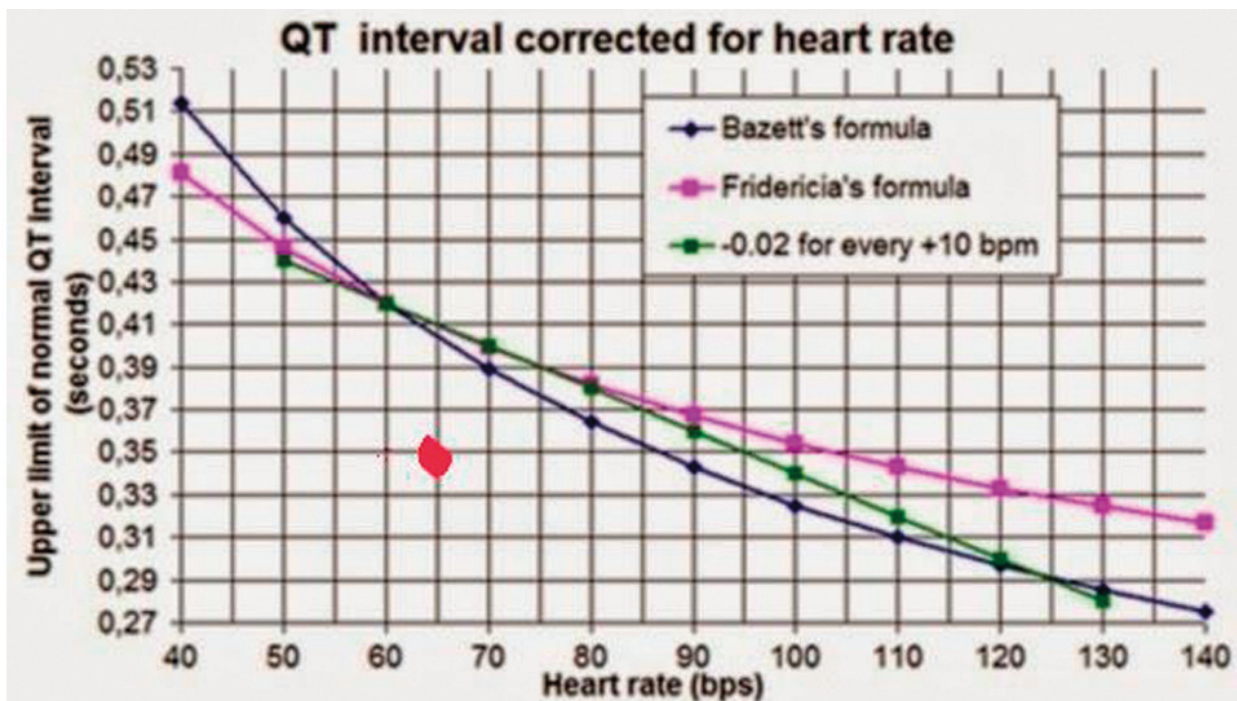
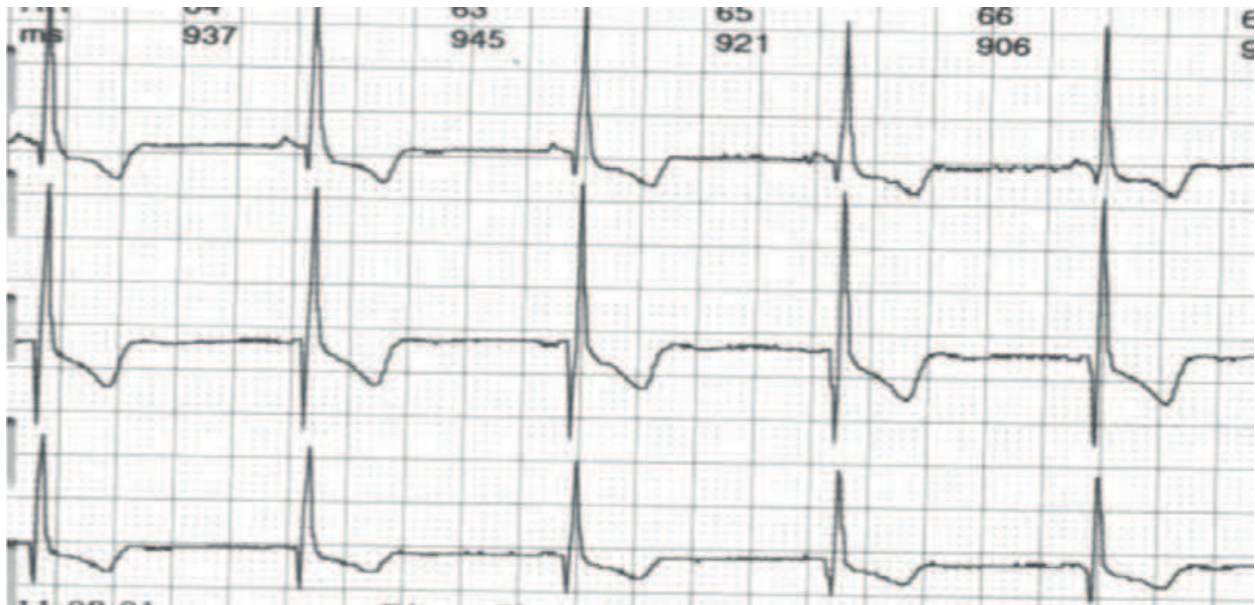

Figure 4. Graphic representation of the value obtained on the Boston diagram.



**Figure 5.** Same features as in **Figure 1**. PQ-interval: 0.100–0.110 s = Short PQ-interval. QTc (Bazzet) 0.339–0.340 s (< 0.350 s) = Short QT-interval. QTc (Fridericia) 0.332 s (< 0.350 s) = Short QT-interval.

In 60 bpm can be seen the short PR-interval (< 0.120 s) together in the short QT-interval (< 0.350 s.). Chiefly in inferior and precordial leads.

On the Boston Diagram, it would be (red marked).

## 5. Differential diagnosis

A differential diagnosis is imperative for any electrocardiographic entity that has a shortened PR interval.

These are fundamentally.

1. Wolff-Parkinson-White (**W P W**).
2. Lown-Ganong-Levine (**LGL**).
3. Mahaim.

Entity	PR-interval	QRS complex	QTc-interval
WPW	Short	Wide ( $\delta$ -wave)	Normal
L.G.L	Short	Normal	Normal
Breijo pattern	Short	Normal	Short
Mahaim	Normal or short	Normal or wide	Normal

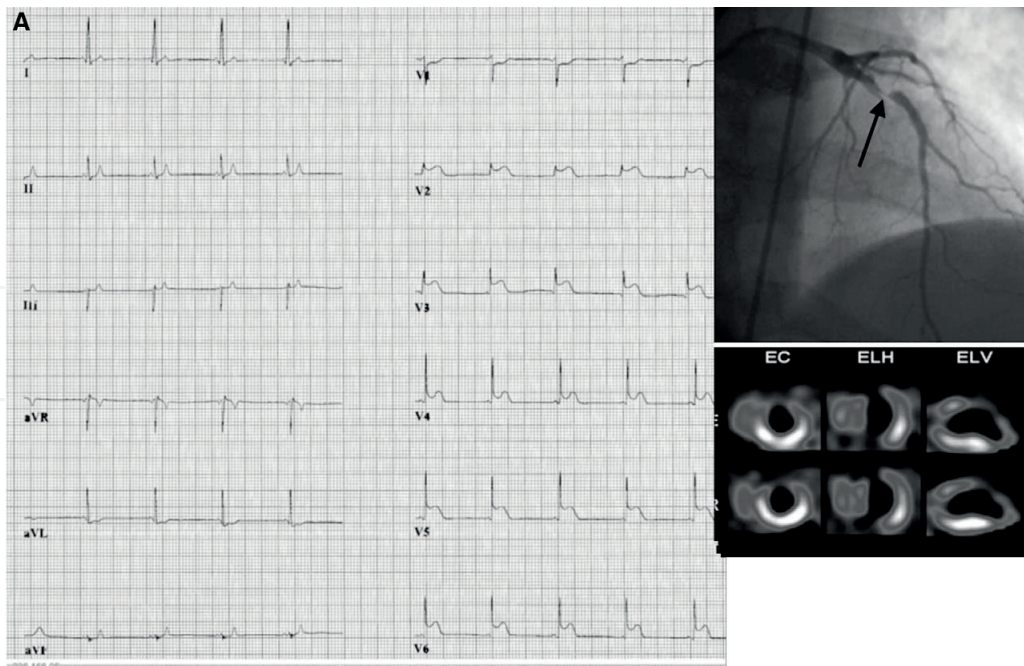


Figure 6. A Breijjo pattern along with a Wellens Pattern can be valued in the image [10, 11].

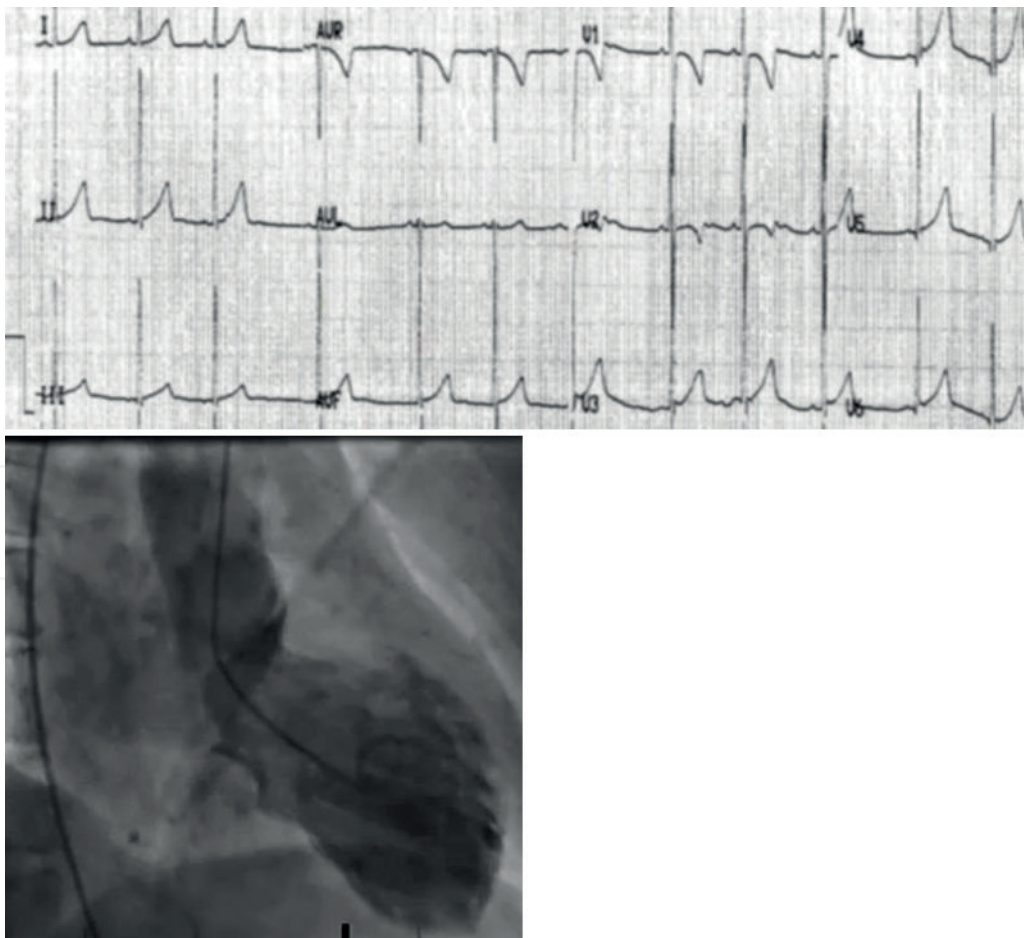


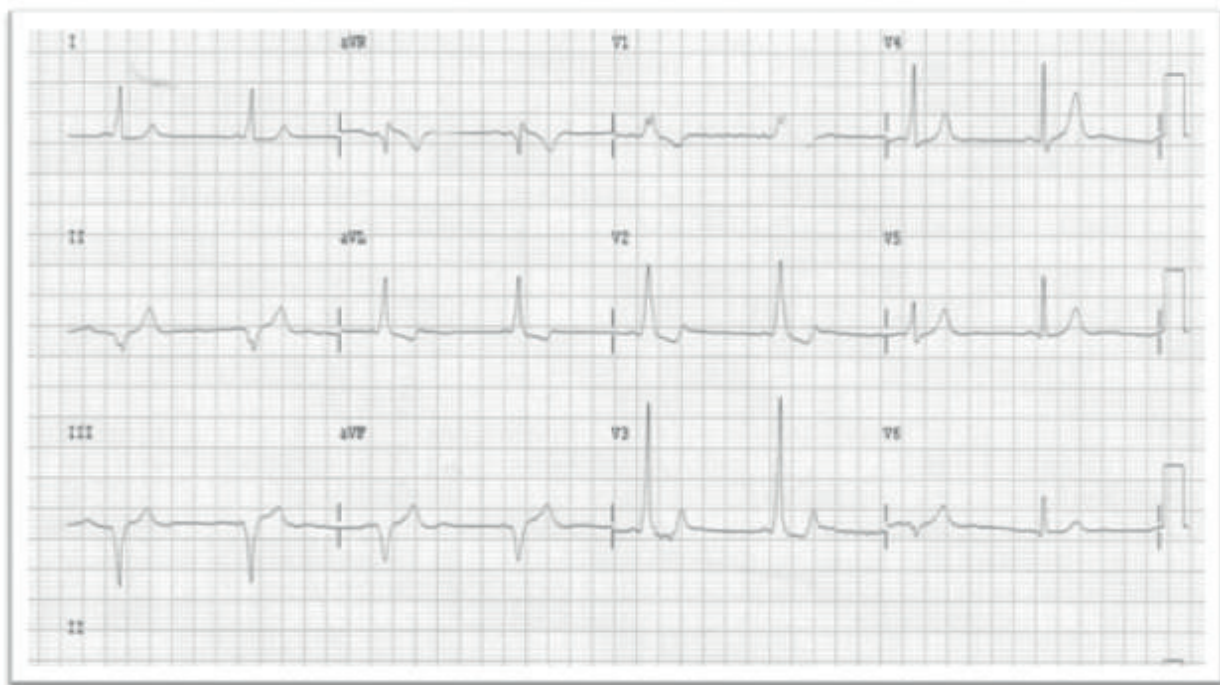
Figure 7. Electrocardiographic and arteriographic imaging of Takotsubo syndrome.

Differential diagnosis, based on the characteristics of the different intervals and complex.

This “**Breijo pattern**” we have assessed both in isolation and in association with other kinds of cardiac pathologies such as “*Wellens Pattern*”, *Wolf-Parkinson-White syndrome* and in “*Takotsubo’s Disease*” as can be seen in **Figure 6**.

The “*Broken heart syndrome*” (**Takotsubo**) and the **Breijo pattern** are correctly appreciated in **Figure 7** [12, 13].

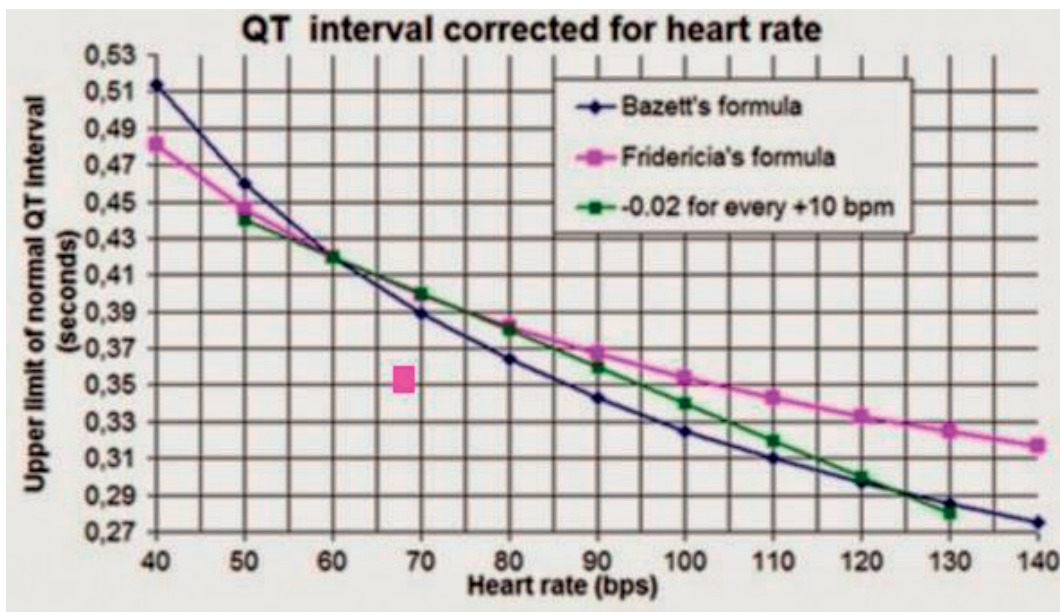
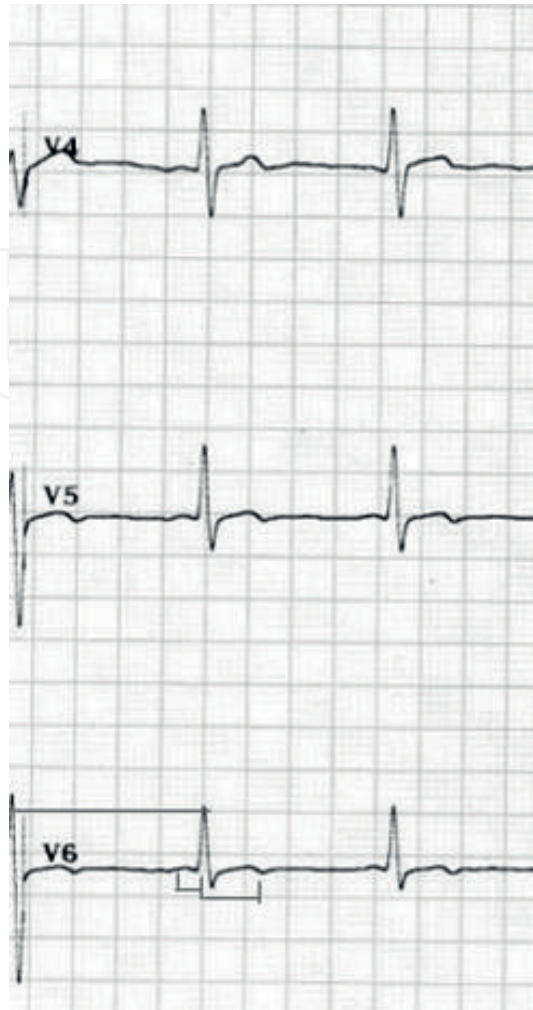
We have also known the existence of a *Wolf-Parkinson-White syndrome* associated with an electrocardiographic **Breijo pattern**, as can be seen in **Figure 8**.

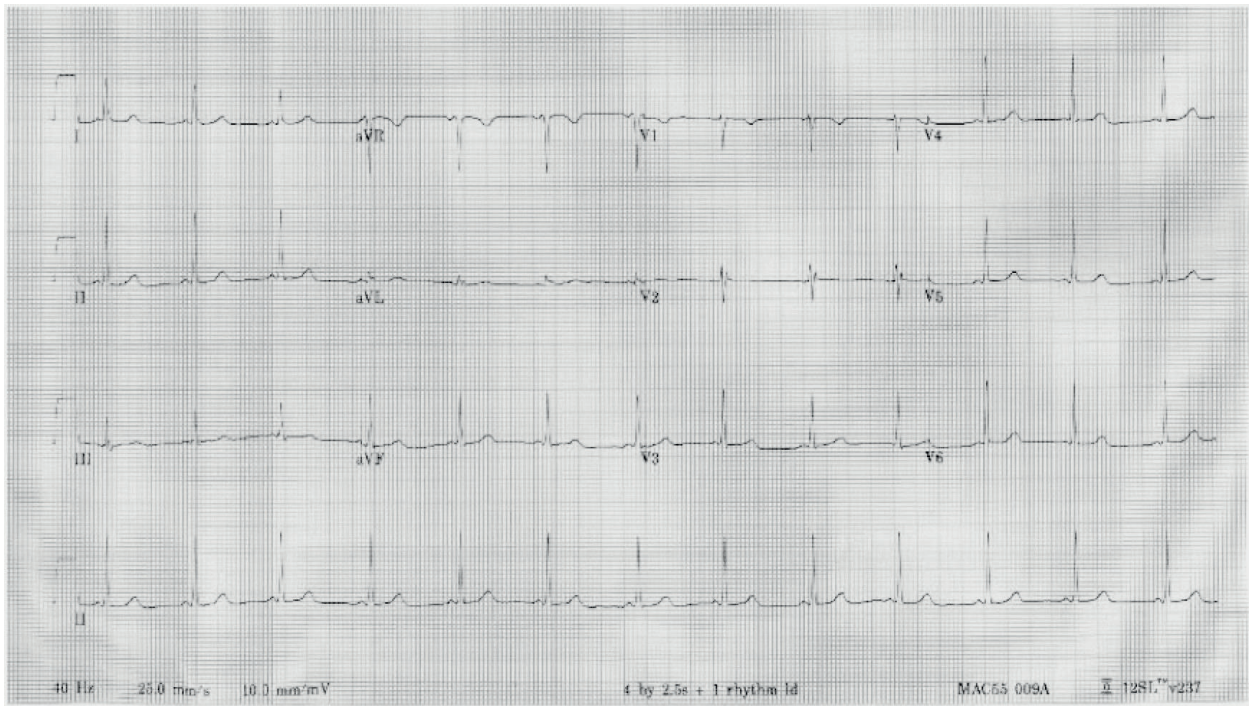


**Figure 8.** A WPW alongside a Breijo pattern can be perfectly seen in the image [14, 15].

RR	0.882352941176	seg
QTc (Rautaharju)	390	mseg
QTc (Bazett)	347	mseg
QTc (Framingham)	326	mseg
QTc (Friderica)	339	mseg
QTC (Call)	342	mseg

**Table 2.** Assessment of the values obtained according to the different formulas used.





**Figure 9.** A full electrocardiogram performed with a Breijo pattern, in a male person.

## 6. Some significant images typical of the Breijo pattern

A typical image of a Breijo pattern in precordial left leads (**Table 2**).

Measured PR interval: 0.988 s.

Calculated QTc interval:

In the Boston diagram at 68 bpm.

\*\* Square in red.

The last electrocardiogram performed with a **Breijo pattern**, in a male person who unfortunately died due to not being able to be recovered from a sudden death.

The electrocardiographic tracing was considered as within acceptable limits and his doctors decided to send him home (**Figure 9**).

PR interval value: 0.89 s (Very short).

Measured QTc value: Between 0.356 and 0.334 s very short).

In a nutshell, we can say the following about Breijo pattern as conclusions:

1. Although relatively little known so far, it is increasingly being discovered in ECG tracings that at first glance may appear normal.

2. The accurate reading of the ECG tracing must be of mandatory compliance. Despite the fact that symptoms referred by patients may be slight.
3. It is usually characteristic fact that most of the patients with a Breijo pattern have suffered in their childhood from seizure crisis without any focus of epilepsy being observed in all the assessed electroencephalography studies.
4. The most harmful consequence of the **Breijo pattern** is the sudden cardiac death, which, although fortunately does not occur often, can happen.

Summarizing:

- It is imperative to always take into account each and every symptom that a patient refers to, however slight they may seem to us. Especially if they are repetitive.
- Any patient who comes to our hospital with symptoms of nocturnal palpitations (which causes him/her to wake up from normal sleep), especially if they are accompanied by profuse sweating, nausea or throwing up, atypical thoracic discomfort as well as symptoms considered as mild or psychosomatic, especially if they are repetitive, should be evaluated in depth, without leaving any diagnostic elements ignored.
- Any patient with such characteristics must have a thorough examination of his or her background. Especially focused on the existence of syncopes or lost consciousness, as if the patient has suffered from convulsions in childhood, treated with antiepileptics and without focus electroencephalographic epileptogenic that can justify it.
- Carrying out an electrocardiographic study is imperative.

Assessing each and every one of its parameters. Making special emphasis on the lengths of the waves, intervals, and segments.

- The presence of a Breijo electrocardiographic pattern makes the heart much more vulnerable to severe arrhythmias and even sudden cardiac death.
- Whenever we find ourselves on an electrocardiogram with a short PR and QTc interval, we must be very alert and careful with the patient.
- Lithium levels in blood must be obligatorily assessed, since all patients with Pattern Breijo have low or very low levels.

## Author details

Francisco R. Breijo-Márquez

Address all correspondence to: frbreijo@gmail.com

Clinical and Experimental Cardiology (on voluntary leave), East Boston Hospital Faculty of Medicine, Boston, MA, USA

## References

- [1] Breijo-Marquez FR. Decrease of electrical cardiac systole. *International Journal of Cardiology*. 2008;**126**(2, 23):e36-e38
- [2] Breijo Marquez FR, Rios MP. Shortening of electrical cardiac systole: A new electrical disturbance? Short PR and QT intervals in the same electrocardiogram tracing (Breijo pattern). *Journal of Cardiology and Current Research*. 2014;**1**(1):00002
- [3] Breijo-Marquez FR. Accelerated atrioventricular stimulation with an early and shortened ventricular repolarization in the same individual. *WebmedCentral. Cardiology*. 2014;**5**(3):WMC004589
- [4] Zabel M, Franz MR, Klingenhoben T, et al. Rate-dependence of QT dispersion and the QT interval: Comparison of atrial pacing and exercise testing. *Journal of the American College of Cardiology*. 2000;**36**:1654-1658
- [5] Glancy JM, Garratt CJ, Woods KL, et al. Three-lead measurement of QTc dispersion. *Journal of Cardiovascular Electrophysiology*. 1995;**6**:987-992
- [6] Behrens S, Li C, Knollmann BC, et al. Dispersion of ventricular repolarization in the voltage domain. *Pacing and Clinical Electrophysiology*. 1998;**21**:100-107
- [7] Goldenberg I, Moss AJ, Wojciech Zareba MD. QT interval: How to measure it and what is "normal". *Journal of Cardiovascular Electrophysiology*. 2006;**17**(3):333-336
- [8] Schwartz PJ, Moss AJ, Vincent GM, Crampton RS. Diagnostic criteria for the long QT syndrome. An update. *Circulation*. 1993;**88**(2):782-784
- [9] Gollob MH, Redpath CJ, Roberts JD. The short QT syndrome: Proposed diagnostic criteria. *Journal of the American College of Cardiology*. 2011 Feb 15;**57**(7):802-812
- [10] Tandy TK, Bottomy DP, Lewis JG. Wellens' syndrome. *Annals of Emergency Medicine*. 1999;**33**(3):347-351
- [11] Breijo-Márquez FR, Ríos MP, Baños MA. Presence of a critical stenosis in left anterior descending coronary artery alongside a short "P-R" and "Q-T" pattern, in the same electrocardiographic record. *Journal of Electrocardiology*. 2010;**43**(5):422-424
- [12] Vicenty A, Ortiz F, et al. Heart: Takotsubo cardiomyopathy. *Boletín de la Asociación Médica de Puerto Rico*. 2016;**108**(1):25-28
- [13] Breijo-Marquez FR, Pardo Rios M. Sudden death in a patient with a short PR interval and subsequent sudden onset of a typical Tako-tsubo pattern. *Open Journal of Internal Medicine*. 2013;**3**:95-97
- [14] Munger TM, Packer DL, Hammill SC, et al. A population study of the natural history of Wolff-Parkinson-White syndrome in Olmsted County, Minnesota, 1953-198. *Circulation*. 1993;**87**(3):866-873
- [15] Breijo-Marquez FR. A Breijo pattern associated to a Wolff-Parkinson-White pattern. *Journal of Cardiology and Current Research*. 2016;**5**(3):00161



