

We are IntechOpen, the world's leading publisher of Open Access books Built by scientists, for scientists

4,800

Open access books available

122,000

International authors and editors

135M

Downloads

Our authors are among the

154

Countries delivered to

TOP 1%

most cited scientists

12.2%

Contributors from top 500 universities



WEB OF SCIENCE™

Selection of our books indexed in the Book Citation Index
in Web of Science™ Core Collection (BKCI)

Interested in publishing with us?
Contact book.department@intechopen.com

Numbers displayed above are based on latest data collected.
For more information visit www.intechopen.com



Hand Coverage

Francisco Martinez Martinez,
M. Llanos Guerrero Navarro, Juan Garcia Navarro,
Alberto Gimenez Ros and
Alba Izquierdo Robledano

Additional information is available at the end of the chapter

<http://dx.doi.org/10.5772/intechopen.74152>

Abstract

Hand and finger soft tissue defects have always represented a surgical challenge at any accident and emergency department. Techniques may vary from just direct closure of the wound to free tissue transfer. Knowledge of the main locoregional hand flaps is paramount to solve most of the soft tissue defects at this level. Flaps vary depending on their blood supply and design. Their vascularity might be at random, they can be pedicled with anterograde or reversed flow or they can rely on simple or complex free tissue transfer whose blood flow depends on vascular anastomosis. This article reviews all the main soft tissue local or locoregional reconstructive techniques for hands and fingers.

Keywords: hand coverage, hand reconstruction, fingertip reconstruction, soft tissue defect

1. Introduction

Soft tissue coverage represents an essential part of the treatment of a traumatic hand. Conservative approach of soft tissue loss may lead to irreversible stiffness and in some cases a higher chance of infection.

The design of different flaps for the hand has been the result of an improvement in the knowledge of hand neurovascular anatomy as well as their hemodynamic behaviour. This has allowed the development of an immense variety of regional flaps to fit a wide range of soft tissue problems.

Before all this knowledge, flaps were harvested at random, and a 2:1 width to length relation was a necessary condition in order to ensure the survival of a flap. This represented an important limitation to solve the different soft tissue challenges.

The description of pedicled flaps importantly increased the possibilities of coverage. The first neurovascular pedicled island flap was described by Littler [1]. Reverse-flow pedicled flap was first described by Foucher [3] based on the distal anastomotic connections with the dorsal metacarpal arteries, which were found in anatomy studies. Besides, the later description of perforator flaps also simplified the reconstructive techniques, avoiding the sacrifice of important vascular structures. Pollicisation of the index finger, already performed in congenital hand cases, was also applied in traumatic loss of the thumb. Eventually, the development of microsurgical advanced techniques such as toe to finger transfer for partial or complete amputation of a finger was an important asset in cosmesis and function.

Currently, our effort has also been focused not merely on coverage but also on reducing donor site morbidity; techniques leading to incapacitating neuralgias or scars have to be avoided. In some patients, this type of pain may represent a more serious problem than stiffness itself.

There are different possibilities of coverage depending on the tissue exposed and its location. This chapter will only deal with locoregional basic flaps.

2. Split- and full-thickness skin grafts

This type of technique (**Figure 1**) can only be used when bones or tendons are not exposed. Due to inevitable contracture after the graft has taken, most patients will need some sort of

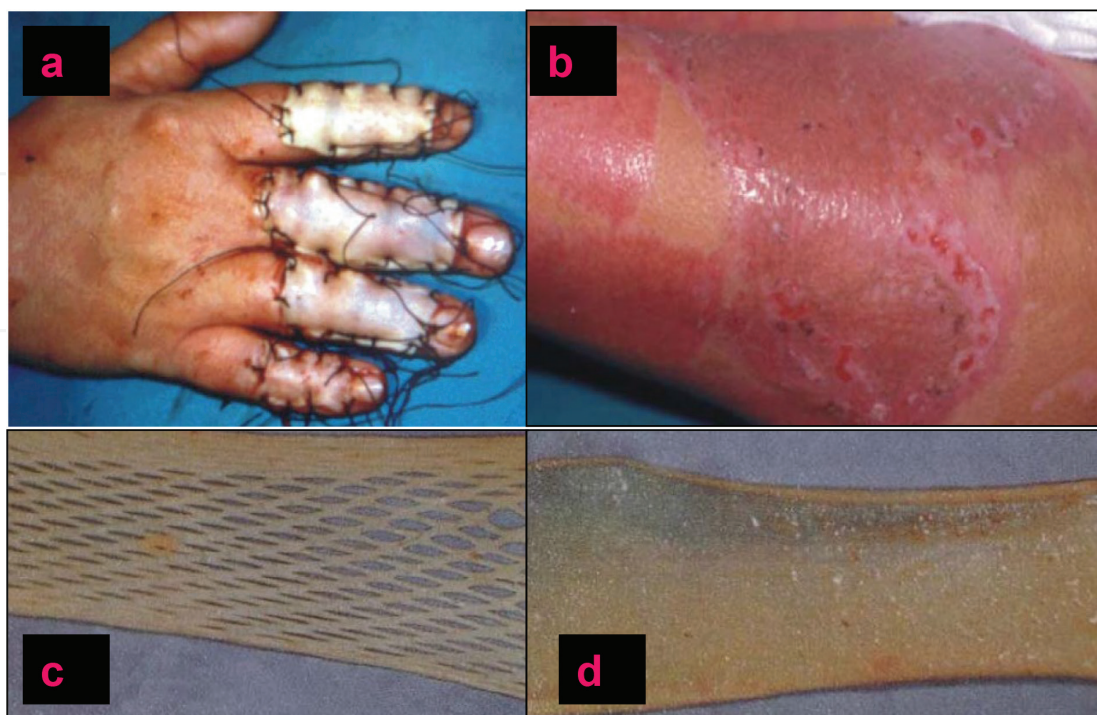


Figure 1. Skin grafts: (a) full-thickness skin grafts applied to the dorsum of the hands, (b) donor site of split-thickness skin grafts, (c) split-thickness skin graft meshed and (d) split-thickness skin graft.

hand physiotherapy. This is even more the case, when partial-thickness skin grafts have been used. This type of graft is more prone to contract after having taken.

Split-thickness skin grafts have to be harvested with the help of a dermatome and must be 0.25–0.3 mm wide. Thicker grafts may lead to a non-healing donor site plus a less chance of graft taking. They are often meshed in order to increase their size and to allow exudate to escape.

Full-thickness skin grafts are usually used in finger coverage. One of the reasons is that the amount of the skin to cover a defect in fingers is small enough to be easily obtained from the groin, the wrist or even the anterior skin of the arm or forearm. Also, this type of graft tends to contract less than the split one allows a better functional and cosmetic result.

3. Local flaps for the dorsum of the hand

The dorsal skin of the hand is particularly elastic, and different local flaps can be performed in order to cover small defects. The blood supply is mostly at random in these flaps. They might be useful when small to moderate defects are approached and mostly if bone or tendons are exposed. The palmar skin of the hand can be considered the opposite in these terms. Local flaps will not usually solve any coverage difficulty.

Cuadrangular skin advancements and rotational flaps are simple and allow stable coverage with optimal rates of survival.

Limberg or Dufourmentel (Figure 2) flaps are local cuadrangular transposition flaps. These are mostly performed in elective surgery such as excisional removal of lesions [2].

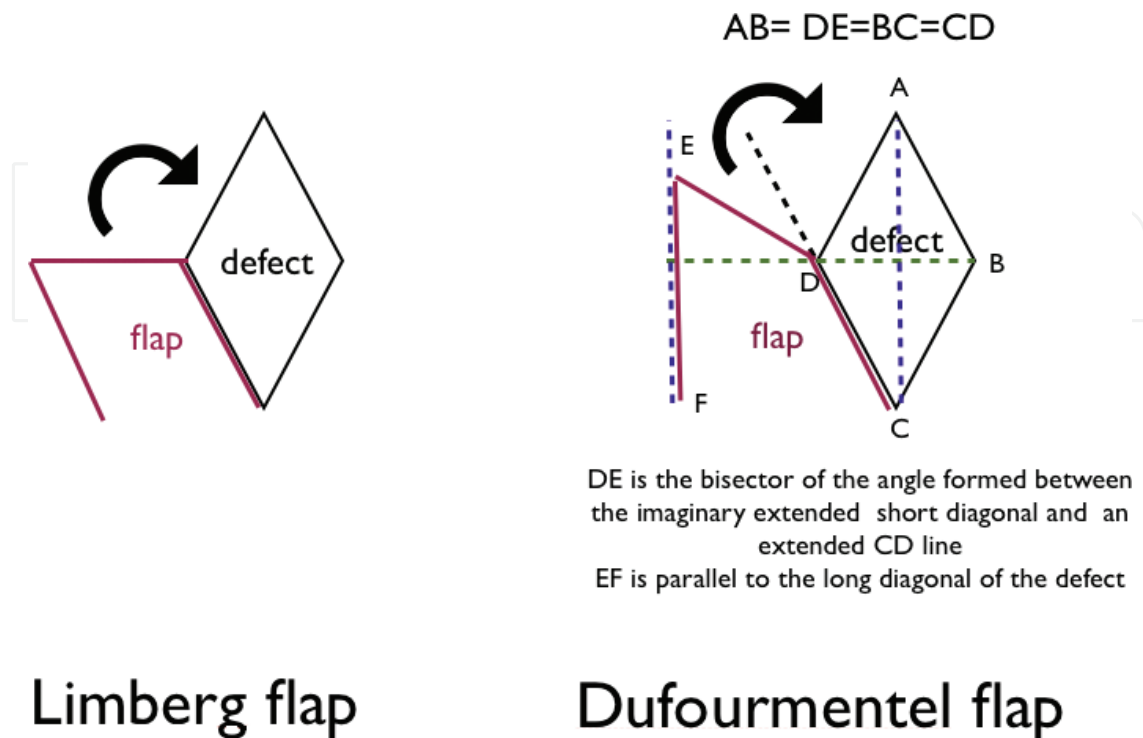


Figure 2. Limberg's and Dufourmentel's flaps.

4. Coverage of the palm of the hand

4.1. Radial fasciocutaneous flap

Described by Yang [4] in 1981 as a free flap for the hand, this is a fasciocutaneous island flap based on the radial artery. Currently, it is not considered the first surgical option due to inevitable sacrifice of the radial artery and possible donor site morbidity. Allen's test is performed before surgical planning (**Figure 3**).

When the objective is palm coverage, the design of the paddle starts in the middle third of the forearm between the brachioradialis (BR) and the flexor carpi radialis (FCR). The dissection can be performed suprafascially, but once the septum in between the two muscles is reached, the fascia along with the septum and the artery has to be included. The peritenons of the FCR and BR must not be injured. The cephalic vein is usually necessary when harvesting a free flap but not in the case of a reverse-flow type, in which only concomitant veins are needed. The artery will be ligated at the proximal aspect of the flap. The arterial blood flow to the radial artery occurs through the distal ulnar artery connections in the vascular palmar arches; thus, this will then be considered a reverse-flow island flap.

The same flap can also be raised as an adipofascial flap in order to reduce morbidity of the donor site, but then again the flap itself will have to be grafted. An osteocutaneous radial flap

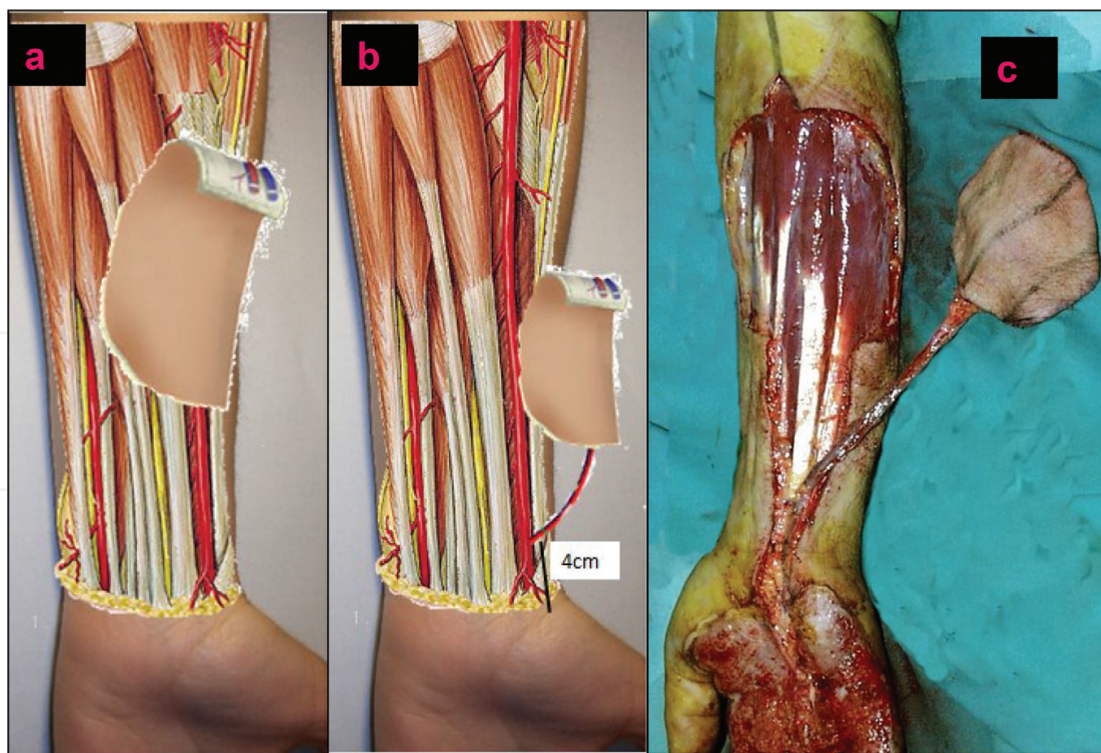


Figure 3. Fasciocutaneous radial flap: (a) retrograde fasciocutaneous radial flap, (b) radial perforator flap and (c) clinical case of a retrograde fasciocutaneous radial flap for a defect of the palm of the hand.

has also been described. In this case a small portion of the radius diaphysis is taken along with the artery. This type of reconstruction has been widely used as a free flap and not much as a pedicled flap.

A perforator radial flap has also been described based on about ten existent perforating vessels (0.3–0.5 mm in diameter) located 2–4 cm proximal to the radial styloid process. To raise an adipofasciocutaneous flap, the territory will be marked over the proximal or middle third of the volar aspect of the forearm, with the pivot point about 2–4 cm proximal to the radial styloid. The proximal perforators can be ligated leaving the distal ones intact. The flap can be also potentially raised as an adipofascial flap [5].

4.2. Glabrous skin flap

Orbay et al. [6] described a flap based on a superficial cutaneous branch of the radial artery at the thenar eminence (**Figure 4**).

The superficial palmar arch is mainly formed by the ulnar artery, less so the superficial branch of the radial artery emerges 1–2 cm proximal to the wrist fold before dividing into superficial and dorsal branches (the latter one eventually enters Guyon's canal).

The superficial radial branch courses underneath the palmar fascia and irrigates the thenar eminence before proceeding under the adductor and opponens muscles. At the level of the insertion of the FCR, the cutaneous branch of the superficial radial artery perforates the palmar

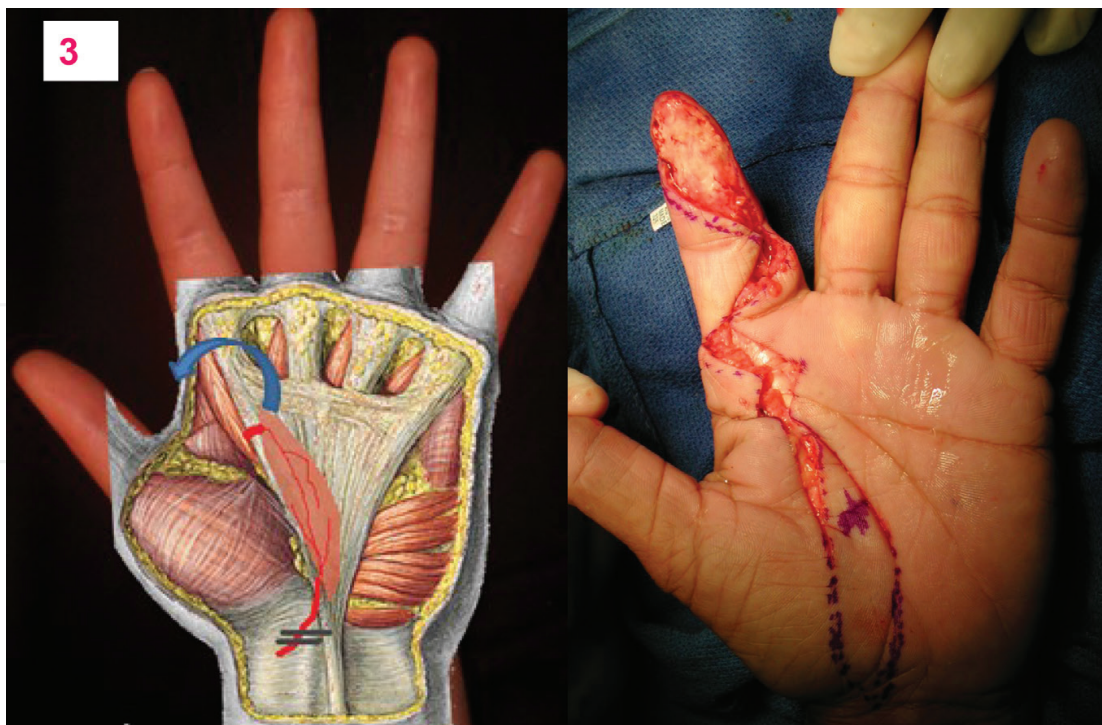


Figure 4. Reverse-flow flap based on the anastomosis of the superficial palmar branch of the radial artery with the vascular palmar arches. Notice the 180° arc of rotation of the flap.

fascia; this level corresponds to a point 0.5–1 cm radial to the cutaneous thenar fold. A distal perforating vessel from the profundus or the superficial arch emerges at the confluency of Kaplan's line with the second webspace axis. The flap can then be raised based on the proximal cutaneous perforator and down to the radial superficial artery. Thus raised, the flap can be used as a free flap. Based on the distal perforators, it can also be designed to be a retrograde flap and can be used to solve first web contractures. In this case the superficial radial branch must be ligated proximal to the skin paddle.

5. Coverage of the dorsum of the hand

5.1. Posterior interosseous fasciocutaneous flap

Described by Zancolli and Angrigiani [7] in 1988 for the dorsal coverage of the hand, this flap is based on the existence of an anastomosis between the posterior interosseous artery and the dorsal branch of the anterior interosseous artery at the dorsal aspect of the wrist. The posterior interosseous artery will be ligated, and the blood flow will course retrogradely from the anterior interosseous artery to the posterior interosseous pedicle (**Figure 5**).

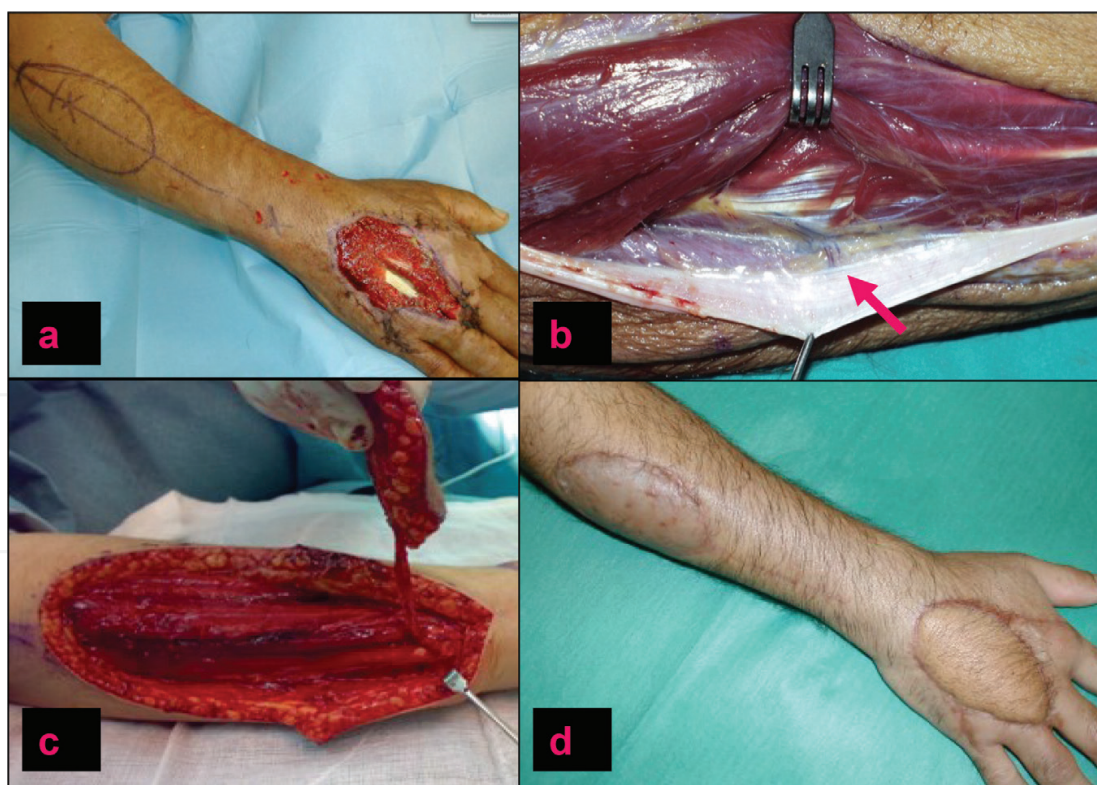


Figure 5. Interosseous posterior flap: (a) defect located on the dorsum of the hand and markings of the flap, (b) septum between the fifth and sixth extensor compartment where a cutaneous perforator can be visualized, (c) the flap harvested and (d) the final outcome.

The design of the posterior interosseous flap starts with the marking of the cutaneous island. A line is drawn between the lateral humeral epicondyle and the distal radioulnar joint. The island must be outlined in between the proximal and distal thirds of the forearm. The main posterior interosseous cutaneous branch emerges 9 centimetres distal to the lateral epicondyle in the same line; this can also be easily identified with a Doppler ultrasound.

The vascular anastomosis between the two interosseous arteries can be found 2 cm proximal to the radiocarpal joint at the proximal border of the pronator quadratus.

The interosseous posterior artery is found at the septum between the extensor carpi ulnaris (ECU) and the extensor digiti minimi (EDM). This septum and the anastomosis are easily identified distally, which is the reason why many surgeons prefer to first identify the anastomosis and the posterior interosseous artery and eventually raise the flap. The posterior interosseous artery is closely related with the posterior interosseous nerve. This condition might represent a challenge in the hands of an inexperienced surgeon.

Donor site may be close directly or with a split skin graft depending on the width of the cutaneous island.

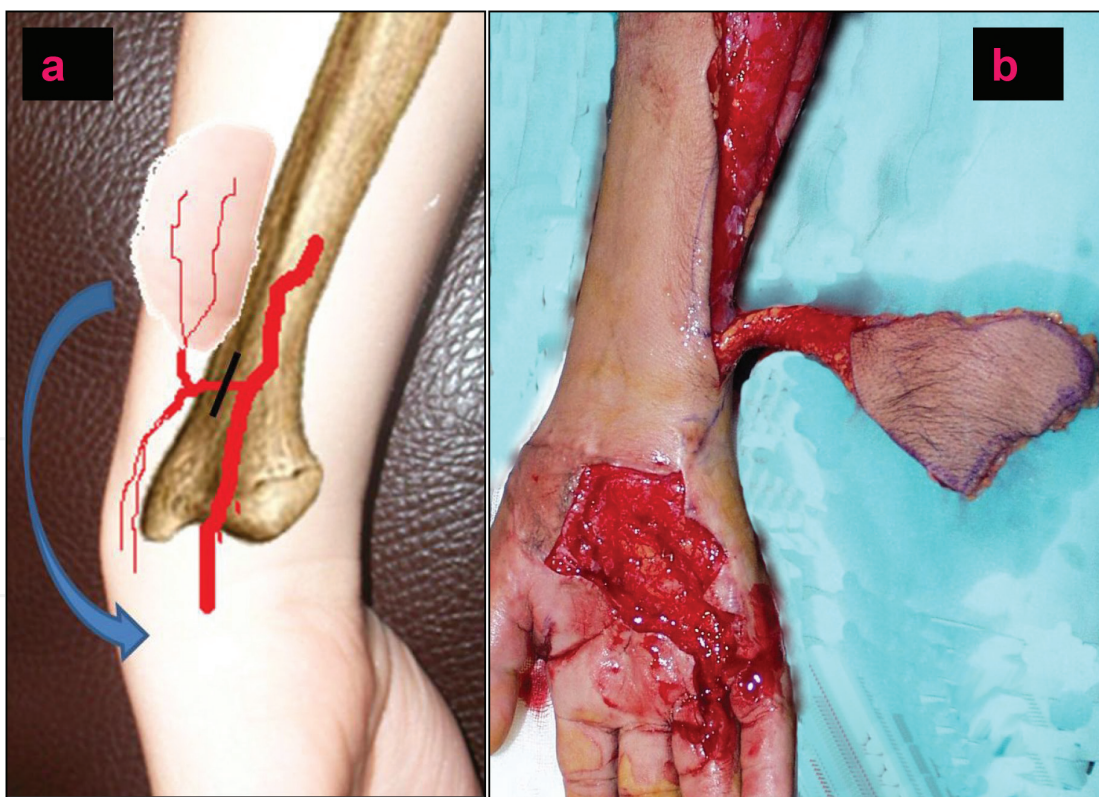


Figure 6. Dorsoulnar fasciocutaneous flap: (a) anatomy of the distal dorsal branch of the ulnar artery and elevation of the flap based on the distal anastomosis of the ascending branch with the dorsal radial arch and the cutaneous ulnar branch needs to be ligated in order to perform a retrograde flap (black line) and (b) clinical case of dorsoulnar fasciocutaneous flap to cover a defect of the palm.

5.2. Dorsoulnar fasciocutaneous flap

This is a flap that is based on the distal branch of the ulnar artery which emerges 2–5 cm proximal to the pisiform bone. This branch courses between the flexor carpi ulnaris (FCU) and the ECU and then reaches the cutaneous skin crossing between the ulnar nerve and the FCU distally. It then divides into descending and ascending branches. The descending branch anastomoses with skin perforators of the dorsal arch (**Figure 6**).

This distal branch can be identified with Doppler ultrasound. The flap can then be raised as a propeller flap (rotating the fasciocutaneous island around this branch) or as a reversed flap based on the anastomosis with the descending branch. This second option allows further advancement. This flap reaches the fourth and the fifth metacarpophalangeal joints.

Bertelli and Pagliei [8] have made an anatomic description of an osteocutaneous flap based on the ulnar periosteal branches of the ascending branch.

6. Finger coverage

6.1. Cross-finger flap

The cross-finger flap is a two-stage flap reconstruction that was first described by Cronin in 1951 [9] (**Figure 7**).

This flap can be easily raised due to the fact that it does not require the dissection of vascular pedicles. It is a transposition flap based on the subcutaneous dorsal branches of a proper palm digital artery (PDA).

The fact that this is a two-stage surgical technique is the main disadvantage.

This flap is frequently designed over the dorsal skin of a medial phalanx in order to cover a distal phalanx or a medial phalanx of a contiguous finger. The limits of flap dissection are always represented by the finger folds. The vascular base of the flap is located at the medio-lateral line of the donor finger that is directly opposite to the defect on the adjacent finger. In the case of volar skin loss, the flap has to be raised based on the dorsal skin of the medial phalanx of the donor finger. In case of dorsal skin loss, the coverage will be performed based on the volar aspect instead.

Dissection must include the skin and subcutaneous tissue, and the tendon sheath should not be exposed. The donor site has to be covered with a full-thickness skin graft.

The donor and recipient finger should be buddy splinted for 2 weeks. The second surgical step is then performed and the syndactyly is released. Hand physiotherapy will be necessary after the surgical procedure has been completed.

This type of coverage is particularly interesting for the triphalangeal fingers. The middle finger acts as a proper donor for the index and ring fingers. Little finger injuries require the skin

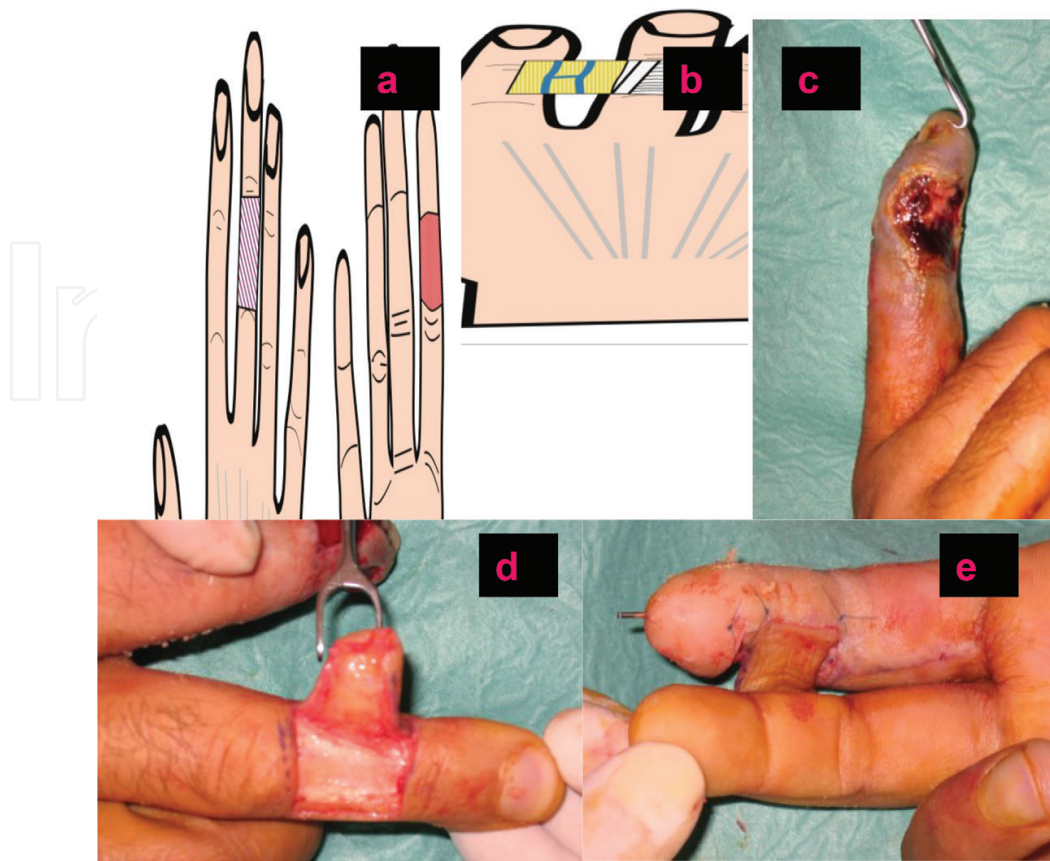


Figure 7. Cross-finger flap: (a and b) defect and markings of the flap and (c, d and e) clinical case; always preserve the peritenon to be able to apply a skin graft on the donor digit.

from the ring finger. This flap is not a good option for the coverage of the tip of the middle finger, because the ring or the index medial phalanges are more proximally located and the middle finger needs to be forced into flexion in order to fit next to them.

6.2. Thenar flap

This flap has also been described for the reconstruction of the tip of the long fingers. This is not only a simple technique but also needs a two-step procedure (**Figure 8**).

The skin is taken from the radial aspect of the thenar eminence, proximal to the metacarpophalangeal fold. Despite of its name, scars at the thenar eminence should be avoided above all the weight-bearing central axis of the thenar eminence.

The base of the flap can be cranially or caudally located. The donor site needs to be grafted.

6.3. V to Y Atasoy flap

This triangular advancement flap was described by Tranquili [10] and popularised by Atasoy [11]. This flap is indicated in the case of transverse or dorsally oblique amputation of the tip of the fingers (**Figure 9a**).

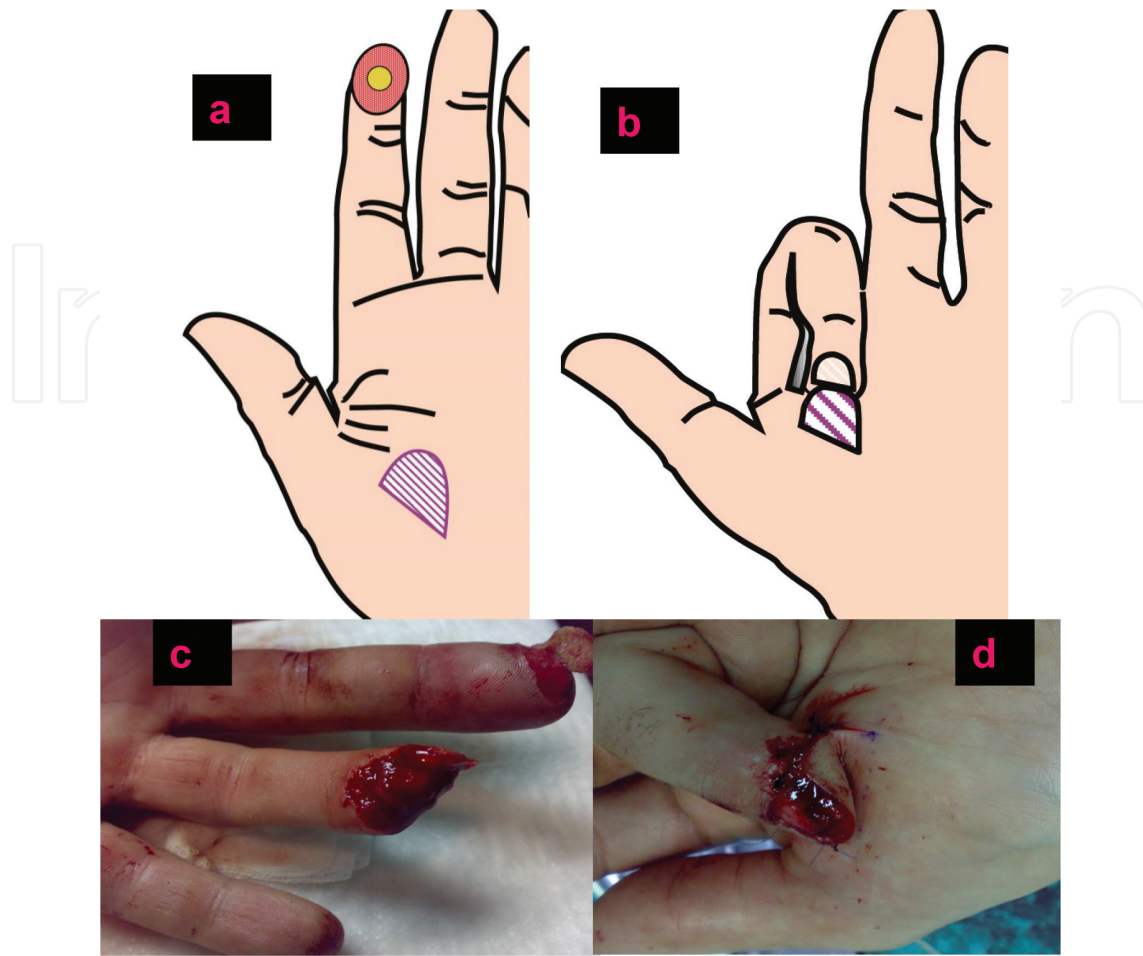


Figure 8. Thenar flap: (a and b) schema and (c and d) clinical case.

This flap is one of the most frequently performed in the emergency department but can be advanced only up to 7 to 8 mm. If higher expectations are sought, this flap would not be suitable. Inexperienced surgeons may tend to skeletonize the base of the flap or suture it under tension; any of these situations lead to inevitable flap necrosis.

The design of the flap is marked on the volar aspect of the affected distal phalanx down to the distal fold. The subcutaneous tissue can be fully elevated from the tendon sheath. The skin will only be incised superficially (i.e. until the subcutaneous tissue appears). Once dissected, the distal aspect of the flap is fixed with the help of a small needle rather than direct sutures, because direct suturing may damage the nail bed. The skin must be closed in a V to Y fashion in order to advance the flap.

6.4. Bilateral V to Y Kutler's flap

This bilateral flap was described by Kutler [12] in 1930; it is based on the same principles as the V to Y flap (**Figure 9b**).

The Vs are marked at both sides of the defect, taking into account that they will be irrigated by the small branches of the proper palmar digital arteries.

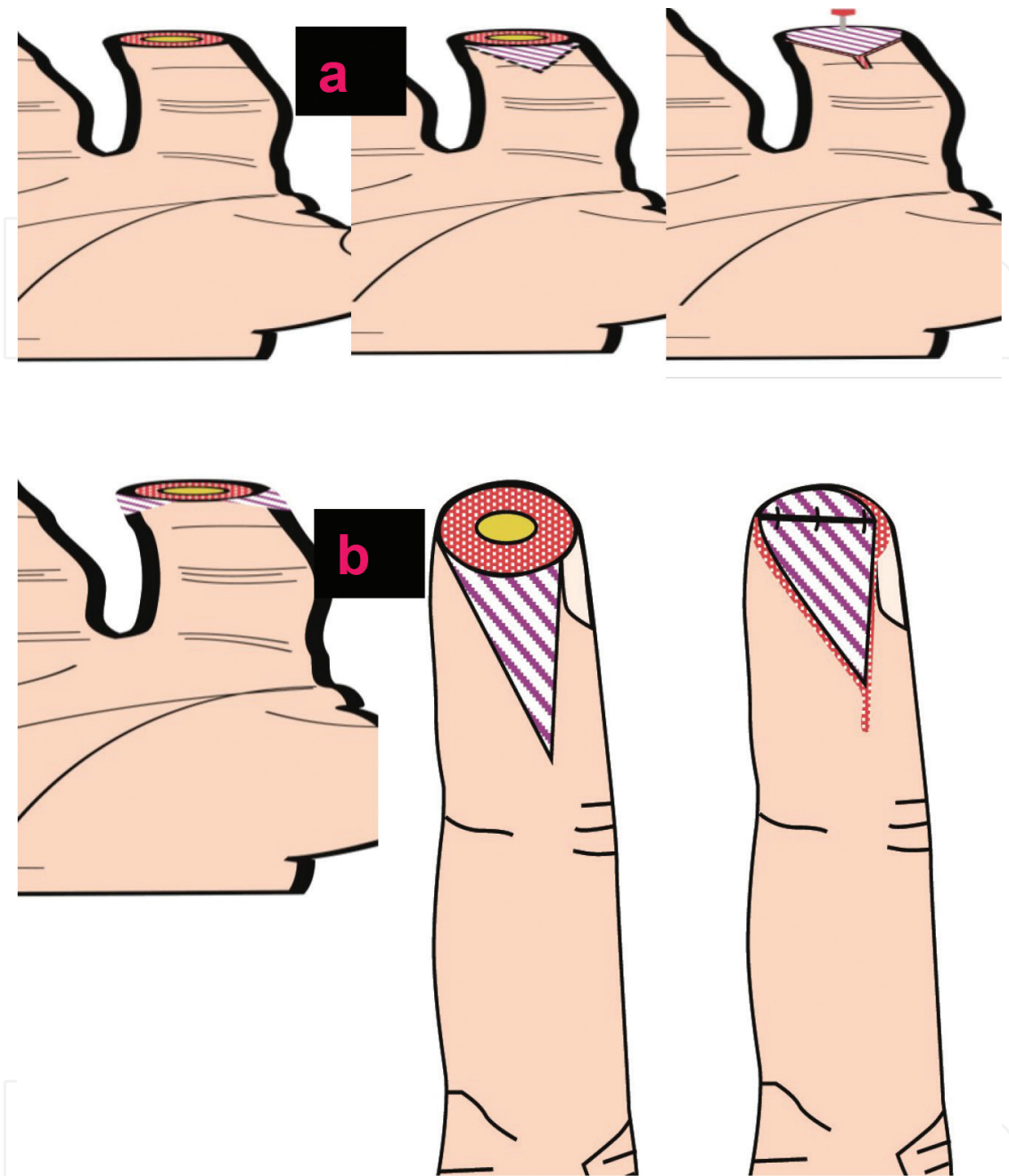


Figure 9. (a) Atasoy's flap and (b) Kutler's flap.

As a main drawback, this flap leaves an unpleasant longitudinal linear scar at the tip of the finger.

6.5. Homodigital pedicled island flaps

6.5.1. Oblique triangular neurovascular flap

This flap was described by Venkataswami and Subramanian [13] in 1980; it is mostly suitable for oblique fingertip amputations. The flap is based on the vascular pedicle opposite

the amputated side. The base of the triangular flap lies adjacent to the amputated side. A vertical incision is performed in the midlateral line of the finger down to the periosteum, and the pedicle of the finger is visualised and fully raised avoiding skeletonization. A partial thickness oblique incision is then performed; only the fibrous septa are divided to allow flap advancement (**Figure 10**).

The apex of the triangle is usually marked at the PIP joint. Small islands will tend to contract in time. Therefore, the island should never be small in size.

Unlike most unipedicled digital flaps, it contains the digital nerve of the flap and branches of the contralateral digital nerve. It cannot be considered as a true island flap but the first step just before that.

In case the advancement provided is insufficient, decision has to be made as to whether a true island flap is needed.

6.5.2. Homodigital neurovascular anterograde unipedicled island flap

This was described by Littler [1] although as a heterodigital flap. The design of the flap is subject to the location of the lesion. Despite of that, Brunelli described some considerations as to which donor site is more advisable in order to leave intact the dominant hemipulp. Advisable donor sites are the ulnar aspect of the index and middle fingers as well as the radial aspect of the ring and little fingers (**Figures 11 and 12**).

A U-shaped flap is marked, proximal to the defect, apex based at the PIP joint. The vertical incision reaches the periosteum, and once again, the pedicle must be visualised and not skeletonized to preserve a suitable venous drainage. The oblique incision also reaches the tendon sheath, and the flap would finally only be attached by its pedicle. The advancement can be

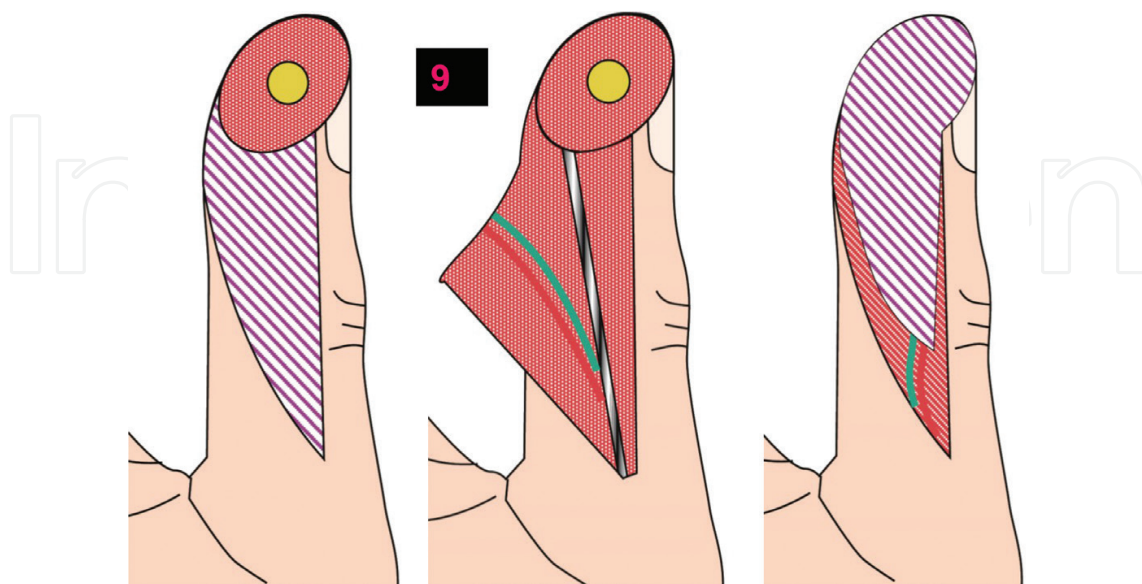


Figure 10. Neurovascular island flap and Venkataswami's flap.

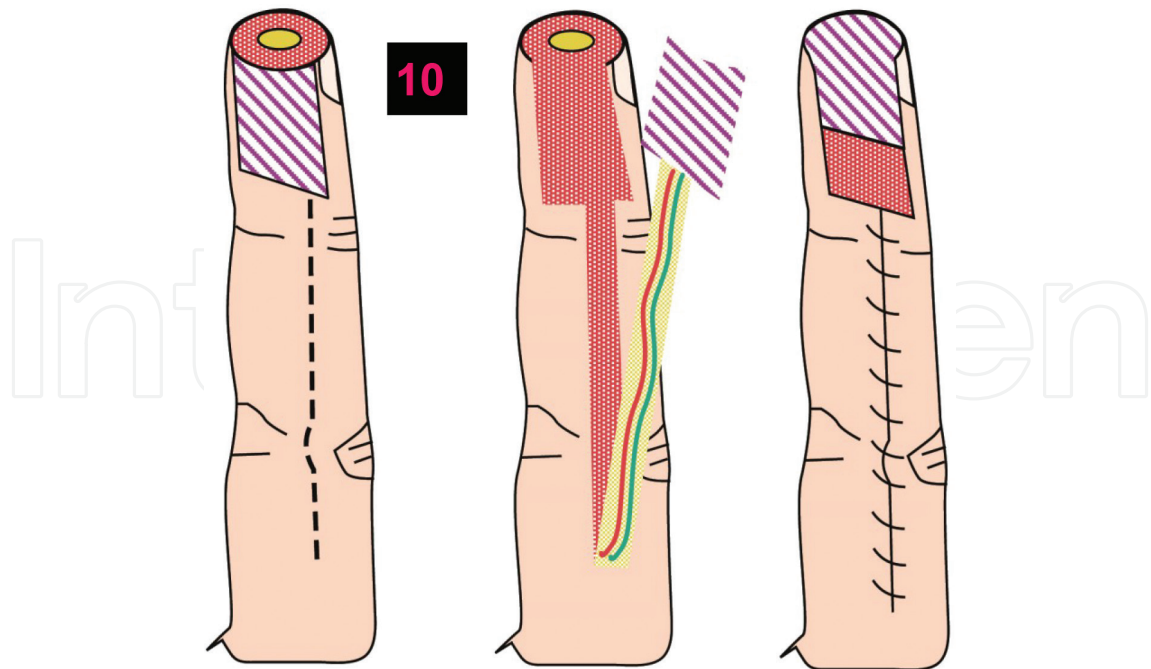


Figure 11. Homodigital anterograde neurovascular flap.

improved by releasing the pedicle down to the base of the finger. Brunner or hemi-Brunner incisions are then performed to avoid scar contractures in the future.

A full-thickness skin graft is hardly ever necessary to cover the donor site.

A splint is advisable in the first week to prevent tension of the pedicle; the MCP joints should be kept flexed and the DIP and PIP joints extended. Hand physiotherapy is paramount to fully recover function.

This flap is not suitable for patients with peripheral vascular disease or in digits nourished by a single vessel.

6.5.3. Homodigital quadrangular flap

Described in 1966 by Hueston [14], this flap is meant to be advanced and rotated to reach the defect. It is based on one of the neurovascular pedicles and is eligible for transverse defects. Further dissection of the pedicle down to the base of the finger is not performed (**Figures 13 and 14**).

The island paddle is outlined at the midaxial lateral line of the less affected side, or in case of a complete transverse amputation, the lateral line transected will correspond to the nondominant side. Therefore, this flap will be based on the dominant neurovascular pedicle. The flap is elevated and the tendon sheath will be left intact. The flap will then be advanced and rotated to cover the area of defect.

The proximal end will be closed in a V to Y fashion or with a skin graft if needed.

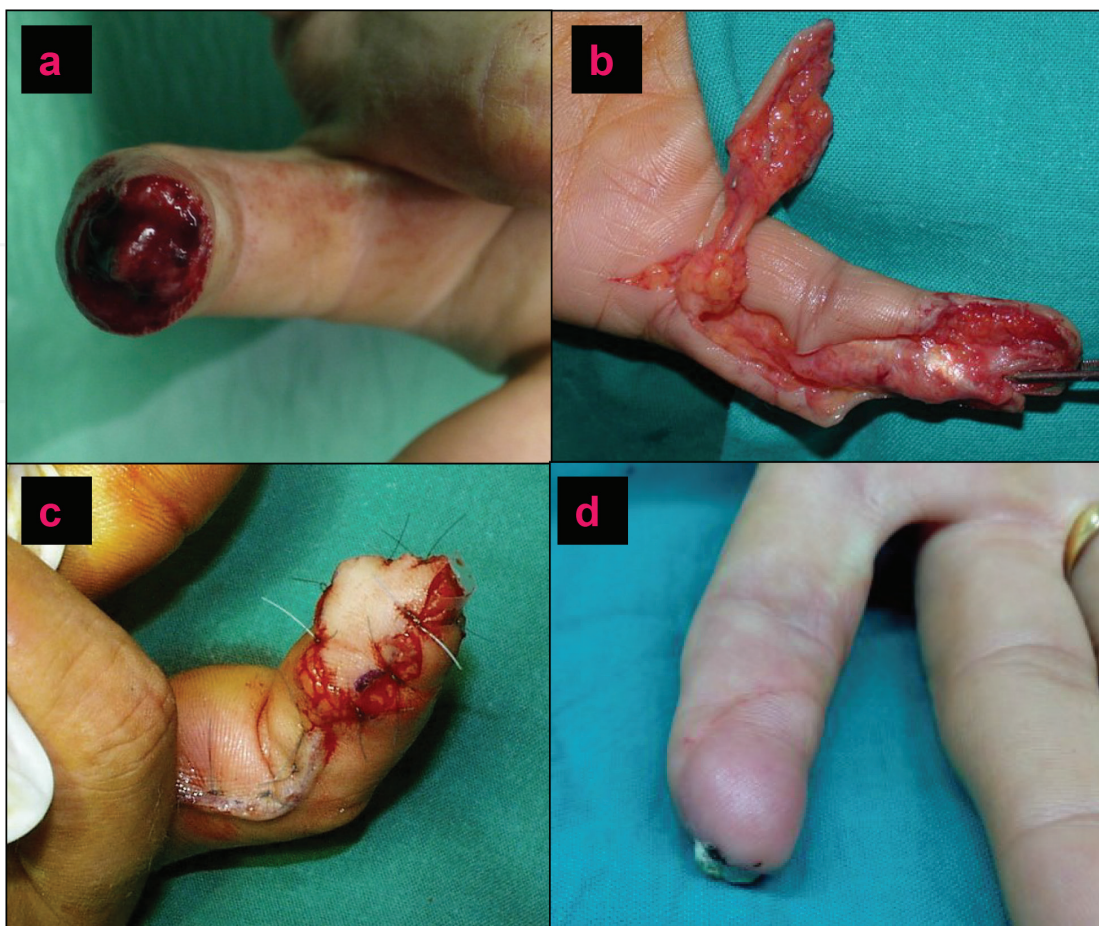


Figure 12. Clinical case of a homodigital anterograde neurovascular flap: (a) distal amputation, (b) flap dissection, (c) result at the end of the surgery and (d) the final outcome.

6.5.4. Homodigital neurovascular retrograde unipedicled flap

Described by Lai [15] in 1989, this flap is outlined on the lateral nondominant border of the base of the affected digit. The availability of the skin paddle is larger than the one for the anterograde flap (**Figure 15**).

Elevation is carried out from proximal to distal until enough length of the pedicle is obtained. The vascularity of this flap is dependent on transverse commissural arteries found at the PIP and DIP joints. Therefore, dissection should not proceed more than 1 cm proximal to the DIP joint. During dissection the proper digital nerve (PDN) is gently separated from the vascular pedicle, and the digital vessel is ligated proximally. The artery must be raised along with a cuff of fat and again never skeletonised the pedicle.

A full-thickness skin graft is used to close the secondary defect at the donor site.

The flap described is a non-sensate flap, and the PDN is left buried under a skin graft, which in some cases may be the cause of scar donor site dysaesthesias.

A retrograde sensate flap has also been described, including the PDN along with the artery. Once the flap reaches the defect, the nerve needs to be sutured to the amputated contralateral nerve in order to achieve sensation.

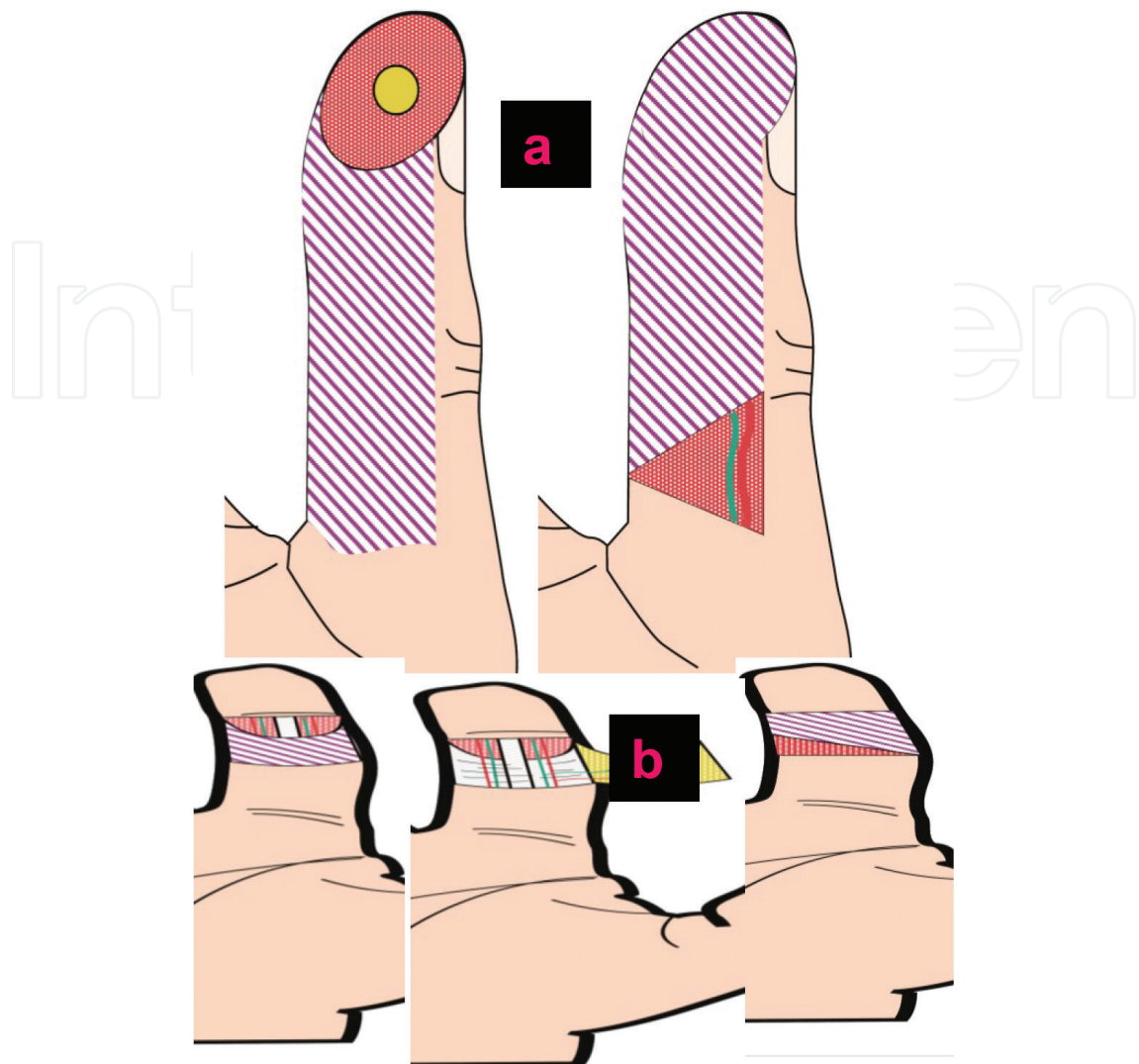


Figure 13. Hueston's flap: (a) schema of the flap for a thumb defect and (b) schema of the flap for a triphalangeal finger.

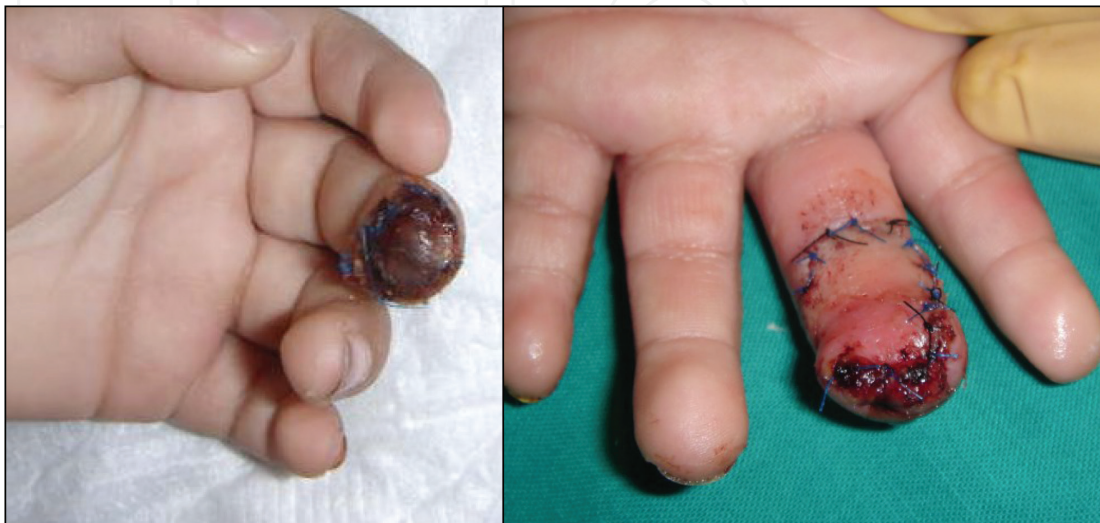

Figure 14. Clinical case of homodigital quadrangular flap after necrosis of the tip of the middle finger.

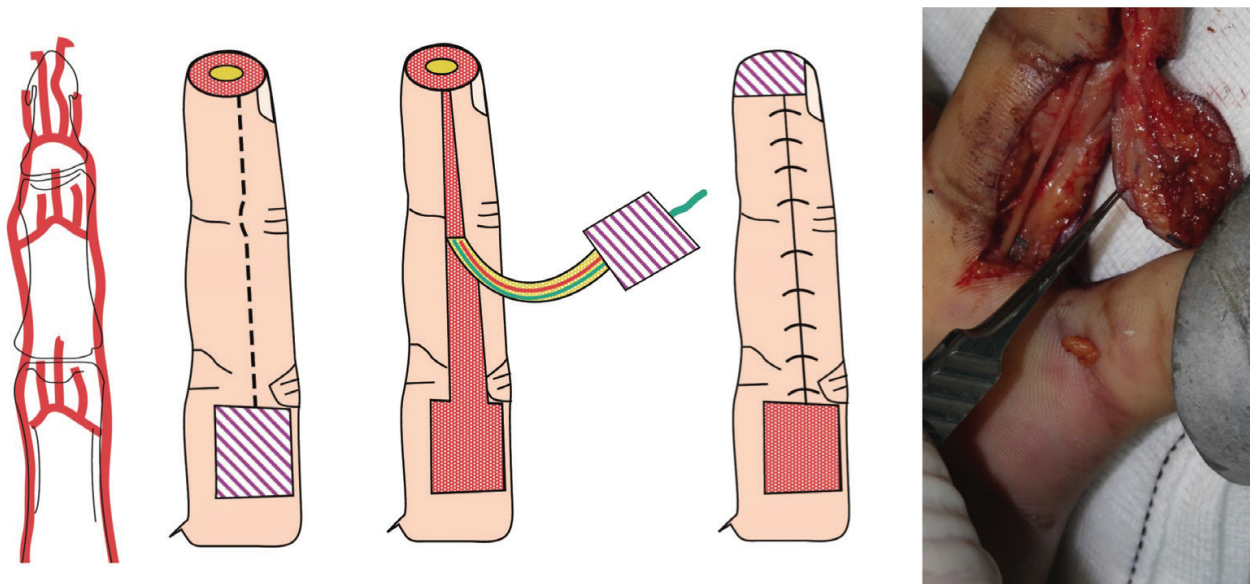


Figure 15. Homodigital retrograde neurovascular flap. The vascular connections of the proper palmar digital arteries are represented on the left image.

The main drawback is the fact that the stump of the donor nerve might turn into a neuroma and neuralgic pain may be quite invalidating.

6.5.5. Homodigital bipediced island flap for the thumb

Moberg [16] first described this flap in 1964, which consisted of undermining of the volar skin from the dorsal aspect along the midaxial lines of the thumb, starting proximal to the defect. The quadrangular advancement of the volar skin includes the two proper digital arteries and nerves. The arterial supply of the thumb differs from other fingers. Whereas the volar side of the thumb is supplied by two palmar collateral arteries which are branches of the princeps pollicis artery, the dorsal skin is predominantly supplied by ulnar and radial dorsolateral arteries and branches of the dorsal branch of the radial artery. Due to this particular vascularity, this flap can be raised to cover distal defects of the thumb but can potentially cause dorsal skin necrosis in triphalangeal fingers. The IP joint of the thumb should be kept flexed at 15–20° for a week, and later on hand physiotherapy is advised (**Figure 16**).

O'Brien [17] modified this flap in order to avoid flexion contractures. He added a skin incision distal to the MCP fold. Both pedicles are visualised and left intact with surrounding the subcutaneous tissue. This technique allows further advancement of the flap. A graft is then placed to cover this secondary defect.

6.5.6. Homodigital unipedicle retrograde island flap for the thumb

This flap was described by Brunelli [18]. The skin paddle is designed over the dorsoulnar aspect of the first metacarpal distal to the emergence of the dorsal branch of the radial artery in the first webspace. Dorsoulnar and dorsoradial arteries for the thumb branch out directly from the radial artery or from the first dorsal interosseous artery. This axial flap carries the

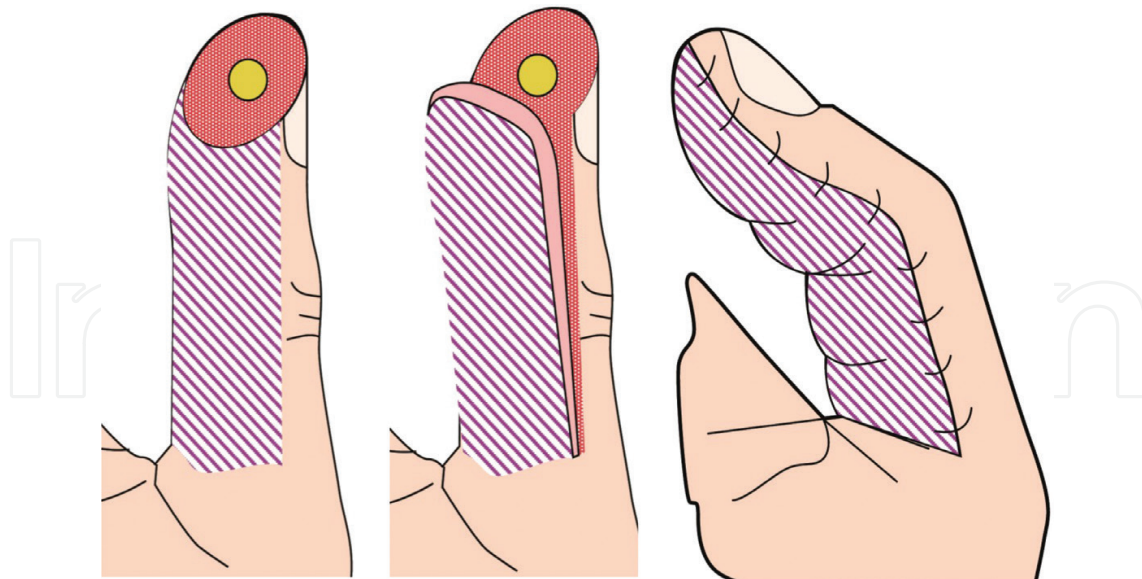


Figure 16. Möberg's flap.

dorsoulnar branch of the thumb which anastomoses with the thumb proper ulnar artery at the neck of the proximal phalanx. The dorsoulnar artery needs to be ligated proximal to the island paddle, and dissection is performed from distal to proximal (Figures 17 and 18).

The flap can potentially include radial sensory branches found near the dorsoulnar branch which can then be sutured to the proper digital nerve to attempt a sensate type of flap. Otherwise, this flap will not provide sensation to the tip of the thumb.

A similar flap has been described based on the dorsoradial artery of the thumb [19]. However, the dorsoulnar branch is considered more dominant and constant.

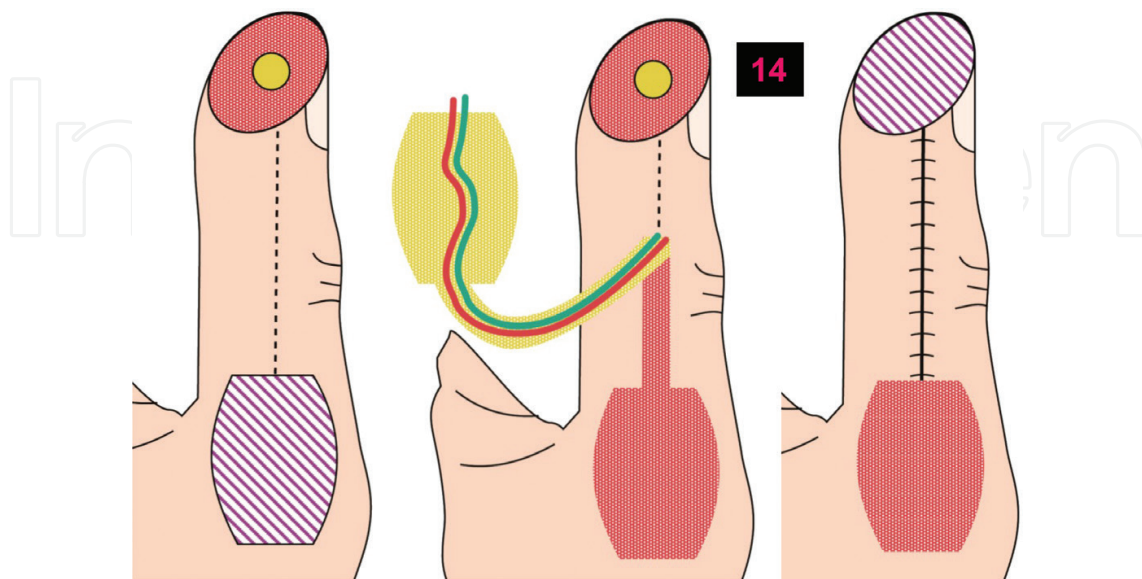


Figure 17. Brunelli's flap.

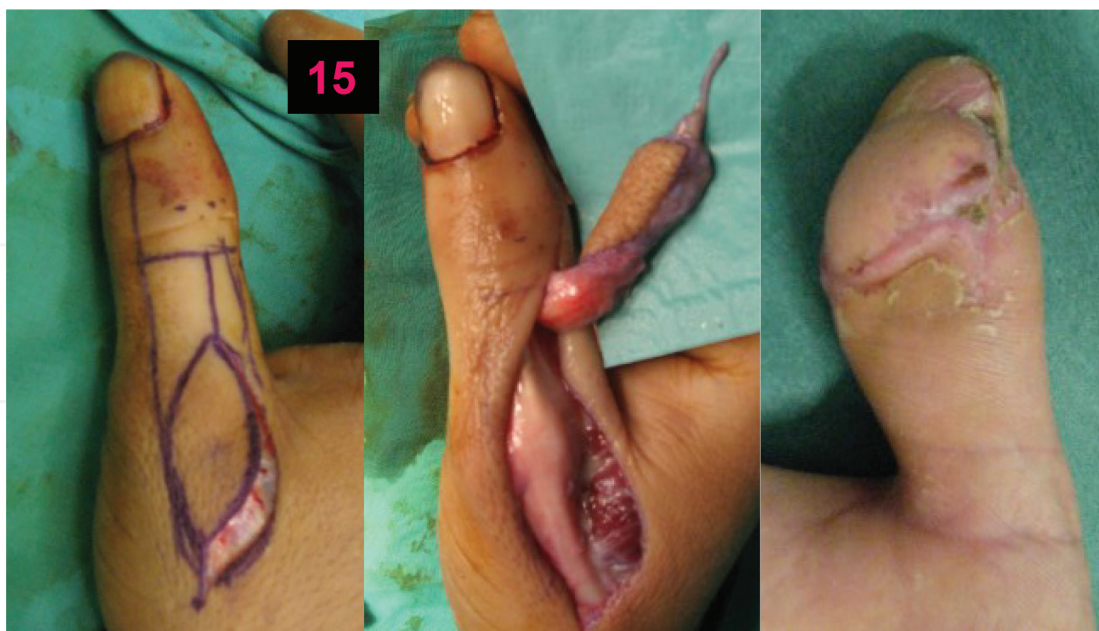


Figure 18. Clinical case of homodigital dorsoulnar retrograde flap for the tip of the thumb.

Cavadas [20] described a modification that included a small portion of the first metacarpal diaphysis. This was presented as an option for complex injuries with a severe bone defect at the distal phalanx.

6.6. Heterodigital flaps

6.6.1. Littler neurovascular island flap

Currently, this type of reconstruction has lost popularity. The previously described antero- grade homodigital flaps and microsurgical procedures such as toe to pulp transfer have limited its use. It is still interesting in case of a spare skin paddle and corresponding neuro-vascular pedicle of an otherwise nonsalvageable digit. This can then be used to reconstruct other injured digits but mainly for thumb reconstruction (**Figure 19**).

The selected donor site is the ulnar aspect of the middle and ring fingers. The skin paddle is marked; it extends from the volar midline until the dorsal midline. The pedicle dissection must be continued until the superficial palmar arch has been reached. A cuff of perivascular tissue needs to be preserved; after releasing the natatory fibres of the palmar fascia, the proper digital artery of the adjacent finger is ligated at the bifurcation of the common palmar digital artery, and the dissection of the pedicle is then accomplished up to the superficial arch. Brunner and hemi-Brunner types of incisions in both zone II and zone III have to be done in order to reach the proper pedicle length. The island flap has to be transferred without tension, kinking or compression through a subcutaneous tunnel to the thumb.

The sensory integration of the flap is variable, and the older the patient is, the less recognition will take place. However, this is not essential to reach adequate function.

The donor site needs skin grafting.

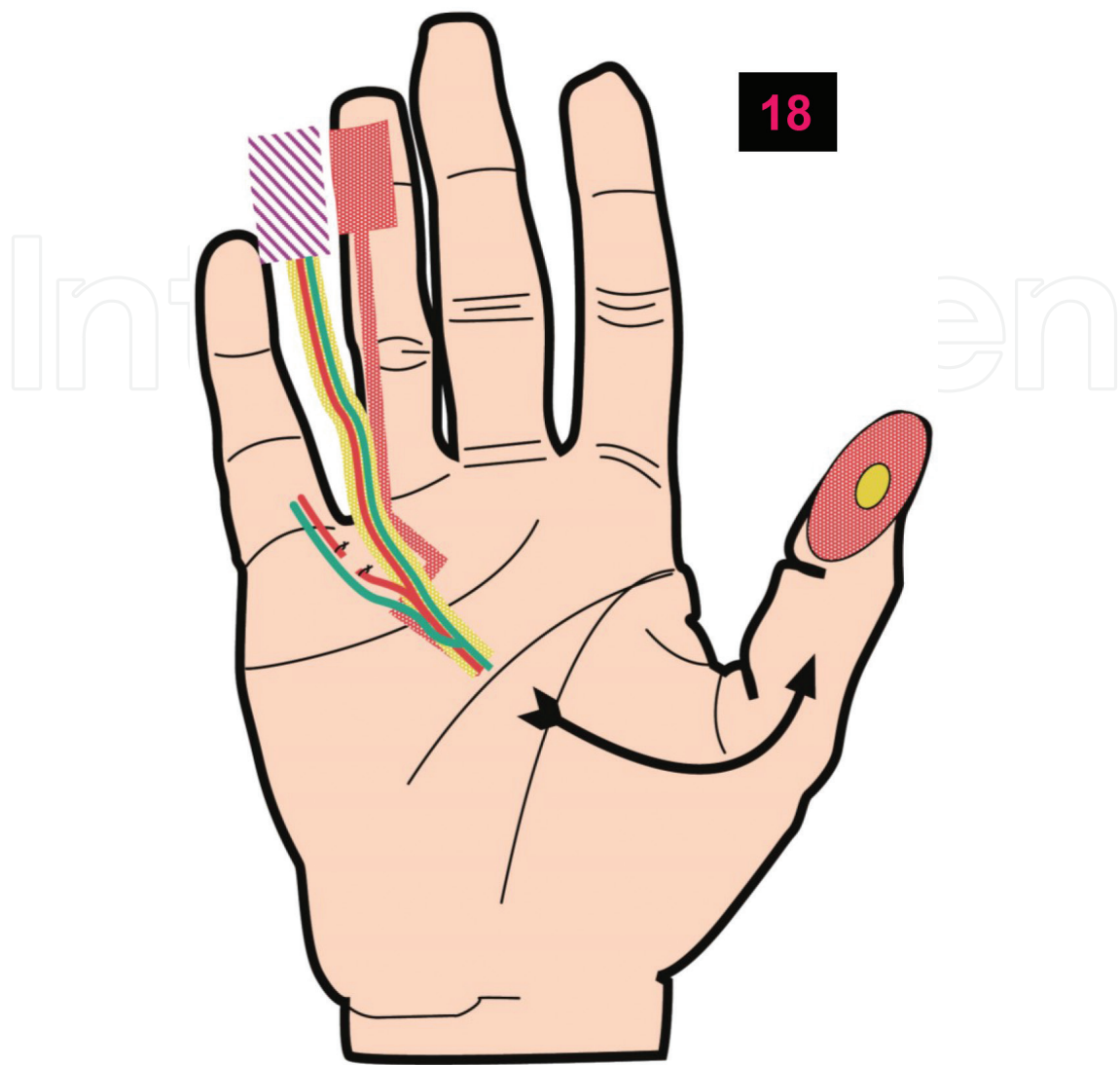


Figure 19. Littler's flap and heterodigital hemipulp neurovascular flap.

6.7. Metacarpal artery island flaps

6.7.1. First dorsal metacarpal artery flap

The so-called cerf-volant was described by Foucher and Braun [21] and has been considered the main workhorse in thumb reconstruction (**Figures 20** and **21**).

Based on the first dorsal metacarpal artery (FDMA), which is a branch of the dorsal radial artery of the hand, it courses parallel to the first metacarpal bone and superficial to the first dorsal interosseous muscle fascia although some fibres may cover the vessel at its course. The FDMA has vascular connections with the PDA at the level of the metacarpal neck.

The island paddle is outlined at the dorsal skin of the proximal phalanx. It extends from the PIP joint to the MCP joint. Laterally, it can extend from the radial midline to the ulnar midline of the finger. Dissection has to be carried out subfascially in order not to damage the pedicle.

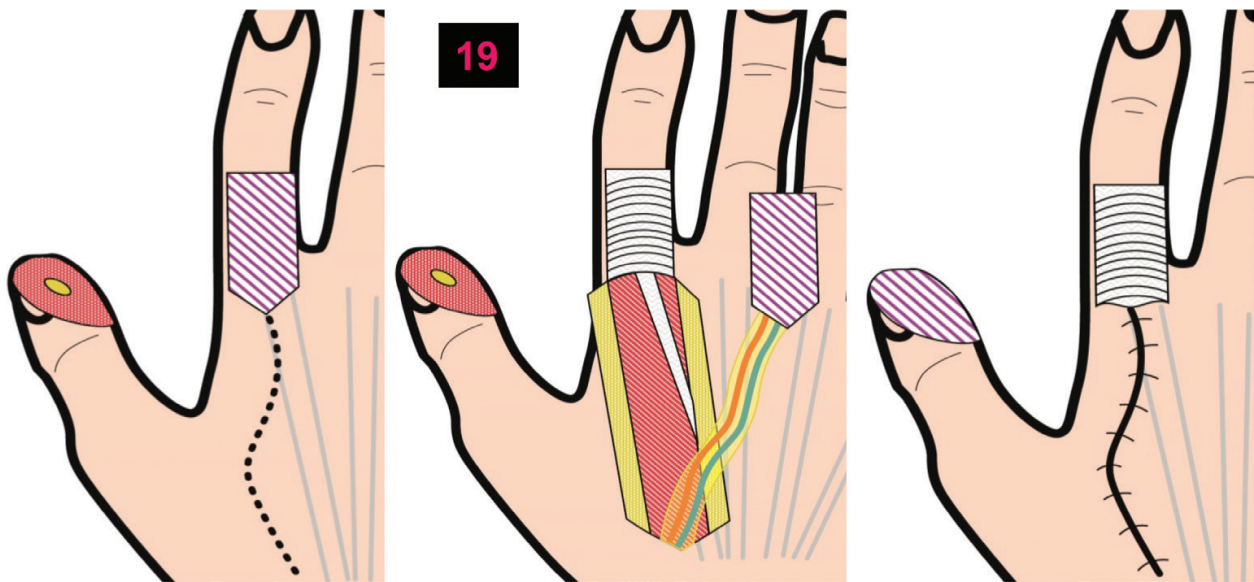


Figure 20. Cerf-volant Foucher's flap, based on the first dorsal interosseous artery.

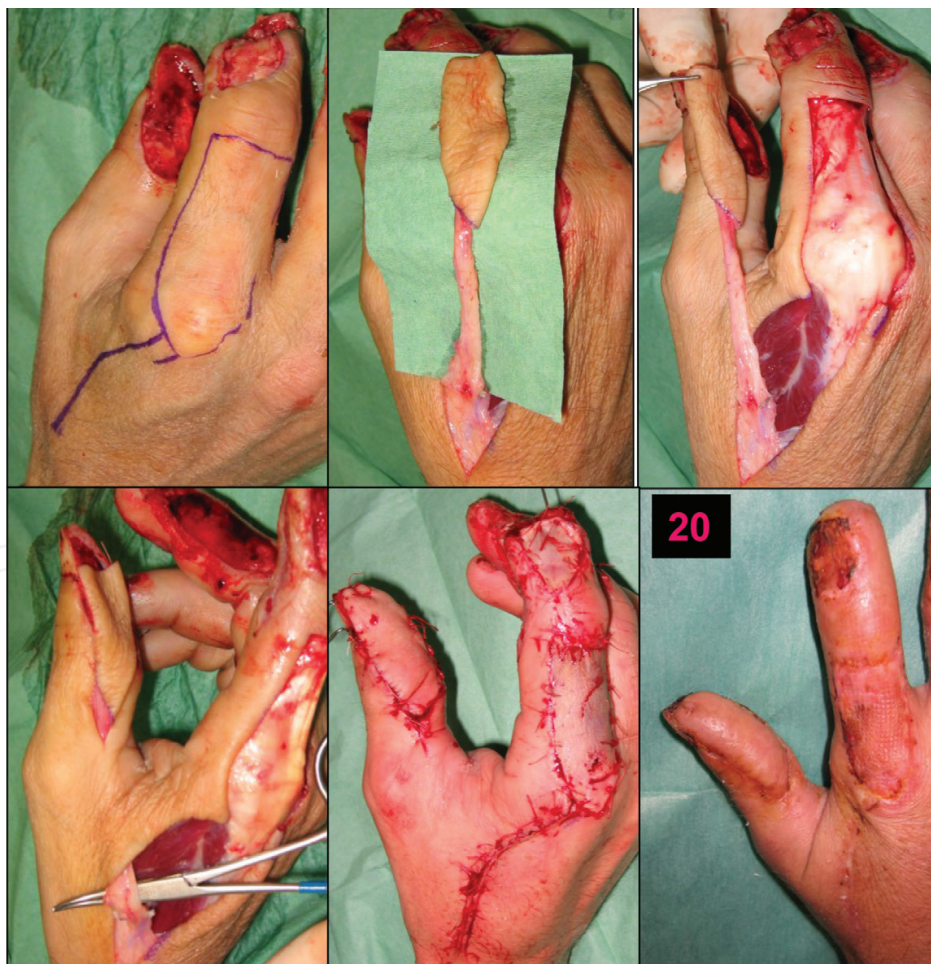

Figure 21. Clinical case of a defect of the tip of the thumb treated with a Foucher's flap.

A lazy S incision is performed from the MCP joint to the anatomic snuffbox. The pedicle is then released until its emergency at the dorsal radial artery. Subcutaneous veins and sensory branches of the radial nerve are identified and can be included in the flap.

A tunnel is dissected from the first interosseous webspace to the defect at the tip of the thumb, and the flap and its pedicle are transferred and sutured. The pedicle must not be compressed under the tunnel, and the flap should be sutured tension-free.

6.7.2. Reverse-flow dorsal metacarpal flaps

The dorsal metacarpal arteries (DMA) are branches of the dorsal arch supplied by the radial artery. They course underneath the extensor tendons, included in the epimysial lining of the dorsal interosseous muscles (**Figures 22 and 23**).

Due to the vascular connections with the deep palmar arch through recurrent cutaneous branches, this flap can be raised retrogradely. These connections are found distal to the juncturae tendinum.

Early and Milner [22] developed a reverse-flow island flap, based on the dorsal metacarpal arteries. This flap includes the whole course of the metacarpal artery; at the proximal end, the artery is ligated. The dissection must leave the peritenon of the extensor tendon intact

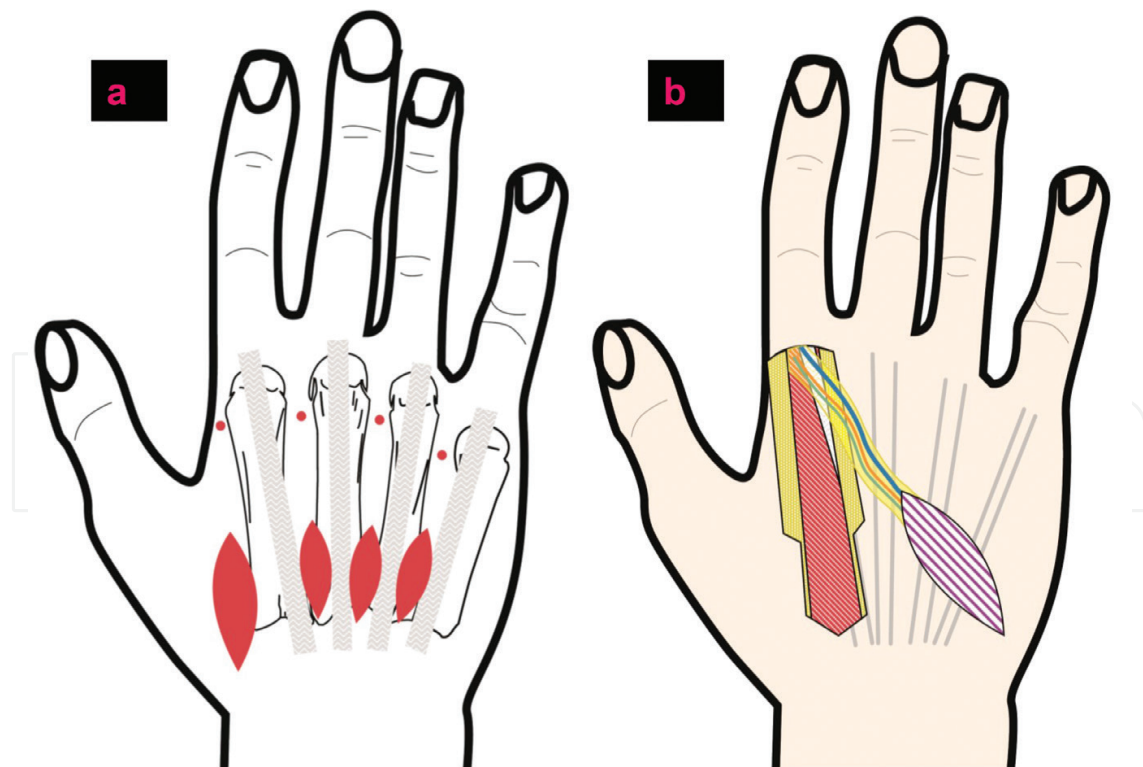


Figure 22. Dorsal metacarpal flaps of reverse flow: (a) position of the skin paddles (ellipses) and pivotal points (red dots); (b) the pedicle includes the fascia of the dorsal interosseous muscle.

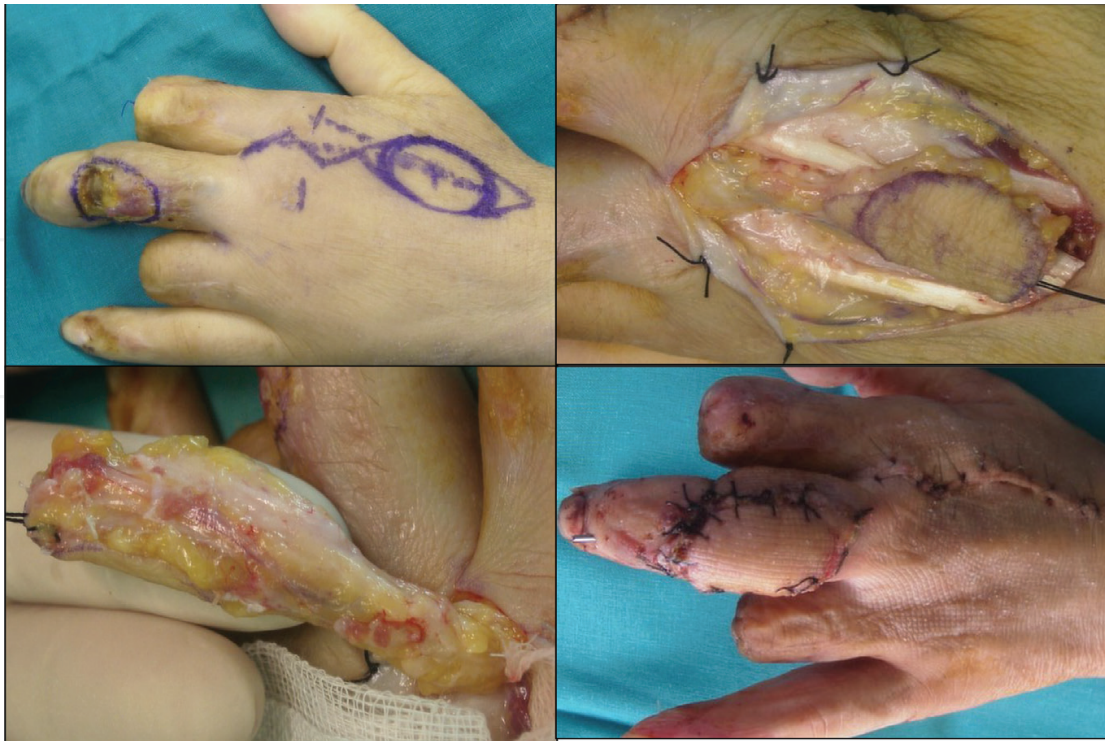

Figure 23. Clinical case of skin defect on the proximal interphalangeal joint of the middle finger; the second dorsal metacarpal artery flap is performed.

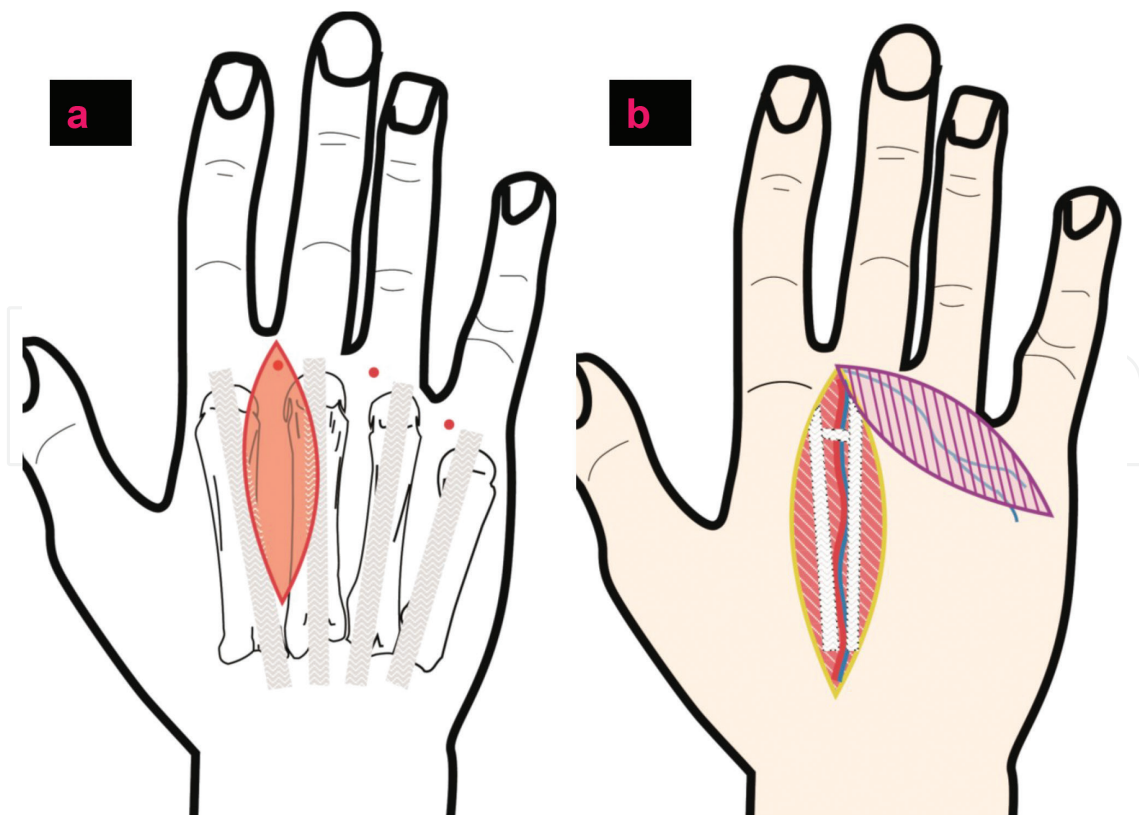


Figure 24. Quaba Davison's flaps: (a) location of the skin paddles (ellipses) and pivotal points (red dots); (b) the flap does not include the fascia of the dorsal interosseous muscle, and the pivotal point is immediately distal to the juncturae tendinum.

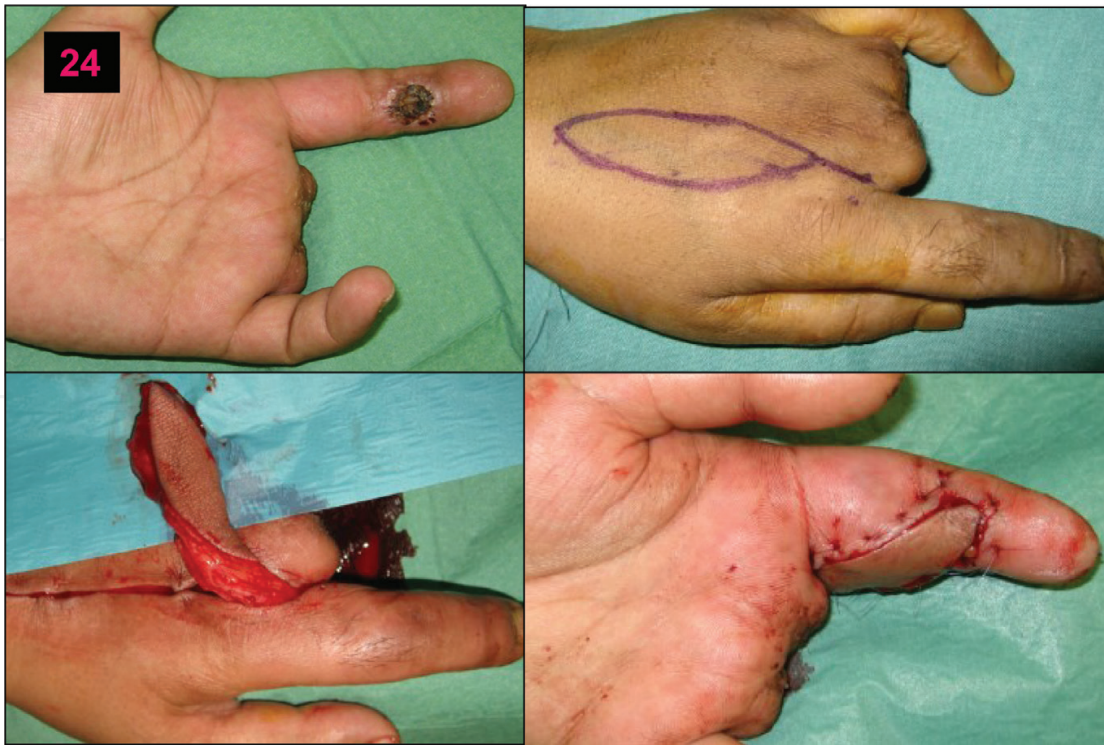

Figure 25. Clinical case of a volar defect at the medial phalanx: a Quaba Davison's flap was used since many of the adjacent digits had been amputated.

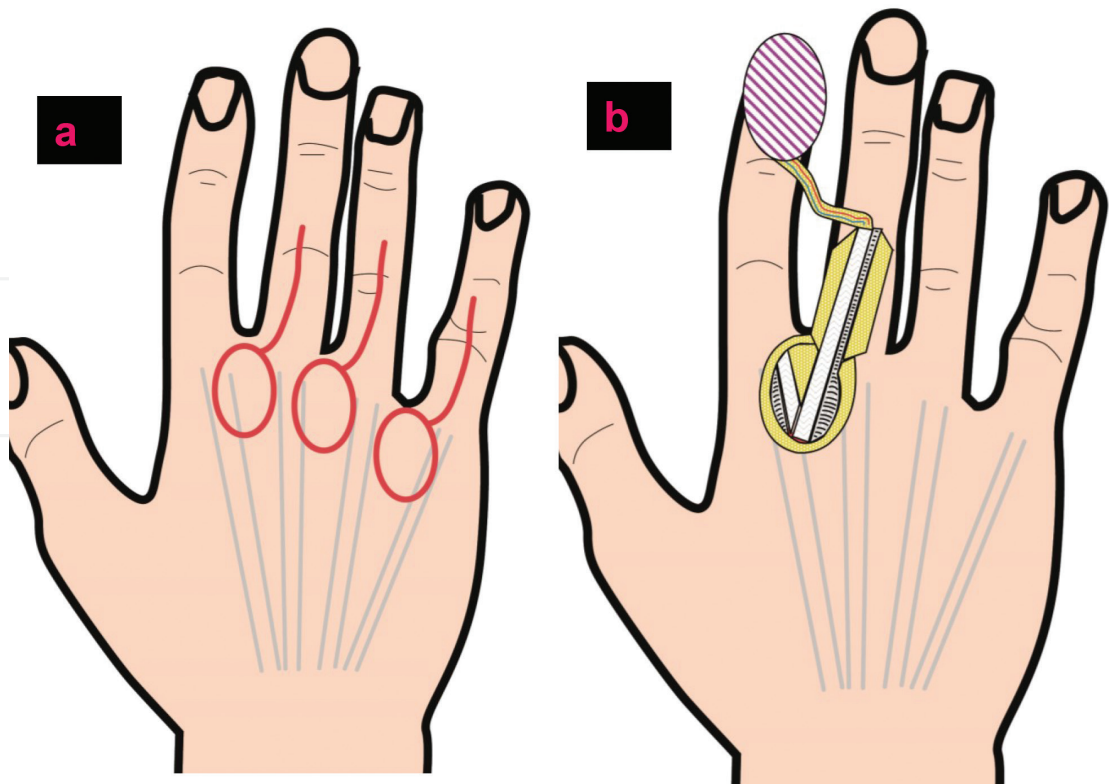


Figure 26. Dorsal commissural flaps: (a) location of the skin paddles (ellipses); (b) the flap reaches the distal interphalangeal joints and the distal phalanx.

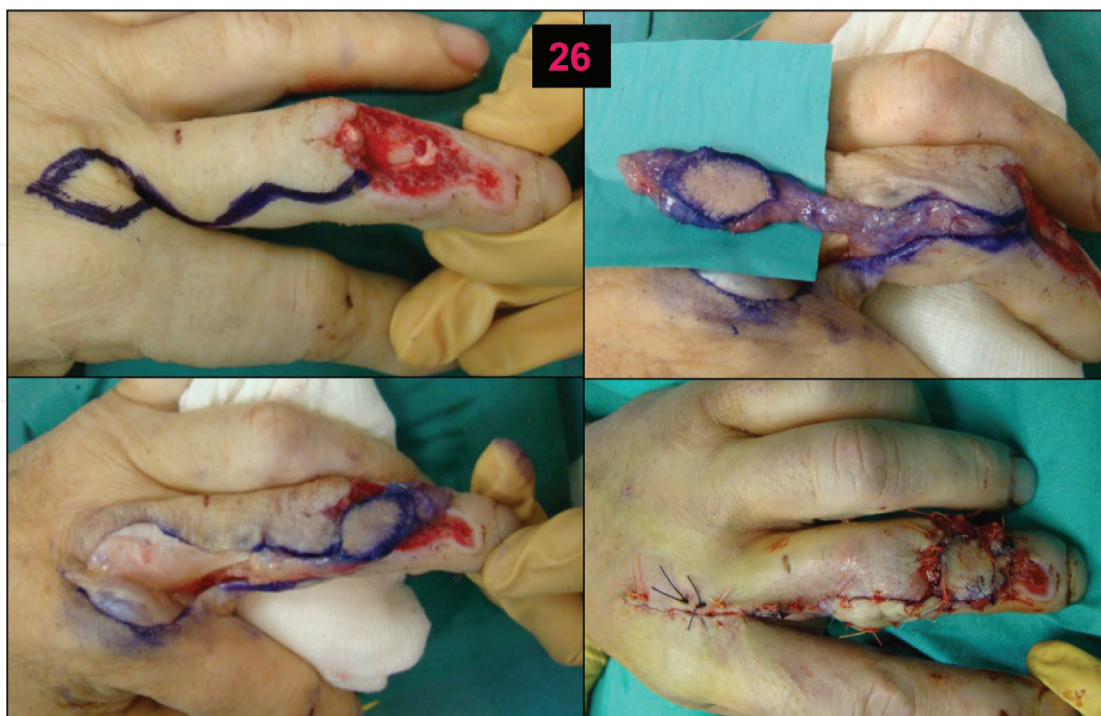

Figure 27. Clinical case of soft tissue defect on the medial phalanx where a dorsal commissural flap was obtained.

and include the interosseous fascia. The juncturae must be released, and dissection has to end at the level of the metacarpal neck. Dorsal sensory branches and possible veins must be included in the flap. The island paddle extends from the MCP joint to the wrist crease. The arc of rotation of this flap (180°) allows the coverage of the proximal phalanx and PIP joint up to the middle phalanx.

Quaba and Davidson [23] described the same flap without incorporating the DMA (**Figures 23 and 24**). Dissection of the flap proceeds suprafascially, and it is based only on the recurrent cutaneous branch. The flap can also extend from the MCP joint to the wrist crease. The flap is then easier to elevate and provides a thinner coverage (**Figures 25 and 26**).

Eventually, anatomic studies confirmed the existence of vascular connections at different levels of the proximal phalanx and medial phalanx between the PDA and cutaneous branches of the DMA. Karacalar and Özcan [24] described a modified version of this flap based on these anatomic findings. This is a reverse-flow flap with the skin paddle outlined on the second and third webspaces (**Figure 27**). The arc of rotation reaches the distal phalanx, and the pivot point is found at the neck of the proximal phalanx (**Figures 25 and 26**).

7. Summary

Local hand flaps offer excellent coverage of soft tissue loss when a skin graft is not eligible and when the defect is small or moderate.

The knowledge of the neurovascular anatomy is paramount in order to understand and perform these flaps.

Most local flaps provide adequate sensation and cosmesis using locoregional skin. However, local flaps obviously have limited indications, and larger or complex cases need a microsurgical approach instead of or even further amputation if considered nonsalvageable. Surgeons should recognize which indication is correct in every case.

Author details

Francisco Martinez Martinez^{1*}, M. Llanos Guerrero Navarro², Juan Garcia Navarro¹, Alberto Gimenez Ros¹ and Alba Izquierdo Robledano¹

*Address all correspondence to: fmtnez@gmail.com

1 Hospital Universitario Virgen de la Arrixaca, Murcia, Spain

2 Hospital General Universitario Santa Lucia, Cartagena, Murcia, Spain

References

- [1] Littler JW. Neurovascular pedicle transfer of tissue in reconstructive surgery of the hand. *The Journal of Bone and Joint Surgery. American Volume*. 1956;**38**:917
- [2] Lister GD, Gibson T. Closure of rhomboid skin defects: The flaps of Limberg and Dufourmentel. *British Journal of Plastic Surgery*. 1972;**25**(3):300-314
- [3] Foucher G, Braun JB. A new island flap transfer from the dorsum of the index to the thumb. *Plastic and Reconstructive Surgery*. 1979;**63**(3):344-349
- [4] Yang G, Chen B, Gao Y. The forearm free skin flap transplantation. *National Medical Journal of China*. 1981;**61**:139
- [5] Medalie DA. Perforator-based forearm and hand adipofascial flaps for the coverage of difficult dorsal hand wounds. *Annals of Plastic Surgery*. 2002;**48**(5):477-483
- [6] Orbay JL, Rosen JG, Khouri RK, et al. The glabrous palmar flap: The new free or reversed pedicled palmar fasciocutaneous flap for volar hand reconstruction. *Techniques in Hand & Upper Extremity Surgery*. 2009;**13**(3):145-150
- [7] Zancolli EA, Angrigiani C. Posterior interosseous island forearm flap. *Journal of Hand Surgery British*. 1988;**13**(2):130-135
- [8] Bertelli JA, Pagliei A. The neurocutaneous flap based on the dorsal branches of the ulnar artery and nerve. A new flap for extensive reconstruction of the hand. *Plastic and Reconstructive Surgery*. 1998;**101**(6):1537-1543

- [9] Cronin TD. The cross finger flap: A new method of repair. *The American Surgeon*. 1951; **17**(5):419-425
- [10] Tranquilli-Leali E. Reconstruzione del apice falangi vaguali mediante autoplástica volare pedunculata per scorimento. *Infort Traum Lavoro*. 1935;**1**:186-193
- [11] Atasoy E, Ioakimidis E, Kasdan ML, et al. Reconstruction of the amputated finger tip with a triangular volar flap. *Journal of Bone and Joint Surgery*. 1970;**52**:921-926
- [12] Kutler W. A new method for fingertip amputation. *Journal of the American Medical Association*. 1947;**133**(1):29-30
- [13] Venkataswami DR, Subramanian N. Oblique triangular flap: A new method of repair for oblique amputations of the fingertip and thumb. *Plastic and Reconstructive Surgery*. 1980;**66**(2):296-300
- [14] Hueston JT. Local flap repair of fingertip injuries. *Plastic and Reconstructive Surgery*. 1966;**37**(4):349-350
- [15] Lai CS, Ling SD, Yang CC. The reverse digital artery flap for fingertip reconstruction. *Annals of Plastic Surgery*. 1989;**22**(6):495-500
- [16] Moberg E. Aspects of sensation in reconstructive surgery of the upper extremity. *The Journal of Bone and Joint Surgery*. American Volume. 1964;**46**:817-825
- [17] O'Brien B. Neurovascular island pedicle flaps for terminal amputations and digital scars. *British Journal of Plastic Surgery*. 1968;**21**(3):258-261
- [18] Brunelli F, Vigasio A, Valenti P, Brunelli GR. Arterial anatomy and clinical application of the dorsoulnar flap of the thumb. *Journal of Hand Surgery*. 1999;**24**(4):803-811
- [19] Bakhach J, Sentucq-Rigal J, Mouton P, Boileau R, Panconi B, Guimberteau JC. The dorso-radial flap: A new flap for hand reconstruction. Anatomical study and clinical applications. *Annales de Chirurgie Plastique et Esthétique*. 2006;**51**(1):53-60
- [20] Cavadas P. Reverse osteocutaneous dorsoulnar thumb flap. *Plastic and Reconstructive Surgery*. 2003;**111**(1):326-329
- [21] Foucher G, Braun J. A new island flap transfer from the dorsum of the index to the thumb. *Plastic and Reconstructive Surgery*. 1979;**62**(3):344-349
- [22] Early MJ, Milner RH. Dorsal metacarpal flaps. *British Journal of Plastic Surgery*. 1987; **10**:333-341
- [23] Quaba AA, Davidson PM. The distally-based dorsal hand flap. *British Journal of Plastic Surgery*. 1990;**43**(1):28-39
- [24] Karacalar A, Özcan M. A new approach to the reverse dorsal metacarpal artery flap. *Journal of Hand Surgery American*. 1997;**22**(2):307-310