

We are IntechOpen, the world's leading publisher of Open Access books Built by scientists, for scientists

4,800

Open access books available

122,000

International authors and editors

135M

Downloads

Our authors are among the

154

Countries delivered to

TOP 1%

most cited scientists

12.2%

Contributors from top 500 universities



WEB OF SCIENCE™

Selection of our books indexed in the Book Citation Index
in Web of Science™ Core Collection (BKCI)

Interested in publishing with us?
Contact book.department@intechopen.com

Numbers displayed above are based on latest data collected.
For more information visit www.intechopen.com



New Horizons in Regenerative Medicine in Organ Repair

Paramjit Singh Dhot and Mayurika S. Tyagi

Additional information is available at the end of the chapter

<http://dx.doi.org/10.5772/intechopen.74241>

Abstract

Regenerative medicine is a scientific field that focuses on new approaches in the autologous repair and/or replacement of cells, tissues and/or organs. With time and technical advancements, urethral regeneration, corneal and retinal regeneration, genetically modified skin transplantation has become routine clinical and tissue reconstructive art only due to successful clinical use of stem cells and engineered tissue grafting at defined locations in respective organs in order to bring back the natural or improved physiological functions with enhanced capacity. The tissue engineering and reconstructive art are becoming integral part of the regenerative medicine. This chapter highlights the importance of regenerative medicine in successful tissue reconstruction for organ transplantation.

Keywords: regenerative medicine, urethral defects, bronchomalacia, limbal stem cells, skin transplants, amniotic stem cells, corneal and retinal stem cells

1. Introduction

There have been exponential advances in the field of tissue engineering and regenerative medicine (TERM). There is an active and progressive focus of research to study the mechanisms of injury and how they interface and activate endogenous progenitor cell populations and with a particular focus on elucidating how progenitor cells interact with cells of the immune system. A lot of work has focused on identifying precisely which pool of stem cells actively participates in endogenous repair/regeneration processes.

Human embryonic stem cells have an endless capacity to divide, offer an unlimited source of cells, are capable of becoming any type of cell, and can be differentiated in the laboratory.

The use of hESC-derived cells is an attractive treatment approach, in fact, for many different diseases because transplanted cells may be able to react to changing conditions in the micro-environment, which is an important biological process.

In the biomaterial area of regenerative medicine, much attention has been paid to the advancement of material design through the promotion of endogenous stem cell differentiation toward a specific phenotype of interest by modulating physical attributes of the scaffold (including stiffness, topography and porosity). Advanced materials that select refined populations and direct their differentiation may provide a mechanism to achieve improved *in vivo* regeneration.

This chapter presents the current state of the art on identifying organ defects, applying feasibility testing of regenerative host-progenitor cell interactions and finally, assessment of endogenous repair or reconstructed urethra, cornea, bronchi, retina, skin, foetal tissues with a possibility of engineered tissue transplants widely used in routine clinical practice.

2. Clinical success in tissue reconstruction

2.1. Urethral reconstruction for large ureteral defects

In an interesting research area, a tissue engineering approach was used to restore function in a small group of boys with large urethral defects. Biopsies of bladder tissue were obtained, and smooth muscle and epithelial cells were isolated and cultured. The cells were then seeded onto tubular poly(glycolic acid)-poly(lactic-co-glycolic acid) scaffolds. Following culture for 1 week to ensure cell viability and matrix production, grafts were used for urethral reconstruction. The authors report that all five patients maintained functional flow rates at 36–72 months post-implantation, and biopsies confirmed that tissue organisation is similar to the native tissue.

2.2. Autologous limbal stem cells in corneal damage

Autologous stem cell therapy has been used to reverse corneal destruction due to burns. In one study, autologous limbal stem cells were cultured on fibrin to treat corneal damage in over 100 patients. At 10 years of follow-up, more than 75% of patients had a restored corneal epithelium layer. Clinical success was correlated to the percentage of functional stem cells (holoclone-forming) observed in the culture. Specifically, if cultures contained more than 3% holoclone-forming cells, clinical success was found in 78% of patients. On the other hand, if less than 3% holoclone-forming cells were found, success was seen in only 11% of the patients. This chapter elucidates the potential for limbal stem cells for corneal repair.

2.3. Platelet-rich plasma in orthopaedic sports injuries

Currently, use of platelet-rich plasma (PRP) to treat orthopaedic sports injuries is showing promise in this area. Several randomised control trials are underway, and early results have been recently published. Peerbooms *et al.* first reported the beneficial effects of PRP over corticosteroid injections for the treatment of lateral epicondylitis in a double-blind RCT. At 1 year, marked improvements were seen in both patient-reported outcomes as well as functional scores, and more recent data suggest these results persist up to 2 years.

2.4. Tissue engineered airway

A 30-year-old woman with end-stage bronchomalacia was transplanted with a tissue-engineered airway. Cells and MHC antigens were removed from human donor trachea and then colonised by epithelial cells, and mesenchymal stem cell-derived chondrocytes were taken from the recipient. This graft was then used to replace the recipient's left main bronchus. The graft immediately provided the recipient with a functional airway, improved her quality of life and had a normal appearance and mechanical properties at 4 months. The patient had no anti-donor antibodies and was not on immunosuppressive drugs. This case suggested that autologous cells combined with appropriate biomaterials might provide successful treatment for patient with serious clinical disorders (**Figure 1**) [1].

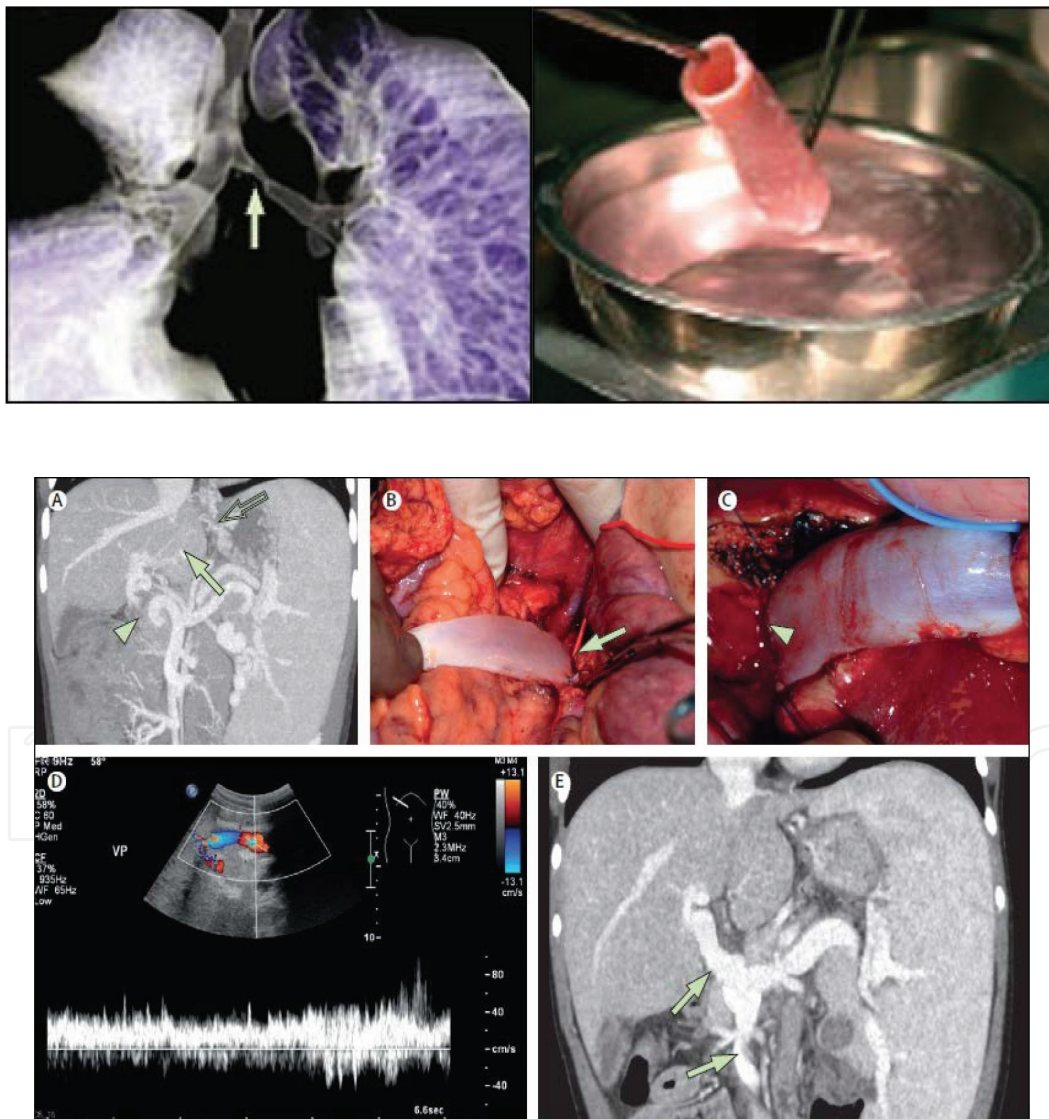


Figure 1. (A) Diagnostic CT angiography of intrahepatic portal flow (arrow), collaterals feeding the portal vein but no external portal vein in continuity (arrowhead) and enlarged spleen and collaterals around the oesophagus and in the liver hilum (open arrow). (B and C) Surgical correction showing graft attachment to the superior-mesenteric vein (arrow) and left portal vein (arrowhead). (D) Perioperative ultrasound with blood flows of 25–40 cm/s in the graft and intrahepatic portal vein. (E) Angiography showing a patent graft (arrows) 1 week after the surgery (reconstruction of 3–4 CT scans).

2.5. Transplant of genetically modified skin

Recently, Dr Michele De Luca, MD and his colleagues in Italy saved the life of a boy who had lost most of his epidermis by life-saving regeneration of virtually the entire epidermis. Patient's own epidermal stem cells were genetically modified to have functional copies of the gene that was mutant [2].

The boy was presented with blistered skin, which is the characteristic of junctional epidermolysis bullosa (JEB), and associated bacterial skin infections. Within days, about 60% of his epidermis had vanished. LAMB3 is one of three genes that encode a laminin protein that links the epidermis to the dermis.

The researchers cultured primary keratinocytes from a 4-cm² biopsy specimen from an unblistered area in the boy's left inguinal region. Then, they used retroviral vectors to introduce LAMB3 genes. The grafts grew. The genetic modification of those cells by introducing extra copies of the LAMB3 gene restored the epidermal machinery.

Three types of cultures grew into grafts from the boy's cells: holoclones, which are all stem cells; paraclones, which are specialised cells and meroclones, which are partly differentiated cells. The transgenic grafts harbour all three types of clones, but only the holoclones persist.

Procedures were done to cover the affected areas with genetically modified and regenerated grafts. The patches were up to several inches in diameter and were applied on a properly prepared wound bed. After engraftment, the epidermis looks basically normal, and that is also true at the molecular level in terms of the adhesion machinery that has been replaced. Within 5 weeks, the cells had covered about 80% of the boy's body. Even hairs grew, which usually does not happen with the conventional skin grafts. This case suggested that transgenic epidermal stem cells can regenerate a fully functional epidermis virtually indistinguishable from a normal epidermis, in the absence of related adverse events [2].

2.6. Amniotic-derived tissue grafts for enhanced skin regeneration

Amniotic tissues contain many regenerative cytokines, growth factors and extracellular matrix molecules, including proteoglycans, hyaluronic acid and collagens I, III and IV. Dehydrated amnion/chorion grafts are currently used to treat a variety of wounds such as diabetic foot ulcers and burns. In a recent study, Mowry et al. [3] found that all amniotic-derived tissue grafts appeared to stimulate improved healing over sham wounds (ungrafted wounds), evidenced by more normal appearing dermal matrix architecture, epidermal structure and maturity. In addition, the hypothermally stored amniotic membrane (HSAM) grafts promoted greater tissue regeneration than the dehydrated amnion/chorion (dHACM) meshed grafts, as measured by the presence of basket-weave collagen matrix and formation of follicles and glands (**Figures 2 and 3**).

Current studies point to several critical factors that may contribute to enhanced wound repair with amniotic-derived tissues including ECM, cytokines and growth factors, stem cells and

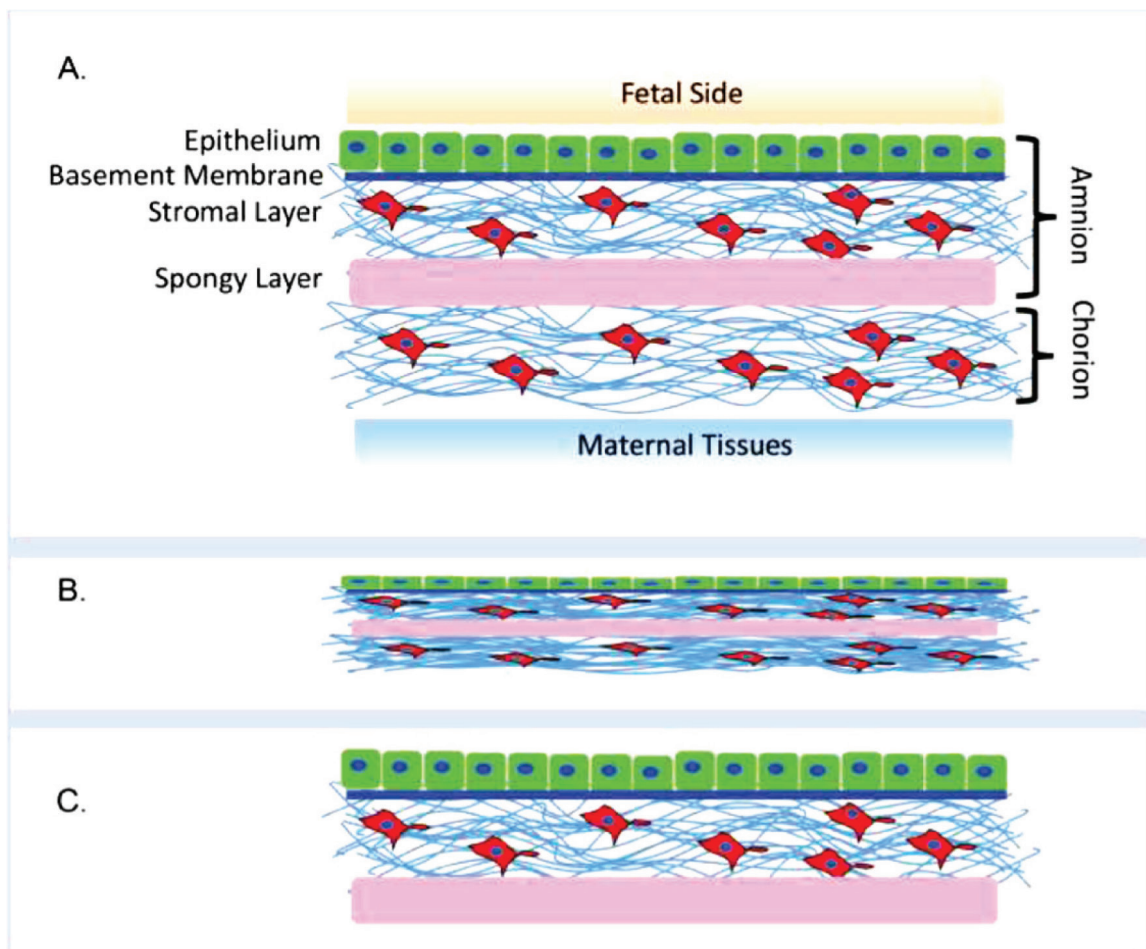


Figure 2. Schematic of the composition of amniotic-derived products. (A) Basic structure of native placental tissues outlining amniotic membrane, which interfaces with the foetus and major components such as epithelium, basement membrane, stromal layer and the spongy layer and the chorion which interfaces maternal tissues. Schematic of (B) dehydrated amnion/chorion and (C) hypothermically stored amniotic membrane.

immunomodulation of the wound environment [4]. This study highlights the importance of processing techniques and how they influence the quality of wound healing.

2.7. Stem cell therapy in retinal degeneration

Retinal pigment epithelial (RPE) cells derived from human embryonic stem cells can be safely transplanted into the eyes of the patients with retinal degeneration, with early signs of vision gain, according to pioneers in the field.

Two teams of researchers (Dr Eyal Banin from Israel and Dr. Ninel Z. Gregori from Florida) reported preliminary findings from phase 1 and phase 2 trials at the American Academy of Ophthalmology (AAO) 2017 Annual Meeting [5]. Patients had the dry form of age-related macular degeneration (AMD) or Stargardt disease and received injections of human embryonic stem cell (hESC)-derived RPE cells. Results of the studies are optimistic even though the

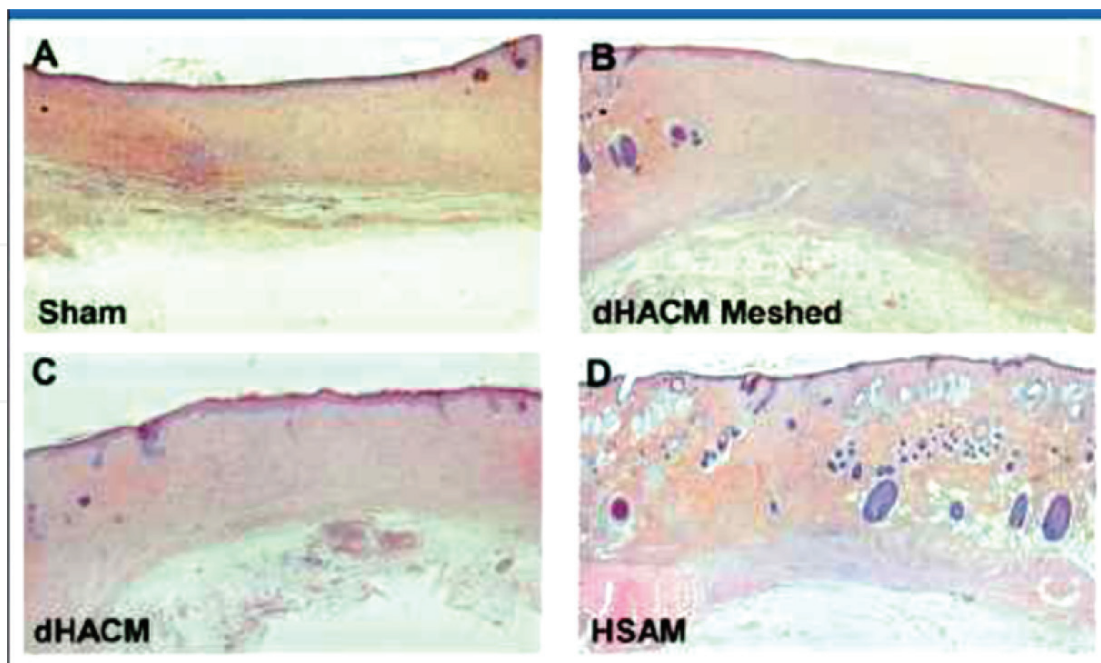


Figure 3. Twenty-one day representative histological sections: (A) sham; (B) dehydrated amnion-chorion (dHACM) meshed; (C) dHACM; and (D) hypothermically stored amniotic membrane (HSAM). Histologic summary: High-magnification images were used to assess the wounds qualitatively, and representative images are shown in this figure. Amniotic-derived grafts stimulated more robust healing and wound repair than sham wounds. Interestingly, HSAM-treated wounds displayed early epidermal formation, reconstitution of dermal appendages and a high degree of the basket-weave matrix, thus producing regenerated skin tissue that closely mimics unwounded skin at 21 days.

studies are very early and very small. This is just a first step in the long road toward making regenerative cell therapy a reality in macular and retinal degeneration.

Dysfunction and degeneration of RPE cells contribute to vision loss in AMD. In both studies, human embryonic stem cells were turned into RPE cells and injected into the sub-retinal space of the patients with retinal degeneration at a dose of 50,000–200,000 cells. The expectation is that, once in place, the new RPE cells will support or replace the patient's own failing RPE cells and boost the survival of photoreceptors.

3. Conclusion

With science and technical advancement in the regenerative medicine and tissue engineering, recent research data suggest detailed investigative studies on the mechanisms of endogenous injury, interactions at organ or tissue cell interface with activated endogenous progenitor cell populations, with a particular focus on mechanisms of how progenitor cells behave with cells of the immune system. Several reports suggest success in identifying pool of stem cells transplanted and actively participated in endogenous corneal, retinal, epicondyle, skin, bronchi and foetal organ repair/regeneration processes.

Acknowledgements

Authors acknowledge knowledge database for this study.

Conflict of interest

Authors have no conflict of interest.

Author details

Paramjit Singh Dhot* and Mayurika S. Tyagi

*Address all correspondence to: psd2682@gmail.com

Saraswathi Institute of Medical Sciences, Hapur, India

References

- [1] Macchiarini P et al. Clinical transplantation of a tissue-engineered airway. *The Lancet*. 2008;**372**(9655):2023-2030
- [2] Stem Cell Gene Therapy Replaces Boy's Entire Epidermis. *Medscape*. Nov 8, 2017
- [3] Mowry KC, Bonvallet PP, Bellis SL. Enhanced skin regeneration using a novel amniotic-derived tissue graft. *Wounds: A Compendium of Clinical Research and Practice*. 2017;**29**(9):277
- [4] Litwiniuk M, Grzela T. Amniotic membrane: New concepts for an old dressing. *Wound Repair and Regeneration*. 2014;**22**(4):451-456
- [5] Stem Cell Therapy Shows Promise for Retinal Degeneration. *Medscape*. Nov 16, 2017

