

We are IntechOpen, the world's leading publisher of Open Access books Built by scientists, for scientists

4,800

Open access books available

122,000

International authors and editors

135M

Downloads

Our authors are among the

154

Countries delivered to

TOP 1%

most cited scientists

12.2%

Contributors from top 500 universities



WEB OF SCIENCE™

Selection of our books indexed in the Book Citation Index
in Web of Science™ Core Collection (BKCI)

Interested in publishing with us?
Contact book.department@intechopen.com

Numbers displayed above are based on latest data collected.
For more information visit www.intechopen.com



Neurological Complications of Elbow Arthroscopy

William B. Stetson, Kevin Vogeli, Brian Chung,
Nicole J. Hung, Stephanie Morgan and
Milan Stevanovic

Additional information is available at the end of the chapter

<http://dx.doi.org/10.5772/intechopen.75594>

Abstract

Elbow arthroscopy is an increasingly common procedure performed in orthopedic surgery. However, due to the presence of several major neurovascular structures in close proximity to the operative portals, it can have potentially devastating complications. The largest series of elbow arthroscopies to date described a 2.5% rate of post-operative neurological injury. All of these injuries were transient nerve injuries resolved without intervention. A recent report of major nerve injuries after elbow arthroscopy demonstrated that these injuries are likely under-reported in literature. A review of our records from 1998 to 2014 revealed six patients who had undergone elbow arthroscopy and developed neurological injury post-operatively. While complications after elbow arthroscopy are rare, the most common permanent nerve palsy post-operatively is the posterior interosseous nerve (PIN) followed by the ulnar nerve. Because of the surrounding neurovascular structures, familiarity with the normal elbow anatomy and portals will decrease the risk of damage to important structures. The purpose of this chapter is to review important steps in performing elbow arthroscopy with an emphasis on avoiding neurovascular injury. With a sound understanding of the important bony anatomic landmarks, sensory nerves, and neurovascular structures, elbow arthroscopy can provide both diagnostic and therapeutic intervention with little morbidity.

Keywords: elbow arthroscopy, neurological complications, posterior interosseous nerve, ulnar nerve, neurovascular injury

1. Introduction

Elbow arthroscopy is a technically demanding procedure, which requires extensive hands-on training and supervised experience to acquire proficiency [1, 2]. When performed with

appropriate judgment and technique, elbow arthroscopy is an excellent tool for the correction of many lesions of the elbow joint with minimal risk [3]. However, it poses greater technical challenges and neurological risks than knee or shoulder arthroscopy. Arthroscopy of the elbow joint is perhaps the most hazardous due to the potential for causing injury to important nearby nerves and vessels. The reason for this relates to the complex relationship of these structures to the joint (**Figure 1**) [4]. Because of the surrounding neurovascular structures, familiarity with the normal elbow anatomy and portals will decrease the risk of damage to important neurovascular structures [5]. With a sound understanding of the important bony anatomic landmarks, sensory nerves, and neurovascular structures, elbow arthroscopy can serve as an opportunity for both diagnostic and therapeutic intervention with little morbidity.

Due to the proximity of several neurovascular structures to the established portals, the risk of neurological injury during elbow arthroscopy is higher as compared to other joints [6]. Additionally, the complications after elbow arthroscopy have been reported to be 10%, compared to a rate of ~3% after knee arthroscopy [1]. Multiple anatomical studies have documented the relationship and location of the nerves crossing the elbow to the commonly used arthroscopic portals [7–12]. Not surprisingly, injuries to every nerve about the elbow have been reported after arthroscopy [13–18]. Despite these concerns, the three largest consecutive series of elbow arthroscopy to date have reported a low incidence of neurological

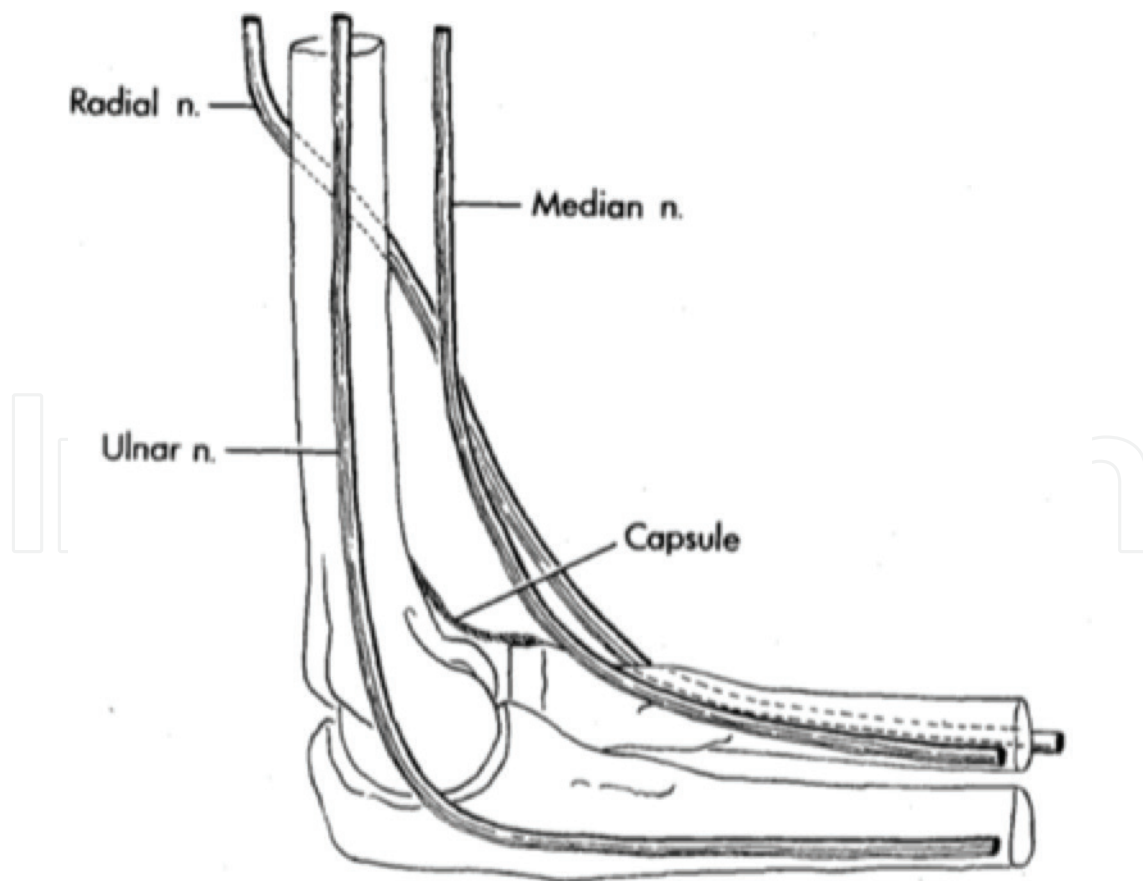


Figure 1. The antecubital fossa with important neurovascular structures.

complications [1, 2, 18]. The first large series of consecutive elbow arthroscopies reported one laceration of the ulnar nerve in 187 consecutive cases (0.5%) [19]. The largest series reported a 2.5% rate of neurological injury after elbow arthroscopy in 473 consecutive cases with ulnar nerve dysfunction being the most common [1]. All of the reported injuries in this series resolved spontaneously without intervention.

In the most recent series, a 1.7% rate of neurological injury was reported in 417 consecutive elbow arthroscopies [2]. As with the previous series, all of the reported injuries were transient in nature. From these studies, it can be inferred that a permanent neurological deficit is an

Patient	Age (yrs) at Arthroscopy	Indication for Arthroscopy	Arthroscopic Procedure	Documented Nerve Palsy	Additional Procedures
1	25	Synovial chondromatosis	Synovectomy	Ulnar nerve	Primary nerve repair
2	25	Synovial chondromatosis	Synovectomy	Ulnar nerve	N/A
3	16	Posterior olecranon impingement	Synovectomy, olecranon debridement	PIN	Nerve repair, tendon transfers
4	27	Radial head non-union	Radial head resection, capsular release	PIN	Nerve repair, tendon transfers
5	39	Post-traumatic stiffness	Loose body removal, capsular release	PIN	Nerve exploration, tendon transfers
6	38	Rheumatoid arthritis	Radial head resection	PIN	Nerve repair, tendon transfers

Table 1. Neurological complications following elbow arthroscopy.

extremely rare occurrence, despite the risks highlighted in the anatomical studies. However, a recent online survey of members of the American Society for Surgery of the Hand reported a much higher incidence of major nerve injuries after elbow arthroscopy indicating that this is not a rare occurrence [20].

Review of our medical records revealed six patients with documented nerve palsies after elbow arthroscopy. All of these patients were referred to our institutions; their index procedures were performed at other facilities and no cases of neurological injury were found at our institutions. The complete results are presented in **Table 1**. The indications for the arthroscopies performed included synovial chondromatosis [3], stiffness after elbow trauma [3], posterior olecranon impingement [2], and stiffness due to rheumatoid arthritis [2]. All patients underwent arthroscopic synovectomy in the anterior and posterior compartments to improve range of motion, two patients underwent radial head resection, two patients underwent capsular release and one patient underwent posterior olecranon debridement. Four patients demonstrated isolated posterior interosseous nerve (PIN) palsies (66%) with inability to extend all digits and radial deviation with wrist extension. In these four patients, the anterior lateral portal used was found to be at or distal to the radiocapitellar joint. Two other patients demonstrated isolated ulnar nerve palsies (33%). All nerve injuries were confirmed by EMG/NCS or by direct visualization during surgical exploration. None of the neurological injuries demonstrated recovery without further surgical intervention.

Five out of the six patients underwent additional surgical procedures to address their nerve palsies. Four patients underwent attempted repair of the lacerated nerve (3 PIN, 1 ulnar), with only one demonstrating any improvement in function at 1 year (1 ulnar). All four patients with PIN palsy underwent modified Brandt tendon transfers (flexor carpi radialis to extensor digitorum communis, palmaris to extensor pollicis longus) to restore finger and thumb extension successfully. In this chapter, we will provide a step-by-step process for performing elbow arthroscopy in order to minimize the risk to neurovascular structures.

2. History and physical examination

Before proceeding with elbow arthroscopy, a comprehensive history should be taken including the occupation of the patient, whether they are right or left handed, the location of their pain, and the duration of their symptoms. It is also important to determine the details of whether their symptoms started with a single traumatic event or from repetitive activities. Symptoms in the lateral region of the elbow may be indicative of radiocapitellar chondromalacia, osteochondral loose bodies, radial head fracture, osteochondritis dissecans (OCD) lesions, and most commonly lateral epicondylitis. Symptoms in the medial region of the elbow most commonly present as medial epicondylitis, but MCL sprains, ulnar neuritis, ulnar nerve subluxation, or even a medial epicondyle avulsion fracture should also be considered.

The differential diagnosis for symptoms of the anterior elbow includes distal biceps tendon rupture, which can be partial, or complete, an anterior capsular strain, and a brachioradialis muscle strain [21]. Symptoms in the posterior compartment can reflect valgus extension

overload syndrome, posterior impingement, osteochondral loose bodies, triceps tendonitis, triceps tendon avulsion, or olecranon bursitis [22]. A careful neurovascular history is also important, as ulnar nerve paraesthesias can be the result of cubital tunnel syndrome, a subluxing ulnar nerve, or a traction injury from valgus instability [23]. A careful physical examination of all three compartments of the elbow is critical to determine the correct diagnosis. Each compartment should be examined individually in order to fully evaluate the elbow.

3. Diagnostic imaging

Routine diagnostic radiographs include an anterior posterior (AP) view with the elbow in full extension and a lateral view with the joint in 90 degrees of flexion. An axial view can also be obtained to outline the olecranon and its medial and lateral articulations. When there is a history of trauma, an oblique view should also be done to rule out occult fractures.

Magnetic resonance imaging (MRI) is useful for evaluating osteochondral lesions in the radiocapitellar joint [24, 25] and for demonstrating early vascular changes which are not yet apparent on plain radiographs and can be used to assess the extent of the lesion and displacement of fragments [23]. MRI is also helpful for evaluating the soft tissue structures of the elbow including the tendinous insertions of the flexor and extensor musculature to help in diagnosing medial and lateral epicondylitis, the triceps insertion, and associated musculature to evaluate for triceps tendonitis, and the medial and lateral collateral ligaments for possible tears. Magnetic resonance arthrography with saline contrast or gadolinium can increase the sensitivity for detecting undersurface tears of the ulnar collateral ligament and has now become the test of choice to detect these tears [26].

4. Operating room setup and positioning

We typically perform this procedure under general endotracheal anesthesia in the prone position. This procedure can also be performed with the patient in the lateral decubitus position [27], but the prone position is our preference. We prefer the prone position as it allows easy access to the both the anterior and posterior compartments of the elbow joint. Similar access can be achieved in the lateral decubitus position but we prefer the prone position as we find it easier to gain access into both compartments. We strongly advise against the supine position, as access to the posterior compartment is difficult and can lead to unintentional neurovascular injury.

We prefer general anesthesia as it allows proper positioning of the patient, which is key to avoiding neurological and vascular injuries although a regional block is possible. After an appropriate level of anesthesia (general endotracheal or axillary block) has been achieved, the patient is placed in the prone position, using two large chest-rolls under the torso to raise the patient's torso up from the operating table. These are made of operating room blankets rolled up and taped together. These chest rolls are very important and must be firm so that it elevates the chest wall off of the operating room table. We advise against the pre-made

devices used by spine surgeons for prone positioning, as it does not elevate the patient high enough off of the operating room table.

In the prone position, an arm-board is placed on the operative side of the table and parallel to it. A sandbag, block, or firm bump of towels is placed under the shoulder to further elevate the arm away from the table and increases the mobility of the upper extremity. If the chest rolls are not high enough or firm enough, the chest is not elevated far enough away from the operating room table and the shoulder will be placed in hyper-abduction, which can place unnecessary stress or strain on the shoulder capsule or surrounding structures. The forearm is then allowed to hang in a dependent position over the arm-board at 90° (**Figure 2**). A sterile tourniquet may be placed around the proximal aspect of the arm to help to control bleeding during the procedure, but it is not always necessary to inflate when using a mechanical irrigation system [3]. The forearm is prepared from the proximal arm to the tip of the fingers and then the extremity is wrapped with an elastic bandage from the fingers to just below the elbow to minimize fluid extravasation into the forearm [28]. After the extremity is prepped and draped, a large sterile “bump” is placed under the arm proximal to the elbow to keep the shoulder abducted to 90° and the elbow at approximately 90 degrees of flexion (**Figure 3**).

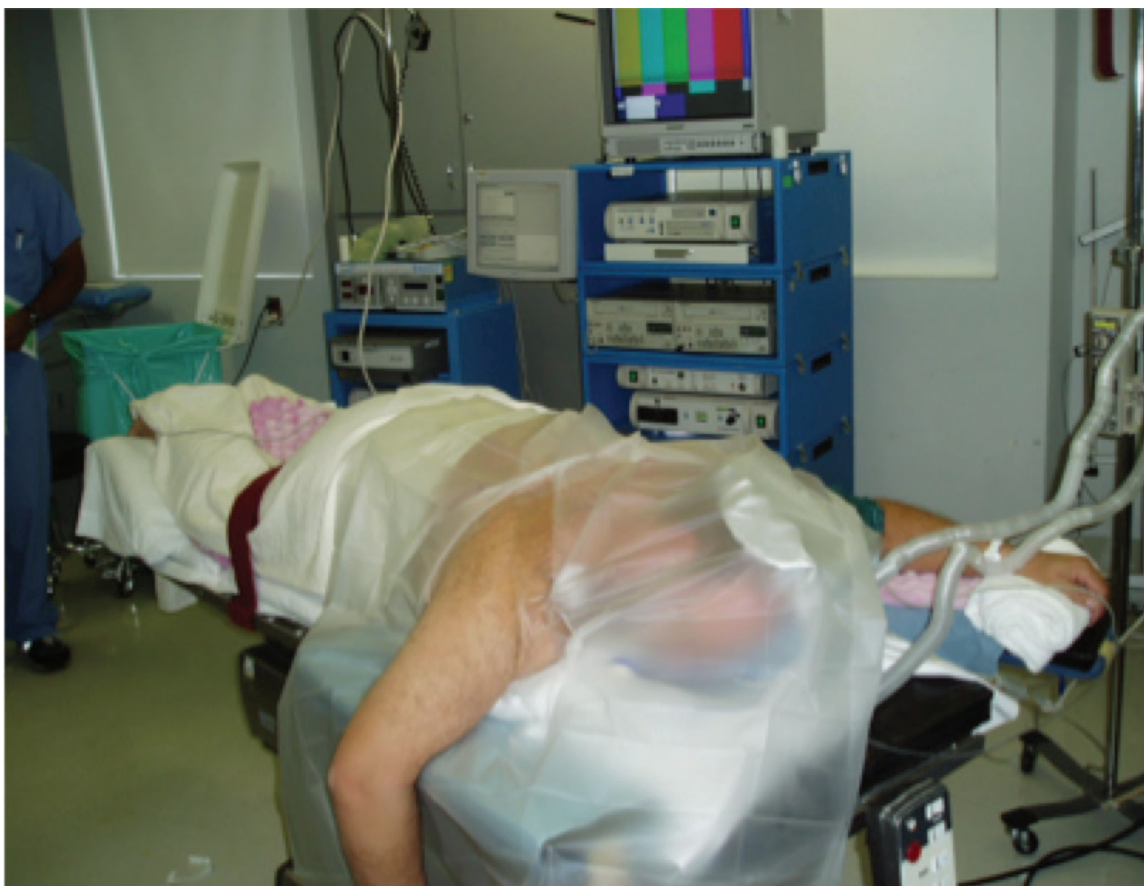

Figure 2. The prone position with the right elbow resting over an arm board, which is parallel to the operating room table. A non-sterile U-drape is placed proximally. A sterile bump is placed under the arm for support after the extremity is prepped.

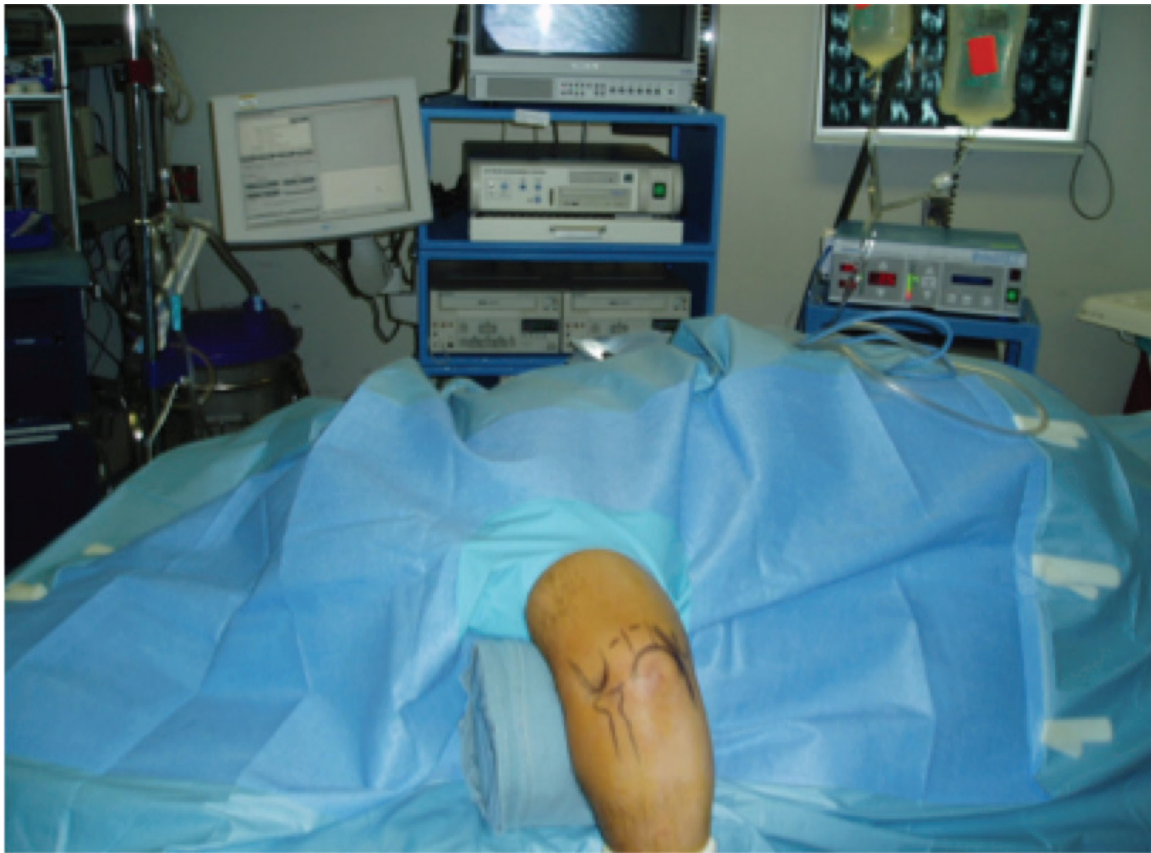

Figure 3. A left elbow is shown in the prone position. Anesthesia is at the head (left) of the patient and all equipment is on the opposite side of the table. Note the sterile bump under the arm which helps stabilize the elbow during the procedure. This rests on the arm board, which has been placed parallel to the table.

5. Portal placement and diagnostic arthroscopy

5.1. Anterior compartment

After prepping and draping the extremity, all bony landmarks are then outlined including the olecranon, the medial and lateral epicondyles, the radiocapitellar joint and the course of the ulnar nerve (**Figure 4**). The proximal anteromedial portal is located approximately 2 cm proximal to the medial epicondyle and just anterior to the intermuscular septum (**Figure 5**) and is established first. If close attention is paid to anatomic landmarks, joint insufflation is not necessary. Prior to establishing this portal, the location and the stability of the ulnar nerve should be assessed. If there is any history of a previous ulnar transposition or a question of a subluxing ulnar nerve, this portal incision should be extended the ulnar nerve dissected out and identified before portal placement (**Table 2**).

If the course of the ulnar nerve is not in question, then blunt dissection is carried through proximal anterior medial portal with a straight Kelly instrument until the anterior aspect of the humerus is palpated. This is the key step. If the portal is placed too anterior then the neurovascular structures in the antecubital fossa are at risk. If the portal is posterior to the

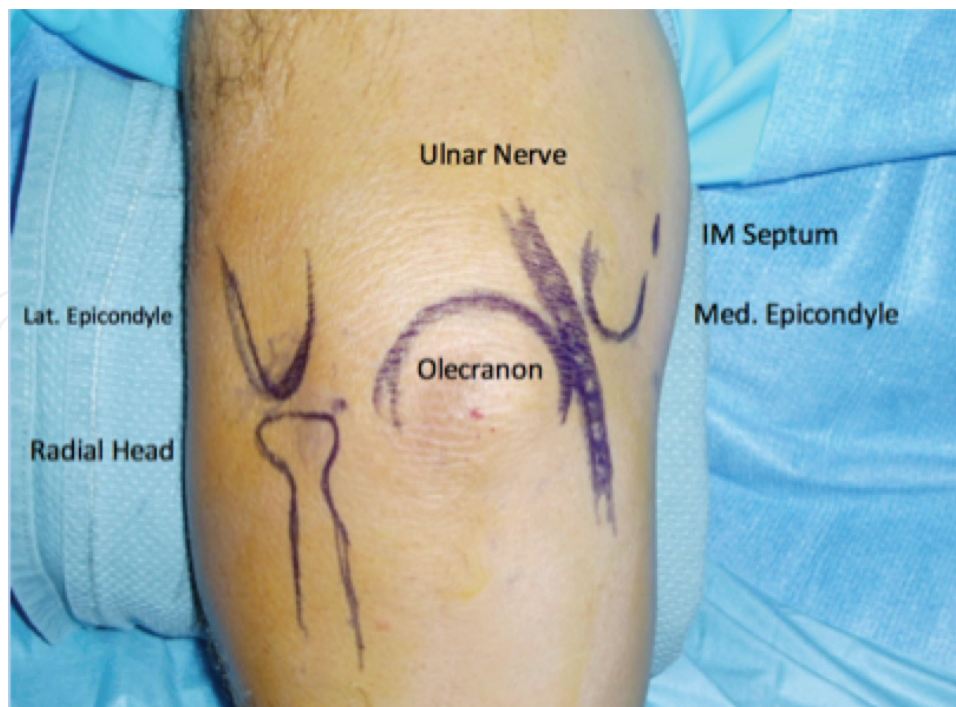


Figure 4. Anatomic landmarks are identified of the left elbow in the prone position including the medical epicondyle (right), the lateral epicondyle (left), the radial head, the olecranon, and the ulnar nerve (dark blue line on right). The intermuscular septum is also identified on the medial aspect of the elbow, just anterior to the medial epicondyle.

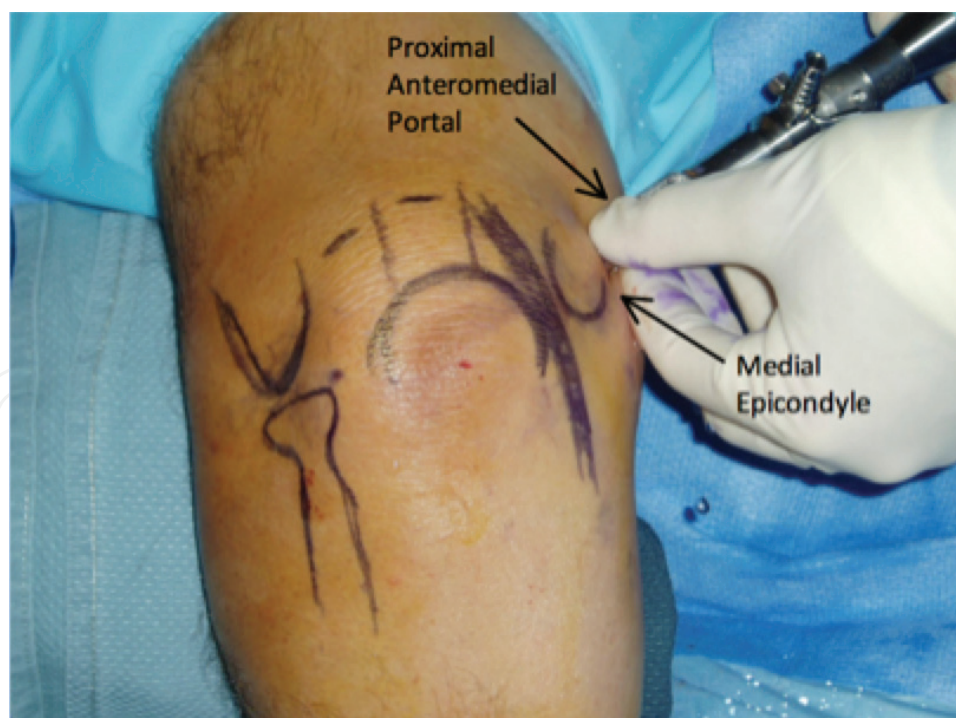


Figure 5. The proximal anteromedial portal is the first to be established, it is located just anterior to the intermuscular septum and two centimeters proximal to the medial epicondyle.

Advantages	Disadvantages
1. Elbow arthroscopy can be an effective and less invasive tool to enter into the elbow joint to confirm the diagnosis of an infection, irrigate the joint, debride infected tissue, remove loose bodies and osteophytes, and treat lateral epicondylitis.	1. Significant distortions of normal bony or soft tissue anatomy, previous ulnar nerve transposition, or severe ankylosis may place important neurovascular structures at risk and preclude safe entry of the arthroscope into the joint.
2. Elbow arthroscopy permits a more complete visualization of the articular surface of the elbow, rapid rehabilitation, and an earlier return to work or sports.	2. Iatrogenic damage to the radial nerve, posterior interosseous nerve, and ulnar nerve can occur but can be minimized with careful attention to detail. Careful portal placement is necessary to avoid damage to neurovascular structures along with the careful and judicious use of the arthroscopic shaver in the elbow joint.
3. There are new frontiers of elbow arthroscopy which include treatment of radial head, coronoid, and capitellar fractures, olecranon bursitis, distal biceps tendon repair, triceps repair, and ulnar nerve release.	

Table 2. Pearls and pitfalls of elbow arthroscopy.

humerus and posterior to the intermuscular septum, the ulnar nerve can be damaged. We have seen iatrogenic ulnar nerve damage from improper portal placement and so meticulous attention to detail is important to avoid this complication.

The arthroscopic cannula and sheath is then inserted anterior to the intermuscular septum while maintaining contact with the anterior aspect of the humerus and directing the trocar toward the radial head. Use of the anterior surface of the humerus as a constant guide helps to prevent injury to the median nerve and the brachial artery, which are anterior to the capsule. The ulnar nerve is located approximately 3 to 4 mm from this portal, posterior to the intermuscular septum (**Figure 6**). Palpating the septum and making sure that the portal is established anterior to the intermuscular septum minimizes the risk of injury to the nerve while providing excellent visualization of the radiocapitellar joint, the humeroulnar

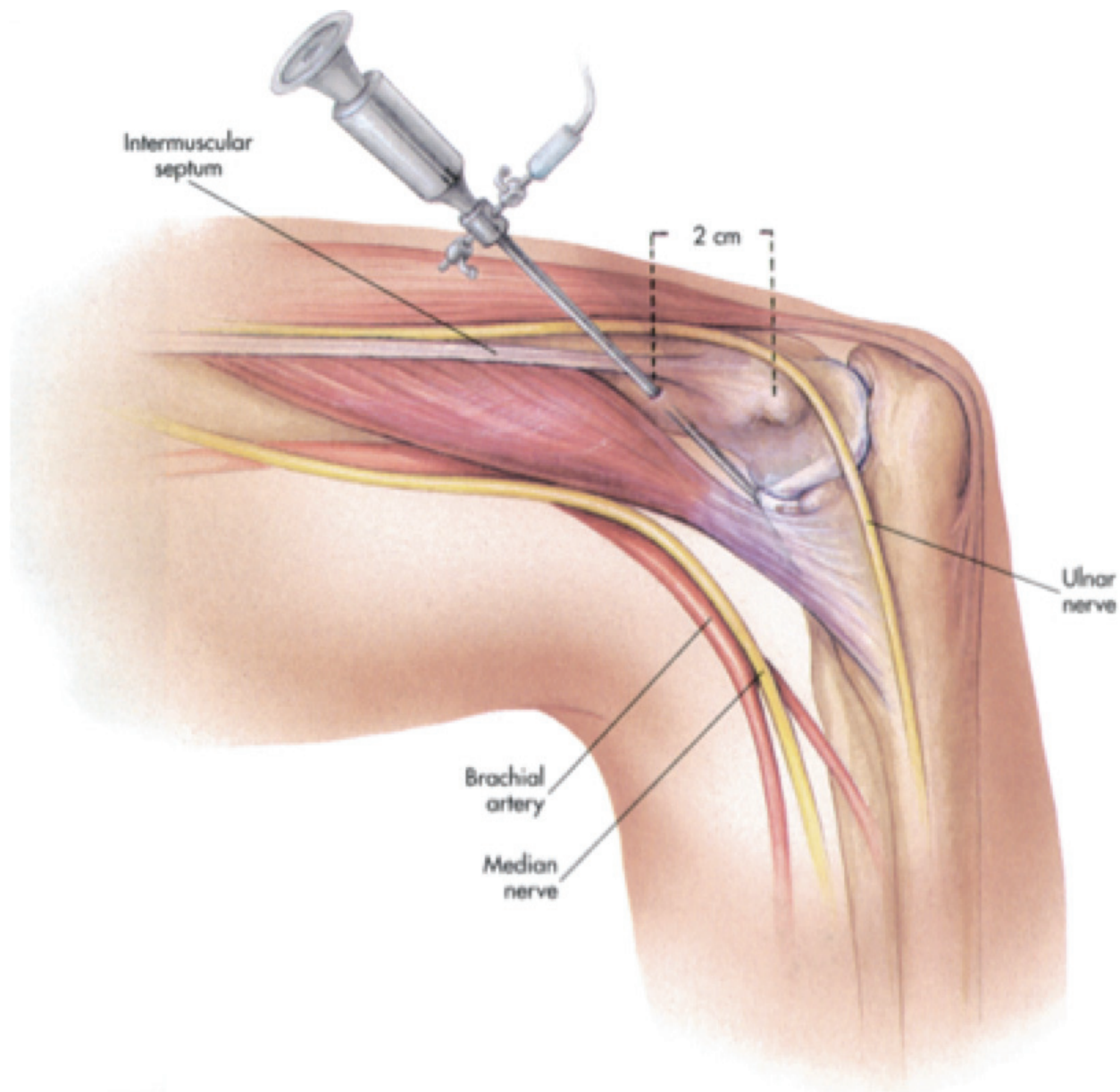


Figure 6. The arthroscope is inserted two centimeters proximal to the medial epicondyle and just anterior to the intermuscular septum on the medial aspect of the arm. In the prone position, the brachial artery and median nerve fall away from the joint capsule allowing for safe portal placement.

joints, the coronoid fossa, and superior joint capsule [3, 23]. We prefer establishing the proximal anterior medial portal first, as there is less fluid extravasation when starting medially because this portal traverses predominantly tendinous tissue and a tough portion of the forearm flexor muscles [29, 30]. The thicker tissues minimize fluid extravasation more effectively than the softer, thinner, radial capsule laterally [29, 30]. Finally, most elbow disorders are located in the lateral compartment, which is best visualized from the proximal anteromedial portal [23] including the lateral capsule, the radiocapitellar joint and the distal aspect of the humerus (**Figure 7**).

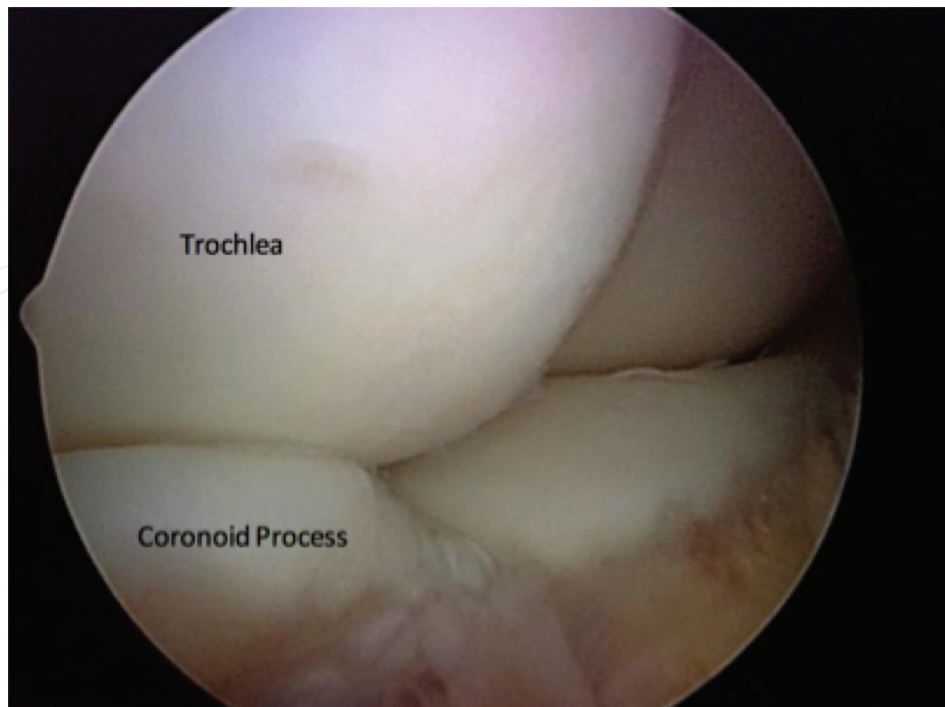


Figure 7. The trochlea (top left) and the coronoid process (lower left) can also be seen from the proximal anteromedial portal.

After creating the proximal anteromedial portal, we establish the proximal anterolateral portal using an outside-in technique localizing the position with a spinal needle. This portal is created 2 cm proximal and 1 cm anterior to the lateral epicondyle, as described by Field and coworkers [31]. If this portal is created too far distally near the radiocapitellar joint or even further distally near the radial neck, it places the posterior interosseous nerve at significant risk. Non-fenestrated cannulas are used to prevent extravasation of the fluid into the subcutaneous tissues.

Visualizing from the proximal anteromedial portal, one can visualize the lateral capsule and palpate the skin to localize the exact location of the spinal needle for accurate portal placement (**Figure 8**). It is important to direct the cannula toward the humerus while penetrating the capsule so that the portal placement is not too far anterior and medial [5]. The proximal anterolateral portal is often a working portal and is ideal for arthroscopic lateral epicondyle release and debridement of the radiocapitellar joint. Viewing from this portal permits visualization of the anterior compartment, and is particularly good in evaluating medial structures, such as the trochlea, coronoid tip, and the medial capsule (**Figure 9**).

5.2. Posterior compartment

For evaluating the posterior compartment, the straight posterior portal is usually created first and is located 3 cm proximal to the tip of the olecranon and can be used as a viewing portal or as a working portal. When it is the first portal created, a cannula with a blunt trocar is

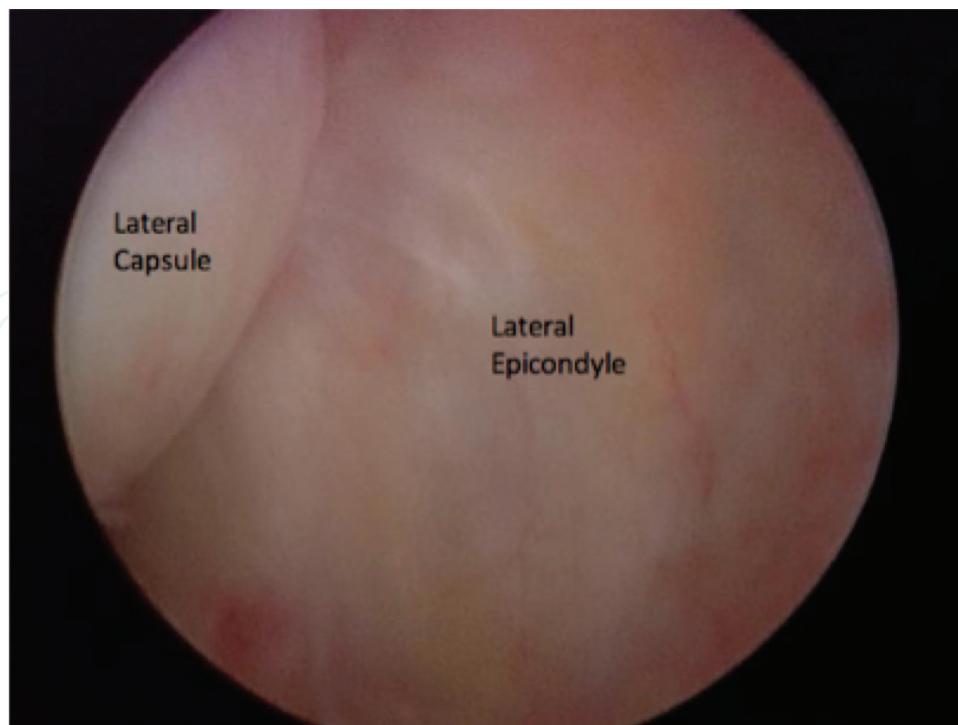


Figure 8. The lateral capsule is seen from the proximal anteromedial portal. This is the location where a spinal needle is introduced for the proximal anterolateral portal.

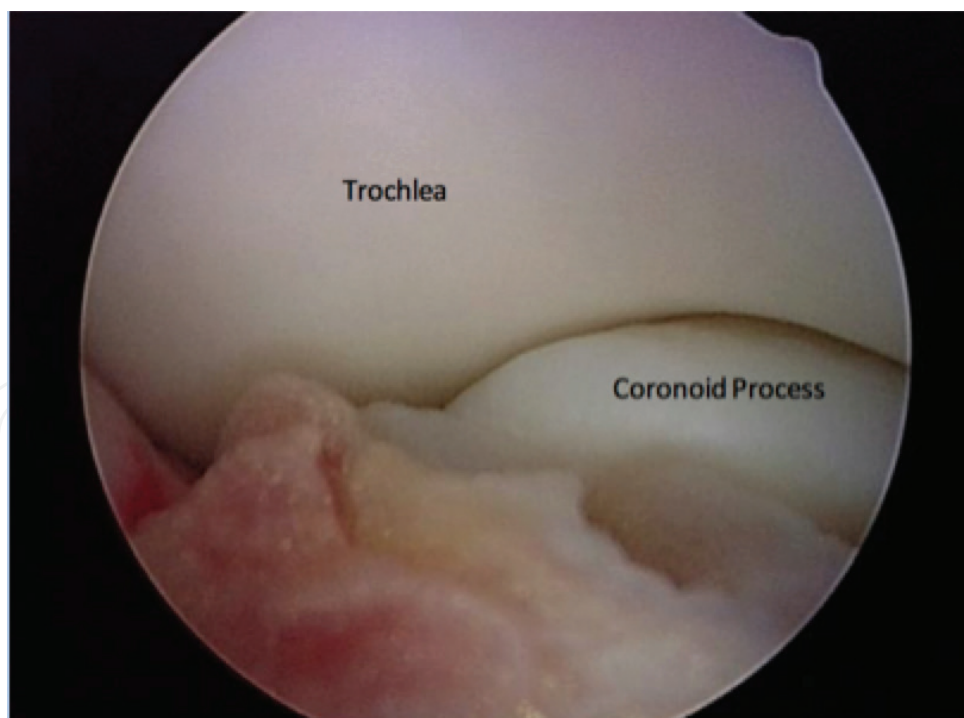


Figure 9. Viewing from the proximal anterolateral portal, the trochlea and the coronoid process can also be seen.

inserted. The cannula pierces the triceps muscle just above the musculotendinous junction and is bluntly maneuvered in a circular motion manipulating the soft tissues from the olecranon fossa for better visualization. When used as a working portal, it is helpful for removal

Pearls	Pitfalls
1. The prone or the lateral decubitus position is the preferred patient positioning for elbow arthroscopy. Both positions allow easy access to the both the anterior and posterior compartments.	1. The anterolateral portal located 3 cm distal and 2 cm anterior to the lateral epicondyle places the radial nerve at significant risk and should be avoided.
2. It is important to identify and mark landmarks of the elbow joint. This includes the tip of the olecranon, the medial and lateral epicondyle, the radial head, the soft spot of the elbow, the medial intermuscular septum, and the ulnar nerve.	2. A subluxing ulnar nerve or a previous ulnar nerve transposition places the ulnar nerve at risk with proximal anteromedial portal placement.
3. The proximal anterolateral portal located 2 cm proximal and 1 cm anterior to the lateral epicondyle is safest and gives excellent visualization of the radiohumeral joint.	3. If the trocar is placed posterior to the intermuscular septum, injury to the ulnar nerve can occur.

Table 3. Advantages and disadvantages of elbow arthroscopy.

of impinging olecranon osteophytes and loose bodies from the posterior elbow joint (**Table 3**) [32]. The straight posterior portal passes within 25 mm of the ulnar nerve and within 23 mm of the posterior antebrachial cutaneous nerve [29].

The posterolateral portal is located 2–3 cm proximal to the tip of olecranon at the lateral border of the triceps tendon. This is created while visualizing from the straight posterior portal using a spinal needle directed toward the olecranon fossa (**Figure 10**). Initial visualization of the posterior compartment can be impeded by synovitis, scar tissue, and fat pad hypertrophy. A trocar is directed toward the olecranon fossa, passing through the triceps muscle to reach the capsule. A shaver is then introduced to improve visualization of the posterior compartment. This portal permits visualization of the olecranon tip, olecranon fossa, and posterior trochlea. It may also be used as a working portal to remove osteophytes and loose bodies from the posterior compartment (**Figure 11**). The medial and posterior antebrachial cutaneous nerves are the two neurovascular structures at most risk, residing an average of 25 mm from this portal [33]. The ulnar nerve is also at significant risk near the medial epicondyle and the medial gutter. Careful direct visualization of the arthroscopic shaver is important when in this area, and judicious use of the suction of the shaver can prevent iatrogenic injury to the ulnar nerve. At no time should the arthroscopic shaver be used “blind” in this area as the ulnar nerve can be inadvertently sucked into the shaver tip and cause significant and possible irreversible damage to the nerve.

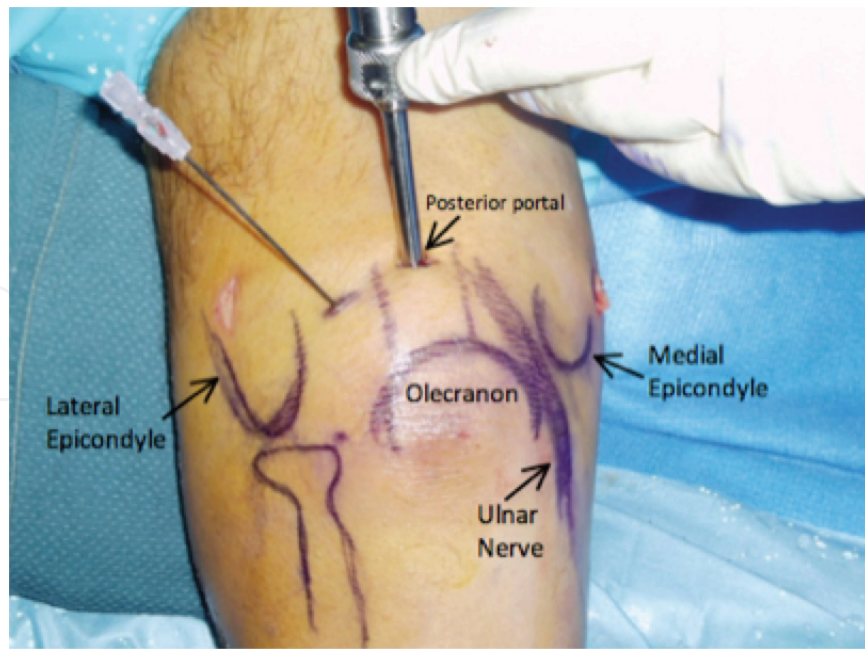


Figure 10. The arthroscope is introduced into the posterior compartment using a straight posterior portal, 3 cm proximal from the tip of the olecranon. A spinal needle is introduced lateral to the triceps tendon toward the olecranon fossa for the posterolateral portal.

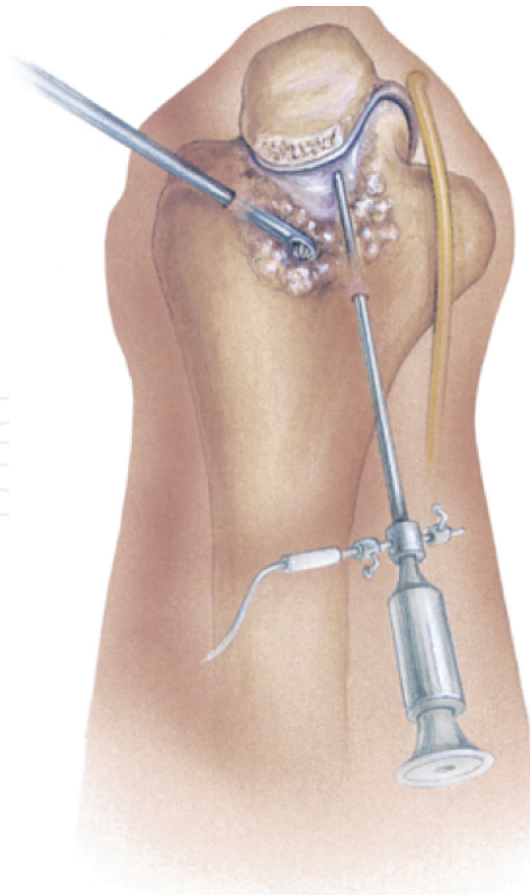


Figure 11. The posterior lateral portal is used as a working portal to remove osteophytes and loose bodies from the posterior compartment.

The direct lateral portal is located at the “soft spot” which is the triangle formed by the radial head, lateral epicondyle, and olecranon. It is developed under direct visualization using a spinal needle and may be used as either a viewing portal for the posterior compartment and radiocapitellar joint or a working portal for radial head resection [34]. This is the only portal that provides easy access to the posterior capitellum and radioulnar joint and can be useful for lesions of the radiocapitellar joint [22]. Altering the portal position along the line between the posterolateral portal and lateral soft spot changes the orientation of the portal relative to the joint [28]. These portals are particularly useful for gaining access to the posterolateral recess.

6. Summary and conclusions

The several published consecutive series of elbow arthroscopies performed demonstrated extremely low rates of neurological complications. Taken in the aggregate, these studies demonstrated one permanent nerve palsy out of over a thousand elbow arthroscopies. The vast majority of the nerve palsies reported in these series was transient, sensory deficits.

However, a recent survey of members of the American Society for Surgery of the Hand received 322 responses and a total of 222 nerve injuries were reported. There were 107 major nerve injuries, which were defined as those requiring surgical intervention. The most common nerve involved was the ulnar nerve (38%), followed by the radial nerve (22%) and the posterior interosseous nerve (PIN) 19%. It is obvious from this report that the risk of neurological complications after elbow arthroscopy has likely been under-reported in the literature [20].

At our institutions where we have been referred patients with neurovascular complications following elbow arthroscopy, we have found that the PIN palsy is the most common injury after elbow arthroscopy followed by ulnar nerve palsy. Many of these complications could have been avoided with proper portal placement. In particular, each of the patients with PIN palsies or lacerations had lateral portal placements either at the level of the radiocapitellar joint or distal to it. Staying at least 2 cm proximal to the lateral epicondyle will minimize or even eliminate this risk. This is important when performing an anterior capsule release or a radial head resection.

For the anterior-medial portal, it is very important to stay anterior to the intermuscular septum, which protects the ulnar nerve. Palpation of the intermuscular septum is key, and the inability to locate it can cause inadvertent placement of the arthroscopic cannula and trocar posteriorly and damage the ulnar nerve. Blunt dissection anterior to the intermuscular septum and anteriorly to the anterior aspect of the humerus is critical. Use of the anterior surface of the humerus as a constant guide helps to prevent injury to the median nerve and the brachial artery, which are anterior to the capsule. It also prevents posterior placement of the portal posterior to the humerus, which can place the ulnar nerve at risk. As mentioned previously, if there is a question of a subluxing ulnar nerve or if there is a history of a previous ulnar nerve transposition, the portal incision should be enlarged both proximally and distally and the ulnar nerve should be dissected out and identified before portal placement.

In the posterior compartment, the ulnar is also at greatest risk and can be injured with the use of the arthroscopic shaver in the medial gutter, so careful attention must be used when the shaver is used in this region. It is paramount that there is direct visualization of the shaver tip at all times and that there is never “blind” shaving in the medial gutter.

Elbow arthroscopy is a technically demanding procedure. Attention to detail, including careful portal placement, is necessary to avoid iatrogenic injury to neurovascular structures around the elbow joint. In every clinical case, the bony anatomy should be drawn on the patient's elbow and an 18-gauge spinal needle should be used to confirm correct portal location before introducing larger arthroscopic instruments [20]. As with any operative procedure, careful preoperative planning, including a detailed history and physical examination, along with proper imaging studies, and sound clinical judgment, is necessary to ensure a successful procedure.

Conflict of interest

The authors have no conflicts of interest to report.

Author details

William B. Stetson¹, Kevin Vogeli², Brian Chung^{1,2}, Nicole J. Hung^{1*}, Stephanie Morgan¹ and Milan Stevanovic²

*Address all correspondence to: nicolehung20@gmail.com

1 Stetson Powell Orthopedics and Sports Medicine, Burbank, CA, United States of America

2 Keck School of Medicine, University of Southern California, Los Angeles, CA, United States of America

References

- [1] Kelly EW, Morrey BF, O'Driscoll SW. Complications of elbow arthroscopy. *The Journal of Bone and Joint Surgery. American Volume*. 2001;**83**(1):25-34
- [2] Nelson GN, Wu T, Galatz LM, Yamaguchi K, Keener JD. Elbow arthroscopy: Early complications and associated risk factors. *Journal of Shoulder and Elbow Surgery*. Feb 23, 2014;**2**:273-278. DOI: 10.1016/j.jse.2013.09.026
- [3] Strothers D, Day B, Regan WR. Arthroscopy of the elbow: Anatomy, portal sites, and description of the proximal lateral portal. *Arthroscopy*. 1995;**11**:449-457
- [4] Poehling GG, Ekman EF. Arthroscopy of the elbow. *Journal of Bone and Joint Surgery (A)*. 1994;**8**:1265-1271
- [5] Moskal MJ. Advanced arthroscopic management of common elbow disorders. In: *Arthroscopy Association of North America 24th Annual Meeting, Vancouver, Canada*. May 2005
- [6] Adams JE, Steinmann SP. Nerve injuries about the elbow. *Journal of Hand Surgery*. 2006;**31A**:303-313. DOI: 10.1016/j.jhssa.2005.12.006

- [7] Lynch GJ, Meyers JF, Whipple TL, Caspari RB. Neurovascular anatomy and elbow arthroscopy: Inherent risks. *Arthroscopy*. 1987;**2**(3):191-197
- [8] Marshall PD, Fairclough JA, Johnson SR, Evans EJ. Avoiding nerve damage during elbow arthroscopy. *Journal of Bone and Joint Surgery. British Volume (London)*. 1993;**75**:129-131
- [9] Miller CD, Jobe CM, Wright MH. Neuroanatomy in elbow arthroscopy. *Journal of Shoulder and Elbow Surgery* 1995;**4**:168-74
- [10] Omid R, Hamid N, Keener JD, Galatz LM, Yamaguchi K. Relation of the radial nerve to the anterior capsule of the elbow: Anatomy with correlation to arthroscopy. *Arthroscopy*. 2012;**12**:1800-1804. DOI: 10.1016/j.arthro.2012.05.890
- [11] Unlu MC, Kesmezacar H, Akgun I, Ogut T, Uzun I. Anatomic relationship between elbow arthroscopy portals and neurovascular structures in different elbow and forearm positions. *Journal of Shoulder and Elbow Surgery*. 2006;**15**:457-462. DOI: 10.1016/j.jse.2005.09.012
- [12] Verhaar J, van Mameren H, Brandsma A. Risks of neurovascular injury in elbow arthroscopy: Starting anteromedially or anterolaterally? *Arthroscopy*. 1991;**7**:287-290
- [13] Dumonski ML, Arciero RA, Mazzocca AD. Ulnar nerve palsy after elbow arthroscopy. *Arthroscopy*. 2006;**22**:577. E1-3. DOI: 10.1016/j.arthro.2005.12.049
- [14] Haapaniemi T, Berggren M, Adolfsson L. Complete transection of the median and radial nerves during arthroscopic release of post-traumatic elbow contracture. *Arthroscopy*. 1999;**15**:784-787
- [15] Gupta A, Sunil TM. Complete division of the posterior interosseous nerve after elbow arthroscopy: A case report. *Journal of Shoulder and Elbow Surgery*. 2004;**13**:566-567. DOI: 10.1016/j.jse.2004.02.004
- [16] Papilion JD, Neff RS, Shall LM. Compression neuropathy of the radial nerve as a complication of elbow arthroscopy: A case report and review of the literature. *Arthroscopy*. 1988;**4**:284-286
- [17] Ruch DS, Poehling GG. Anterior interosseous nerve injury following elbow arthroscopy. *Arthroscopy*. 1997;**13**:756-758
- [18] Thomas MA, Fast A, Shapiro D. Radial nerve damage as a complication of elbow arthroscopy. *Clinical Orthopaedics and Related Research*. 1987:130-131
- [19] Reddy AS, Kvitne RS, Yocum LA, Elattrache NS, Glousman RE, Jobe FW. Arthroscopy of the elbow: A long-term clinical review. *Arthroscopy*. Sep 16, 2000;**6**:588-594
- [20] Desai MJ, Suhail KM, Lodha SL, Richard MJ, Leversedge FJ, Ruch DS. Major peripheral nerve injuries after elbow arthroscopy. *Arthroscopy*. 2016;**32**:999-1002
- [21] Dodson CC, Nho SJ, Williams RJ, Altchek DW. Elbow arthroscopy. *Journal of the American Academy of Orthopaedic Surgeons*. 2008;**16**(10):574-585

- [22] Yadao MA, Field LD, Savoie III FH. Osteochondritis dissecans of the elbow. *Instructional Course Lectures*. 2004;**53**:599-606
- [23] Baker CL, Grant LJ. Arthroscopy of the elbow. *American Journal of Sports Medicine*. 1999;**27**(2):251-264
- [24] Jaraw PM, Hessen U, Hirsch G. Osteochondral lesion in the radiocapitellar joint in the skeletally immature: Radiographic MRI and arthroscopic findings in 13 conservative cases. *Journal of Pediatric Orthopedics*. 1997;**17**:311-314
- [25] Takahara M, Shundo M, Kondo M, et al. Early detection of osteochondritis dissecans of the capitellum in young baseball players: Report of three cases. *Journal of Bone Joint Surgery*. 1998;**80A**:892-897
- [26] Timmerman LA, Schwartz ML, Andrews JR. Preoperative evaluation of the ulnar ligament by magnetic resonance imaging and computed tomography arthrography: Evaluation in 25 baseball players with surgical confirmation. *The American Journal of Sports Medicine*. 1994;**22**:26-32
- [27] O'Driscoll SW, Morrey BF. Arthroscopy of the elbow: Diagnostic and therapeutic benefits and hazards. *Journal of Bone and Joint Surgery*. 1992;**74A**:84-94
- [28] Abboud JA, Ricchette ET, Tjoumakaris F, Ramsey ML. Elbow arthroscopy: Basic set-up and portal placement. *The Journal of the American Academy of Orthopaedic Surgeons*. 2006;**14**:312-318
- [29] Baker CL, Brooks AA. Arthroscopy of the elbow. *Clinics in Sports Medicine*. 1996;**15**:261-281
- [30] Lo IKY, King GJW. Arthroscopic radial head excision (case report). *Arthroscopy*. 1994;**10**:689-692
- [31] Field LD, Altchek DW, Warren RF, O'Brian SJ, Skyltar MJ, Wickiewicz TL. Arthroscopy anatomy of the lateral elbow: A comparison of 3 portals. *Arthroscopy*. 1994;**10**:602-607
- [32] Andrews JR, St Pierre RK, Carson WG. Arthroscopy of the elbow. *Clinics in Sports Medicine*. 1986;**5**:653-662
- [33] Lynch GJ, Meyers JF, Whipple TL, Caspari RB. Neurovascular anatomy and elbow arthroscopy: Inherent risks. *Arthroscopy*. 1986;**2**:190-197
- [34] Savoie FH, Nunley PD, Field LD. Arthroscopic management of the arthritic elbow: Indications, technique and results. *Journal of Shoulder Elbow Surgeries*. 1999;**8**:214-219