

We are IntechOpen, the world's leading publisher of Open Access books Built by scientists, for scientists

4,800

Open access books available

122,000

International authors and editors

135M

Downloads

Our authors are among the

154

Countries delivered to

TOP 1%

most cited scientists

12.2%

Contributors from top 500 universities



WEB OF SCIENCE™

Selection of our books indexed in the Book Citation Index
in Web of Science™ Core Collection (BKCI)

Interested in publishing with us?
Contact book.department@intechopen.com

Numbers displayed above are based on latest data collected.

For more information visit www.intechopen.com



Surgical Treatment of Burn Scars

Pertevniyal Bodamyalizade

Additional information is available at the end of the chapter

<http://dx.doi.org/10.5772/intechopen.72303>

Abstract

The relationship between a burns patient and a reconstructive surgeon is normally long lasting and continues lifelong. Patients not only require a surgeon's professional expertise, but also time, optimism and compassion. Scar management relates to the physical and aesthetic components as well as the psychosocial implications of scarring. Hypertrophic scar formation which can cause debilitating deficiencies and poor aesthetic outcomes might be a result of burn injuries. Although nonsurgical treatment modalities in the early phase of scar maturation are critical to decrease hypertrophic scar formation, surgical management is often indicated to restore function. Operative scar management releases the tension and can often be achieved through local tissue arrangement.

Keywords: surgery, burn, scar, treatment

1. Introduction

Today, a lot of patients survive burn injuries, but they will not escape the burden of severe scar formation. The scarred tissue leaves contractures at joints, and this causes functional limitations. Surgical treatment is an indication to treat the burn scars [1]. In this chapter we explain the surgical treatment of burn scars. Superficial burn wounds usually heal without complications. Deep partial and full-thickness burns have an increased risk for hypertrophic scar formation [2]. In the burns that include epidermis, the dermis remains intact and re-epithelization occurs by keratinocytes. Superficial partial-thickness burns involve epidermis and superficial dermis which results in blisters. Superficial injuries may require careful monitoring only. In deep partial-thickness burns, prolonged time for re-epithelialization is needed [3]. Assessing the depth of burn earlier is important to administer optimal treatment and prevent hypertrophic scar formation. Wound healing has three phases: inflammation, proliferation and remodeling [4, 5].

The dorsal area of the hands is thin and susceptible to hypertrophic scar formation. Dorsal scarring of the hands may not only inhibit passive flexion at the metacarpophalangeal joint but in some severe cases further result in hyperextension and subluxation of the joint [6].

A healed burn patient may have varying degrees of scars with functional and aesthetic components. Depending on the depth of the burn injury, post-burn scars are inevitable even with the best treatment. Second-degree deep dermal and full-thickness burns heal by scarring. The post-burn scars may be immature/mature, atrophic/hypertrophic/keloid, stable/unstable, depigmented (vitiligo)/hyperpigmented. They can turn into malignancy as well [7]. Unfortunately, the head and neck area are the most frequently affected area involved in burn injuries [8]. Especially, the neck with its ability to develop severe contractures and its aesthetic importance, deserves more attention [9]. Achieving long-term results with patient satisfaction remains a challenge [10]. Pre-expansion of free and regional axial island flap have all contributed to achieve this goal [11, 12]. The color match of skin grafts might be poor and also not as elastic as face and neck skin [13, 14]. Pre-expansion of tissue is valuable when large areas need to be resurfaced. This helps to cover more surfaces enabling the closure of the donor site. Studies showed that pre-expansion increases vascularization, reliability and the amount of tissue needed to be transferred [15–17]. Pre-expansion also causes atrophy of all expanded tissue layers except the epidermis that makes the flaps become thinner [18]. If there is no scar formation and the donor site can be closed primarily, then local options should be preferred. Supraclavicular flaps are preferred to infraclavicular flaps because they have greater proximity as well as better skin and tissue match to the affected areas when compared with infraclavicular flaps. Pre-expanded groin flaps show thinner dermis, expand easily and can be harvested without patient repositioning. If locoregional options cannot be used, in comparison to scapular and parascapular flaps, pre-expanded groin flaps are preferred (**Figure 1**).

As a rule, surgical treatment for post-burn contractures should not be undertaken during healing and scarring which usually takes 1 year. The surgical management of any post-burn contracture involves complete release of contracture. To decrease the requirement for skin cover, incision can be performed. To have a relatively bloodless field, incision line can be infiltrated with 1:200,000 adrenaline solution. The limb contractures can be released under tourniquet which should be deflated after complete release and hemostasis is achieved. Generally, for the patients who have received pre-operative physical therapy and their scars have become soft, incision rather than excision is applied to release the contracture. For example, in a case of post-burn contracture of neck, the scars may extend from chin, neck onto the chest and even abdomen. In this case, partial excision of hypertrophic scars may sometimes be done. If there is a contracture, it should be completely released. In severe long-standing contractures, the musculotendinous units and neurovascular structures can be shortened. Hence, complete release might be impossible. For example, if the joints are subluxated or dislocated, complete release might be impossible. In this case, the possible release is done, and then, full correction is achieved by serial splintage, skin/skeletal traction or by using the modern distractor systems. After the full correction is performed, then the skin is covered over the area. After releasing the contracture, the defect must be covered by using skin grafts or a skin flap [7].

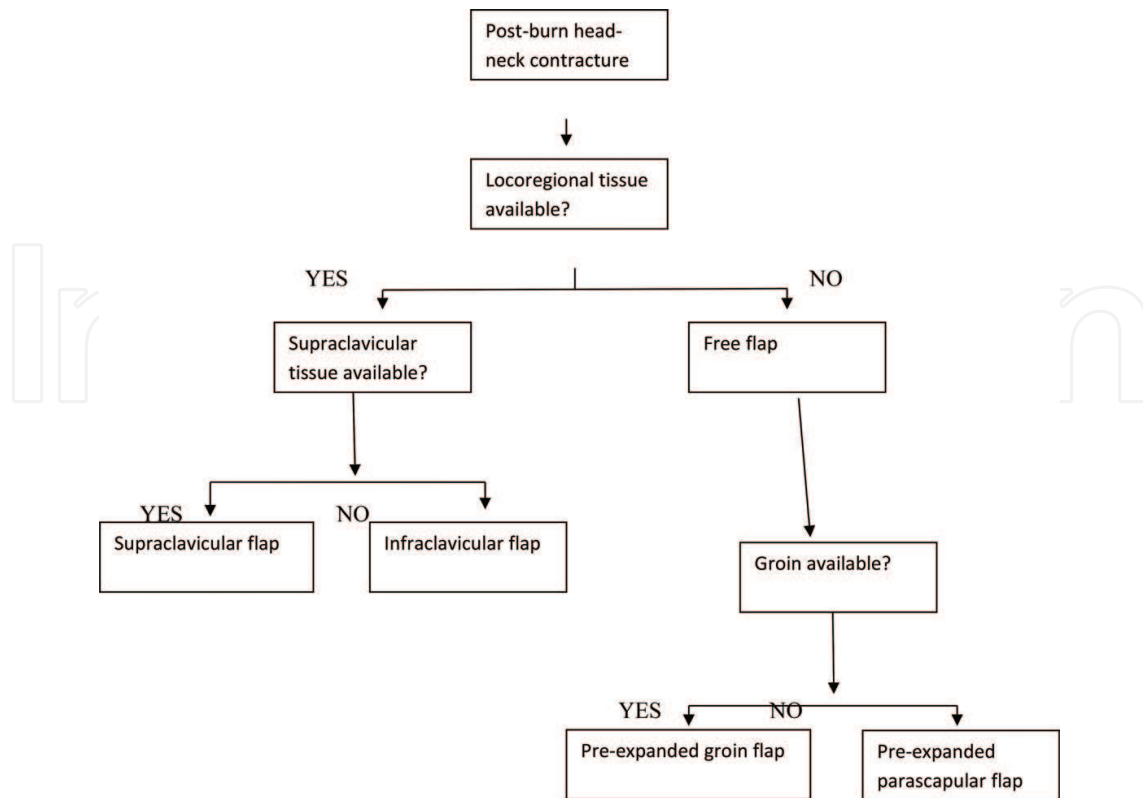


Figure 1. Post-burn treatment algorithm for head and neck contractures.

1.1. Skin graft

When we use the grafts sheet, grafts are preferred and expansion should not be preferred [13, 19, 20]. The junction line of the grafts' sheets should be parallel to the joint motion axis. After immediately release, the skin grafts are applied. Generally, contractures are treated with split skin grafts of intermediate or thick variety. This helps the donor site to heal up spontaneously.

1.2. Skin flaps

If the contracture release is likely to open up the joint of the hands and feet or tendon nerve, surgery is planned at a later date, for example, for old healed electrical burns, the skin flap is a must. The surgeon must provide a flap cover after release of contracture. If the defect is located in a cosmetic area and the reconstruction with a flap is thought to give a better cosmetic result, then covering a flap should be considered. For example, to repair upper lip ectropion of a male patient, the flap can be provided from scalp or upper neck. If it is a female patient, a graft cover is needed to repair upper lip ectropion.

1.3. Donor sites

For the split-skin grafts, thighs are usually used for harvesting. In a patient with severe burn and extensive scar formation, the grafts may be harvested from legs, abdomen and upper

limb, scalp or back. In cases with multiple and massive contractures, the donor sites should be checked and plan charted out for “which donor site for which contracture.” For neck, axilla and facial resurfacing, large sheets are important to be required while comparatively smaller pieces of graft are adequate for eyelid or finger contractures [7].

1.4. Postoperative care

The grafts become stable usually in 3 weeks time. Daily physical therapeutic exercises are required to keep the joints in range of motion. These exercises are continued till the grafts mature and range of motion is achieved. Care of the grafted areas is done till the graft loses its tendency to contract and can be pinched and moved over the recipient area [7]. According to Burn Association Repositories’ data, it has been found that 500,000 burn victims seek medical treatment every year, and 39% of these injuries involve upper extremity and hand [2, 21, 22]. There are several risk factors for the formation of hypertrophic scars like young age, infection, skin stretch and anatomic location (axilla, neck) [23].

2. Operative burn scar management

In the acute phase of the thermal injury and during initial scar maturation, scar management can ameliorate hypertrophic scar formation and prevent scar banding. Timing of the operative procedure should allow enough time for complete scar maturation, as premature intervention can result in increased inflammation and additional scarring. Reconstructive procedures usually start 6 months after injury. For the correction of mild and moderate hypertrophic scar contractures, local skin flaps are commonly used to avoid more complex procedures [24]. Simple linear scar bands which can be seen across joints can be treated best with a scar-lengthening Z-plasty. The classic Z-plasty is designed with its central limb along the hypertrophic scar band and with a 60° angle of the lateral limbs. By making the corner 90° before extending the Z-plasty to 60°, perfusion to the tip of the Z-plasty is improved [25]. The flaps can be raised in scar tissue if maintained thick and involving underlying adipose tissue to achieve active lengthening of 75%. Creating the angle to 90° results in lengthening of 125%, however, involves larger limbs. To modify this approach, a series of smaller z-plasties along a scar can be performed. This helps to achieve similar lengthening but avoiding donor site morbidity with larger flaps. While larger flaps are used for axillary contractures, smaller flaps are used for palms and digits [26]. In web space contractures, modifications of plasties and a variety of local flaps are commonly devised [27, 28]. Because of its geometric design, the 5-flap Z-plasty is frequently used to create concavity and lengthening within the web space. Another option is the V-Y advancement flaps that use the supple dorsal tissue which is advanced into web space. These flaps can later on be combined with forms of z-plasties [29]. The second most common contractures behind neck contractures are the axillary scar contractures and they are difficult to improve. With z-plasties, small linear bands can be removed. Larger contractures can be treated with release and thick split thickness skin graft or full-thickness skin graft. Ogawa et al. describe treatment of severe contractures with pedicled flaps or with regional and free tissue transfer [30]. Usually palmar burn scars involve a large surface and result in tight contractures. Mild forms can be treated with a

sequence of z-plasties. If it is a severe contracture, release of the scar may be required leaving a large defect. Full-thickness skin graft can be used to fill this defect. Full-thickness skin grafts are preferred over split-thickness graft because they have a decreased effect of secondary contraction to minimize scarring. If the contracture release leads to exposed tendon or bone, local flaps may be used [31].

2.1. General principles of contracture release

1. Proximal joint contractures should be released before distal contractures. For example, if the shoulder and elbow have limited range of movement, then there is a little value to have a mobile wrist.
2. If there are multiple joints requiring release, each joint should be considered separately and each contracture should be fully released. The Y-V plasty technique simultaneously leads to release of multiple joints.
3. Function is always prior over cosmesis; it is better to have a functioning joint with an albeit disappointing cosmesis than to have a cosmetically perfect joint without mobility. This does not mean cosmesis is not important but it should not take precedence over function.
4. When split-thickness graft is applied over a wound, it will again contract with the potential for recurrent contracture formation. To prevent this, physiotherapy is a method to mobilize the joint. A flap is much more preferred than a split-skin graft. It has its own blood supply and also supplies bulk, which might lead to better cosmetic appearance.
5. Sometimes, the important underlying structures may be exposed and require release. For example, a dorsal release of the ankle joint may leave extensor tendons exposed. In a long-standing contracture, ligaments and tendons may have permanently shortened, and tendon lengthening may be necessary for dorsiflexion.

2.2. Time for surgical contracture release

Burn contracture release is undertaken once it is deemed "mature." Interfering with an active scar leads further contracture formation. Contracture and hypertrophic scar formation increases in the first 6 months, and full scar maturation will occur after 2 years. When the scar is active, it is pliable and amenable to stretching by physiotherapy [32].

To reconstruct the contracture, surgical treatment should be combined with release and split-skin grafting. This recently is called conventional waiting approach. For example, in the acute lower lid treatment, some studies showed that full-thickness grafts reduce the incidence of subsequent ectropion release [33]. It is important that, when flap cover of the defect is planned, this timing restriction is not applicable. Some authors support waiting for 2 or 3 weeks acutely, prior to undertaking release and free flap cover, and have reported success rates of 94% [34].

2.3. How to treat the burn scar contractures

1. Split-skin grafting
2. Local plastic surgical procedures

- a. Z-plasty
- b. Y-V plasty
3. Full-thickness skin grafting
4. Flap cover
5. Artificial skin substitutes
6. Tissue expansion with or without flap cover

When there is a mild contracture which means that there is 50% of joint movement possibility, to lengthen the scar, Z-plasty can be performed. In more severe cases, different surgical procedures are needed.

To remove the contracture, even a band or a sheet of scar tissue must be fully released. Unless local adjacent skin flaps are used, the release and the reconstruction can be considered as two different procedures, e.g., Z-plasty. The contracture release incision must be placed at the meridian of the joint and must be “fish-mouthed” at either end, and should extend into normal tissue medially and laterally. Using a swab on the index finger will “sweep” tissue away from the center contracture and divide “softer” bands. By using this manoeuvre, the extent of the defect to be covered will be increased. It is also designed to be sure that the wound is formed from normal tissue, not scar.

2.3.1. Split-skin grafting

This traditional method of split-skin grafting helps the defect import non-scarred, healthy, non-bulky skin without the need to compromise local tissues. The graft is ideally harvested from buttocks or scalp, which are cosmetically acceptable sites [35]. Once the contracture is fully released and full joint extension is achieved, then the graft is only applied to the wound bed. The ability to release multiple joints at the same sitting is an advantage, but leading to hypertrophic scar formation is a disadvantage. Also, when a split-skin graft is placed on a wound bed, the wound will again contract and recurrence might occur and re-release can be required again.

Because there is a risk such as immobilization difficulty, bleeding and infection, the split-skin grafts are at risk of suboptimal “take.” Then the patient needs physiotherapy for motion of joint especially in children. Donor site morbidity is also a problem.

2.3.2. Local surgical procedures

2.3.2.1. Z-plasty

If there is a contracture which is due to a band, then a “local” procedure which both divides the contracting band and lengthens it is amenable avoiding the need for a donor site. The Z-plasty is a technique that divides the scar contracture and lengthens the band by importing local lateral adjacent tissue. Z-plasty does not create new tissue to lengthen

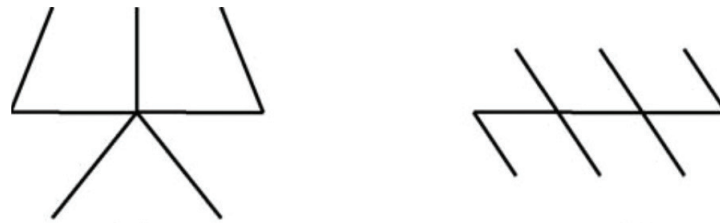

Figure 2. Z-plasty in series (5-flap Z-plasty); Z-plasty in parallel (multiple Z-plasties).

the band, but borrows tissue adjacent to the contracture. Unless there is a short contracture band with a good deal of lax adjacent skin, Z-plasty is possible. These can be thought of as Z-plasty-in-parallel or Z-plasty-in-series [36]. The Z-plasty-in-series (e.g., five-flap Z-plasty) recruits a large amount of adjacent tissue. The Z should always be designed as large as possible. The bigger the Z-plasty is in size the greater the lengthening obtained. When compared the Z-plasty-in-parallel (e.g., multiple single Z-plasties) recruits much less adjacent tissue than Z-plasty-in-series. The actual lengthening obtained is relatively less (**Figure 2**).

If the surrounding tissue is less pliable, this technique can be used. There is a risk of ischemic necrosis when the undermining and subsequent transposition of skin flaps are in an area of scarring and fibrosis (especially the tips). The reorientation of the scar can also result in distortion of the surrounding tissues.

2.3.2.2. Y-V plasty

Y-V plasty is especially useful in linear sheet contractures. The V extends the whole length of the band, and the Y passes into normal skin. The scar is not excised. The flaps simply are pulled forward to form a V [37]. To achieve this, skin laxity should be enough [38], and the “pinch” test is useful to evaluate this [39].

The advantages of this technique:

1. There is little risk of flap tip necrosis because the blood supply of the flaps is less compromised as there is no need for undermining.
2. This technique effects reorientation of scar tissue.
3. The contracture band length is not important. This technique is especially useful in very long contracture bands. The running Y-V plasty is especially useful in these cases.
4. 100% lengthening of the long axis of the contracture which is the theoretical lengthening of the contracture [38].

This is only true when the flap can be advanced half the length of the sides of the V forming the flap. For two reasons, the actual lengthening obtained is much less than it is supposed to be. The first reason is as the burnt tissue has lost its elasticity, it is often difficult to advance the burnt skin. The second reason is interdigitation of each adjacent advancement flap. While

using the “straight-line” advancement flaps, the problem is that the stretching of the skin limits the actual obtained lengthening. That is the reason only Y-V technique can be applied in mild contractures.

5. Y-V plasty is a simple procedure. While the operation is performed, the flap advancement degree can be refined. There is a disadvantage of this technique. Excision of a thick scar band is not actually possible, and there are poor cosmetic results (**Figure 3**).

The W-plasty, double-reverse V-Y plasty [40] and X-plasty [41] are the variations of the methods described above. To remove web-shaped burns, the seven-flap plasty has been described [42].

2.3.3. Full-thickness skin grafting

After the contracture release is complete, reconstruction with full-thickness grafting has a better texture match than with split-skin grafting, and is associated with less recurrence [13]. A full-thickness graft provides less wound contraction, because it has more dermis in the graft. After large burns, there may be limited available skin; thus in such cases, full-thickness grafts are impractical. Taking graft is much more tenuous than with split-skin grafts, when a contour to the underlying bed is required, like whole cheek, which is not a flat surface. Full-thickness grafts need a healthy bed on which to take and leave a donor site. They usually exhibit hyperpigmentation which causes poor cosmetic results.

2.3.4. Flap cover

Flap cover can be either a pedicled flap or free flap. To release the burn contracture, both local [43] and free [44] fasciocutaneous flaps are successfully used. In most of the superficial burns, perforators to the deep fascia are usually protected. In this case, a burn scar may itself be used as part of this flap [43]. In large burn areas, local pedicled flaps are sometimes inappropriate, however, due to the lack of local skin plasticity or simply a paucity of available or acceptable donor sites. In this situation, using a free flap should be considered. The latissimus dorsi, serratus anterior, lateral arm, scapular, gracilis, anterolateral thigh, arterialised venous

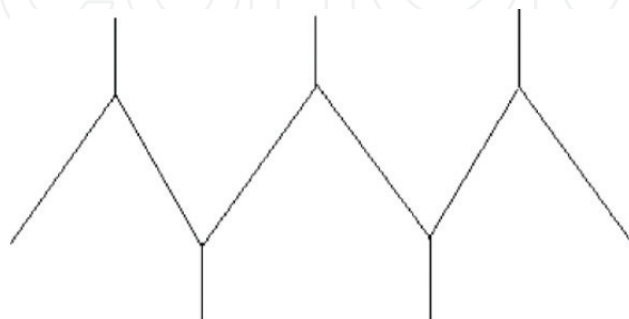


Figure 3. Y-V plasty. V is marked along the contracture band and Y extension passes into normal tissue on each side.

and temporalis fascial flaps are generally used [34]. There is a wide variety of flap choice which allows the surgeon to make judgments according to each individual case. There is no risk for recurrence, and this is the key advantage of flap. Free flaps may lead to an unacceptable cosmetic result because they import tissue different in color, thickness and texture. The flaps size must be as the same size as the defects size. Free flaps lead to a large donor defect and often require themselves a covering split-skin graft. Usually the adjacent tissue is burnt and the thick hypertrophic nature of the scar may make dissection of the recipient vessel difficult. Microvascular circulation should be kept up at higher level. Post-operative complications including complete or partial failure are disastrous. The free flap is an expensive and demanding procedure. It is a good option to apply when only one joint has a severe contracture from broad sheet of scar in the extremities.

2.3.5. Artificial skin substitutes

Following Yannas and Burke's original design, artificial skin templates have been developed [45]. Integra is a bilayer artificial dermis product consisting of porous bovine collagen spongy matrix combined with an overlying temporary epidermal substitute comprised of a silicone sheet. Combination of bilayer artificial dermis with split-skin grafting has been used by Soejima to reconstruct burn contractures [35]. The skin quality resembles full-thickness skin and also there is improved flexibility and suppleness, and scar hypertrophy does not exist [46]. There is reduced inflammatory response accompanying artificial skin substitutes, thus leading to reduced contraction. Donor site morbidity from split skin graft harvesting lower take rates than conventional autografts, more intensive dressing requirements and higher cost implications are the disadvantages [47]. This procedure has two steps. Sometimes it is noticed that areas of keloid scarring (and joint extremities in children) do not give good response to artificial dermis and tend to lead to recontracture or hypertrophic scar formation [35]. Hunt et al. treated a small series of neck contractures with Integra and they all developed recontracture [48]. The results of Integra over joints are disappointing despite adequate splintage [46]. In the management of complex wounds, Integra has been successful, but contamination and subsequent infection can lead to adverse results. A multicenter post-approval study in the United States including 216 burn injury patients found that the total incidence of infection in Integra-treated sites was 16.3% [49]. Another multicenter study managed with Integra following release of scar contractures noted a 20% infection rate. The second most common complication underneath Integra was fluid collection with 14% [50]. Matriderm is a thin (1 mm) single layer dermal matrix composed of collagen types I, III, and V and it has been marketed as a single-stage dermal template for reconstruction [51].

2.3.6. Expansion of tissue with or without flap cover

Expansion of tissue is a simple procedure. The color, texture and thickness of the expanded skin is the same as adjacent skin. Tissue expanders together with a pre-expanded free [52] or fasciocutaneous flap [53] can be used in contractures caused by burns. Expansion of tissues helps the maximum utilization of the non-involved areas.

The number of new scars and donor site morbidity is reduced. Neck, chest and scalp are the most suitable areas where tissue expansion is commonly performed. In the lower limb, expansion is especially difficult in the burned extremity [54]. While planning the expansion, it is often difficult to predict the size of the defect. Expansion has the risks of infection, leakage and skin ischemia, and even failure. The patients should attend regular follow-up to improve outcomes and reduce complication rates.

3. Clinical assessment

1. Is the reason for the contracture an intrinsic force or an extrinsic force?

For example, if there is a burn scar on the cheek, then lower lid ectropion can occur without any intrinsic lower eyelid deformity.

2. How is the severity of the contracture? Is the joints range of motion more than 50%?
3. Is the cause of the contracture a broad sheet of scar or a band of scar?
4. What is the cause of the contracture? If it is a band, then is it surrounded by normal tissue or a burned tissue?
5. Check if the band includes only one joint or if it involves other joints.

Below, there is an algorithm to help surgeons to choose the best reconstruction process for burn contractures after release (Figures 4 and 5) [32].

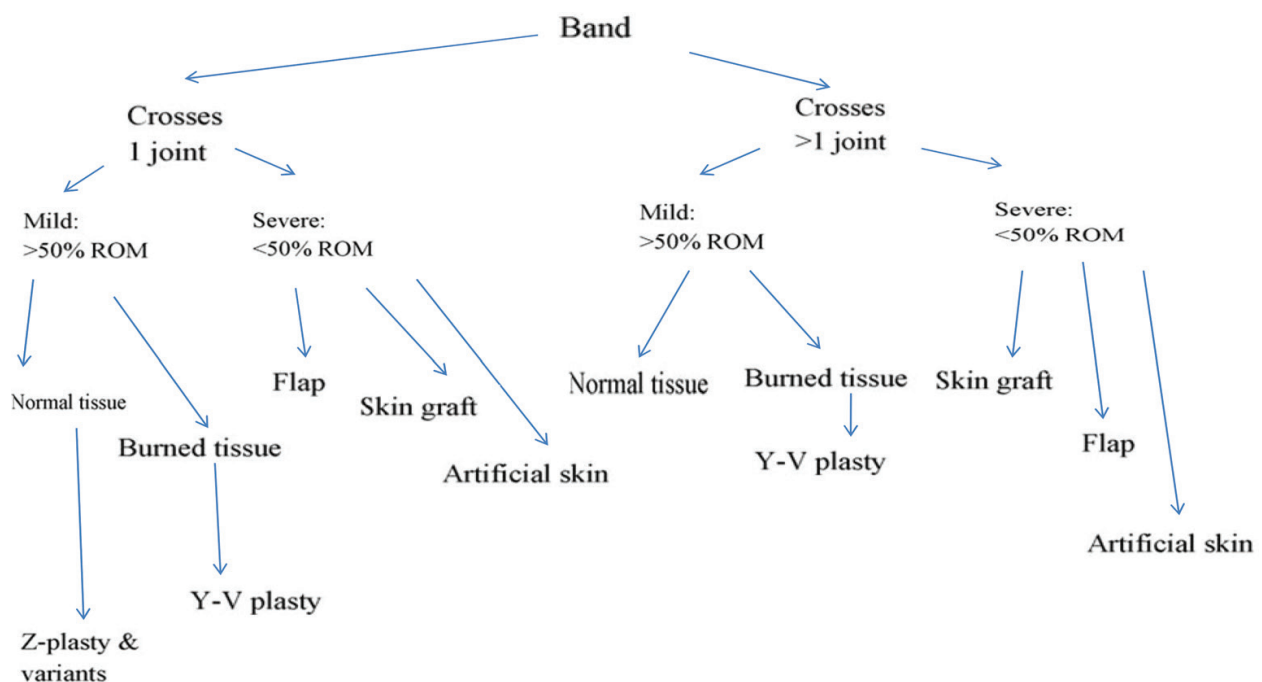


Figure 4. Algorithm for the cover of burn contractures of the extremities after release: band contracture (ROM = range of motion).

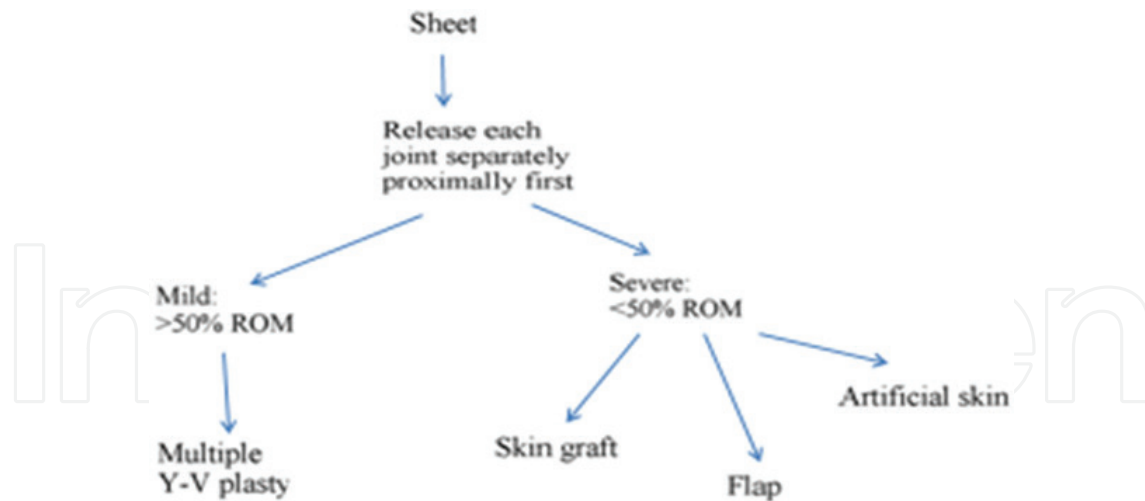


Figure 5. Algorithm for the cover of burn contractures of the extremities after release: broad sheet of scar (ROM = range of motion).

4. Conclusion

The algorithms above are an attempt to simplify the approach to burn contracture release. Naturally, there are situations where the algorithm might not be applicable, and the surgeon, in all such cases, must plan an approach according to knowledge and experience.

Author details

Pertevniyal Bodamyalızade

Address all correspondence to: pniyal@gmail.com

Near East University Hospital, Faculty of Medicine, North Nicosia, Northern Cyprus

References

- [1] Stekelenburg CM, Mark RE, Verhaegen PDHM, et al. Perforator-based flaps for the treatment of burn scar contractures: A review. *Burns & Trauma*. 2017;**5**:5
- [2] McKee DM. Acute management of burn injuries to the hand and upper extremity. *Journal of Hand Surgery*. 2010;**35**(9):1542-1544
- [3] Monstrey S, Hoeksema H, Verbelen J, et al. Assessment of burn depth and burn wound healing potential. *Burns*. 2008;**34**(6):761-769
- [4] Kwan P, Hori K, Ding J, et al. Scar and contracture: biological principles. *Hand Clinics*. 2009;**25**(4):511-528
- [5] Tredget EE, Levi B, Donelan MB. Biology and principles of scar management and burn reconstruction. *The Surgical Clinics of North America*. 2014;**94**(4):793-815

- [6] Graham TJ, Stern PJ, True MS. Classification and treatment of postburn metacarpophalangeal joint extension contractures in children. *Journal of Hand Surgery*. 1990;**15**(3):450-456
- [7] Goel A, Shrivastava P. Post-burn scars and scar contractures. *Indian Journal of Plastic Surgery*. 2010;**43**(Supplement 1)
- [8] Prasad JK, Bowdwin ML, Thomson PD. A review of the reconstructive surgery need of 3167 survivors of burn injury. *Burns*. 1991;**17**:302-305
- [9] Edlich RF, Nichter LS, Persing JA. Burns of the head and neck. *Otolaryngologic Clinics of North America*. 1988;**12**:361-388
- [10] Angrigiani C. Aesthetic microsurgical reconstruction of anterior neck burn deformities. *Plastic and Reconstructive Surgery*. 1994;**93**:507-518
- [11] Ninkovic M, Moser-Rumer A, Ninkovic M, et al. Anterior neck reconstruction with pre-expanded free groin and scapular flaps. *Plastic and Reconstructive Surgery*. 2004;**113**:61-68
- [12] Pallua N, von Heimburg D. Pre-expanded ultra-thin supraclavicular flaps for (full-) face reconstruction with reduced donor-site morbidity and without the need for microsurgery. *Plastic and Reconstructive Surgery*. 2005;**115**:1837-1844
- [13] Iwuaqwu FC, Wilson D, Bailie F. The use of skin grafts in postburn contracture release: A 10-year review. *Plastic and Reconstructive Surgery*. 1999;**103**:1198-1201
- [14] Voinchet V, Bardot J, Echinard C. Advantage of early burn excision and grafting in treatment of burn injuries of the anterior cervical region. *Burns*. 1995;**21**:126-128
- [15] Argenta LC. Controlled tissue expansion in reconstructive surgery. *Plastic and Reconstructive Surgery*. 1990;**86**:520-529
- [16] De Filippo RE, Atala A. Stretch and growth: The molecular and physiologic influences of tissue expansion. *Plastic and Reconstructive Surgery*. 2002;**109**:2450-2462
- [17] Cherry GW, Austad E, Pasyk K, et al. Increased survival and vascularity of random pattern skin flaps elevated in controlled, expanded skin. *Plastic and Reconstructive Surgery*. 1983;**72**:680-687
- [18] Van Rappard JH, Sonneveld GJ, Borghouts JM. Histologic changes in soft tissues due to tissue expansion (in animals studies and humans). *Facial Plastic Surgery*. 1998;**5**:280-286
- [19] Harrison CA, MacNeil S. The mechanism of skin graft contraction: An update on current research and potential future therapies. *Burns*. 2008;**34**:153-163
- [20] Rudolph R, Ballantyne DL. Skin Grafts. In: McCarthy JG, editor. *Plastic Surgery*. Vol. 1. Philadelphia: W.B. Saunders Co; 1990. pp. 221-274
- [21] Ng D, Anastakis D, Douglas LG, et al. Work-related burns: A 6 year retrospective study. *Burns*. 1991;**17**(2):151-154
- [22] Sheridan RL, Hurley J, Smith MA, et al. The acutely burned hand: Management and outcome based on a ten year experience with 1047 acute hand burns. *The Journal of Trauma*. 1995;**38**(3):406-411

- [23] Butzelaar L, Ulrich MM, Mink van der Molen AB, et al. Currently known risk factors for hypertrophic skin scarring: A review. *Journal of Plastic, Reconstructive & Aesthetic Surgery*. 2016;**69**(2):163-169
- [24] Hop MJ, Langenberg LC, Hiddingh J, et al. Reconstructive surgery after burns: A 10-year follow-up study. *Burns*. 2014;**40**(8):1544-1551
- [25] Rohrich RJ, Zbar RI. A simplified algorithm for the use of Z-plasty. *Plastic and Reconstructive Surgery*. 1999;**103**(5):1513-1517 [quiz: 1518]
- [26] Sorkin M, Cholok D, Levi B. Scar management of the burned hand. *Hand Clinics*. 2017
- [27] Sari E, Tellioglu AT, Altuntas N, et al. Combination of rhomboid flap and double Z-plasty technique for reconstruction of palmar and dorsal web space burn contractures. *Burns*. 2015;**41**(2):408-12
- [28] Grishkevich VM. First web space post-burn contracture types: Contracture elimination methods. *Burns*. 2011;**37**(2):338-347
- [29] Peker F, Celebiler O. Y-V advancement with Z-plasty: An effective combined model for the release of postburn flexion contractures of the fingers. *Burns*. 2003;**29**(5):479-482
- [30] Ogawa R, Hyakusoku H, Murakami M, et al. Reconstruction of axillary scar contractures—retrospective study of 124 cases over 25 years. *British Journal of Plastic Surgery*. 2003;**56**(2):100-105
- [31] Karanas YL, Buntic RF. Microsurgical reconstruction of the burned hand. *Hand Clinics*. 2009;**25**(4):551-556
- [32] Hudson DA, Renshaw A. An algorithm for the release of burn contractures of the extremities. *Burns*. 2006;**32**:663-668
- [33] Lille ST, Engrav LH, Caps MT, Orcutt JC, Mann R. Full-thickness grafting of acute eyelid burns should not be considered taboo. *Plastic and Reconstructive Surgery*. 1999;**104**(3):637-645
- [34] De Lorenzi F, van der Hulst R, Boeckx W. Free flaps in burn reconstruction. *Burns*. 2001;**27**:603-612
- [35] Soejima K, Nozaki M, Sasaki K, Takeuchi M, Negishi N. Reconstruction of burn deformity using artificial dermis combined with thin splitskin grafting. *Burns*. 1997;**23**:501-504
- [36] Hudson DA. Some thoughts on choosing a Z-plasty: The Z made simple. *Plastic and Reconstructive Surgery*. 2000;**106**(3):665-671
- [37] Ebbehøj J. Y to V instead of Z to N. *Burns*. 1983;**10**:121
- [38] Lai CS, Lin SD, Tsai CC, Tsai CW. Running Y-V plasty for burn scar contracture. *Burns*. 1995;**21**:458-462
- [39] Cooper MACS. The multiple Y-V plasty in linear burn scar contracture release. *British Journal of Plastic Surgery*. 1990;**43**:145-149

- [40] Askar I. Double-reverse V–Y plasty in postburn scar contractures: A new modification of V–Y plasty. *Burns*. 2003;**29**(7):721-725
- [41] Vartak A, Keswani MH. X-plasty for repair of burn contractures. *Burns*. 1992;**18**(4):326-328
- [42] Suliman MT. Experience with the 7 flap-plasty for the release of burns contractures. *Burns*. 2004;**30**(4):374-379
- [43] Hallock GG. The role of local fasciocutaneous flaps in total burn wound management. *Plastic and Reconstructive Surgery*. 1992;**90**(4):629-635
- [44] Mast BA, Douglas Newton E. Aggressive use of free flaps in children for burn scar contractures and other soft tissue deficits. *Annals of Plastic Surgery*. 1996;**36**:569-575
- [45] Yannas IV, Burke JF. Design of artificial skin. I. Basic design principles. *Journal of Biomedical Materials Research*. 1980;**14**:65-81
- [46] Young RC, Burd A. Paediatric upper limb contracture release following burn injury. *Burns*. 2004;**30**:723-728
- [47] Heimbach D, Luterman A, Burke J, et al. Artificial dermis for major burns: A multi-center randomized clinical trial. *Annals of Surgery*. 1988;**208**:313-320
- [48] Hunt JA, Moisidis E, Haertsch P. Initial experience of Integra in the treatment of post-burn anterior cervical neck contracture. *British Journal of Plastic Surgery*. 2000;**53**(8):652-658
- [49] Heimbach DM, Warden GD, Luterman A, et al. Multicenter postapproval clinical trial of Integra dermal regeneration template for burn treatment. *The Journal of Burn Care & Rehabilitation*. 2003;**24**:42-48
- [50] Frame JD, Still J, Lakhel-LeCoadou A, et al. Use of dermal regeneration template in contracture release procedures: A multicenter evaluation. *Plastic and Reconstructive Surgery*. 2004;**113**:1330-1338
- [51] Theodore TN, Chiang HA, Leavitt T, Ozambela M, Orgill DP. Plastic and reconstructive surgery. Tissue-Engineered Skin Substitutes. *Regenerative Medicine*. December 2015;**136**(6):1379-2015
- [52] Santanelli F, Grippando FR, Ziccardi P, Onesti MG. The role of preexpanded free flaps in revision of burn scarring. *Burns*. 1997;**23**(7-8):620-625
- [53] Stuffer M, Papp C. Reconstruction of large scar areas with controlled skin expansion combined with fasciocutaneous flaps. *Burns*. 1991;**17**(2):166-169
- [54] Pisarski GP, Mertens D, Warden GD, Neale HW. Tissue expansion complications in the paediatric burns patient. *Plastic and Reconstructive Surgery*. 1998;**102**:1008-1012