

# We are IntechOpen, the world's leading publisher of Open Access books Built by scientists, for scientists

4,800

Open access books available

122,000

International authors and editors

135M

Downloads

Our authors are among the

154

Countries delivered to

TOP 1%

most cited scientists

12.2%

Contributors from top 500 universities



WEB OF SCIENCE™

Selection of our books indexed in the Book Citation Index  
in Web of Science™ Core Collection (BKCI)

Interested in publishing with us?  
Contact [book.department@intechopen.com](mailto:book.department@intechopen.com)

Numbers displayed above are based on latest data collected.  
For more information visit [www.intechopen.com](http://www.intechopen.com)



---

# Total Laparoscopic Hysterectomy

---

Nidhi Sharma and Vanusha Selvin

Additional information is available at the end of the chapter

<http://dx.doi.org/10.5772/intechopen.75652>

---

## Abstract

The applications of minimally invasive pelvic surgery continue to grow. This chapter focuses primarily on the preoperative evaluation, surgical technique and post-operative care of total laparoscopic hysterectomy. Since laparoscopic assisted vaginal hysterectomy is a slight modification of the procedure it is not being discussed separately. The major physiologic obstacles to safe laparoscopy include pregnancy, increased intra cranial pressure, abnormalities of cardiac output and gaseous exchange in the lung, chronic liver diseases and coagulation disorders. In a redo surgery there may be problems of laparoscopic port entry.

**Keywords:** hysterectomy, laparoscopy, surgery, total laparoscopic hysterectomy, laparoscopic supracervical hysterectomy, minimally invasive gynecological procedure

---

## 1. Introduction

The invention of Veress needle by Sir Janos Veres, an internist working in Hungary on tuberculosis, launched the era of laparoscopy [1]. The first laparoscopic hysterectomy was performed by Reich in 1989 [2]. Laparoscopic hysterectomy carries an edge over open hysterectomy as it provides a better magnification of anatomy and pathology [3–6].

The three main considerations are ergonomics, task analysis and minimizing injury and adhesions. When we apply the baseball diamond concept of trocar placement, the target in total laparoscopic hysterectomy is the uterine artery.

## 2. Preoperative evaluation

The goal of preoperative evaluation is to identify and modify risk factors that might adversely affect anesthetic care and surgical outcome.

### 2.1. History

1. Pulmonary disease—either obstructive or restrictive lung disease.
2. Cardiac disease
3. History of previous abdominal surgeries
4. History of coagulation disorders in self or in family
5. Previous history of anesthesia related complications
6. History of dentures or prosthetic devices
7. Previous operative records if any

### 2.2. Physical examination

1. Assessment of head and neck
2. Assessment of lungs and heart
3. Vascular and neurological examination
4. Airway evaluation by anesthetist
5. Vital signs
6. Abdominal examination to look for scar site and to decide on alternate port site and to assess the extent of adhesions.

### 2.3. Basic prerequisites before laparoscopic surgery

1. Hemoglobin
2. Blood urea and creatinine
3. Serum electrolytes
4. Liver function test
5. Coagulation profile
6. ECG and chest X-ray
7. Serology testing
8. Ultrasound abdomen and pelvis
9. Urine analysis

Tests obtained within 6 months of surgery are acceptable if there is no significant change in patient medical history.

## 2.4. Patient education

The expectations with regard to the surgery should be clearly discussed with the patient. Anesthetic and surgical procedure and complications should be clearly explained to the patient. Risk of perioperative morbidity and mortality, post op pain, recovery, length of stay everything in detail should be counseled to the patient prior to surgery. Detailed informed consent regarding chance of conversion to laparotomy, chance of visceral injury should be obtained.

## 3. Surgical technique

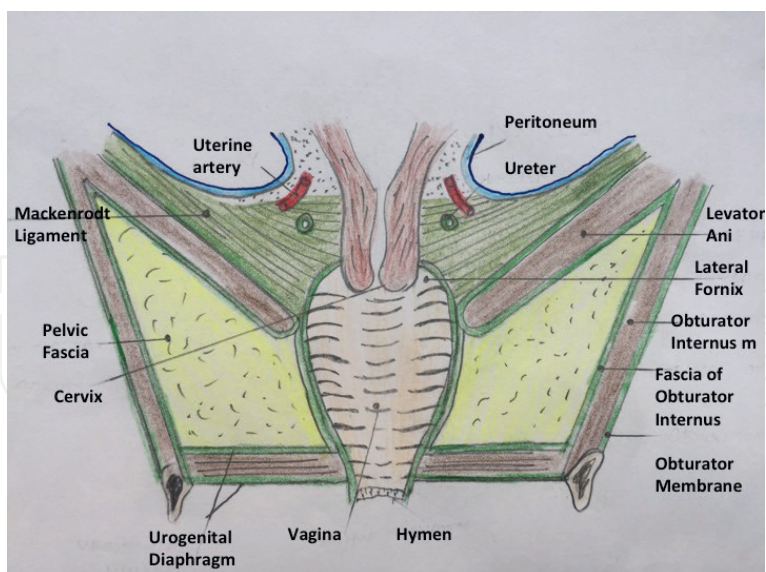
The laparoscopic hysterectomy is classified depending on the extent of dissection done laparoscopically (**Table 1**). The knowledge of anatomy is essential before hysterectomy (**Figure 1**). The sterile precautions are maintained to arrange and assemble the laparoscopy instruments (**Figure 2**).

### 3.1. Positioning

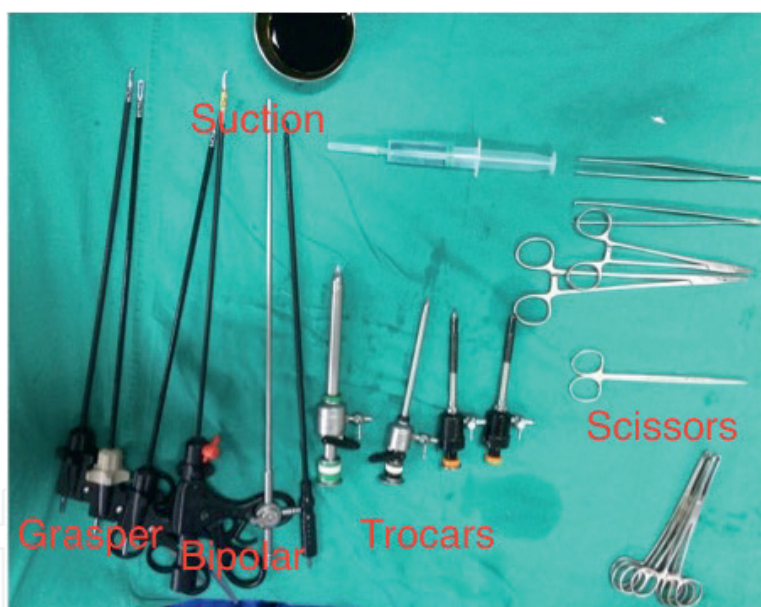The patient is given general anesthesia, with oral tracheal intubation. The patient is positioned in dorsal decubitus position Loyd Davis Position. The legs are positioned in the low lithotomy position with thighs flexed at 30° and knees supported, the arms are positioned along the body, and the buttocks extending slightly over the edge of the surgical table. The bladder is catheterized. The surgeon is positioned to the left of the patient. The first assistant

Hysterectomy Type	Description
I	Diagnostic laparoscopy and vaginal hysterectomy
II	Laparoscopic assisted vaginal Hysterectomy
III	Laparoscopic hysterectomy
IV	Total Laparoscopic Hysterectomy
V	Laparoscopic supracervical Hysterectomy
VI	Vaginal Hysterectomy with Laparoscopic Vault suspension
VII	Laparoscopic Hysterectomy with lymphadenectomy
VIII	Laparoscopic hysterectomy with lymphadenectomy and omentectomy
IX	Laparoscopic radical hysterectomy and lymphadenectomy

**Table 1.** The classification of laparoscopy assisted hysterectomy.

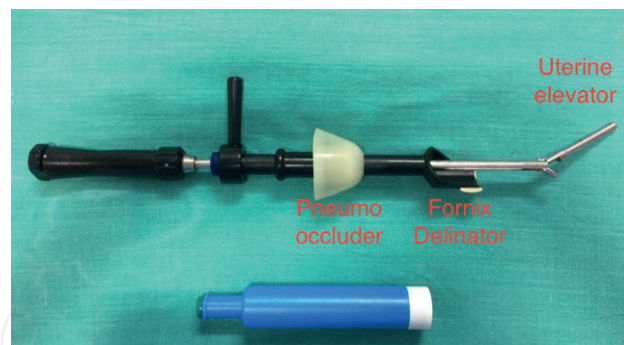


**Figure 1.** A sagittal section of a cadaveric specimen of female pelvis showing the anterior and posterior relation of the uterus.



**Figure 2.** The laparoscopy instruments required are arranged in a sterile cart: grasper, bipolar, scissors, suction irrigation, trocars and cannula. One 10 mm and three 5 mm ports are necessary.

is on the right side of the patient. The second assistant does the uterine manipulation and he stands between the legs of the patient. A foam mattress is placed directly under the patient to prevent sliding during steep Trendelenburg. The table is kept in a low position to enable wrist movements for intracorporeal knotting. The monitor to directly face each surgeon at the angle of resting eye, i.e., 30°, to promote an ergonomic working environment. The surgeon, the target tissue and the monitor should be in straight line. The height of the table should be about the half of surgeons' height to enable wrist movements.



**Figure 3.** The uterine manipulator is used to antevert the uterus and delineate the fornixes for laparoscopic colpotomy. The pneumoperitoneum is maintained by the soft silastic parts of the instrument that prevent the air leak after colpotomy.

### 3.2. Vaginal manipulation

Uterine cannulation is performed with a specific instrument named The Clermont-Ferrand type Karl Storz Uterine Manipulator or RUMI - Uterine Manipulator (**Figure 3**).

First, a Sims speculum is placed into the vagina. Cervix is held with a tenaculum and the uterus is sounded. The cervix is dilated to Hegar number 9. RUMI tip used should be selected according to the patient after sounding the uterine cavity with a uterine sound. If the uterine cavity is 7, a 6-cm tip should be selected. The sizes available are 6, 8, or 10 cm. The distal end of the shaft may be dipped in the lubricant prior to attaching the tip. This greatly facilitates the insertion into the uterine cavity. The pneumo-occluder is now slid over the tip and the shaft. Now the Koh cup (3, 3.5, and 4 cm in width) is attached. The Koh cup should be appropriately sized according to the cervix of the patient. This is important because a small ring will not mark the vaginal fornices exactly and only push up the cervix. The delineation of fornices is important because it serves as a landmark till the surgery is complete. A large ring will increase the risk of a ureteral injury. Insert the tip of the RUMI as far into the cervix as it will go. The correct placement is confirmed by palpation or direct visualization. Inflate the Uterine balloon with 5 cc of normal saline to manipulate the uterus and facilitate specimen removal through the vagina at the end of the case. The bladder is catheterized with Foleys catheter. The pneumo-occluder is now inflated with 60 to 100 cc of saline. RUMI II and RUMI arc are recent modifications that facilitate easy manipulation.

### 3.3. Establishing the pneumo-peritoneum

The stomach should be deflated by Ryle's tube insertion and aspiration. First step is to insert the Veress needle following the double click sound at subumbilical incision or the Palmer's point in the left upper quadrant, about 2 to 3 cm below the left costal margin, in the left mid-clavicular line [7]. Now, CO<sub>2</sub> insufflation is done to create pneumoperitoneum to achieve an intra-abdominal pressure of 12 to 14 mmHg [8, 9]. An easy way to confirm intraperitoneal entry is to look for the pressure reading on the insufflator. If the pressure reading is high the Veress needle is likely to be impinging on the omentum. A slight gentle movement will dislodge it. Alternatively bubble test can be done.

### 3.4. Positioning the trocar

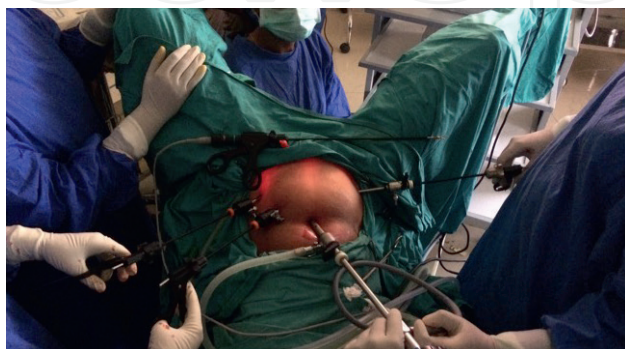Four trocars are positioned: one 10 mm umbilical trocar with a 30° optic and three 5 mm trocars, with one 2 cm medial to the right superior iliac crest, another 2 cm medial to the left anterior superior iliac crest, and a third in the midline, 8–10 cm below the umbilical port. These trocars are placed lateral to the rectus abdominis muscles, 2 cm above and 2 cm medial to the anterior superior iliac spine (**Figure 4**). The last 5 mm trocar can be substituted by a 10–15 mm trocar during surgery for the introduction of suture needles and for suturing of the vaginal vault. A complete survey of the abdomen to rule out any visceral injury at the time of entry is done. The lower quadrant trocar sleeves are placed under direct vision. In the case of very voluminous uteri, the trocars can be positioned more cephalad using the diamond baseball concept.

### 3.5. Visualization of pelvic organs

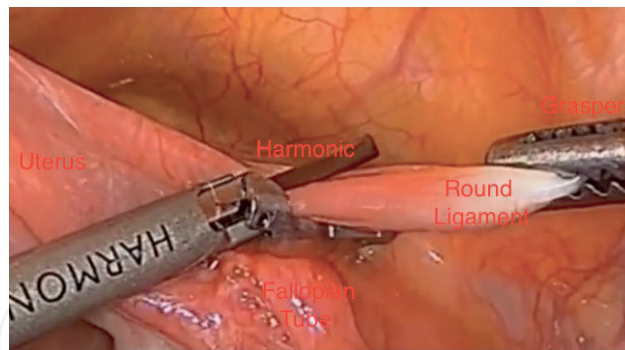
After inserting the ports the trocars are withdrawn and instruments are inserted. The patient is placed in 15° head low position to move the bowel loops away from pelvis. The small intestine loops are mobilized upwards to visualize the uterus, tubes, ovaries, round ligaments and infundibulopelvic ligaments. The surgeon uses a grasper and a bipolar and follows the manipulation angle of 60°. The Azimuth angle is maintained at 30°. Manipulation angle is the angle between the two operating instruments. Azimuth angle is the angle between the scope and the operating instrument. The first assistant holds the scope with the left hand and uses the Maryland grasper forceps in the right hand. If adhesions are seen they should be gently released. Releasing adhesions between sigmoid colon and utero-ovarian ligament permits the correct exposure of the infundibulopelvic ligament and posterior surface of the uterus. The sequence to be followed is look, hook, coagulate and cut. Thick tissue should be cauterized in small steps with coagulating cautery set at 35 W to prevent charring. The uterus is mobilized by the second assistant and is maintained cranially and anteriorly.

### 3.6. Coagulation and section of round ligament

The round ligament is secured with traction by the first assistant, making possible its exposure for the start of the surgery. The round ligament is coagulated at a distance of 2 to 3 cm from the lateral pelvic wall using a bipolar cautery (**Figure 5**). The coagulation of the round



**Figure 4.** Laparoscopic port positions for total laparoscopic hysterectomy with ipsilateral ports. The infraumbilical port is the telescopic port. The right iliac fossa port is the traction port and the two left iliac fossa ports are the operating ports.

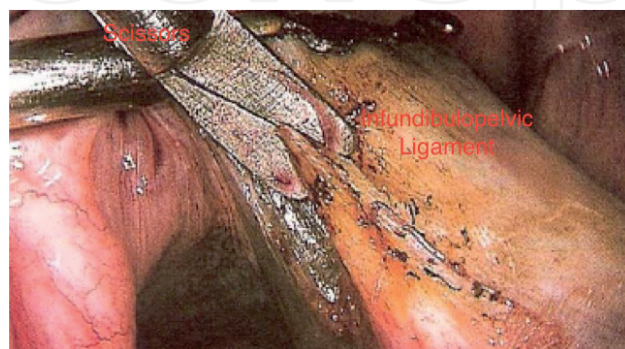


**Figure 5.** The round ligament is held 2–3 cm from the lateral pelvic wall. The ligament is coagulated with bipolar and cut with scissors.

ligament near the uterus is difficult as there is an artery to the round ligament which may bleed. This is followed by opening the anterior leaflet of the broad ligament to the vesico-uterine peritoneal reflection.

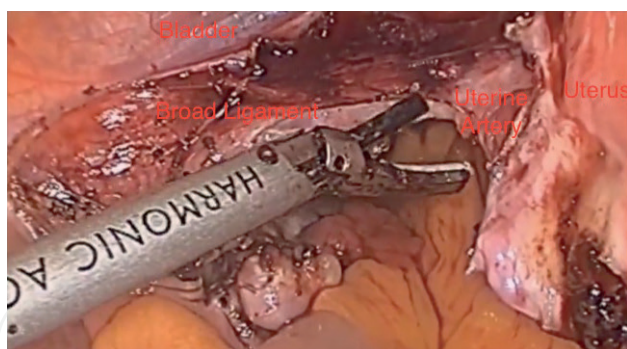
### 3.7. Coagulation and section of the infundibulo-pelvic ligament

The first assistant should secure the adnexa and apply traction in a direction opposite to the operating side (**Figure 6**). The coagulation and sectioning of the ligament should be progressive, plane to plane (peritoneum, followed by the vessels and connective tissue). The infundibulopelvic ligament or the tubo-ovarian ligament are now coagulated and with a bipolar grasper and scissors. The infundibulopelvic ligament should be coagulated close to the ovary (hug the ovary) as this helps to avoid injury to the vital structures in the pelvic sidewall. The tubo-ovarian ligament should also be coagulated close to the ovary to prevent injury to the uterine vessel during ovarian conservation. When you want to preserve the adnexa, the coagulation and section is performed proximal to the fallopian tubes and the utero-ovarian ligament. The posterior leaf of broad ligament is opened with incision extending till the internal os being careful not to injure the uterine artery and vein (**Figure 7**). The peritoneum is opened, coagulated and cut till the attachment of the utero-sacral ligaments. The capillaries in the posterior leaf of broad ligament and the parametrial veins that run between the ovary and round ligament should be taken care of.



**Figure 6.** The infundibulopelvic ligament is identified by gentle traction. It is also coagulated with bipolar and cut with scissors.





**Figure 7.** The peritoneum in the broad ligament is opened and uterine vessels are identified at the level of internal os.



**Figure 8.** The loose vesicouterine fold of peritoneum is held with grasper and scissors used to dissect the bladder. The bladder is gently dissected downwards by laparoscopic pledgets or applying traction from the jaws of bipolar.

### 3.8. Mobilization of bladder

The assistant uses an atraumatic forceps to grasp the peritoneum and the bladder in the midline, applying vertical and cranial traction (**Figure 8**). The peritoneum and the adjacent connective tissue are coagulated and sectioned, thus accessing the vesico-vaginal plane and posteriorly to expose the bottom of vesico-uterine sac. The dissection continues in a caudal direction, initially in the midline and then laterally, performing the coagulation and section of the vesico-uterine ligaments thereby mobilizing the bladder off the lower uterine segment. The plane of loose areolar tissue should be identified and opened avoiding injury to the vessels. In women with previous cesarean delivery, there are adhesions between bladder and lower uterine surface and so dissection should be a little high as close to the uterus as possible to avoid bladder injury. It is important to identify and pick small bits of tissue close to the uterus and coagulate and cut them gradually moving down towards the cervix [10]. Alternatively a lateral approach of opening the broad ligament may be the preferred route [11, 12]. During laparoscopic hysterectomy, if the patient has significant adhesions from prior cesarean deliveries, a reverse inferior to superior vesico-uterine fold dissection can be used to dissect the bladder from the uterus [13]. This lateral dissection and accessing the bladder from below can be used as an alternative to the commonly practiced technique of mobilizing the bladder in a superior to inferior fashion at the time of laparoscopic hysterectomy. The anatomy of the space

of Seth can be helpful in identifying the lateral structures of bladder. Space of Seth is bounded laterally by the tangential line joining the maximum bulging on the uterine body and cervix, medially the bladder comes in contact with the uterocervical surface thickening at the level of bladder pillars. Anteriorly there is the undersurface of bladder and anterior leaf of broad ligament, posteriorly there is the uterocervical surface [14].

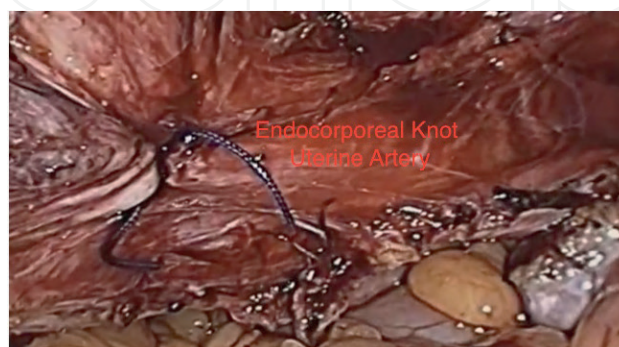
A reevaluation of the route of dissection is advised if fat is encountered because the fat belongs to the bladder and this may indicate that the dissection is moving too close to the bladder. With this the ureter is kept out-of-the-way, since it is mobilized along with the peritoneum.

### 3.9. Secure uterine vessels

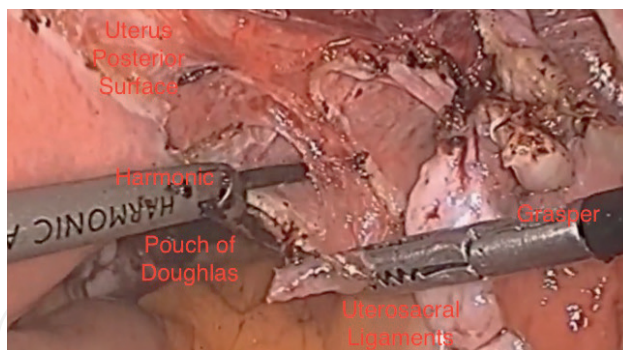
Desiccate the ascending uterine vessels with the bipolar grasper at the level of internal cervical os. The RUMI uterine can be pushed upwards to increase the distance between uterine artery and. The uterine vessels should coagulate till there is vaporization and bubble formation. The uterine vessels should be grasped perpendicularly to coagulate the 7 mm lumen efficiently. If the uterine are grasped obliquely the lumen to be coagulated becomes wider. Grasping the uterine artery perpendicularly is made easier by the new articulating instruments which can change direction and allow the uterine artery to be grasped and coagulated perpendicularly (**Figure 9**). After the coagulation and cutting of uterine arteries the vascular pedicles are deflected laterally and dissection is continued in the avascular plane over the cervix towards the delineated vaginal fornices (**Figure 10**). The ureters should be reconfirmed and the dissection continued close to the uterus [15].

### 3.10. Removal of uterus

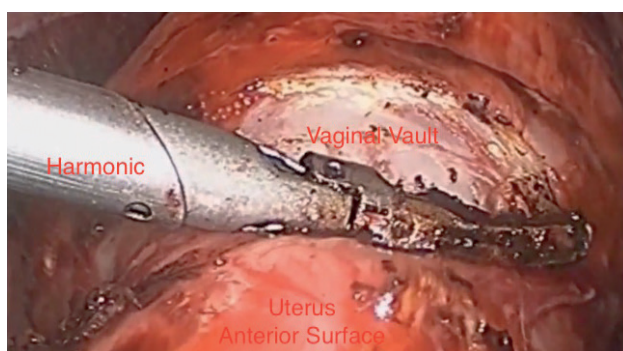
While pushing cephalad with the uterine manipulator, vaginal fornices are identified. It is identified by indentation of the Rumi Koh colpotomizer or by palpation with a laparoscopic instrument. The Harmonic scalpel or laparoscopic monopolar hook is then used to cut circumferentially around the cup, thus uterus with cervix is separated from vaginal apex (**Figures 11 and 12**). In patients with limited vaginal access, the uterus can be morcellated using an electronic morcellator and specimen removed abdominally. It is important to keep the tip of the morcellator in clear view at all times.



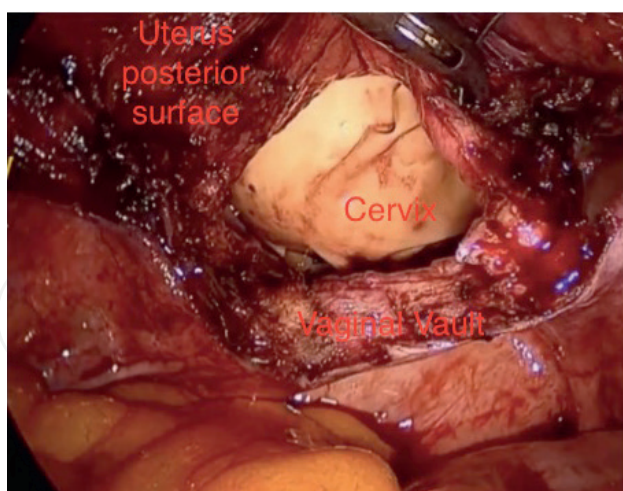
**Figure 9.** The uterine vessels are secured with endocorporeal knotting or harmonic.



**Figure 10.** Uterosacral ligaments are identified and the peritoneal incision is extended to the pouch of Douglas. The peritoneal incision is above the uterosacral ligaments.



**Figure 11.** The vaginal vault is incised with a harmonic or laparoscopy monopolar hook after delineating the fornixes. The vaginal vault is incised above the attachment of uterosacral ligaments.



**Figure 12.** The posterior lip of cervix is seen after vaginal vault is incised. The pneumoperitoneum leakage is prevented by the RUMI manipulator in the vagina.

### 3.11. Vaginal cuff closure

Vaginal cuff should be closed beginning at the margins of angle of the vaginal canal. The barb sutures are continued in a running manner. The vaginal mucosa and the pubocervical and rectovaginal fascia are included in the suture line. Each suture should be placed at 1 cm in distance

from vaginal cuff margins. This is important and can be guessed as a comparison to the wide open jaw of grasper which is 2 cm wide. Distances can be easily underestimated because of the magnification of the laparoscope. Irrigation and suction is performed and hemostasis rechecked. The bidirectional barbed suture is available in which wound tension is evenly distributed across the length of the suture line rather than at the knotted end. No knots are required with bidirectional barbed suture. Since uterosacral ligament attachment to vagina is undisturbed in Total Laparoscopic hysterectomy the vaginal vault fixation is not required.

No routine cystoscopy is needed to ensure ureteral patency and bladder injury except in cases of dense bladder adhesions. However cystoscopy does not identify delayed thermal injury to ureters and bladder.

The pneumoperitoneum is deflated.

### **3.12. Port wound closure**

The fascial defect of the 10 mm trocar in the midline is sutured and the skin is sutured with 3-0 monofilament absorbable suture.

Laparoscopic direct visualization fascial closure methods provide more accurate placement of sutures under direct vision.

Recommendations regarding port wound closure:

1. All ports greater than 10 mm either in midline or lateral should be closed at fascial level.
2. 5 mm ports if manipulated extensively or enlarged significantly during the procedure need to be closed
3. Port closure should include fascia and peritoneum.

The LigaSure Vessel Sealer, The EnSeal—Advanced Tissue Sealing Technology and the Ultracision® harmonic scalpel are newer advances in laparoscopic surgery. Articulating vessel sealer helps to grasp and coagulate the vessel at right angle to the course of the vessel, thereby minimizing the diameter of vessel to be coagulated. Each surgeon should develop his own routine and use the available materials and technology to facilitate the surgical procedure.

## **4. Advantages of laparoscopic hysterectomy**

1. Small surgical wound
2. Short hospital stay
3. Quick recovery
4. No abdominal wound
5. Decrease in intra op bleeding

6. Decrease in post op pain and infection
7. Low incidence of DVT.
8. Early return of bowel activity
9. Less risk of adhesion formation

## **5. Indications for conversion to open procedure**

### **5.1. Planned conversion**

1. Failure to progress
2. Dense or extensive lower abdominal or pelvic adhesions
3. Acute or chronic inflammatory changes causing increased vascularity resulting in tethering or tearing of tissues.
4. Difficulty to maintain pneumoperitoneum due to gas leaks in and around the ports.
5. Poor or inadequate exposure—obesity may preclude placement of ports
6. Altered or aberrant or unclear anatomy
7. Inexperience of the surgeon

### **5.2. Emergency conversion**

1. Technical problem/instrument malfunction
2. Anesthesia related issues like—poorly tolerating pneumoperitoneum
3. Complex viscus injury

The surgeon should keep in mind the time of dissection and the progress made as well as the remaining tasks to be completed. Also the surgeon's threshold for conversion should be low while gaining experience.

## **6. Adhesion prevention during laparoscopic surgery**

1. Minimize tissue damage
2. Perfect hemostasis
3. Minimize length of insufflation
4. Minimize intra-abdominal pressure
5. Adequate irrigation to avoid desiccation

6. Gentle tissue manipulation
7. Physical barriers like Seprafilm/Intercede

## **7. Post-operative pain management**

There is a documented reduction in the narcotic requirement after laparoscopic Hysterectomy when compared to open procedure. It is also associated with earlier return of bowel function, earlier discharge, and improved pulmonary function.

Post op pain is due to irritation of somatic nerve fibers by overdistension of the diaphragm and carbon dioxide pneumoperitoneum related acidic intraperitoneal environment. Peritoneal ischemia, distension neurapraxia are other mechanisms that account for post op pain.

Method of reducing postoperative pain:

1. Infiltration of abdominal wall incision with local anesthetics
2. Intra peritoneal instillation of saline at the end of the procedure
3. Epidural analgesia
4. Complete removal of insufflated gas
5. Postoperative non-steroidal anti-inflammatory drugs

### **7.1. Prophylaxis against deep vein thrombosis**

The addition of deep vein thrombosis prophylaxis should be at the discretion of the operating surgeon based upon the earlier recommendations and risk assessment of that particular patient.

### **7.2. Prevention of post-operative wound infection**

1. Optimize the patient and iatrogenic risk factors.
2. Appropriate use of systemic perioperative antibiotics.
3. Adequate operative site preparation.
4. Avoid unnecessary trauma from hair removal techniques.
5. Avoid wiping off antiseptic after the skin preparation
6. Strict adherence to principles of sterility
7. Wide preparation of skin in case of conversion to laparotomy.
8. Adequate sized skin incisions will prevent ischemia and marginal wound necrosis.
9. Occlusive dressings to be released after 48 h because they might be conducive to bacterial overgrowth.

How to avoid Port site bleeding complications?

1. The trocar and the port should enter the abdomen at 90° to skin surface.
2. Dermal incision should be complete before using the trocar to penetrate the fascia.
3. Surgeon should be familiar with the mechanics of the given trocar.
4. Port placement should be made either in the midline or lateral to the edge of rectus sheath to avoid inferior epigastric artery.
5. Blunt tip ports are preferable to sharp tipped ones.

### **7.3. Post-operative advice**

1. Advice to start on liquids after 6 h and to a regular light diet as tolerated on first day.
2. Bath after 48 h—for skin incision to re-epithelialize.
3. No restriction to walking from first post op day.
4. Resumption to preoperative activity by second week.
5. Regular exercise encouraged after 4 weeks.
6. Resumption of driving depends on mobility, reaction time, patient ability to respond to any road hazard. Usually resumes by 1–2 weeks.
7. Return to work by 2 weeks.
8. Continue Hematinics and Calcium supplements for 3 months.
9. Abstinence for 6 weeks.

### **7.4. How to avoid port site hernia**

1. Minimum number of ports with smallest possible diameter.
2. Violent torqueing of port which can enlarge fascial defect.
3. Slow desufflation of abdomen while removing the ports—rapid removal of ports may draw bowel and omentum into port sites.
4. Before closure of ports shake the abdomen to dislodge the stuck bowel.
5. Closure of fascial defects before patient is extubated.

### **7.5. Port site seroma**

It is a painless ballotable swelling at a healing port site. It usually occurs within 1–5 days post-operatively. There is no evidence of inflammation. It usually resolves spontaneously within days unless complicated by secondary bacterial infection.

## 7.6. Port site tumors

Port site tumor is common when an unexpected malignant specimen is retrieved through one of the ports. Serious complication has been noted in setting of ovarian cancer and to lesser extent in patients with endometrial cancer and rare in cervical cancer patients. The presence of 10–15 mm Hg pneumoperitoneum may facilitate the dispersion of liberated tumor cells throughout the abdomen and to port site during insufflation events. The employment of specimen bags is recommended to retrieve the specimen. Laparoscopic skill level of the surgeon also plays a critical factor.

## 8. Conclusion

Laparoscopy offers the advantage of clear magnified anatomy and pathology. The adhesions can be dissected carefully under vision. To minimize complications the basic principles that should be kept in mind can be summarized.

1. Proper patient selection
2. Adequate experience of the surgeon and assistants
3. Proper port placement
4. Avoid gas leaks
5. Sound surgical techniques
6. Adequate sized incisions
7. Thorough irrigation of port and abdomen before closure
8. Fascial and peritoneal wound closure for 10 mm or larger ports

## Acknowledgements

Authors thank the nursing staff of Department of Obstetrics and Gynecology, Department of Radiology and Department of Anesthesiology, Saveetha Medical College, Chennai, for the care given to the women. We also thank the staff of Operation theaters and staff of blood bank. We thank the Biotechnical Department of Saveetha Medical College and hospital.

We also acknowledge the funds provided by Saveetha University, Chennai for the laparoscopy surgical care for women.

## Conflict of interest

The authors declare that there is no conflict of interest.



## Author details

Nidhi Sharma\* and Vanusha Selvin

\*Address all correspondence to: drbonuramkumar@yahoo.co.in

Saveetha Medical College, Saveetha University, Chennai, India

## References

- [1] Veres J. Neues instrument zur ausfuhrung von brust-oder bauchpunktionen und pneumothoraxbehandlung. *Deutsche Medizinische Wochenschrift*. 1938;**64**:1480-1481
- [2] Reich H, DeCaprio J, McGlynn F. Laparoscopic hysterectomy. *Journal of Gynecologic Surgery*. 1989;**5**:213-216
- [3] Reich H. Laparoscopic hysterectomy. *Surgical Laparoscopy and Endoscopy*. 1992;**2**:85-88
- [4] Liu CY. Laparoscopic hysterectomy: A review of 72 cases. *The Journal of Reproductive Medicine*. 1992;**37**:351-354
- [5] Liu CY. Laparoscopic hysterectomy. Report of 215 cases. *Gynaecological Endoscopy*. 1992;**1**:73-77
- [6] Reich H, McGlynn F, Sekel L. Total laparoscopic hysterectomy. *Gynaecological Endoscopy*. 1993;**2**:59-63
- [7] Palmer R. Instrumentation et technique de la coelioscopie gynecologique. *Gynecologie Et Obstetrique (Paris)*. 1947;**46**:420-431. PMID 18917806
- [8] Gould JC, Philip A. Principles and techniques of abdominal access and physiology of pneumoperitoneum. *Scientific American Surgery*. 2011;**8**:P1-P9
- [9] Molloy D, Kaloo PD, Cooper M, et al. Laparoscopic entry: A literature review and analysis of techniques and complications of primary port entry. *The Australian & New Zealand Journal of Obstetrics & Gynaecology*. 2002;**42**:246-253
- [10] Wang L, Merkur H, Hardas G, Soo S, Lujic S. Laparoscopic hysterectomy in the presence of previous caesarean section: A review of one hundred forty-one cases in the Sydney west advanced pelvic surgery unit. *Journal of Minimally Invasive Gynecology*. 2010;**17**(2):186-191. DOI: 10.1016/j.jmig.2009.11.007
- [11] Sinha R, Sundaram M, Lakhota S, Hedge A, Kadam P. Total laparoscopic hysterectomy in women with previous cesarean sections. *Journal of Minimally Invasive Gynecology*. 2010;**17**(4):513-517. DOI: 10.1016/j.jmig.2010.03.018. PMID: 20621012
- [12] Celle C, Pomés C, Durruty G, Zamboni M, Cuello M. Total laparoscopic hysterectomy with previous cesarean section using a standardized technique: Experience of Pontificia Universidad Catolica de Chile. *Gynecological Surgery*. 2015;**12**(3):149-155

- [13] Nezhat C, Grace LA, Razavi GM, Mihailide C, Bamford H. Reverse vesicouterine fold dissection for laparoscopic hysterectomy after prior cesarean deliveries. *Obstetrics and Gynecology*. 2016;**128**(3):629-633. DOI: 10.1097/AOG.0000000000001593. PMID: 27500328
- [14] Sheth SS. Reverse vesicouterine fold dissection for laparoscopic hysterectomy after prior cesarean deliveries. *Obstetrics & Gynecology*. 2017;**129**(4):749-750. DOI: 10.1097/AOG.0000000000001954
- [15] Manoucheri E, Cohen SL, Sandberg EM, Kibel AS, Einarsson J. Ureteral injury in laparoscopic gynecologic surgery. *Reviews in Obstetrics and Gynaecology*. 2012;**5**(2):106-111

IntechOpen

