

We are IntechOpen, the world's leading publisher of Open Access books Built by scientists, for scientists

4,800

Open access books available

122,000

International authors and editors

135M

Downloads

Our authors are among the

154

Countries delivered to

TOP 1%

most cited scientists

12.2%

Contributors from top 500 universities



WEB OF SCIENCE™

Selection of our books indexed in the Book Citation Index
in Web of Science™ Core Collection (BKCI)

Interested in publishing with us?
Contact book.department@intechopen.com

Numbers displayed above are based on latest data collected.
For more information visit www.intechopen.com



Atrial Flutter: Diagnosis and Management Strategies

Hamid Reza Bonakdar

Additional information is available at the end of the chapter

<http://dx.doi.org/10.5772/intechopen.74850>

Abstract

Atrial flutter (AFL) is a regular, macro reentrant arrhythmia traditionally defined as a supraventricular tachycardia with an atrial rate of 240–320 beats per minute (bpm). Pathophysiology of atrial flutter and atrial fibrillation (AF) is closely related to the similar risk of stroke and they coexist clinically. Atrial flutter is classified to cavotricuspid isthmus (CTI) dependent (or typical) and non-isthmus dependent (atypical). Isthmus is a distinct structure in the right atrium (RA) through which atrial flutter passes and makes a good target for ablation therapy. Ablation is the primary therapy in atrial flutter, particularly in CTI dependent group, with regard to its safety profile and high success rate of approximately 90%. Three-dimensional electroanatomic mapping is progressively being used to ablate atypical forms of atrial flutter.

Keywords: typical flutter, atypical flutter, cavotricuspid isthmus, mapping, isthmus block, differential pacing, entrainment, ablation

1. Introduction

Atrial flutter is between three important atrial arrhythmias resulting remarkable morbidities including heart failure and stroke. Atrial flutter has been defined as a macro-reentrant arrhythmia around an anatomic obstacle with an area larger than 2 cm². Fast atrial activation inside the atria produces sinusoidal flutter waves at a rate of 240–320 bpm with no baseline isoelectric, most clearly visible in inferior and V1 leads in the surface ECG. Atrial flutter and fibrillation frequently coexist and atrial flutter can degenerate into atrial fibrillation. With regard to the mechanism of flutter (reentry), this atrial tachyarrhythmia is very amenable to Radio-frequency Ablation (RFA). In this chapter, clinical aspects of atrial flutter will be discussed in detail which includes classification, clinical manifestation, ECG and electrophysiological characteristics and medical or invasive management.

2. Epidemiology

Overall, the incidence of AFL in the United States is 88 per 100,000 person-years. 15% of supraventricular arrhythmias are AFL and usually coexists with AF. More than 80% of patients who undergo RFA of typical AFL will have AF within the following 5 years. The incidence of AFL in men is more than twice that of women. Paroxysmal AFL can be seen in patients with no structural heart disease (SHD), whereas chronic AFL is frequently associated with underlying SHD, such as valvular disease or heart failure. Acute AFL may happen secondary to acute disease process, such as pericarditis, pulmonary embolism, exacerbation of lung disease, following heart or lung surgery, or myocardial infarction. [1]

3. Definition and classification

AFL is defined as abnormal atrial activity inside a reentrant circuit with a diameter more than 2 cm^2 at a high rate of 240–320 bpm which makes a continuous oscillation without an isoelectric baseline [2]. In contrast, focal atrial tachycardia (AT) is a rapid abnormal atrial rhythm originating from a “point source” with a baseline between P waves on ECG. The most practical classification is based on isthmus versus non-isthmus dependency (**Diagram 1**). According to the new classification, typical AFL is a macroreentrant atrial tachycardia that usually proceeds up the atrial septum (counterclockwise or CCW), down the lateral atrial wall, and through the CTI between the tricuspid valve annulus and inferior vena cava (IVC). It is also known as “common AFL” or “CTI-dependent AFL.” When the circuit rotates in the opposite direction, it is referred to as clockwise (CW) typical AFL or reverse typical AFL (**Figure 1**). Clockwise AFL is observed in only 10% of clinical cases. However, the flutter wave morphology might change in the presence of underlying atrial disease, prior surgery, or previous ablation which makes the flutter wave morphology not a reliable indicator of AFL type [2, 3].

Atypical flutter, or “non-CTI-dependent macroreentrant atrial tachycardia,” is attributed to those flutters that do not use the CTI originating in the right (RA) or left atrium (LA) [3]. In this

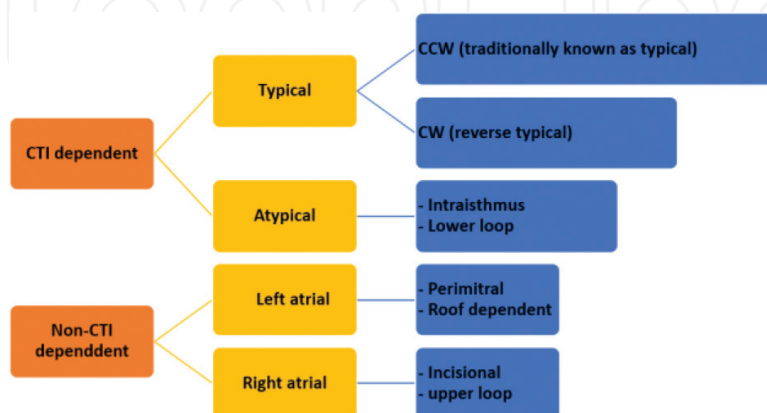


Diagram 1. Classification of atrial flutter (see the text for discussion).

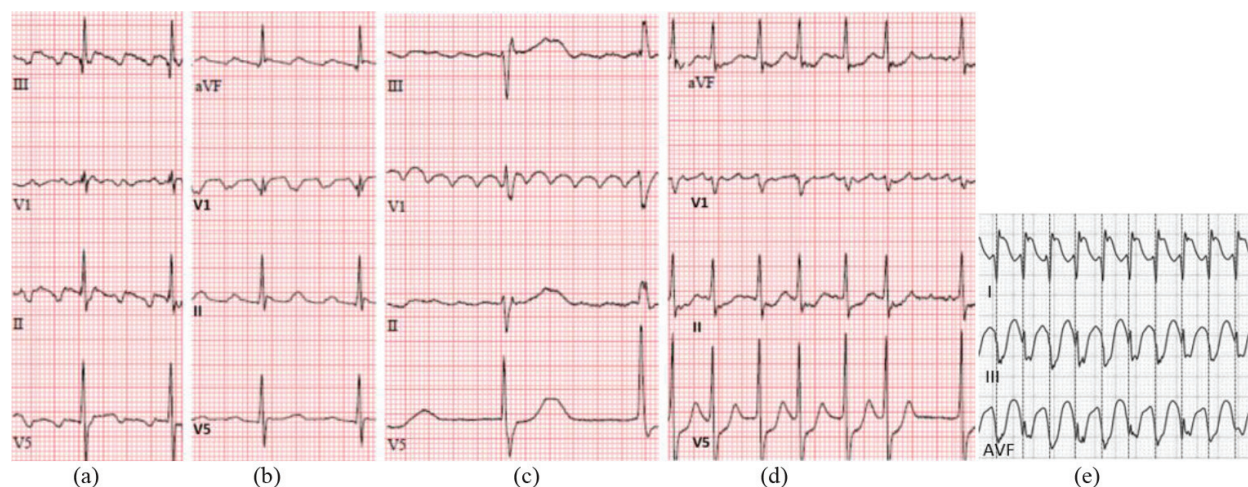


Figure 1. Counterclockwise typical flutter (a), clockwise typical flutter (b), atypical flutter (c), atrial fibrillation (d), atrial flutter 1:1 in a patient on flecainide (e). In tracing d, the atrial waves amplitude in V1 is changing with irregular irregular RR interval.

group, different circuits have been described, including “perimitral flutter” reentry, LA roof dependent flutter and reentry around scars from previous surgery or ablation in atria. Obviously, these flutters are not amenable to ablation of the CTI, but common AFL often coexists with these atypical reentry circuits [4].

3.1. Anatomy of the CTI

The CTI is bounded anteriorly by the tricuspid annulus and posteriorly by the ostium of the IVC and the eustachian ridge. The width and muscle thickness of CTI are variable, from several millimeters to around 3 cm in width and depth of 1 cm roughly. The CTI is wider in the lateral portion and thinner in the central portion. The central isthmus is concave and pouch-like in 47 and 45% of patients, respectively. The subeustachian isthmus is the area between the tricuspid annulus and the eustachian ridge which ends in IVC junction. The pectinates, spare the myocardium just in atrial part of the tricuspid valve and makes the smooth portion of the CTI which is referred to as the vestibular portion. Of note, the septal part of the CTI is adjacent to the posterior extensions of the AV node as well as the middle cardiac vein [5, 6]. This anatomic proximity explains the higher risk of AV block if ablation is done in the septal aspect. Also, the smooth vestibular portion around the tricuspid valve lies very close to the right coronary artery.

4. Clinical manifestation

The patients with flutter sometimes are asymptomatic or may present with a variety of symptoms including palpitations, dyspnea, fatigue, dizziness or reduced functional class. However, it might be the first presentation of more serious conditions like acute pulmonary embolism, acute coronary syndrome or acute pulmonary edema. The severity of symptoms

closely depends on the baseline left ventricular ejection fraction (LVEF), ventricular rate during the flutter and underlying SHD. As a common scenario, the patients present with a stroke or with decompensated heart failure secondary to tachycardia-induced cardiomyopathy. AFL occurs in nearly 25% of patients with AF.

5. Management

5.1. Acute management

The clinical presentation will dictate acute therapeutic approach which may include cardioversion or rate control strategy. Cardioversion (electrical or chemical) is usually the initial treatment of choice. Antiarrhythmic medication such as intravenous amiodarone, sotalol, have been reported with a high success rate of chemical cardioversion. These class III antiarrhythmics prolong the refractory period leading slower cycle length which could terminate AFL. Interestingly, intravenous ibutilide has been more effective than the formers up to 76% of patients. Electrical cardioversion at a low energy of 50 J has very high success rate. Overdrive atrial pacing by a catheter in RA or in preexisting pacemaker/defibrillator is an effective alternative option in terminating typical AFL. Anticoagulation by using the same criteria as for AF, prior to cardioversion should be considered [3]. In order to control the rate, oral or intravenous atrioventricular node (AVN) blockers such as verapamil, diltiazem, beta blockers, and digoxin, can be used. However, the rate control is difficult to achieve as opposed to AF.

5.2. Chronic management

If AFL occurs in the context of an acute disease process, long-term rhythm control medication is usually not required once the AFL is converted and the underlying pathologic process is eliminated. However, if there is a certain substrate for AFL recurrence such as enlarged RA or scar, medical suppression of AFL can be extremely difficult. Hence, the ablation procedure with highly successful rate and low complication risk is the approach of choice for typical AFL [7]. However, medication may be tried in some situation (i.e. patient preference). Several antiarrhythmic drugs have been somehow effective in AFL suppression, including class IC (flecainide and propafenone), and class III (usually sotalol and amiodarone) antiarrhythmics. In the absence of SHD, class IC agents are the first line medication. The antiarrhythmic agents should be combined with AVN blockers to avoid the risk of rapid ventricular rates. In fact, class IC drugs have a vagolytic effect on AVN. Although the atrial flutter rate will be slowed, more proportion of these atrial impulses will be conducted through AVN (enhanced conduction), by which net ventricular rate increases [3]. As a result, rapid 1:1 AV conduction is mostly seen if Class IC antiarrhythmic medication is not combined with AVN blockers such as beta blockers (**Figure 1e**). As mentioned, typical AFL is very amenable to ablation but AV junction ablation and pacemaker implantation may be indicated if rhythm and rate control strategies including ablation have failed in atypical flutter. The anticoagulant policy will be implemented based on the same guideline for AF.

6. Typical flutter

6.1. Electrocardiographic characteristics

In “typical” counterclockwise AFL, the wave of depolarization propagates through the lateral right atrium, then travels through the CTI in a lateral-to-medial direction. The wave of depolarization arrives at the inferior part of the interatrial septum, splits and propagates caudocephalically up the septum, finally traveling across the roof to arrive lateral RA to complete the circuit. At the same time, the depolarization wave propagates from inferior septum to the lateral wall of the left atrium. Flutter waves have constant morphology and polarity with same CL. In typical AFL, they are most visible in lead V1 and the inferior leads (II, III, aVF) with a sawtooth appearance. The propagation of depolarization wave is through interatrial septum which makes it positive or negative in inferior leads in clockwise (high to low) or counterclockwise (low to high) AFL, respectively. The wave includes a slow downsloping portion, with a sharp negative deflection, followed by a rapid positive deflection, merging to the next downsloping deflection (**Figure 2**). Because of constant activation inside the circuit, there is no electrically silent period and consequently no isoelectric period. This is as opposed to focal AT with silent periods between focal discharges (**Figure 3**). However, focal

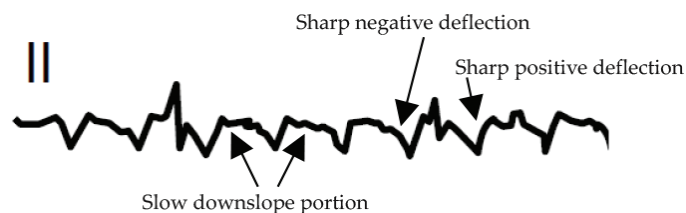


Figure 2. The typical CCW flutter ECG characteristic (see the text).

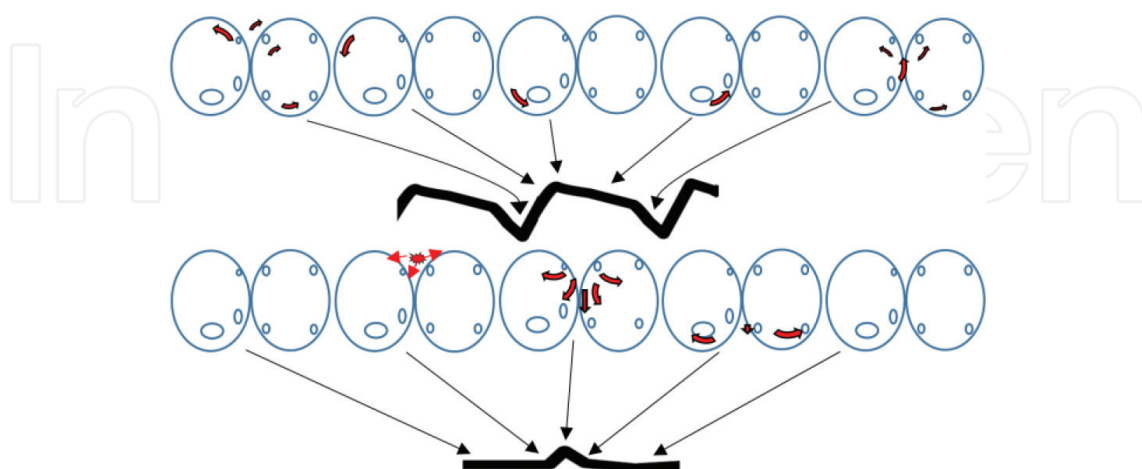


Figure 3. The top diagram demonstrates the atrial activation sequence correlated with typical CCW atrial flutter. The slow conduction through CTI causes the flutter portion of flutter wave. The bottom diagram shows atrial activation sequence in focal AT with silent periods causing flat isoelectric line.

AT can produce a continuous wave pattern on ECG if the atrial CL is short enough to shorten the interval between atrial depolarization [4, 8].

During CW AFL, the positive deflections in the inferior leads are nearly equal negative deflections in inferior leads making a sinusoidal pattern which makes it somehow difficult to recognize positive from negative deflections. So lead V1 is important in order to recognize clockwise typical AFL.

The atrial rate in AFL is typically 240–320 bpm, but it might be slower if conduction is slow inside the circuit due to scars from prior ablation or surgery. Also, antiarrhythmic medication can cause conduction delay. In these instances, distinct isoelectric intervals between flutter waves may be recognized similar to focal AT. The rapid ventricular response is occasionally seen in those patients with underlying anterogradely conducting bypass tracts or secondary to high sympathetic tone (e.g., exercise, sympathomimetic drugs) which enhance AV conduction [2]. Typically, the patients with flutter present with 2:1 AV conduction but variable AV conduction and higher grade AV block (e.g., 4:1 or 6:1) or AV dissociation (slow and fixed RR interval) may occur. P wave morphology is usually of limited anatomical value for precise circuit localization in other atypical forms of AFL. If there is any doubt on the initial ECG, infusion of adenosine or carotid massage may transiently decrease AV conduction, unmasking the flutter waves. Adenosine and digoxin increase the degree of AV block, but shorten atrial refractoriness and can cause the AFL to degenerate into AF. Of note, AF is sometimes confused with AFL when the atrial activity in lead V1 might look organized (see **Figure 1d**).

In case of AF, the cycle length of atrial waves is less than 200 ms, the RR interval is truly irregular (with precise measurement) and atrial activation is not usually organized in the limb leads. Also, there is no true relationship between the apparent “flutter waves” and QRS complexes, best seen in lead V1, and close inspection often reveals the atrial waves do not have the constant morphology and amplitude as seen in a real atrial flutter. These instances are usually defined as “coarse AF.” In rare examples, RA is in AFL but LA is in AF in which lead V1 might show more uniform morphology but the other leads manifest characteristics of fibrillation [9].

6.2. Electrophysiological testing in typical flutter

In brief, RFA is performed by creating lesions across the critical isthmus to achieve the complete and stable bi-directional block across CTI. The procedure includes linear lesion, finding the residual conducting gaps to eliminate, and ultimately the end point is the confirmation of bidirectional block across CTI. Typically, three catheters are used for ablation of typical AFL. They include the ablation catheter, multipolar coronary sinus (CS) catheter, and a duo-decapolar halo catheter. Halo catheter is positioned around tricuspid annulus so that proximal poles positioned in upper interatrial septum and roof, mid poles positioned from high to low in the lateral RA anterior to the crista terminalis and distal poles positioned in lateral inferior at 6–7 o’clock in the LAO view in fluoroscopy. In fact, the distal poles will record the middle and lateral part of the CTI [10, 11].

6.2.1. Induction of tachycardia

It’s very crucial to distinguish between isthmus-dependent and non-isthmus-dependent flutters in order to perform curative ablation. Hence, AFL should be induced to confirm the

diagnosis and make sure the AFL is isthmus dependent prior to ablation. AFL can usually be induced with programmed electrical stimulation (PES) from different locations; however, it is usually performed with pacing from proximal coronary sinus which can induce CCW typical flutter. Isoproterenol infusion (0.5–4 $\mu\text{g}/\text{min}$) may be needed to facilitate tachycardia induction. Burst pacing or atrial extra stimulus at the shorter CL/ coupling intervals will more likely induce AF which is often self-terminating. However, AF can be sustained around 10% of cases needing cardioversion in EP lab. The importance of AF induction in these patients with no clinical history of AF is uncertain [10, 12].

6.2.2. Flutter circuit features

In typical AFL, intracardiac electrogram (EGM) shows bipolar electrograms with constant CL, polarity and morphology with sequential atrial activation characteristic of a macroreentry in which the atrial CL is very stable and less than <15% as opposed to focal AT [13]. The endocardial recordings of the interatrial septum, upper anterolateral, and CTI indicates low-voltage atrial electrical activity cover 100% of the tachycardia cycle length (TCL) (**Figure 4**). In focal AT, the atrial activation covers less than 50% of TCL, even if only RA atrial activation recordings are taken account. The CTI is the zone of delayed conduction required for establishing reentry. Some studies show slow conduction area is probably located in the medial part of CTI in older patients versus the lateral part of CTI in younger people [7, 14]. With consideration of depolarization propagation around the circuit in typical isthmus-dependent AFL, the atrial activation sequence is predictable. The onset of flutter waves in the surface ECG is simultaneous with activation of the septal atrial electrogram which is His atrial recording in clockwise and the atrial recording of proximal CS in counterclockwise AFL [9].

6.2.3. Diagnostic maneuvers

6.2.3.1. Entrainment and technique

Entrainment is the essential maneuver to confirm the diagnosis. It determines whether AFL is CTI dependent [12].

Overdrive atrial pacing is performed at a CL of 10–20 ms shorter than the TCL to entrain. As shown in **Figure 5**, if the pacing site is farther from the reentrant circuit, it takes longer for the impulse to get the circuit and entrain the tachycardia. By definition, the entrainment is a continuous resetting of a reentrant circuit with an excitable gap by a series of stimuli with following characteristics:

1. During pacing at shorter CL, all P waves (and intracardiac atrial electrograms) are accelerated to the pacing rate
2. During pacing at progressively faster cycle lengths, progressive fusion of flutter waves (surface ECG) or intracardiac EGM occurs
3. The same tachycardia (same TCL and atrial activation sequence) resumes upon termination of pacing.

The post-pacing interval (PPI) is the time between the last pacing stimulus that entrained the AFL and the next recorded atrial EGM at the same pacing site (same catheter through which

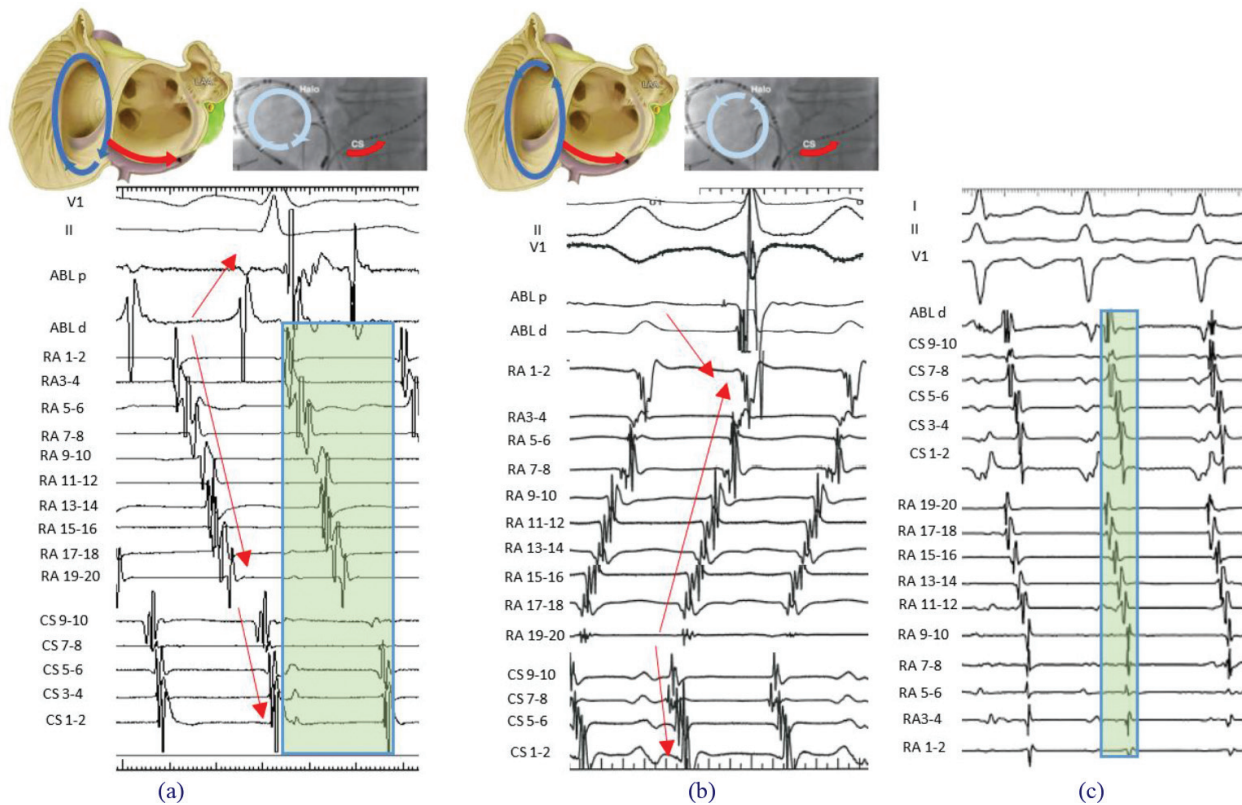


Figure 4. Electrocardiogram and endocardial electrogram of CCW typical flutter (b), CW (reverse) typical flutter (a) and focal atrial tachycardia (c). Arrows show the atrial activation sequence. The halo catheter (RA channel) has 10 bipolar electrograms recorded from the distal (low lateral right atrium or RA 1–2) to the proximal (high right atrium or RA 19–20) poles of the halo catheter positioned around the tricuspid annulus. The distal pole of RA 1–2 is at 7 o'clock and the proximal pole of RA 19–20 is at 1–2 o'clock. CS 9–10 electrograms are recorded from the CS proximal positioned at the CS ostium, ABL d (distal) electrogram is recorded from ablation catheter positioned in the cavotricuspid isthmus. Green shading shows the portion of the tachycardia cycle covered by the activation; which is around 100% in atrial flutter and less than 50% in focal atrial tachycardia (see the text).

pace was done). Obviously, PPI will be shorter if the pacing stimulus site is closer to the circuit. Accordingly, if PPI is equal or within 20 ms of TCL, it means the pacing stimulus site is inside the circuit. In order to assess whether AFL is isthmus (CTI) dependent, an ablation catheter is placed in CTI and paced at shorter CL to entrain AFL. If PPI is within 20 ms of TCL, it indicates that CTI is in the circuit which confirms AFL is isthmus (CTI) dependent. If the pacing site is outside of the circuit, the PPI will be equal to TCL plus the time required for the stimulus to travel from the pacing site to the flutter circuit and return back to the stimulus site [12, 14, 15] (Figure 5).

6.3. Ablation

6.3.1. Technique

Typically, a 4-mm irrigated steerable ablation catheter is used in order to deliver point-by-point RF applications across CTI. Adequacy and quality of lesions depend on proper contact, local

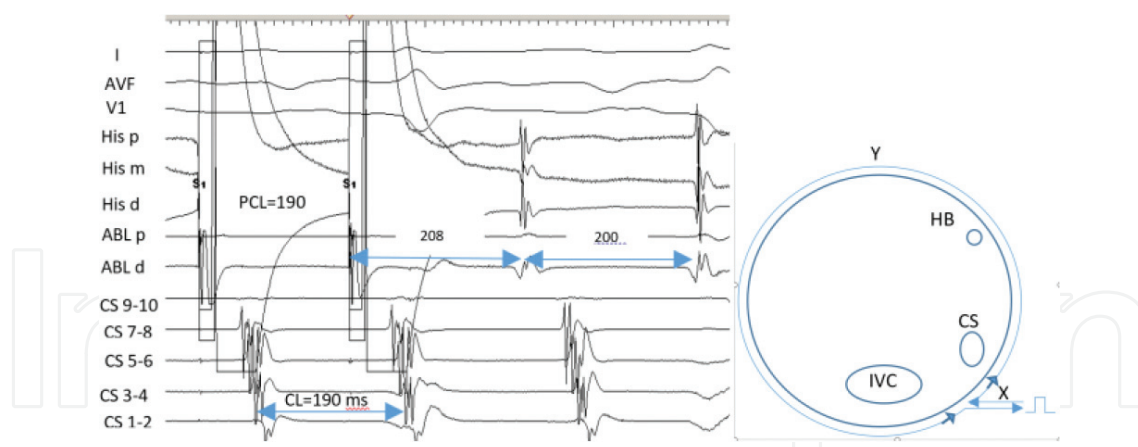


Figure 5. The right diagram illustrates the entrainment concept. The time from the stimulus site to the circuit is equal to X . The whole circuit time is equal to Y , so the time required for the stimulus to travel from stimulus site to get the circuit, turn around the circuit, returning back to the stimulus site is equal to $2X + Y$. In the left tracing, $TCL = 200$, overdrive pacing from ablation catheter positioned at CTI is performed at $CL = 190$ ms which entrains the tachycardia. The PPI (208 ms in this example) is measured from the stimulus to the first potential appears in ablation catheter channel. $PPI - TCL = 8$ ms which confirms the ablation catheter is inside the circuit at the CTI; hence, the flutter is CTI dependent.

blood flow, enough power, and tissue thickness. A guiding sheath (e.g. SR0 or ramp sheath) can help stabilizing the catheter position and prevent sliding off the line of ablation during RF application. At first, the catheter is advanced into the RV in RAO view, then is dragged back gradually until the EGM shows small atrial and large ventricular electrograms. The relative electrogram size of the ventricular and atrial signals helps to estimate the approximate location of catheter tip (e.g. the A/V ratio is around 1:4 at the ventricular side of the tricuspid annulus, and 4:1 near the IVC). The tip of the ablation catheter is finely adjusted in midway between the interatrial septum (CS Ostium as a landmark) and lateral RA lateral in the LAO view (at around 6 or 7 o'clock). The first RF application is delivered at the tricuspid annulus with small AV ratio. After each RF application lasting for 30–60 s, the atrial electrogram voltage is reduced and may become fragmented; then the catheter is dragged back around 4 mm until EGM shows new sharp atrial electrogram (not far field), and the next RF burn is delivered. This sequence is repeated until EGM shows minimal or no atrial electrograms which implies that the catheter tip has reached the IVC border [10, 16, 17].

6.3.2. Anatomic considerations

Firstly, the eustachian ridge is a “floppy” structure that comprises the posterior border of CTI and separates the IVC from the inferior RA, and sometimes prevents complete ablation of the posterior part of CTI with simple dragging of the catheter. In such situation, the catheter tip should be curled back, in order to get access to the most posterior part of CTI and the floor of pouch created by “Eustachian ridge” (Figure 6). It is important to keep in mind that AV block can occur in approximately 1% of cases, particularly during ablation of the medial side of CTI (5 o'clock) which is close to the septum. Observation of changing variable conduction of 2:1–3:1 or appearance of relatively regular QRS complexes should warrant possibility of damage to

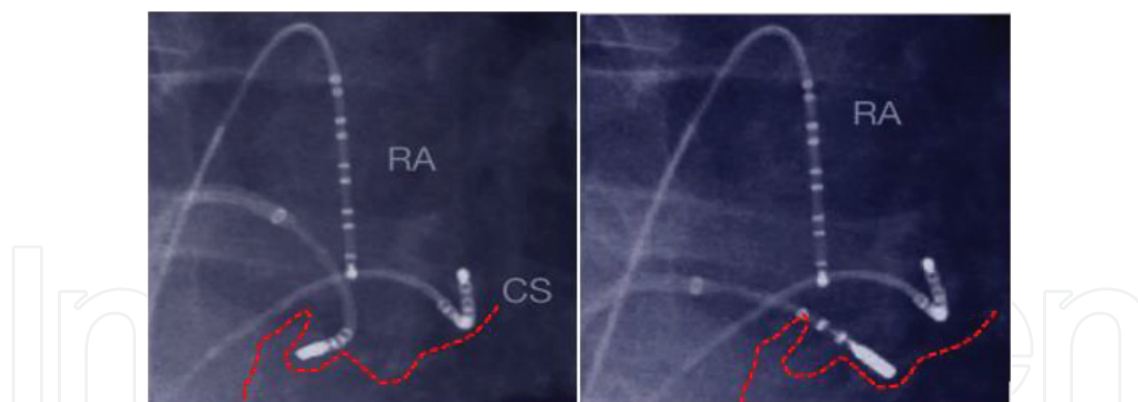


Figure 6. In some difficult cases, the eustachian ridge separates the IVC from the inferior RA and creates a pouch. In order to get access to the pouch floor to complete the line of the block, the ablation catheter should be curled back as shown on the left panel.

AVN and consequent high-grade AV block. So the risk of AV block is less likely if ablation is done far away septum [18, 19]. In AFL recurrence and re-do cases, 3D mapping system and intracardiac echocardiography will be helpful to figure out the complex anatomy and hence to ablate effectively the gaps.

6.4. Post-ablation study

6.4.1. Identification and ablation of residual gaps

With respect to isthmus anatomy and the presence of potential pouches, conduction gaps frequently remain despite continuous lesions. Locating and ablating residual gaps is mandatory to achieve complete bidirectional block and to prevent AFL recurrence. The residual gaps can be detected via local electrograms including fractionated EGM potential or the isoelectric interval between double potentials [20] (**Figure 7**).

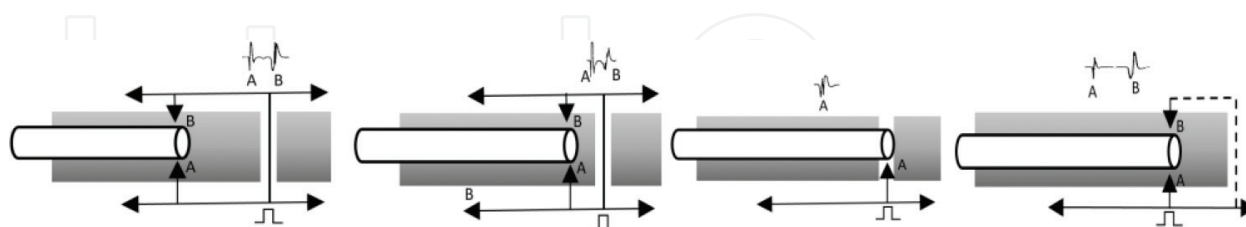


Figure 7. Identification of residual gaps in the ablation line. An interval separating the two components of double potentials recorded along the ablation line in the CTI during CS pacing, after RF ablation. The first component (potential a) is produced once the stimulus impulse reaches the one side of the ablation catheter. If there is a gap along the line of ablation, the impulse still can travel through the gap to another side of the ablation catheter, producing second potential (B). When the tip of catheter moves toward to the site of the gap, the time required for an impulse to reach the tip of the catheter on the other side gets shorter, which leads to shortening of the interval between two components. Finally, at the site of gap, the two signals will be fused and the double potentials disappear. This approach with moving the catheter through the line can detect the gap. The last diagram shows completion of block line in which the impulse should turn around the RA (far away CTI) that will obviously increase the time required for the impulse to reach spot B; thus, the interval between two components will be prolonged.

6.4.2. Endpoints

Confirmation of bidirectional block is traditionally considered as the endpoint of AFL ablation. The created lesion can recover conduction so bidirectional block should be verified with the current maneuver as the endpoint of RF ablation and repeated after 20–30 min monitoring [21].

6.4.3. Atrial activation sequence during atrial pacing in the presence of isthmus block

Pacing from the medial side of the ablation line (e.g. from CS proximal) is performed and atrial activation sequence is evaluated (**Figure 8**). In the presence of medial to lateral block across

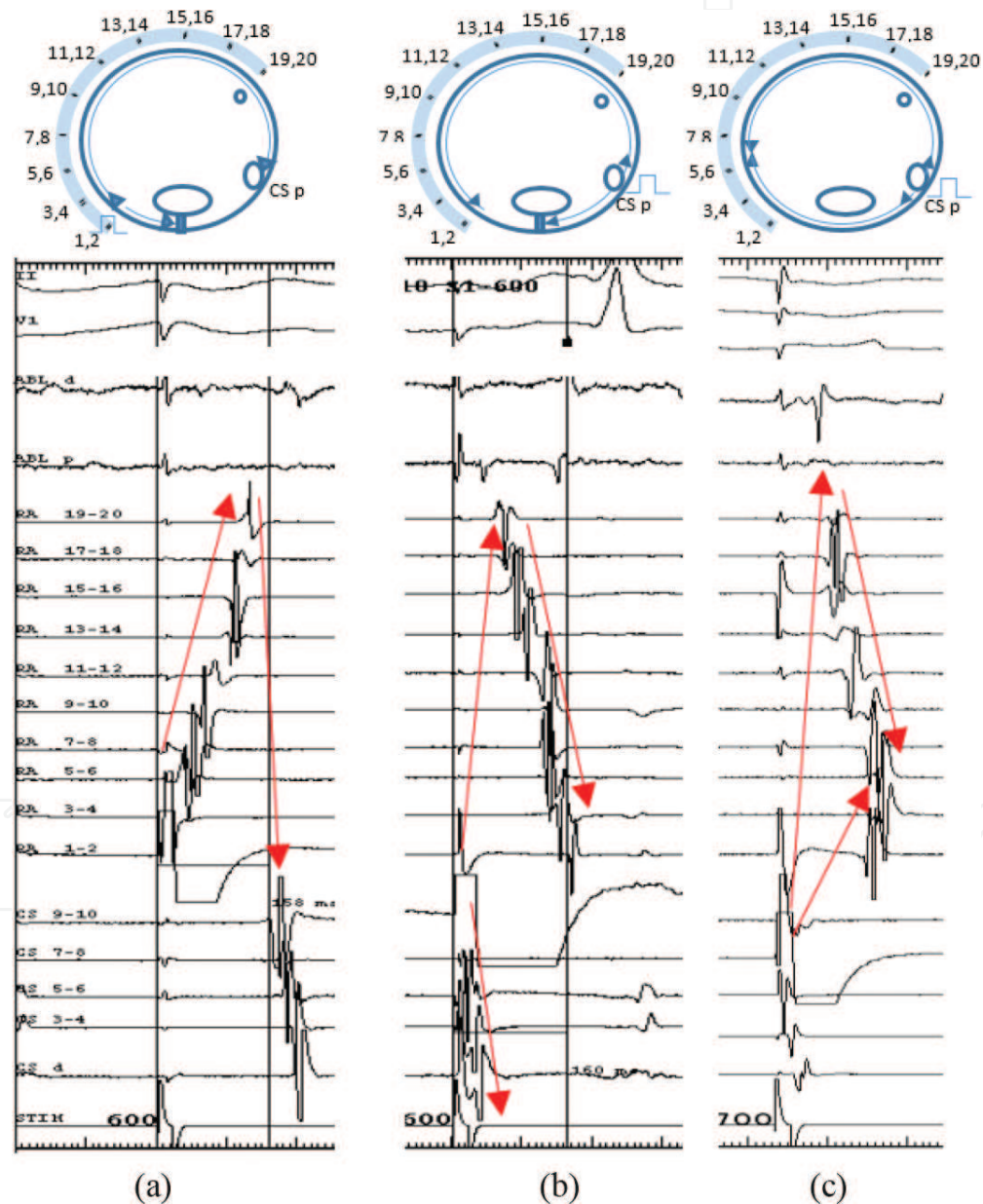


Figure 8. Right atrial endocardial electrograms recorded during CSp pacing from distal halo catheter or RA 1–2 after ablation (a) and from CSp pacing before (c) and after (b) ablation of CTI during sinus rhythm (see the text for discussion).

CTI, atrial depolarization wave must propagate caudocephalically up the septum and travel down to the lateral RA to arrive at distal poles of halo catheter. So the distal poles of halo catheter are the last poles which record the atrial potentials (**Figure 8b**). In order to assess the lateral to medial block across CTI, pacing from lateral to the ablation line is performed (e.g. halo distal poles or tip of ablation catheter at 8:00 o'clock). In case of lateral to medial block, atrial depolarization wave will propagate superiorly up the lateral RA and travel down the interatrial septum to reach the CS ostium, recorded at proximal CS (**Figure 8a**). **Figure 8c** shows the atrial activation during CS proximal pacing prior to medial to lateral isthmus block which demonstrates the collision of the cranial and caudal right atrial wave fronts in the mid-lateral RA (RA 5–6).

6.4.4. Trans CTI conduction time

CS proximal or low lateral RA is usually paced in order to measure conduction interval across CTI. Obviously, the interval is the time from the stimulus pacing artifact from one side of the isthmus (e.g. CS proximal) to the atrial electrogram recorded on the other side (e.g. distal halo poles). More than 50% prolongation of this interval or an absolute interval time of 150 ms or more is in favor of CTI block [22, 23].

6.4.5. Differential pacing

This maneuver is used to assess CW and CCW block across CTI. At first, pacing is performed close to the ablation line, then pacing site is moved away from first pacing spot (**Figure 9**). For example, to check CCW (lateral to medial) block, the pacing is done from halo distal poles (Halo 1,2) and the time from stimulus artifact to the atrial electrogram recorded on the proximal CS is measured. Then pacing site is done farther from ablation line (Halo 3,4). If there is CCW, the measured interval will be shortened on the latter spot (Halo 3,4). When CTI conduction is intact, conduction occurs via a counterclockwise wavefront across the CTI to reach proximal CS, so the measured interval will be longer once it is paced from Halo 3,4 compared to Halo 1,2 [24].

6.4.6. Electroanatomical mapping

Electroanatomical 3D mapping can also be used to confirm conduction block across CTI. For example, when CCW block is present, Halo 1,2 pacing results in an activation wavefront directing in a CW pattern and CTI immediately medial to the ablation line will be the last part in the circuit which will be activated. If CTI is intact, with pacing from Halo 1,2 the activation wavefront travels rapidly through the CTI, with the upper septum will be the last part of activation.

6.5. Complication

RF ablation of the typical AFL is relatively safe, with an average complication rate of 3% which includes mostly peripheral vascular injury (0.5%). The risk of serious complication is very low which include complete heart block (0.3%), tamponade, myocardial infarction due to damage to the right coronary artery, stroke and pulmonary embolism (0.1%). The recurrence

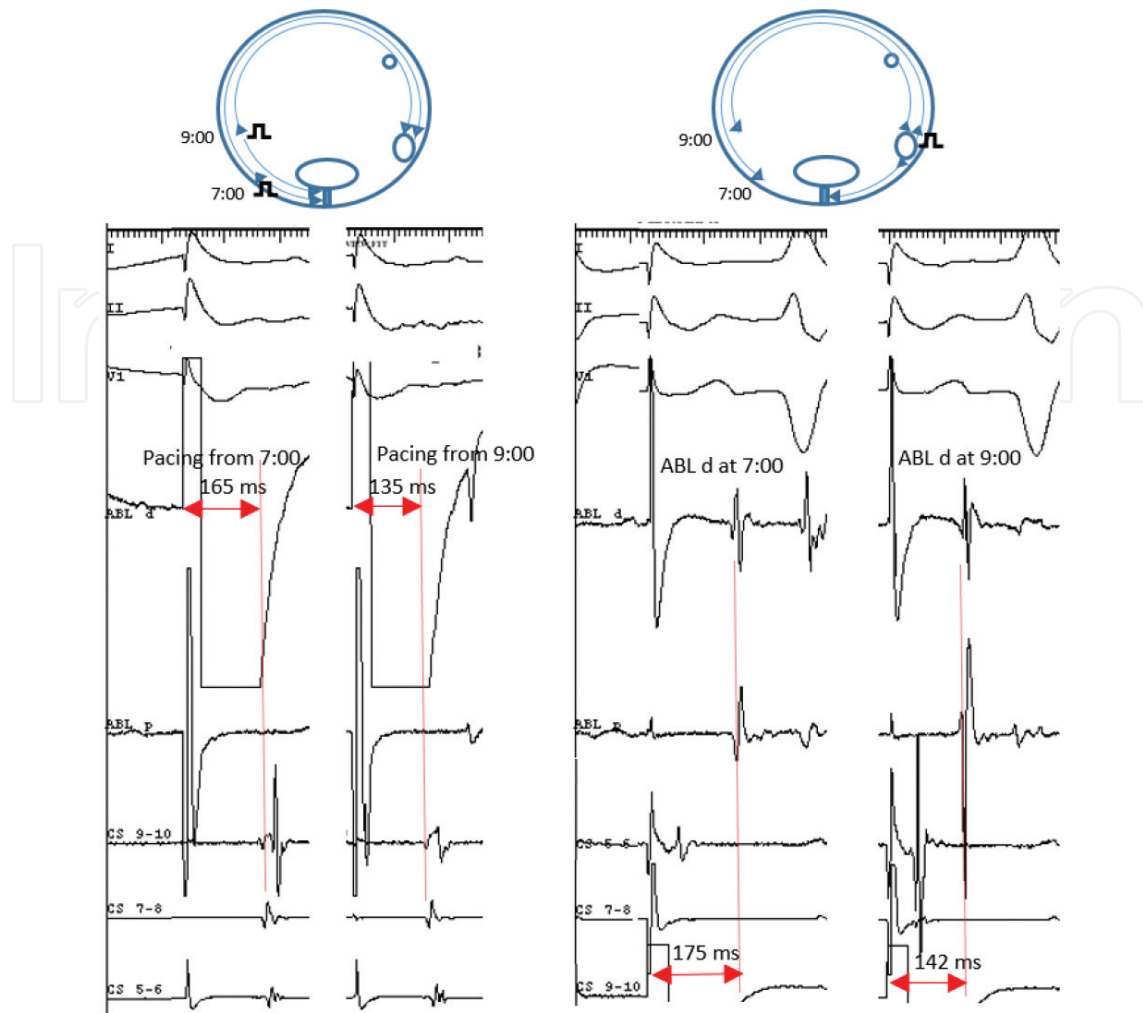


Figure 9. The method of differential pacing to evaluate bidirectional CTI block (see the text).

rate of AFL has been reduced by using irrigated tip catheters and is around half of the recurrence in standard RF ablation (7 vs 14%). The occurrence of AF or atypical AFL is dramatically high at around 70% in long-term follow up [25, 26]

7. Atypical AFL

Atypical AFL frequently demonstrates attenuated flutter waves which help to distinguish from typical flutter. They are classified as atypical right or left atrial flutter [27] (**Figure 10**). Prompt identification of these AFL types will maximize the success rate of ablation.

7.1. Atypical right atrial isthmus-dependent flutter

7.1.1. Lower loop reentry

Lower loop reentry is a form of CTI-dependent AFL in which the circuit is around IVC. The eustachian ridge and lower crista terminalis usually cause a breakdown in wavefront

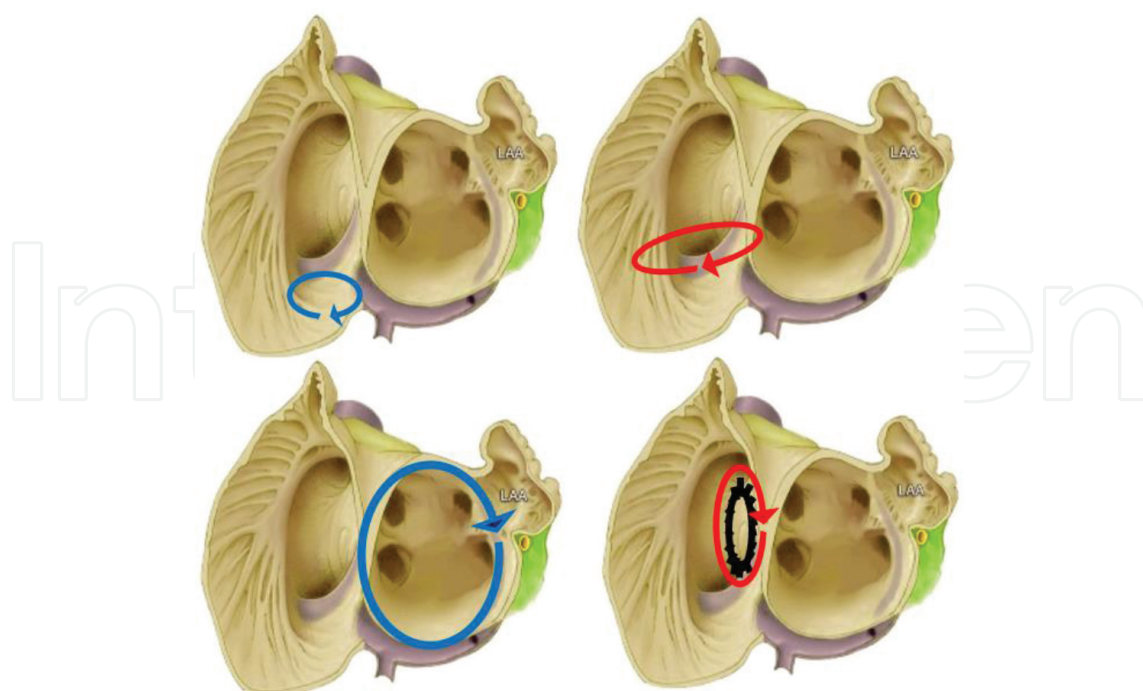


Figure 10. Types of atypical flutter. Top left, Intraisthmus reentry. Top right, lower loop reentry. Bottom left, perimitral reentry. Bottom right, incisional (around ASD patch) reentry.

conduction across CTI; consequently, impulse revolves around the IVC instead of the tricuspid annulus. It is mostly identified during 3D activation mapping [28].

7.1.2. Intraisthmus reentry

The circuit of intraisthmus reentry is bounded by the medial side of CTI and CS ostium. The previous ablation at the CTI might predispose and perpetuate this reentry. The EGMs are usually similar to typical AFL but entrainment shows the lateral CTI is not inside the circuit (long PPI) whereas the medial side of CTI presents in the circuit (short PPI). The mapping of the region between proximal CS and medial CTI usually shows fractionated or double potentials which are a good target for ablation. A linear lesion across the medial CTI usually breaks the circuit [27, 28].

7.2. Atypical right atrial non-isthmus dependent flutter

7.2.1. Lesional right atrial flutter

These circuits arise around a low-voltage area, incision, patch or scar in the lateral or posterolateral RA. These areas usually develop after the atriotomy and surgery for the congenital disease. 3D activation mapping is an excellent modality to identify this type of AFL circuits [28].

7.2.2. Upper loop reentry

In this type of AFL, the wavefront activation propagates around the superior vena cava (SVC) and travels through a conduction gap in the crista terminalis.

7.2.3. *Dual-loop reentry*

The coexistence of two circuits is known as dual-loop reentry. The activation wavefront can propagate through both circuits intermittently. In practice, they are identified when the ablation of one circuit leads to change in atrial activation sequence suggesting a transition to the other circuit [27].

7.3. **Atypical left atrial flutter**

LA flutter often coexists with AF. It is usually secondary to AF ablation (up to 50%) or open heart surgery for the valvular disease. The central obstacle of the AFL circuits is low-voltage or scar areas in the LA detected by electroanatomic 3D mapping [29].

7.3.1. *ECG characteristics of left atrial flutter*

Whenever the flutter wave morphology in ECG is not characteristic of typical AFL, left atrial flutter must be considered. A characteristic finding in LA flutter is a dominantly positive broad deflection in lead V1. The combination of attenuated deflections in the frontal leads with a dominantly positive deflection in V1 also suggests that origin of flutter is probably in LA. Uncommonly, negative flutter deflections in the inferior leads might be seen in left AFL mimicking typical AFL (pseudo-typical flutter). However, typical AFL demonstrates positive overshoot immediately following the negative deflection. This positive deflection is as a result of inferiorly down activation of the lateral RA. Lack of this sharp positive deflection raises suspicion of atypical AFL. In the presence of low voltage areas, the electrical impulse traversing the isthmus (protected within scar) might generate low voltage potentials, demonstrated on the surface ECG as an iso-electric interval. In addition, a small portion of the atria is being activated during the silent isoelectric period. Therefore, the isoelectric interval strongly supports the presence of a slow conducting isthmus, although its absence does not exclude it. For example, if intracardiac CS electrograms coincide with an isoelectric interval, it suggests CS region may be involved in the reentrant circuit, indirectly implies the flutter might be left sided in origin. Likewise, the electrograms of CTI region coincide with the isoelectric period between the negative flutter waves in typical AFL [30, 31].

7.3.2. *Perimitral atrial flutter*

In this type of AFL, the reentrant circuit arises around the mitral annulus. 3D voltage mapping often shows low-voltage or scar areas on the posterior LA which act as a boundary of this circuit. Most of the patients have a past history of AF ablation [29].

7.4. **EPS and mapping in atypical AFL**

In addition to CS and Halo catheter, the transeptal puncture is performed to insert a catheter in LA (usually irrigated tip ablation catheter) for the full study. In order to confirm LA flutter, a systematic approach is used. The first step is the exclusion of CTI dependent AFL. Coronary sinus activation from proximal to distal can suggest that AFL origin is from the RA; however, CS activation sequences are not very valuable in LA flutter diagnosis. If EGMs recorded

throughout RA (i.e. atrial electrograms recorded on all Halo poles) covers more than 50% of the TCL, it is another clue for RA AFL. Another helpful maneuver is entrainment at multiple sites in the RA and comparison of their PPIs. For instance, if PPI is shorter in septum compared to lateral RA or CTI, it might be suggestive for LA flutter. In fact, the gradient of PPI in LA flutter typically is longest (more than 30 ms) in the lateral RA and remarkably shorter in the mid and distal coronary sinus. However, roof or anterior LA flutter might show long PPI in mid to distal CS [28, 29, 32]. The 3D mapping system is often necessary to perform the full activation and voltage mapping for localization and effective ablation of the reentrant circuit [33].

8. Conclusion

Atrial flutter is relatively common atrial arrhythmia with the nearly similar morbidity and mortality to atrial fibrillation. However, it's highly amenable to RF ablation. This procedure has emerged as therapy of choice in the light of highly successful rate and low complication risk. The knowledge of the anatomy and electrophysiology of the atrial flutter circuit is essential to choosing the optimal site for elimination of reentry. An electroanatomic 3D mapping system is highly recommended to perform the full activation and voltage mapping in order to localize the circuit and critical isthmus targeted for effective ablation.

Acknowledgements

I thank my wife, Mojgan for her continued inspiration and my daughter, Diana for her tremendous support to complete this chapter. But most importantly, I want to thank my son Arshia for his great technical support and his help, editing this chapter.

Disclosure

None.

Author details

Hamid Reza Bonakdar

Address all correspondence to: hamidreza.bonakdar@gmail.com

St. Michael Hospital, Affiliated to University of Toronto, Canada

References

- [1] Granada J, Uribe W, Chyou PH, Maassen K, Vierkant R, Smith PN, et al. Incidence and predictors of atrial flutter in the general population. *Journal of the American College of Cardiology*. 2000 Dec;**36**(7):2242-2246. DOI: 10.1016/S0735-1097(00)00982-7
- [2] Saoudi N, Cosi'o F, Waldo A, Chen SA, Iesaka Y, Lesh M, et al. A classification of atrial flutter and regular atrial tachycardia according to electrophysiologic mechanism and anatomic bases. A statement from a joint expert group from the working Group of Arrhythmias of the European Society of Cardiology and the north American society of pacing and electrophysiology. *European Heart Journal*. 2001;**22**:1162-1182. DOI: 10.1053/euhj.2001.2658
- [3] Blomstrom-Lundqvist C, Scheinman MM, Aliot EM, et al. ACC/AHA/ESC guidelines for the management of patients with supraventricular arrhythmias—executive summary. A report of the American college of cardiology/American heart association task force on practice guidelines and the European society of cardiology committee for practice guidelines (writing committee to develop guidelines for the management of patients with supraventricular arrhythmias) developed in collaboration with NASPE-Heart Rhythm Society. *Journal of the American College of Cardiology*. 2003;**42**:1493-1531. DOI: 10.1161/01.CIR.0000091380.04100.84
- [4] January CT, Wann LS, Alpert JS, et al. 2014 AHA/ACC/HRS guideline for the management of patients with atrial fibrillation: A report of the American College of Cardiology/American Heart Association task force on practice guidelines and the Heart Rhythm Society. *Journal of the American College of Cardiology*. 2014 Dec 2;**64**(21):e1-76. DOI: 10.1016/j.jacc.2014.03.021
- [5] Tai CT, Chen SA. Cavotricuspid isthmus: Anatomy, electrophysiology, and long-term outcome of radiofrequency ablation. *Pacing and Clinical Electrophysiology*. 2009;**32**: 1591-1595. DOI: 10.1111/j.1540-8159.2009.02555.x
- [6] Saremi F, Pourzand L, Krishnan S, et al. Right atrial cavotricuspid isthmus: Anatomic characterization with multi-detector row CT. *Radiology*. 2008;**247**:658-668. DOI: 10.1148/radiol.2473070819
- [7] Waldo AL, Atiezna F. Atrial flutter: Mechanisms, features, and management. In: Zipes DP, Jalife J, editors. *Cardiac Electrophysiology: From Cell to Bedside*. 5th ed. Philadelphia: Saunders; 2009. pp. 567-576
- [8] Medi C, Kalman JM. Prediction of the atrial flutter circuit location from the surface electrocardiogram. *Europace*. 2008;**10**:786-796. DOI: 10.1093/europace/eun106
- [9] Josephson ME. Atrial flutter. In: Zimetbaum P, Josephson M, editors. *Practical Clinical Electrophysiology*. 2nd ed. Wolter Kluwer; 2017. pp. 73-83

- [10] Josephson ME. Atrial flutter and fibrillation. In: Josephson ME, editor. *Clinical Cardiac Electrophysiology*. 4th ed. Philadelphia: Lippincott Williams & Wilkins; 2008. pp. 285-338
- [11] Miyazaki H, Stevenson WG, Stephenson K, et al. Entrainment mapping for rapid distinction of left and right atrial tachycardias. *Heart Rhythm*. 2006;**3**:516-523. DOI: 10.1016/j.hrthm.2006.01.014
- [12] Deo R, Berger R. The clinical utility of entrainment pacing. *Journal of Cardiovascular Electrophysiology*. 2009;**20**:466-470. DOI: 10.1111/j.1540-8167.2008.01409.x
- [13] Jaïs P, Matsuo S, Knecht S, Weerasooriya R, Hocini M, et al. A deductive mapping strategy for atrial tachycardia following atrial fibrillation ablation: Importance of localized reentry. *Journal of Cardiovascular Electrophysiology*. 2009;**(5)**:480-491. DOI: 10.1111/j.1540-8167.2008.01373.x
- [14] Huang JL, Tai CT, Lin YJ, et al. Right atrial substrate properties associated with age in patients with typical atrial flutter. *Heart Rhythm*. 2008;**5**:1144-1151. DOI: 10.1016/j.hrthm.2008.05.009
- [15] Waldo AL. Atrial flutter: Entrainment characteristics. *Journal of Cardiovascular Electrophysiology*. 1997 Mar;**8**(3):337-352. DOI: 10.1111/j.1540-8167.1997.tb00798.x
- [16] Marrouche NF, Schweikert R, Saliba W, et al. Use of different catheter ablation technologies for treatment of typical atrial flutter: Acute results and long-term follow-up. *Pacing and Clinical Electrophysiology*. 2003;**26**:743-746. DOI: 10.1046/j.1460-9592.2003.00126.x
- [17] Cosio FG, Pastor A, Nunez A, Giocolea A. Catheter ablation of typical atrial flutter. In: Zipes DP, Haissaguerre M, editors. *Catheter Ablation of Arrhythmias*. Armonk, NY: Futura; 2002. pp. 131-152
- [18] Gami AS, Edwards WD, Lachman N, et al. Electrophysiological anatomy of typical atrial flutter: The posterior boundary and causes for difficulty with ablation. *Journal of Cardiovascular Electrophysiology*. 2010;**21**:144-149. DOI: 10.1111/j.1540-8167.2009.01607.x
- [19] Lo LW, Tai CT, Lin YJ, et al. Characteristics of the cavotricuspid isthmus in predicting recurrent conduction in the long-term follow-up. *Journal of Cardiovascular Electrophysiology*. 2009;**20**:39-43. DOI: 10.1111/j.1540-8167.2008.01269.x
- [20] Shah D, Haïssaguerre M, Jaïs P, Takahashi A, Hocini M, Clémenty J. High-density mapping of activation through an incomplete isthmus ablation line. *Circulation*. 1999;**2**:211-215. PMID: 9892585
- [21] Chen J, De Chillou C, Basiouny T, Sadoul N, Filho JD, Magnin-Poull I, et al. Cavotricuspid isthmus mapping to assess bidirectional block during common atrial flutter radiofrequency ablation. *Circulation*. 1999 Dec 21-28;**100**(25):2507-2513. DOI: 10.1161/01.CIR.100.25.2507
- [22] Chen J, De Chillou C, Hoff PI, Rossvoll O, Andronache M, Sadoul N, et al. Identification of extremely slow conduction in the cavotricuspid isthmus during common atrial flutter

- ablation. *Journal of Interventional Cardiac Electrophysiology : An International Journal of Arrhythmias and Pacing*. 2002 Aug;7(1):67-75. DOI: 10.1023/A:102082430
- [23] Oral H, Sticherling C, Tada H, et al. Role of transisthmus intervals in predicting bidirectional block after ablation of typical atrial flutter. *Journal of Cardiovascular Electrophysiology*. 2001;12:169-174. DOI: 10.1046/j.1540-8167.2001.00169.x
- [24] Shah D, Haïssaguerre M, Takahashi A, et al. Differential pacing for distinguishing block from persistent conduction through an ablation line. *Circulation*. 2000;102:1517-1522. DOI: 10.1161/01.CIR.102.13.1517
- [25] Gilligan DM, Zakaib JS, Fuller I, et al. Long-term outcome of patients after successful radiofrequency ablation for typical atrial flutter. *Pacing and Clinical Electrophysiology*. 2003;26:53-58. DOI: 10.1046/j.1460-9592.2003.00150.x
- [26] Tai CT, Chen SA, Chiang CE, et al. Long-term outcome of radiofrequency catheter ablation for typical atrial flutter: Risk prediction of recurrent arrhythmias. *Journal of Cardiovascular Electrophysiology*. 1998;9:115-121. DOI: 10.1111/j.1540-8167.1998.tb00892.x
- [27] Garan H. Atypical atrial flutter. *Heart Rhythm*. 2008;5:618-621. DOI: 10.1016/j.hrthm.2007.10.031
- [28] Fiala M, Chovancik J, Neuwirth R, et al. Atrial macroreentry tachycardia in patients without obvious structural heart disease or previous cardiac surgical or catheter intervention: Characterization of arrhythmogenic substrates, reentry circuits, and results of catheter ablation. *Journal of Cardiovascular Electrophysiology*. 2007;18:824-832. DOI: 10.1111/j.1540-8167.2007.00859.x
- [29] Morady F, Oral H, Chugh A. Diagnosis and ablation of atypical atrial tachycardia and flutter complicating atrial fibrillation ablation. *Heart Rhythm*. 2009;6(Suppl):S29-S32. DOI: 10.1016/j.hrthm.2009.02.011
- [30] Shah D. ECG manifestations of left atrial flutter. *Current Opinion in Cardiology*. 2009;(1): 35-41. DOI: 10.1097/HCO.0b013e32831ca5a8
- [31] Bochoeyer A, Yang Y, Cheng J, Randall J. Surface electrocardiographic characteristics of right and left atrial flutter. *Circulation*. 2003;108:60-66. DOI: 10.1161/01.CIR.0000079140.35025.1E
- [32] Jais P, Shah DC, Haïssaguerre M, Hocini M, Peng JT, et al. Mapping and ablation of left atrial flutters. *Circulation*. 2000;(25):2928-2934. DOI: 10.1161/01.CIR.101.25.2928
- [33] Shah DC, Jais P, Haïssaguerre M, Chouairi S, Takahashi A, Hocini M, et al. Three dimensional mapping of the common atrial flutter circuit in the right atrium. *Circulation*. 1997; 96:3904-3912. DOI: 10.1161/01.CIR.96.11.3904

