

# We are IntechOpen, the world's leading publisher of Open Access books Built by scientists, for scientists

4,800

Open access books available

122,000

International authors and editors

135M

Downloads

Our authors are among the

154

Countries delivered to

TOP 1%

most cited scientists

12.2%

Contributors from top 500 universities



WEB OF SCIENCE™

Selection of our books indexed in the Book Citation Index  
in Web of Science™ Core Collection (BKCI)

Interested in publishing with us?  
Contact [book.department@intechopen.com](mailto:book.department@intechopen.com)

Numbers displayed above are based on latest data collected.

For more information visit [www.intechopen.com](http://www.intechopen.com)



---

# Long-Term Complications of Tracheal Intubation

---

Abdelfattah A. Touman and Grigoris K. Stratakos

Additional information is available at the end of the chapter

<http://dx.doi.org/10.5772/intechopen.74160>

---

## Abstract

Endotracheal intubation is an intervention frequently performed in the hospital setting in order to protect the central airway and provide mechanical support of ventilation. Many health care providers are expected to be able to intubate the patients for different indications. As the case in any medical intervention, endotracheal intubation can cause complications. These complications are categorized as early or late according to the time of onset of the presenting symptoms. This chapter will discuss the long term complications of endotracheal intubation that might be encountered by the treating physicians. The chapter will stress on the predisposing factors for these complications and the available methods to avoid and treat them.

**Keywords:** intubation related complications, obstructive fibrinous tracheal pseudomembranes, post-intubation tracheal stenosis, tracheomalacia, tracheoesophageal fistula

---

## 1. Introduction

Intubation is an invasive, however, lifesaving procedure which established its role in the daily management of critically ill patients. Physicians treating patients with endotracheal tubes can encounter complications during or immediately after the procedure. Complication appearance or identification can be delayed for days to weeks. They can be categorized into three categories:

1. Long term complications that occur immediately during endotracheal tube (ETT) insertion
  2. Complications of the prolonged intubation
  3. Late onset complications
-

## 2. Risk assessment and general preventive measures

Risk assessment and preventive measures of the intubation-related complications should be undertaken immediately after the decision for an endotracheal tube (ETT) insertion is taken for the patient's management. These measures can be divided into three main groups:

### I. Measures that should be taken *before* intubation:

1. Routine assessment for potentially difficult intubation cases.
2. Choosing the proper sized tube.
3. Using proper technique
4. Choose an experienced, skilled physician to perform the procedure.
5. Preparing alternative plans in cases of unanticipated difficulties. The Difficult Airway Society (DAS) guidelines recommended a four steps plans A–D as the following [1]:
  - A. Preparing an initial tracheal intubation plan that includes using the direct laryngoscopy.
  - B. Preparing a secondary intubation plan which includes using a dedicated supraglottic airway device such as the classic laryngeal mask airway (LMA) in case of plan A has failed.
  - C. When plan B fails; the physician should be prepared to oxygenate and ventilate the patient, postpone the surgery, and awaken the patient.
  - D. In cases where physician 'cannot intubate, cannot ventilate' (CICV) rescue techniques such as cannula or surgical cricothyroidotomy should be available at the facility.

### II. Measures that applied *during* intubation:

1. Intubating the patients under direct vision.
2. Using intubation assisting devices as the ETT stylet, Eschmann tracheal tube introducer (gum-elastic bougie tube), video laryngoscope or the flexible bronchoscopy in difficult to intubate cases [2].
3. Applying appropriate cuff pressure not to exceed 20 mm H<sub>2</sub>O.
4. Stabilization the ETT using fixation tapes or devices.

### III. Measures which should be applied *after* intubation:

1. Frequent suctioning of the oral and endotracheal secretions.
2. Application of antiseptics as chlorhexidine to decontaminate the oral cavity.
3. Assessments of skin integrity around lips and adhesive tape at least twice daily.

### 3. Complications that occur immediately during endotracheal tube (ETT) insertion

Complications of tracheal intubation might occur at any stage during the intubation with devastating consequences which may last as long as patients survive.

**Table 1A** lists the chronic complications that usually result from trauma during intubation.

---

Prolonged voice hoarseness
Arytenoid dislocation
Cervical spine and spinal cord injuries
Traumatic dental injury

---

**Table 1A.** Chronic complications that occur immediately at ETT insertion.

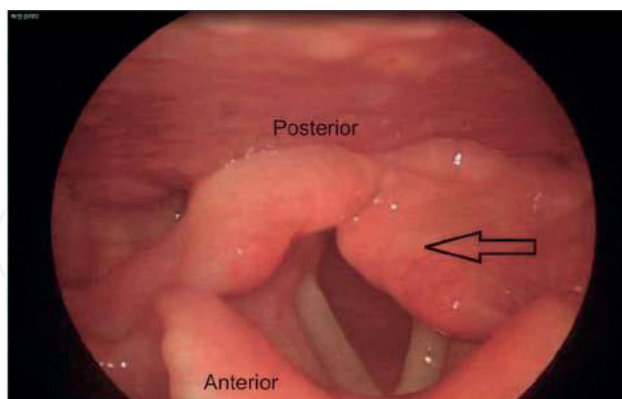
#### 3.1. Post intubation prolonged voice hoarseness

*Temporary* hoarseness is a common complain that occur in one third [3] to half [4] of the intubated patients and usually resolve spontaneously within 1 week; however, the incidence of *prolonged* hoarseness (>7 days) is estimated to be less than 1% [4, 5]. Vocal cord edema or lacerations, epiglottic hematoma and vocal cord paralysis secondary to compression of anterior branch of the recurrent laryngeal nerve are all potential etiologies of prolonged hoarseness [6]. In a prospective study 7 out of 25 cases (28%) of prolonged hoarseness had no identifiable causes [4]. *Permanent* hoarseness is even more rare, and being caused by granuloma of the vocal cord or arytenoid dislocation. The risk factors for this complication found to be longer duration of intubation, older age [4] and female gender [7]. Using a smaller size tube especially for females has been suggested to decrease the incidence of prolonged voice hoarseness [4, 8].

#### 3.2. Arytenoid dislocation

Arytenoid dislocation is a rare cause of vocal cord paralysis with less than 0.1% incidence rate [9]. The commonest mechanism of intubation related vocal cord paralysis is compression of the anterior branch of the recurrent laryngeal nerve as a result of prolonged intubation which will be discussed separately under complication of prolonged intubation subtitle. Risk factors for this complication can either be related to patients or the procedure. Patients related factors include retrognathia, dental malocclusion, a large tongue base, and cricoarytenoid joint involvement by rheumatoid arthritis. While; Procedure related risk factors include traumatic and/or prolonged intubation, protrusion of the endotracheal tube stylet, pressure from the distal curved part of the ETT and inexperience and poor techniques by the performance [10]. The majority of the patients present with dysphagia [11]; prolonged hoarseness, sore throat, and cough are less frequent symptoms. There are two types of dislocation, the posterolateral and the anteromedial dislocation; the latter being the most dangerous as it can compromise the

airway causing acute stridor and acute respiratory distress soon after extubation [12]. **Figure 1** shows example of anteromedial left arytenoid cartilage dislocation [13].



**Figure 1.** Laryngoscopic image of anteromedial dislocation of left arytenoid cartilage. Courtesy of Oh et al. [13].

Diagnosis can be confirmed by laryngoscopy and/or CT scan [14]. Laryngeal electromyography is sometimes used to differentiate arytenoid dislocation from recurrent laryngeal nerve paralysis. Tracheotomy is required in cases which present with acute airway compromise, other cases may have spontaneous repositioning of arytenoid cartilage thus do not need treatment [15]. Many surgical laryngoscopic techniques have been described as the definitive treatment [16, 17]. Late treatment options include Teflon injection, cricoarytenoid arthrodesis [18] and laryngeal framework procedure [19].

### 3.3. Cervical spine and spinal cord injuries

Urgent intubation to ensure protection of the airways is frequently required for poly-trauma patients. Careful manipulation of the neck by an experience health care provider is of crucial importance as such patients potentially have cervical spine injuries. Predictors of spinal injury in poly-trauma cases are accident by motor vehicle collision or fall down. Presence of pelvic fracture or Injury Severity Score (ISS) >15 should alert the physician to a possible cervical spine involvement [20]. Patients with systemic diseases which potentially affect the cervical spine as rheumatoid arthritis or ankylosing spondylitis must be handled as high risk for intubation related cervical spine injuries. Once the health care provider suspects a high risk cervical spine injury, he should maintain the patient's head in a neutral position throughout the intubation procedure. Cervical hyperextension in such cases can traumatize the spinal cord resulting in paraplegia. Manual In-Line Stabilization (MILS) is the recommended method to stabilize the head and neck during high risk intubation. The caveats of this method are: firstly, the need of a second health care provider who stabilizes the patient's occiput and mastoid processes using his **both** hands. Secondly, it decreases the laryngoscopic view by 45% [21]. Application of cervical collar is another important protective measure; available collars include soft collar, hard collar, extrication collar, Philadelphia collar. Again, application of collar significantly limit mouth opening and make intubation harder [22]. Cervical spine can also be stabilized using a bilateral sandbags with 3-inch-wide cloth tape across the forehead. Adding Philadelphia collar to the sand bags further reduced the extension movement [23].

In cases of difficult intubation the available choices are:

1. Video or fiberoptic laryngoscopy intubation.
2. Gum elastic bougie which has been shown in a clinical study to facilitate the intubation while applying MILS [21].

### 3.4. Traumatic dental injury

The incidence of traumatic dental injury found to be 1:2805 in a large analysis of more than 500 thousand surgeries. The most common tooth to be traumatized is the upper incisors; furthermore, 13% of the cases had multiple teeth involved. Different type of teeth injuries have been described, crown fracture and partial dislocation being the commonest [24]. Difficult intubation is the main risk factor for dental injury, other risk factor include poor dentation and preexisting craniofacial abnormalities [24].

## 4. Complications of the prolonged intubation

Prolonged intubation is defined as intubation exceeding 7 days [25]. Clinical studies have shown that prolonged intubation is a risk factor for many complications.

**Table 1B** lists complications of prolonged intubation that present while patient is still on mechanical ventilator or early at extubation.

---

Pressure ulcer around adhesive tapes

Vocal cord paralysis

Ventilator-associated pneumonia (VAP)

Sinusitis

Tracheomalacia

Laryngotracheal stenosis

---

**Table 1B.** Complications of prolonged intubation.

### 4.1. Mucosal/dermal pressure ulcer

Mucosal/dermal pressure ulcers are caused either by the tube itself or by the securing taps and devices. It can affect the lips, mouth, gums, and tongue. This complication is very common despite it is preventable; its incidence reported to be 20% in mechanically ventilated patients [26]. The identified risks for pressure ulcer are [27, 28]:

1. Hypoalbuminemia, older age, catabolic diseases.
2. Increase pressure, shearing forces and friction over bony prominence.
3. Moisture.



Prevention of ETT related pressure ulcer can be summarized in the following steps [29]:

1. To Proper size of the tube before the insertion.
2. To adequately secure the tube to prevent dislodgment without creating additional pressure.
3. To inspect the skin beneath the tube at least twice daily.
4. To keep the skin under the tube dry and clean as possible.
5. To reposition the ETT to redistribute pressure while make sure that the ETT depth did not change.
6. To remove the tube once it is not absolutely necessary.

Pressure ulcers prevention is crucial as they are painful and their healing process is slow. Generally, removal of the cause of the pressure, cleaning, application of antiseptics and debridement is the available treatment options.

#### **4.2. Vocal cord paralysis**

Intubation related vocal cord paralysis is rare with estimated incidence of 0.03%; nevertheless, it constitutes 22.6% of all causes of vocal cord paralysis [30]. It is usually a result of compression of the anterior branch of the recurrent laryngeal nerve between the inflated cuff of the ETT and the thyroid cartilage [31]. Prolonged intubation is the major risk factor for vocal cord paralysis which can be unilateral (left vocal cord is more commonly involved than the right) or bilateral [6]. Unilateral vocal cord paralysis present immediately after extubation with hoarseness of voice and dysphonia; while, bilateral paralysis presented as sever stridor which lead to reintubation. Re-establishment of vocal cord motion is a good prognostic sign of improvement of the voice [32]. In bilateral vocal cord palsy pulmonary function testing shows variable extrathoracic obstruction on flow volume loop [33]. Direct laryngoscopy and/or laryngeal electromyography are the diagnostic test of choice. Intervention is not required for unilateral paralysis as spontaneous resolution usually occurs on average of about 10 weeks [6], however, if no resolution occurs in 12 months then recovery is unlikely [32]. Temporary injection of the affected vocal cord is an option to improve the voice [32]. Unfortunately, tracheostomy is necessary in many cases suffering from bilateral vocal cord paralysis for long term management.

#### **4.3. Ventilator-associated pneumonia (VAP)**

Ventilator-associated pneumonia (VAP) is defined in the latest Infectious Diseases Society of America (IDSA) and the American Thoracic Society (ATS) guideline as a pneumonia occurring >48 h after endotracheal intubation [34]. VAP is subsequently divided for practical reasons in to an early onset pneumonia and late-onset pneumonia; the earliest is a pneumonia that develops within the first 4 days of admission in the mechanically ventilated patients [35]. A systematic review has estimated that between 10 and 20% of patients receiving >48 h of mechanical ventilation develop VAP [36]; up to 50% of them develop an early VAP (within the first 4 days after admission) [35]. Interestingly, the VAP hazard is decreasing over days, this has been shown in a prospective multicentre Canadian study where VAP rate was approximately 3% per day in the first week of mechanical ventilation, then the rate dropped to 2%

and 1% per day in the second and the third week respectively [37]. Gastric colonization, oropharyngeal and tracheal colonization, and cross colonization of the patients by contaminated hands of hospital personnel are all risks for VAP. Endotracheal tubes itself appear to be an independent risk factor for VAP [38]. Its presence impairs the host natural defenses against infections; furthermore, bacteria adhere to the plastic tube forming a complete or partial biofilm in 84 and 95% respectively [39]. Intubated patients are having recurrent aspirations of dislodged parts of this biofilm or from the pooled secretions above the tube cuff.

Studies have shown that the bacterial colonization is changed from community to nosocomial pattern after the fourth day of the admission [34]. In early-onset pneumonia the commonest pathogens include, *Streptococcus pneumoniae*, *Haemophilus influenzae* and methicillin sensitive *Staphylococcus aureus* (MSSA); while in the late onset methicillin resistant *Staphylococcus aureus* (MRSA), Gram-negative bacilli such as *Pseudomonas aeruginosa*, *Escherichia coli*, *Klebsiella pneumoniae*, and *Acinetobacter baumannii* are frequently encountered [40]. Moreover, it is not uncommon for VAP to have polymicrobial infection. VAP diagnosis is achieved by using the following diagnostic criteria [41]:

1. Clinical sign of infection as fever, purulent tracheal secretions, and leucocytosis.
2. Bacteriologic evidence of infection.
3. Radiologic suggestion of infection.

Application of strict prevention measures in the intensive care units is practical approach to decrease the burden of VAP on the patients and the health care system. VAP prevention measures include:

1. *Noninvasive positive-pressure ventilation in selected groups of patients.*
2. *Silver covered tube:* it has been shown in a Cochrane review that silver coated tube decrease the risk of VAP in the first 10 days of mechanical ventilation possibly due to the antimicrobial effect of silver [42].
3. *Mouth hygiene with chlorhexidine as a mouthrinse or a gel:* this has shown in a Cochrane review to reduce the risk of VAP from 24% to about 18% [43].
4. *Positioning the patient in semirecumbent position:* decrease the risk of VAP from 35 to 8% comparing to supine position [44].
5. *Applying an endotracheal tube cuff pressure of 20 cm H<sub>2</sub>O to prevent aspiration.*
6. *Continuous aspiration of subglottic secretions (CASS):* it reduce both early and late onset VAP [45].
7. *Discontinuation of mechanical ventilation as early as possible.*

IDSA/ATS updated guideline recommends empirical coverage of both *S. aureus* and *P. aeruginosa* in patients with suspected VAP. They recommended either vancomycin or linezolid to cover MRSA in at risk patients or in patients who are treated in units with high methicillin resistant rate (>10–20%). Single antipseudomonal antibiotic is generally suggested unless the patient is at high risk for antimicrobial resistance or being treated in a unit with high resistant rate for pseudomonas (>10%). A 7-day course is generally recommended [34].



#### 4.4. Sinusitis

Incidence of nosocomial sinusitis is estimated to be 12 cases per 1000 patient-days [46]. Prolonged intubation is the main risk factor as the majority of the infections occur after 7 days of the hospitalization [47]. The route of intubation either orotracheal or nasotracheal does not alter the nosocomial sinusitis rate as shown in a randomized clinical trial of patients needing intubation for more than 7 days [48]. Other identified risk factors include sedative use, nasogastric feeding tube, Glasgow Coma Score (GCS) less than 7 and nasal colonization with Gram-negative bacteria [46]. Nosocomial sinusitis usually presents with fever; the disease should be suspected in all intubated patients who have a fever without an obvious source. Most patients have leucocytosis [47]; purulent nasal discharge is a useful clinical sign that raises the suspicion of sinusitis as a source of the infection. Air-fluid level or opacification are the radiological signs seen on the sinus CT scan images. Microbiological confirmation of the infection can be achieved by culture of sinus fluid in 75 and 90% of the cases using antral tap or endoscopic tissue culture respectively [49]. Infective bacteria that cause nosocomial sinusitis are similar to those of VAP, furthermore, up to 62% of patients with confirmed sinusitis had evidence of concomitant ventilator-associated pneumonia (VAP); thus, assessment for VAP is warranted [50]. Nosocomial sinusitis requires 5–7 days of empirical broad-spectrum systemic antibiotic that cover the common hospital-acquired pathogens until the result of the sinus fluid culture is available [51]. Additional local measures include removal of nasogastric tubes and using nasal decongestants [51]. Surgical drainage of the infected sinuses is indicated if the condition failed to respond to the appropriate course of antibiotic therapy within 2–5 days of treatment [51].

### 5. Late onset complications

In this section we discuss the complications which usually present days to weeks after extubation. Many of the late-onset complications are consequences of prolonged intubation. **Table 2** summarizes the late-onset complications.

#### 5.1. Obstructive fibrinous tracheal pseudomembrane

Formation of an obstructive fibrinous tracheal pseudomembrane (OFTP) is a rarely reported but potentially fatal complication. OFTP has been reported in 53 patients (39 adult and 15

---

Obstructive fibrinous tracheal pseudomembrane formation

Post-intubation tracheal stenosis

Laryngeal stenosis

Tracheomalacia

Tracheoesophageal fistula

Tracheoarterial fistula

---

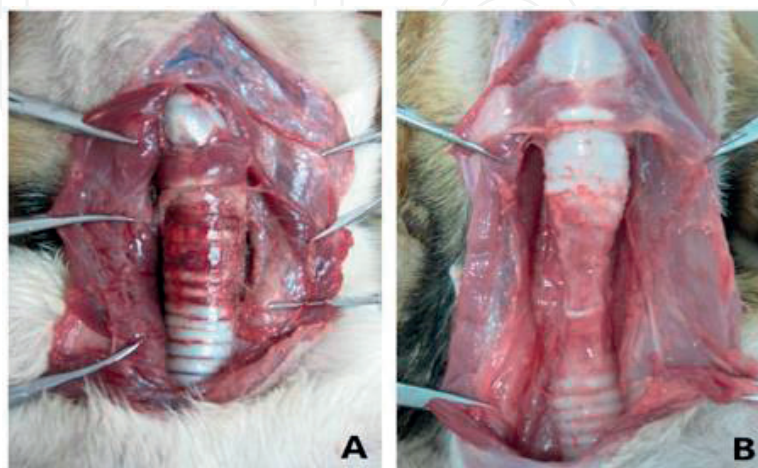
**Table 2.** Late onset complications.

pediatric) until September 2016 [52]. The OFTP is not just a thick mucus plug that impact on the tracheal wall; it is a well-formed, well-organized fibrinous membrane.

The exact mechanism of this fibrinous material formation is not completely known. It is hypothesized that OFTP is a consequences of tracheal ischemic injury which lead to mucosal injury. This cause desquamation and necrosis of the tracheal epithelium in addition to polymorphonuclear cells infiltration; and subsequently fibrinous material formation [53, 54]. OFTP has been reported in patients intubated with different types of ETT including cuffed rubber tubes, double lumen tube, and cuffed and uncuffed silicone tubes. Clinical studies have suggested several risk factors such as increase pressure of ETT cuff, usage of large tracheal tubes, traumatic intubation and prolonged intubation [54]. Presence of one or more of the previously mentioned risk factors is not absolutely necessary for OFTP to develop. Patients having OFTP most commonly present with post extubation stridor, cough and/or hoarseness with 74.1%, 13% and 9.3% respectively. Respiratory failure may develop in almost one third of the cases. The median time to onset of symptoms after extubation was 30 h in adult population. Nevertheless, OFTP is still in the differential diagnosis for early extubation failure; it has been presented immediately after extubation in few cases [52]. CT scan can show the intratracheal pseudomembrane, however, the definitive diagnosis is usually obtained by flexible bronchoscopy. Spontaneous expulsion of the fibrinous tracheal pseudomembrane is uncommon (11.1%), and flexible bronchoscopy is a very useful option for removal of the pseudomembrane especially in the pediatric population. Rigid bronchoscopy is another important tool which was reported to be necessary for a successful management in more than 50% of the adult patients [52].

## 5.2. Post intubation tracheal stenosis (PITS)

The incidence of PITS was previously estimated to occur in 1% of the intubated patients; however, the use of low pressure high volume cuffs has reduced its incidence by 10-fold [55]. The pathogenesis of PITS starts by a mucosal ischemic injury due to excessive ETT cuff pressure (>30 mm Hg) [56]. This compression injury on the tracheal cartilages causes chondritis with subsequent cicatricial fibrosis and progressive stenosis [57]. **Figure 2** shows the ETT cuff related compression injury in a canine model [58].



**Figure 2.** A. Congestion of the external tracheal wall compressed by cuff was observed immediately after extubation. B. Tracheal cartilage underwent necrosis and collapsed at 2 weeks after extubation. Courtesy of Su et al. [58].

PITS is categorized into three types [55]:

1. *Simple (web-like) stenosis* (**Figure 3A and D**):

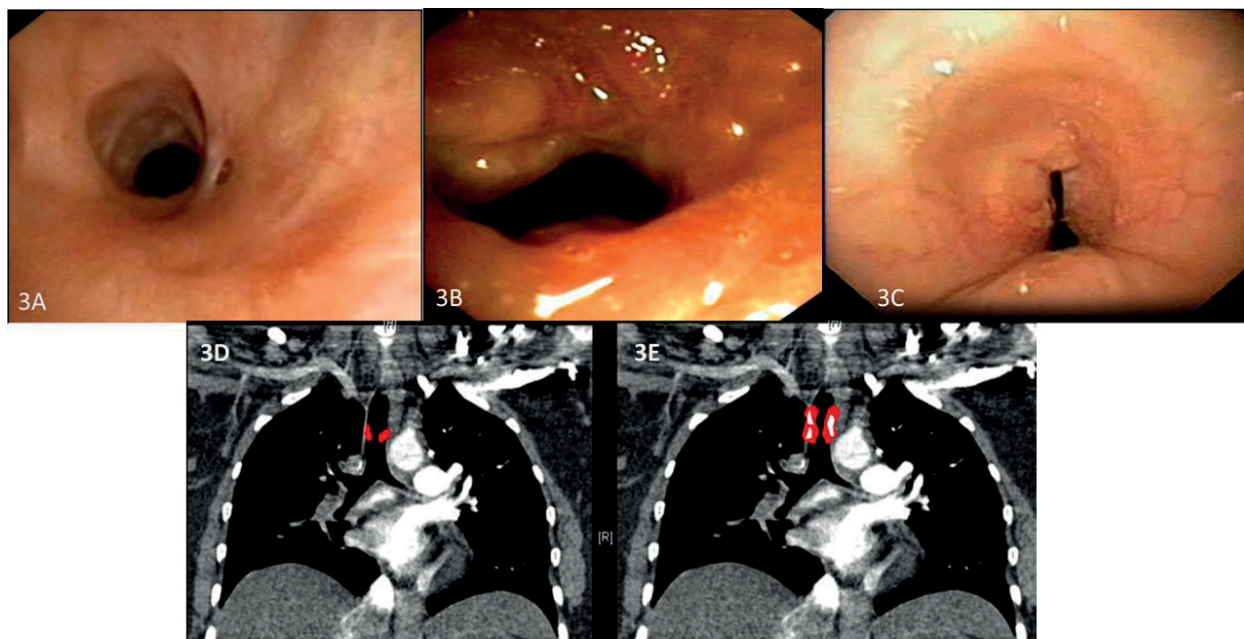
- The length is less than 1 cm
- No or minimal damage to tracheal cartilages.

2. *Complex stenosis* (**Figure 3B and E**):

- Longer than 1 cm.
- Tracheal cartilages are damaged.
- Usually complicated with tracheomalacia.

3. *Pseudoglottic (A-shaped or tent-shaped) stenosis* (**Figure 3C**) [59]:

- It is a particular subtype of the complex stenosis that usually follows tracheostomy insertion.
- The stenosis is due to dislocation or fracture of the tracheal cartilaginous rings with localized tracheomalacia



**Figure 3.** A–C: Bronchoscopic images show the different types of the PITS (G. Stratakos; *Intubation/Long-Term Complications of Tracheal Intubation*). D and E: Schematic illustration of simple and complex PITS on coronal cut of chest CT (A. Touman; *Intubation/Long-Term Complications of Tracheal Intubation*).

Increased ETT cuff pressure is considered to be the most important cause of PITS; other proposed risk factors are [60]:

1. *Oversizing the ETT* in comparison to the tracheal lumen.
2. *Prolonged intubation*. It should be noted that a brief intubation does not exclude the diagnosis of PITS as it has been reported to follow intubation of less than 24 h [61].

3. *Hypotension*
4. *Steroid use and local tracheal infection* are potential risk factors.

Patients with PITS usually complain of dyspnea with or without stridor. Expiratory wheeze at exertion is also a feature of PITS which can be easily confused with asthma. Therefore, the diagnosis is not initially suggested in up to 44% of the cases [56]. Furthermore, PITS manifest lately during patients' recovery from the ICU admission; during which patients' physical activity is minimal. Thus dyspnea and stridor may not be clinically evident until the disease reaches an advanced stage i.e. trachea has lost 70% of its diameter [55, 62].

PITS symptoms usually start within the first 3 months after extubation. The stenotic segment can be visualized by the computed tomography or directly during bronchoscopy. If pulmonary function test is requested the characteristic plateaued expiratory curve of the flow-volume loops exhibit only if the tracheal lumen is critically stenosed [55]. Management of PITS requires a multidisciplinary approach including thoracic surgeon and interventional pulmonologist experience in the treatment of such cases. Simple web-like stenoses can be treated by radial incisions at 3 and 9-o'clock positions using neodymium-yttrium aluminum garnet (Nd-YAG) laser, photo-dissection or electro-knife [63]. Circumferential sleeve resection with end to end anastomosis is the treatment of choice if applicable for the Complex stenosis and in cases of multiple relapses of the web like stenoses. In non-operable patients balloon dilatation, Nd-YAG laser, photo-dissection and/or stent placement are alternative options [55].

### 5.3. Tracheomalacia

Malacia derives from the Greek word "μαλακία" which means softness. Tracheomalacia (TM) describes the condition where the anterolateral wall of the trachea collapses during respiratory cycle due to softening of the cartilaginous rings that maintain the contour of the trachea. If the disease extends to involve the trachea and the main bronchi the term tracheobronchomalacia (TBM) is used. In cases where the posterior membranous part of the trachea excessively displaces anteriorly during expiration as a result of atrophy of the longitudinal elastic fibers of the membranous wall, the condition is described as excessive dynamic airway collapse (EDAC) [64]. TM and EDAC may or may not coexist [65].

The tracheal lumen caliber normally varies during the respiratory cycle; decrease in the cross-sectional area of the trachea by more than 50% is considered abnormal [66]. Tracheomalacia may result from primary (congenital) or secondary (acquired) causes;

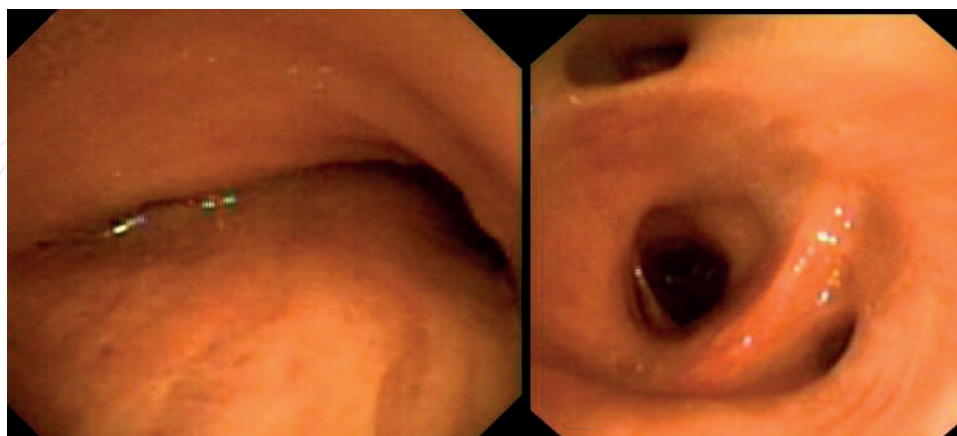
The exact incidence of the TM after intubation is unknown; in general the acquired TM is more common than the congenital one [64]. Intubation and tracheostomy are the commonest secondary causes [66]. Risk factors and the pathogenesis of the TM are similar to PITS where the tracheostomy stoma or the excessive and/or prolonged ET tube cuff pressure causes airway ischemia and chondritis which eventually result in necrosis and softening of the tracheal cartilage [66]. Depending on the site of the insult TM can be



intrathoracic or extrathoracic; the intrathoracic (below the thoracic inlet) tracheomalacia being the commonest. In cases of intrathoracic tracheomalacia the trachea collapses during expiration because the intrathoracic pressure exceeds the intraluminal pressure; while in the extrathoracic tracheomalacia the collapse occur during the inspiration because the atmospheric pressure exceed the negative intratracheal pressure [67].

TM might be overseen if the tracheal narrowing is mild; On the contrary, it can be diagnosed early in case of difficulty to wean a patient from mechanical ventilation [6]. Intubation itself can pose diagnostic challenges for diagnosis because the ETT keeps the malacic part of the trachea patent preventing its collapse. Moreover, the positive-pressure ventilation acts as a pneumatic stent [65]. In milder cases, exertional dyspnea, cough, difficulty to clear sputum and hemoptysis are the main symptoms [68]. Barking cough [69] and cough syncope [70] associated with forced cough are also feature of the disease. In severe cases of TM symptoms can progress to hypercapnic (type 2) respiratory failure [71]. Inspiratory and/or expiratory stridor presence depends on the severity of the collapse and the location of the malacic tracheal segment. As was the case with PITS, TM poses diagnostic challenge due to overlap between its symptoms and asthma symptoms. In fact, dyspnea associated with wheeze is present in 51% of TM cases which frequently misdiagnosed as bronchial asthmas. Moreover, physician might confuse the recurrent episodes of bronchitis which result from the retained secretions by asthma exacerbation. History of ET intubation or tracheostomy should alert the treating physician to consider TM especially if the patient condition is refractory to corticosteroids and bronchodilators therapy [65].

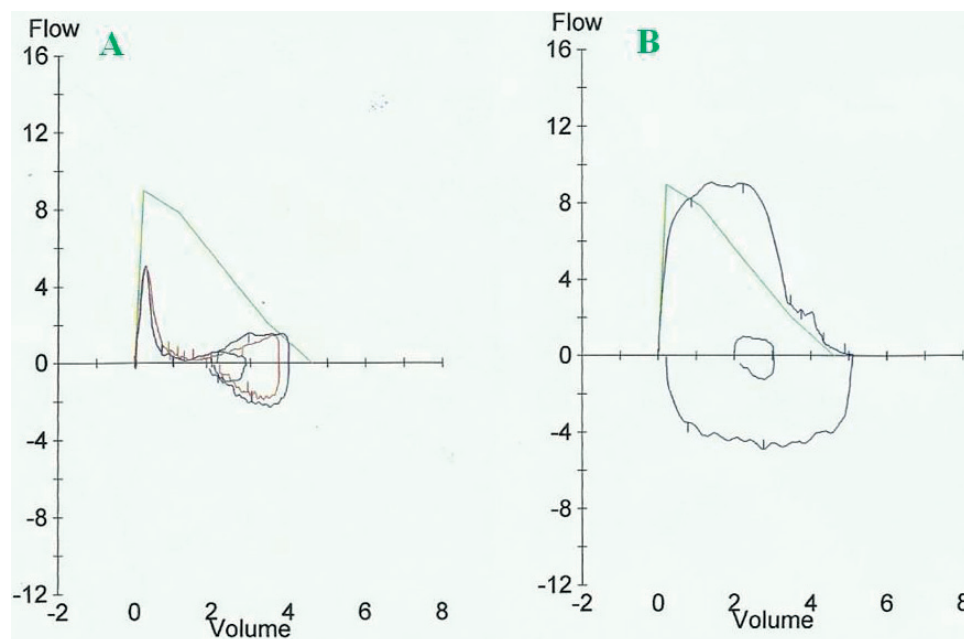
Once TM is suspected a dynamic airway CT scan (during inspiratory and expiratory phase) can confirm the diagnosis. The dynamic flexible bronchoscopy preferably performed on spontaneously breathing patients under conscious sedation is considered the gold standard diagnostic method (**Figure 4**) [72]. Cine fluoroscopy and Cine magnetic resonance imaging are alternative methods for diagnosis.



**Figure 4.** Bronchus intermedius with severe bronchomalacia, before and after establishment of C-PAP non-invasive mechanical ventilation (G. Stratakos; Intubation/Long-Term Complications of Tracheal Intubation).

Different abnormalities on the pulmonary function test can suggest the TM, however, none are characteristic. The reported abnormalities include:

1. The commonest abnormality is an *obstructive lung physiology* with decreased value of forced expiratory volume in 1 s (FEV1); it was reported to occur in approximately 70% of the cases [73].
2. *Flattening of the expiratory limb of the flow volume curve*. This pattern is highly suggestive of TM and it was recorded in 50% of the moderate severity cases [73].
3. *The flow-volume loop shows rapid declines of the maximal expiratory flow following a sharp low peak* [74] **Figure 5**.
4. Rarely, *flow oscillations (saw-tooth appearance)* appear on the flow volume curve (observed in 1.4% of the cases) [75, 76].



**Figure 5.** A. The flow volume loop of a post intubation TM patient shows rapid decline in the maximal expiratory flow after a sharp peak. B. Flow volume loop of the same patient after treatment with tracheal silicon stent (G. Stratakos; Intubation/Long-Term Complications of Tracheal Intubation).

Incidental discovery of TM or EDAC during bronchoscopy in asymptomatic patients does not require medical intervention. Available treatments for the symptomatic cases include:

1. *Noninvasive positive-pressure ventilation (NIPPV)* using Continuous positive airway pressure (CPAP) which act as pneumatic splint for the malacic collapsing airway [65].
2. *Bronchoscopic interventions and stent placement* are one of the most commonly used treatment options in TM. Silicone stents are preferred because of the dynamic nature of the airway during breathing. Patients should be aware of the need of continues care of the stent to prevent obstruction of the stent by retained mucus [65].
3. *Tracheostomy* which bypasses the malacic segment; if a longer tube used as Montgomery T-tube the tube itself splint the airway open. In cases of long malacic segment it can be combined with the NIPPV [64].

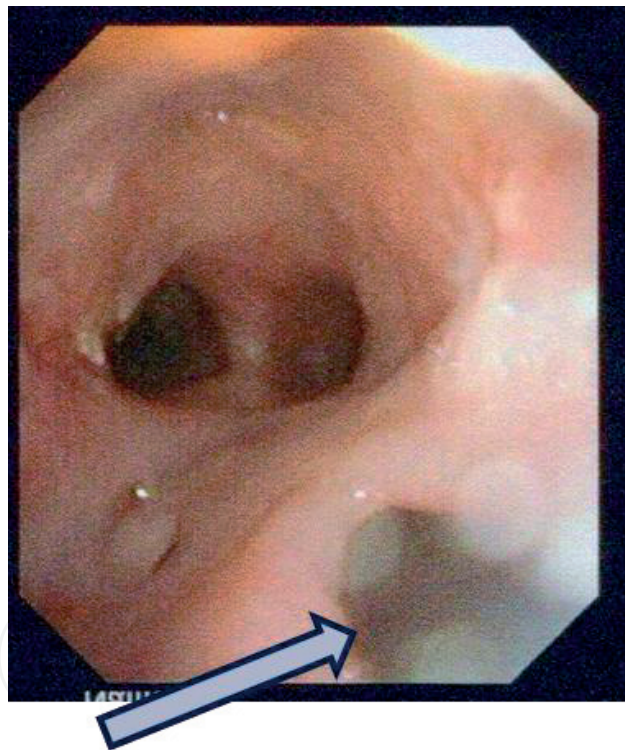


4. *Surgical interventions* such as:

- a. Tracheal resection and end to end anastomosis can be curative in short segment tracheomalacia [77].
- b. Tracheobronchoplasty: different surgical methods have been described to reinforce the wall of the malacic trachea; surgeon used mesh, autologous grafts from fascia, bone or costal cartilage as tracheal splint. Biocompatible ceramic rings and plastic prostheses have also been used [64].

#### 5.4. Tracheoesophageal fistula

Development of a tracheoesophageal fistula (TEF) in an intubated is rare; it is estimated to occur in less than 1% of the intubated patients [78]. High ETT cuff pressure is the major cause of this complication, it cause the tube to erode through the posterior membranous part of the trachea in to the esophagus forming a communicating tract **Figure 6**.



**Figure 6.** Illustrates a TEF shown during bronchoscopy. Arrow is pointing the orifice of the esophageal fistula (Gr. Stratakos; Intubation/Long-Term Complications of Tracheal Intubation).

Ischemic necrosis starts to appear after as little as 10 h of intubation with ETT cuff pressures of greater than 20–30 cm of water [78]. Other risk factors of TEF include [79]:

1. Prolonged duration of intubation.
2. Excessive repeated ETT manipulations.
3. Use of a rigid nasogastric tube

#### 4. Diabetes, infection and/or steroids use.

TEF presentations are variable and depend in many cases on the size of the fistula and the amount of the gastric contents regurgitated to the airway. TEF may be discovered by the treating team while the patient on mechanical ventilator in cases the enteral food materials are aspirated from the ETT during suctioning. Physician might also notice that the patient's abdomen is distended with air; positive endotracheal cuff leaks might also be the pointer toward the diagnosis. On the other hand, the patients might present after extubation with choking and coughing with feedings, copious secretions, progressive dyspnea and recurrent episodes of aspiration pneumonia and/or recurrent hypoxemic events [80].

Once the condition is suspected clinically it can be confirmed by imaging. CT scan or esophagograph with barium or gastrografin contrast can be used. The communicating fistulous tract can directly be visualized during Esophagogastroduodenoscopy (EGD) or bronchoscopy. A small or high up fistulas might be missed during bronchoscopy; therefore, bronchoscopist should pull the ETT up and meticulously search the fistula [81]. Bronchoscopic signs of fistula include redness and swollen of the mucosa and/or presence of whitish material in the airway [81].

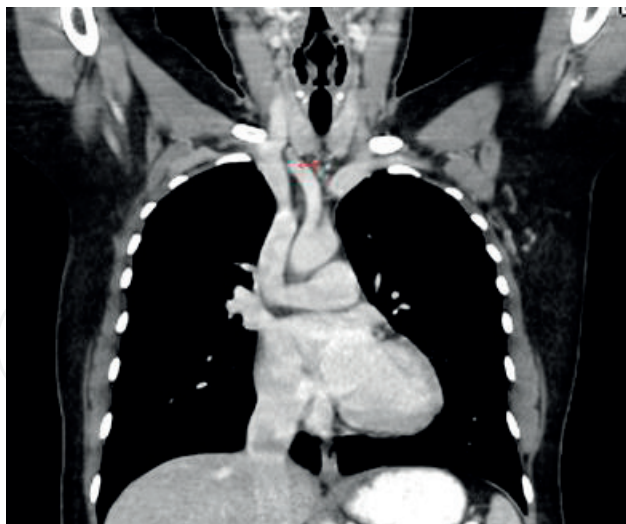
Spontaneous closure of the fistula is rare; therefore, once a TEF has been identified a prompt medical intervention should be undertaken as a bridge until the patient general condition improves to allow for definitive surgical interventions. The following management's steps are absolutely necessary [82]:

1. Prompt diagnosis and treatment of the aspiration pneumonia, using broad spectrum antibiotics which cover Gram positive and negative pathogens as well as the anaerobes.
2. A tracheostomy tube should be inserted so that its cuff to be below the fistula. If this is not possible, the ETT cuff to be placed distal to the fistula; its cuff should be inflated with minimal pressure.
3. Insertion of a jejunostomy tube for feeding or using total parenteral nutrition (TPN).
4. Gastrostomy tube insertion to reduce gastric contents reflux to the airway.

Surgical repair is the definitive treatment for most cases of intubation induced TEF. The TEF repair surgeries are high risk surgeries with a mortality rate of 10.9%; the recurrent rate of the fistulas is 7.9% and post-operative delayed tracheal stenosis has been reported to occur on 2.6% [82]. Endoscopic closure of small fistula, or inoperable ones using fibrin glue [81], cardiac septal defect occluders [83] or silicon rings [84] have been reported in few case reports. Single or dual esophageal and/or tracheal stent placement has been used for palliation in cases where TEF is resulted from malignant underlying diseases [81].

#### 5.5. Tracheoarterial fistula

The term tracheoarterial fistula describes an abnormal communication between the tracheo-bronchial tree and blood vessels. The innominate artery is the most affected vascular structure (72% of the reported cases) due to its close anatomical proximity to the trachea (**Figure 7**). The



**Figure 7.** Coronal CT with intravenous contrast shows the innominate artery lies adjacent to the trachea (A. Touman; Intubation/Long-Term Complications of Tracheal Intubation).

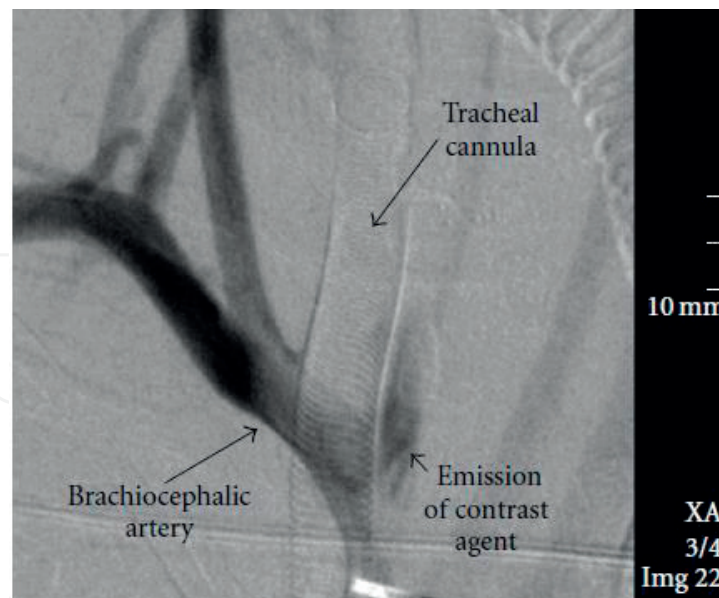
incidence of trachea-innominate fistula has been reported to be 0.7% of patient underwent tracheostomy [85]. Fistulas were also reported to occur between the trachea and the carotid arteries in 4.3% and between the trachea and the superior and inferior thyroid artery in 0.9 and 2.6% of the cases respectively [86]. It was also reported with aortic aneurysm (1.8%), or even with a venous structure as the right innominate vein <3.5% [86].

Low lying tracheostomy tube insertion is the major risk for this devastating complication [86]. Tracheoinnominate fistula can also be caused by ETT due to high cuff pressure [87]. Tracheal mucosa erosion can occur with cuff pressure as low as 25 mm Hg and as early as 24–48 h after tube placement [88, 89]. Other possible risk factors along with high cuff pressure are:

1. *Inappropriate cuff size* [87].
2. *Neuromuscular disorders* as (cerebral palsy, myoclonus epilepsy, agenesis of the corpus callosum, cerebral contusion, muscular dystrophy and spinal deformities) because the need of long-term mechanical ventilation and tracheostomy, as well as the presence of atypical head and neck positions of the patient [87, 90, 91].
3. *Tracheal ring fracture* during tracheostomy tube insertion; the tracheal ring fragment can cause continues mechanical irritation and eventually erode through the wall of innominate artery [92].

The full-blown presentation of tracheoarterial fistula might be preceded by warning symptoms, such as aspiration of blood during suctioning, bleeding beside the tracheal cannula, or pulsation of the cannula.

Bronchoscopy, catheter angiography or CT angiography are the investigational tools to localize the fistula. Nonetheless, a small size fistula can poses diagnostic challenges. In view of almost certain grave outcome in non-operated patients, non-diagnostic results of the investigations in presence of high clinical suspicion should not delay the surgical exploration and repair [93]. **Figure 8** shows catheter angiography picture of tracheoinnominate fistula.



**Figure 8.** Angiographic scan of a free contrast agent beside the innominate artery and beside left lateral side of the tracheal cannula. Courtesy of Richter et al. [92].

Warning signs such as sentinel bleeding or pulsating tracheostomy tube are described in literature and should be checked and reported despite they are frequently absent. Tracheoarterial fistula presentation is of massive bleeding. The majority of the cases (72%) bleed in the first 3 weeks [86], however, bleeding might occur as late as after 20 years [84]. In cases with massive bleeding hemostasis should be insured before pursuing investigations or definitive treatment. Hemostasis can be achieved by over inflating the tracheostomy/Endotracheal tube cuff until the bleeding stop [90]. The aspirated blood should be suctioned as asphyxiation is more likely to cause death than blood exsanguination. Supportive measures such as intravenous volume replacement to correct hypovolemia, or blood transfusion to replace the blood loss and optimize oxygen delivery should be given as necessary. The definitive treatment is surgical; with various techniques that have been described in the literature. There is always concern while dissecting the innominate artery to cause arterial insufficiency to the cerebral circulation. Neurological deficit reported to occur in 4.5% of fistula repair survivor [91]; therefore, cerebral blood flow monitoring during the surgery is of utmost important [90].

## Author details

Abdelfattah A. Touman<sup>1\*</sup> and Grigoris K. Stratakos<sup>2</sup>

\*Address all correspondence to: [abdoutouman@gmail.com](mailto:abdoutouman@gmail.com)

1 Cardiovascular Specialist Centre, Dammam, Kingdom of Saudi Arabia

2 1st Department of Respiratory Medicine, National and Kapodistrian University of Athens, Athens, Greece



## References

- [1] Frerk C, Mitchell VS, McNarry AF, Mendonca C, Bhagrath R, Patel A, O'Sullivan EP, Woodall NM, Ahmad I. Difficult Airway Society 2015 guidelines for management of unanticipated difficult intubation in adults. *BJA: British Journal of Anaesthesia*. 1 December 2015;**115**(6):827-848. DOI: 10.1093/bja/aev371
- [2] Komasaawa N, Hyoda A, Matsunami S, Majima N, Minami T. Utility of a gum-elastic bougie for difficult airway management in infants: A simulation-based crossover analysis. *BioMed Research International*. 2015;**2015**:5. Article ID 617805. DOI: 10.1155/2015/617805
- [3] Jones MW, Catling S, Evans E, Green DH, Green JR. Hoarseness after tracheal intubation. *Anaesthesia*. 1992;**47**:213-216
- [4] Yamanaka H, Hayashi Y, Watanabe Y, Uematu H, Mashimo T. Prolonged hoarseness and arytenoid cartilage dislocation after tracheal intubation. *British Journal of Anaesthesia*. 2009;**103**(3):452-455
- [5] Peppard SB, Dickens JH. Laryngeal injury following short-term intubation. *The Annals of Otolaryngology, Rhinology, and Laryngology*. 1983;**92**:327-330
- [6] Sue RD, Susanto I. Long-term complications of artificial airways. *Clinics in Chest Medicine*. 2003;**24**:457-471
- [7] Maruyama K, Sakai H, Miyazawa H, Toda N, Iinuma Y, Mochizuki N, Hara K, Otagiri T. Sore throat and hoarseness after total intravenous anaesthesia. *British Journal of Anaesthesia*. 2004 Apr;**92**(4):541-543. Epub 2004 Feb 6
- [8] Stout DM, Bishop MJ, Dwersteg JF, Cullen BF. Correlation of endotracheal tube size with sore throat and hoarseness following general anesthesia. *Anesthesiology*. 1987;**67**:419-421
- [9] Kambic V, Radsel Z. Intubation lesions of the larynx. *British Journal of Anaesthesia*. 1978;**50**:587-589
- [10] Tolley NS, Cheesman TD, Morgan D, Brookes GB. Dislocated arytenoid: An intubation-induced injury. *Annals of the Royal College of Surgeons of England*. 1990;**72**:353-356
- [11] Quick CA, Merwin GE. Arytenoid dislocation. *Archives of Otolaryngology*. 1978;**104**(5):267-270
- [12] Castella X, Gilabert J, Perez C. Arytenoid dislocation after tracheal intubation: An unusual cause of acute respiratory failure. *Anesthesiology*. 1991;**74**:613-615
- [13] Oh TK, Yun J-Y, Ryu CH, Park YN, Kim NW. Arytenoid dislocation after uneventful endotracheal intubation: A case report. *Korean Journal of Anesthesiology*. 2016;**69**(1):93-96. DOI: 10.4097/kjae.2016.69.1.93
- [14] Alexander AE, Lyons GD, Fazekas-May MA, Rigby PL, Nuss DW, David L, Williams K. Utility of helical computed tomography in the study of arytenoid dislocation and arytenoid subluxation. *The Annals of Otolaryngology, Rhinology, and Laryngology*. 1997;**106**(12):1020-1023

- [15] Gauss A, Treiber HS, Haehnel J, Johannsen HS. Spontaneous reposition of a dislocated arytenoid cartilage. *British Journal of Anaesthesia*. 1993;**70**:591-592
- [16] Leelamanit V, Sinkijcharoenchai W. A promising new technique for closed reduction of arytenoid dislocation. *The Journal of Laryngology and Otology*. 2012;**126**(2): 168-174
- [17] Lee SW, Park KN, Welham NV. Clinical features and surgical outcomes following closed reduction of arytenoid dislocation. *JAMA Otolaryngology. Head & Neck Surgery*. 2014; **140**(11):1045-1050
- [18] Prasertwanitch Y, Schwartz JJH, Vandam LD. Arytenoid cartilage dislocation following prolonged endotracheal intubation. *Anesthesiology*. 1971;**41**:516-517
- [19] Hoffman H, Brunberg J, Winter P, Sullivan M, Kileny P. Arytenoid subluxation: Diagnosis and treatment. *The Annals of Otology, Rhinology, and Laryngology*. 1991;**100**:1-9
- [20] Clayton JL, Harris MB, Weintraub SL, Marr AB, Timmer J, Stuke LE, et al. Risk factors for cervical spine injury. *Injury*. 2012 Apr;**43**(4):431-435
- [21] Nolan JP, Wilson ME. Orotracheal intubation in patients with potential cervical spine injuries. An indication for the gum elastic bougie. *Anaesthesia*. 1993;**48**:630-633
- [22] Goutcher CM, Lochhead V. Reduction in mouth opening with semi-rigid cervical collars. *British Journal of Anaesthesia*. 2005;**95**:344-348
- [23] Podolsky S, Baraff LJ, Simon RR, Hoffman JR, Larmon B, Ablon W. Efficacy of cervical spine immobilization methods. *The Journal of Trauma*. 1983 Jun;**23**(6):461-465
- [24] Warner ME, Benenfeld SM, Warner MA, Schroeder DR, Maxson PM. Perianesthetic dental injuries: Frequency, outcomes, and risk factors. *Anesthesiology*. 1999 May;**90**(5):1302-1305
- [25] Vogelhut MM, Downs JB. Prolonged endotracheal intubation. *Chest*. 1979 Jul;**76**(1):110-111
- [26] Pender L, Frazier S. The relationship between dermal pressure ulcers, oxygenation and perfusion in mechanically ventilated patients. *Intensive & Critical Care Nursing*. 2004;**21**: 29-38
- [27] Allman RM. Pressure ulcers among the elderly. *The New England Journal of Medicine*. 1989;**320**:850
- [28] Bourdel-Marchasson I, Barateau M, Rondeau V, Dequae-Merchadou L, Salles-Montaudon N, Emeriau JP, et al. A multicenter trial of the effects of oral nutritional supplementation in critically ill older patients. *Nutrition*. 2000;**16**:1-5
- [29] National Pressure Ulcer Advisory Panel, European Pressure Ulcer Advisory Panel and Pan Pacific Pressure Injury Alliance. In: Haesler E, editor. *Prevention and Treatment of Pressure Ulcers: Quick Reference Guide*. Perth, Australia: Cambridge Media; 2014
- [30] Sariego J. Vocal fold hypomobility secondary to elective endotracheal intubation: A general surgeon's perspective. *Journal of Voice*. 2010 Jan;**24**(1):110-112. Epub 2009 Jan 29



- [31] Ellis PD, Pallister WK. Recurrent laryngeal nerve palsy and endotracheal intubation. *The Journal of Laryngology and Otology*. 1975;**89**:823-826
- [32] Young VN, Smith LJ, Rosen C. Voice outcome following acute unilateral vocal fold paralysis. *The Annals of Otology, Rhinology, and Laryngology*. 2013 Mar;**122**(3):197-204
- [33] Miller RD, Hyatt RE. Evaluation of obstructing lesions of the trachea and larynx by flow-volume loops. *The American Review of Respiratory Disease*. 1973 Sep;**108**(3):475-481
- [34] Kalil AC, Metersky ML, Klompas M, Muscedere J, Sweeney DA, Palmer LB, et al. Management of adults with hospital-acquired and ventilator-associated pneumonia: 2016 Clinical Practice Guidelines by the Infectious Diseases Society of America and the American Thoracic Society. *Clinical Infectious Diseases*. 2016 Sep 1;**63**(5):e61-e111
- [35] Langer M, Cigada M, Mandelli M, Mosconi P, Tognoni G. Early onset pneumonia: A multicenter study in intensive care units. *Intensive Care Medicine*. 1987;**13**:342-346
- [36] Safdar N, Dezfulian C, Collard HR, Saint S. Clinical and economic consequences of ventilator-associated pneumonia: A systematic review. *Critical Care Medicine*. 2005 Oct; **33**(10):2184-2193
- [37] Guyatt GH, Leasa D, Jaeschke RZ, Brun-Buisson C. Incidence of and risk factors for ventilator-associated pneumonia in critically ill patients. *Annals of Internal Medicine*. 1998;**129**(6):433-440
- [38] Craven DE, Steger KA. Epidemiology of nosocomial pneumonia. New perspectives on an old disease. *Chest*. 1995;**108**:1S-16S
- [39] Sottile FD, Marrie TJ, Prough DS, Hobgood CD, Gower DJ, Webb LX, et al. Nosocomial pulmonary infection: Possible etiologic significance of bacterial adhesion to endotracheal tubes. *Critical Care Medicine*. 1986 Apr;**14**(4):265-270
- [40] Chastre J, Fagon J-Y. Ventilator-associated pneumonia. *American Journal of Respiratory and Critical Care Medicine*. 2002;**165**:867-903
- [41] Fagon J, Chastre J, Hance A. Evaluation of clinical judgment in the identification and treatment of nosocomial pneumonia in ventilated patients. *Chest*. 1993;**103**(2):547-553
- [42] Tokmaji G, Vermeulen H, Müller MCA, Kwakman PHS, Schultz MJ, Zaat SAJ. Silver-coated endotracheal tubes for prevention of ventilator-associated pneumonia in critically ill patients. *Cochrane Database of Systematic Reviews*. 2015;(8). Art. No.: CD009201. DOI: 10.1002/14651858.CD009201.pub2
- [43] Hua F, Xie H, Worthington HV, Furness S, Zhang Q, Li C. Oral hygiene care for critically ill patients to prevent ventilator-associated pneumonia. *Cochrane Database of Systematic Reviews*. 2016;(10). Art. No.: CD008367. DOI: 10.1002/14651858.CD008367.pub3
- [44] Drakulovic MB, Torres A, Bauer TT, Nicolas JM, Nogué S, Ferrer M. Supine body position as a risk factor for nosocomial pneumonia in mechanically ventilated patients: A randomised trial. *Lancet*. 1999;**354**(9193):1851-1858

- [45] Lacherade JC, De Jonghe B, Guezennec P, Debbat K, Hayon J, Monsel A, et al. Intermittent subglottic secretion drainage and ventilator-associated pneumonia: A multicenter trial. *American Journal of Respiratory and Critical Care Medicine*. 2010;**182**(7): 910-917
- [46] George DL, Falk PS, Umberto Meduri G, Leeper KV Jr, Wunderink RG, Steere EL, et al. Nosocomial sinusitis in patients in the medical intensive care unit: A prospective epidemiological study. *Clinical Infectious Diseases*. 1998;**27**(3):463
- [47] Caplan ES, Hoyt NJ. Nosocomial sinusitis. *JAMA*. 1982;**247**:639-641
- [48] Holzapfel L, Chevret S, Madinier G, et al. Influence of long-term oro or nasotracheal intubation on nosocomial maxillary sinusitis and pneumonia: Results of a prospective, randomized, clinical trial. *Critical Care Medicine*. 1993;**21**:1132-1138
- [49] Casiano RR, Cohn S, Villasuso E 3rd, Brown M, Memari F, Barquist E, Namias N. Comparison of antral tap with endoscopically directed nasal culture. *The Laryngoscope*. 2001;**111**(8):1333
- [50] Rouby J, Laurent P, Gosnach M, et al. Risk factors and clinical relevance of nosocomial maxillary sinusitis in the critically ill. *American Journal of Respiratory and Critical Care Medicine*. 1994;**150**:776-784
- [51] Stein M, Caplan ES. Nosocomial sinusitis: A unique subset of sinusitis. *Current Opinion in Infectious Diseases*. 2005;**18**:147-150
- [52] Sehgal IS, Dhooria S, Bal A, Aggarwal AN, Behera D, Agarwal R. Obstructive fibrinous tracheal pseudomembrane after endotracheal intubation. *Respiratory Care*. 2016 Sep;**61** (9):1260-1266
- [53] Deslée G, Bricchet A, Lebuffe G, Copin MC, Ramon P, Marquette CH. Obstructive fibrinous tracheal pseudomembrane. A potentially fatal complication of tracheal intubation. *American Journal of Respiratory and Critical Care Medicine*. 2000;**162**:1169-1171
- [54] Manassero A, Ugues S, Bertolaccini L, Bossolasco M, Terzi A, Coletta G. A very early stage of obstructive fibrinous tracheal pseudo-membrane formation. *Journal of Thoracic Disease*. 2012;**4**(3):320-322. DOI: 10.3978/j.issn.2072-1439.2012.05.10
- [55] Stratakos G. Postintubation tracheal stenosis and endoscopic management. *Pneumonologie*. 2003;**16**(3):262-270
- [56] Spittle N, McCluskey A. Lesson of the week: Tracheal stenosis after intubation. *BMJ*. Oct 21 2000;**321**(7267):1000-1002
- [57] Grillo HC, Cooper JD, Geffin B, et al. A low pressure cuff for tracheostomy tubes to minimize tracheal injury. A comparative clinical trial. *The Journal of Thoracic and Cardiovascular Surgery*. 1971;**62**:898-907
- [58] Su Z et al. A canine model of tracheal stenosis induced by cuffed endotracheal intubation. *Scientific Reports*. 2017;**7**:45357. DOI: 10.1038/srep45357

- [59] Plojoux J, Laroumagne S, Vandemoortele T, Astoul PJ, Thomas PA, Dutau H. Management of benign dynamic "A-shape" tracheal stenosis: A retrospective study of 60 patients. *The Annals of Thoracic Surgery*. 2015 Feb;**99**(2):447-453. DOI: 10.1016/j.athoracsur.2014.08.037. Epub 2014 Dec 12
- [60] Farzanegan R, Farzanegan B, Alehashem M, Zangi M, Niakan Kalhori SR, Sheikhy K, et al. Item selection and content validity of the risk factors of post-intubation tracheal stenosis observation questionnaire for ICU-admitted patients. *Tanaffos*. 2017;**16**(1):22-33
- [61] Yang KL. Tracheal stenosis after a brief intubation. *Anesthesia and Analgesia*. 1995 Mar;**80**(3):625-627
- [62] Andrews MJ, Pearson FG. Analysis of 59 cases of tracheal stenosis following tracheostomy with cuffed tube and assisted ventilation, with special reference to diagnosis and treatment. *The British Journal of Surgery*. 1973;**60**:208-212
- [63] Mehta AC, Lee FY, Cordasco EM, Kirby T, Eliachar I, De Boer G. Concentric tracheal and subglottic stenosis. Management using the Nd±YAG laser for mucosal sparing followed by gentle dilatation. *Chest*. 1993;**104**:673-677
- [64] Carden KA, Boiselle PM, Waltz DA, Ernst A. Tracheomalacia and tracheobronchomalacia in children and adults: An in-depth review. *Chest*. 2005 Mar;**127**(3):984-1005
- [65] Murgu SD, Colt HG. Tracheobronchomalacia and excessive dynamic airway collapse. *Respirology*. 2006;**11**:388-406
- [66] Feist JH, Johnson TH, Wilson RJ. Acquired tracheomalacia: Etiology and differential diagnosis. *Chest*. 1975;**68**(3):340-345
- [67] Austin J, Ali T. Tracheomalacia and bronchomalacia in children: Pathophysiology, assessment, treatment, and anaesthesia management. *Paediatric Anaesthesia*. 2003;**13**:3-11
- [68] Nuutinen J. Acquired tracheobronchomalacia. *European Journal of Respiratory Diseases*. 1982;**63**:380
- [69] Wright CD. Tracheomalacia. *Chest Surgery Clinics of North America*. 2003;**13**:349-357
- [70] Koziej M, Gorecka D. Cough-syncope syndrome in tracheobronchomalacia. *Pneumonologia i Alergologia Polska*. 1992;**60**:89-91
- [71] Collard P, Freitag L, Reynaert MS, et al. Respiratory failure due to tracheobronchomalacia. *Thorax*. 1996;**51**:224-226
- [72] Majid A, Gaurav K, Sanchez JM, et al. Evaluation of tracheobronchomalacia by dynamic flexible bronchoscopy. A pilot study. *Annals of the American Thoracic Society*. 2014;**11**:951-955
- [73] Gilkeson RC, Ciancibello LM, Hejal RB, Montenegro HD, Lange P. Tracheobronchomalacia: Dynamic airway evaluation with multidetector CT. *AJR*. 2001;**176**:205-210
- [74] Campbell AH, Faulks LW. Expiratory air-flow pattern in tracheobronchial collapse. *The American Review of Respiratory Disease*. 1965;**92**:781-791

- [75] Garcia-Pachon E. Tracheobronchomalacia: A cause of flow oscillations on the flow-volume loop. *Chest*. 2000;**118**:1519
- [76] Vincken W, Cosio MG. Flow oscillations on the flow-volume loop: A nonspecific indicator of upper airway dysfunction. *Bulletin Européen de Physiopathologie Respiratoire*. 1985;**21**:559
- [77] Grillo HC. Surgical treatment of postintubation tracheal injuries. *The Journal of Thoracic and Cardiovascular Surgery*. 1979;**78**:860-875
- [78] Mooty RC, Rath P, Self M, Dunn E, Mangram A. Review of tracheo-esophageal fistula associated with endotracheal intubation. *Journal of Surgical Education*. 2007 Jul-Aug;**64**(4):237-240
- [79] Darteville P, Macchiarini P. Management of acquired tracheoesophageal fistula. *Chest Surgery Clinics of North America*. 1996;**6**:819-836
- [80] Reed MF, Mathisen DJ. Tracheoesophageal fistula. *Chest Surgery Clinics of North America*. 2003 May;**13**(2):271-289
- [81] Ernst A, Herth FJ. *Principles and Practice of Interventional Pulmonology*. New York: Springer; 2013
- [82] Mathisen DJ, Grillo HC, Wain JC, Hilgenberg AD. Management of acquired nonmalignant tracheoesophageal fistula. *The Annals of Thoracic Surgery*. 1991;**52**:759-765
- [83] Li J, Gao X, Chen J, Lao M, Wang S, Zeng G. Endoscopic closure of acquired oesophagor-espriatory fistulas with cardiac septal defect occluders or vascular plugs. *Respiratory Medicine*. 2015 Aug;**109**(8):1069-1078. Epub 2015 May 5
- [84] Erdim I, Sirin AA, Baykal B, Oghan F, Guvey A, Kayhan FT. Treatment of large persistent tracheoesophageal peristomal fistulas using silicon rings. *Brazilian Journal of Otorhinolar-yngology*. Sep-Oct 2017;**83**(5):536-540. DOI: 10.1016/j.bjorl.2016.06.011. Epub 2016 Jul 21
- [85] Scalise P, Prunk SR, Healy D, Votto J. The incidence of tracheoarterial fistula in patients with chronic tracheostomy tubes. A retrospective study of 544 patients in a long term care facility. *Chest*. 2005;**128**:3906-3909
- [86] Schaefer OP, Irwin RS. Tracheoarterial fistula: An unusual complication of tracheostomy. *Journal of Intensive Care Medicine*. 1995;**10**:64-75
- [87] Tijana D, Ivana Č, Milenko B, Slobodan S. Iatrogenic tracheoarterial fistula: Case report and literature review. *Medicine, Science, and the Law*. 2017 Jul;**57**(3):143-145. DOI: 10.1177/0025802417720567
- [88] Stiles PJ. Tracheal lesions after tracheostomy. *Thorax*. 1965;**20**:517-522
- [89] Nordin U. Trachea and cuff-induced tracheal injury: An experimental study on causative factors and prevention. *Acta Oto-Laryngologica. Supplementum*. 1977;**345**:1-71
- [90] Furukawa K, Kamohara K, Itoh M, Morokuma H, Morita S. Operative technique for tracheo-innominate artery fistula repair. *Journal of Vascular Surgery*. 2014;**59**:1163-1167

- [91] Jones JW, Reynolds M, Hewitt RL, Drapanas T. Tracheo-innominate artery erosion: Successful surgical management of a devastating complication. *Annals of Surgery*. 1976 Aug; **184**(2):194-204
- [92] Richter T, Gottschlich B, Sutarski S, Müller R, Ragaller M. Late life-threatening hemorrhage after percutaneous tracheostomy. *International Journal of Otolaryngology*. 2011; **2011**:3. Article ID 890380. DOI: 10.1155/2011/890380
- [93] Vaidya N, Strauchler D, Guelfguat M. Computed tomography angiography diagnosis of tracheoinnominate fistula: A case report and review of literature. *Quantitative Imaging in Medicine and Surgery*. 2013;**3**(2):121-125

IntechOpen