

We are IntechOpen, the world's leading publisher of Open Access books Built by scientists, for scientists

4,800

Open access books available

122,000

International authors and editors

135M

Downloads

Our authors are among the

154

Countries delivered to

TOP 1%

most cited scientists

12.2%

Contributors from top 500 universities



WEB OF SCIENCE™

Selection of our books indexed in the Book Citation Index
in Web of Science™ Core Collection (BKCI)

Interested in publishing with us?
Contact book.department@intechopen.com

Numbers displayed above are based on latest data collected.

For more information visit www.intechopen.com



Surgical Treatment for Tricuspid Valve Infective Endocarditis

Takashi Murashita

Additional information is available at the end of the chapter

<http://dx.doi.org/10.5772/intechopen.74951>

Abstract

Isolated tricuspid valve infective endocarditis is relatively rare. However, the frequency of tricuspid valve infective endocarditis in the United States is rapidly increasing, mainly due to the epidemic of intravenous drug use. A medical treatment is the first choice for this disease; however, surgical intervention is required when the patients suffer from heart failure, large vegetation, or persistent bacteremia despite appropriate medical treatment. Several techniques for tricuspid valve reconstruction have been proposed, and their outcomes have been reported to be good. However, in the cases of severe valve destruction, tricuspid valve replacement is required. Post-surgical management of drug-induced infective endocarditis is challenging due to its poor compliance to medication and high rate of reinfection. There is an ethical controversy as to surgical indication for reinfection induced by relapse of drug use. In addition, because reoperation for tricuspid valve carries high risk, there is also a controversy regarding valve choice in drug users.

Keywords: tricuspid valve infective endocarditis, intravenous drug use, surgical outcomes

1. Introduction

Infective endocarditis carries high mortality and mortality. Murdoch et al. studied 2781 adults with definite infective endocarditis admitted to 58 hospitals in 25 countries [1]. They reported that surgical treatment was performed in 48%, and in-hospital mortality was 18%. Nevertheless, surgery during the current endocarditis episode was associated with decreased risk of in-hospital death (odds ratio, 0.56; 95% confidence interval, 0.44-0.69).

Tricuspid valve infective endocarditis was relatively rare and accounted for 5 to 10% of all infective endocarditis [2]. In the study of Murdoch et al. which was reported in 2009 [1], tricuspid valve infective endocarditis was found in 12% of the entire cohort. However, the frequency of tricuspid valve infective endocarditis is rapidly increasing along with the epidemic of intravenous drug use. Seratnahaei et al. reported that the incidence of tricuspid valve infective endocarditis was 6% between 1999 and 2000, and it markedly increased to 36% between 2009 and 2010 [3]. Also reported history of intravenous drug use increased from 15 to 40%.

2. Surgery for tricuspid valve infective endocarditis

2.1. Epidemiology

The key predisposing factors for tricuspid valve infective endocarditis include intravenous drug use, cardiac implantable electronic devices, long-term central venous access catheters, and congenital heart disease [4].

In the study of Murdoch et al. [1], current intravenous drug use was found in 16% of the cohort of North America, chronic intravenous access accounted was found in 25%, implantable cardiac devices accounted was found in 12%, and congenital heart disease accounted was found in 25%.

Moss et al. reported that 41% of injection drug users with bacteremia had the evidence of endocarditis [5].

Athan et al. performed a prospective cohort study which described a 6.4% incidence of cardiac device-related infective endocarditis among 2760 patients [6]. There was coexisting valve involvement in 37.3% patients and predominantly tricuspid valve infection (24.3%). Concomitant valve infection was associated with higher mortality than no valve infection (odds ratio, 3.31; 95% confidence interval, 1.71–6.39).

2.2. Indications for surgery

The most recent guidelines from the American Heart Association stated that the surgical intervention is reasonable for patients with certain complications with class IIa recommendations, and they also stated that it is reasonable to avoid surgery when possible in patients who are intravenous drug users [7]. The 2015 European Society of Cardiology guidelines for the management of infective endocarditis stated that surgery should be considered in the following situations with class IIa recommendations: [1] right heart failure secondary to severe tricuspid regurgitation with poor response to diuretic therapy, [2] infective endocarditis caused by organisms that are difficult to eradicate (e.g. persistent fungi) or bacteremia for at least 7 days despite adequate antimicrobial therapy, and [3] tricuspid valve vegetations >20 mm that persist after recurrent pulmonary emboli with or without concomitant right heart failure [8].

Hecht et al. followed the clinical course of 121 patients with right-sided infective endocarditis caused by intravenous drug use, and reported that vegetations greater than 20 mm were associated with increased mortality [9].

Kiefer et al. performed a prospective, multicenter study enrolling over 4000 patients with infective endocarditis and known heart failure status [10]. In-hospital mortality was lower in the patients undergoing valvular surgery compared with medical therapy alone (20.6 vs. 44.8%, $p < 0.001$), and 1-year mortality was also lower in patients undergoing surgery compared with medical therapy alone (29.1 vs. 58.4%, $p < 0.001$).

2.3. Timing of surgery

The early surgical intervention for left-sided infective endocarditis has been well suggested [7, 11, 12]; however, the surgical indications for right-sided infective endocarditis are not well defined.

Akinosoglou et al. suggested that the timing of surgical management depends on the following factors: [1] cause of endocarditis (e.g. urgent in pacemaker and prosthetic infective endocarditis), [2] causative infective factors (e.g. fungal and *Staphylococcus aureus*), [3] coexistent left-sided infection, [4] response to antibiotic therapy, [5] toxicity of medical treatment, and [6] complications of disease (e.g. abscess and increased vegetation size) [13].

Early surgery should be considered if the causative organism is *Staphylococcus aureus*, which often results in large vegetations, massive valve destruction, and embolic manifestations [14]. Remadi et al. reported that early surgery was associated with reduced mortality in *Staphylococcus aureus* infective endocarditis [15].

Taghavi et al. compared the outcomes between surgical management and medical treatment for tricuspid valve endocarditis [16]. They found that patients treated surgically had clear blood cultures sooner, defervesced earlier, and demonstrated a complete resolution of vegetations. They concluded that the early surgery is warranted for patients with tricuspid valve endocarditis when they are bacteremia and/or systemically infected despite optimal medical treatment.

In contrast, Gaca et al. reviewed the surgical outcomes for isolated tricuspid valve endocarditis using the Society of Thoracic Surgeons Database, and reported that patients in the healed tricuspid valve endocarditis had lower complications rates, shorter overall length of stay, and a trend toward lower operative mortality compared with active endocarditis [17].

2.4. Tricuspid valve reconstruction

Akinosoglou et al. suggested that, in intravenous drug users who run a high risk of complications, vegetectomy and valve repair, avoiding artificial materials should be considered as that can improve late survival rate [13].

Successful surgical intervention requires radical debridement of infected tissue first [4]. In case of leaflet perforation or small defects localized to one or two leaflets can be repaired by either direct closure or patch plasty using an autologous pericardial patch [18] (**Figure 1**).

In case of limited infection on the posterior leaflet, bicuspid valve formation of the tricuspid valve can be performed by excising the posterior leaflet and mobilizing the anterior and septal

leaflets [18] (**Figure 2**). Ghanta et al. reported good mid-term outcomes of suture bicuspidization of the tricuspid valve [19].

Artificial chordae using expanded polytetrafluoroethylene sutures can be applied after the resection of infected chordae [20].

Tricuspid annuloplasty is performed either with prosthetic rings or with non-prosthetic suture annuloplasty such as Kay's or De Vega's annuloplasty [13]. Although suture annuloplasty has an advantage of avoiding prosthetic materials in the setting of infection, several studies

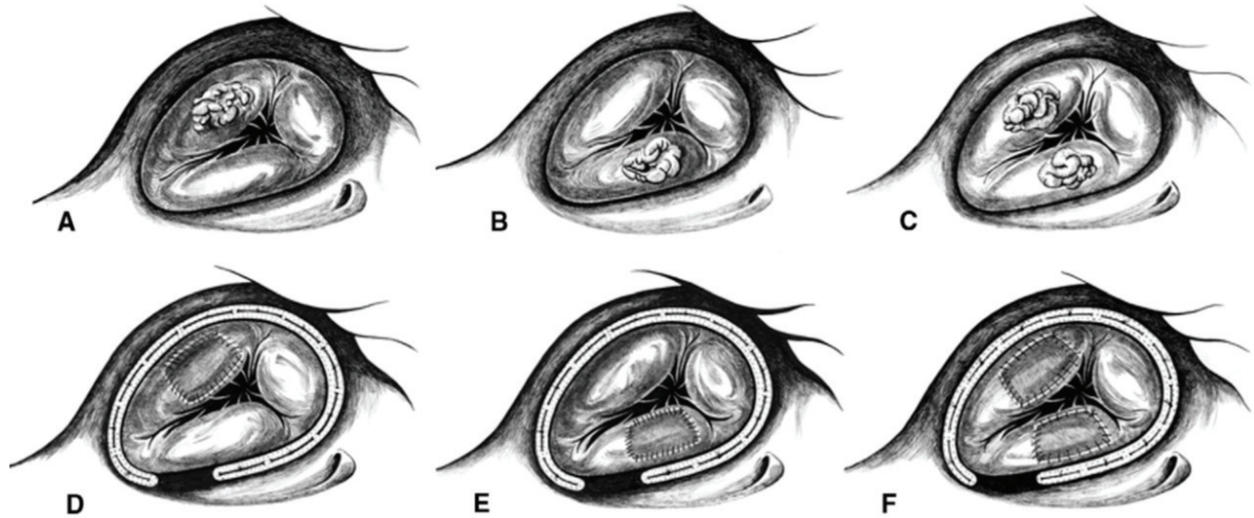


Figure 1. Endocarditic lesion on the anterior leaflet (A), the posterior leaflet (B), or on both (C), anterior and septal leaflet (D–F) after the excision of the endocarditic lesion, patch plasty, and stabilization of the valve with a tricuspid annuloplasty ring.

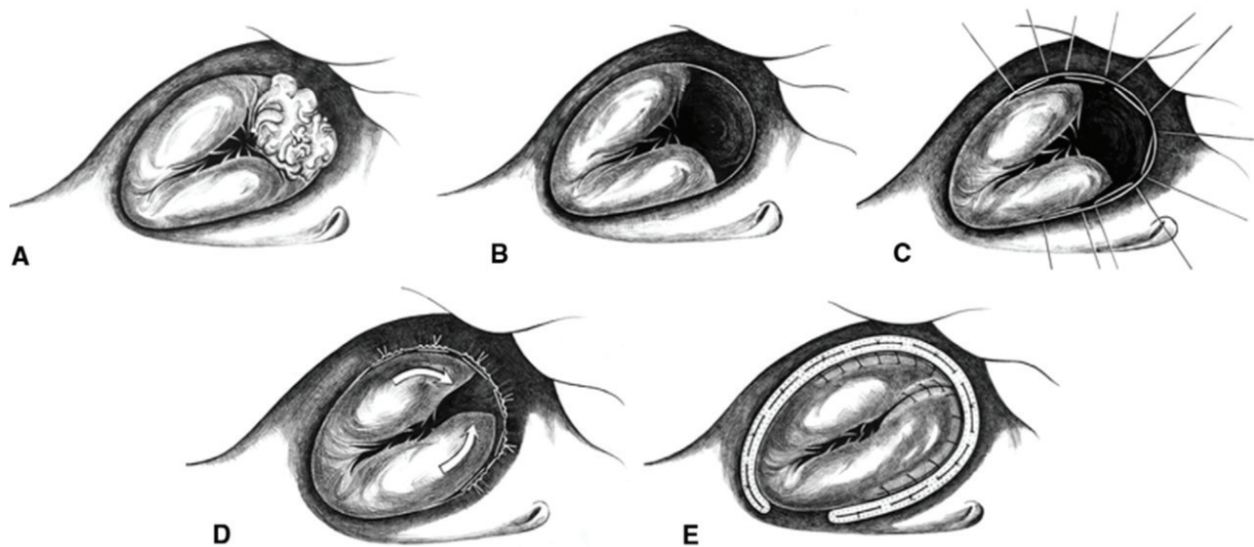


Figure 2. (A) Endocarditic lesion on the posterior leaflet. (B) Excision of the posterior leaflet. (C) Partial mobilization of the anterior and septal leaflet and preparation of plication sutures. (D) Bicuspid leaflet formation of the valve. (E) Stabilization of the valve with a tricuspid annuloplasty ring.

showed that the ring annuloplasty is superior to suture annuloplasty in terms of recurrent tricuspid regurgitation or reoperation [21–24].

2.5. Tricuspid valve replacement

In case of severe valve destruction, valve replacement is performed using either a mechanical valve or tissue valve.

Cho et al. compared surgical outcomes of mechanical tricuspid valve replacement (n = 59) and tissue tricuspid valve replacement (n = 45), and found that there was no difference in long-term valve-related complications such as thromboembolic or bleeding events [25].

Hwang et al. also reported that there was no difference in long-term survival, cardiac death rates, and thromboembolic and bleeding complication rates between mechanical and tissue tricuspid valve replacements [26].

Liu et al. performed a meta-analysis to review the results of mechanical and bioprosthetic valves in the tricuspid valve position [27]. They did not find difference in survival, reoperation, or prosthetic valve failure between two valve types.

2.6. Surgical outcomes for tricuspid valve infective endocarditis

The surgical outcomes for tricuspid valve infective endocarditis are listed in **Table 1**. Overall good surgical outcomes were reported, and the durability of tricuspid valve reconstruction was good.

Study	Year	Number of pts	Surgical technique	Mortality (%)	Recurrence of regurgitation	Recurrence of infection
Musci et al. [28]	2007	51	31 reconstructions, 17 tissue TVR, 3 mechanical TVR	11.3% for reconstruction, 12.5% for TVR	—	2 patients had reoperation due to reinfection after the tricuspid reconstruction.
Gottardi et al. [18]	2007	22	18 reconstructions, 3 tissue TVR, 1 mechanical TVR	0	3 patients had grade 1–2 TR	2 patients had recurrent endocarditis, which were treated conservatively.
Baraki et al. [29]	2013	33	15 reconstructions, 14 tissue TVR, 4 mechanical TVR	9	2 patients had grade > 2 TR	3 patients underwent reoperation for recurrent endocarditis
Gaca et al. [17]	2013	910	354 reconstructions, 66 valvectomies, 490 TVR	7.6% for reconstruction, 12.1% for valvectomy, 6.3% for TVR	—	—

TVR, tricuspid valve replacement; TR, tricuspid regurgitation.

Table 1. Surgical outcomes for tricuspid valve endocarditis.

Musci et al. reported a 20-year single institution surgical experience for right-sided infective endocarditis [28]. They performed 31 tricuspid valve reconstructions and 20 valve replacements. The 30-day, 1-, 5-, 10- and 20-year survival rate after the operation was 96.2, 88.4, 73.5, 70.4 and 70.4%, respectively, for isolated right-sided infective endocarditis. The survival rate was significantly better than the patients with combined right- and left-sided infective endocarditis. Survival was not different between valve reconstruction and replacement.

Gottardi et al. performed 18 tricuspid valve repair and 4 tricuspid valve replacements for active infective endocarditis, and there was no mortality [18]. During the follow-up, three patients presented with grade 1–2 tricuspid valve regurgitation after the valve reconstruction.

Baraki et al. reviewed 33 tricuspid valve surgeries for endocarditis, which included 14 tissue valve replacements, 4 mechanical valve replacements, and 15 tricuspid valve repairs [29]. Thirty-day mortality was 9%, and advanced age, EuroSCORE, and *Staphylococcus aureus* were associated with a less long-term survival rate. Residual tricuspid valve regurgitation grade ≥ 2 was found in two patients.

2.7. Intravenous drug user

Intravenous drug abuse is increasing dramatically in the United States [30]. Of many medical complications caused by drug use, infective endocarditis is one of the most challenging issues given the significant risk of acute mortality as well as late recidivism, reinfection, and poor social situations.

The infection caused by the drug use can be found both on right- and left-sided heart or even on both sides. Even though the prognosis of right-sided infective endocarditis is better than left-sided, surgery may be required in at least 25% of patients [31].

The surgical outcomes for drug-induced endocarditis are summarized in **Table 2**. Overall, the short-term and long-term survival was not different between drug users and non-drug users; however, the rates of late reinfection and reoperation are higher in drug users.

The choice of valve prosthesis for intravenous drug users is controversial [32]. Rabkin et al. reported that the median survival of intravenous drug users was only 3 years, and therefore tissue valves are justified even for young patients [33]. Kaiser et al. used tissue valves more frequently in drug users than non-drug users (75 vs. 52%), even though drug users were younger [34].

In the meantime, several previous studies showed that the postoperative survival rate of drug users is similar to non-drug users [34–37]. That may imply that intravenous drug users receiving tissue valves will live long enough to require a reoperation for valve degeneration. Given the fact that the redo surgery for tricuspid valve carries high risk [38], the use of mechanical valve may be justified for selected patients who can be compliant with anticoagulation. Mechanical tricuspid valves have a risk of thrombosis with an incidence of $\leq 3.3\%$ of patient-years [39].

2.8. Reinfection after surgery

Patients with intravenous drug use are high risk of reinfection. The surgical outcomes for redo tricuspid valve surgery have been reported to be poor.

Study	Year	Number of pts	Hospital	Findings
Shrestha et al. [35]	2015	536; 41 (8%) were drug users	Cleveland clinic	Short-term mortality was not different between drug users and non-drug users; however, a hazard of death or reoperation between 3 and 6 months after the operation was 10 times higher in drug users compared with non-users.
Kim et al. [36]	2016	436; 78 (17.9%) were drug users	Massachusetts General Hospital and Brigham and Women's Hospital	Operative mortality was lower among drug users; however, overall mortality was not different. Drug users had higher risk of valve-related complications principally because of higher rates of reinfection.
Rabkin et al. [33]	2012	197; 64 (32.5%) were drug users	University of Washington Medical Center	Survival was lower in drug users than non-drug users (at 30 days, 1 year, 5 years, and 10 years; 91.2 vs. 93.6%, 77.5 vs. 83.0%, 46.7 vs. 71.1%, and 41.1 vs. 52.0%, respectively, $p = 0.027$). Intravenous drug use was an independent risk factor for diminished survival ($p = 0.03$). 8 of 64 (12.5%) of drug users experienced recurrent infective endocarditis.
Kaiser et al. [34]	2007	346; 62 (17.9%) were drug users	Washington University	Long-term survival and perioperative complications were not different between drug users and non-drug users; however, reoperation for recurrent infection was higher in drug users (17 vs. 5%, $p = 0.03$).
Carozza et al. [37]	2006	39 drug-induced infective endocarditis and 85 non-drug-induced infective endocarditis	Second University of Naples	Although hospital and long-term survival did not significantly differ between two groups, the rate of recurrence of infection was higher in drug users.

Table 2. Surgical outcomes for drug-induced infective endocarditis.

Jeganathan et al. reviewed 68 patients who had previous history of tricuspid valve surgery and underwent reoperations on the tricuspid valve, and in-hospital mortality was 13.2% [38]. They also reported high incidence of postoperative bleeding, low cardiac output syndrome, stroke, and renal failure.

Musci et al. reported that 6 out of 79 patients underwent reoperation due to reinfection after the correction of right-sided active infective endocarditis, and only 1 of them (16.7%) survived the reoperation [28].

The prognosis of prosthetic valve infection without surgical intervention is dismal. Ivert et al. reported that 64% of the patients with prosthetic valve endocarditis died, and most deaths occurred within 3 months of the first evidence of infection [40]. Nevertheless, the surgical treatment for prosthetic valve endocarditis is also challenging [41].

Luciani et al. performed multicentre study for surgical outcomes for prosthetic valve endocarditis [42]. Among 209 patients who underwent surgery for prosthetic valve endocarditis, the in-hospital mortality was high (21.5%). Grubitzsch et al. reviewed 149 patients who underwent redo surgery for prosthetic valve endocarditis [43]. The operative mortality was 12.8%.

In the setting of high risk of surgical treatment for reinfection, a dilemma exists regarding the surgical indication for patients who are non-compliant to medical treatment, and develop reinfection due to relapsing of drug use [44]. There is a controversy as how many chances surgeons should give to non-compliant patients.

Hull et al. proposed that the patients who have a history of intravenous drug use should be encouraged to sign a contract agreeing to undergo drug rehabilitation and make a good faith effort to abstain from substance abuse in the future [45].

3. Conclusions

The incidence of tricuspid valve infective endocarditis is increasing along with the epidemic of intravenous drug use. Surgical treatment would be necessary when the patients suffer from heart failure, large vegetation, and persistent bacteremia despite appropriate antibiotic therapy. Tricuspid valve reconstruction is desirable as artificial material can be avoided; however, in cases of severe valve destruction, tricuspid valve replacement is warranted. Management of patients with intravenous drug users is challenging due to late recidivism, reinfection, and poor social situations. The operation for reinfection carries high risk. There is an ethical controversy regarding the surgical indication for reinfection induced by relapse of drug use. Surgeons can play a role by bringing the problem of epidemic of drug use to public consciousness.

Author details

Takashi Murashita

Address all correspondence to: tmurashita@gmail.com

Heart and Vascular Institute, West Virginia University, Morgantown, WV, USA

References

- [1] Murdoch DR, Corey GR, Hoen B, Miró JM, Fowler VG Jr, Bayer AS, Karchmer AW, Olaison L, Pappas PA, Moreillon P, Chambers ST, Chu VH, Falcó V, Holland DJ, Jones P, Klein JL, Raymond NJ, Read KM, Tripodi MF, Utili R, Wang A, Woods CW, Cabell CH. International collaboration on endocarditis-prospective cohort study (ICE-PCS) investigators. Clinical presentation, etiology, and outcome of infective endocarditis in the 21st century: The international collaboration on endocarditis-prospective cohort study. *Archives of Internal Medicine*. 2009;**169**:463-473. DOI: 10.1001/archinternmed.2008.603
- [2] Chan P, Ogilby JD, Segal B. Tricuspid valve endocarditis. *American Heart Journal*. 1989; **117**:1140-1146

- [3] Seratnaehai A, Leung SW, Charnigo RJ, Cummings MS, Sorrell VL, Smith MD. The changing 'face' of endocarditis in Kentucky: An increase in tricuspid cases. *American Journal of Medicine*. 2014;**127**, 04:786.e1, 009-786.e6. DOI: 10.1016/j.amjmed.2014
- [4] Yong MS, Coffey S, Prendergast BD, Marasco SF, Zimmet AD, McGiffin DC, Saxena P. Surgical management of tricuspid valve endocarditis in the current era: A review. *International Journal of Cardiology*. 2016;**202**:44-48. DOI: 10.1016/j.ijcard.2015.08.211
- [5] Moss R, Munt B. Injection drug use and right sided endocarditis. *Heart*. 2003;**89**:577-581
- [6] Athan E, Chu VH, Tattevin P, Selton-Suty C, Jones P, Naber C, Miró JM, Ninot S, Fernández-Hidalgo N, Durante-Mangoni E, Spelman D, Hoen B, Lejko-Zupanc T, Cecchi E, Thuny F, Hannan MM, Pappas P, Henry M, Fowler VG Jr, Crowley AL, Wang A. ICE-PCS investigators. Clinical characteristics and outcome of infective endocarditis involving implantable cardiac devices. *JAMA*. 2012;**307**:1727-1735. DOI: 10.1001/jama.2012.497
- [7] Baddour LM, Wilson WR, Bayer AS, Fowler VG Jr, Tleyjeh IM, Rybak MJ, Barsic B, Lockhart PB, Gewitz MH, Levison ME, Bolger AF, Steckelberg JM, Baltimore RS, Fink AM, O'Gara P, Taubert KA. American Heart Association Committee on rheumatic fever, endocarditis, and Kawasaki disease of the council on cardiovascular disease in the young, council on clinical cardiology, council on cardiovascular surgery and anesthesia, and stroke council. Infective endocarditis in adults: Diagnosis, antimicrobial therapy, and Management of Complications: A scientific statement for healthcare professionals from the American Heart Association. *Circulation*. 2015;**132**:1435-1486. DOI: 10.1161/CIR.0000000000000296
- [8] Habib G, Lancellotti P, Antunes MJ, Bongiorni MG, Casalta JP, Del Zotti F, Dulgheru R, El Khoury G, Erba PA, Iung B, Miro JM, Mulder BJ, Plonska-Gosciniak E, Price S, Roos-Hesselink J, Snygg-Martin U, Thuny F, Tornos Mas P, Vilacosta I, Zamorano JL. ESC guidelines for the management of infective endocarditis: The task force for the management of infective endocarditis of the European Society of Cardiology (ESC). Endorsed by: European Association for Cardio-Thoracic Surgery (EACTS), the European Association of Nuclear Medicine (EANM). *European Heart Journal*. 2015;**36**:3075-3128. DOI: 10.1093/eurheartj/ehv319
- [9] Hecht SR, Berger M. Right-sided endocarditis in intravenous drug users. Prognostic features in 102 episodes. *Annals of Internal Medicine*. 1992;**117**:560-566
- [10] Kiefer T, Park L, Tribouilloy C, Cortes C, Casillo R, Chu V, Delahaye F, Durante-Mangoni E, Edathodu J, Falces C, Logar M, Miró JM, Naber C, Tripodi MF, Murdoch DR, Moreillon P, Utili R, Wang A. Association between valvular surgery and mortality among patients with infective endocarditis complicated by heart failure. *JAMA*. 2011;**306**:2239-2247. DOI: 10.1001/jama.2011.1701
- [11] Ghoreishi M, Foster N, Pasrija C, Shah A, Watkins AC, Evans CF, Maghami S, Quinn R, Wehman B, Taylor BS, Dawood MY, Griffith BP, Gammie JS. Early operation in patients with mitral valve infective endocarditis and acute stroke is safe. *The Annals of Thoracic Surgery*. 2018;**105**:69-75. DOI: 10.1016/j.athoracsur.2017.06.069

- [12] Kang DH, Kim YJ, Kim SH, Sun BJ, Kim DH, Yun SC, Song JM, Choo SJ, Chung CH, Song JK, Lee JW, Sohn DW. Early surgery versus conventional treatment for infective endocarditis. *The New England Journal of Medicine*. 2012;**366**:2466-2473. DOI: 10.1056/NEJMoa1112843
- [13] Akinosoglou K, Apostolakis E, Koutsogiannis N, Leivaditis V, Gogos CA. Right-sided infective endocarditis: Surgical management. *European Journal of Cardio-Thoracic Surgery*. 2012;**42**:470-479. DOI: 10.1093/ejcts/ezs084
- [14] Lowes JA, Hamer J, Williams G, Houang E, Tabaqchali S, Shaw EJ, Hill IM, Rees GM. 10 years of infective endocarditis at St. Bartholomew's hospital: Analysis of clinical features and treatment in relation to prognosis and mortality. *Lancet*. 1980;**1**:133-136
- [15] Remadi JP, Habib G, Nadji G, Brahim A, Thuny F, Casalta JP, Peltier M, Tribouilloy C. Predictors of death and impact of surgery in *Staphylococcus aureus* infective endocarditis. *The Annals of Thoracic Surgery*. 2007;**83**:1295-1302
- [16] Taghavi S, Clark R, Jayarajan SN, Gaughan J, Brann SH, Mangi AA. Surgical management of tricuspid valve endocarditis in systemically infected patients. *The Journal of Heart Valve Disease*. 2013;**22**:578-583
- [17] Gaca JG, Sheng S, Daneshmand M, Rankin JS, Williams ML, O'Brien SM, Gammie JS. Current outcomes for tricuspid valve infective endocarditis surgery in North America. *The Annals of Thoracic Surgery*. 2013;**96**:1374-1381. DOI: 10.1016/j.athoracsur.2013.05.046
- [18] Gottardi R, Bialy J, Devyatko E, Tschernich H, Czerny M, Wolner E, Seitelberger R. Midterm follow-up of tricuspid valve reconstruction due to active infective endocarditis. *The Annals of Thoracic Surgery*. 2007;**84**:1943-1948
- [19] Ghanta RK, Chen R, Narayanasamy N, McGurk S, Lipsitz S, Chen F, Cohn LH. Suture bicuspidization of the tricuspid valve versus ring annuloplasty for repair of functional tricuspid regurgitation: Midterm results of 237 consecutive patients. *The Journal of Thoracic and Cardiovascular Surgery*. 2007;**133**:117-126
- [20] Morokuma H, Minato N, Kamohara K, Minematsu N. Three surgical cases of isolated tricuspid valve infective endocarditis. *Annals of Thoracic and Cardiovascular Surgery*. 2010;**16**:134-138
- [21] Matsuyama K, Matsumoto M, Sugita T, Nishizawa J, Tokuda Y, Matsuo T, Ueda Y. De Vega annuloplasty and Carpentier-Edwards ring annuloplasty for secondary tricuspid regurgitation. *The Journal of Heart Valve Disease*. 2001;**10**:520-524
- [22] McCarthy PM, Bhudia SK, Rajeswaran J, Hoercher KJ, Lytle BW, Cosgrove DM, Blackstone EH. Tricuspid valve repair: Durability and risk factors for failure. *The Journal of Thoracic and Cardiovascular Surgery*. 2004;**127**:674-685
- [23] Murashita T, Okada Y, Kanemitsu H, Fukunaga N, Konishi Y, Nakamura K, Koyama T. Long-term outcomes of tricuspid annuloplasty for functional tricuspid regurgitation associated with degenerative mitral regurgitation: Suture annuloplasty versus ring annuloplasty using a flexible band. *Annals of Thoracic and Cardiovascular Surgery*. 2014;**20**:1026-1033. DOI: 10.5761/atcs.0a.13-00292

- [24] Hata H, Fujita T, Miura S, Shimahara Y, Kume Y, Matsumoto Y, Yamashita K, Kobayashi J. Long-term outcomes of suture vs. ring tricuspid annuloplasty for functional tricuspid regurgitation. *Circulation Journal*. 2017;**81**:1432-1438. DOI: 10.1253/circj.CJ-17-0108
- [25] Cho WC, Park CB, Kim JB, Jung SH, Chung CH, Choo SJ, Lee JW. Mechanical valve replacement versus bioprosthetic valve replacement in the tricuspid valve position. *Journal of Cardiac Surgery*. 2013;**28**:212-217. DOI: 10.1111/jocs.12093
- [26] Hwang HY, Kim KH, Kim KB, Ahn H. Propensity score matching analysis of mechanical versus bioprosthetic tricuspid valve replacements. *The Annals of Thoracic Surgery*. 2014;**97**:1294-1299. DOI: 10.1016/j.athoracsur.2013.12.033
- [27] Liu P, Qiao WH, Sun FQ, Ruan XL, Al Shirbini M, Hu D, Chen S, Dong NG. Should a mechanical or biological prosthesis be used for a tricuspid valve replacement? A meta-analysis. *Journal of Cardiac Surgery*. 2016;**31**:294-302. DOI: 10.1111/jocs.12730
- [28] Musci M, Siniawski H, Pasic M, Grauhan O, Weng Y, Meyer R, Yankah CA, Hetzer R. Surgical treatment of right-sided active infective endocarditis with or without involvement of the left heart: 20-year single center experience. *European Journal of Cardio-Thoracic Surgery*. 2007;**32**:118-125
- [29] Baraki H, Saito S, Al Ahmad A, Fleischer B, Schmitto J, Haverich A, Kutschka I. Surgical treatment for isolated tricuspid valve endocarditis- long-term follow-up at a single institution. *Circulation Journal*. 2013;**77**:2032-2037
- [30] Ferraris VA, Sekela ME. Missing the forest for the trees: The world around us and surgical treatment of endocarditis. *The Journal of Thoracic and Cardiovascular Surgery*. 2016;**152**: 677-680. DOI: 10.1016/j.jtcvs.2016.05.014
- [31] Gould FK, Denning DW, Elliott TS, Foweraker J, Perry JD, Prendergast BD, Sandoe JA, Spry MJ, Watkin RW. Working Party of the British Society for Antimicrobial Chemotherapy. Guidelines for the diagnosis and antibiotic treatment of endocarditis in adults: A report of the Working Party of the British Society for Antimicrobial Chemotherapy. *The Journal of Antimicrobial Chemotherapy*. 2012;**67**:269-289. DOI: 10.1093/jac/dkr450
- [32] Carozza A, Della Corte A, Ursomando F, Cotrufo M. The choice of valve prosthesis for infective endocarditis in intravenous drug users: Between evidence and preference. *The Annals of Thoracic Surgery*. 2008;**85**:1141. DOI: 10.1016/j.athoracsur.2007.04.090
- [33] Rabkin DG, Mokadam NA, Miller DW, Goetz RR, Verrier ED, Aldea GS. Long-term outcome for the surgical treatment of infective endocarditis with a focus on intravenous drug users. *The Annals of Thoracic Surgery*. 2012;**93**:51-57. DOI: 10.1016/j.athoracsur.2011.08.016
- [34] Kaiser SP, Melby SJ, Zierer A, Schuessler RB, Moon MR, Moazami N, Pasque MK, Huddleston C, Damiano RJ Jr, Lawton JS. Long-term outcomes in valve replacement surgery for infective endocarditis. *The Annals of Thoracic Surgery*. 2007;**83**:30-35
- [35] Shrestha NK, Jue J, Hussain ST, Jerry JM, Pettersson GB, Menon V, Navia JL, Nowacki AS, Gordon SM. Injection drug use and outcomes after surgical intervention for infective endocarditis. *The Annals of Thoracic Surgery*. 2015;**100**:875-882. DOI: 10.1016/j.athoracsur.2015.03.019

- [36] Kim JB, Ejiofor JI, Yammine M, Ando M, Camuso JM, Youngster I, Nelson SB, Kim AY, Melnitchouk SI, Rawn JD, MacGillivray TE, Cohn LH, Byrne JG, Sundt TM 3rd. Surgical outcomes of infective endocarditis among intravenous drug users. *The Journal of Thoracic and Cardiovascular Surgery*. 2016;**152**:832-841. DOI: 10.1016/j.jtcvs.2016.02.072
- [37] Carozza A, De Santo LS, Romano G, Della Corte A, Ursomando F, Scardone M, Caianiello G, Cotrufo M. Infective endocarditis in intravenous drug abusers: Patterns of presentation and long-term outcomes of surgical treatment. *The Journal of Heart Valve Disease*. 2006;**15**:125-131
- [38] Jeganathan R, Armstrong S, Al-Alao B, David T. The risk and outcomes of reoperative tricuspid valve surgery. *The Annals of Thoracic Surgery*. 2013;**95**:119-124. DOI: 10.1016/j.athoracsur.2012.08.058
- [39] Kunadian B, Vijayalakshmi K, Balasubramanian S, Dunning J. Should the tricuspid valve be replaced with a mechanical or biological valve? *Interactive Cardiovascular and Thoracic Surgery*. 2007;**6**:551-557
- [40] Ivert TS, Dismukes WE, Cobbs CG, Blackstone EH, Kirklin JW, Bergdahl LA. Prosthetic valve endocarditis. *Circulation*. 1984;**69**:223-232
- [41] Mahesh B, Angelini G, Caputo M, Jin XY, Bryan A. Prosthetic valve endocarditis. *The Annals of Thoracic Surgery*. 2005;**80**:1151-1158
- [42] Luciani N, Mossuto E, Ricci D, Luciani M, Russo M, Salsano A, Pozzoli A, Pierri MD, D'Onofrio A, Chiariello GA, Glieca F, Canziani A, Rinaldi M, Nardi P, Milazzo V, Trearichi EM, Santini F, De Bonis M, Torracca L, Bizzotto E, Tumbarello M. Prosthetic valve endocarditis: Predictors of early outcome of surgical therapy. A multicentric study. *European Journal of Cardio-Thoracic Surgery*. 2017;**52**:768-774. DOI: 10.1093/ejcts/ezx169
- [43] Grubitzsch H, Schaefer A, Melzer C, Wernecke KD, Gabbieri D, Konertz W. Outcome after surgery for prosthetic valve endocarditis and the impact of preoperative treatment. *The Journal of Thoracic and Cardiovascular Surgery*. 2014;**148**:2052-2059. DOI: 10.1016/j.jtcvs.2014.05.025
- [44] DiMaio JM, Salerno TA, Bernstein R, Araujo K, Ricci M, Sade RM. Ethical obligation of surgeons to noncompliant patients: Can a surgeon refuse to operate on an intravenous drug-abusing patient with recurrent aortic valve prosthesis infection? *The Annals of Thoracic Surgery*. 2009;**88**:1-8. DOI: 10.1016/j.athoracsur.2009.03.088
- [45] Hull SC, Jadbabaie F. When is enough enough? The dilemma of valve replacement in a recidivist intravenous drug user. *The Annals of Thoracic Surgery*. 2014;**97**:1486-1487. DOI: 10.1016/j.athoracsur.2014.02.010