

We are IntechOpen, the world's leading publisher of Open Access books Built by scientists, for scientists

4,800

Open access books available

122,000

International authors and editors

135M

Downloads

Our authors are among the

154

Countries delivered to

TOP 1%

most cited scientists

12.2%

Contributors from top 500 universities



WEB OF SCIENCE™

Selection of our books indexed in the Book Citation Index
in Web of Science™ Core Collection (BKCI)

Interested in publishing with us?
Contact book.department@intechopen.com

Numbers displayed above are based on latest data collected.

For more information visit www.intechopen.com



Cochlear Implants: An Excursus into the Technologies and Clinical Applications

Mohammad Hossein Khosravi, Ali Kouhi,
Sasan Dabiri, Pedram Borghei and
Masoumeh Saeedi

Additional information is available at the end of the chapter

<http://dx.doi.org/10.5772/intechopen.74266>

Abstract

Hearing loss causes severe alterations in social function and daily communications. Cochlear device implantation (CDI) is the only beneficiary method for auditory rehabilitation in patients with severe to profound sensorineural hearing loss (SNHL). Regarding a report in 2014, over 300,000 people had received cochlear implants throughout the world since December 2012 among which about 60,000 were adults and 40,000 were children in the United States. In this chapter, we discuss the history, origin, mechanism of action, and type of cochlear implants, as well as method of surgery and complications.

Keywords: cochlear implantation, hearing loss, complications, clinical applications, surgical technique, epidemiology

1. History and introduction

Most of the patients with significant social dysfunction due to hearing loss can be treated by nonsurgical interventions. Many ways such as selective seating closer or with the better ear near important sound sources or using hearing aids can be utilized for these situations [1].

Cochlear device implantation (CDI) is the only beneficiary method for auditory rehabilitation in patients with severe to profound sensorineural hearing loss (SNHL). Regarding a report in 2014, over 300,000 people had received cochlear implants throughout the world since December 2012, among which about 60,000 were adults and 40,000 were children in the United States [2].

A 60-year-old history protects cochlear implantation technology, which has experienced multiple changes in devices and speech processing strategies. It was about 200 years ago when Alessandro Volta described the early auditory percepts induced by applying a large voltage between his own ears in 1790 [3–6]. Further investigations by Weaver and Bray were focused and resulted in this concept that it might be possible to generate electrical signals mimicking auditory input stimulus [7].

In 1957, an electrode with receiver coil was successfully implanted for a patient with resected cochlear nerve due to cholesteatoma, which was able to stimulate the apparatus for months, and shockingly, the patient had sound awareness and simple word recognition [8–10]. Following Djourno and Eyries, House started his work in the early 1960s who implanted simple wires, wires with ball electrodes, and even simple arrays into the scala tympani, which finally led into production of implantable device in 1972; this was a beginning point for clinical trials [3, 11].

At the beginning, there was a resistance from scientific community especially neurophysiologists and otologists against CI; however, the national institute of health (NIH) approved the use of electrical stimulation of auditory nerves as a rehabilitation method in 1977, while evaluating the outcome in patients with single channel implants [3, 4, 12, 13].

Multichannel CIs were produced in greater numbers due to the food and drug administration (FDA) approval because of their ability of open-set word recognition and better frequency spectrum percepts [3, 6, 14]. Another remarkable progress was occurred in 1991, while continuous interleaved sampling (CIS) strategy was introduced, which developed improved open-set word recognition in comparison with previous analogue methods, so that all currently available strategies are based on CIS [15].

2. Structure and mechanism of action

Sensory hair cells within the cochlea have the responsibility for transforming sound vibration to neural signal in healthy individuals; then, the signal continues its way to auditory cortex through cochlear nerve. Cochlear implants take the place of these cells using electrodes which stimulate the nerve fiber electrically. **Figure 1** illustrates a cochlear implant device. Common cochlear implants have two parts: external component as a hearing aid and internal component which is surgically inserted in mastoid [16].

The external part is consisted of three parts: a microphone for gathering sounds, a speech processor analyzing and encoding sound into a digital code, and a magnetic headpiece which transmits coded signals by a transcutaneous radiofrequency link to the internal part.

The internal part has a receiver stimulator which receives and decodes the data and conducts decoded signal to the electrode array. In the next step, there is a flexible silicone carrier, which has variable number of electrodes. The remaining cochlear nerve fibers are stimulated by the electrode array, which is surgically implanted in scala tympani of the cochlea.

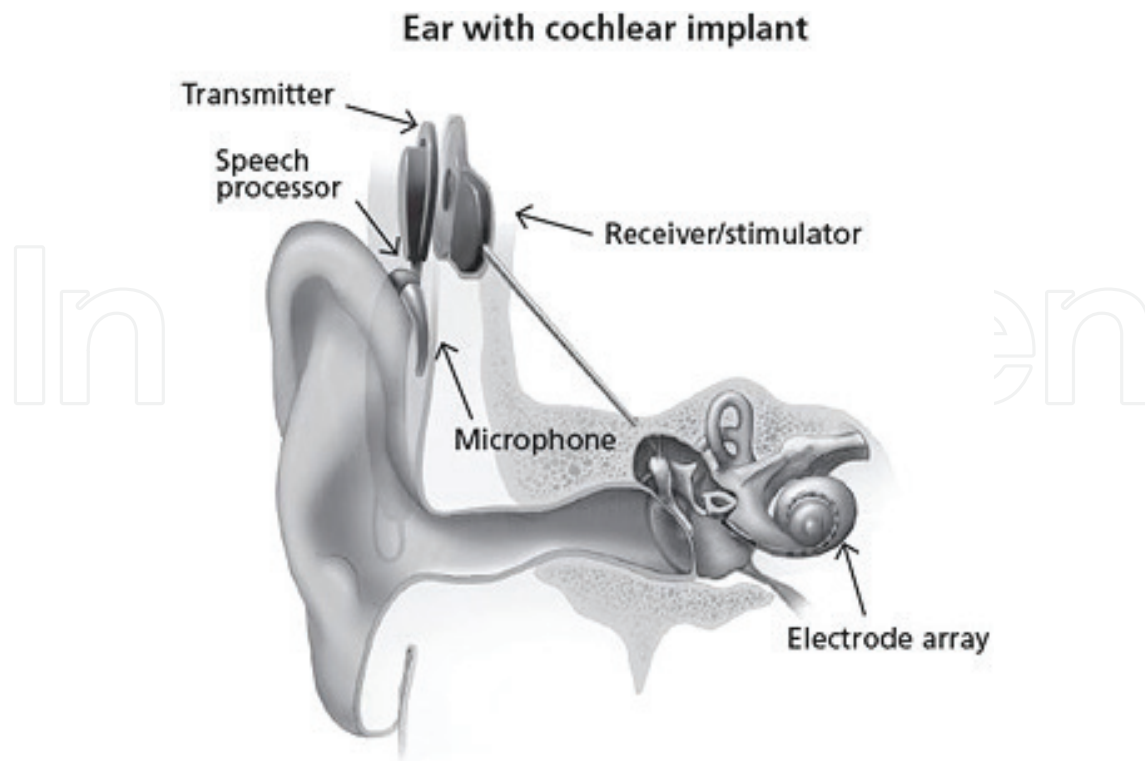


Figure 1. Different parts of cochlear implant (source: NIH/NIDCD <https://www.nidcd.nih.gov/health/cochlear-implants>).

3. Types of cochlear implants

3.1. Totally implantable cochlear implants

Currently available implants have an external part and need patients to wear it consisted of an external microphone, processor, and transmitting coil for empowering the electrode, which needs a dry and stable environment. Thus, development of totally implantable cochlear implants that make the whole system available underneath the skin is a new area of research. There are several challenges and requirements in the way of this progress including a tiny and sensitive microphone with ability to filter the endogenous noises, as well as a rechargeable battery with appropriate long life. There is a report of three patients with totally implantable cochlear implants [17].

3.2. Unilateral or bilateral cochlear implantation

Unilateral cochlear implantation was the only option offered at the beginning. Later, it was questioned if the patients would take more benefits from bilateral cochlear implants. Surprisingly, it was revealed that patients with bilateral cochlear implantation show better speech perception and improvement in "hearing in noise." Also, these patients showed a significantly better sound localization in comparison with their single-side implantation condition [18, 19].

Previous studies have concluded that there is no significant difference for audiologic outcomes between unilateral and bilateral cochlear implantation regarding surgical timing, as both ears can be implanted simultaneously or sequentially. Adult studies have shown that the second ear matches the first ear performance at 6 months [20]. The story has a difference when it comes to children, as it has been concluded that patients with simultaneous bilateral cochlear implantation have improved speech recognition and language when compared to children who were implanted sequentially [21].

The cost-effectiveness of bilateral cochlear implantation has remained controversial despite evident advantages of binaural stimulation. A Canadian study has reported that cochlear implantation is cost-effective in adults compared to no implantation; however, sequential bilateral cochlear implantation has a slight superiority in comparison with unilateral implantation [22]. Other studies have approved cost effectiveness of bilateral simultaneous pediatric implantation and unilateral adult cochlear implantation, although they have not approved cost-effectiveness of bilateral sequential pediatric implantation and bilateral (sequential or simultaneous) adult implantation [23].

4. Candidacy and patient selection

Selecting the right patient is the building block of a successful cochlear implantation. Therefore, a complete medical and audiologic workup is needed for evaluating candidacy of cochlear implantation and to make sure that the patient can tolerate anesthesia and surgical process. Patients are considered to take benefit from CI when they suffer from bilateral moderate to profound sensorineural hearing loss and when hearing aids cannot help them [24]. A combination of objective and subjective hearing tests is conducted to accurately identify the degree of hearing loss within audiometric frequencies. Currently available guidelines mention that children up to 2 years of age should have a bilateral profound sensorineural hearing loss, which is indicated by a pure tone audiometry (PTA) more than 90 dBHL for 500, 1000, and 2000 Hz frequencies, while patients older than 2 years of age should have bilateral severe to profound SNHL indicated by PTA more than 75 dBHL for 500, 1000, and 2000 Hz frequencies [25, 26]. Preoperative speech and language evaluation has the same importance for decision making regarding rehabilitation strategies and programs, as well as appropriateness of auditory performance, speech production, and mode of communication. Hearing loss is categorized to prelingual, postlingual, and perilingual types based on the time of onset. In prelingually deaf patients, hearing impairment occurs before gaining speaking skills, which is usually before 2 years of age, while it occurs after gaining complete speaking skills in postlingual patients which is usually after age of 5 years. In perilingual patients, hearing impairment occurs when some speaking skills are gained but are not completed usually between 2 and 5 years of age [16].

In addition, preoperative imaging and auditory testing are needed. Imaging modalities such as computed tomography (CT) scan, for assessing temporal bone, and magnetic resonance imaging (MRI), for evaluating brain anatomy and ruling out abnormalities of cochlear nerve, are conducted [15]. After scheduling patient for surgery, pneumococcal vaccines are administered according to FDA guidelines.

Current contraindications for cochlear implantation are two absolute and relative categories. Absence of cochlear development, deafness due to lesions of the central auditory pathway, and massive cochlear ossification that prevents electrode insertion are among absolute contraindications. Relative contraindications include aplasia of the acoustic nerve and medical conditions or developmental delays that would severely limit participation in aural rehabilitation.

5. Surgery

Cochlear implantation procedure is performed under general anesthesia associated with facial nerve monitoring. Surgeon needs to expose the mastoid, so a postauricular incision is made and soft tissue is dissected; latter, the surgeon makes a subperiosteal pocket for placement of implant magnet. A cortical mastoidectomy is performed associated with finding landmarks of temporal bone, such as incus, tegmen tympani, lateral semicircular canal, and sigmoid sinus. Then, the surgeon opens the facial recess, which is surrounded by chorda tympani, facial nerve, and incus buttress as its boundaries to identify the round window niche through the recess.

There are different methods for accessing scala tympani after finding the round window; in cochleostomy, the surgeon drills a separate hole and the anterior limit of the round window in extended cochleostomy. The implant is inserted into the cochlea, once the cochlea is opened. For making sure of the proper function of implant, an integrity test is performed by an audiologist at the end of the procedure. X-ray radiography is used to ensure proper location of cochlear implant by some surgeons. At the end, the patient is discharged the same day, and cochlear implant is usually activated 2–4 weeks postoperatively.

6. Complications

Cochlear implantation is generally a safe performed surgical procedure throughout the world with globally estimated complication rate of 16% [18]. Requiring additional surgery or cochlear explantation is categorized as major, and complications needing conservative medical management are classified as minor complications. Now, complication rates are decreasing due to improved experience, using smaller incisions and improvements in designing devices, and are generally calculated to be 11.8% for minor and 3.2% for major complications [27].

Infection is one of the most important major complications of cochlear implantation. Skin infection and acute otitis media are the most common type of implant-related infections ranging from 1 to 12% in the literature. Otitis media and soft tissue infection increase the risk of cochlear implant removal if leading to receiver stimulator infection. Also, it has been reported that cochlear implantation increases the risk of bacterial meningitis as 30-fold greater than general population; however, dawn of vaccination has made these cases sporadic [28]. Facial nerve palsy is another major complication of cochlear implantation, which is estimated to occur in 0.7% of cases due to heat induced by drill, cochleostomy, or reactivation of herpes virus as a result of surgery stress [29]. Finally, device failure is another major complication of cochlear

implantation occurring in 2.5–6% of cases [18, 27]. Vestibular symptoms, such as vertigo and disequilibrium, are present in about one-third of patients postoperatively and are believed to last for more than 1 week after surgery. Most of these symptoms are resolved in weeks; however, patients over 70 years of age are more likely to have permanent vestibular weakness [30].

7. Hearing after cochlear implantation

Acoustic hearing remains preserved in more than half of the patients after cochlear implantation; however, previously, it was believed that insertion of electrode into the cochlea destroys the natural mechanism of hearing [31]. Preserving physiologic pathway of hearing has several advantages such as ability to localize the sound, recognize the speech, and hear in complex listening environments [32]. A variety of factors and approaches have been considered for improving hearing preservation after cochlear implantation. Previous studies have reported that full electrode insertion makes the hearing preservation possible; however, electrode insertion depth and length are determining factors for intracochlear trauma [24, 33].

Studies believe that the most hearing preservation achieves when the electrode is entirely located in scala tympani [34]. The most appropriate surgical approach has remained controversial; some previous studies have mentioned that there is no significant difference between round window and cochleostomy approaches regarding hearing outcomes [35, 36], while others reported that each method is superior for maximizing atraumatic scala tympani insertion. Eventually, preoperative prescription of steroids and steroid-eluting implants have been reported to improve hearing preservation up to 1 year from implantation [32].

In another retrospective analysis of cochlear implanted patients, researchers investigated the impact of related factors on hearing preservation. They reported an overall preservation likelihood of 39% for patients operated by refined soft surgery technique with a higher conservation rate at low frequencies when compared to high frequencies [37]. Age at the time of implantation, etiology of deafness, side of implant, electrode array model, and insertion technique, as well as type of cochleostomy, are investigated factors, which are considered to possibly affect hearing preservation; however, there are a variety of opinions on their effects, and further studies are required for conclusive results [36, 38–52].

8. Other applications of cochlear implant

8.1. Cochlear implantation for single-sided sensorineural hearing loss

Recently, a new topic has come up about cochlear implantation in setting of single-sided sensorineural hearing loss [53]. So far, options such as hearing aids, bone-anchored implants, and contralateral routing of signal (CROS) devices were applied for single-side deaf patients. While these options improve hearing by healthy ear, cochlear implantation restores hearing by deaf ear. Sound localization is a special challenge for patients with unilateral hearing loss.

A proper localization involves a good bilateral hearing and sound stimulation, as well as intraaural time differences, which allow complex processing of sounds. Recent studies have mentioned some advantages for cochlear implantation in unilateral hearing loss, and some has reported a better sound localization in comparison with bone-anchored implants [54]. Additionally, it has been shown that cochlear implants resolve tinnitus up to an acceptable extent in patients with single-sided deafness and may improve speech perception [34, 55].

8.2. Hybrid cochlear implants

A hybrid cochlear implant was developed by Gantz et al. with the aim of preserving residual hearing, which has only 10 mm of height [56]. This provides the possibility for stimulating the region responsible for high-frequency hearing in cochlea without stimulating regions responsible for low frequency hearing. Primary studies have revealed that hybrid implant application is associated with better hearing preservation and increased speech perception [35, 36, 57, 58]. In addition to the comparable performance of hybrid implants with conventional ones, patients with hybrid implants had improved music appreciation as a result of acoustic and electrical stimulation combination [56, 57]. Replacement of hybrid implant with full-length implant in a progressive hearing loss improves hearing and word recognition; however, it is associated with a notable additional cost [59, 60].

8.3. Cochlear implantation and Meniere's disease

Cochlear implantation has been utilized for Meniere's disease, a condition consisted of episodic attacks of tinnitus, hearing loss, and debilitating vertigo spells. Previous studies have shown resolution of related symptoms after cochlear implantation in Meniere's disease patients, although the hearing outcomes are not as acceptable as patients implanted for other reasons [61, 62].

9. Prospective of cochlear implantation

So far, some in vitro and animal studies have been conducted to resolve the hearing impairment problem using regenerative medicine; nevertheless, cochlear implantation remains as the most effective current treatment method. Further efforts are being put to cochlear implantation technology field in order to improve understanding speech in noise and music appreciations.

Abbreviations

| | |
|------|---------------------------------|
| CI | cochlear implant |
| CROS | contralateral routing of signal |
| dBHL | decibels hearing level |

| | |
|------|-----------------------------|
| Hz | Hertz; unit of frequency |
| PTA | pure tone audiometry |
| SNHL | sensory-neural hearing loss |

Author details

Mohammad Hossein Khosravi^{1,2}, Ali Kouhi^{2,3}, Sasan Dabiri⁴, Pedram Borghei⁵ and Masoumeh Saeedi^{2,6*}

*Address all correspondence to: m.saeedi67@gmail.com

1 Student Research Committee (SRC), Baqiyatallah University of Medical Sciences, Tehran, Iran

2 International Otorhinolaryngology Research Association (IORA), Universal Scientific Education and Research Network (USERN), Tehran, Iran

3 Department of Otolaryngology – Head and Neck Surgery, Otorhinolaryngology Research Center, Tehran University of Medical Sciences, Tehran, Iran

4 Department of Otorhinolaryngology – Head and Neck Surgery, Amir Alam Hospital, Tehran University of Medical Sciences, Tehran, Iran

5 Otolaryngology Head and Neck Surgery, Tehran University of Medical Sciences, Tehran, Iran

6 Department of Otorhinolaryngology – Head and Neck Surgery, Faculty of Medicine, Baqiyatallah University of Medical Sciences, Tehran, Iran

References

- [1] Roche JP, Hansen MR. On the horizon: Cochlear implant technology. *Otolaryngologic Clinics of North America*. 2015;**48**(6):1097
- [2] <https://www.nidcd.nih.gov/health/cochlear-implants>
- [3] Carlson ML, Driscoll CL, Gifford RH, McMenemy SO. Cochlear implantation: Current and future device options. *Otolaryngologic Clinics of North America*. 2012;**45**(1):221-248
- [4] Ramsden RT. History of cochlear implantation. *Cochlear Implants International*. 2013; **14**(suppl. 4):3-5
- [5] Volta A. XVII. On the electricity excited by the mere contact of conducting substances of different kinds. In a letter from Mr. Alexander Volta, FRS Professor of Natural Philosophy in the University of Pavia, to the Rt. Hon. Sir Joseph Banks, Bart. *KBPRS. Philosophical Transactions of the Royal Society of London*. 1800 Jan 1;**90**:403-431

- [6] Eshraghi AA, Nazarian R, Telischi FF, Rajguru SM, Truy E, Gupta C. The cochlear implant: Historical aspects and future prospects. *The Anatomical Record*. 2012;**295**(11):1967-1980
- [7] Wever EG, Bray CW. The nature of the acoustic response: The relation between stimulus intensity and the magnitude of cochlear responses in the cat. *Journal of Experimental Psychology*. 1938;**22**(1):1
- [8] Djourno A, Eyries C, Vallancien B. Electric excitation of the cochlear nerve in man by induction at a distance with the aid of micro-coil included in the fixture. *Comptes Rendus des Seances de la Societe de Biologie et de ses filiales*. 1957;**151**(3):423
- [9] Arts HA, Jones DA, Anderson DJ. Prosthetic stimulation of the auditory system with intraneural electrodes. *Annals of Otolaryngology, Rhinology & Laryngology*. 2003;**112**(9_suppl):20-25
- [10] Eisen MD. Djourno, eyries, and the first implanted electrical neural stimulator to restore hearing. *Otolaryngology & Neurotology*. 2003;**24**(3):500-506
- [11] Eshraghi AA, Gupta C, Ozdamar O, Balkany TJ, Truy E, Nazarian R. Biomedical engineering principles of modern cochlear implants and recent surgical innovations. *The Anatomical Record*. 2012;**295**(11):1957-1966
- [12] Kiang NY, Moxon EC. Physiological considerations in artificial stimulation of the inner ear. *Annals of Otolaryngology, Rhinology & Laryngology*. 1972;**81**(5):714-730
- [13] Bilger R, Black F. Auditory prostheses in perspective. *Annals of Otolaryngology, Rhinology & Laryngology*. 1977;**86**(3_suppl):3-10
- [14] Clark GM, Tong YC, Martin LF. A multiple-channel cochlear implant: An evaluation using open-set cid sentences. *The Laryngoscope*. 1981;**91**(4):628-634
- [15] Wilson BS, Finley CC, Lawson DT, Wolford RD, Eddington DK, Rabinowitz WM. Better speech recognition with cochlear implants. *Nature*. 1991;**352**(6332):236-238
- [16] Vincenti V, Bacciu A, Guida M, Marra F, Bertoldi B, Bacciu S, et al. Pediatric cochlear implantation: An update. *Italian Journal of Pediatrics*. 2014;**40**(1):72
- [17] Briggs RJ, Eder HC, Seligman PM, Cowan RS, Plant KL, Dalton J, et al. Initial clinical experience with a totally implantable cochlear implant research device. *Otolaryngology & Neurotology*. 2008;**29**(2):114-119
- [18] Venail F, Sicard M, Piron JP, Levi A, Artieres F, Uziel A, et al. Reliability and complications of 500 consecutive cochlear implantations. *Archives of Otolaryngology-Head & Neck Surgery*. 2008;**134**(12):1276-1281
- [19] Dunn CC, Tyler RS, Witt S, Ji H, Gantz BJ. Sequential bilateral cochlear implantation: Speech perception and localization pre-and post-second cochlear implantation. *American Journal of Audiology*. 2012;**21**(2):181-189
- [20] Reeder RM, Firszt JB, Holden LK, Strube MJ. A longitudinal study in adults with sequential bilateral cochlear implants: Time course for individual ear and bilateral performance. *Journal of Speech, Language, and Hearing Research*. 2014;**57**(3):1108-1126

- [21] Lammers MJ, Venekamp RP, Grolman W, Heijden GJ. Bilateral cochlear implantation in children and the impact of the inter-implant interval. *The Laryngoscope*. 2014; **124**(4):993-999
- [22] Chen JM, Amoodi H, Mittmann N. Cost-utility analysis of bilateral cochlear implantation in adults: A health economic assessment from the perspective of a publicly funded program. *The Laryngoscope*. 2014; **124**(6):1452-1458
- [23] McKinnon BJ. Cost effectiveness of cochlear implants. *Current Opinion in Otolaryngology & Head and Neck Surgery*. 2014; **22**(5):344-348
- [24] Yawn R, Hunter JB, Sweeney AD, Bennett ML. Cochlear implantation: A biomechanical prosthesis for hearing loss. *F1000prime Reports*. 2015; **7**
- [25] Heman-Ackah SE, Roland JT, Haynes DS, Waltzman SB. Pediatric cochlear implantation: Candidacy evaluation, medical and surgical considerations, and expanding criteria. *Otolaryngologic Clinics of North America*. 2012; **45**(1):41-67
- [26] Forli F, Arslan E, Bellelli S, Burdo S, Mancini P, Martini A, et al. Systematic review of the literature on the clinical effectiveness of the cochlear implant procedure in paediatric patients. *Acta Otorhinolaryngologica Italica*. 2011; **31**(5):281
- [27] Farinetti A, Gharbia DB, Mancini J, Roman S, Nicollas R, Triglia J-M. Cochlear implant complications in 403 patients: Comparative study of adults and children and review of the literature. *European Annals of Otorhinolaryngology, Head and Neck Diseases*. 2014; **131**(3):177-182
- [28] Reefhuis J, Honein MA, Whitney CG, Chamany S, Mann EA, Biernath KR, et al. Risk of bacterial meningitis in children with cochlear implants. *New England Journal of Medicine*. 2003; **349**(5):435-445
- [29] Fayad JN, Wanna GB, Micheletto JN, Parisier SC. Facial nerve paralysis following cochlear implant surgery. *The Laryngoscope*. 2003; **113**(8):1344-1346
- [30] Enticott JC, Tari S, Koh SM, Dowell RC, O'leary SJ. Cochlear implant and vestibular function. *Otology & Neurotology*. 2006; **27**(6):824-830
- [31] Carlson ML, Driscoll CL, Gifford RH, Service GJ, Tombers NM, Hughes-Borst BJ, et al. Implications of minimizing trauma during conventional cochlear implantation. *Otology & Neurotology: Official Publication of the American Otological Society, American Neurotology Society [and] European Academy of Otology and Neurotology*. 2011; **32**(6):962
- [32] Gifford RH, Dorman MF, Skarzynski H, Lorens A, Polak M, Driscoll CL, et al. Cochlear implantation with hearing preservation yields significant benefit for speech recognition in complex listening environments. *Ear and Hearing*. 2013; **34**(4):413
- [33] Bruce IA, Bates JEHM, Melling C, Mawman D, Green KMJ. Hearing preservation via a cochleostomy approach and deep insertion of a standard length cochlear implant electrode. *Otology & Neurotology*. 2011; **32**(9):1444-1447

- [34] Vlastarakos PV, Nazos K, Tavoulari E-F, Nikolopoulos TP. Cochlear implantation for single-sided deafness: The outcomes. An evidence-based approach. *European Archives of Oto-rhino-laryngology*. 2014;**271**(8):2119-2126
- [35] Adunka OF, Dillon MT, Adunka MC, King ER, Pillsbury HC, Buchman CA. Cochleostomy versus round window insertions: Influence on functional outcomes in electric-acoustic stimulation of the auditory system. *Otology & Neurotology*. 2014;**35**(4):613-618
- [36] Havenith S, Lammers MJ, Tange RA, Trabalzini F, della Volpe A, van der Heijden GJ, et al. Hearing preservation surgery: Cochleostomy or round window approach? A systematic review. *Otology & Neurotology*. 2013;**34**(4):667-674
- [37] Zanetti D, Nassif N, de Zinis LR. Factors affecting residual hearing preservation in cochlear implantation. *Acta Otorhinolaryngologica Italica*. 2015;**35**(6):433
- [38] Skarzynski H, Lorens A, Piotrowska A, Anderson I. Partial deafness cochlear implantation in children. *International Journal of Pediatric Otorhinolaryngology*. 2007;**71**(9):1407-1413
- [39] Causon A, Verschuur C, Newman TA. A retrospective analysis of the contribution of reported factors in cochlear implantation on hearing preservation outcomes. *Otology & Neurotology*. 2015;**36**(7):1137-1145
- [40] Adunka OF, Buss E, Clark MS, Pillsbury HC, Buchman CA. Effect of preoperative residual hearing on speech perception after cochlear implantation. *The Laryngoscope*. 2008;**118**(11):2044-2049
- [41] Skarzynski H, Lorens A, Piotrowska A, Anderson I. Preservation of low frequency hearing in partial deafness cochlear implantation (PDCI) using the round window surgical approach. *Acta Oto-laryngologica*. 2007;**127**(1):41-48
- [42] Giordano P, Hatzopoulos S, Giarbini N, Prosser S, Petruccelli J, Simoni E, et al. A soft-surgery approach to minimize hearing damage caused by the insertion of a cochlear implant electrode: A guinea pig animal model. *Otology & Neurotology*. 2014;**35**(8):1440-1445
- [43] Berrettini S, Forli F, Passetti S. Preservation of residual hearing following cochlear implantation: Comparison between three surgical techniques. *The Journal of Laryngology & Otology*. 2008;**122**(3):246-252
- [44] Briggs RJ, Tykocinski M, Xu J, Risi F, Svehla M, Cowan R, et al. Comparison of round window and cochleostomy approaches with a prototype hearing preservation electrode. *Audiology and Neurotology*. 2006;**11**(Suppl. 1):42-48
- [45] Sun CH, Hsu CJ, Chen PR, Wu HP. Residual hearing preservation after cochlear implantation via round window or cochleostomy approach. *The Laryngoscope*. 2015;**125**(7):1715-1719
- [46] Lenarz T, James C, Cuda D, Fitzgerald O'Connor A, Frachet B, Frijns JH, et al. European multi-centre study of the nucleus hybrid L24 cochlear implant. *International Journal of Audiology*. 2013;**52**(12):838-848

- [47] Gstoettner WK, Van de Heyning P, Fitzgerald O'Connor A, Morera C, Sainz M, Vermeire K, et al. Electric acoustic stimulation of the auditory system: Results of a multi-centre investigation. *Acta Oto-laryngologica*. 2008;**128**(9):968-975
- [48] Souter MA, Briggs RJ, Wright CG, Roland PS. Round window insertion of precurved perimodiolar electrode arrays: How successful is it? *Otology & Neurotology*. 2011; **32**(1):58-63
- [49] Di Nardo W, Cantore I, Cianfrone F, Melillo P, Rigante M, Paludetti G. Residual hearing thresholds in cochlear implantation and reimplantation. *Audiology and Neurotology*. 2007;**12**(3):165-169
- [50] Rebscher SJ, Hetherington A, Bonham B, Wardrop P, Whinney D, Leake PA. Considerations for the design of future cochlear implant electrode arrays: Electrode array stiffness, size and depth of insertion. *Journal of Rehabilitation Research and Development*. 2008;**45**(5):731
- [51] Di Nardo W, Cantore I, Melillo P, Cianfrone F, Scorpecci A, Paludetti G. Residual hearing in cochlear implant patients. *European Archives of Oto-rhino-laryngology*. 2007; **264**(8):855-860
- [52] Jurawitz M-C, Büchner A, Harpel T, Schüssler M, Majdani O, Lesinski-Schiedat A, et al. Hearing preservation outcomes with different cochlear implant electrodes: Nucleus® hybrid™-L24 and nucleus freedom™ CI422. *Audiology and Neurotology*. 2014;**19**(5):293-309
- [53] Kamal SM, Robinson AD, Diaz RC. Cochlear implantation in single-sided deafness for enhancement of sound localization and speech perception. *Current Opinion in Otolaryngology & Head and Neck Surgery*. 2012;**20**(5):393-397
- [54] Nawaz S, McNeill C, Greenberg SL. Improving sound localization after cochlear implantation and auditory training for the management of single-sided deafness. *Otology & Neurotology*. 2014;**35**(2):271-276
- [55] Kim D-K, Bae S-C, Park K-H, Jun B-C, Lee D-H, Yeo SW, et al. Tinnitus in patients with profound hearing loss and the effect of cochlear implantation. *European Archives of Oto-Rhino-Laryngology*. 2013;**270**(6):1803-1808
- [56] Gantz BJ, Dunn CC, Walker EA, Kenworthy M, Van Voorst T, Tomblin B, et al. Bilateral cochlear implants in infants: a new approach—Nucleus Hybrid S12 project. *Otology & Neurotology: Official Publication of the American Otological Society, American Neurotology Society [and] European Academy of Otology and Neurotology*. 2010;**31**(8):1300
- [57] Douchement D, Terranti A, Lamblin J, Salleron J, Siepmann F, Siepmann J, et al. Dexamethasone eluting electrodes for cochlear implantation: Effect on residual hearing. *Cochlear Implants International*. 2015;**16**(4):195-200
- [58] Wanna GB, Noble JH, Carlson ML, Gifford RH, Dietrich MS, Haynes DS, et al. Impact of electrode design and surgical approach on scalar location and cochlear implant outcomes. *The Laryngoscope*. 2014;**124**:S1-S7

- [59] Fitzgerald MB, Sagi E, Jackson M, Shapiro WH, Roland JT Jr, Waltzman SB, et al. Reimplantation of hybrid cochlear implant users with a full-length electrode after loss of residual hearing. *Otology & Neurotology*. 2008;**29**(2):168-173
- [60] Carlson ML, Archibald DJ, Gifford RH, Driscoll CL, Beatty CW. Reimplantation with a conventional length electrode following residual hearing loss in four hybrid implant recipients. *Cochlear Implants International*. 2012;**13**(3):148-155
- [61] Hansen MR, Gantz BJ, Dunn C. Outcomes following cochlear implantation for patients with single-sided deafness, including those with recalcitrant Ménière's disease. *Otology & Neurotology: Official Publication of the American Otological Society, American Neurotology Society [and] European Academy of Otology and Neurotology*. 2013;**34**(9):1681-1687
- [62] McRackan TR, Gifford RH, Kahue CN, Dwyer R, Labadie RF, Wanna GB, et al. Cochlear implantation in Ménière's disease patients. *Otology & Neurotology*. 2014;**35**(3):421-425

IntechOpen

