

We are IntechOpen, the world's leading publisher of Open Access books Built by scientists, for scientists

4,800

Open access books available

122,000

International authors and editors

135M

Downloads

Our authors are among the

154

Countries delivered to

TOP 1%

most cited scientists

12.2%

Contributors from top 500 universities



WEB OF SCIENCE™

Selection of our books indexed in the Book Citation Index
in Web of Science™ Core Collection (BKCI)

Interested in publishing with us?
Contact book.department@intechopen.com

Numbers displayed above are based on latest data collected.
For more information visit www.intechopen.com



Characterization of Hearing Loss in Children with Mucopolysaccharidosis

Diego Zanetti, Margherita Vezzani,
Federica Di Bernardino, Serena Gasperini and
Rossella Parini

Additional information is available at the end of the chapter

<http://dx.doi.org/10.5772/intechopen.74196>

Abstract

Hearing impairment is common in patients with mucopolysaccharidoses (MPS) in the preschool age. Conductive or mixed hearing loss is the most frequent occurrence while the involvement of the inner ear or central auditory pathways may occur in more severe forms. A retrospective review of 82 children with MPS admitted at the Pediatric Department of the University of Milano Bicocca was performed to determine the incidence of otological symptoms. We focused particularly on audiological investigations in a subgroup of 47 children diagnosed before 6 years of age (MPS I, n = 11 patients; MPS II, n = 10; MPS III, n = 7; MPS IV, n = 14; MPS VI, n = 5). In 37 children, a magnetic resonance imaging (MRI) of the brain and cervical spine was also performed in order to correlate the audiological findings with the imaging of the middle and inner ear. A total of 40 out of 47 children (86%) showed some degree of hearing impairment: sensorineural or mixed hearing loss in 23 cases (48.93%) and retrocochlear in 4 (8.51%). MRI ascertained multiple CNS abnormalities in 13 (35.3%): dilated perivascular spaces in 5 (38.5%); dilated ventricular cavities in 5 (38.5%); demyelinated and gliotic areas in 3 (23.0%). Conversely, one-fourth of the children's inner ears showed some morphological anomaly (24.3%).

Keywords: mucopolysaccharidoses, hearing loss, auditory brainstem responses (ABR), transient-evoked otoacoustic emissions (TEOAE), MRI

1. Introduction

Mucopolysaccharidoses (MPSs) are a group of rare inherited metabolic disorders resulting from deficiencies of enzymes involved in the breakdown of glycosaminoglycans (GAGs).

MPS disorders have an overall incidence reported of 1.53 per 100,000 live births ranging from 1 in 150,000 to as high as 1 in 10,000 live births [1]. The highest birth prevalence was 0.84 for MPS II, accounting for 55% of all MPS. MPS I, III, and IV accounted for 15, 16, and 10%, respectively. MPS VI and VII were more rare and accounted for 1.7 and 1.3%, respectively.

The majority are characterized by an autosomal recessive pattern (except for X-linked MPS II type). The deficiency of one of the enzymes participating in the GAGs degradation pathway causes progressive storage in the lysosomes, leading to cellular, tissues and organs dysfunction. The damage is both direct or by activation of secondary and tertiary pathways among which a role is played by inflammation.

Nowadays 11 different enzyme deficiencies are known to be involved in MPSs producing seven distinct clinical phenotypes. In contrast to a recent past when there was only palliative treatment for these diseases, now many specific treatments like hematopoietic stem cell transplantation (HSCT) in selected cases (severe MPS I) and enzyme replacement therapy (ERT) for MPS I, II, IV and VI are available.

MPSs can manifest as severe or attenuated clinical picture. The “severe” forms frequently appear in the first 2–3 years of life with skeletal abnormalities often accompanied by dysmorphic facies, organomegaly, multiple hernias (inguinal, umbilical), abnormally frequent and severe upper airways infections, otitis media and chronic rhinitis. In the “attenuated” forms of the disease instead, the progression of signs and symptoms is much slower [2, 3].

These patients may show the prevalent involvement of a single organ and are often seen by one or two specialists for years before reaching the diagnosis [2, 3].

The most frequent signs of presentation are cardiac valve disease, eye disease, hearing loss, carpal tunnel syndrome and functional limitation of major joints [4–6].

In both forms, the disease invariably progresses with time. MRI of the brain and cervical spine is recommended at the time of diagnosis and at regular intervals thereafter [7].

Surgery to stabilize the spine by posterior fusion can be life-saving. Both central and peripheral nervous systems are affected in the MPSs. Prominent perivascular spaces, hydrocephalus, brain atrophy, gliosis and white matter changes are common [8, 9].

The communicating hydrocephalus that occurs in MPSs is usually slowly progressive, with mild or absent clinical symptoms. Corneal clouding in MPS I, IV, VI and VII may lead to significant visual disability. Glaucoma and cataracts have been reported in MPS I and MPS VI and in MPS III and IV respectively [10].

In the ENT field, these patients often present obstructive sleep apnea/hypopnea (OSAHS), noisy breathing, upper respiratory tract infections, chronic rhinitis, frequent middle ear infections and mixed (conductive + sensorineural) hearing loss. The conductive component is explained by Eustachian tube obstruction or insufficiency by macroglossia, pharyngeal and soft palate mucosal swelling, hyperplasia of adenoids and tonsils. Occasionally, congenital deformities

of the middle ear ossicles are observed. Treatments with continuous positive airways pressure (CPAP) during the night sleep, adenotonsillectomy, grommets insertion and hearing aids may be needed [11]. The sporadic finding of sensorineural hearing loss is related to the central and peripheral nervous systems involvement; in some instances it is retrocochlear in nature [12], and it slowly worsens over time [13]. In this study, we reviewed the clinical data of a consecutive series of patients with MPSs, focusing on the early involvement of the auditory pathways.

2. Materials and methods

A retrospective chart review was undertaken to document the otological clinical features and the hearing status of a group of 82 children affected by MPS who were consecutively admitted at the Department of Pediatrics of the San Gerardo Hospital, University of Milano-Bicocca, Monza, Italy, for diagnostic purposes. The young patients were included in the study at the end of the diagnostic process, when the disease had been already characterized by its enzymatic and genetic substrate. Thus, the diagnosis was definite in all cases. We then selected to restrict the investigation to a subgroup of 47 younger children, aged less than 6 years, in order to define audiological profiles with an early prognostic value and early treatment.

We classified the 47 children according to the known MPS types (**Table 1**).

All children underwent an ENT examination during their in-hospital admission, including fiberoptic endoscopy of the upper airways and otomicroscopy. The audiological workup included:

1. Either behavioral audiometry (children <4 years of age) or pure-tone audiometry (children >4 years of age): they were conducted in a soundproof booth, with procedures adequate for the child's age: (a) infants: conditioned oriented responses—COR; (b) toddlers: play audiometry; (c) older children: air (AC) and bone conducted (BC) six frequencies pure tone threshold determination with conventional procedures
2. Middle ear impedance testing: tympanograms and contralateral stapedial reflexes
3. Auditory brainstem responses (ABR): responses elicited by 0.1 ms alternated polarity clicks at intensities decreasing by 10 dB-steps starting from 120 dB p.e.SPL, via ER3A inserts; the electrodes setup was A1/A2-Cz-Fpz; the electrodes impedance <5 kOhm; threshold estimation was obtained by visually checking the wave V latencies and by a test/retest procedure of the lowest amplitude recognizable of the Vth peak. In younger children the procedure was performed during spontaneous sleep; in selected instances, it was obtained during the sedation required for the MR imaging.

Criteria for labeling a response as “abnormal” were the following:

- Absence of any of the III main wave peaks
- Increased latency of any peak, compared with the normative data for the corresponding age groups at the Audiology Service

- Increased interpeak latency (IPI) compared with the normative data
- Interaural latency difference greater than 0.20 ms

A test/retest procedure was applied at 120 dB SPL stimulation and at the wave V threshold tracing.

A control group of 20 normally hearing children aged 1 year (*normative 1*), 20 children aged 18–24 months (*normative 2*) and 20 aged 3–6 years (*normative 3*) provided the ABR waves latencies normative data.

Therefore, we selected to restrict the investigation to a subgroup of younger children, aged less than 6 years. A full set of audiological data was then gathered for these 47 younger children; among them, 37 (80.43%) underwent also an MRI of the brain and ear. It was therefore possible to cross-check the outcomes of the hearing test and neuroradiological imaging in this subgroup of 37 children. They were 21 males and 16 females with a median age at admission of 3.2 years, ranging between 12 months and 6 years. **Figure 1** shows the flowchart of the study protocol.

In the majority of cases the MRIs of the brain and ear were performed under slight sedation (infants, toddlers and uncooperative children). The MRIs were obtained by a basic protocol

Disease	Number of observed cases	Defective enzyme	GAG storage material	Estimated incidence
MPS-I (Hurler, Hurler/Scheie Scheie)	11	α -L-Iduronidase	Dermatan sulfate, heparan sulfate	1:84,000
MPS-II (Hunter)	10	Iduronate-2-sulfatase	Dermatan sulfate, heparan sulfate	1:196,000
MPS-IIIa (Sanfilippo A)	7	Heparan N-sulfatase	Heparan sulfate	1:92,000
MPS-IIIb (Sanfilippo B)		N-Acetyl- α -glucosaminidase	Heparan sulfate	1:157,000
MPS-IIIc (Sanfilippo C)		Acetyl-CoA: α -glucosamide N-acetyltransferase	Heparan sulfate	1:714,000
MPS-IIId (Sanfilippo D)	0	N-Acetylglucosamine-6-sulfatase	Heparan sulfate	1:1,000,000
MPS-IVA (Morquio A)	14	Galactose-6-sulfatase	Keratan sulfate, chondroitin-6-sulfate	1:131,000
MPS-IVB (Morquio B)		Beta-galactoidase	Keratan sulfate	1:130,000
MPS-VI (Maroteaux-Lamy)	5	Arylsulfatase B	Dermatan sulfate	1:120,000

Table 1. Clinical types of mucopolysaccharidosis (MPSs) with their underlying enzyme deficiency, accumulated substrate, and relative incidence.

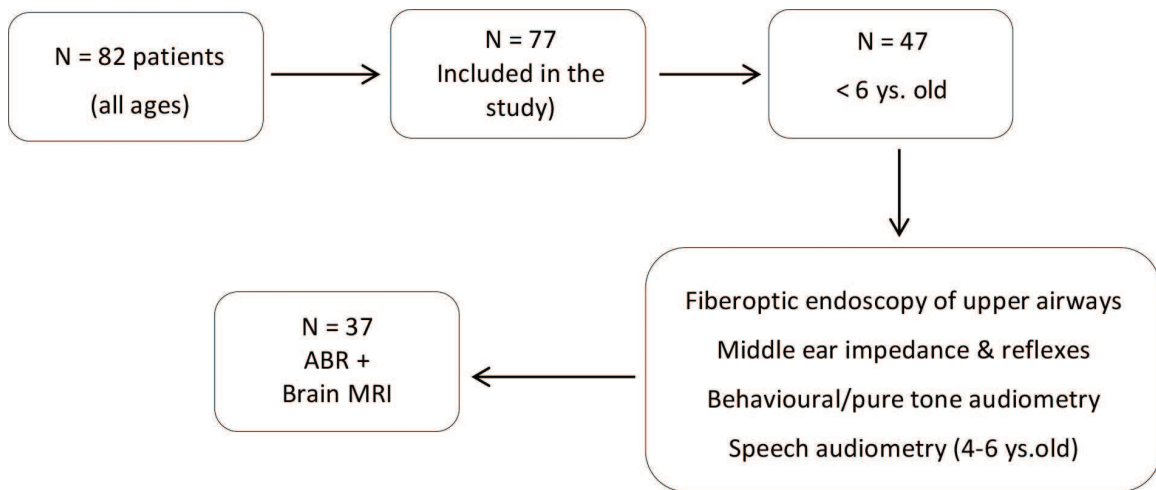


Figure 1. Flowchart showing the young patients’ distribution according to the tests performed in the current study.

including axial, coronal and sagittal 3D–Steady-State Free Precession sequence (SSFP), T1-weighted Fast Spin-Echo (FSE) sequence, and T2-weighted 3D Fluid Attenuated Inversion Recovery (FLAIR) sequence. MRI scans were extended from top of the skull to C7. No intra-venous injection of contrast medium was applied as a standard procedure. An expert senior Neuroradiologist categorized the findings according to the three most prevalent patterns: (a) dilated perivascular spaces; (b) dilated ventricular cavities; (c) demyelinated and gliotic areas.

After establishing an audiological diagnosis in terms of presence and type of hearing loss (conductive, mixed, sensorineural → cochlear or retrocochlear), degree of loss, laterality, and checking the eardrum morphology at otomicroscopy, these data were contrasted with the MRI findings.

Children were divided in two groups according to the type of hearing loss: “C” = purely conductive; “S” = sensorineural or mixed that is reported in **Figure 2**.

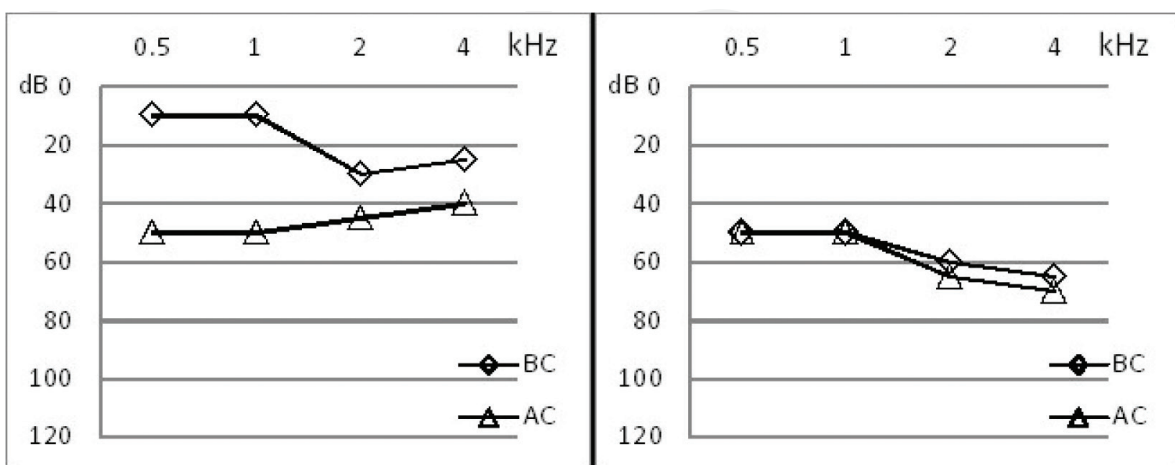


Figure 2. Mean hearing thresholds levels in the “mixed” (left panel) and in the “sensorineural” hearing loss group (right panel). n = 47.

3. Results

3.1. Audiological workup

Some degree of hearing impairment was present in 61 children (74.4%) of the whole cohort of 82 young patients (up to 14 years of age). A total of 21 children (25.6%) were normally hearing. Approximately the same rate of hearing impairment was found in 36 children of the cohort 47 under 6 years of age (76.6%) rather than at older ages; it was sensorineural or mixed in almost half of the ears (47.44%) and purely conductive in about one-third (27.02%). Hearing loss was always symmetrical in the two ears (within 10 dB differences between ears at same frequencies).

Five children presented with normal hearing at admission (mean PTA <20 dB HL bilaterally). The average AC threshold in the "C" group was 44 dB HL with an air-bone gap (ABG) of 21 dB HL; the "S" group showed an AC threshold PTA = 62.5 dB HL with an ABG of 2.3 dB HL. In 7 children (18.9%), the tympanograms were normal (type "A") at the time of the initial assessment and contralateral stapedial reflexes showed a normal threshold and morphology; in the other 30 (81.0%) they were pathological in both ears (Type "B" n = 14; type "C" n = 16).

Transient evoked otoacoustic emissions (TEOAE) were absent bilaterally in all children with a hearing threshold worse than 25 dB HL; normal otoacoustic emission responses were obtained in 9 out of 10 normally hearing ears.

Normative latencies for the three main ABR peaks in normally hearing children of different ages are reported in **Table 2**, and compared to those obtained in the MPS cohort stratified in the same three age groups. Statistical analysis was performed by means of Wilcoxon signed rank test; $p < 0.005$ was considered statistically significant.

In MPS children, ABRs to click stimuli were morphologically normal with peak latencies within normal limits ($\text{avg} \pm 1 \text{ SD}$) in 25 out of 47 subjects (53.2%), whereas 22 tracings showed abnormalities (46.8%). A typical waveform with the 3 main peaks was recognizable or only wave I was missing in 18 of these 22 cases at a stimulus intensity of 90 dB HL, but the amplitudes were reduced and all the latencies delayed ("cochlear" site of lesion); in 7 children no

Wave latencies	MPS 12 mo	Norm 1	p	MPS 18-24 mo	Norm 2	p	MPS 2-6 ys	Norm 3	p
Wave I	1.89 ± 0.21	1.62 ± 0.31	0.046	2.01 ± 0.18	1.88 ± 0.26	n.s.	2.18 ± 0.29	1.99 ± 0.48	n.s.
Wave III	4.30 ± 0.12	4.00 ± 0.34	n.s.	4.51 ± 0.25	4.12 ± 0.11	0.0001	4.45 ± 0.22	4.17 ± 0.3	0.0001
Wave V	6.39 ± 0.18	5.92 ± 0.25	0.0001	7.02 ± 0.2	5.96 ± 0.28	0.0001	7.39 ± 0.26	5.98 ± 0.11	0.0001
IPI I-III	2.40 ± 0.22	2.37 ± 0.21	n.s.	2.50 ± 0.31	2.24 ± 0.25	n.s.	2.27 ± 0.22	2.18 ± 0.21	n.s.
IPI I-V	4.33 ± 0.1	4.31 ± 0.16	n.s.	5.01 ± 0.18	4.98 ± 0.16	n.s.	5.21 ± 0.1	4.0 ± 0.26	0.0001

Latency values expressed in ms. Wilcoxon signed rank test, statistical significance at $p < 0.005$.

Table 2. ABR's absolute wave latencies (ms) and inter-peak intervals (IPI, ms) in the MPS cohort stratified by age and compared to those obtained in the normally hearing age-matched children (control groups Norm 1-2-3).

identifiable response was obtained: in 3 of them, the hearing threshold was severe enough to explain the absence of the response; in 4 cases a retrocochlear involvement was suspected. Overall, a retrocochlear involvement was likely in 8.5% of MPS children.

The relationship between the MPS types and the ABR findings is shown in **Table 3**: all children with MPS III demonstrated an altered ABR; the greatest majority of MPS II also proved pathological, as well as half of the MPS I. None of the patients affected by MPS IVA and VI revealed abnormal ABR tracings.

According to ABR response, the hearing loss was of the “cochlear” type in 83.3, 77.8 and 85.7% of MPS I, MPS II and MPS III, respectively. One case of absent wave I plus absent or delayed wave III and V were observed in MPS I and III, similarly to two cases of MPS II. In no instance an isolated delay of wave V was observed, thus excluding purely “central” site of lesions.

In most MPS children with hearing loss, the hearing threshold derived from the ABRs wave V thresholds ranged between 70 and 90 dB SPL (40–60 dB HL) with an average of 85.62 dB SPL.

3.2. Neuroimaging

Among the 37 MRI, 14 (37.84%) were normal, whereas 23 (62.16%) were pathologic. The most frequent abnormal neuroradiological findings were represented by dilated perivascular spaces (due to extracellular storage of GAGs) in = 12 (32.43%); dilated ventricular cavities n = 15 (40.54%); demyelinated and gliotic areas n = 9 (24.32%). The frequent observation of a J-shaped sella was considered a non-pathological anatomical variant.

We reviewed all MRI with a particular attention on the middle and inner ear findings, although imaging was a standard brain study, not addressing the ear morphology per se. We ascertained five cases of globose internal auditory canal (IAC), and one case of cystic cochlear

MPS type	Normal latencies (all peaks recognizable)	Abnormal ABR	Absent wave I or delayed wave I-III-V (cochlear hearing loss (IPI within normal range)	Absent wave I and absent or delayed wave III and V	Delayed wave V only
MPS-I (n = 11)	5 (46.5%)	6 (54.5%)	5	1	0
MPS-II (n = 10)	1 (10%)	9 (90%)	7	2	0
MPS III (n = 7)	0	7 (100%)	6	1	0
MPS IV (n = 14)	14	0	0	0	0
MPS VI (n = 5)	5	0	0	0	0
Total	25/47 (53.2%)	22/47 (46.8%)	18 (81.8%)	4 (8.5%)	0

Table 3. Distribution of abnormal ABR findings according to MPS type (n = 47).

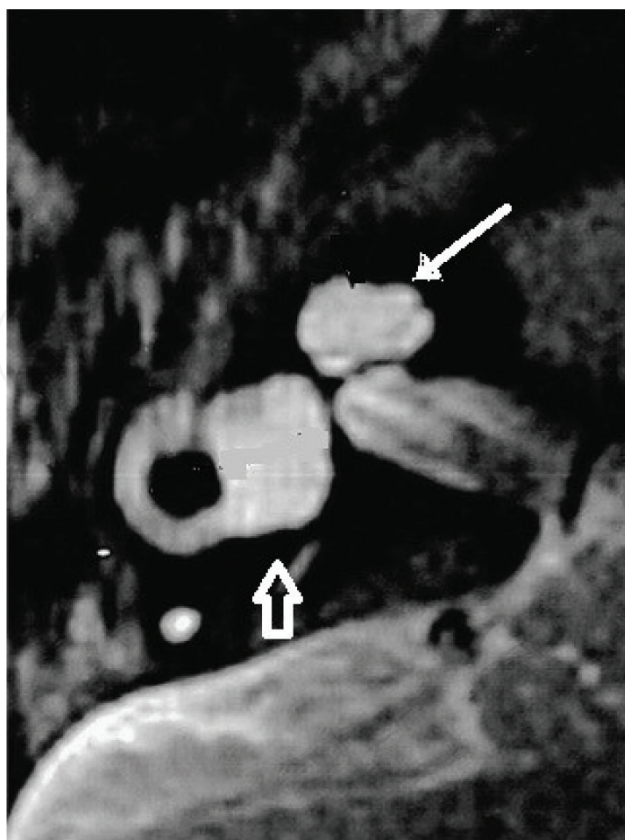


Figure 3. Detail of axial T2-weighted MRI scan of the right ear of patient #14, showing cystic cochlear apex (thin arrow) and enlarged vestibule (empty arrow).

apex and dilated vestibule, which is shown in **Figure 3**. All detected anomalies were bilateral except for the dilated vestibule (right ear, pt. # 14). The middle ear pathological findings consisted in 15 cases of sero-mucinous effusion in the mastoid cells and in the tympanic cavity, 9 bilateral and 4 unilateral (always the right side). In no instance an enlarged vestibular aqueduct was detected. Similarly, no pathological conditions were identified along the central auditory pathways in any young MPS patients.

We further stratified the 37 MR+ patients in 3 subgroups related to age: 5 (13.51%) patients were under 1 years old, only 2 children (5.4%) were between 1 and 2 years old and 30 children

Age	# of patients (%)	Rate of pathological ABRs	Rate of pathological brain MRIs
<1 year	5	2 (40%)	3 (60%)
1–2 years	2	2 (100%)	1 (100%)
2–6 years	30	23 (77.7%)	22 (72.2%)
Total	37	27 (72.9%)	26 (70.2%)

Table 4. Incidence of pathological ABRs and MRIs at different ages in the subgroup of 37 MPS patients who underwent both investigations.

(81.08%) were between 2 and 6 years old. By contrasting the rate of pathological ABR and the MRI findings according to the age layers we obtained the outcomes illustrated in **Table 4**. Noticeably, the majority of children underwent an ABR after 2 years of age, when, theoretically, the physiological maturation of the central auditory pathways should be completed.

4. Discussion

The MPSs are a group of monogenic disorders due to lysosomal storage of glycosaminoglycans (GAGs), previously called mucopolysaccharides [14]. The deficiency of one of the enzymes participating in the GAGs degradation pathway causes progressive storage in the lysosomes and cytoplasm, leading to cell swelling and multiple organs dysfunction. The damage is both direct or by activation of secondary and tertiary pathways among which a role is played by inflammation. [15] All MPSs have an autosomal recessive transmission with the exception of MPS type II (Hunter syndrome) which is X-linked [16].

The incidence of MPSs as a group is reported between 1:25,000 and 1:45,000 [17]. At present, 11 different enzyme deficiencies are involved in MPSs producing 7 distinct clinical phenotypes [14] (**Table 1**). Depending on the enzyme deficiency, the catabolism of dermatan sulfate, heparin sulfate, keratin sulfate, chondroitin sulfate, or hyaluronan may be impaired, singularly or in combination.

MPSs virtually affect all organs and tissues and show a progressive worsening with time. Diagnosis is suspected clinically on the basis of rather constant physical appearance (signs can be subtle or overt) such as: coarse facial features; short stature; “claw hand” and/or joint stiffness or ligamentous laxity (seen in MPS VI); corneal clouding (from very mild to severe), retinopathy, glaucoma; chronic nasal congestion, noisy breathing; abdominal protuberance owing to liver and spleen enlargement; spinal deformity (gibbus, scoliosis, kyphosis, lordosis); abnormal gait (e.g., toe walking); hearing deficits and brain involvement with progressive cognitive delay. In MPS III and II, mental retardation at 2–3 years may be the only, or most evident, presenting sign. Heart failure and severe valve disease in the first year of life are reported as the first presenting symptom in the *severe* forms [18–20]. In these patients, quality of life and life span are generally substantially reduced [21, 22].

The *attenuated* forms have widely variable clinical presentations with different presenting signs at different ages, often one or few organs only clinically manifest the disease [2, 3]. In these milder forms the progression of signs and symptoms is much slower than in the severe ones. These patients may have a presentation apparently limited to one organ only and are often seen by a specialist for years before reaching the diagnosis [2, 3], that is usually accomplished by means of biochemical, enzymatic and molecular tests.

Currently, specific treatments such as hematopoietic stem cell transplantation in selected cases of severe MPS I and enzyme replacement therapy for MPS I, II, IV and VI are available [23]. These treatments are able to improve the clinical course of the disease if started early. This brings along the responsibility for the clinician to recognize these diseases at the first signs to allow access to treatment before a severe damage has been established.

Although similar, each type of MPSs has a peculiar phenotypic expression [14]; besides, within the same type of MPSs, the phenotypic spectrum is largely variable, as a result of the different severity of mutations and overall genetic background of the single individual.

The otorhinolaryngological involvement is represented by otitis media with effusion, progressive mixed hearing loss, OSAHS, pathology of the Waldeyer lymphatic ring and difficulties during intubation [24].

In the *severe* forms, which most frequently present in the first 2–3 years of life with skeletal abnormalities, dysmorphic facies, organomegaly and multiple hernias, children suffer abnormally frequent and severe upper airways infections, chronic rhinitis and otitis media. Hearing loss is a frequent feature of the more severe forms of MPS; therefore, it should be identified as early as possible in order to help assessing a correct diagnosis and provide an etiological treatment [33].

It occurs frequently in the early childhood, mainly as a consequence of recurrent episodes of otitis media. It is often discovered occasionally, during an otorhinolaryngological referral requested for the control of the upper airways. OME is the most frequent finding: if the clinical history is silent, it may be overlooked; its incidence in children affected by MPS is higher than in the general population [24].

A middle ear effusion can easily mask an underlying sensorineural hearing loss. The inner ear involvement has been generally neglected in the literature; the major pathologic alterations have been found in the Corti organ, tectorial and Reissner's membranes, ciliated cells and auditory nerve [13]. In the *attenuated* forms of MPS, hearing loss occurs more frequently at a later stage, but it sometimes develops already in first infancy. If correctly recognized, it can be effectively rehabilitated with hearing aids, reducing the already existing disability related with the multi-organ dysfunction.

In our series, 32% of the young patients were affected by mixed hearing loss, 28% by purely conductive, 16% by sensorineural type and 24% were normally hearing. This distribution is coherent with other reports [25, 26]. The degree of hearing loss in purely sensorineural involvement ranged between 40 and 60 dB (average 55.62 dB HL).

In our MPS children, auditory brainstem responses to click stimuli were morphologically normal with peak latencies within normal limits ($\text{avg} \pm 1 \text{ SD}$) in 25 out of 47 subjects (53.2%), whereas 22 tracings showed abnormalities (46.8%). At a stimulus intensity of 90 dB HL, the 3 main peaks of the typical ABR waveform were recognizable, or only wave I was missing, in 18 of these 22 cases. Reduced amplitudes and delayed latencies with regular interpeak latencies indicated a "cochlear" site of lesion; in 7 children no identifiable response was obtained: in 3 of them the hearing threshold was severe enough to explain the absence of the response; in 4 cases a retrocochlear involvement was suspected. Overall, a retrocochlear involvement was likely in 8.5% of MPS children.

The relationship between the MPS types and the ABR findings is shown in **Table 3**: all children with MPS III demonstrated an altered ABR; the greatest majority of MPS II also proved pathological, as well as half of the MPS I. None of the patients affected by MPS IVA and VI revealed abnormal ABR tracings. On a speculative basis, this might reflect a more severe compromise of the auditory periphery in MPS I-II and III.

Based on the ABR response, the hearing loss was of the “cochlear” type in 83.3, 77.8 and 85.7% of MPS I, MPS II and MPS III, respectively; purely “central” lesions were excluded.

The retrocochlear patterns of auditory evoked potentials observed in four of our patients with sensorineural hearing loss highlighted a conduction delay within the central auditory system, possibly related to progressive storage of GAGs.

Up to date, the reason for the sensorineural component of the hearing loss has not been fully ascertained: some alterations, such as the presence of lysosomal deposit in the outer and /or inner hair cells suggest a dysfunction of the cochlear sensorial structures; conversely, the findings of PAS+ material occupying the cytoplasm of the spiral and vestibular ganglion cells might indicate an altered neural transmission [27, 28]. Furthermore, animal studies also showed an alteration in the mechanical properties of the Reissner’s and Basilar membranes [12].

The most characteristic modification in the CNS is the dilatation of the perivascular spaces, caused by extracellular storage of GAGs; it appears as a variable amount of tiny spot-like cystic lesions with CSF-like signal in all sequences. It is probably determined by large GAG inclusions between vascular adventitial cells, typically at basal ganglia, subcortical parietal and occipital white matter, and in the corpus callosum, with radial orientation along the vascular developmental lines [29]. Widening of liquor spaces and hydrocephalus, secondary to pathologic leptomeningeal thickening with resorption deficit by the Pacchioni’s granulations and/or obstruction of the CSF flow, can lead to severe neurologic compromise (requiring a shunt) or to neuronal loss and decrease of association fibers and atrophy [30]. The expression of white matter dystrophy in mucopolysaccharidoses, probably on a microvascular basis, is common also to several other diseases that share the same vulnerable areas, such as the peritrigonal white matter. Compared to dilated perivascular spaces, these lesions show brighter (hyperintense) signals both in T₂-weighted and FLAIR images.

In our series of 37 MPS children who underwent MRI, 14 (37.84%) were normal, whereas 23 (62.16%) showed some abnormalities such as dilated perivascular spaces in 12 (32.43%), dilated ventricular cavities in 15 (40.54%), demyelinated and gliotic areas in 9 (24.32%). A globose internal auditory canal was observed in five cases of IAC, and a cystic cochlear apex and dilated vestibule in 1 child. The middle ear pathological findings consisted in 15 cases of sero-mucinous effusion in the mastoid cells and in the tympanic cavity. The limited number of children tested under 2 years of age does not allow to draw general conclusions. Instead, within the group of 30 children aged 2–6 years, the rate of pathological ABRs (77.7%) and of pathological MRI of the brain (72.2%) showed a high degree of correlation. Assuming that the physiological maturation of the central auditory pathways is being completed during this age range, the ABR abnormalities would possibly be attributed no longer to a delayed myelination. Therefore, the “retrocochlear” ABR findings might be a real expression of “central” auditory dysfunction, although the MRI abnormalities did not seem to involve directly the auditory pathways.

The interpretation of these neuroimaging findings is somehow challenging, because a clear relationship with cognitive insufficiency in MPS patients is lacking [30, 31], although mental retardation has been reported in the more severe forms of MPS 1 [32–37].

Similarly, the relationship with hearing loss is not clear. Nevertheless, a prompt recognition of the hearing difficulties, which can be among the first manifestations of the disease, might help assessing an earlier diagnosis and, therefore, provide a timely treatment.

5. Conclusions

Inner ear and retrocochlear involvement in MPS patients is more frequent than initially suspected. Observation of seromucinous effusion in the middle ear does not exclude the presence of a sensorineural hearing loss. An otological and audiological investigation should be warranted to all defined or suspected MPS patients. Inner ear or central auditory lesions detected by the audiological tests should be further investigated by specific MR imaging processing algorithms.

Early identification of hearing loss not only enables proper acoustic rehabilitation, but also supports the diagnosis of MPS, especially in its milder forms and/or initial stages.

Acknowledgements

The authors wish to thank Dr. Paolo Remida, M.D. for the Neuroradiological workup; Prof. Werner Garavello, M.D. for clinical advice; and Dr. Serena Costanzo, Ph.D., for audiological testing. No funding sources supported research.

Conflicts of interest

The authors report no financial interest in the subject matter, no actual/potential conflict of interest.

Abbreviations

ABR	auditory brainstem responses (acoustically evoked potentials)
AC	air conduction (pure tone audiometry)
avg.	average
BC	bone conduction (pure tone audiometry)
CNS	central nervous system
COR	conditioned oriented responses (test of hearing for babies)
CPAP	continuous positive airways pressure

dB	decibel
ENT	ear, nose and throat (otorhinolaryngology)
ERT	enzyme replacement therapy
FLAIR	fluid attenuated inversion recovery sequence
FSE	Fast Spin-Echo sequence
GAG	glycosaminoglycans
HL	hearing level
HSCT	hematopoietic stem cell transplantation
IAC	internal auditory canal
MPS	mucopolysaccharidoses
MRI	magnetic resonance imaging
MR+	positive at MRI
OME	otitis media with effusion
OSAHS	obstructive sleep apnea/hypopnea syndrome
p.e.SPL	peak-equivalent sound pressure level
PTA	pure tone average (average of thresholds to pure tone stimuli at 0.5–1–2-3 kHz; value expressed in dB HL)
SD	standard deviation
SSFP	3D–Steady-State Free Precession sequence
TEOAE	transient-evoked oto-acoustic emissions

Author details

Diego Zanetti^{1*}, Margherita Vezzani^{2,3}, Federica Di Bernardino¹, Serena Gasperini⁴ and Rossella Parini⁴

*Address all correspondence to: diego.zanetti.bs@gmail.com

1 Audiology Unit, Department of Community Health and Clinical Sciences, Università degli Studi di Milano; Fondazione IRCCS Cà Granda, Ospedale Maggiore Policlinico Milano, Italy

2 Otorhinolaryngology Department, University of Milano-Bicocca, San Gerardo Hospital, Monza, Italy

3 Pediatric Otorhinolaryngology Department, Children's Hospital, Cincinnati, USA

4 Rare Metabolic Diseases Unit, Department of Pediatrics, University of Milano-Bicocca, San Gerardo Hospital, Monza, Italy

References

- [1] Khan SA, Peracha H, Ballhausen D, Wiesbauer A, Rohrbach M, Gautschi M, Mason RW, Giugliani R, Suzuki Y, Orii KE, Orii T, Tomatsu S. Epidemiology of mucopolysaccharidoses. *Molecular Genetics and Metabolism*. 2017;**121**(3):227-240
- [2] Thomas JA, Beck M, Clarke JTR, Cox GF. Childhood onset of Scheie syndrome, the attenuated form of mucopolysaccharidosis I. *Journal of Inherited Metabolic Disease*. 2010;**33**:421-427
- [3] Munoz-Roja MV, Bay L, Sanchez L. Clinical manifestations and treatment of mucopolysaccharidosis type I patients in Latin America as compared with the rest of the world. *Journal of Inherited Metabolic Disease*. 2011;**34**:1029-1037
- [4] Muenzer J, Beck M, Eng CM, Escolar ML, Giugliani R, Guffon NH, Harmatz P, Kamin W, Kampmann C, Koseoglu ST, Link B, Martin RA, Molter DW, Muñoz Rojas MV, Ogilvie JW, Parini R, Ramaswami U, Scarpa M, Schwartz IV, Wood RE, Wraith E. Multidisciplinary management of Hunter syndrome. *Pediatrics*. 2009;**124**(6):e1228-e1239
- [5] Haddad FS, Jones DH, Vellodi A, Kane N, Pitt MC. Carpal tunnel syndrome in the mucopolysaccharidoses and mucopolipidoses. *Journal of Bone and Joint Surgery. British Volume (London)*. 1997;**79**(4):576-582
- [6] Lin HY, Chuang CK, Chen MR, Lin SM, Hung CL, Chang CY, Chiu PC, Tsai WH, Niu DM, Tsai FJ, Lin SJ, Hwu WL, Lin JL, Lin SP. Cardiac structure and function and effects of enzyme replacement therapy in patients with mucopolysaccharidoses I, II, IVA and VI. *Molecular Genetics and Metabolism*. 2016;**117**(4):431-437
- [7] Nestrasil I, Vedolin L. Quantitative neuroimaging in mucopolysaccharidoses clinical trials. *Molecular Genetics and Metabolism*. 2017 Sep 15. pii: S1096-7192(17)30340-2. DOI: 10.1016/j.ymgme.2017.09.006
- [8] Rasalkar DD, Chu WCW, Hui J, et al. Pictorial review of mucopolysaccharidosis with emphasis on MRI features of brain and spine. *The British Journal of Radiology*. 2011;**84**:469-477
- [9] Manara R, Priante E, Grimaldi M, et al. Brain and spine MRI features of Hunter disease: Frequency, natural evolution and response to therapy. *Journal of Inherited Metabolic Disease*. 2011;**34**:763-780
- [10] Summers CG, Ashworth JL. Ocular manifestations as key features for diagnosing mucopolysaccharidoses. *Rheumatology*. 2011;**50**(Suppl 5):34-40
- [11] Valayannopoulos V, Wijburg FA. Therapy for the mucopolysaccharidoses. *Rheumatology (Oxford)*. 2011;**50**(Suppl 5):49-59
- [12] Ohlemiller KK, Hennig AK, Lett JM, Heidbreder AF, Sands MS. Inner ear pathology in the mucopolysaccharidosis VII mouse. *Hearing Research*. 2002;**169**(1-2):69-84

- [13] Netzloff ML, Elsea SH, Fisher RA. Genetic hearing loss associated with metabolic disorders. In: Toriello, Reardon, Gorlin, editors. *Hereditary Hearing Loss and Its Syndromes*. Oxford University Press; 2004. pp. 387-392
- [14] Neufeld EF, Muenzer J. The mucopolysaccharidoses. In: Scriver CR et al., editors. *The Metabolic and Molecular Bases of Inherited Disease*. New York: McGraw Hill; 2001. pp. 3421-3452
- [15] Clarke LA. Pathogenesis of skeletal and connective tissue involvement in the mucopolysaccharidoses: Glycosaminoglycan storage is merely the instigator. *Rheumatology (Oxford, England)*. 2011;**50**(Suppl 5):13-18
- [16] Hopwood JJ, Bunge S, Morris, et al. Molecular basis of mucopolysaccharidosis type II: Mutations in the iduronate-2-sulphatase gene. *Human Mutation*. 1993;**2**:435-442
- [17] Nelson J, Crowhurst J, Carey B, Greed L. Incidence of the mucopolysaccharidoses in Western Australia. *American Journal of Medical Genetics*. 2003;**123A**:310-313
- [18] Fesslová V, Corti P, Sersale G, Rovelli A, Russo P, Mannarino S, Butera G, Parini R. The natural course and the impact of therapies of cardiac involvement in the mucopolysaccharidoses. *Cardiology in the Young*. 2009;**19**(2):170-178
- [19] Hirth A, Berg A, Greve G. Successful treatment of severe heart failure in an infant with Hurler syndrome. *Journal of Inherited Metabolic Disease*. 2007;**30**:820
- [20] Hayflick S, Rowe S, Kavanaugh-McHugh A, Olson JL, Valle D. Acute infantile cardiomyopathy as a presenting feature of mucopolysaccharidosis VI. *The Journal of Pediatrics*. 1992;**120**(2 Pt 1):269-272
- [21] Muenzer J. The mucopolysaccharidoses: A heterogeneous group of disorders with variable pediatric presentations. *Journal of Pediatrics*. 2004;**144**:527-534
- [22] Muenzer J. Overview of the mucopolysaccharidoses. *Rheumatology*. 2011;**50**(Suppl 5):4-12
- [23] Bradley LA, Haddow HRM, Palomaki GE. Treatment of mucopolysaccharidosis type II (Hunter syndrome): Results from a systematic evidence review. *Genetics in Medicine*. 2017;**19**(11):1187-1201
- [24] Motamed M, Thorne S, Narula A. Treatment of otitis media with effusion in children with mucopolysaccharidosis. *International Journal of Pediatric Otorhinolaryngology*. 2000;**53**:121-124
- [25] Simmons MA, Bruce IA, Penney S, Wraith E, Rothera MP. Otorhinolaryngological manifestations of the mucopolysaccharidoses. *International Journal of Pediatric Otorhinolaryngology*. 2005;**69**(5):589-595. Review
- [26] Wold SM, Derkay CS, Darrow DH, Proud V. Role of the pediatric otolaryngologist in diagnosis and management of children with mucopolysaccharidoses. *International Journal of Pediatric Otorhinolaryngology*. 2010;**74**(1):27-31
- [27] Zechner G, Moser M. Otosclerosis and mucopolysaccharidosis. *Acta Oto-Laryngologica*. 1987;**103**(5-6):384-386

- [28] Friedmann I, Spellacy E, Crow J, Watts RW. Histopathological studies of the temporal bones in Hurler's disease [mucopolysaccharidosis (MPS) IH]. *The Journal of Laryngology and Otology*. 1985;**99**(1):29-41
- [29] Van der Knaap MS, Valk J, Barth PG, Smit LM, van Engelen BG, Tortori Donati P. Leukoencephalopathy with swelling in children and adolescents: MRI patterns and differential diagnosis. *Neuroradiology*. 1995;**37**(8):679-686
- [30] Matheus MG, Castillo M, Smith JK, Armao D, Towle D, Muenzer J. Brain MRI findings in patients with mucopolysaccharidosis types I and II and mild clinical presentation. *Neuroradiology*. 2004;**46**:666-672
- [31] Gabrielli O, Polonara G, Regnicolo L, Petroni V, Scarabino T, Coppa GV, Salvolini U. Correlation between cerebral MRI abnormalities and mental retardation in patients with mucopolysaccharidoses. *American Journal of Medical Genetics*. 2004;**125**:224-231
- [32] Arn P, Wraith JE, Underhill L. Characterization of surgical procedures in patients with mucopolysaccharidosis type I: findings from the MPS I Registry. *Journal of Pediatrics*. 2009;**154**(6):859-864.e3
- [33] D'Aco K, Underhill L, Rangachari L, Arn P, Cox GF, Giugliani R, Okuyama T, Wijburg F, Kaplan P. Diagnosis and treatment trends in mucopolysaccharidosis I: Findings from the MPS I Registry. *European Journal of Pediatrics*. 2012;**171**(6):911-919
- [34] Arn P, Whitley C, Wraith JE, Webb HW, Underhill L, Rangachari L, Cox GF. High rate of postoperative mortality in patients with mucopolysaccharidosis I: Findings from the MPS I Registry. *Journal of Pediatric Surgery*. 2012;**47**(3):477-484
- [35] Beck M, Arn P, Giugliani R, Muenzer J, Okuyama T, Taylor J, Fallet S. The natural history of MPS I: Global perspectives from the MPS I Registry. *Genetics in Medicine*. 2014;**16**(10):759-765
- [36] Arn P, Bruce IA, Wraith JE, Travers H, Fallet S. Airway-related symptoms and surgeries in patients with mucopolysaccharidosis I. *The Annals of Otology, Rhinology, and Laryngology*. 2015;**124**(3):198-205
- [37] Mendelsohn NJ, Harmatz P, Bodamer O, Burton BK, Giugliani R, Jones SA, Lampe C, Malm G, Steiner RD, Parini R, Hunter Outcome Survey Investigators. Importance of surgical history in diagnosing mucopolysaccharidosis type II (Hunter syndrome): Data from the Hunter Outcome Survey. *Genetics in Medicine*. 2010;**12**(12):816-822