

# We are IntechOpen, the world's leading publisher of Open Access books Built by scientists, for scientists

5,300

Open access books available

130,000

International authors and editors

155M

Downloads

Our authors are among the

154

Countries delivered to

TOP 1%

most cited scientists

12.2%

Contributors from top 500 universities



WEB OF SCIENCE™

Selection of our books indexed in the Book Citation Index  
in Web of Science™ Core Collection (BKCI)

Interested in publishing with us?  
Contact [book.department@intechopen.com](mailto:book.department@intechopen.com)

Numbers displayed above are based on latest data collected.  
For more information visit [www.intechopen.com](http://www.intechopen.com)



---

# Surgical Approaches to the Temporomandibular Joint

---

Mohammad Esmaeelinejad and Maryam Sohrabi

Additional information is available at the end of the chapter

<http://dx.doi.org/10.5772/intechopen.74141>

---

## Abstract

The temporomandibular joint (TMJ) acts as a sliding hinge between mandible and temporal bone. Disorders of temporomandibular joint are intolerable for the patients in severe cases. Furthermore, surgical treatment of temporomandibular joint problems is a challenge for surgeons in some cases. In that order, it is critical for the surgeon to choose the best surgical approach in treating the temporomandibular joint diseases. There are several surgical approaches in the management of temporomandibular joint problems including some pros and cons. So, in this chapter, we aim to present a comprehensive review of surgical approaches to the temporomandibular joint.

**Keywords:** facial nerve, mandible, mandibular condyle, superficial musculoaponeurotic system, temporomandibular joint

---

## 1. Introduction

Exact diagnosis and appropriate treatment plan are two important fundamentals of successful surgical results. Planning the treatment of temporomandibular joint (TMJ) problems is not an exception. TMJ is a hinge that connects the mandible to the temporal and serves the movement of lower jaw. TMJ problems such as disc derangement, pathologic lesions, and traumatic injuries would have a significant influence on quality of life of the patients.

Treatment of TMJ diseases is still one of the controversial issues in maxillofacial surgery field. It is important to choose the best surgical technique to solve the problem and rehabilitate the TMJ function. There are several surgical approaches to the TMJ mentioned in the literature and a maxillofacial surgeon should know the technical aspects of these surgical procedures.

This chapter is based on recent investigations reported in the literature and briefly presents the different aspects of available surgical approaches to TMJ including their indications, techniques, and benefits.

## 2. Applied anatomy

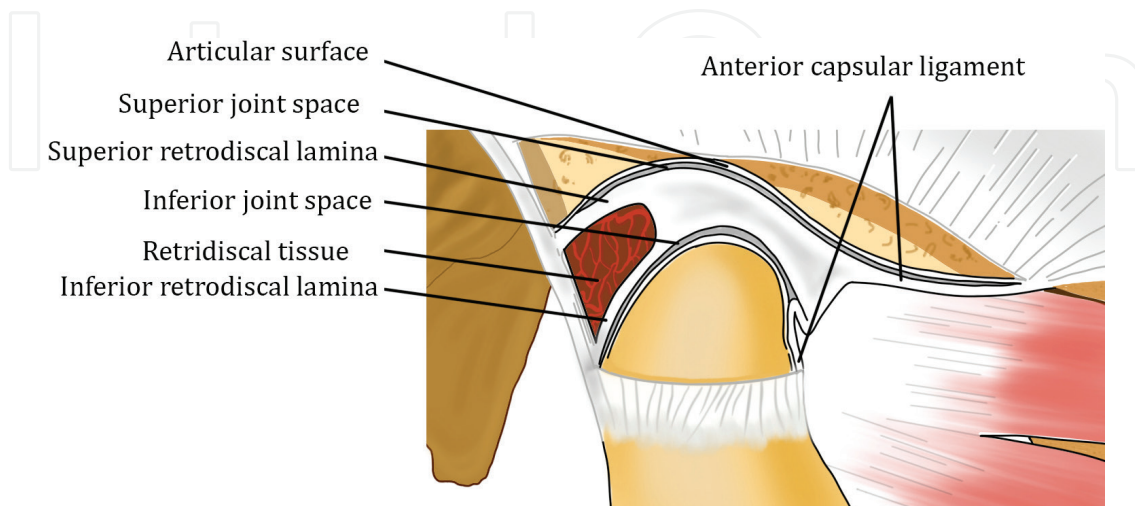
TMJ is a synovial joint between the head of mandibular condyle and the temporal glenoid fossa. The space between the head of mandibular condyle and the glenoid fossa of temporal bone is divided into two separate cavities by the articular disc (**Figure 1**). The inferior compartment is involved in the hinge movement of the joint, while the superior joint space participates in the translation movement.

The postglenoid process and articular eminence are the posterior and anterior limitations of the articular space, respectively. TMJ is surrounded by a fibrous capsule called articular capsule, and its extension is the articular disc (**Figure 2**).

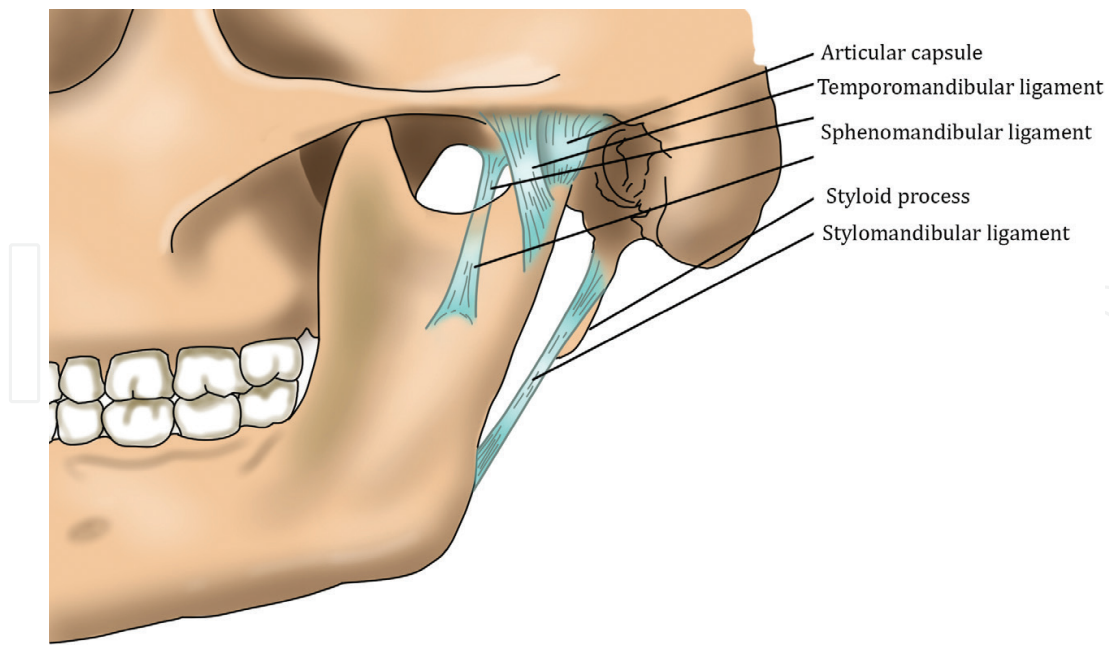
The movements of TMJ are restricted by three main ligaments. The temporomandibular ligament is the lateral portion of articular capsule. This fan-shaped ligament is responsible for synchronizing the condyle and articular disc. The other two ligaments are sphenomandibular and stylomandibular ligaments which are involved in controlling the mandibular movements (**Figure 2**).

### 2.1. Regional nerves

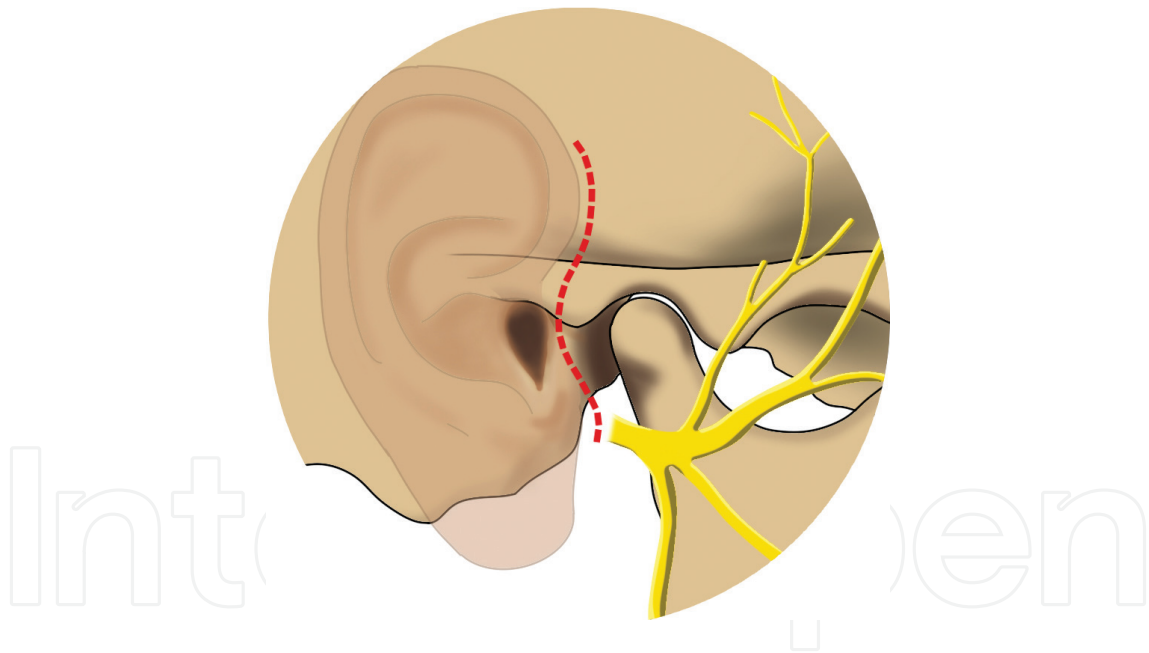
The most common anatomical structure facing during the approaches to the TMJ is the facial nerve. The main trunk of facial nerve exits the stylomastoid foramen and after passing about 2 cm distance divides into two main branches of temporofacial and cervicofacial divisions (**Figure 3**) [1]. The distance from the bony part of external auditory canal to the bifurcation is 1.5–2.8 cm (mean is 2.3 cm) [2]. The assumed line connected from the tragus to the



**Figure 1.** Anatomy of the TMJ.



**Figure 2.** Anatomy of the articular ligaments.



**Figure 3.** Anatomy of the facial nerve.

lateral palpebral commissure is considered the superior limit of temporal branch of the facial nerve. This branch of facial nerve is mostly located under this oblique line [3]. Temporal branch is the most susceptible branch of facial nerve that would be damaged during the approaches to the TMJ [4]. This nerve branch lies under the surface of temporoparietal fascia [5]. The average distance of bony part of external auditory canal to the location where temporal branch of facial nerve crosses the zygomatic arch is almost 2 cm (8–35 mm). In some surgical approaches to the subcondylar area, the most important anatomical structure that

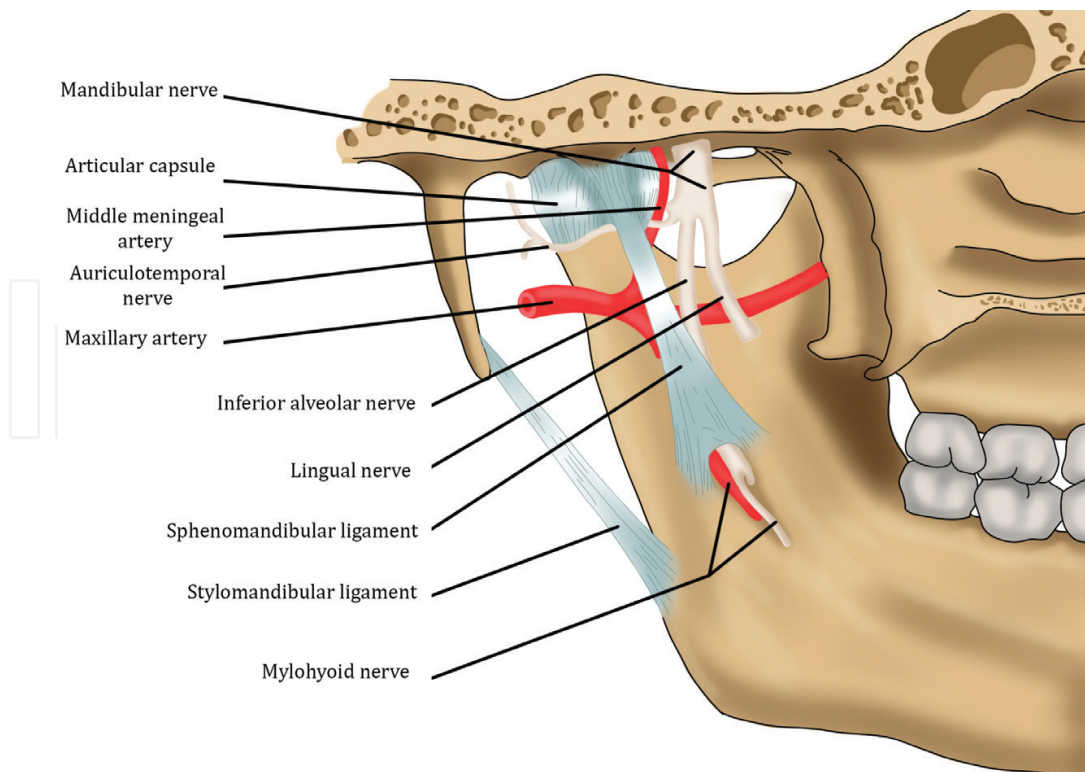
should be preserved is the marginal mandibular branch of the facial nerve. This branch is superior to the mandibular inferior border in 74% of the cases [6]. The maximum distance to the mandibular inferior border is 1.2 cm; in other patients that marginal mandibular branch of facial nerve is located beneath the inferior border of the mandible. This branch is located superior to the facial artery and vein immediately deep to the superficial layer of the deep cervical fascia.

The branches of trigeminal nerve are other critical structures adjacent to the TMJ. The auriculotemporal branch supplies sensation to the anterior external meatus and the temporal and preauricular region skin. This branch of trigeminal nerve passes behind the neck of mandibular condyle (**Figure 4**).

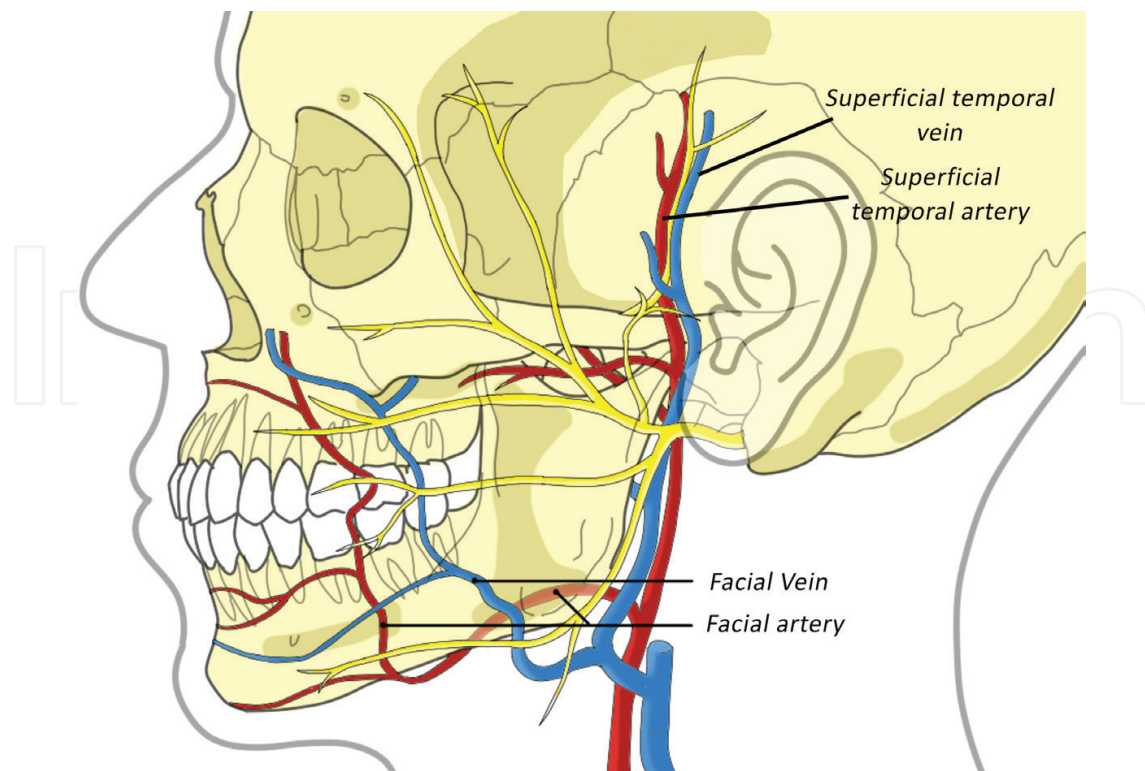
## 2.2. Anatomy of regional vessels

Maxillary artery and superficial temporal artery are two last branches of external carotid artery and important structures adjacent to the TMJ. The surgeons usually face the superficial temporal artery during the preauricular approaches. This terminal branch of external carotid artery runs posterolateral to the mandibular condyle within the temporoparietal fascia (**Figure 5**).

Maxillary artery is important in condylectomy procedure. Middle meningeal artery is a branch of internal maxillary artery that passes medial to the mandibular condyle and could be damaged during the surgical procedures on TMJ.



**Figure 4.** Relation of trigeminal nerve to the TMJ.



**Figure 5.** Vascular anatomy of the face encountered during surgical procedures of the TMJ.

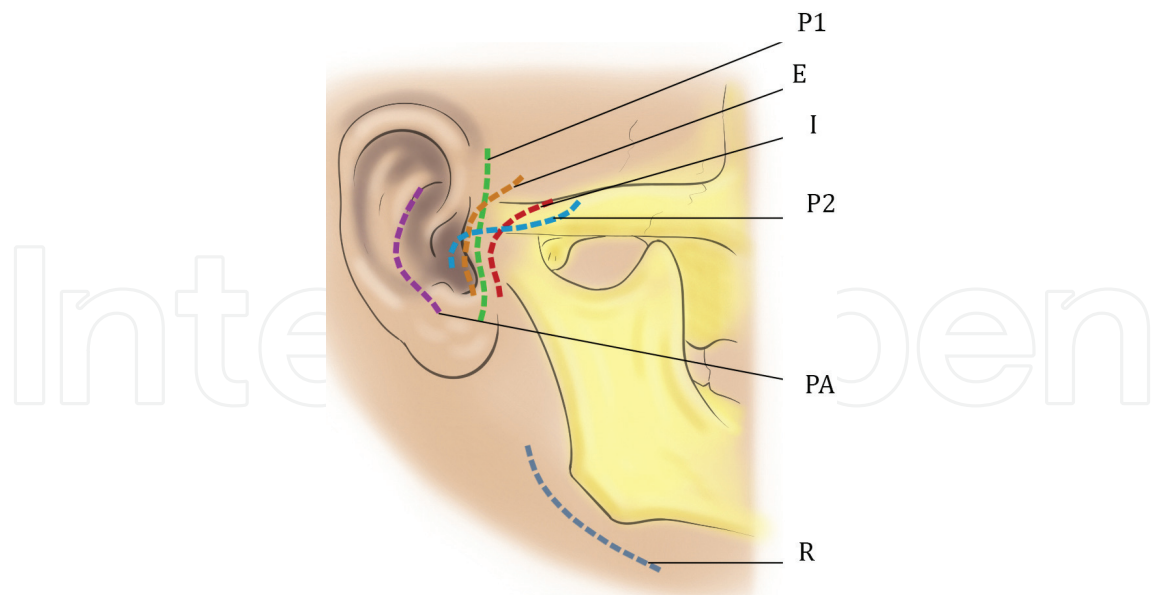
The important vein that the surgeon usually encounters in surgical treatment of the TMJ problems is retromandibular vein which is formed from the superficial temporal and the maxillary veins.

### 3. Surgical approaches

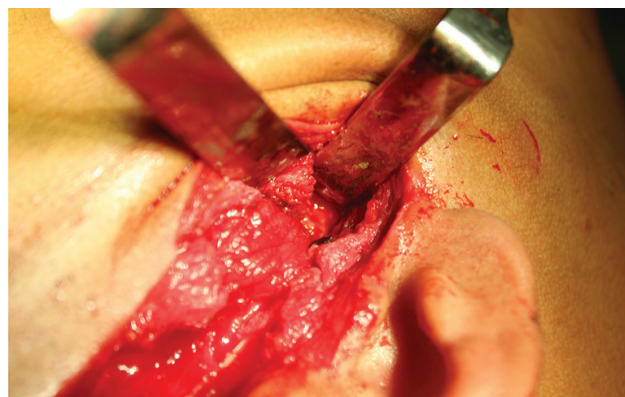
#### 3.1. Preauricular surgical technique

Preauricular incision is made along the natural crease anterior to the tragus (**Figure 6**). Dissection should be continued along the cartilage of external auditory canal in order to prevent damaging the auriculotemporal nerve and superficial temporal artery. Superficial layer of the temporalis fascia would be incised 2 cm above the zygomatic arch in an oblique line. Blunt dissection should be continued to reach the zygomatic arch. The periosteum of the zygomatic arch is incised at this time, and it should be reflected laterally to achieve to the articular capsule (**Figure 7**). If the surgeon needs to expose the superior joint space, the incision should be made along the posterior slope of the articular eminence. Incising the disc along the superior joint space, lateral recess allows the surgeon to expose the inferior joint space.

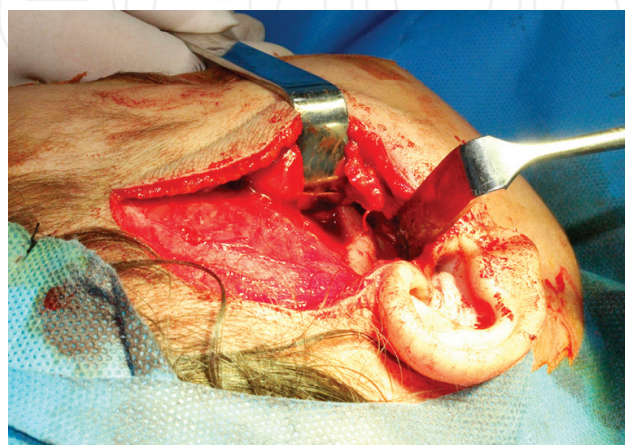
In some cases, to maximize the exposure to the TMJ, preauricular incision is modified to a question mark pattern presented by Al-Kayat and Bramley (**Figure 8**).



**Figure 6.** Surgical approaches to the TMJ. P1 and P2—preauricular approaches; PA—postauricular approach; I—  
inverted hockey stick approach; E—endaural approach. R—retromandibular approach.



**Figure 7.** After exposing the articular capsule, it could be incised to reach to the joint spaces.



**Figure 8.** Al-Kayat and Bramley incision to expose the TMJ for condylectomy.

### 3.1.1. Indications

This approach is ideally used to manage the problems encountered in upper condylar process and TMJ compartments. Al-Kayat modified preauricular incision is routinely used in TMJ ankylosis cases. Preauricular incision is also used in treatment of high condylar fractures.

### 3.1.2. Advantages

Almost invisible scars are main advantages of a preauricular approach. This surgical technique provides access to the superior part of the TMJ and anteromedially displaced mandibular condyle.

### 3.1.3. Disadvantages

There is no access to the lower portion of condylar process. Rigid fixation of mandibular condyle fracture is difficult in this approach [7]. The possibility of facial nerve damage is a major disadvantage of this surgical technique.

## 3.2. Endaural surgical technique

This approach is provided to achieve the benefits of preauricular methods simultaneously with more cosmetic results. The incision is made behind the prominence of the tragus. The skin flap is reflected over the cartilage of the tragus, and then, dissection is continued in the same manner of preauricular approach.

### 3.2.1. Indications

This technique is indicated when there is the aim to provide the access to the TMJ and fractures of condylar head and neck.

### 3.2.2. Advantages

The cosmetic result of scar is better than preauricular incision [8].

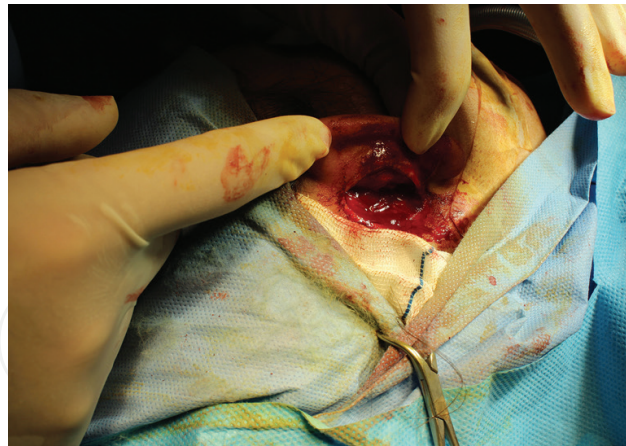
### 3.2.3. Disadvantages

Tragus cartilage damage is the main disadvantage of this approach. When the problem happens, poor healing process is expected.

## 3.3. Postauricular surgical technique

The incision is made 3 mm posterior to the posterior auricular fold and carried to the mastoid fascia (**Figure 9**). Dissection is continued above the mastoid fascia to the external auditory canal which is then transected to retract the pinna anteriorly. Dissection through the superficial layer of temporalis fascia is carried out to the zygomatic arch, and the periosteum is sharply incised to expose the joint. There is no need to suture the cartilage after the surgery, and closing the skin of the ear is enough.





**Figure 9.** The incision pattern of postauricular approach (Courtesy of Dr. F. Pourdanesh).

### 3.3.1. Indications

Exposing the entire joint is the main indication of this technique. This approach is also indicated in the patients with the tendency to form keloids who should undergo TMJ surgery.

### 3.3.2. Advantages

The resulting scar is not very noticeable, and an excellent exposure to the TMJ is provided by this method.

### 3.3.3. Disadvantages

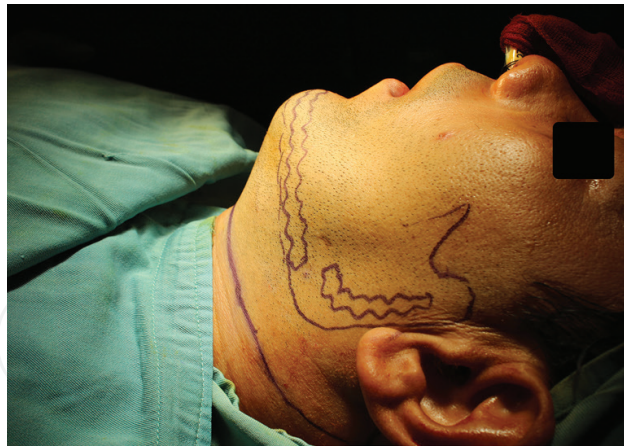Auricular stenosis is the main disadvantage of this procedure. External otitis and infection of the TMJ are the contraindications of this approach.

## 3.4. Submandibular surgical technique

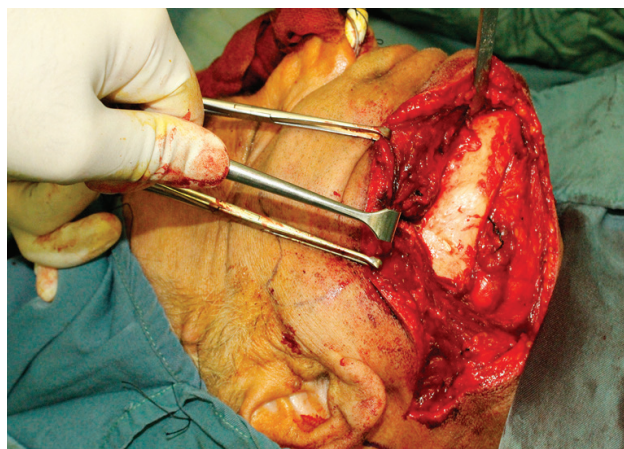
To provide the safety zone of marginal mandibular nerve, the incision is made 2 cm below the inferior border of the mandible (**Figure 10**). The sharp incision is made through the skin and subcutaneous tissue. Then, the platysma is sharply incised to expose the superficial layer of deep cervical fascia. The fascia is incised at the level of the skin incision. The facial artery and vein are retracted or ligated. According to the Hayes-Martin maneuver, ligation and upward retraction of facial vessels protect the marginal mandibular nerve from injury [9]. The dissection is carried to the pterygomasseteric sling. The sling is sharply incised by the blade, and the inferior border of the mandible is exposed (**Figure 11**).

### 3.4.1. Indications

This approach is usually used for mandibular angle and body fractures and sometimes for low subcondylar fractures.



**Figure 10.** Outline of lateral ramus and submandibular incision. The distance from the inferior border of mandible to the incision should be about 2 cm.



**Figure 11.** Exposure of mandibular angle, body, and lateral ramus area by submandibular approach.

#### *3.4.2. Advantages*

The advantage of this technique is the ability to retract the mandibular angle when the surgeon attempts to reduce the condylar fracture. Also, this method provides good accessibility for anchor screw fixation technique of mandibular subcondyle fractures.

#### *3.4.3. Disadvantages*

There is limited access to the high condylar portion and joint spaces.

### **3.5. Retromandibular surgical technique**

The incision is made along the posterior border of mandible 5 mm below the earlobe inferiorly for a distance of about 3 cm. Incision is continued through the skin, subcutaneous tissue, platysma, and superficial musculoaponeurotic system (SMAS). The SMAS layer is undermined,

and blunt dissection is continued to the substance of the parotid. The dissection is carried to the periosteum of the posterior border of the mandible. The periosteum is sharply incised, and the access to the lower portion of condylar process is provided.

### 3.5.1. Indications

This technique is used for internal rigid fixation of low condylar fracture. This approach is also used for fixation of costochondral graft in TMJ region.

### 3.5.2. Advantages

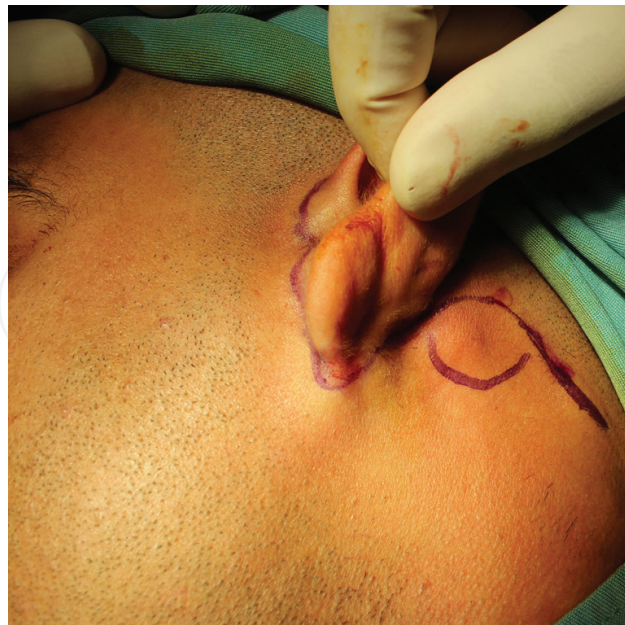Good accessibility to the lower portion of condylar fracture and subcondylar area is the main advantage of retromandibular approach. A less noticeable scar in comparison with the submandibular technique is the other advantage of this approach.

### 3.5.3. Disadvantages

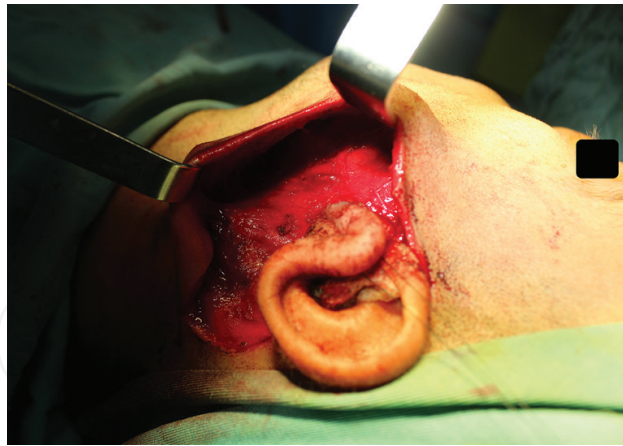
A more visible scar than preauricular incision is the disadvantage of this technique. The access to the joint spaces and anteromedially displaced condyle is limited in this surgical method.

## 3.6. Rhytidectomy surgical technique

The incision is made in preauricular area and in the neck hairline (**Figure 12**). The skin and subcutaneous tissue are incised, and dissection is carried above the level of SMAS (**Figure 13**).



**Figure 12.** Outline of incision for rhytidectomy approach is combined of preauricular incision and an incision in neck hairline.



**Figure 13.** After incising the skin and subcutaneous tissue for rhytidectomy approach, dissection is continued over the SMAS.

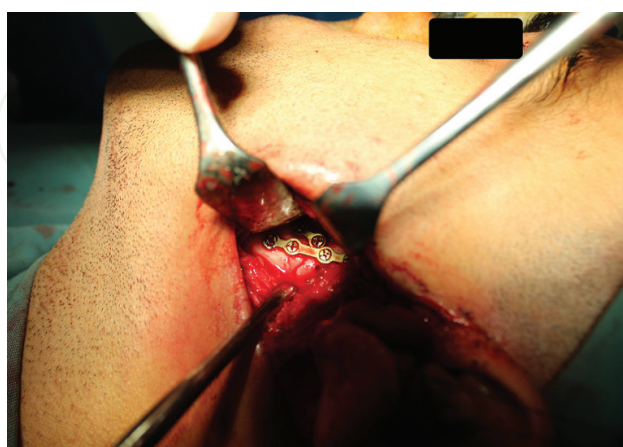
A vertical incision is made through the SMAS onto the parotid gland, extending from just below the ear lobe toward the gonial angle. Blunt dissection through the substance of parotid is continued to the posterior border of the mandible. The periosteum is sharply incised, and the entire mandibular ramus is exposed (**Figure 14**).

#### *3.6.1. Indications*

This approach is indicated when the accessibility to the lower portion of TMJ is needed similar to the retromandibular technique although its cosmetic results are much better than the latter technique.

#### *3.6.2. Advantages*

Good cosmetic results of the scar and enough access to the condylar process are the most important advantages.



**Figure 14.** Exposure of condylar neck fracture by rhytidectomy approach. The fracture was reduced and fixed by two miniplates.

### 3.6.3. Disadvantages

Damage to the branches of facial nerve is the most important disaster that could happen in this method.

## 3.7. Intraoral approach surgical technique

Incision is made in an external oblique ridge area. Subperiosteal dissection is carried out over the mandibular ramus (**Figure 15**).

### 3.7.1. Indications

Reduction and fixation of subcondyle fracture are two usual indications of intraoral approach. This method is also used sometimes for condylectomy [10].

### 3.7.2. Advantages

Invisible scar and preventing from facial nerve damage are the benefits of current approach.

### 3.7.3. Disadvantages

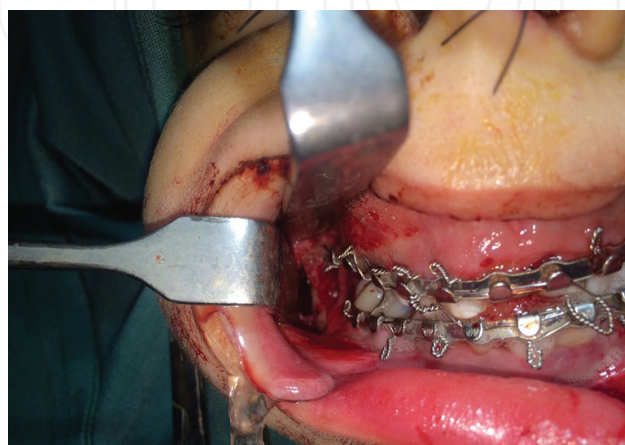Limited access to the TMJ is the main problem during this surgical method.

## 3.8. Endoscopic approach surgical technique

Subperiosteal dissection is performed following the incision of posterior mandibular buccal sulcus. A percutaneous incision is then made perpendicular to the mandibular condyle just to pass the endoscope. Further dissection is then carried under direct vision provided by the endoscope.

### 3.8.1. Indications

Mandibular condyle fractures are the main indications of this approach.



**Figure 15.** Intraoral approach to manage mandibular subcondyle fracture in a 9-year-old boy.

### 3.8.2. Advantages

This method is minimally invasive with invisible scars. The possibility of nerve damage during this technique is very low [11].

### 3.8.3. Disadvantages

Increasing the operation time is a disadvantage of endoscopic technique [12].

## 4. Conclusion

Deciding on choosing a unique surgical technique for the treatment of all pathologies and diseases of the TMJ is impossible. It is important to understand the pros and cons of all available procedures and choose the best approach with most benefits which provides the best access to the TMJ.

## Acknowledgements

We would like to thank Hossein Esmaeelinejad for providing the illustrations of the chapter.

## Conflict of interest

The authors declare that they have no conflict of interest.

## Author details

Mohammad Esmaeelinejad<sup>1\*</sup> and Maryam Sohrabi<sup>2</sup>

\*Address all correspondence to: [esmaelnejad@gmail.com](mailto:esmaelnejad@gmail.com)

1 Department of Oral and Maxillofacial Surgery, School of Dentistry, Semnan University of Medical Sciences, Semnan, Iran

2 Department of Oral and Maxillofacial Surgery, School of Dentistry, Azad University of Medical Sciences, Tehran, Iran

## References

- [1] Yang HM, Won SY, Kim HJ, Hu KS. Neurovascular structures of the mandibular angle and condyle: a comprehensive anatomical review. *Surgical and Radiologic Anatomy: SRA*. 2015;37:1109-1118

- [2] Al-Kayat A, Bramley P. A modified pre-auricular approach to the temporomandibular joint and malar arch. *The British Journal of Oral Surgery*. 1979;**17**:91-103
- [3] Saylam C, Ucerler H, Orhan M, Ozek C. Anatomic guides to precisely localize the zygomatic branches of the facial nerve. *The Journal of Craniofacial Surgery*. 2006;**17**:50-53
- [4] de Bonnecaze G, Chaput B, Filleron T, Al Hawat A, Vergez S, Chaynes P. The frontal branch of the facial nerve: can we define a safety zone? *Surgical and radiologic anatomy: SRA*. 2015;**37**:499-506
- [5] Pourdanesh F, Esmaeelinejad M, Jafari SM, Nematollahi Z. Facelift: Current Concepts, Techniques, and Principles. In: *A Textbook of Advanced Oral and Maxillofacial Surgery Volume 3*. InTech; 2016
- [6] Saylam C, Ucerler H, Orhan M, Uckan A, Ozek C. Localization of the marginal mandibular branch of the facial nerve. *Journal of Craniofacial Surgery*. 2007;**18**:137-142
- [7] Jayavelu P, Riaz R, Tariq Salam AR, Saravanan B, Karthick R. Difficulties encountered in preauricular approach over retromandibular approach in condylar fracture. *Journal of Pharmacy & Bioallied Sciences*. 2016;**8**:S175-S1s8
- [8] Santos GS, Nogueira LM, Sonoda CK, de Melo WM. Using endaural approach for temporomandibular joint access. *The Journal of Craniofacial Surgery*. 2014;**25**:1142-1143
- [9] Richards AT. Chapter 14 - Surgical Exposures for the Nerves of the Neck A2 - Tubbs, R. Shane. In: Rizk E, Shoja MM, Loukas M, Barbaro N, Spinner RJ, editors. *Nerves and Nerve Injuries*. San Diego: Academic Press; 2015. p. 201-213
- [10] Li B, Sun H, Zhang L, Wang X. Simple way of facilitating intraoral condylectomy and securing the excised condyle: technical note. *The British journal of oral & maxillofacial surgery*. 2013;**51**:e305-e306
- [11] You HJ, Moon KC, Yoon ES, Lee BI, Park SH. Clinical and radiological outcomes of transoral endoscope-assisted treatment of mandibular condylar fractures. *International Journal of Oral and Maxillofacial Surgery*. 2016;**45**:284-291
- [12] Schmelzeisen R, Cienfuegos-Monroy R, Schon R, Chen CT, Cunningham L Jr, Goldhahn S. Patient benefit from endoscopically assisted fixation of condylar neck fractures--a randomized controlled trial. *Journal of oral and maxillofacial surgery : Official Journal of the American Association of Oral and Maxillofacial Surgeons*. 2009;**67**:147-158