

We are IntechOpen, the world's leading publisher of Open Access books Built by scientists, for scientists

4,800

Open access books available

122,000

International authors and editors

135M

Downloads

Our authors are among the

154

Countries delivered to

TOP 1%

most cited scientists

12.2%

Contributors from top 500 universities



WEB OF SCIENCE™

Selection of our books indexed in the Book Citation Index
in Web of Science™ Core Collection (BKCI)

Interested in publishing with us?
Contact book.department@intechopen.com

Numbers displayed above are based on latest data collected.
For more information visit www.intechopen.com



Learning and Teaching after 50 Years of THORAX Surgery

Jaime Villalba Caloca, Avelina Sotres Vega,
Javier Pineda Gutiérrez, Sergio Martínez Fonseca,
Marcelino Alonso Gómez and
Bettina Sommer Cervantes

Additional information is available at the end of the chapter

<http://dx.doi.org/10.5772/intechopen.72915>

Abstract

Surgeries are practiced in different areas, and specifically in the thorax described in this chapter, the medical doctors must know in detail the biological structures in which they perform such surgical procedures. Therefore, in this chapter, we refer to the descriptive and topographical anatomy written by French doctors L. Testut and A. Latarjet. In earlier times, for several reasons, the medical surgeon operated all body organs and was involved in resolving the pathology of different areas. Currently and in the future, medical knowledge in thoracic surgery will cover subspecialties specifically divided, for example: assisted video surgery, interventional bronchoscopy, and mediastinoscopies to take mediastinal biopsies using robotic surgery of pulmonary exeresis to shorten the hospitalization period and even the days spent in the intensive care unit.

Keywords: surgery, thorax, education

1. Introduction

In the past, the assessment of surgical education started with the difficult acquisition of knowledge, reading through a total of six anatomy volumes published by Testut and Jacob and Testut and Latarjet. Besides, an unlimited number and type of general surgical procedures had to be carried out. Currently, surgical practice is mainly obtained through experimental models. These methods of teaching and learning surgical skills have shown that “if students outlive” the anatomical and functional steps, they will gain a greater understanding of anatomy and physiology. Nonetheless, surgeons must get a specific surgical specialty. In the

future, surgeons will become subspecialists with genetic and robotic multitraining. However, it must be said that this issue may contain sensible medical ethical dilemmas, although this discipline derived from philosophy has grown in a very important way and surely will continue growing every day, mainly because of the positive impact of technological development on human well-being.

Regarding surgery, in the past, surgeons without any surgical specialty were capable of performing incisions in all cavities; they could correctly perform surgeries in the central nervous system, resolve cardiopathies, and dissect the abdomen. Currently, for instance in chest surgery, there are many subspecialties such as video-assisted surgery or interventional bronchoscopy performing surgeries such as pleural decortication, pulmonary resection, oncologic surgery, endocavitary aspiration, and transbronchial punctures for therapeutic, diagnostic or palliative purposes, and lately long-distance surgery and robotic surgery. The large number of subspecialties that have currently been added to pneumology, such as thoracic oncology, pulmonary pathophysiology, and intensive care of sleeping disorders, is worth noting. In addition to technological changes, in the future, thoracic surgeons will have to have knowledge/comprehend and support genomic medicine, molecular biology, epigenetics, computer networks, telecommunications, bioelectronics, artificial intelligence, communication and psychomedical techniques of treatment, geriatrics, preventive medicine, administration and health economics as well as ethics. Currently, thoracic surgery in the future will be practiced by groups of subspecialists that will need to be competent to select/choose from millions of data published daily in order to obtain and classify information.

2. From pulmonary collapse to video-assisted and robotic surgery

“Writing about general chest surgery practiced since 50 years ago to date, and its future trends is to describe the medical-surgical fight against two important diseases: in the past, against pulmonary tuberculosis, and currently, against lung cancer. In the future, the challenge will be to unify video-assisted approach and robotics along with research and study of new drugs against these two diseases” [1].

Pulmonary tuberculosis or “the great white plague” was a serious public health problem worldwide since time immemorial, as confirmed by the forensic analysis of human remains showing signs of tuberculosis.

If we remember and think about Thomas Mann’s classic book “The Magic Mountain,” which began to be written in 1912 and was finished in 1924 and which describes the hospitals that existed in the mountains of Switzerland, we may recognize that in those times it was suggested that the air that could be breathed at those heights was a good treatment for the white plague. The hospital most talked about is the Walls Sanatorium in Davos, where lung collapse measures were used to treat tuberculosis patients. Nowadays, some of those homes once inhabited by patients with Koch bacillus, became fashion great luxury hotels.

The National Institute of Respiratory Diseases in Mexico (NIRDM) was inaugurated in 1936 as the Huipulco Tuberculosis Sanatorium (**Figure 1**), a place where most patients suffered



Figure 1. Huipulco tuberculosis sanatorium, Mexico City, 1936.

from pulmonary tuberculosis. The sanatorium was architecturally designed in such a way that the rooms for patients had only three and a half walls to allow the free cycling of fresh air. NIRD was built approximately 15 km away from the urban area, on green fields full of trees with temperatures ranging between 5 and 11°C [2].

Over the years, overpopulation and the consequent urban growth have caused environmental changes along with different ways of thinking about the treatment of some diseases, including tuberculosis. Because tuberculosis has been earmarked with lower income, less financial resources are allotted to its treatment while much more money is allocated to chronic-degenerative diseases.

In the past, young students' restlessness and an unreal desire to dress in the surgeon's uniform made the work even harder. The process was relatively slow since during the period as a medical student and specifically during the first 2 years, two tremendous subjects had to be studied exhaustively: the first one was descriptive anatomy. This task implied using "The Treatise on Descriptive Human Anatomy" by Testud and Jacob as a bedside book. The second subject was topographic anatomy based on "The Compendium of Topographic Anatomy" by Testut and Latarjet, a textbook that described human anatomy by regions.

Currently, much functional knowledge of the human body is mainly obtained in a practical way, either through experimental models or with dummies that had shown that "if students outlive" the anatomical and functional study steps, they will indisputably gain a greater understanding of anatomy and physiology knowledge.

When a medical student studies, learns clinical subjects such as pneumology, gastroenterology, or cardiology among other subjects, he or she does it closely to his or her tutor. The semiological study of the patient is performed on the analysis of the patient's symptoms, that is, if the patient presents clinical signs such as dyspnea or cough, lung anatomy will be remembered, as well as the physiology of the lower airways regarding ventilation, perfusion,

and diffusion; the surgical coil will especially be thought about when procuring the patient's benefit. I think that in the future, all surgical/medical decisions will have to be taken by a group of experts, and a biologist-immunologist must be considered as one of them.

As for surgery, in the past, it was said that "the great surgeons made large incisions." Furthermore, these great surgeons surgically intervened all the organs of the different cavities of the human body, and, as I experienced while I was a medical student, I saw the same surgeon from The General Hospital of Mexico practicing surgeries very dexterously in the central nervous system, or to alleviate heart diseases as well as the most frequent procedures practiced in the abdomen, such as colicystectomies and intestinal resections.

When I was in the fourth year of my Bachelor's studies in medicine, I started studying the respiratory apparatus. It was the time when several types of thoracoplasty and some pulmonary resections were performed. After entering the surgery and seeing the surgical technique of thoracoplasty and the type of anesthesia used, I was impressed by the incision at the skin level, by the muscular separation, the entrance to the pleural cavity, and the desperiostization of the first, second and third ribs. So I decided to learn the surgical method and the postoperative management of this irreversible pulmonary collapse. Likewise, observing pulmonary resection was surprising too, due to the dissection of the pulmonary hilum and by the different techniques used to close the lobular bronchus or the lung.

In Mexico, Koch's bacillus caused severe damage to the population, and around 1890s, health authorities and the distinguished physician Eduardo Liceaga started an organization to fight against the infection by *Mycobacterium tuberculosis*. Among their actions, they initiated a medical service called Observation and Treatment of Tuberculosis.

In 1905, The General Hospital of Mexico was inaugurated. There, two pavilions were assigned for tuberculosis patients only, and after the Mexican Revolution (1910), this pathology incidence increased because of the poverty increment after the armed conflict [1].

In those years, no specific treatment against *M. tuberculosis* was available and its therapeutic management was based on herbal medicine without any etiological basis, even though the causal agent of this millennial suffering had been discovered since 1882 by the German doctor Roberto Koch.

In those previous years, "pulmonary resections" were performed by placing the pulmonary hilum, either lobar or the whole lung, in a tourniquet, and a dissection was performed. True cunning was required in order to apply a tourniquet to the entire pulmonary hilum to perform the pneumonectomy. This surgery caused significant bleeding and bronchopleural fistulas with 25–30% of mortality rate. Indisputably, in order to practice a pneumonectomy, the surgeon must dissect the veins, artery, and bronchus either from the segment, the lobe, or the lung. Doctor Overholt, who intervened his patients in a face-down position on an operation table specially designed by him, insisted in the dissection of the pulmonary hilum. Leo Eloesser also supported this surgical procedure.

In 1882, the same year in which Robert Koch (**Figure 2**) discovered the causal agent of pulmonary tuberculosis, Carlo Forlanini devised intrapleural pneumothorax [3]. Since Koch's postulates have been valid for 135 years, it is worth remembering them:

1. The bacterial pathogen is isolated from sick animals and never from healthy animals.
2. Bacteria can be isolated, cultivated, and purified from sick animals.
3. If bacteria are inoculated into a healthy susceptible host, illness would occur.

In 1954, Dr. Miguel Jiménez Sánchez registered a book describing the doctrine of respiratory trauma very well. His intention was to prevent it and give rise to the collapse therapy. It is worth describing this concept in the words of Dr. Jiménez:

“By the action of the inspiratory muscles, the lung tissue is subjected to a centrifugal distension that increases during inspiration, but does not disappear in the expiratory phase, since, during this phase, it occupies a space much bigger than the corresponding to its true complete rest position, which is the total collapse of the viscera, in which its retraction force is annulled, a circumstance that does not occur “in vivo” due to the existence of the pleural attraction that keeps the lung in a state of constant distension in the vicinity of the costal wall. In other words, the lung during expiration (physiological rest) is in a state of centrifugal hyperdistension that increases during each inspiration by the mechanisms already indicated.”



Figure 2. Robert Koch.

Also in the words of Dr. Jimenez: “The lung has a very delicate anatomical constitution and is formed of a tissue that is essentially elastic, uniform and eccentrically dilatable in the course of inspiration. It can be considered as a small elastic balloon that cannot dilate or retract as long as the inspiration does not allow the entrance of the air and the exhalation its exit. The alveolus is subjected to two opposing forces; on the one hand, the inspiratory muscles tend to dilate it, and on the other, the narrowing of the airways, by delaying the arrival of the air, oppose this dilatation. It is notable that a tissue as weak as that of the alveolus, due exclusively to its elastic expansion potential, can dampen the action of two opposing forces; and if its very delicate wall is not injured, it is that its dilatability is superior to the inspiratory dilation of the thorax” [4] (**Figure 3**).

These concepts described by Dr. Forlanini and established by Dr. Jimenez led to the idea that normal function became abnormal because of lung disease.

It must be mentioned that inflammatory factors generated by pulmonary infection develop pleuritis, since the pleural leaves are adhered, and because their function to impede lung collapse gets compromised, Dr. Forlanini implemented a surgical technique called “section of adhesions,” to section them and avoid the lung’s collapse. When this procedure was executed, the urethroscope was used because there was no other equipment (as, for instance, a pleuroscope) available to section the parieto-visceral adhesions.

With Dr. Forlanini’s idea of causing pulmonary immobility, several physicians who treated pulmonary tuberculosis performed irreversible pulmonary collapse using different surgical techniques that comprised resection of the ribs in order to “letting the lung fall”, that is, inducing pulmonary collapse and, consequently, improving mainly cavitary lesions.

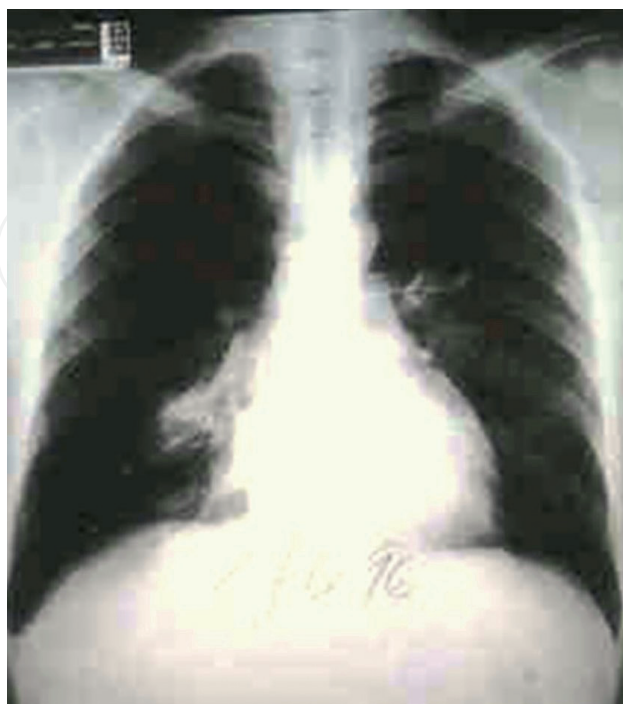


Figure 3. Right pneumothorax X-ray image.

Breathing is carried out through inspiration and expiration in a number of 12–18 breaths per minute in diseased lungs, and this gave Dr. Carlo Forlanini the notion of the respiratory trauma concept. He explained that in lungs infected with *M. tuberculosis*, the inspiration and expiration “beat” the lung parenchyma, therefore increasing the pulmonary injury, and his idea was to avoid the respiratory trauma through the intrapleural pneumothorax as far as possible.

The discovery of *M. tuberculosis* coincides with the concept that respiratory trauma caused the persistence of the pathology. Dr. Carlo Forlanini claimed that inspiration and exhalation hit the lung fundamentally on the thoracic area that he called “dominant lines” which he described in the diaphragm and in the pulmonary hilum areas, and he concluded that an injured lung suffered from respiratory trauma while the movement of inspiration and expiration did not affect the parenchyma of healthy lungs. Based on this idea, it was concluded that a measure for the treatment of pulmonary tuberculosis was to keep the patient at rest since it was a patient with respiratory trauma. To achieve this goal, different methods were conceived.

Subsequently, in Naples, Italy, Dr. Monaldi pursued the endocavitary aspiration to eliminate caseum from the tuberculous cavern, because the greatest amount of bacilli concentrates in that area [5].

Another surgical procedure practiced to avoid respiratory trauma was the phrenicectomy, although it caused respiratory insufficiency, paralysis of the hemidiaphragm, and therefore serious pulmonary ventilation problems.

In 1952, Waksman was awarded the Nobel Prize for his research in streptomycin discovery, a drug that fortunately led to a significant reduction in surgical measures for the treatment of pulmonary tuberculosis.

There are different procedure types of thoracoplasty as follows:

1. Total thoracoplasty.
2. Subtotal thoracoplasty.
3. Upper partial thoracoplasty.
4. Partial inferior thoracoplasty.
5. The widened thoracoplasty.
6. Iterative thoracoplasties.
7. Thoraco-apicolysis.

Frequently, pulmonary tuberculosis caused infection in the pleural cavity or empyema tuberculosis. In most cases, this pathological situation required draining of pleural pus through a water seal connected to suction. Furthermore, the pleura responded to the *M. tuberculosis* invasion with inflammation and thickening of both visceral and parietal leaves of the pleura; the lung remained “imprisoned” by the pleural response. Simultaneously, “pulmonary incarceration” caused ventilation disorders, and it was necessary to practice surgery and resect the “pleural shell,” removing the tuberculosis pleura and improving ventilatory mechanics.

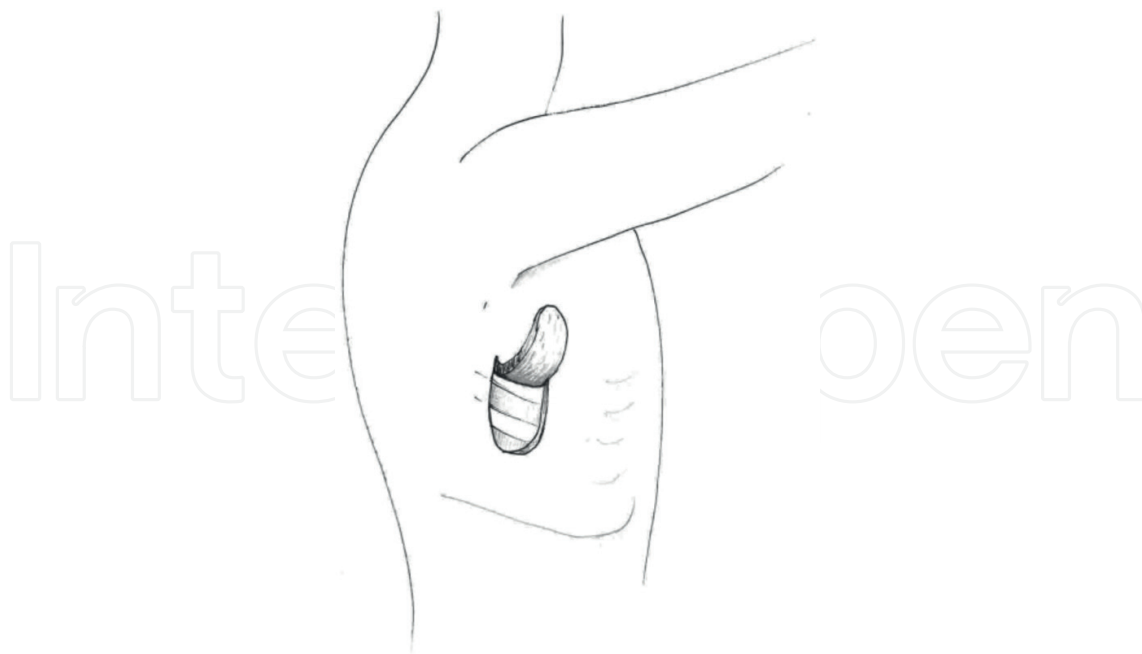


Figure 4. Eloesser's window technique for pleural drainage.

In 1935, Dr. Leo Eloesser devised a surgical technique called Eloesser's Window to drain the tuberculous empyema by opening the pleural cavity. This "window" was a $2 \times 3 \text{ cm}^2$ cut into the costal wall and thus allowing the cleaning of the cavity to perform the pulmonary decortication (**Figure 4**).

3. Plumbing, gel, and lucite balls

Extrapleural pneumolysis. To collapse the pulmonary apex, extrapleural pneumolysis was devised. It consists of lowering the "tip of the lung" via the extrapleural route to allow collapsing of the cavernous lesions of the upper pulmonary segments. One of the problems with this technique was to support the collapse of the vertex because the application of air was difficult due to the presence of fibrous tissue. This led to the inclusion of different materials as, for instance, lucite balls (similar to ping pong balls) into the extrapleural space to maintain the pulmonary collapse and facilitate the application of air into the extrapleural space.

Around 1933, Dr. Banyai, while trying to perform an intrapleural pneumothorax in a tuberculous patient, introduced air into the peritoneal cavity, causing a pneumoperitoneum (**Figure 5**) that enhanced the evolution of tuberculosis lesions in the inferior lung lobes. This gave rise to the fact that in certain topographic situations of the tuberculous lesions, the pneumoperitoneum will be used.

All surgical interventions, intrapleural pneumothorax, extrapleural pneumothorax (difficult to maintain), plumbing (**Figure 6**), lucite balls (**Figure 7**), phrenicectomy, pneumoperitoneum,

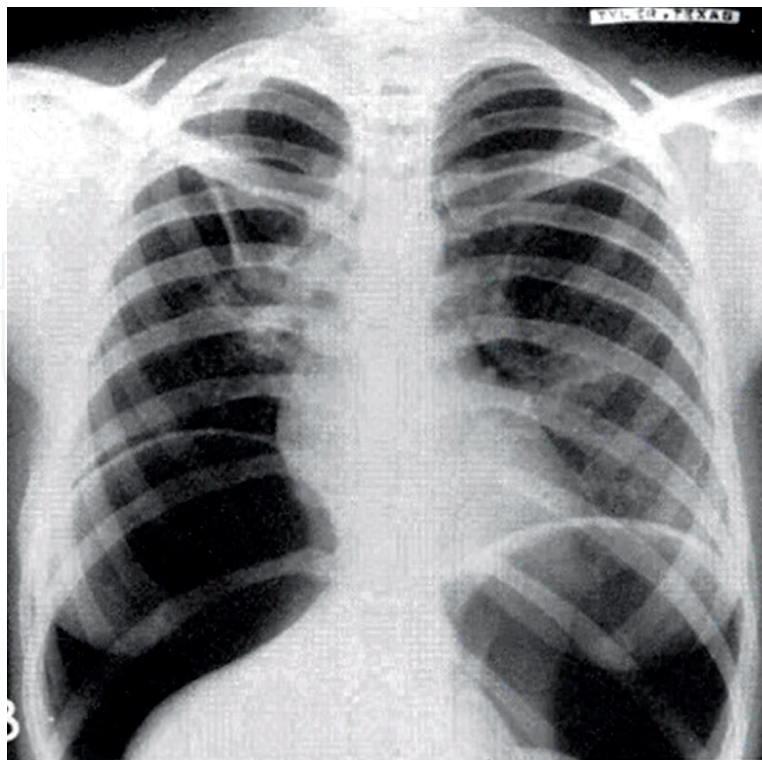


Figure 5. Pneumoperitoneum X-ray image.

and all types of thoracoplasty mentioned earlier are practiced to keep the lung at rest to avoid respiratory trauma.

Although nowadays, efficient primary and secondary drugs for tuberculosis treatment exist, the lack of education and low-economic income have contributed to bacillary resistance, and occasionally thoracic surgery must be practiced to maintain the lung at rest.

Undoubtedly, as it has been stated by well-known physiology specialists “tuberculosis has been an excellent teacher and an important teaching and learning factor in the management and treatment of different diseases of the chest.”

On the other hand, thoracoplasties consist of removing the posterior and lateral edges of the ribs, which are the parietal pleural support. This excision induced the lung collapse, and the surgical techniques are shown in **Table 1** [6].

Plumbing, a technique that consisted of the application of oil to provoke lung collapse and diminish the respiratory trauma, lowers the apex of the lung, and the introduction of lucite balls into the pleural cavity was also used to avoid respiratory trauma. These methods occasionally caused erosions of the bronchi; even though oil could be expelled through air expulsion, the lucite balls had to be surgically removed.

Thoracoplasty was another surgical method used to reduce respiratory trauma. It consists of the resection of the first five ribs in two surgical times, from the vertebral joint to the sternum costal joint. All patients submitted to thoracoplasty had paradoxical breathing due to the lack

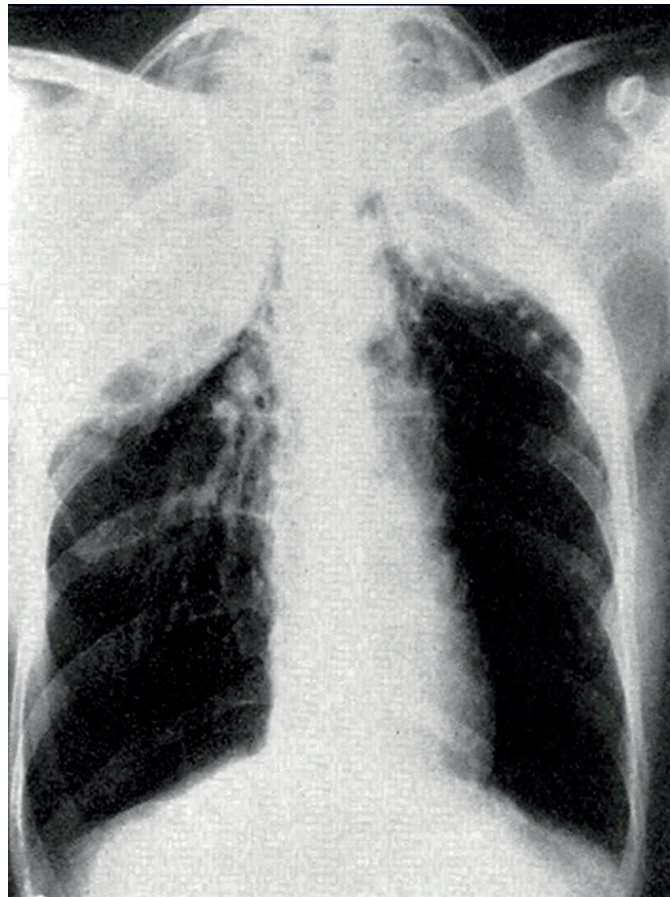


Figure 6. Plumbing X-ray image.

of support offered by the ribs, to the development of pleural adhesion, and to consequent negative pressure. These disturbances on the pulmonary ventilation “mediastinal swing and loss of costal support” invited the surgeon to practice a different type of thoracoplasty, that is, performing a partial resection of the ribs. This type of surgery, called chondroflexion, decreased the hemithorax space and no paradoxical breathing was produced (**Figure 8**).

In some patients, a post-thoracoplasty resection was prescribed in order to remove excavated lesions through lobar or segmental resection.

In addition to thoracoplasties, to keep the lung at rest, the phrenic nerve was sectioned with the purpose of paralyzing the corresponding hemidiaphragm and avoid trauma in the inferior dominant line. This surgery was performed for many years but unfortunately caused respiratory insufficiency because of diaphragmatic immobility and infections that were consequence of poor secretion management. In the long term, hemodynamic disorders such as pulmonary artery hypertension developed (**Figure 9**).

In Mexico City, the first lung resection was performed by Leo Eloesser at the Huipulco Tuberculosis Sanatorium (NIRD), and he was assisted by William B. Neff, who took care of the general anesthesia (**Figure 10**).

In the 1950s, staplers were developed in the Soviet Union to perform resections of pulmonary pathology in “wedge,” that is, without dissecting the corresponding hilum. This surgical

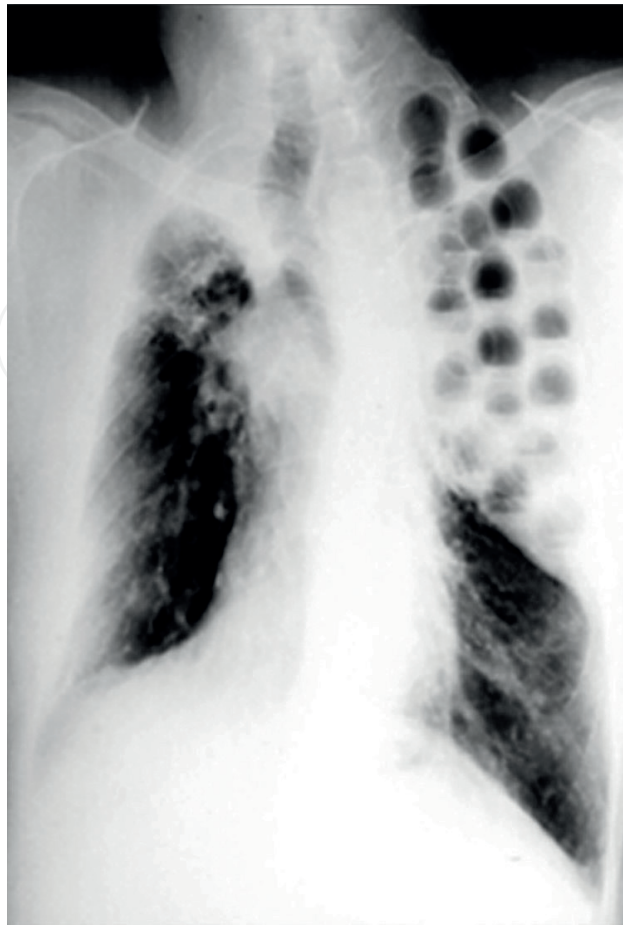


Figure 7. Lucite balls X-ray image.

method was used in the Soviet Union mainly due to the serious problem of pulmonary tuberculosis that they faced in addition to the lack of pleuropulmonary surgeons. Over time, these staplers were used less frequently to perform wedge resection but more often mainly to perform pulmonary resections stapling the bronchus only, to try to solve bronchial fistulas (**Figure 11**).

Pulmonary tuberculosis repeatedly causes pleural effusion due to infected pulmonary peripheral nodules. This situation causes tuberculous empyema and bronchopleural fistula. These patients with tuberculous empyema were handled by Dr. Leo Eloesser through a drainage of the pleural cavity to the outside, communicating the pleural cavity by means of a 2- or 3-cm opening to the outside. This technique facilitated the daily cleaning and healing of the pleural cavity, and due to the symphysis of the pleural leaves, there was no total pulmonary collapse. This surgical technique, called Eloesser, was generally followed by decortication of the pleural cavity and closure, if any, of the air leakage of the lung parenchyma. In the past, Eloesser's surgery in addition to antituberculosis drugs provided good results, and currently Eloesser's method continues to be performed from time to time (**Figures 12 and 13**).

The discovery of streptomycin by Waskman in 1943 was worth the Nobel Prize for Medicine and caused the surgical measures for the treatment of pulmonary tuberculosis to decrease significantly. Streptomycin sulfate is an aminoglycoside that has activity against aerobic gram-negative bacteria such as the tuberculosis bacillus. Streptomycin penetrates the cell

1. Intrapleural pneumothorax	
1882	Forlanini
1898	Murphy
1908	Saugman
1909	Brauer
1912	Jacobeus
2. Phrenic nerve palsy	
1911	Stüertz
1913	Sauerbruch
1920	Felix/Goetze
3. Thoracoplasty	
1907	Friedrich
1911	Wilms
1913	Sauerbruch
1922	Brauer
1925	Alexander
1935	Semb
1954	Björk
4. Extrapleural pneumolysis	
1891	Tuffer
1913	Baer
1936	Graff
5. Pneumoperitoneum	
1933	Banyai
	Klopstoc
	Vajda
1938	Bennet

Table 1. Surgery of pulmonary tuberculosis.

membrane of bacteria, fixes to the ribosome, and therefore does not stop the initiation of protein synthesis in bacteria. Unfortunately, in some cases, it causes renal failure and deafness, and patients receiving this antibiotic must be closely monitored.

3.1. Trachea

Tuberculosis patient's expectoration also affected the trachea producing ulcers and sometimes retraction by proliferation of connective tissue and stenosis. This, at least a 50-year-old

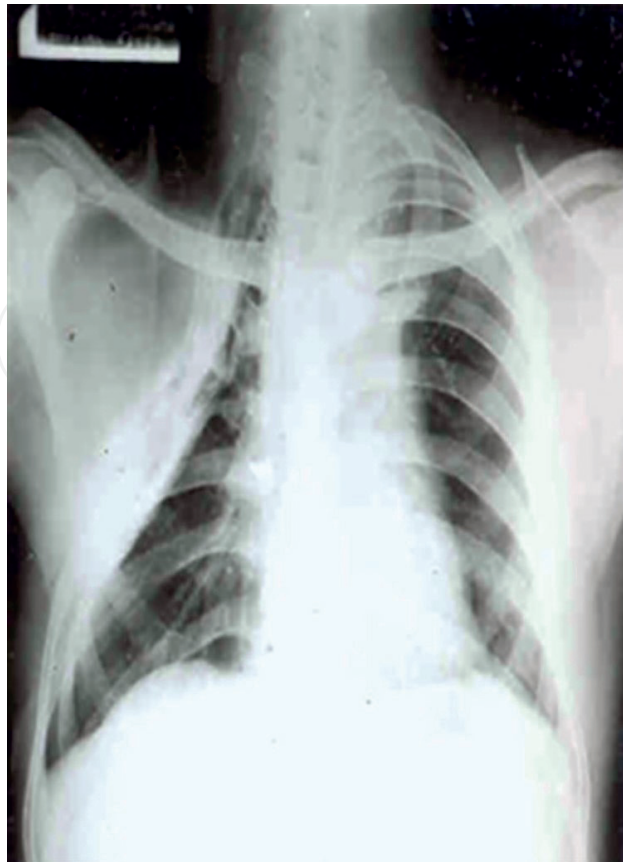

Figure 8. Right thoracoplasty X-ray image.

problem, was a very serious complication without antituberculosis drugs, since morbidity and mortality rates and low-economic income contributed to the failure of its surgical treatment. Dr. Hermes Grillo started tracheal surgery and devised different surgical techniques with good results. A very important contribution for the study of the trachea was made by Dr. Chevalier Jackson (1865–1958) who is considered the father of bronchoscopy and laryngoscopy; he designed rigid bronchoscopes and used them for diagnosis and bronchodilation (**Figure 14**).

Isoniazid was discovered in 1945; this drug inhibits the synthesis of mycolic acid on the wall of the bacteria. On the other hand, parasinosalicylic acid (PAS) is a bacteriostatic of the tuberculous bacillus, which is very useful in inhibiting or retarding bacterial resistance to streptomycin and isoniazid. With isoniazid, streptomycin, PAS, and ethambutol (1961), thoracic surgery decreased due to diminished indications in pulmonary tuberculosis therapies and new drug treatments.

It is impossible to explain and describe the surgical techniques of the past without mentioning some words about pulmonary tuberculosis. Pulmonary tuberculosis was the pathological condition that originated the art of its surgical management.

Currently, the prevalence of tuberculosis patients has decreased significantly, whereas diseases such as cancer, pulmonary fibrosis, and asthma have increased in a high percentage. In the future, chronic-degenerative diseases will dominate respiratory pathology, and so in

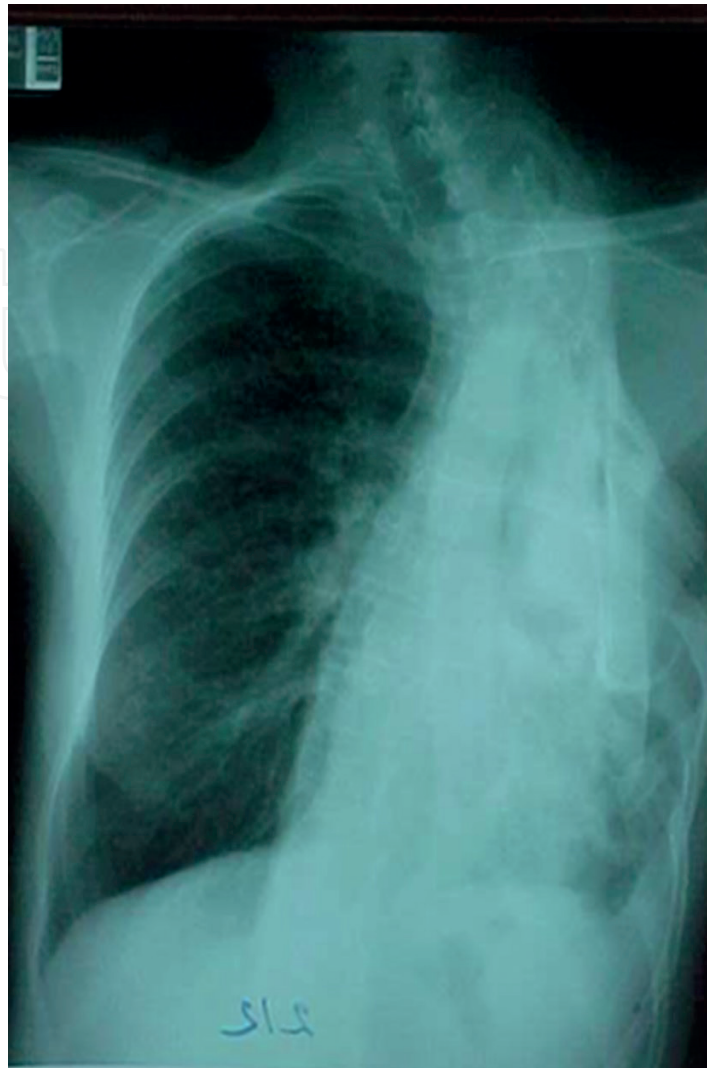


Figure 9. Left thoracoplasty X-ray image.



Figure 10. From right to left: Ismael Cosío Villegas, Leo Eloesser, William B. Neff, and Donato Alarcón at the National Institute of respiratory diseases (NIRD), Mexico City.



Figure 11. Russian stapler.

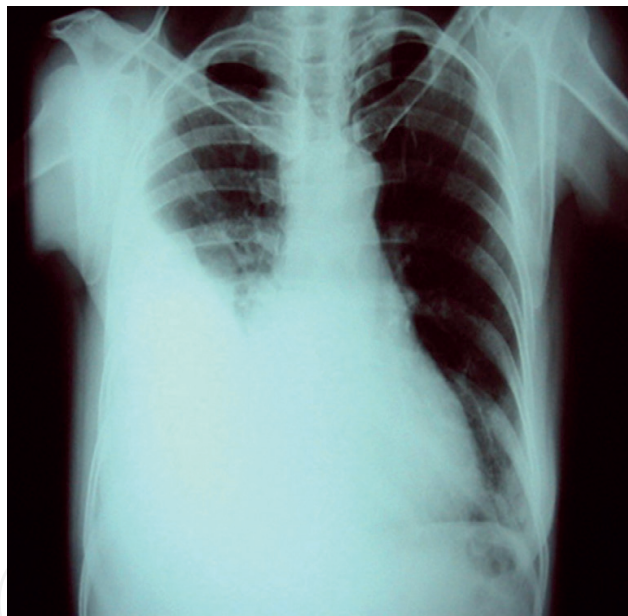


Figure 12. Pleural effusion X-ray image.

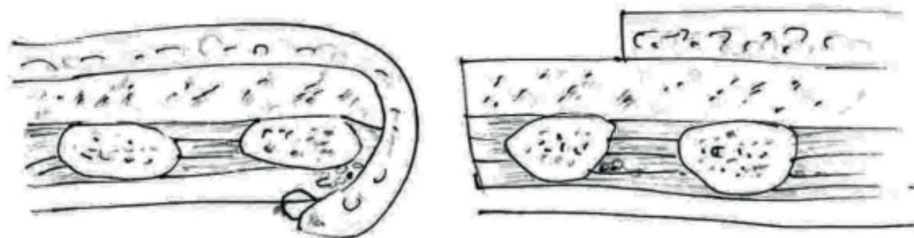


Figure 13. Drainage of the pleural cavity by communicating the pleural cavity to the outside through an incision.

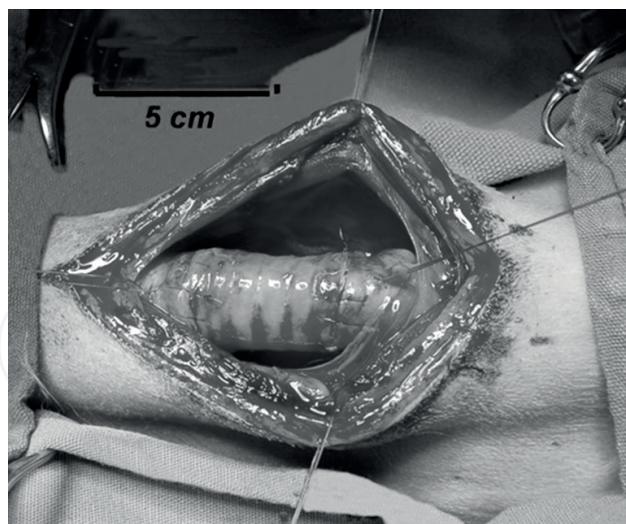


Figure 14. Tracheal surgery.

this section, we must indicate and contraindicate methods such as video-assisted and robotic surgeries.

In addition, although drug administration is not a surgical procedure, the synergy of drugs based on studies of molecular biology for the treatment of chronic-degenerative diseases will be very important.

4. Contraindications of video-thoracoscopic surgery

4.1. Video-assisted surgery/robotic surgery

Currently, there are many surgical subspecialties and technological advances, that is, chest surgery procedures such as pleural decortication, pulmonary resection, endocavitary aspiration, and transbronchial punctures are performed in order to obtain lymph node tissue through video-assisted surgery (Tables 2 and 3) [7].

As of today, the long-distance surgery along with robotic surgery will be preponderant in the future. The large number of subspecialties currently underway should be noted, that is, surgical oncology, interventional bronchoscopy, or cochlear implants and surgeons must become subspecialists with genetic and robotic multitasking.

The medicine of the future plus multiple technological changes will force a student who chooses a medical degree to rely on genomics, molecular biology, epigenetics, computer networks and telecommunications, bioelectronics, artificial intelligence, communication and psycho-medical sciences, treatment techniques, geriatrics, preventive medicine, administration, and health economics and ethics. Likewise, the health professional will need to be competent in selecting worthy information from millions of data published daily. It is also

Advantages	Disadvantages
Lesser traumatic interventions	Difficult access in deep lesions
Better postoperative recovery	Increased possibility of leaving hidden disease
Faster functional recovery	More postoperative follow-up due to increased chance of hidden disease
Better immune response	Greater difficulty in the evaluation of surgical margins.
Quicker reincorporation to full activity	
Lower economic cost	

Table 2. Advantages and disadvantages of video-thoracoscopic surgery [7].

Absolute	Relative
Dense pleural symphysis	Significant hilar lymphadenopathy
Absence of pleural space	Major emphysema
Inability of achieving ipsilateral pulmonary collapse	Nodular lesions less than 1 cm deep
Inability of tolerating monopulmonary ventilation	Tumor size greater than 5 cm
Decompensated cardiovascular disease	Chest wall involvement
Thrombocytopenia of less than 60,000 or INR greater than 20	Serious deformity of the thoracic cage
Inadequate visualization and instrumentation	Radiotherapy or neoadjuvant chemotherapy

Table 3. Contraindications of video-thoracoscopic surgery [7].

important to point out that the knowledge obtained will be added to information in the basic subjects, and both will enable the medical student to prevent some diseases like diabetes. All this accumulation of knowledge will mean that the medicine of the future will be practiced by groups of specialists and subspecialists, as it is already being done in some countries; conceivably, individual practice is going to decrease significantly.

The book of the General Health Council entitled “Futures of the formation of human resources for health in Mexico” by Dr. Enrique Ruelas Barajas, Dr. Antonio Alonso Concheiro, and Guadalupe Alarcón Fuentes has been fundamental to integrate this topic. It includes references from complementary medicine (herbal and acupuncture), which, in some European countries, is already part of the medical profession. Some groups of professionals even include specialists in administration and health economics [8].

Finally, some sensible words about medical ethics must be mentioned: this discipline derived from philosophy has grown in a very important way and is surely going to increase every day, mainly because of the positive complexity of technological development.

In accordance with Louie et al., which report an early experience with robotic lung resection, it resulted in similar outcomes when compared with mature video-assisted thoracoscopic surgery (VATS) cases. However, a potential benefit of robotics may relate to postoperative

pain reduction ($p = 0.039$), and early return to usual activities ($p = 0.001$) was shorter in the robotic group [9].

The Spanish Royal Academy defines a robot as a programmable electronic machine with the capacity to manipulate objects and carry out operations that only the human being is capable of doing. In this regard, it is also known that the word robot derives from the word *robot*, which in Czechoslovakia designates “compulsive work.” These words appeared in the play Rossum’s *Universal Robots* written in 1921 by Karel Čapek, a story about the sudden inability for humans to reproduce and a war between robots and humans [10]. On the other hand, the American Institute of Robotics expresses the following idea of a robot: a machine of human form that performs the tasks of a human being, but without sensitivity. Meanwhile, the University of Nebraska in the United States was one of the earliest institutions to employ distance-assistance methods in the 1950s. It was until 1986 that the first satellite program was launched by the Mayo Clinic in Rochester, Minnesota, and the Scottsdale Clinic in Arizona. These facts gave rise to the era of telemedicine that would later establish the foundation of remote surgery.

The concept of robotic surgery with telepresence was born by the effort and collaboration of the Research Institute of Stanford University, NASA, and the United States Department of Defense to treat wounded soldiers. This technology was initially assigned to the neurosurgeons, and in 1985 the first surgical procedure with a robot was performed with the Mitsubishi system to obtain a brain biopsy through stereotaxy.

In 1988, the PROBOT system was created in England to aid in a transurethral prostatic resection. It consisted of the elaboration of a three-dimensional model of the prostate where the surgeon delineated the limits of the resection and the robot calculated the trajectories of the incisions. In 1992, IBM produced a robot called ROBODOC for orthopedic interventions; the number of surgeries performed by this method increased with hip replacement surgery.

In Mexico City in 1996, two cholecystectomies were operated from a distance of 10 m by a robotic arm with 6° of pronosupination.

In November 2001, a robotic arm was used to assist in a hysterectomy [11].

In 1997, Dr. Garcia Ruiz of Mexico and Dr. Falcone of the Cleveland Clinic performed the first remote robotic surgery that consisted of a tubal reanastomosis. This performance demonstrated the feasibility of making endoscopic sutures, which surgeons said were faster and more accurate. In 1996, at the Mexican Institute of Social Security of Tijuana, doctors Carvajal and Fogel performed a laparoscopic cholecystectomy in porcine models.

In 2001, the Zeus project (a system of robotic instruments) performed hiatus and gall-bladder operations [12].

Unfortunately, the cost of a robot, which is around one million dollars, increases the costs of surgeries. For example, the costs of the Da Vinci system are higher than of a laparoscopy, and some doctors refer to the robot as “expensive toy.”

Hopefully, robot systems will be smaller in the future and, therefore, cheaper.

Swanson et al. [13] compared hospital cost and clinical outcomes for lobectomies by video-assisted thoracic surgery (VATS) and wedge resections versus robot-assisted (RATS) lobectomies. Data from 15,502 surgeries were analyzed. The average cost of inpatient procedures with RATS was \$25,040.70 US DIs versus \$20,476.60 for VATS ($p = 0.0001$) for lobectomies and \$19,592.40 versus \$16,600.10 ($p = 0.0001$) for wedge resections. Inpatient operating times were longer for RATS lobectomy than for VATS lobectomy (4.49 vs. 4.23 h; $p = 0.959$) and wedge resection (3.26 vs. 2.86 h; $p = 0.003$). The length of stay was similar with no differences in adverse events. They concluded that RATS lobectomy and wedge resection seem to have higher hospital cost and longer operating times, without any differences in adverse events.

Resection with robot seems to be an appropriate alternative for VATS and with better results than with an open surgery [14].

“Robotic lobectomy for cancer offers excellent results, with excellent lymph node removal with minimal morbidity, mortality and pain. Despite its costs, it is cost-effective for the hospital system. Disadvantages include capital costs, equipment learning curve, and lack of lung palpation. Robotic surgery is an important tool in the arsenal for the thoracic surgeon, but its precise function continues to evolve” [15].

General thorax surgery was a series of maneuvers especially indicated in pulmonary tuberculosis, so it is not possible to describe a technique without describing the pathology indicated. This treatment was carried out, as has been mentioned before, in the past, because today the drug treatment is very useful in tuberculosis.

Currently, lung cancer, which is the main cause of hospitalization and the invasive methods that apply to this disease, has advanced very importantly as video-assisted surgery and surgery performed with a robot.

Histopathological diagnoses vary in lung cancer. These techniques are being applied for diagnosis, and therefore the treatment is modified. Immunohistochemical techniques help improve and personalize the patient's treatment. For these histological studies, a sample can be taken by video-assisted surgery, and in some pulmonary resections surgery with a robot is practiced. Biopsies taken by VATS are possible in the topographic areas of the thorax, and with robotic surgery it is possible to perform pulmonary excision and, if necessary, pneumonectomy. There is no doubt that with VATS and RATS (robotic surgery), the advance has been of great importance because the incisions are small, and the days of hospital stay also and the costs in the VATS have decreased, but unfortunately this has not been so in the RATS. Undoubtedly, this type of treatment in general chest surgery will change radically because of the important advance that the technology has had. It is currently possible to detect pathology that in previous years was not feasible to diagnose. The latest publications on these topics of surgery describe them favorably and the results on VATS and RATS also; new generations of human resources must be very attentive to technological changes and should be mentally prepared to learn and perform this type of surgery. However, a very important doctors' complaint is the impossibility of palpating some of the pathologies. There is no doubt that this situation will be solved “with a new technology” that tells us the organs' consistency or about hidden ganglia.

According to different opinions from 2020 to 2030, there will be several disciplines that currently do not exist in the curriculum of students due to scientific and technological advances [8].

As I mentioned in the previous lines, surgery and armed interventions have been practiced more in pulmonary tuberculosis in the past and currently in lung cancer and chronic-degenerative conditions.

There is no doubt that knowledge, technology, and the spirit of research have achieved this progress in addition to the progress in basic matters such as molecular biology, epigenetics, immunology, and so on. In brief, there will be further great progress. Many physical examinations can be achieved in lung cancer patients using the mediastinoscope and fibrobronchoscopes. Fortunately, different types of antibodies that are tested for diagnostic purpose have been found and will, surely, have very positive effects.

An example I find very illustrating can be found on page 241 of the book "The Shock of the Future" by Alvin Toffler. The biochemist Marvin Johnson from the University of Wisconsin wrote: "Recently, microorganisms have been domesticated because human did not know its existence" [16]. Currently, human not just knows them but gets many benefits from them, that is, large-scale production of vitamins, enzymes, antibiotics, citric acid, and other useful compounds. In a few years, biologists will create microorganisms to feed animals and ultimately humans.

Acknowledgements

The authors are grateful to Miss María de Lourdes Espinosa Cruz for her invaluable dedication and secretarial assistance as well as to Mr. Manuel Silva Alvarado for the elaboration of the drawings.

Author details

Jaime Villalba Caloca^{1*}, Avelina Sotres Vega¹, Javier Pineda Gutiérrez¹, Sergio Martínez Fonseca¹, Marcelino Alonso Gómez¹ and Bettina Sommer Cervantes²

*Address all correspondence to: jaimevc@iner.gob.mx

1 Experimental Lung Transplantation Research Unit, National Institute of Respiratory Diseases, Mexico City, Mexico

2 Department of Bronchial Hyperreactivity, National Institute of Respiratory Diseases, Mexico City, Mexico

References

- [1] Villalba-Caloca J. Cirugía de tórax en México. *Neumología y Cirugía de Tórax*. 2010;**69**: 46-53

- [2] Cárdenas de la Peña E, editor. Del sanatorio de Huipulco, al Instituto Nacional de Enfermedades Respiratorias cincuenta años. Unique edition. México: INER; 1986. 328 p
- [3] Salazar-Lezama MA, Valdez-Vázquez R, Villareal-Velarde H, Torres-Cruz A, López-Segundo E. In: Cano-Valle F, Ibarra-Pérez C, Morales-Gómez J, editors. Tuberculosis pulmonar. 1st ed. España: Elsevier; 2006. pp. 103-114
- [4] Jiménez M. Nociones de fisiología. Unique ed. Stylo: México; 1954. 673 p
- [5] Monaldi V. Lotta contro la Tuberculosis. 9: No. 9 (Sept), 1938
- [6] Vara-Cuadrado F. Apuntes históricos sobre la cirugía de la tuberculosis pulmonar en el siglo XX. Revista de Patología Respiratoria. 2005;8:3-16
- [7] Gutiérrez E, Ortiz CA, Gómez J, Duitama J, Díaz J, Fernández MR, Field RA, García F, García CC. Situación actual de la cirugía videoasistida. Revista Colombiana de Cirugía. 2013;28:212-222
- [8] Ruelas-Barajas E, Concheiro-Alonso A, Fuentes-Alarcón G, editors. Futuros de la formación de recursos humanos para la salud en México 2005-2050. Consejo de Salubridad General. 1st ed. México: Láser SA de CV; 2005. 85 p
- [9] Louie B, Farivar A, Aye R, Vallières E. Early experience with robotic lung resection results in similar operative outcomes and morbidity when compared with matched video-assisted thoracoscopic surgery cases. The Annals of Thoracic Surgery. 2012;93:1598-1605. DOI: 10.1016/j.athoracsur.2012.01.067
- [10] Zjawinskisonia Zjawinski S. Rossum's universal robots is revived in New York, culture. 07.05.0701:16 pm. <https://www.wired.com/2007/07/rossums-univers/>
- [11] Dueñas-García OF, Rico-Olvera H, Beltrán-Montoya JJ. Telemedicina y cirugía robótica. Ginecología y Obstetricia de México. 2008;76:161-166
- [12] Carbajal-Ramos A. Cirugía Robótica. Cirujano General. 2003;25:314-320
- [13] Swanson S, Miller D, McKenna RJ, Howington J, Marshall BM, Yoo CA, Moore M, Gunnarsson CL, Meyers BF. Comparing robot-assisted thoracic surgical lobectomy with conventional video-assisted thoracic lobectomy and wedge resection: Results from a multihospital database (premier). The Journal of Thoracic and Cardiovascular Surgery. 2014;147:929-937
- [14] Basil S, Bryant A, Minnich D, Wei B, Cerfolio R. Performing robotic lobectomy and segmentectomy: Cost, profitability and outcomes. The Annals of Thoracic Surgery. 2014;98:203-209. DOI: 10.1016/j.athoracsur.2014.02.051
- [15] Kent M, Wang T, Whyte R, Curran T, Flores R, Gangadharan S. Open, video-assisted thoracic surgery and robotic lobectomy: Review of a national database. The Annals of Thoracic Surgery. 2014;97:236-244. DOI: 10.1016/j.athoracsur.2013.07.117
- [16] Toffler A. El shock del futuro, 10th ed. España: Plaza Janes SA; 1979. 241 p

