

We are IntechOpen, the world's leading publisher of Open Access books Built by scientists, for scientists

4,800

Open access books available

122,000

International authors and editors

135M

Downloads

Our authors are among the

154

Countries delivered to

TOP 1%

most cited scientists

12.2%

Contributors from top 500 universities



WEB OF SCIENCE™

Selection of our books indexed in the Book Citation Index
in Web of Science™ Core Collection (BKCI)

Interested in publishing with us?
Contact book.department@intechopen.com

Numbers displayed above are based on latest data collected.
For more information visit www.intechopen.com



Craniocervical Junction Syndrome: Anatomy of the Craniocervical and Atlantoaxial Junctions and the Effect of Misalignment on Cerebrospinal Fluid Flow

Scott Rosa, John W. Baird, David Harshfield and Mahan Chehrena

Additional information is available at the end of the chapter

<http://dx.doi.org/10.5772/intechopen.72890>

Abstract

The craniocervical junction (CCJ) is comprised of the inferior surface of the skull, the atlas and axis, as well as muscles and connective tissues that attach the skull to the cervical spine. The CCJ encloses the central nervous system (CNS), encephalic vasculature and the cerebrospinal fluid (CSF) system. The CCJ spans the brainstem to the spinal cord, including the vascular system as well as connecting the cerebrospinal fluid (CSF) cisterns within the skull to the CSF channels in the spinal canal. Malformation and misalignment of the craniocervical junction can cause a constellation of cerebral and other neurological signs and symptoms collectively called craniocervical syndrome (CCS). The signs and symptoms of craniocervical junction syndrome may be due to mechanical strain causing deformation of dura mater, vasculature and other structures of the cranial vault resulting in irritation of and dysfunction of affected tissues. Deformation of the CCJ may also obstruct blood and CSF flow. Chronic ischemia, edema and hydrocephalus can cause degenerative cascades that can in turn lead to neurodegenerative diseases.

Keywords: craniocervical junction, hydrocephalus, ligament disruption, CSF flow, CSF obstruction, cerebellar tonsillar ectopia, brain stem compression, IGAT, image guided atlas treatment

1. Anatomy of the craniocervical junction

The cervical spine is made up of seven vertebrae divided into upper and lower sections. The upper cervical spine includes the first two vertebrae, classically named atlas (C1) and axis (C2). The CCJ links the skull to the upper cervical spine and therefore the foramen magnum

to the spinal canal. The atlas is essentially a ring of bone formed by two arches that are flanked and joined by the lateral masses, which contain the superior and inferior facets [1].

The transverse processes of the atlas are attached to the lateral masses and contain the intertransverse foramina. The intertransverse foramina of the cervical spine form a flexible protective tunnel for the passage of the vertebral arteries. The alignment of occiput (C0) with the atlas and axis is crucial to the integrity and functional architecture of the spinal cord and mid brain structures [2]. Like the entire spine, this connection is primarily ligamentous and membranous in nature. The atlantoaxial joint (C1–2) is arguably the most unique and complex of all spinal intersegmental relationships. The relative horizontal to biconvex orientation of the opposing weight-bearing facets allows excellent rotation at the expense of osseous stability [3]. The transverse band of the cruciate ligament arises from tubercles on the atlas lateral masses and stretches across and behind the dens of C2 holding the odontoid process (dens) against the anterior arch preventing migration of the dens into the spinal canal [4–6].

The alar ligaments are much larger and stronger than the apical or accessory ligaments. Damage to the alar ligaments can cause joint instability and excess motion [7]. Excess motion can lead to kinking or compression of the vertebral arteries and irritation of nociceptor and mechanoreceptors, which may play a role in symptoms such as headache, neck pain and dizziness associated with head/neck trauma and whiplash-type injuries (**Figure 1**).

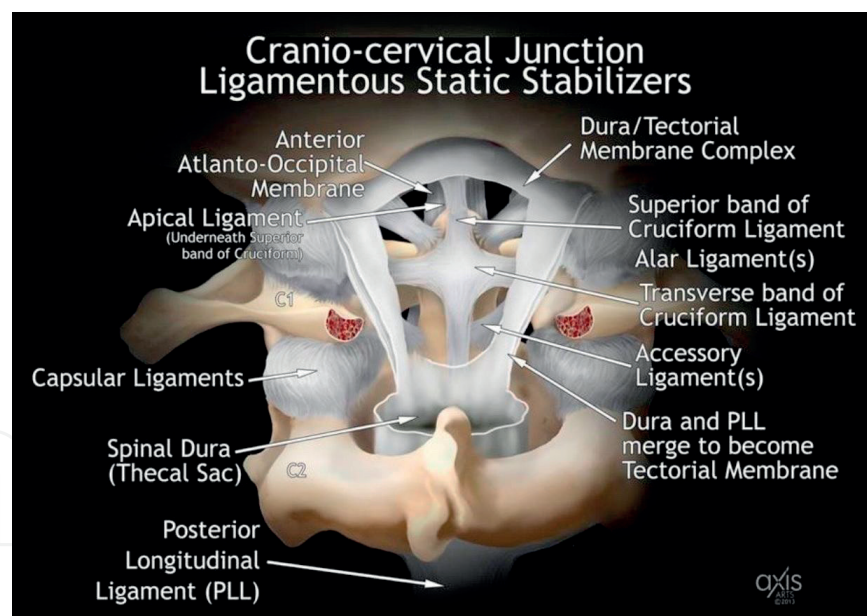


Figure 1. Coronal illustration of the ligamentous stabilizers of the Cranio-cervical junction.

The anterior and posterior spinal longitudinal ligaments (ALL and PLL) are major stabilizers of the anterior and middle columns of the entire spinal axis [8]. The posterior longitudinal ligament transcends into what becomes the anterior dura-mater/tectorial “membrane” complex cephalad to the mid C2 vertebral body (the longitudinal collagenous architecture of the tectorial “membrane” is indistinguishable from the posterior longitudinal “ligament”). The ALL and PLL are two “paired” ligaments known as the suboccipital stabilizers to flexion and extension stress [9, 10]. The capsular ligaments stabilize the facet joints by limiting flexion and rotation (**Figure 2**) [11].

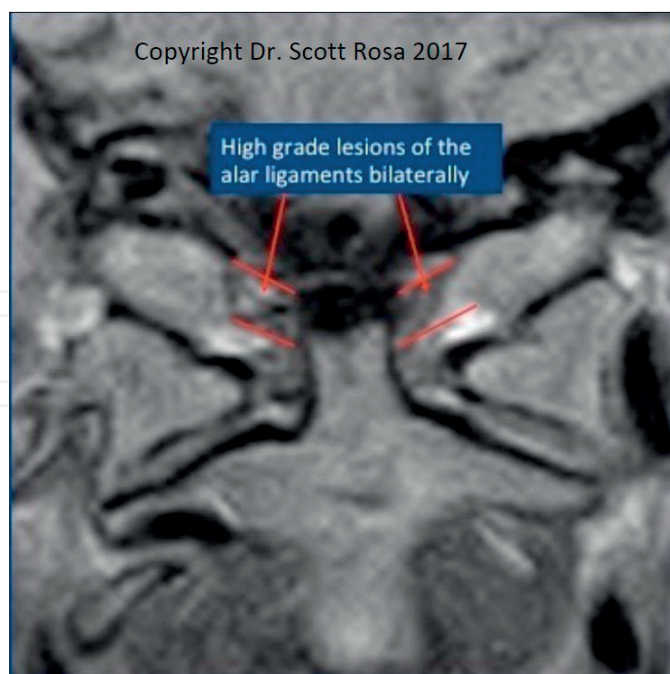

Figure 2. Disruption of the alar ligaments.

The tectorial membrane is a continuation of the posterior longitudinal ligament and ultimately coalesces with the periosteum lining along the anterior margin of the foramen magnum at the basion [6, 12, 13]. The Tectorial Membrane (TM) plays a substantial role in stabilizing the cranio-cervical junction, especially by limiting flexion. During head/neck trauma, hyperextension/hyperflexion and translation take place at the cranio-cervical junction. Hyperflexion alone or combined with anterior translation is the presumed mechanism for injury/damage to the TM (**Figures 3 and 4**) [14].

Grading of ligament disruption is as follows:

1. Partial thinning involving less than 1/3rd the width of the TM (grade I lesion) can represent a normal variant,
2. Lesions involving up to 2/3rd's of the width (grade II) may be seen as a consequence of head/neck trauma and or repetitive micro-stress.
3. Complete absence of or disruption of greater than 2/3rds of the membrane (grade III lesion), accompanied by a normal or partially ruptured dura mater, has not been described in the normal patient population [15].

Weakening and disruption of the key stabilizers of the CCJ can lead to a head forward posture resulting in loss or reversal of the cervical lordosis. This straightening effectively lengthens the spinal canal. The dentate ligaments stabilize the position of the spinal cord in the center of the spinal canal. The spinal cord subsequently can become tethered to each spinal segment by way of the dentate ligaments, and such loss of the cervical lordosis may create traction on the spinal cord resulting in a caudal downward pulling of the brain and cranial elements (brainstem/cerebellar tonsils) downward into the foramen magnum [16, 17]. This can result in

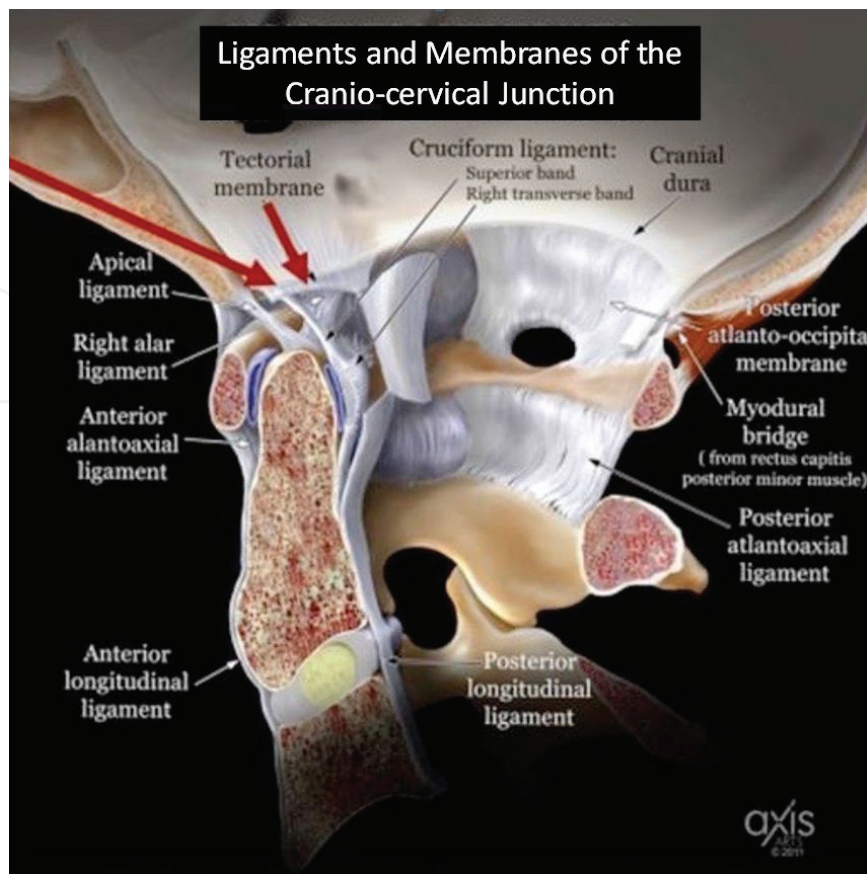


Figure 3. Sagittal illustration of the ligamentous stabilizers of the Cranio-cervical junction.

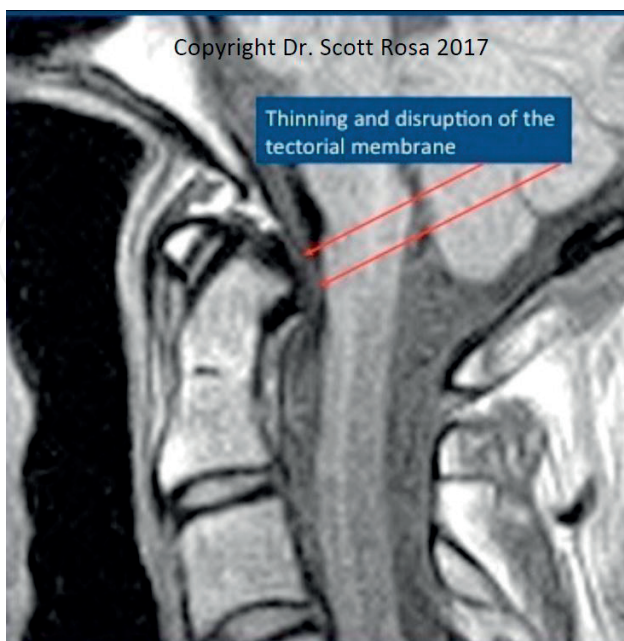


Figure 4. Disruption of the tectorial membrane.

an acquired cerebellar tonsillar ectopia, which can interfere with the cerebral spinal fluid flow of CSF, resulting in a disequilibrium of arterial and venous flow while degrading the nutritive, restorative and support function of the CSF for the central nervous system (**Figure 5**) [18].

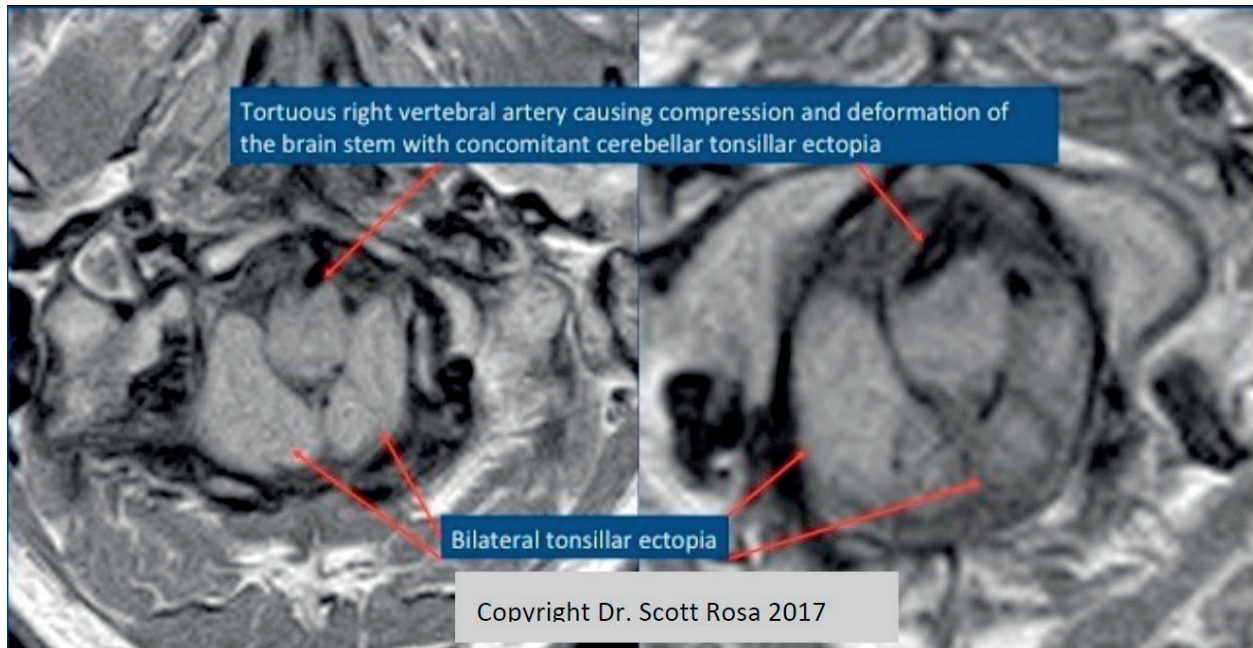


Figure 5. Brain stem compressed by the right vertebral artery. Low cerebellar tonsils.

Rotary misalignments of C1–2 can impair the normal CSF flow as well as contributing to an insufficiency of blood flow of the vertebro-basillar system (**Figure 6**).

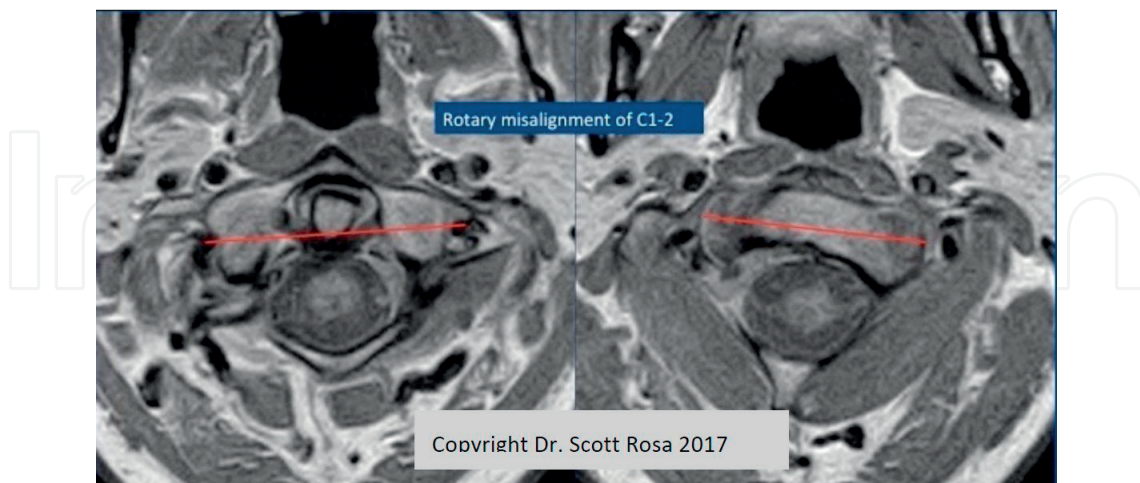


Figure 6. Rotary misalignment of atlas (C1) and axis (C2).

A tortuous vertebral artery may be visible on MRI imaging. Pulsatile compression of the brain stem by the vertebral artery is associated with cerebellar dysfunction, hydrocephalus, ischemic

stroke, transient or permanent motor deficits, central sleep apnea, trigeminal neuralgia, as well as brain stem compression syndrome [19–21].

FONAR upright weight bearing MRI has been shown to be most sensitive in detecting cerebellar tonsillar ectopia since weight-bearing posture presents the cerebellar tonsils further distended into the foramen magnum [18]. Visualization of misalignment of the craniocervical junction and its effects on the nervous system is also demonstrated when images are acquired under the effects of gravity. Imaging of the sagittal, coronal and axial planes ensure a fulsome evaluation of the adequacy of the foramen magnum and provides good sensitivity in the evaluation of the cerebellar tonsils (Figures 7–10).

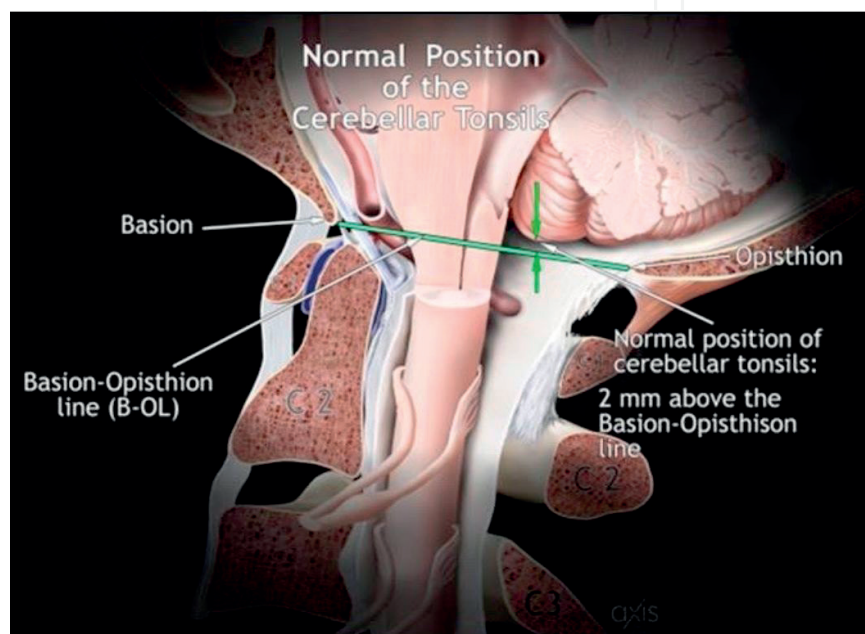


Figure 7. Normal position of cerebellar tonsils.

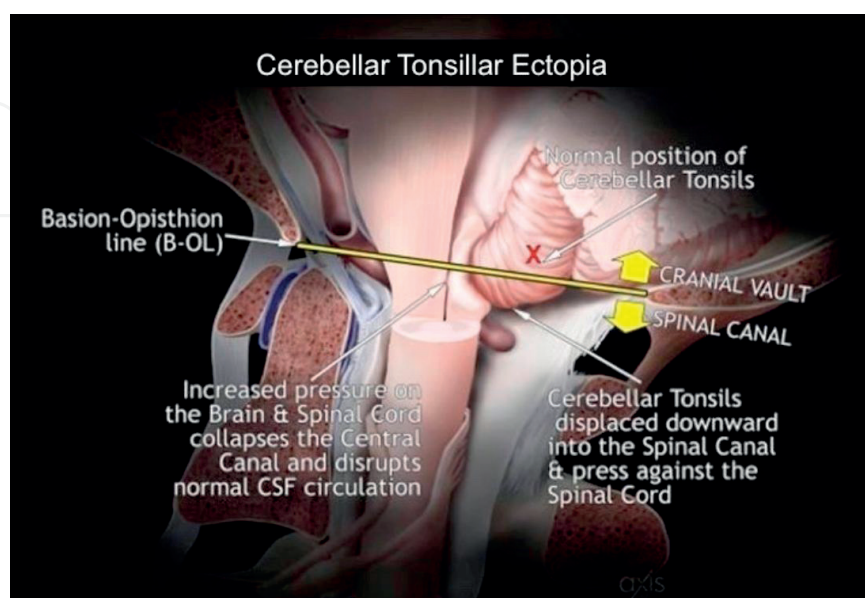


Figure 8. Cerebellar tonsillar ectopia.

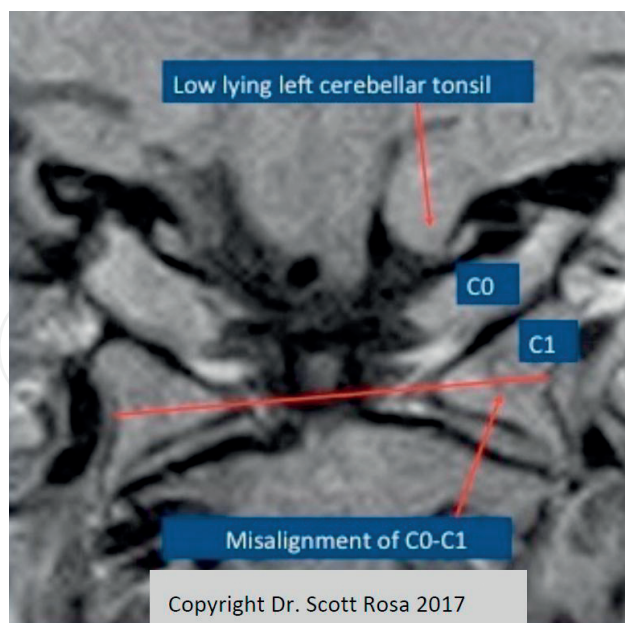


Figure 9. Coronal view demonstrating misalignment of C0-C1 with left cerebellar tonsillar ectopia.

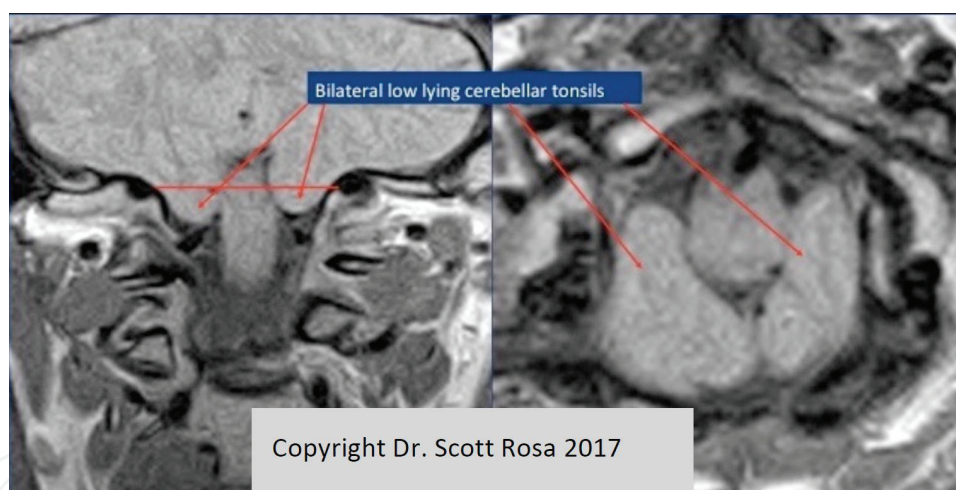


Figure 10. Bilateral cerebellar tonsillar ectopia demonstrated on the coronal view (left) and on the axial view (right).

2. CSF flow

In 1891, Chiari discovered anomalies involving the cerebellar tonsils while performing postmortem examinations on children and adolescents with cerebral hydrocephalus. He recognized that the size of these structural defects in the brain was not related to the severity of the hydrocephalus [18].

The classic definition of Chiari malformation is herniation of the cerebellar tonsils 3 to 5 mm below the foramen magnum. This excess tissue in the upper cervical spinal canal creates pressure and disrupts the flow of cerebrospinal fluid (CSF). Blocked spinal fluid can cause hydrocephalus or, as is more common in Chiari malformation, a fluid-filled cyst known as a syrinx [22].

Spinal integrity may be restored through reduction of misalignments at the cranio-cervical junction. Image Guided Atlas Treatment (IGAT™) has been shown to be effective at restoring CSF flow reducing and reversing the neurodegenerative cascade [23].

Image-Guided Atlas Treatment (IGAT) utilizes dynamic upright MRI imaging sequences in order to permit proper visualization of the CCJ misalignments (**Figure 11**).

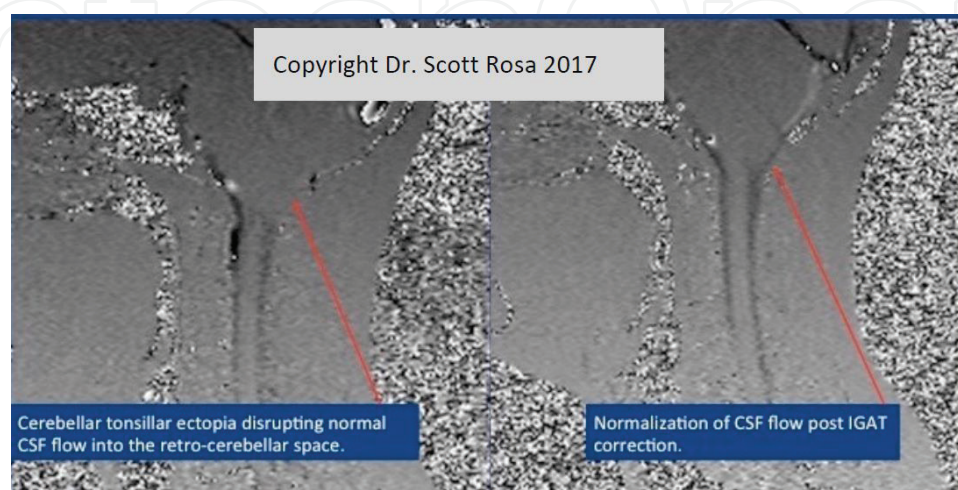


Figure 11. Disruption of CSF flow (left) with restoration of normal flow post IGAT (right) on phase contrast cine CSF flow MR.

Cerebrospinal fluid (when unencumbered) contains low-molecular weight chelating agents that remove metal atoms from the interstitial spaces of the brain and spinal cord, as well as from neurons and glial cell membranes. Abnormal iron deposition is a consequence of the cascade of malevalence associated with cerebellar ectopia induced CSF stasis [24]. What is equally surprising, if not more so, is the fact that ferromagnetic mineral magnetite (Fe_3O_4) crystals are formed biochemically as a manifestation of normal brain tissue metabolism. Parkinson's and Alzheimer's diseases may be induced by toxic build-up of heavy metals within the basal ganglia in the case of Parkinson's, and in the cortical and sub-cortical regions of the brain in the case of Alzheimer's disease (**Figure 12**).

With the cascade of CSF pathophysiology induced by cerebellar tonsillar ectopia, there is compromise of the total encephalic venous outflow due to obstruction of the venous system that cannot be adequately shunted from the cranial vault. Portions of the superficial venous system draining the frontal, parietal, temporal, and occipital lobes are also drained by direct connections into the transverse sinuses and the middle cerebral veins. The inability to redistribute or disperse the obstructed superficial venous outflow results in intracerebral venocongestion, leading to loss of intracerebral compliance thereby decreasing intracerebral blood flow.

Review of available data provides a reasonable model of cerebral venous outflow that, when used in conjunction with our understanding of arterial blood supply and CSF dynamics, may explain much of the pathophysiology of hydrocephalus [25].

Simultaneous obstruction of both the "principal" and "collateral venous outflow" tracts (as an indirect result of cerebellar tonsillar ectopia) can lead to elevated venous pressure and

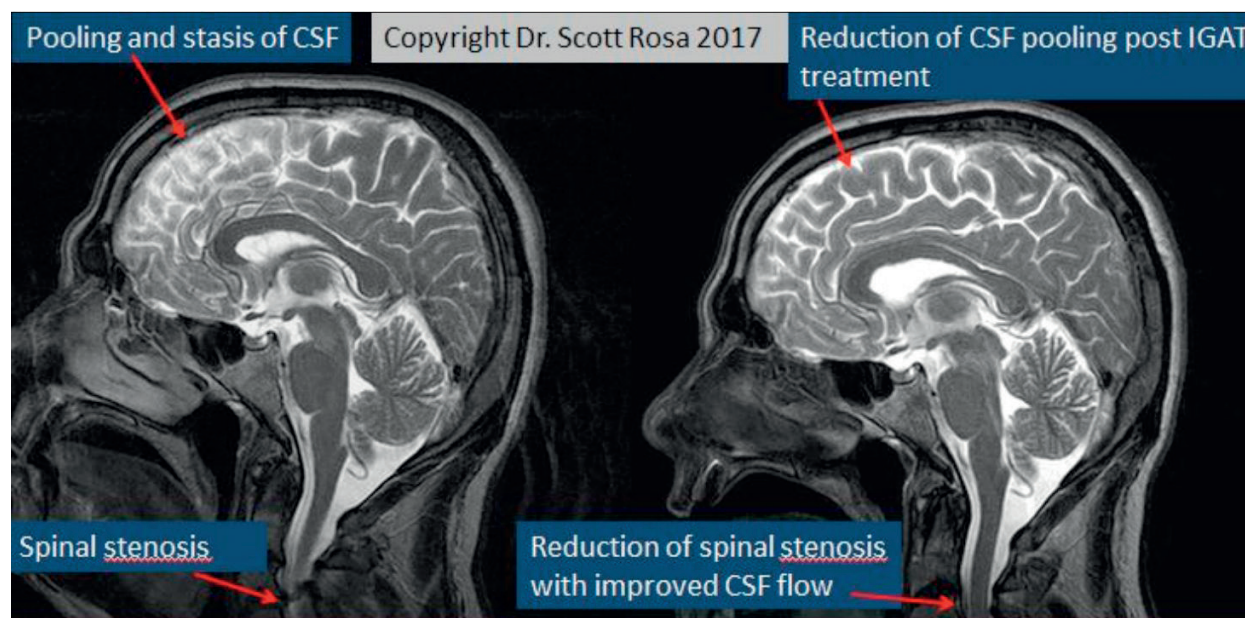


Figure 12. Obstructed effusion of CSF from the cranium may result in pooling and stasis (left). Correction of spinal misalignment results in improved CFS flow (right).

eventually to insufficiency of cerebral blood flow (CBF). With increased intracranial pressure (and decreasing intracranial compliance), ventricular enlargement may occur due to atrophy of the periventricular white matter.

Cerebrospinal fluid shunting (surgically) results in an initial increase in CBF as the essential therapeutic effect in treating patients with hydrocephalus, but ultimately CSF shunting precipitates venocongestive brain edema, which helps explain the reduced ventricular size along with the known side effects of shunting [26].

Upright Ciné MRI of the cranio-cervical junction demonstrates CSF flow dynamics. MRI examination of the brain reveals subtle structural defects in addition to any obvious tonsillar ectopia.

Subtle deformities within the posterior fossa, with or without frank herniation, can be more problematic in their effect on brain function than a large but simple ectopia that leaves room for normal fluid flow. This explains why short, thick cerebellar tonsils that barely plug the foramen magnum can cause a serious impediment, while a longer herniation that is thin or peg-shaped sometimes may cause few problems [27]. The encroachment of the cerebellar vermis and tonsils on the foramen magnum disturbs the CSF flow patterns, thereby precipitating headaches and other neurological symptoms [25–32].

3. Radiological features

Imaging studies of the cranio-cervical junction, particularly standard MRI, lacks sensitivity when viewing the CCJ ligaments for signs of sub-failure. X-ray based imaging (conventional radiographs, fluoroscopy and CT), do not show ligament tears, particularly when chronic scarring replaces the “thickness” of the normal cable-like arrangement of collagen in healthy ligaments [33, 34]. Intraligamentous heme is released when ligaments are torn, creating a

susceptibility artifact, particularly on T2 weighted images, making the torn ligament appear “normal” (uniform, hypointense, “dark” signal with uniform thickness) [35]. With proper MRI sequences, such as “Proton Density” thin section data sets, the “gray” intermediate signal indicative of ligamentous disruption can be contrasted by a background of adjacent “brighter” CSF (versus intermediate signal with T1 weighting) [36].

Standard T1 W and T2 W CCJ MRI protocols with 5- to 7-mm-thick slices are insufficient to demonstrate such membrane/ligament lesions [37]. Sections 2–3 mm thick give adequate spatial resolution with an adequate signal-to-noise ratio. The low membrane/ligament signal afforded by proton density (PD)-weighted images provide better delineation from both CSF and adjacent soft tissues compared to the standard T1- and T2-weighted sequences that typically comprise standard cervical MRI studies [38].

On T1-weighted images, ligaments are not as well defined because a damaged ligament and the surrounding edema/inflammation and adjacent CSF will all be ‘gray’, or intermediate in T1 signal [15]. However, with the PD sequence (especially with fat suppression) the edema/inflammation and CSF become hyperintense (increased in PD signal) while depicting intact ligaments as relatively hypointense (lower) signal. The reason PD-weighted images are not routinely used to replace the standard T1-weighted images (on current C-spine protocols) is that PD can “miss” medullary space lesions [39].

In hyperflexion trauma, all posterior cervical ligaments and membranes are subjected to strain forces. When the atlanto-occipital membrane is stretched beyond its elastic limit, these forces are transmitted to the adjacent dura mater. The rupture of the latter indicates a sprained/injured membrane.

4. Kinematic imaging of the craniocervical junction

The complex nature of the structure and function of the craniocervical junction makes it especially vulnerable to injury and deformation. Forces acting upon the head and cervical spine as occurs in head/neck trauma, may occur in complex patterns [40]. Accordingly, it is important to ensure that complex injuries are properly evaluated and are not overlooked as complex injury scenarios are plausible when trauma occurs to the craniocervical junction [41].

Acknowledgements

The authors would like to acknowledge Dr. Michael Flanagan’s numerous contributions to the literature and his seminal writings on the anatomy of the craniocervical junction and the role of cerebrospinal fluid in brain function and health. <https://uprightdoctor.wordpress.com/about-dr-michael-flanaga/>

Special thanks to Ron Tribell and Axis Medical Illustrations for the illustrations at **Figures 1, 3, 7 and 8.**

Author details

Scott Rosa^{1*}, John W. Baird², David Harshfield³ and Mahan Chehrena⁴

*Address all correspondence to: drscottrosa@hvc.rr.com

1 Private Practice, Rock Hill, NY, USA

2 Private Practice, Markham, ON, Canada

3 Private Practice, Little Rock, AR, USA

4 Private Practice, McLean, VA, USA

References

- [1] Cone RO, Flournoy J, MacPherson R. The craniocervical junction. *Radiographics*. 1981;**1**(2)
- [2] Kao SC, Waziri MH, Smith WL, Sato Y, Yuh WT, Franken EA Jr. MR imaging of the Craniovertebral junction, cranium, and brain in children with Achondroplasia. *American Journal of Roentgenology*. 1989 Sep;**153**(3):565-569
- [3] Clark CR, Ducker TB. Cervical Spine Research Society Editorial Committee. *The Cervical Spine*. 3rd ed. Philadelphia, PA: Lippincott-Raven; 1998. p. 1003
- [4] Penning L, Wilmsink JT. Rotation of the cervical spine: A CT study in normal subjects. *Spine*. 1987;**12**:732-738
- [5] White AA III, Johnson RM, Panjabi MM, Southwick WO. Biomechanical analysis of clinical stability in the cervical spine. *Clinical Orthopaedics*. 1975:85-96
- [6] Bogduk N, Mercer S. Biomechanics of the cervical spine, I: Normal kinematics. *Clinical Biomechanics* (Bristol, Avon). 2000;**15**:633-648
- [7] Dvorak J, Panjabi M, Gerber M, Wichmann W. CT-functional diagnostics of the rotatory instability of upper cervical spine, 1: An experimental study on cadavers. *Spine*. 1987;**12**:197-205
- [8] Monu J, Bohrer SR, Howard G. Some upper cervical spine norms. *Spine*. 1987;**12**:515-519
- [9] Bohrer SR, Chen YM, Sayers DG. Cervical spine flexion patterns. *Skeletal Radiology*. 1990;**19**:521-525
- [10] Davis SJ, Teresi LM, Bradley WG, Ziemba MA, Bloze AE. Cervical spine hyperextension injuries: MR findings. *Radiology*. 1991;**180**:245-251
- [11] Green JD, Harle TS, Harris JH. Anterior subluxation of the cervical spine. *AJNR*. 1981;**2**:243-250

- [12] Tubbs RS, Hallock JD, Radcliff V, et al. Ligaments of the craniocervical junction. *Journal of Neurosurgery. Spine*. 2011;**14**:697-709
- [13] Panjabi M, Dvorak J, Crisco J III, Oda T, Hilibrand A, Grob D. Flexion, extension, and lateral bending of the upper cervical spine in response to alar ligament transections. *Journal of Spinal Disorders*. 1991;**4**:157-167
- [14] Krakenes J, Kaale BR, Moen G, Nordli H, Gilhus NE, Rorvik J. MRI of the tectorial and posterior atlanto-occipital membranes in the late stage of whiplash injury. *Neuroradiology*. 2003;**45**:585-591
- [15] Krakenes J, Kaale BR, Moen G, et al. MRI assessment of the alar ligaments in the late stage of whiplash injury-a study of structural abnormalities and observer agreement. *Neuroradiology*. 2002;**44**:617-624
- [16] Tubbs RS, Salter G, Grabb PA, Oakes WJ. The denticulate ligament: Anatomy and functional significance. *Journal of Neurosurgery*. 2001 Apr;**94**(2 Suppl):271-275
- [17] Grostic JD. Dentate ligament-cord distortion hypothesis. *Chiropr Res J*. 1988;**1**(1):47-55
- [18] Freeman MD, Rosa S, Harshfield D, Smith F, Bennett R, Centeno CJ, Kornel E, Nystrom A, Heffez D, Kohles SS. A case-control study of cerebellar tonsillar ectopia (Chiari) and head/neck trauma (whiplash). *Brain Injury*. 2010;**24**(7-8):988-994
- [19] Ubogu EE, Zaidat OO. Vertebrobasilar dolichoectasia diagnosed by magnetic resonance angiography and risk of stroke and death: A cohort study. *Journal of Neurology, Neurosurgery, and Psychiatry*. 2004;**75**:22-26
- [20] Tomasello F, Alafaci C, Salpietro FM, Longo M. Bulbar compression by an ectatic vertebral artery: A novel neurovascular construct relieved by microsurgical decompression. *Neurosurgery*. 2005;**56**:117-124
- [21] Milandre L, Bonnefoi B, Pestre P, Pellissier JF, Grisoli F, Khalil R. Vertebrobasilar arterial dolichoectasia: Complications and prognosis. *Revue Neurologique (Paris)*. 1991;**147**:714-722
- [22] Chiari Conundrum. *JAMA* (2009-01-14). Chiari conundrum: Researchers tackle a brain puzzle for the 21st century. Rebecca Voelker *JAMA*. 2009;**301**(2):147-149
- [23] Rosa S, Baird JW. *The Craniocervical Junction: Observations Regarding the Relationship between Misalignment, Obstruction of Cerebrospinal Fluid Flow, Cerebellar Tonsillar Ectopia, and Image-Guided Correction*. Basel, Karger: *The Craniocervical Syndrome and MRI*; 2015. pp. 48-66
- [24] Upledger J. The Expanding Role of Cerebrospinal Fluid in Health and Disease. *Cranio-sacrally Speaking Massage Today*; March 2002
- [25] Sakka L, Coll G, Chazal J. Anatomy and physiology of cerebrospinal fluid. *European Annals of Otorhinolaryngology, Head and Neck Diseases*. 2011;**128**:309-316
- [26] Andeweg J. Intracranial venous pressures, hydrocephalus and effects of cerebrospinal fluid shunts. *Child's Nervous System*. October 1989;**5**(5):318-323 (2005), 1-4

- [27] Rogers SJ, Whitehead D. Chiari-1 Malformation. Factsheets for Docs-on-the-go
- [28] Milhorat TH, Chou MW, Trinidad EM, Kula RW, Mandell M, Wolpert C, Speer MC. Chiari I malformation redefined: Clinical and radiographic findings for 364 symptomatic patients. *Neurosurgery*. 1999 May;**44**(5):1005-1017
- [29] William B. Simultaneous cerebral and spinal fluid pressure recordings. 2. Cerebrospinal dissociation with lesions at the foramen magnum. *Acta Neurochirurgica*. 1981;**59**(1-2):123-142
- [30] Williams HA. Unifying hypothesis for hydrocephalus, Chiari malformation, Syringomyelia, anencephaly and Spina bifida. *Cerebrospinal Fluid Research*. 2008
- [31] Kwong Y, Rao N, Latief K. Craniometric measurements in the assessment of Craniovertebral settling: Are they still relevant in the age of cross-sectional imaging? *American Journal of Roentgenology*. 2011;**196**:421-425
- [32] Milhorat TH, Bolognese PA, Nishikawa M, McDonnell NB, Francomano CA. Syndrome of occipitoatlantoaxial hypermobility, cranial settling, and Chiari malformation type I in patients with hereditary disorders of connective tissue. *Journal of Neurosurgery. Spine*. 2007;**7**:601-609
- [33] Myran R, Kvistad KA, Nygaard OP, Andresen H, Folvik M, Zwart JA. Magnetic resonance imaging assessment of the alar ligaments in whiplash injuries. A case-control study. *Spine*. 2008;**33**(18):2012-2016
- [34] Borchgrevink GE, Smevik O, Nordby A, et al. MR imaging and radiography of patients with cervical hyperextension-flexion injuries after car accidents. *Acta Radiologica*. 1995;**36**:425-428
- [35] Ronnen H, de Korte PJ, Brink PRG, et al. Acute whiplash injury: Is there a role for MR imaging? A prospective study of 100 patients. *Radiology*. 1996;**201**:93-96
- [36] Krakenes J, Kaale BR, Rorvik J, et al. MRI assessment of normal ligamentous structures in the craniovertebral junction. *Neuroradiology*. 2001;**43**:1089-1097
- [37] Krakenes J, Kaale BR. MRI assessment of craniovertebral ligaments and membranes after whiplash trauma. *Spine*. 2006;**31**:2820-2826
- [38] Pfirrmann CWA, Binkert CA, Zanetti M, et al. MR morphology of alar ligaments and occipitoatlantoaxial joints: Study in 50 asymptomatic subjects. *Radiology*. 2001;**218**:133-137
- [39] Roy S, Hol PK, Laerum LT, et al. Pitfalls of magnetic resonance imaging of alar ligament. *Neuroradiology*. 2004;**46**:392-398
- [40] Davis JW, Phreaner DL, Hoyt DB, Mackersie RC. The etiology of missed cervical spine injuries. *The Journal of Trauma*. 1993;**34**:342-346
- [41] Swartz EE, Floyd RT, Cendoma M. Cervical spine functional anatomy and the biomechanics of injury due to compressive loading. *Journal of Athletic Training*. 2005;**40**(3):155-161

