

We are IntechOpen, the world's leading publisher of Open Access books Built by scientists, for scientists

4,800

Open access books available

122,000

International authors and editors

135M

Downloads

Our authors are among the

154

Countries delivered to

TOP 1%

most cited scientists

12.2%

Contributors from top 500 universities



WEB OF SCIENCE™

Selection of our books indexed in the Book Citation Index
in Web of Science™ Core Collection (BKCI)

Interested in publishing with us?
Contact book.department@intechopen.com

Numbers displayed above are based on latest data collected.
For more information visit www.intechopen.com



Osteoarthritis of the Temporomandibular Joint: Clinical and Imagenological Diagnosis, Pathogenic Role of the Immuno-Inflammatory Response, and Immunotherapeutic Strategies Based on T Regulatory Lymphocytes

Gustavo Monasterio, Francisca Castillo,
Daniel Betancur, Arnoldo Hernández,
Guillermo Flores, Walter Díaz,
Marcela Hernández and Rolando Vernal

Additional information is available at the end of the chapter

<http://dx.doi.org/10.5772/intechopen.72496>

Abstract

Osteoarthritis is a degenerative disease affecting the TMJ. It is the most common TMJ disorder and shows a higher prevalence in women and older people. TMJ osteoarthritis (TMJ-OA) is characterized by variable degrees of inflammation, destruction of the articular cartilage, and sub-chondral bone resorption. In this context, diverse pro-inflammatory cytokines, chemokines, enzymes, and bone-resorptive associated factors have been considered as possible markers of active TMJ-OA. The molecular balance is determinant not only for initiation and progression, but also for the clinical expression of the disease. Recent advances in the biochemical analysis of synovial fluid from affected patients have provided new insights into the patho-physiology of the TMJ-OA; however, its molecular pathogenesis still remains unclear. Recently, a Th1 and Th17-dominated immune response has been associated with the inflammatory and destructive events characteristic of TMJ-OA and, in particular, the Th17 lymphocyte pathway has a pivotal role in the increased production of RANKL, which is involved in osteoclast activation and subsequent sub-chondral bone resorption. Understanding the TMJ physiology and pathogenesis of the TMJ-OA, together with the key molecular determinants of the TMJ tissue destruction, will enable the development of new chair-side point of care diagnostics and more conservative treatment modalities with minimal complications.

Keywords: osteoarthritis, temporomandibular joint, pathogenesis, diagnosis, immunotherapy, Treg cells

1. Introduction

The temporomandibular joint (TMJ) is the movable articulation of the bone head. Its structure and morphology share common features with other synovial joints; however, it also presents particularities that make it unique. In fact, deep knowledge of the anatomy and function of the TMJ is a central challenge for clinicians and scientists, since many of the pathological conditions that affect this articulation can be explained based on its morphological and physiological aspects.

2. Temporomandibular joint: anatomical characteristics

The TMJ is a synovial joint composed of two articular surfaces [1–4] (**Figure 1**). The inferior articular surface is given by the mandibular articular surface, which is part of the mandibular head. Structurally, the mandibular head is formed by two surfaces, anterior and posterior, both separated by a ridge that follows the same axis of the mandibular head [5–7]. The anterior portion of the mandibular head is relatively convex in contrast with the posterior surface which is characterized for being flat and vertical [7, 8] (**Figure 2**). On the other hand, the superior articular surface of the TMJ is given by the horizontal portion of the squama of the temporal bone, which is organized forming two highly relevant structures: the mandibular fossa and the articular eminence of the temporal, also called temporal condyle [1, 2, 7–11]. The mandibular fossa corresponds to a concave surface with its greater axis in the transverse diameter [2, 7, 8, 12] and the temporal condyle corresponds to a convex bony elevation with its major dimension at the transverse axis, formed by an anterior and posterior surfaces without a clear boundary between the two of them [8, 9, 11]. Additionally, in the TMJ, it is possible

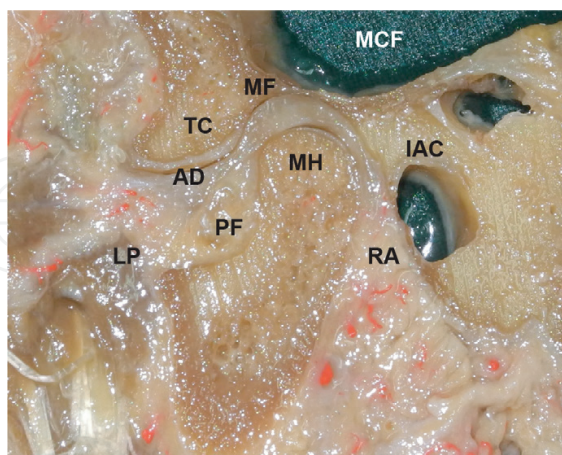


Figure 1. Anatomical characteristics of the temporomandibular joint (TMJ). Sagittal section of TMJ. Mandibular head (MH) articulating with temporal condyle (TC) and mandibular fossa (MF). Between the two joint surfaces the articular disc (AD) is interposed. The middle portion of the thinner disc portion being located in the work area; the anterior articular disc is continuous with the fibers of the lateral pterygoid muscle (LP), which is also inserted into the pterygoid fossa (PF) of the mandibular condyle neck; the back of the disc is related to the vascularized tissue in the retrodiscal area (RA). TMJ localizes superior to the middle cranial fossa (MCF) and posterior to the internal auditory canal (IAC).

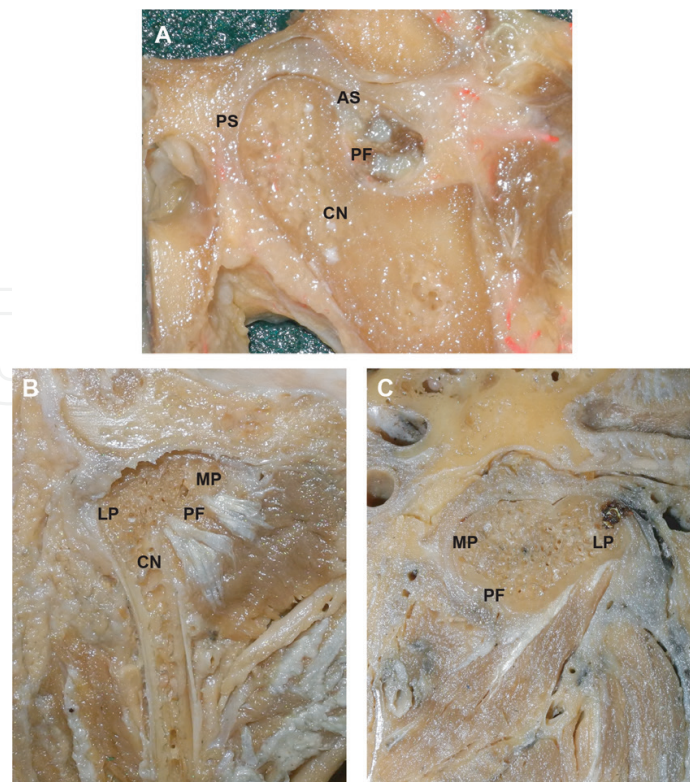


Figure 2. Anatomical characteristics of the temporomandibular joint. (A) Lateral, (B) frontal, and (C) superior view of the mandibular head. This is formed by two poles, the lateral pole (LP) and the medial pole (MP), the latter being larger. In a side view, it is possible to observe the morphology of the anterior surface (AS) (convex) and posterior surface (PS) (flat) of the mandibular head. In the lower portion of the mandibular head at its point of junction with the condylar neck (CN), the pterygoid fossa can be seen (PF), where the lateral pterygoid muscle is inserted.

to observe an articular disc, which allows fitting the temporal condyle and the mandibular head [1, 5]. It is avascular and not innervated at its center, which coincides with the area of greatest work [2, 6, 8, 13]. Like the mandibular fossa and head, its greater dimension is at the transverse axis and adapts closely to the adjacent surfaces [2, 6–8].

3. Temporomandibular joint: physiological characteristics

Mandibular movements are limited by a number of structures, which actively or passively avoid excessive mandibular displacement and consequently limit the movements within the joint. The main protective and customizing element of the joint complex relates to the joint capsule. This structure consists of thick organized bundles of collagen fibers that are upholstered with several proprioceptors that report changes in mandibular dynamics, thereby limiting the mandibular border movements [6]. Anteriorly, the capsule is inserted in the articular eminence [7, 8]. Laterally, the capsule strongly adheres to the longitudinal root of the zygoma and is continued backwards in tympanosquamous fissure [7, 8, 14]. The medial insertion is less extensive, inserted mainly in the sphenoid spine. The inferior insertion of the capsule extends along the condyle neck as a ring that is down on the backside of condylar process neck [7, 8, 14].

There is a set of ligaments that meet a similar role to the capsule, functionally and structurally reinforcing the TMJ [6–8]. The main reinforcement ligament capsule corresponds to temporomandibular ligament which is located lateral to it. From this point of insertion the temporomandibular ligament lateral band descends obliquely and posteriorly, and finally inserts onto the posterior surface of condylar neck [7]. The medial band is horizontal, presenting a similar cranial origin to the lateral band, and is inserted into the lateral side of the mandibular head [11]. Portions of the temporomandibular ligament execute a different role within the mandibular dynamics [6].

Additionally, there are a number of ligaments in the TMJ that are not structural or for its reinforcement, however limit the mandibular dynamics and hence the joint function. The stylo-mandibular, sphenomandibular, pterygomandibular and pterygospinous ligaments meet this role [7, 14]. The stylomandibular ligament is a segment of the muscular structures and it is originated in the styloid process forming the styloid bouquet [7]. Since its origin, the stylomandibular ligament descends obliquely to finally insert on the posterior and inferior border of the ramus. In the case of the sphenomandibular ligament, this appears as a thickening of the interpterygoid fascia, which inserts cranially into the sphenoid spine and in the mandibular lingula [7, 14, 15]. Its thickness and extent varies between the individuals and in its upper portion penetrates into the middle ear throughout the petrotympanic fissure being continued as the anterior ligament of the malleus [10, 16–18]. The pterygomandibular ligament originates from the pterygoid hamulus of the medial lamina of the pterygoid process of the sphenoid bone and from that point is inserted into the lateral lip of the mandibular retromolar trigone [7]. It is inserted in the buccinator muscles anteriorly and the superior constrictor muscle of the pharynx posteriorly. Finally, the pterygoespinous ligament, like the sphenomandibular, corresponds to a thickening of the interpterygoid fascia. It is reported that this ligament may undergo calcifications, which could produce alterations in the transmission of the mandibular nerve, because of its intimate relationship with the mandibular foramen determining nerve compression [19].

4. TMJ-OA: clinical classification and diagnosis

Temporomandibular disorders (TMDs) are the most widely accepted term to designate the musculoskeletal alterations of the TMJs. All TMDs share similar signs and symptoms, traditionally described as a triad of pain (TMJs, muscles, and tooth pain), interferences during mandibular movement (frequently associated with joint noises), and/or movement range limitation [20]. Bell developed the first classification of TMDs in 1986, and it was based on an orthopedic-mechanical model [21]. This classification was composed of four major categories (masticatory pain, restriction of mandibular movements, joint interference during mandibular movements, and acute malocclusion) and identified five muscular processes (myositis, muscle spasm, myofascial pain, late-onset muscle irritation, and protective co-contraction or protective stiffness). However, it was not until 1990 that the American Academy of Craniomandibular Disorders (AACD), along with the International Headache Society (IHS), developed the first taxonomic system of classification [22]. The main contributions were the distinction of two major categories (joint disorders and muscle disorders) and the possibility of establishing multiple diagnoses.

In 1992, a new taxonomic classification system was developed and termed “The Research Diagnostic Criteria for Temporomandibular Disorders (RDC/TMD)” [23]. This system was based on the biopsychosocial model of pain, and included the Axis I (physical assessment using reliable and well-operationalized diagnostic criteria), and Axis II (assessment of psychosocial status and pain-related disability) [23]. The main purpose of this classification system was to establish standardized criteria for research, and to provide simultaneously a physical diagnosis in order to identify other patients’ characteristics that could modify the expression and eventually the management of their TMD [22].

Since 2014, the new DC/TMD Axis I and Axis II provide an evidence-based assessment protocol also based on the biopsychosocial model (**Figure 3**) that can be directly applied in the clinical and research setting [24]. In this consensus, the information required for fulfilling the Axis I diagnostic criteria is obtained from a specified examination protocol in conjunction with the core self-report instruments that assess pain symptoms involving the jaw, jaw noise and locking, and headache. Axis II core assessment instruments assess pain disability, pain intensity, jaw functioning, parafunctional behaviors, psychosocial distress, and widespread pain. All of these incorporations and changes in the core patient assessment instrument set serve as a broad foundation for patient assessment and further research [24].

The DC/TMD also includes changes to original RDC/TMD TMJ diagnoses. An important consideration was the low sensitivity for the diagnostic algorithms for disc displacement (DD) and degenerative joint disease (DJD) (osteoarthritis and osteoarthrosis) in RDC/TMD that can provide only provisional diagnoses [24]. This is due to the fact that some DD with reduction do not have clinically detectable noise, and the disorder will not be diagnosed using the clinical criteria

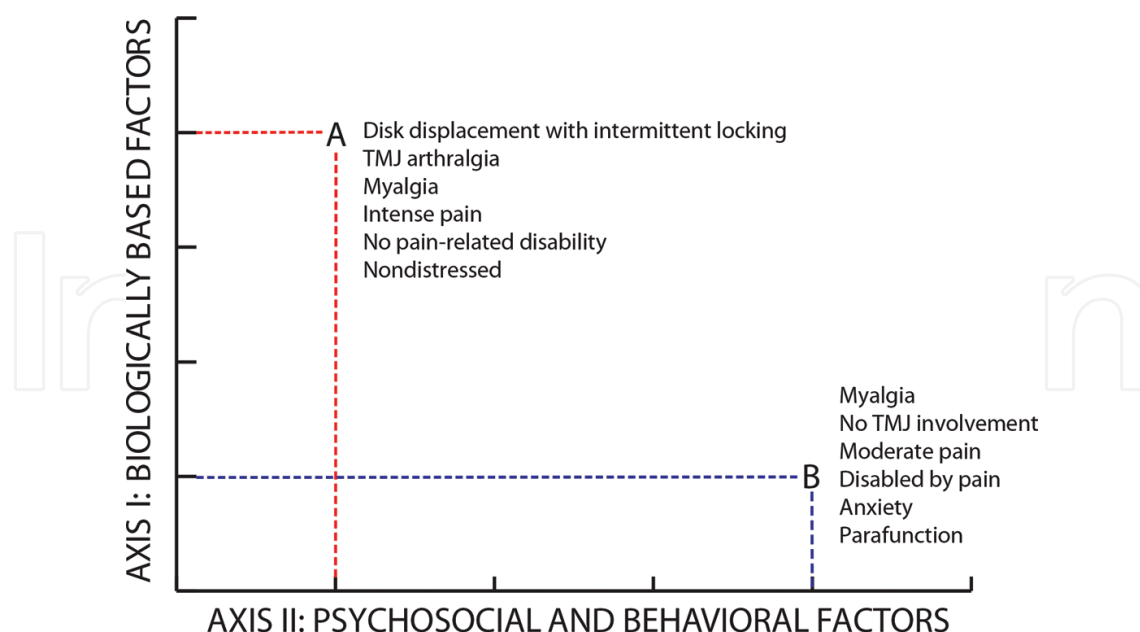


Figure 3. Biopsychosocial model of disease applied to temporomandibular disorders. Axis I refers to the severity of the patient’s biological factors, including physical disorders. Axis II refers to the severity of psychosocial and behavioral factors, including interference in functioning because of pain. Two possible types of patients are depicted, each situated according to disease severity on the respective axes: Patient A has a mechanical temporomandibular joint (TMJ) disorder without secondary factors; and patient B has a pain diagnosis and clinically significant disruption in overall function and mood.

(positive history of noise and the presence of clicking noises) [25]. DD with reduction is highly prevalent, and crescent data suggest that internal derangement, such as DD with reduction, is likely to progress to osteoarthritis [20, 26, 27]. However, based on the evidence, DD with reduction is probably without clinical consequences unless pain occurs with noises or functional limitations, such as limited opening or interference in mastication. Nonetheless, the DC/TMD suggests that imaging using MRI is required for a definitive diagnosis of TMJ DD [24].

The differential diagnosis with the other TTMs is very important in the clinical assessment. The DC/TMD taxonomic classification for TMDs is divided in four major groups: temporomandibular joint disorders, masticatory muscle disorders, headache, and associated structures. Of these, the temporomandibular joint disorders main group includes two subtypes of joint pain, three subtypes of joint disorders, and seven different subtypes of joint disease (**Table 1**). The clinical procedures to evaluate DD with reduction, DD without reduction without limited opening, and DJD lead to clinical diagnoses based on procedures that exhibit low sensitivity but well to excellent specificity. Thus, for treatment decision in selective cases, confirmation of presumptive diagnostic requires imaging. In contrast, clinical algorithm for assessing DD without reduction with limited opening has good sensitivity and specificity (80 and 97%, respectively) [28], being enough with the clinical evaluation for the initial working diagnosis [24].

DC/TMD made some changes to the diagnostic procedures of RDC/TMD for DD and DJD. TMJ noise by history is one of the recommended criteria for the intra-articular disorders of DD with reduction and DJD. The patient's report of any joint noise (click or crepitus) during the 30 days prior to examination should be met by the history criterion or the patient's detection of any joint noise with jaw movements during the clinical examination. Furthermore, DD with reduction diagnosis requires examiner detection of clicking, popping, or snapping noises during examination. In DJD diagnosis requires examiner detection of crepitus (e.g., crunching, grinding, or grating noises) during the examination, and distinction between fines versus coarse crepitus is not necessary. For DD without reduction, the subtype depends on an assisted opening measurement (including the amount of vertical incisal overlap): if is <40 mm it is "with limited opening" subtype, and if is ≥40 mm it is "without limited opening" subtype. In this category, joint noise does not affect the diagnosis of DD without reduction as long as the required criteria for DD without reduction are met (**Table 2**) [24].

The DJD includes osteoarthritis and osteoarthrosis (**Table 1**). While the DD with reduction was described as *"An intracapsular biomechanical disorder involving the condyle-disc complex. In the closed mouth position, the disc is in an anterior position relative to the condylar head and the disc reduces upon opening of the mouth. Medial and lateral displacement of the disc may also be present. Clicking, popping, or snapping noises may occur with disc reduction. A history of prior locking in the closed position coupled with interference in mastication precludes this diagnosis,"* the description given by the DC/TMD to DJD is *"A degenerative disorder involving the joint characterized by deterioration of articular tissue with concomitant osseous changes in the condyle and/or articular eminence"* [24]. The diagnostic criteria for these conditions demand a meticulous anamnesis and clinical examination. The DJD diagnosis is considered positive when either the patient reports any TMJ noise in the last 30 days (during mastication or any jaw movement) or the clinician detects any noise during mandibular movements. In addition, the DJD diagnosis is associated with clinical detection of TMJ crepitus during palpation, when patient is doing opening, closing, lateral, or protrusive mandibular movements. These important differences along exploration

I. Temporomandibular joint disorders
a. Joint Pain
i. Arthralgia
ii. Arthritis
b. Joint Disorders
i. Disc disorders
1. Disc displacement with reduction
2. Disc displacement with reduction with intermittent locking
3. Disc displacement without reduction with limited opening
4. Disc displacement without reduction without limited opening
ii. Hypomobility disorders other than disc disorders
1. Adhesions/adherence
2. Ankylosis
a. Fibrous
b. Osseous
iii. Hypermobility disorders
1. Dislocations
a. Subluxation
b. Luxation
c. Joint diseases
i. Degenerative joint disease
1. Osteoarthrosis
2. Osteoarthritis
ii. Systemic arthritides
iii. Condylitis/idiopathic condylar resorption
iv. Osteochondritis dissecans
v. Osteonecrosis
vi. Neoplasm
vii. Synovial chondromatosis
d. Fractures
e. Congenital/developmental disorders
i. Aplasia
ii. Hypoplasia
iii. Hyperplasia

Table 1. DC/TMD taxonomic classification for temporomandibular disorders (only TMJ disorders).

History
a. In last 30 days, any noise present” applicable to disc displacement with reduction with and without intermittent locking, and degenerative joint disease.
b. In last 30 days, jaw locks with limited mouth opening and then unlocks” applicable to disc displacement with reduction with intermittent locking.
c. “Ever has jaw lock or catch so that it would not open all the way” and “interfered with eating” applicable to disc displacement without reduction with and without limited opening.
d. In last 30 days, when you opened your mouth wide, jaw locked or caught so that it would not close all the way” applicable to subluxation.
Examination
<i>i. Disc displacement with reduction.</i>
1. Report by patient of any joint noise (click or crepitus).
2. Click detection (# of opening/closing cycles required for click) (1 of 3).
3. Click detection during lateral and protrusive movements.
<i>ii. Disc displacement with reduction with intermittent locking.</i>
<i>iii. Disc displacement without reduction with limited opening.</i>
1. Assisted opening* < 40 mm.
<i>iv. Disc displacement without reduction without limited opening.</i>
1. Assisted opening* ≥ 40 mm.
<i>v. Degenerative joint disease.</i>
1. Report by patient of any joint noise (click or crepitus).
2. Crepitus (either fine or coarse) with palpation.
*Measurement of opening includes interincisal opening plus vertical incisal overlap.

Table 2. DC/TMD diagnostic procedures for disc displacements and degenerative joint disease with new history-based diagnosis of subluxation.

were not reported in the RDC/TMD previous consensus, which only included coarse crepitus detected by the examiner’s palpation. Nevertheless, the sensitivity and specificity of these criteria are 55 and 61%, respectively, being the imaging the reference standard for this diagnosis. In particular, the diagnosis confirmation suggest by DC/TMD is with TMJ CT [24].

In summary, the DC/TMD assessment protocol has both screening and confirmatory tests for the most common Axis I physical diagnoses and for Axis II contributing factors (**Table 3**). However, an important remark is the poor diversity of diagnostic tools available until now. The DC/TMD raise a useful systematic imagenological and clinical diagnostic tool, but with no usefulness in the study of disease progression and/or prediction. Several studies suggest some biological markers of degenerative joint disease, such as certain cytokines or proinflammatory mediators [29–42], and could be useful in the elaboration of complementary tools for diagnostic purposes with potential in the study of disease prediction/progression. Thereby, the development of diagnostic/prognostic devices based on these molecular markers is an interesting research field that could significantly improve the precision of osteoarthritis diagnosis.

	Axis I: Physical diagnosis		Axis II: Psychosocial status	
	Pain diagnoses	Joint diagnoses	Distress and pain disability	
Application	Clinical or research		Clinical	Clinical or research
Screening test	TMD pain screener	DC/TMD for disc displacements, degenerative joint disease, and subluxation	PHQ-4 and GCPS	PHQ-9, GAD-7, PHQ-15, and GCPS
Confirmatory test	DC/TMD for myalgia, arthralgia, and headache attributed to TMD	Imaging: MRI for disc displacements, CT for degenerative joint disease, and panoramic radiographs, MRI, or CT for subluxation	Consultation with mental health provider	Structured psychiatric or behavioral medicine interview

Patient Health Questionnaire-4 (PHQ-4), Graded Chronic Pain Scale (GCPS), Patient Health Questionnaire-9 (PHQ-9), Generalized Anxiety Disorder-7 (GAD-7), and Patient Health Questionnaire-15 (PHQ-15).

Table 3. Clinical and research applications of selected DC/TMD Axis I and Axis II tests.

5. TMJ-OA: imagenological characteristics

Computed tomography (CT) and magnetic resonance (MRI) are widely useful tools for imaging the TMJ region of TMD patients, in particular for assessing degenerative bony changes, disc position and configuration, inflammatory pathological changes in the posterior disc attachment, the presence of effusion in joint spaces, and bone marrow edematous involvement [43]. Cone beam computed tomography (CBCT) allows the visualization of the TMJ in all three planes with high resolution, minimal distortion, and great precision for identifying condylar cortical changes [44]. The TMJ imaging by CBCT also allows the evaluation of the integrity of the bony structures when a degenerative disease is suspected, and to confirm the extent and progression of any bony changes [45].

The degenerative changes of bone in DJD are more frequent in the mandibular condyle than in the mandibular fossa or the articular eminence, and the characteristic pathological bony changes are erosion, osteophytes, and deformity; and adaptive bony changes are marginal proliferation, flattening, concavity, sclerosis, and sub-chondral cyst [46–49]. All of these anomalies are considered, for diagnostic purposes, as signs of osteoarthritis and frequently are observed in joints with long-standing DD without reduction [47].

Some imaging technologies such as CT [49–51], CBCT [46, 52, 53], and MR [47, 54–56] have been widely used for diagnosing DJD such as TMJ osteoarthritis. However, is CBCT, a fairly new imaging technology, that has the possibility to create images of high diagnostic quality using lower radiation doses than CT [53]. CBCT imaging has shown to be very helpful for depicting abnormal bony changes such as the cortical margin of the surface and sub-chondral cancellous trabecular structure present in the mandibular condyle, where the conventional radiography has shown difficulties to analyze successfully [30]. Conventional tomography also has difficulties in detailed assessment of changes in the surface morphology of the condyle and fossa, due to the thickness of the slices (1.0–3.0 mm) [57].

Another interesting imaging technique for the diagnosis of TMJ osteoarthritis evaluated in the evidence is the bone scintigraphy [58–61]. This technique shows a correlation with signs and symptoms with very good sensitivity, specificity, and accuracy (100, 90.91, and 96.97%, respectively) [59]. Interestingly, some radiographic changes seen by follow-up CBCT, MRI, and scintigraphy suggested that osteonecrosis may be the initial phase of an osteoarthritic process [30]. Thus, knowing all the potential imaging findings of every imaging modality is very important to make right imaging diagnostics (**Table 4**).

Imaging modality	Imaging findings
Medical CT and cone beam CT	Pathological bony changes such as erosion, osteophyte and deformity Osteochondritis dissecans
Static MR imaging	Disc positional abnormalities (1) DD without reduction (2) DD with reduction (3) Sideways disc displacement Joint effusion presence of marked effusion A higher T2 signal of the posterior disc attachment Bone marrow abnormalities (1) Bone marrow edema (2) Bone marrow osteonecrosis Tumor involvement and inflammatory diseases into the TMJ region and the surrounding structures Autoimmune processes such as rheumatoid arthritis A closer proximity between the TMJ disc and the mandibular nerve
Dynamic MR imaging with contrast material	Prominent contrast enhancement of the posterior disc attachment Contrast enhancement of effusion
Magnetization transfer contrast imaging	Detection for the edematous and ischemic changes in the muscles
Magnetic resonance spectroscopy	Ascending of insular glutamine levels by 1H MRS
Functional MR imaging	The regions and the network of brain activation associated with TMD
Ultrasonography	Muscular edema by low-level contraction
Bone scintigraphy	Detection for early changes on the osseous reaction of OA

TMJ, temporomandibular joint; MM, masticatory muscle; DD, disc displacement; TMD, temporomandibular disorders; OA, osteoarthritis.

Table 4. A rating of the usefulness of each imaging modality related to TMJ pain, MM pain and fatigue.

When the clinical diagnosis of DD with reduction or with reduction with intermittent locking needs imaging confirmation, the DC/TMD suggests positive detection of the following: "(1) in the maximum intercuspal position, the posterior band of the disc is located anterior to the 11:30 position and the intermediate zone of the disc is anterior to the condylar head; and (2) on full opening, the intermediate zone of the disc is located between the condylar head and the articular eminence" [24]. Otherwise, the imaging confirmation criteria by TMJ MRI of DD without reduction with/without limited opening clinical diagnosis are: "(1) in the maximum intercuspal position, the posterior band of the disc is located anterior to the 11:30 position and the intermediate zone of the disc is anterior to the condylar head; and (2) on full opening, the intermediate zone of the disc is located anterior to the condylar head (Note: Maximum assisted opening of < 40 or ≥ 40 mm is determined clinically)" [24].

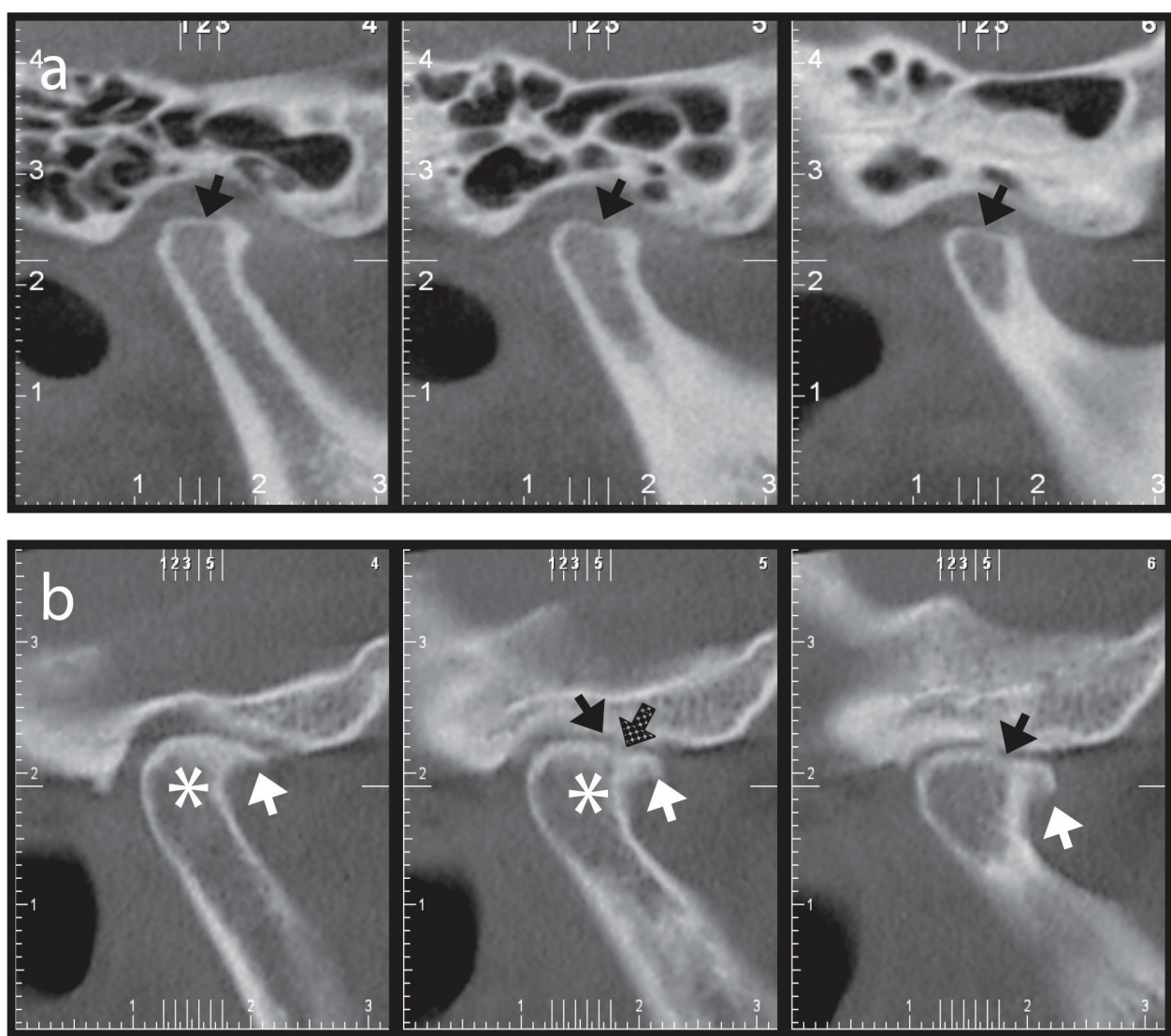


Figure 4. Imagenological characteristics of the temporomandibular joint affected with osteoarthritis. (A) Sagittal CBCT images of a TMJ of a patient with DC/TMD diagnosis of osteoarthritis but without bony osteoarthritic changes (erosions and osteophytes). (B) Sagittal CBCT images of a TMJ of a patient with a DC/TMD diagnosis of osteoarthritis and with bony osteoarthritic changes (erosions and osteophyte). CBCT: Cone beam computed tomography, TMJ: temporomandibular joint, DC/TMD: diagnostic criteria for temporomandibular joint. White arrow: osteophyte; black arrow: flattening; dot pattern arrow: erosion; asterisk: sclerosis.

The DC/TMD criteria consider a positive diagnostic of DJD when the TMJ-CBCT is positive for at least one of the following: sub-chondral cyst(s), erosion(s), generalized sclerosis, or osteophyte(s). An important difference between RDC/TMD and DC/TMD is in flattening and/or cortical sclerosis, because while the first consider as positive findings, the second consider indeterminate findings and possible sign of normal variation, aging, remodeling, or a precursor to frank DJD [24].

The great sensitivity and specificity of TMJ-CBCT in the DJD diagnoses compared with the clinical assessment was well demonstrated in the work of Bakke et al., that shows 21 TMJ-CBCTs positive for osteoarthritis while only two were clinically positive for the disease [62]. The high frequencies of bony changes in the CBCT images of pain-free subjects in this study were in accordance with the findings of Krisjane et al. indicating that radiographic signs of osteoarthritis are a poor indicator of pain [63]. Furthermore, several studies have demonstrated that there is a poor correlation between condylar bony changes including pathological changes, adaptive changes and/or remodeling and pain symptoms in TMJ osteoarthritis [55, 56, 64–66]. These results support the idea that many times the bony changes are not associated with the clinical diagnoses (**Figure 4**), and that good diagnoses comprehend history of the patient, and clinical/imaging diagnostic, although, new assessment tools are necessary for accuracy of the diagnoses.

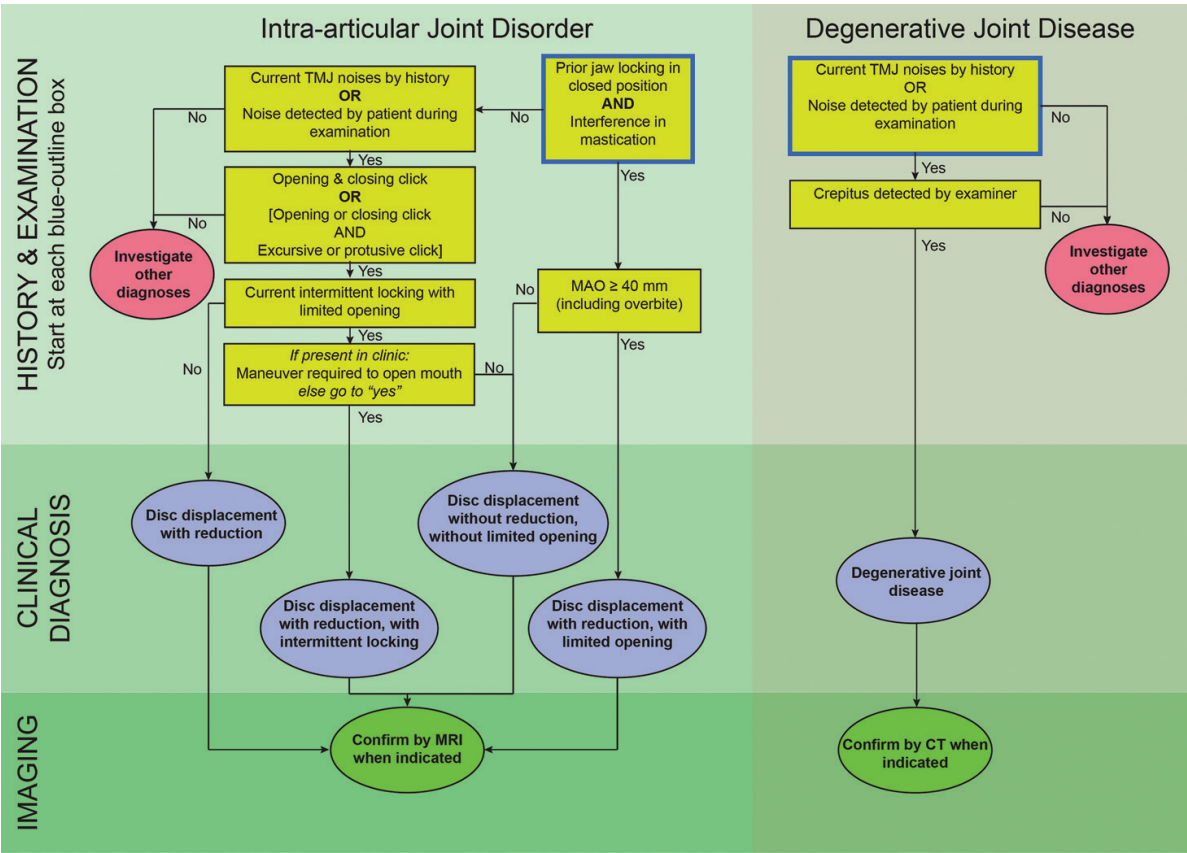


Figure 5. Diagnostic criteria for temporomandibular disorders (DC/TMD): diagnostic decision tree. Schematic diagnostic decision tree made to summarize the algorithm of diagnostic for intra-articular disorders (disc displacement with reduction, disc displacement with reduction with intermittent locking, disc displacement without reduction with limited opening, or disc displacement without reduction without limited opening), or degenerative joint disease (osteoarthritis or osteoarthritis), including history, clinical examination, and imaging.

Finally, **Figure 5** shows the decision tree made in the DC/TMD consensus summarizes the algorithm made for the diagnosis of degenerative joint disease and intra-articular joint disorders with history, clinical, and imagenological features.

6. Role of the immuno-inflammatory response in the pathogenesis of the TMJ-OA

TMJ-OA is a disease having a great deal of variation in progression, symptoms, epidemiology, pathophysiology, and presentation. The rate of progression from a healthy joint to a severe TMJ-OA can vary from weeks to decades and TMJ-OA affects all of the tissues of the joint, including the articular cartilage, synovium, sub-chondral bone, capsule, ligaments, peri-articular muscles, and the sensory nerves innervating the tissues.

Many factors have been proposed as responsible for the TMJ-OA development, such as genetic factors, over-loading, unilateral chewing, bruxism, and internal derangement; however, the molecular basis of the TMJ-OA aetio-pathogenesis remains unclear [67–70].

During TMJ-OA, a complex inflammatory response is developed, involving the synthesis of different cytokines by resident cells (e.g., synovial fibroblast, chondrocytes, and macrophages) and inflammatory cells that infiltrate the joint tissues [71, 72]. This inflammatory response could be triggered as result of the tissue breakdown and the consequent release of damage-associated molecular patterns (DAMPs), such as low molecular weight hyaluronan (LMW-HA), high-mobility group protein 1 (HMGB1), and S100 proteins [73, 74], activating resident inflammatory cells, including dendritic cells and macrophages [75]. At initial stages of the disease, functional overload induces oxidative stress that initiates cartilage disruption [76, 77] and activation of MMPs and aggrecanases, promoting the secretion of DAMPs and the activation of the immune response [75]. During the disease progression, there is a local imbalance between the expression of specific cytokines, their receptors, and regulatory soluble receptors, which may be critical in the biological activity of the cytokine network [35]. Under these conditions, both fibroblast and synovial cells are activated to express MMPs and bone-associated cytokines that control the formation/destruction of articular cartilage and bone, determining the clinical outcome of the OA-TMJ (**Figures 6 and 7**). In fact, higher levels of interleukin (IL)-1 β , IL-6, IL-17, interferon (IFN)- γ , tumor necrosis factor (TNF)- α , prostaglandin E₂ (PGE₂), matrix metalloproteinase (MMP)-2, MMP-9, aggrecanase-1, superoxide dismutase, substance P, and receptor-activator of nuclear factor- κ B ligand (RANKL) have been detected in synovial fluid from TMJ-OA patients as compared with disc displacement with reduction (DDWR), disc displacement without reduction (DDWOR), or healthy subjects **Table 5** [35, 40, 42, 68, 69, 78–86].

Certain cytokines such as IL-1 β , IL-6, and TNF- α has been associated with signs and symptoms of TMJ-OA, in particular, synovitis and arthralgia [39]. In addition, TNF- α and IL-6 have been described as markers of pain and successful clinical outcomes in TMDs [87, 88]. However, a study assessing the relation between the scores from a visual analog scale of pain and the levels of IL-1 β , IL-6, and TNF- α reported no positive correlation [35]. Differences among different studies results could be due to variability in the selection criteria of subjects, sampling techniques, and/or analysis methods.

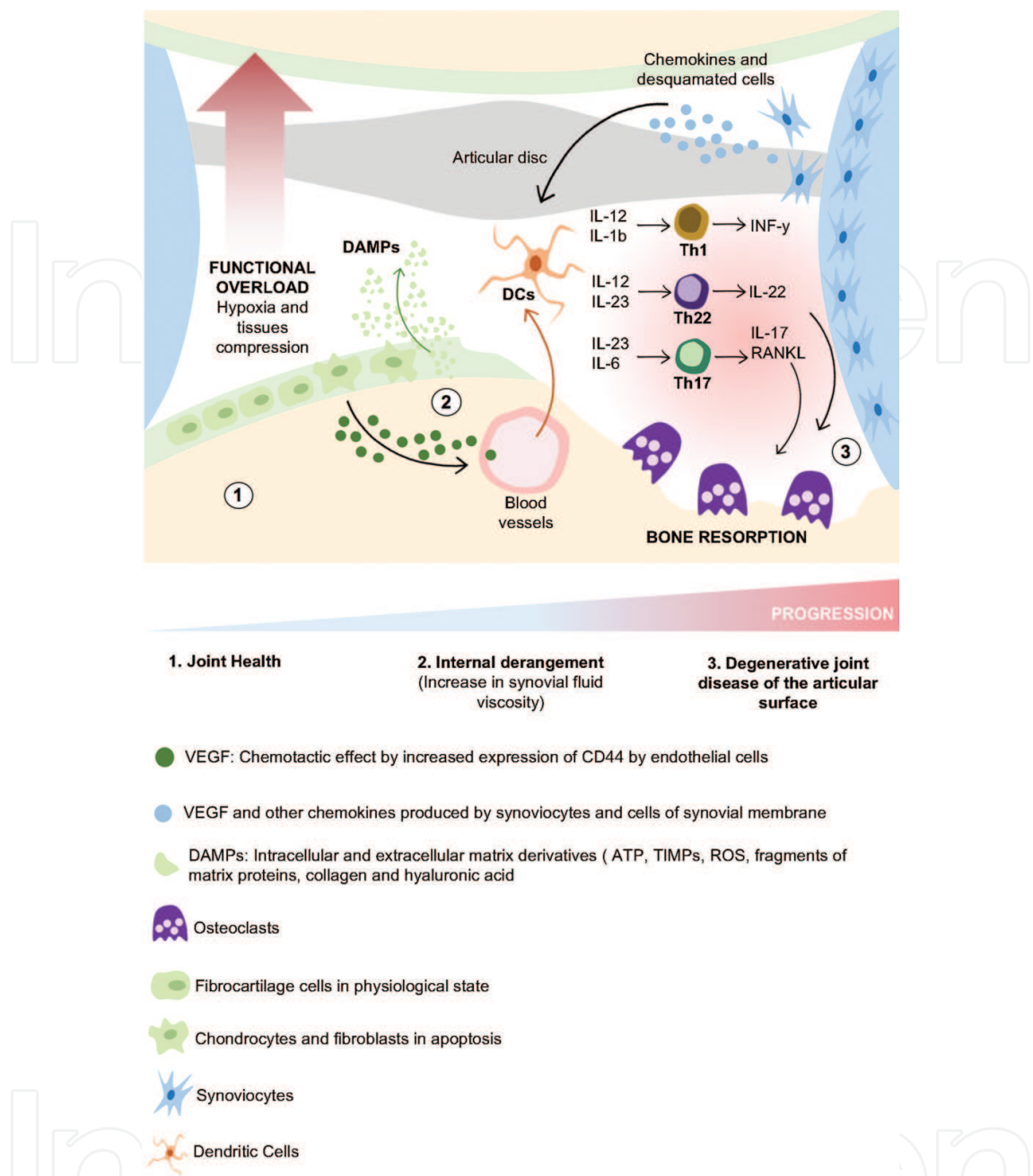


Figure 6. Phases in progression of the degenerative joint disease of the temporomandibular joint. (1) Fibrocartilage and bone tissue in physiological state, (articular disc in correct position). (2) The presence of functional overload or individual susceptibility generates hypoxia and compression of the articular tissues, resulting in apoptosis of chondrocytes and fibroblasts of the fibrocartilage, and DAMP's release, such as ATP, ROS, TIMPs, fragments of collagen and low molecular weight hyaluronic acid. In addition to cytokines and chemokines, these molecules produced by synovocytes allow the migration of immune cells into the joint, such as dendritic cells that generate the environment leading to the polarization of T cell populations towards Th1, Th22, and Th17 phenotypes. These polarized cells in turn will allow the differentiation and activation of osteoclasts that will degrade the articular surface establishing the degenerative and destructive pathology (3).

IL-17 plays a key role in the pathogenesis of rheumatoid arthritis by inducing the synovocyte-dependent IL-6 secretion [89]. In addition, TNF- α and IFN- γ augment the IL-17 activity and IL-17 activity has been associated with synovitis, chondral degradation, and inhibition of chondrocyte proliferation [89]. The presence of IL-17 in the TMJ synovial

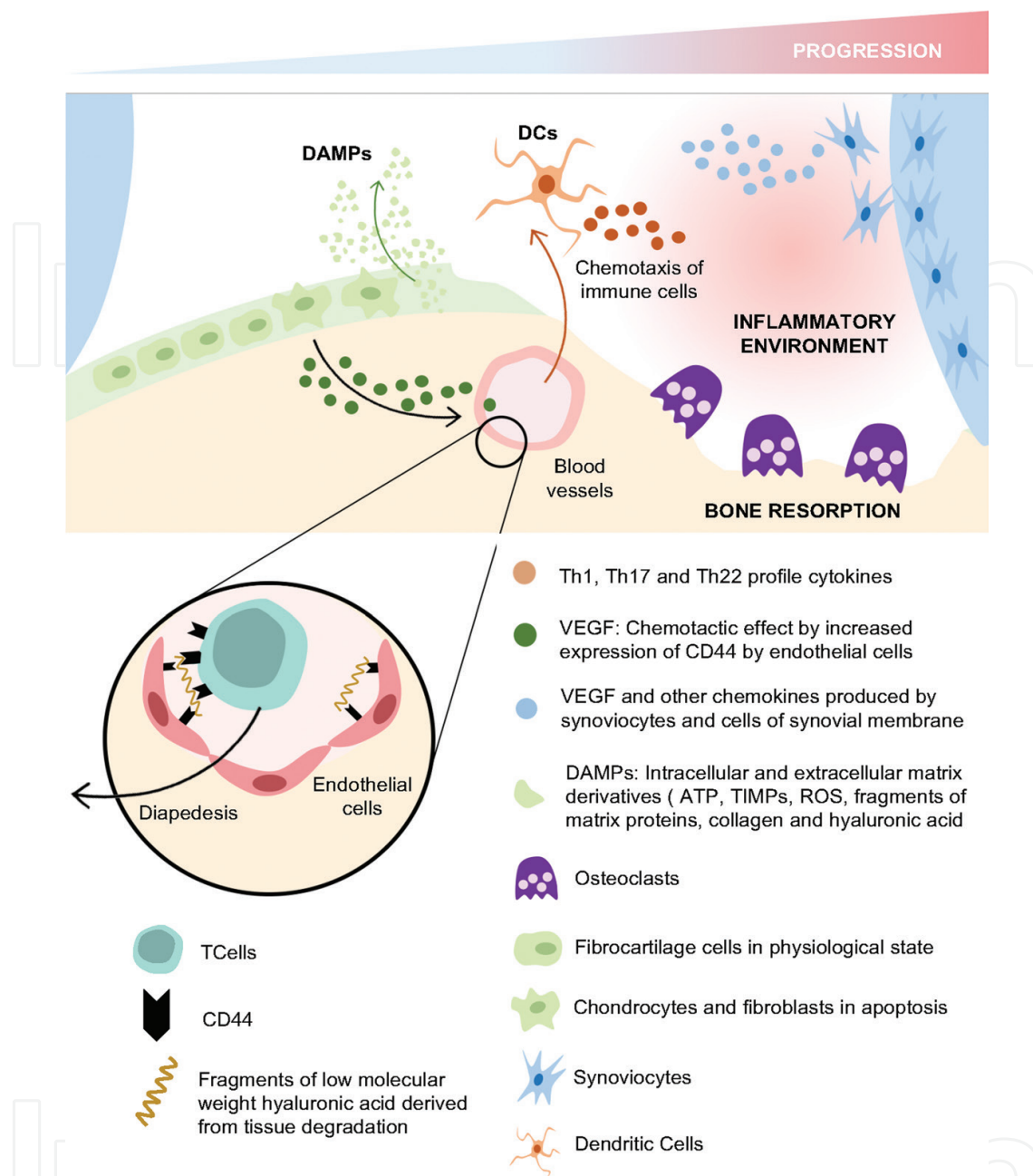


Figure 7. Chemotaxis of immune cells to the subarticular space. Synoviocytes, fibroblasts and chondrocytes produce cytokines, chemokines, intracellular DAMPs, and extracellular matrix derivatives that facilitate the migration of immune cells from the bloodstream into the joint. VEGF and CCL5 facilitate the overexpression of CD44 in endothelial cells and T cells. These molecules, together with low molecular weight hyaluronic acid fragments (sandwich effect), facilitate the diapedesis of lymphocytes through the vessels, enhancing the inflammatory stage of the disease in progress.

fluid could be an important pathophysiological biomarker of TMJ-OA [40]. In fact, bone resorption associated with an increased osteoclast activity is a central phenomenon in the pathophysiology of autoimmune and inflammatory arthritis, and it is also related to IL-17 presence, mainly through T lymphocyte-associated direct and indirect regulation [90, 91]. RANKL is the main molecule involved in the direct regulation of osteoclast activity, through the direct activation of osteoclast precursors [92]. Conversely, the indirect regulation depends on the secretion of IL-17, IL-1 β , and TNF- α by synoviocytes, cytokines that in

Cytokine studied	Authors	Study groups	Measuring technique	Outcomes of study
IL-1 β	Kaneyama et al. [33]	Group 1: DID with clicking. (n = 8) Group 2: DID with locking. (n = 52) Group 3: OA. (n = 57) Group 4: Control. (n = 7)	ELISA	Groups 1, 2 and 3 > Group 4.
	Kaneyama et al. [32]	Group 1: DID (n = 24) Group 2: OA (n = 26) Group 3: Control (n = 5)	ELISA	No differences among the groups.
	Kaneyama et al. [35]	Group 1: Control (n = 5) Group 2: DID (n = 41) Group 3: OA (n = 14)	ELISA	Groups 2, and 3 > Group 1.
	Kubota et al. [36]	Group 1: DID and OA (n = 22)	ELISA	Groups 1 > Group 2.
		Group 2: Control (n = 12)		TMJs with OA > TMJs with DID.
		Group 3: OA of Knee (n = 10)		
	Takahashi et al. [39]	Group 1: DID with clicking (n = 8)	ELISA	IL-1 β presented the higher incidence. Strong correlation between the presence of IL-1 β and TMJ pain in groups 1, 2, and 3.
		Group 2: DID with locking (n = 25)		No cytokines were detected in Group 4.
		Group 3: OA (n = 18)		
		Group 4: Control (n = 6)		
	Vernal et al. [40]	Group 1: OA (n = 12) Group 2: Control (n = 6)	RT-qPCR	Group 1 > Group 2.
TNF- α	Kaneyama et al. [33]	*	ELISA	Groups 1, 2 and 3 > Group 4.
	Kaneyama et al. [32]	*	ELISA	No differences among the groups.
	Kaneyama et al. [35]	*	ELISA	Groups 2, and 3 > Group 1. TNF- α level was positively correlated with those of IL-6, sTNFR-I and sTNFR-II.
	Takahashi et al. [39]	*	ELISA	TNF- α presented the lower incidence. No cytokines were detected in Group 4.
	Vernal et al. [40]	*	RT-qPCR	Group 1 > Group 2.
IL-6	Kaneyama et al. [33]	*	ELISA	Groups 1, 2 and 3 > Group 4.
	Kaneyama et al. [34]	Group 1: Control (n = 7)	ELISA	In groups 2 and 3 was significantly higher in joints with osseous changes in the condyle.
		Group 2: DID (n = 39) Group 3: OA (n = 22)		No cytokines detected in group 1.

Cytokine studied	Authors	Study groups	Measuring technique	Outcomes of study
IL-17	Kubota et al. [36]	*	ELISA	Groups 1 > Group 2. TMJs with OA > TMJs with DID.
	Takahashi et al. [39]	*	ELISA	Group 1, 2 and 3 presented at least 1 of the cytokines in 64.5% of the cases.
	Vernal et al. [40]	*	RT-qPCR	Group 1 > Group 2.
	Kaneyama et al. [34]	*	ELISA	Detection rate of IL-17 was low, and there was no association between the concentration of IL-17 and the presence or absence of osseous changes.
IL-8	Vernal et al. [40]	*	RT-qPCR	Group 1 > Group 2.
	Kaneyama et al. [33]	*	ELISA	Groups 1, 2 and 3 > Group 4.
	Takahashi et al. [39]	*	ELISA	Group 1, 2 and 3 presented at least 1 of the cytokines in 64.5% of the cases.
TGF- β 1	Fang et al. [29]	Group 1: DID (n = 12) Group 2: OA (n = 15) Group 3: Control (n = 4)	ELISA	Group 2 > Group 1.
IL-11	Kaneyama et al. [34]	*	ELISA	In groups 2 and 3 was significantly higher in joints with osseous changes in the condyle.
RANKL	Wakita et al. [42]	Group 1: DID with reduction (n = 25)	ELISA	No significance difference in RANKL concentration between group 4 compared to the rest of groups.
		Group 2: DID without reduction (n = 39)		RANKL/ OPG ratio in group 3 was increased.
		Group 3: OA (n = 53)		
		Group 4: Control (n = 13)		
IL-10	Fang et al. [29]	*	ELISA	Undetectable in all the groups.
OPG	Vernal et al. [40]	*	RT-qPCR	Group 2 > Group 1.
	Kaneyama et al. [32]	*	ELISA	Group 3 > Group 2.
	Wakita et al. [42]	*	ELISA	Group 4 > Groups 1, 2, and 3. RANKL/OPG ratio in group 3 was increased.

Table 5. Molecular mediators proposed as associated with signs and symptoms of TMJ disorders.

turn induce the RANKL expression on synovial fibroblast and osteoblasts [92]. Recently, it has been reported that IL-17, rather than IL-12 or IFN- γ , is critical for the onset of autoimmune arthritis [91, 92]. Thereby, the role of IL-17 in bone metabolism-associated diseases has been extensively defined, and this role is mainly associated with the induction of proinflammatory cytokines, chemokines, and matrix metalloproteinases that leads pathological bone and/or cartilage damage [89, 93, 94].

Our recent data revealed that higher levels of IL-1 β , IL-17, and IL-22, associated with the Th1, Th17, and Th22-pattern of immuno-inflammatory response, were detected in TMJ-OA as compared with DDWR. Increased cytokine levels significantly correlated with an enhancement of RANKL expression and the detection of imagenological signs of articular bone degeneration [95]. IL-22 plays a proinflammatory role through the synergistic activity with IL-1 β and TNF- α [96–98] and IL-22 can indirectly induce osteoclastogenesis and bone resorption by the induction of Th17 lymphocyte activity and IL-17 production [99]. In fact, previous reports have detected over-expressed levels of IL-22 in rheumatoid arthritis synovial fibroblasts, demonstrating a pathogenic role of IL-22 in the rheumatic joint inflammation and destruction through the modulation of the IL-1 β and IL-17R expression [100, 101]. In general terms, we believe that the Th1/Th17/Th22 immuno-inflammatory cell pathways, associated with the production of IL-1 β , IL-17, and IL-22, play a central role in the pathogenesis of the TMJ-OA. Similarly, the role of the Th2/Th9/T regulatory cell pathways, responsible for the production of IL-4, IL-9, and TGF- β 1, respectively, could be associated with TMJ-OA disease healing.

7. Therapeutic potential of T regulatory lymphocytes in TMJ-OA

At the beginning of 1980s, the existence of a suppressor T cell population was proposed, suggesting that these T cells restrict the induction or expression of effector T cells and thereby prevent and control exaggerated immune response and autoimmune disease development [102]. The modern view of suppressor cells began with the observation that the transfer of T cells depleted of the IL-2R α ⁺ (CD25⁺) cell subpopulation induced multiorgan autoimmunity in recipient mice [103]. Nowadays, suppressor T cells have been renamed and are currently known as T regulatory cells (Tregs). These cells have been isolated from mice and humans and their regulatory functions have been demonstrated not only *in vitro* but also *in vivo*. It has also been established that several types of cells carry out regulatory activities. These include IL-10-secreting CD4⁺ T regulatory-1 (Tr1) cells, TGF- β 1-secreting CD4⁺ Th3 cells, NKT cells, CD8⁺CD28⁺Foxp3⁺ cells, γ/δ TCR cells, and CD4⁺CD25^{high}Foxp3⁺ T cells, the last one widely accepted as “professional Tregs” or naturally occurring Tregs [104, 105].

Natural Tregs are CD4⁺ T cells that develop and mature in the thymus carry out their regulatory function during normal surveillance of self-antigens [106]. On normal individuals, they represent 5–10% of the peripheral CD4⁺ T cell population and are characterized by the constitutive expression of high levels of CD25 and low levels of CD45RB [107]. In turn, adaptive Tregs represent CD4⁺ T cells that acquire their regulatory activity during activation [106]. Unlike natural Tregs, which came out from the thymus as CD4⁺CD25⁺ cells, adaptive Tregs originate from peripheral naïve T cells [106]. They are derived from CD4⁺CD25[−] T cells and show variable expression of CD25 during their mature phenotype, depending on the disease and the site of regulatory activity [108] Induced Tregs require TCR stimulation for induction of regulatory functions and have demonstrated limited proliferation *in vitro* [109].

Although induced Tregs and effector Th17 cells play different roles during the immunity, reciprocal developmental pathways have been demonstrated for their generation. Naïve T cells exposed to TGF- β 1 up-regulate Foxp3 and become induced Tregs; however, when cultured with TGF- β 1 and IL-6, naïve T cells generate IL-17 secreting Th17 cells with pathologic activities [110, 111]. Thus, when the immune response is not activated, TGF- β 1 favors the generation of induced Tregs, which suppress inflammation; however, when the inflammatory process is established, IL-6 is synthesized during the innate immune response, inhibiting the generation of Tregs and inducing the differentiation of proinflammatory of Th17 cells in presence of TGF- β 1 [112]. Thus, induced Tregs and Th17 lymphocytes may arise from the same precursor cell and selective differentiation would depend on the local cytokine milieu, which would determine the predominance of either Tregs with suppressor activity or Th17 cells with pathologic activities, determining the outcome of the disease [112].

8. Conclusion

The therapeutic potential of Tregs has created a lot of expectations and a large number of publications have assayed their properties either *in vitro* or in experimental models. Tregs suppress *in vitro* proliferation and cytokine production from co-cultured effector T cells [113]. Tregs suppressed autoimmune diabetes and altered the course of lupus in a TGF- β 1-dependent manner [114]. Additionally, induced Tregs have been successfully used to prevent organ graft rejection [115]. A model of Treg therapy aimed to induce tolerance and restoration of function might show promising results during treatment of TMJ-OA, but additional research is necessary for a better understanding of Treg physiology and to solve several yet unanswered aspects associated to their therapeutic potential in humans.

Author details

Gustavo Monasterio¹, Francisca Castillo¹, Daniel Betancur², Arnoldo Hernández³, Guillermo Flores⁴, Walter Díaz⁴, Marcela Hernández^{1,5} and Rolando Vernal^{1,6*}

*Address all correspondence to: rvernal@uchile.cl

1 Periodontal Biology Laboratory, Faculty of Dentistry, Universidad de Chile, Chile

2 Molecular Immunology Laboratory, Faculty of Biological Sciences, Universidad de Concepción, Chile

3 Anatomy and Biology Program, Faculty of Medicine, Universidad de Chile, Chile

4 Department of Prosthesis, Faculty of Dentistry, Universidad de Chile, Chile

5 Department of Pathology and Oral Medicine, Faculty of Dentistry, Universidad de Chile, Chile

6 Department of Conservative Dentistry, Faculty of Dentistry, Universidad de Chile, Chile

References

- [1] Stankovic S, Vlajkovic S, Boskovic M, Radenkovic G, Antic V, Jevremovic D. Morphological and biomechanical features of the temporomandibular joint disc: An overview of recent findings. *Archives of Oral Biology*. 2013;**58**(10):1475-1482. DOI: 10.1016/j.archoralbio.2013.06.014
- [2] Bag AK, Gaddikeri S, Singhal A, Hardin S, Tran BD, Medina JA, et al. Imaging of the temporomandibular joint: An update. *World Journal of Radiology*. 2014;**6**(8):567-582. DOI: 10.4329/wjr.v6.i8.567
- [3] Siessere S, Vitti M, Semprini M, Regalo SC, Iyomasa MM, Dias FJ, et al. Macroscopic and microscopic aspects of the temporomandibular joint related to its clinical implication. *Micron*. 2008;**39**(7):852-858. DOI: 10.1016/j.micron.2007.12.006
- [4] Kuroda S, Tanimoto K, Izawa T, Fujihara S, Koolstra JH, Tanaka E. Biomechanical and biochemical characteristics of the mandibular condylar cartilage. *Osteoarthritis and Cartilage*. 2009;**17**(11):1408-1415. DOI: 10.1016/j.joca.2009.04.025
- [5] Davies JC, Charles M, Cantelmi D, Liebgott B, Ravichandiran M, Ravichandiran K, et al. Lateral pterygoid muscle: A three-dimensional analysis of neuromuscular partitioning. *Clinical Anatomy*. 2012;**25**(5):576-583. DOI: 10.1002/ca.21298
- [6] Wurgaft RaM MA. Desarrollo y estructura de la articulación temporomandibular. 1st ed. Servimpres Ltda: Santiago, Chile; 2003. DOI: 10.4067/S0717-95022006000300020
- [7] Rouvière HD. A. Anatomía Humana descriptiva, topografica y funcional. 11th ed. Barcelona, España: Editorial Masson; 2005
- [8] Garino F. Anatomía odontológica funcional y aplicada. 2nd ed. Buenos Aires-Argentina, El Ateneo; 2010
- [9] Ilguy D, Ilguy M, Fisekcioglu E, Dolekoglu S, Ersan N. Articular eminence inclination, height, and condyle morphology on cone beam computed tomography. *ScientificWorld Journal*. 2014;**2014**:761714. DOI: 10.1155/2014/761714
- [10] Rodriguez-Vazquez JF, Murakami G, Verdugo-Lopez S, Abe S, Fujimiya M. Closure of the middle ear with special reference to the development of the tegmen tympani of the temporal bone. *Journal of Anatomy*. 2011;**218**(6):690-698. DOI: 10.1111/j.1469-7580.2011.01378.x
- [11] Lang. *Clinical Anatomy of the Masticatory Apparatus and Peripharyngeal Spaces*. Stuttgart: G Thieme Co; 1995
- [12] Arai H, Sato I. Anatomical study of the human discomalleolar ligament using cone beam computed tomography imaging and morphological observations. *Okajimas Folia Anatomica Japonica*. 2011;**88**(3):89-101. DOI: 10.2535/ofaj.88.89
- [13] Asaki S, Sekikawa M, Kim YT. Sensory innervation of temporomandibular joint disk. *Journal of Orthopaedic Surgery (Hong Kong)*. 2006;**14**(1):3-8. DOI: 10.1177/230949900601400102

- [14] Lataryet MRL. A. *Anatomia Humana*. 4th ed. Buenos Aires, Argentina: Ed. Medica Panamericana; 2004
- [15] Shiozaki H, Abe S, Tsumori N, Shiozaki K, Kaneko Y, Ichinohe T. Macroscopic anatomy of the sphenomandibular ligament related to the inferior alveolar nerve block. *Cranio*. 2007;**25**(3):160-165. DOI: 10.1179/crn.2007.025
- [16] Sencimen M, Varol A, Baykal B, Altug HA, Dogan N, Sahin S, et al. Histological characteristics of ligaments between middle ear and temporomandibular joint. *European Journal of Dentistry*. 2009;**3**(4):280-284. DOI: 10.1016/j.bjoms.2009.06.203
- [17] Anagnostopoulou S, Venieratos D, Antonopoulou M. Temporomandibular joint and correlated fissures: Anatomical and clinical consideration. *Cranio*. 2008;**26**(2):88-95. DOI: 10.1179/crn.2008.013
- [18] Monteiro JC, Ennes JP, Zorzatto JR. Ossification of the petrotympanic fissure: Morphological analysis and clinical implications. *Cranio*. 2011;**29**(4):284-290. DOI: 10.1179/crn.2011.042
- [19] Saran RS, Ananthi KS, Subramaniam A, Balaji MT, Vinaitha D, Vaithianathan G. Foramen of civinini: A new anatomical guide for maxillofacial surgeons. *Journal of Clinical and Diagnostic Research*. 2013;**7**(7):1271-1275. DOI: 10.7860/JCDR/2013/5100.3115
- [20] Stegenga B. Osteoarthritis of the temporomandibular joint organ and its relationship to disc displacement. *Journal of Orofacial Pain*. 2001;**15**(3):193-205
- [21] Bell WE. *Temporomandibular Disorders: Classification, Diagnosis, Management*: Year Book Medical; 1986. DOI: 10.1016/0300-5712(88)90071-1
- [22] Poveda Roda R, Bagan JV, Diaz Fernandez JM, Hernandez Bazan S, Jimenez Soriano Y. Review of temporomandibular joint pathology. Part I: Classification, epidemiology and risk factors. *Medicina Oral, Patología Oral y Cirugía Bucal*. 2007;**12**(4):E292-E298
- [23] Dworkin SF, LeResche L. Research diagnostic criteria for temporomandibular disorders: Review, criteria, examinations and specifications, critique. *Journal of Craniomandibular Disorders*. 1992;**6**(4):301-355
- [24] Schiffman E, Ohrbach R, Truelove E, Look J, Anderson G, Goulet JP, et al. Diagnostic criteria for temporomandibular disorders (DC/TMD) for clinical and research applications: Recommendations of the international RDC/TMD consortium network and Orofacial pain special interest Groupdagger. *Journal of Oral & Facial Pain and Headache*. 2014;**28**(1):6-27. DOI: 10.11607/jop.1151
- [25] Okeson JP. Critical commentary 1: Evaluation of the research diagnostic criteria for temporomandibular disorders for the recognition of an anterior disc displacement with reduction. *Journal of Orofacial Pain*. 2009;**23**(4):312-315; author reply 323-314. DOI: 10.1038/sj.bdj.2010.128
- [26] de Leeuw R, Boering G, Stegenga B, de Bont LG. Temporomandibular joint osteoarthritis: Clinical and radiographic characteristics 30 years after nonsurgical treatment: A preliminary report. *Cranio*. 1993;**11**(1):15-24. DOI: 10.1080/08869634.1993.11677936

- [27] Wilkes CH. Internal derangements of the temporomandibular joint. Pathological variations. *Archives of Otolaryngology – Head & Neck Surgery*. 1989;**115**(4):469-477. DOI: 10.1001/archotol.1989.01860280067019
- [28] Schiffman E, Ohrbach R. Executive summary of the diagnostic criteria for temporomandibular disorders for clinical and research applications. *Journal of the American Dental Association (1939)*. 2016;**147**(6):438-445. DOI: 10.1016/j.adaj.2016.01.007
- [29] Fang PK, Ma XC, Ma DL, Fu KY. Determination of interleukin-1 receptor antagonist, interleukin-10, and transforming growth factor- β 1 in synovial fluid aspirates of patients with temporomandibular disorders. *Journal of Oral and Maxillofacial Surgery*. 1999; **57**(8):922-928; discussion 928-929. DOI: 10.1016/s0278-2391(99)90009-5
- [30] KY F, Li YW, Zhang ZK, Ma XC. Osteonecrosis of the mandibular condyle as a precursor to osteoarthritis: A case report. *Oral Surgery, Oral Medicine, Oral Pathology, Oral Radiology, and Endodontics*. 2009;**107**(1):e34-e38. DOI: 10.1016/j.tripleo.2008.09.013
- [31] Herr MM, Fries KM, Upton LG, Edsberg LE. Potential biomarkers of temporomandibular joint disorders. *Journal of Oral and Maxillofacial Surgery*. 2011;**69**(1):41-47. DOI: 10.1016/j.joms.2010.05.013
- [32] Kaneyama K, Segami N, Nishimura M, Sato J, Suzuki T, Fujimura K. Osteoclastogenesis inhibitory factor/osteoprotegerin in synovial fluid from patients with temporomandibular disorders. *International Journal of Oral and Maxillofacial Surgery*. 2003;**32**(4):404-407. DOI: 10.1054/ijom.2002.0363
- [33] Kaneyama K, Segami N, Nishimura M, Suzuki T, Sato J. Importance of proinflammatory cytokines in synovial fluid from 121 joints with temporomandibular disorders. *The British Journal of Oral & Maxillofacial Surgery*. 2002;**40**(5):418-423. DOI: 10.1016/S0266-4356(02)00215-2
- [34] Kaneyama K, Segami N, Sato J, Nishimura M, Yoshimura H. Interleukin-6 family of cytokines as biochemical markers of osseous changes in the temporomandibular joint disorders. *The British Journal of Oral & Maxillofacial Surgery*. 2004;**42**(3):246-250. DOI: 10.1016/S0266-4356(03)00258-4
- [35] Kaneyama K, Segami N, Sun W, Sato J, Fujimura K. Analysis of tumor necrosis factor- α , interleukin-6, interleukin-1 β , soluble tumor necrosis factor receptors I and II, interleukin-6 soluble receptor, interleukin-1 soluble receptor type II, interleukin-1 receptor antagonist, and protein in the synovial fluid of patients with temporomandibular joint disorders. *Oral Surgery, Oral Medicine, Oral Pathology, Oral Radiology, and Endodontics*. 2005;**99**(3):276-284. DOI: 10.1016/j.tripleo.2004.06.074
- [36] Kubota E, Kubota T, Matsumoto J, Shibata T, Murakami KI. Synovial fluid cytokines and proteinases as markers of temporomandibular joint disease. *Journal of Oral and Maxillofacial Surgery*. 1998;**56**(2):192-198. DOI: 10.1016/s0278-2391(98)90868-0
- [37] Lee JK, Cho YS, Song SI. Relationship of synovial tumor necrosis factor α and interleukin 6 to temporomandibular disorder. *Journal of Oral and Maxillofacial Surgery*. 2010;**68**(5):1064-1068. DOI: 10.1016/j.joms.2009.08.007

- [38] Shinoda C, Takaku S. Interleukin-1 β , interleukin-6, and tissue inhibitor of metalloproteinase-1 in the synovial fluid of the temporomandibular joint with respect to cartilage destruction. *Oral Diseases*. 2000;**6**(6):383-390. DOI: 10.1111/j.1601-0825.2000.tb00131.x
- [39] Takahashi T, Kondoh T, Fukuda M, Yamazaki Y, Toyosaki T, Suzuki R. Proinflammatory cytokines detectable in synovial fluids from patients with temporomandibular disorders. *Oral Surgery, Oral Medicine, Oral Pathology, Oral Radiology, and Endodontics*. 1998;**85**(2):135-141. DOI: 10.1016/s1079-2104(98)90415-2
- [40] Vernal R, Velasquez E, Gamonal J, Garcia-Sanz JA, Silva A, Sanz M. Expression of proinflammatory cytokines in osteoarthritis of the temporomandibular joint. *Archives of Oral Biology*. 2008;**53**(10):910-915. DOI: 10.1016/j.archoralbio.2008.04.004
- [41] Wake M, Hamada Y, Kumagai K, Tanaka N, Ikeda Y, Nakatani Y, et al. Up-regulation of interleukin-6 and vascular endothelial growth factor-a in the synovial fluid of temporomandibular joints affected by synovial chondromatosis. *The British Journal of Oral & Maxillofacial Surgery*. 2013;**51**(2):164-169. DOI: 10.1016/j.bjoms.2012.03.004
- [42] Wakita T, Mogi M, Kurita K, Kuzushima M, Togari A. Increase in RANKL:OPG ratio in synovia of patients with temporomandibular joint disorder. *Journal of Dental Research*. 2006;**85**(7):627-632. DOI: 10.1177/154405910608500709
- [43] Suenaga S, Nagayama K, Nagasawa T, Indo H, Majima HJ. The usefulness of diagnostic imaging for the assessment of pain symptoms in temporomandibular disorders. *Japanese Dental Science Review*. 2016;**52**(4):93-106. DOI: 10.1016/j.jdsr.2016.04.004
- [44] Honey OB, Scarfe WC, Hilgers MJ, Klueber K, Silveira AM, Haskell BS, et al. Accuracy of cone-beam computed tomography imaging of the temporomandibular joint: Comparisons with panoramic radiology and linear tomography. *American Journal of Orthodontics and Dentofacial Orthopedics*. 2007;**132**(4):429-438. DOI: 10.1016/j.ajodo.2005.10.032
- [45] Wiese M, Wenzel A, Hintze H, Petersson A, Knutsson K, Bakke M, et al. Influence of cross-sectional temporomandibular joint tomography on diagnosis and management decisions of patients with temporomandibular joint disorders. *Journal of Orofacial Pain*. 2011;**25**(3):223-231
- [46] Talaat W, Al Bayatti S, Al Kawas S. CBCT analysis of bony changes associated with temporomandibular disorders. *Cranio*. 2015:1-7. DOI: 10.1080/08869634.2015.1097323
- [47] Campos MI, Campos PS, Cangussu MC, Guimaraes RC, Line SR. Analysis of magnetic resonance imaging characteristics and pain in temporomandibular joints with and without degenerative changes of the condyle. *International Journal of Oral and Maxillofacial Surgery*. 2008;**37**(6):529-534. DOI: 10.1016/j.ijom.2008.02.011
- [48] Cho BH, Jung YH. Osteoarthritic changes and condylar positioning of the temporomandibular joint in Korean children and adolescents. *Imaging Science in Dentistry*. 2012;**42**(3):169-174. DOI: 10.5624/isd.2012.42.3.169
- [49] Koyama J, Nishiyama H, Hayashi T. Follow-up study of condylar bony changes using helical computed tomography in patients with temporomandibular disorder. *Dento Maxillo Facial Radiology*. 2007;**36**(8):472-477. DOI: 10.1259/dmfr/28078357

- [50] Cevidanes LH, Walker D, Schilling J, Sugai J, Giannobile W, Paniagua B, et al. 3D osteoarthritic changes in TMJ condylar morphology correlates with specific systemic and local biomarkers of disease. *Osteoarthritis and Cartilage*. 2014;**22**(10):1657-1667. DOI: 10.1016/j.joca.2014.06.014
- [51] Lim MJ, Lee JY. Computed tomographic study of the patterns of oosteoarthritic change which occur on the mandibular condyle. *Journal of Cranio-Maxillo-Facial Surgery*. 2014;**42**(8):1897-1902. DOI: 10.1016/j.jcms.2014.07.009
- [52] Cevidanes LH, Hajati AK, Paniagua B, Lim PF, Walker DG, Falconet G, et al. Quantification of condylar resorption in temporomandibular joint osteoarthritis. *Oral Surgery, Oral Medicine, Oral Pathology, Oral Radiology, and Endodontics*. 2010;**110**(1):110-117. DOI: 10.1016/j.tripleo.2010.01.008
- [53] Tsiklakis K, Syriopoulos K, Stamatakis HC. Radiographic examination of the temporomandibular joint using cone beam computed tomography. *Dento Maxillo Facial Radiology*. 2004;**33**(3):196-201. DOI: 10.1259/dmfr/27403192
- [54] Bertram S, Rudisch A, Innerhofer K, Pumpel E, Grubwieser G, Emshoff R. Diagnosing TMJ internal derangement and osteoarthritis with magnetic resonance imaging. *Journal of the American Dental Association (1939)*. 2001;**132**(6):753-761. DOI: 10.14219/jada.archive.2001.0272
- [55] Schmitter M, Essig M, Seneadza V, Balke Z, Schroder J, Rammelsberg P. Prevalence of clinical and radiographic signs of osteoarthrosis of the temporomandibular joint in an older persons community. *Dento Maxillo Facial Radiology*. 2010;**39**(4):231-234. DOI: 10.1259/dmfr/16270943
- [56] Takatsuka S, Yoshida K, Ueki K, Marukawa K, Nakagawa K, Yamamoto E. Disc and condyle translation in patients with temporomandibular disorder. *Oral Surgery, Oral Medicine, Oral Pathology, Oral Radiology, and Endodontics*. 2005;**99**(5):614-621. DOI: 10.1016/j.tripleo.2004.08.024
- [57] Ikeda K, Kawamura A. Assessment of optimal condylar position with limited cone-beam computed tomography. *American Journal of Orthodontics and Dentofacial Orthopedics*. 2009;**135**(4):495-501. DOI: 10.1016/j.ajodo.2007.05.021
- [58] Ahn BC, Kim HJ, Lee SW, Yoo J, Choi JK, Lee J. New quantitative method for bone tracer uptake of temporomandibular joint using Tc-99m MDP skull SPECT. *Annals of Nuclear Medicine*. 2009;**23**(7):651-656. DOI: 10.1007/s12149-009-0287-8
- [59] Coutinho A, Fenyo-Pereira M, Dib LL, Lima EN. The role of SPECT/CT with 99mTc-MDP image fusion to diagnose temporomandibular dysfunction. *Oral Surgery, Oral Medicine, Oral Pathology, Oral Radiology, and Endodontics*. 2006;**101**(2):224-230. DOI: 10.1016/j.tripleo.2005.03.018
- [60] Hersek N, Canay S, Caner B, Ulutuncel N. Bone SPECT imaging of patients with internal derangement of temporomandibular joint before and after splint therapy. *Oral Surgery, Oral Medicine, Oral Pathology, Oral Radiology, and Endodontics*. 2002;**94**(5):576-580. DOI: 10.1067/moe.2002.124855

- [61] Kim JH, Kim YK, Kim SG, Yun PY, Kim JD, Min JH. Effectiveness of bone scans in the diagnosis of osteoarthritis of the temporomandibular joint. *Dento Maxillo Facial Radiology*. 2012;**41**(3):224-229. DOI: 10.1259/dmfr/83814366
- [62] Bakke M, Petersson A, Wiesel M, Svanholt P, Sonnesen L. Bony deviations revealed by cone beam computed tomography of the temporomandibular joint in subjects without ongoing pain. *Journal of Oral & Facial Pain and Headache*. 2014;**28**(4):331-337. DOI: 10.11607/ofph.1255
- [63] Krisjane Z, Urtane I, Krumina G, Neimane L, Ragovska I. The prevalence of TMJ osteoarthritis in asymptomatic patients with dentofacial deformities: A cone-beam CT study. *International Journal of Oral and Maxillofacial Surgery*. 2012;**41**(6):690-695. DOI: 10.1016/j.ijom.2012.03.006
- [64] Ha MH, Kim YI, Park SB, Kim SS, Son WS. Cone-beam computed tomographic evaluation of the condylar remodeling occurring after mandibular set-back by bilateral sagittal split ramus osteotomy and rigid fixation. *Korean Journal of Orthodontics*. 2013;**43**(6):263-270. DOI: 10.4041/kjod.2013.43.6.263
- [65] Honda K, Natsumi Y, Urade M. Correlation between MRI evidence of degenerative condylar surface changes, induction of articular disc displacement and pathological joint sounds in the temporomandibular joint. *Gerodontology*. 2008;**25**(4):251-257. DOI: 10.1111/j.1741-2358.2008.00219.x
- [66] Falconet G, Ludlow JB, Tyndall DA, Lim PF. Correlating cone beam CT results with temporomandibular joint pain of osteoarthritic origin. *Dento Maxillo Facial Radiology*. 2012;**41**(2):126-130. DOI: 10.1259/dmfr/60489374
- [67] Berenbaum F. Osteoarthritis year 2010 in review: Pharmacological therapies. *Osteoarthritis and Cartilage*. 2011;**19**(4):361-365. DOI: 10.1016/j.joca.2011.01.019
- [68] Kellesarian SV, Al-Kheraif AA, Vohra F, Ghanem A, Malmstrom H, Romanos GE, et al. Cytokine profile in the synovial fluid of patients with temporomandibular joint disorders: A systematic review. *Cytokine*. 2016;**77**:98-106. DOI: 10.1016/j.cyto.2015.11.005
- [69] Li C, Long X, Deng M, Li J, Cai H, Meng Q. Osteoarthritic changes after superior and inferior joint space injection of hyaluronic acid for the treatment of temporomandibular joint osteoarthritis with anterior disc displacement without reduction: A cone-beam computed tomographic evaluation. *Journal of Oral and Maxillofacial Surgery*. 2015;**73**(2):232-244. DOI: 10.1016/j.joms.2014.08.034
- [70] Liu F, Steinkeler A. Epidemiology, diagnosis, and treatment of temporomandibular disorders. *Dental Clinics of North America*. 2013;**57**(3):465-479. DOI: 10.1016/j.cden.2013.04.006
- [71] de Bont LG, Boering G, Liem RS, Eulerink F, Westesson PL. Osteoarthritis and internal derangement of the temporomandibular joint: A light microscopic study. *Journal of Oral and Maxillofacial Surgery*. 1986;**44**(8):634-643. DOI: 10.1016/s0278-2391(86)80075-1
- [72] Yamada K, Saito I, Hanada K, Hayashi T. Observation of three cases of temporomandibular joint osteoarthritis and mandibular morphology during adolescence using helical CT. *Journal of Oral Rehabilitation*. 2004;**31**(4):298-305. DOI: 10.1046/j.1365-2842.2003.01246.x

- [73] Foell D, Wittkowski H, Roth J. Mechanisms of disease: A 'DAMP' view of inflammatory arthritis. *Nature Clinical Practice. Rheumatology*. 2007;**3**(7):382-390. DOI: 10.1038/ncprheum0531
- [74] Jiang W, Pisetsky DS. Mechanisms of disease: The role of high-mobility group protein 1 in the pathogenesis of inflammatory arthritis. *Nature Clinical Practice. Rheumatology*. 2007;**3**(1):52-58. DOI: 10.1038/ncprheum0379
- [75] Nefla M, Holzinger D, Berenbaum F, Jacques C. The danger from within: Alarmins in arthritis. *Nature Reviews Rheumatology*. 2016;**12**(11):669-683. DOI: 10.1038/nrrheum.2016.162
- [76] Milam SB, Zardeneta G, Schmitz JP. Oxidative stress and degenerative temporomandibular joint disease: A proposed hypothesis. *Journal of Oral and Maxillofacial Surgery*. 1998;**56**(2):214-223
- [77] Kawai Y, Kubota E. Oxidative stress and temporomandibular joint disorders. *Japanese Dental Science Review*. 2008;**44**(2):145-150
- [78] Guo H, Fang W, Li Y, Ke J, Deng M, Meng Q, et al. Up-regulation of proteoglycan 4 in temporomandibular osteoarthritic synovial cells by hyaluronic acid. *Journal of Oral Pathology & Medicine*. 2015;**44**(8):622-627. DOI: 10.1111/jop.12273
- [79] Lim WH, Toothman J, Miller JH, Tallents RH, Brouxhon SM, Olschowka ME, et al. IL-1 β inhibits TGF β in the temporomandibular joint. *Journal of Dental Research*. 2009;**88**(6):557-562. DOI: 10.1177/0022034509336823
- [80] Long E, Motwani R, Reece D, Pettit N, Hepworth J, Wong P, et al. The role of TGF- β 1 in osteoarthritis of the temporomandibular joint in two genetic mouse models. *Archives of Oral Biology*. 2016;**67**:68-73. DOI: 10.1016/j.archoralbio.2016.03.004
- [81] Lu L, Zhang X, Zhang M, Zhang H, Liao L, Yang T, et al. RANTES and SDF-1 are keys in cell-based therapy of TMJ osteoarthritis. *Journal of Dental Research*. 2015;**94**(11):1601-1609. DOI: 10.1177/0022034515604621
- [82] Ferreira LM, Moura ÁFB, Barbosa GAS, Pereira HSG, dos Santos Calderon P. Do matrix metalloproteinases play a role in degenerative disease of temporomandibular joint? A systematic review. *Cranio*. 2016;**34**(2):112-117. DOI: 10.1179/2151090314Y.0000000034
- [83] Luo S, Deng M, Long X, Li J, Xu L, Fang W. Association between polymorphism of MMP-1 promoter and the susceptibility to anterior disc displacement and temporomandibular joint osteoarthritis. *Archives of Oral Biology*. 2015;**60**(11):1675-1680. DOI: 10.1016/j.archoralbio.2015.08.001
- [84] Sato J, Segami N, Yoshitake Y, Kaneyama K, Yoshimura H, Fujimura K, et al. Specific expression of substance P in synovial tissues of patients with symptomatic, non-reducing internal derangement of the temporomandibular joint: Comparison with clinical findings. *The British Journal of Oral & Maxillofacial Surgery*. 2007;**45**(5):372-377. DOI: 10.1016/j.bjoms.2006.09.011

- [85] Tanaka A, Kumagai S, Kawashiri S, Takatsuka S, Nakagawa K, Yamamoto E, et al. Expression of matrix metalloproteinase-2 and -9 in synovial fluid of the temporomandibular joint accompanied by anterior disc displacement. *Journal of Oral Pathology & Medicine*. 2001;**30**(1):59-64. DOI: 10.1034/j.1600-0714.2001.300110.x
- [86] Yoshida K, Takatsuka S, Tanaka A, Hatada E, Nakamura H, Nakagawa K, et al. Aggrecanase analysis of synovial fluid of temporomandibular joint disorders. *Oral Diseases*. 2005;**11**(5):299-302. DOI: 10.1111/j.1601-0825.2005.01120.x
- [87] Fu K, Ma X, Zhang Z, Pang X, Chen W. Interleukin-6 in synovial fluid and HLA-DR expression in synovium from patients with temporomandibular disorders. *Journal of Orofacial Pain*. 1995;**9**(2):131-137
- [88] Shafer DM, Assael L, White LB, Rossomando EF. Tumor necrosis factor-alpha as a biochemical marker of pain and outcome in temporomandibular joints with internal derangements. *Journal of Oral and Maxillofacial Surgery*. 1994;**52**(8):786-791; discussion 791-782. DOI: 10.1016/0278-2391(94)90217-8
- [89] Fossiez F, Banchereau J, Murray R, Van Kooten C, Garrone P, Lebecque S. Interleukin-17. *International Reviews of Immunology*. 1998;**16**(5-6):541-551. DOI: 10.3109/08830189809043008
- [90] Sato K, Suematsu A, Okamoto K, Yamaguchi A, Morishita Y, Kadono Y, et al. Th17 functions as an osteoclastogenic helper T cell subset that links T cell activation and bone destruction. *The Journal of Experimental Medicine*. 2006;**203**(12):2673-2682. DOI: 10.1084/jem.20061775
- [91] Nakae S, Nambu A, Sudo K, Iwakura Y. Suppression of immune induction of collagen-induced arthritis in IL-17-deficient mice. *Journal of Immunology*. 2003;**171**(11):6173-6177. DOI: 10.4049/jimmunol.171.11.6173
- [92] Sato K, Takayanagi H. Osteoclasts, rheumatoid arthritis, and osteoimmunology. *Current Opinion in Rheumatology*. 2006;**18**(4):419-426. DOI: 10.1097/01.bor.0000231912.24740.a5
- [93] Gravallese EM. Bone destruction in arthritis. *Annals of the Rheumatic Diseases*. 2002;**61**(Suppl 2):ii84-ii86. DOI: 10.1136/ard.61.suppl_2.ii84
- [94] Vernal R, Dutzan N, Chaparro A, Puente J, Antonieta Valenzuela M, Gamonal J. Levels of interleukin-17 in gingival crevicular fluid and in supernatants of cellular cultures of gingival tissue from patients with chronic periodontitis. *Journal of Clinical Periodontology*. 2005;**32**(4):383-389. DOI: 10.1111/j.1600-051X.2005.00684.x
- [95] Monasterio G, Castillo F, Pujol M, Rojas L, Alvarez C, Carvajal P, et al. Variability in the Th1/Th17/Th22 and Th2/Th9/Treg-type of immuno-inflammatory responses and their association with joint pain, imagenological bone degeneration, Rankl expression, and osteoclast-induced bone resorption in temporomandibular joint osteoarthritis and disk displacement with reduction. *Journal of Orofacial Pain*. 2017:Submitted
- [96] Kim KW, Kim HR, Park JY, Park JS, HJ O, Woo YJ, et al. Interleukin-22 promotes osteoclastogenesis in rheumatoid arthritis through induction of RANKL in human synovial fibroblasts. *Arthritis and Rheumatism*. 2012;**64**(4):1015-1023. DOI: 10.1002/art.33446

- [97] Elyaman W, Bradshaw EM, Uyttenhove C, Dardalhon V, Awasthi A, Imitola J, et al. IL-9 induces differentiation of TH17 cells and enhances function of FoxP3⁺ natural regulatory T cells. *Proceedings of the National Academy of Sciences of the United States of America*. 2009;**106**(31):12885-12890. DOI: 10.1073/pnas.0812530106
- [98] Marijnissen RJ, Koenders MI, Smeets RL, Stappers MH, Nickerson-Nutter C, Joosten LA, et al. Increased expression of interleukin-22 by synovial Th17 cells during late stages of murine experimental arthritis is controlled by interleukin-1 and enhances bone degradation. *Arthritis and Rheumatism*. 2011;**63**(10):2939-2948. DOI: 10.1002/art.30469
- [99] Zhang L, Li JM, Liu XG, Ma DX, NW H, Li YG, et al. Elevated Th22 cells correlated with Th17 cells in patients with rheumatoid arthritis. *Journal of Clinical Immunology*. 2011;**31**(4):606-614. DOI: 10.1007/s10875-011-9540-8
- [100] Carrion M, Juarranz Y, Martinez C, Gonzalez-Alvaro I, Pablos JL, Gutierrez-Canas I, et al. IL-22/IL-22R1 axis and S100A8/A9 alarmins in human osteoarthritic and rheumatoid arthritis synovial fibroblasts. *Rheumatology (Oxford, England)*. 2013;**52**(12):2177-2186. DOI: 10.1093/rheumatology/ket315
- [101] Pinto LG, Talbot J, Peres RS, Franca RF, Ferreira SH, Ryffel B, et al. Joint production of IL-22 participates in the initial phase of antigen-induced arthritis through IL-1 β production. *Arthritis Research & Therapy*. 2015;**17**:235. DOI: 10.1186/s13075-015-0759-2
- [102] Green DR, Flood PM, Gershon RK. Immunoregulatory T-cell pathways. *Annual Review of Immunology*. 1983;**1**:439-463. DOI: 10.1146/annurev.iy.01.040183.002255
- [103] Sakaguchi S, Toda M, Asano M, Itoh M, Morse SS, Sakaguchi N. T cell-mediated maintenance of natural self-tolerance: Its breakdown as a possible cause of various autoimmune diseases. *Journal of Autoimmunity*. 1996;**9**(2):211-220. DOI: 10.1006/jaut.1996.0026
- [104] Pillai V, Karandikar NJ. Human regulatory T cells: A unique, stable thymic subset or a reversible peripheral state of differentiation? *Immunology Letters*. 2007;**114**(1):9-15. DOI: 10.1016/j.imlet.2007.08.012
- [105] Sakaguchi S. Regulatory T cells in the past and for the future. *European Journal of Immunology*. 2008;**38**(4):901-937. DOI: 10.1002/eji.200890012
- [106] Bluestone JA, Abbas AK. Natural versus adaptive regulatory T cells. *Nature Reviews. Immunology*. 2003;**3**(3):253-257. DOI: 10.1038/nri1032
- [107] McGuirk P, Mills KH. Pathogen-specific regulatory T cells provoke a shift in the Th1/Th2 paradigm in immunity to infectious diseases. *Trends in Immunology*. 2002;**23**(9):450-455. DOI: 10.1016/s1471-4906(02)02288-3
- [108] Gonzalez A, Andre-Schmutz I, Carnaud C, Mathis D, Benoist C. Damage control, rather than unresponsiveness, effected by protective DX5⁺ T cells in autoimmune diabetes. *Nature Immunology*. 2001;**2**(12):1117-1125. DOI: 10.1038/ni738
- [109] Mittrucker HW, Kaufmann SH. Mini-review: Regulatory T cells and infection: Suppression revisited. *European Journal of Immunology*. 2004;**34**(2):306-312. DOI: 10.1002/eji.200324578

- [110] Bettelli E, Carrier Y, Gao W, Korn T, Strom TB, Oukka M, et al. Reciprocal developmental pathways for the generation of pathogenic effector TH17 and regulatory T cells. *Nature*. 2006;**441**(7090):235-238. DOI: 10.1038/nature04753
- [111] Yamazaki S, Bonito AJ, Spisek R, Dhodapkar M, Inaba K, Steinman RM. Dendritic cells are specialized accessory cells along with TGF- for the differentiation of Foxp3⁺ CD4⁺ regulatory T cells from peripheral Foxp3 precursors. *Blood*. 2007;**110**(13):4293-4302. DOI: 10.1182/blood-2007-05-088831
- [112] Bettelli E, Oukka M, Kuchroo VK. T (H)-17 cells in the circle of immunity and autoimmunity. *Nature Immunology*. 2007;**8**(4):345-350. DOI: 10.1038/ni0407-345
- [113] Brusko T, Bluestone J. Clinical application of regulatory T cells for treatment of type 1 diabetes and transplantation. *European Journal of Immunology*. 2008;**38**(4):931-934. DOI: 10.1002/eji.200738108
- [114] You S, Leforban B, Garcia C, Bach JF, Bluestone JA, Chatenoud L. Adaptive TGF- β -dependent regulatory T cells control autoimmune diabetes and are a privileged target of anti-CD3 antibody treatment. *Proceedings of the National Academy of Sciences of the United States of America*. 2007;**104**(15):6335-6340. DOI: 10.1073/pnas.0701171104
- [115] Horwitz DA, Zheng SG, Wang J, Gray JD. Critical role of IL-2 and TGF- β in generation, function and stabilization of Foxp3⁺CD4⁺ Treg. *European Journal of Immunology*. 2008;**38**(4): 912-915. DOI: 10.1002/eji.200738109

IntechOpen

