

We are IntechOpen, the world's leading publisher of Open Access books Built by scientists, for scientists

4,800

Open access books available

122,000

International authors and editors

135M

Downloads

Our authors are among the

154

Countries delivered to

TOP 1%

most cited scientists

12.2%

Contributors from top 500 universities



WEB OF SCIENCE™

Selection of our books indexed in the Book Citation Index
in Web of Science™ Core Collection (BKCI)

Interested in publishing with us?
Contact book.department@intechopen.com

Numbers displayed above are based on latest data collected.
For more information visit www.intechopen.com



The Neonate with Minor Dysmorphisms

Simona Vlădăreanu, Mihaela Boț, Costin Berceanu,
Claudia Mehedințu and Simona Popescu

Additional information is available at the end of the chapter

<http://dx.doi.org/10.5772/intechopen.71902>

Abstract

Congenital anomalies are present in at least 10% of all neonatal intensive care unit admissions, of whom many have an underlying genetic condition. About 50–60% of human congenital anomalies are of unknown etiology, and approximately one-third are caused by genetic factors. A smaller percentage of birth defects are the result of chromosomal aberrations and gene mutations. Around 1 in 40 or 2.5% of all newborns have a malformation at birth. This may be an isolated malformation or may occur together with other malformations and/or dysmorphic features as part of a malformation syndrome. Around 4000 malformation syndromes have now been delineated. Many are associated with medical problems and making a specific syndrome diagnosis can influence immediate medical management. However, the infant with dysmorphism often does not have a major malformation, and may simply have an appearance that is unusual compared with the general population and of unaffected close relatives. The chapter intends to provide semnificative data concerning the approach and management of a dysmorphic neonate, mainly when there are minor anomalies and will offer all those relevant data and try to establish a protocol guide for the approach of the dimorphic neonate.

Keywords: congenital, anomalies, neonate, dysmorphic, syndrome

1. Introduction

Dysmorphology is the branch of clinical genetics that attempts to interpret the human growth patterns and structural defects.

Often, the neonatologist has the opportunity to be the first to identify a congenital anomaly in the neonates. Thus, the presence of a neonatal dysmorphic syndrome (be it major or minor) must be shared with the parents, something that may certainly cause feelings of anxiety.

Addressing the diagnosis of a dysmorphic newborn is similar to the diagnosis of systemic diseases – it relies on analyzing the family history and on performing a meticulous examination of signs and expressions, in an effort to identify a syndrome [1].

The steps to be taken after identifying a neonatal dysmorphism are to confirm the diagnosis through cytogenetic testing via molecular techniques (in order to confirm/exclude a genetic etiology), followed by family counseling by the neonatologist-geneticist team.

After many years spent ‘looking after little patients’, we hereby discuss a number of anomalies and abnormal physical characteristics, isolated or associated, together with the genetic syndromes in which they can be included.

Since the neonatologists are the first to evaluate the neonates, they must be familiar with various major and minor dysmorphisms. The diagnosis of a syndrome depends on good clinical skills, knowledge of phenotypic features of various syndromes and the experience of the examiner.

Dysmorphism [1] is a morphological anomaly of a structure, a deviation from the norm, and can be classified as major or minor. Major abnormalities may be surgical, medical or cosmetic, and they may be markers for other malformations too. Minor anomalies do not have significant surgical or cosmetic importance, though many genetic syndromes can be recognized based on basis of minor anomalies.

2. Mechanisms of occurrence

Anomalies may occur through three mechanisms [2], each having different implications for the diagnosis:

- **The malformative mechanism** causes structural defects, resulting from an inherently abnormal development process, a primary error in morphogenesis. Malformations include congenital heart, lips, and palate abnormalities. These types of malformations are most commonly associated with a genetic disease or a genetic predisposition.
 - The malformation sequence results from a single primary malformation, as is the case with lumbar neural tube defects.
 - Malformative syndrome results from several different biological errors during morphogenesis.
- **The deforming mechanism** is an anomaly resulting from the action of prenatal mechanical forces on normal fetal structures. The femur, the fingers (that become overlapped) and the head (that grows into an unusual shape) can be affected. Deformations are rarely genetic, and the recurrence risk is usually low.
- **The disruptive mechanism** causes structural defects resulting from the destruction or interruption of normal intrinsic tissue, such as limbs reduction in amniotic band sequence or certain types of intestinal atresia due to vascular insufficiency [3]. The anomalies are rarely caused by a genetic condition and unlikely to occur in a future pregnancy.

Other terms used to describe the congenital anomalies are:

- Dysplasia, which is an abnormal cellular organization within a tissue, causing structural abnormalities (for example changes in bone structure and cartilage in skeletal dysplasia).
- Association, which is a group of abnormalities that occurs more frequently than expected, but which do not have a predictable pattern or a unique etiology.

3. Incidence

The incidence of congenital abnormalities is approximately 10% of total admissions in neonatal intensive care units (NICUs). Many of them have underlying genetic syndromes. Worldwide, around 7.9 million children (6% of births worldwide) are born with congenital anomalies [4] annually.

Minor anomalies, the subject of this chapter, appear to be isolated more frequently. About 15% of neonates are diagnosed with one minor anomaly (**Table 1**). About 71% of them are found in head, neck and hands. Among neonates diagnosed with an isolated minor anomaly, 3% have a major associated abnormality.

Affected segment	Minor anomaly diagnosed
Head and throat	<ul style="list-style-type: none"> • Asymmetric crying facies • Aplasia cutis congenital • Mild micrognathia • Flat nasal bridge • Upturned nose • Large fontanel
Eyes	<ul style="list-style-type: none"> • Brushfield spots • Inner epicanthal folds • Telecanthus and hypertelorism • Slanting of palpebral fissures
Ear	<ul style="list-style-type: none"> • Lack of helical fold • Posteriorly rotated pinna • Preauricular with or without auricular skin tags • Auricular (preauricular) pit or sinus • Small pinna • Folding of helix • Darwinian tubercle • Crushed (crinkled) ear • Asymmetric ear sizes • Low-set ears

Affected segment	Minor anomaly diagnosed
Skin	<ul style="list-style-type: none"> • Dimpling over bones • Capillary hemangioma (face, posterior neck) • Mongolian spots (African Americans, Asians) • Sacral dimple • Pigmented nevi • Redundant skin • Cutis marmorata • Café au lait spot
Hand	<ul style="list-style-type: none"> • Simian creases • Bridged upper palmar creases • Clinodactyly of the fifth finger • Hyperextensibility of thumbs • Single flexion crease of fifth digit (hypoplasia of middle phalanx) • Partial cutaneous syndactyly • Polydactyly • Short, broad thumb • Narrow, hyperconvex nails • Hypoplastic nails • Camptodactyly • Shortened fourth digit
Leg	<ul style="list-style-type: none"> • Partial syndactyly of second and third toes • Asymmetric toe length • Clinodactyly of second toe • Overlapping toes • Nail hypoplasia • Wide gap between hallux and second toe • Deep plantar crease between hallux and second toe
Others	<ul style="list-style-type: none"> • Mild calcaneovalgus • Hydrocele • Shawl scrotum • Hypospadias • Hypoplasia of labia majora

Table 1. Minor anomalies seen in various systems.

0.8% of neonates have two minor anomalies associated, and 11% of them have a major associated abnormality.

The presence of three or more minor abnormalities is rare (about 0.5%), and in most cases (90%), neonates also associate a major malformation.

4. Classification

4.1. Minor head and throat anomalies

4.1.1. *Asymmetric crying facies*

Asymmetric crying facies (ACF) is a minor abnormality, characterized by lowering the corner of the mouth on the unaffected side when crying or sketching a grimace. This is caused by the congenital absence of the anguli oris depressant muscle. The ACF neonates show both nasolabial folds with normal, symmetrical depth and do have the normal ability to lift their forehead and close both eyes. This anomaly must be distinguished from facial nerve paralysis, which is less common [5]. In 20–70% of cases, ACF is associated with other congenital abnormalities, the most common being head/neck, cardiovascular, musculoskeletal, genitourinary and gastrointestinal.

Once this anomaly has been identified, genetic testing is recommended (FISH test or chromosomal microarray comparative genomic hybridization) because ACF is especially associated with 22q11 deletion syndrome (also known as velocardiofacial or DiGeorge syndrome). In this syndrome, the facial dysmorphism coexist with structural heart anomalies, long fingers/limbs, thymus aplasia/hypoplasia and kidney abnormalities. The postnatal follow-up protocol recommends close monitoring of growth and development, evaluation of thyroid and parathyroid function, immunological, hearing and ophthalmic evaluation, echocardiography, renal ultrasonography and the treatment of possibly associated anomalies [6].

4.1.2. *Aplasia cutis congenita*

Aplasia cutis congenita (ACC) is the congenital absence of the skin, and may occur on any part of the body. It affects the scalp in 70–80% of the cases (**Figure 1**), either as solitary lesions or associated with skull and dura mater defects [2, 7]. Aplasia cutis congenita is a rare anomaly in neonates. Over 500 cases have been reported since the first description, by Cordon in 1767. Due to the unreported cases, their real incidence is unknown. An estimate of the incidence is about 3 out of 10,000 births [8].

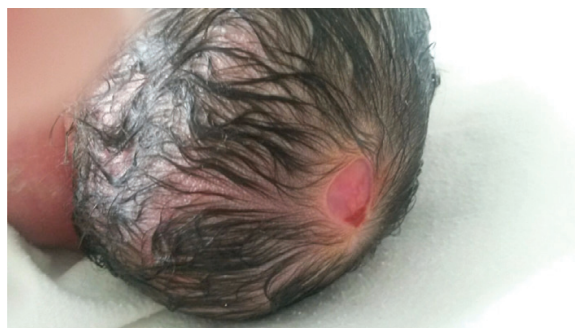

Figure 1. Aplasia cutis congenita.

The pathophysiological mechanism of aplasia cutis congenita is unclear; some theories suggest the involvement of factors such as obstetrical trauma, intrauterine infections with varicella zoster or herpes virus, as well as teratogenic agents, such as cocaine and methimazole [7, 9].

When this anomaly is confirmed, a series of additional investigations are required to determine if there are also other associated malformations that describe a genetic syndrome.

Adams-Oliver's syndrome includes (alongside ACC and limb defects) cutis marmorata telangiectatica congenita, central nervous system abnormalities and cardiovascular abnormalities. To diagnose this genetic syndrome, cerebral and spine (MRI) imaging, limb radiographs, echocardiography and genetic tests with genes ARHGAP31, DOCK6, RBPJ, EOGT [7, 10] sequencing are required. Adams-Oliver Syndrome can be transmitted either autosomal dominant or autosomal recessive. ACC has also been associated with trisomy 13 [11].

ACC may evolve with complications (local infection, meningitis, bleeding and superior sagittal sinus thrombosis). The mortality rate lies between 20 and 50% and depends on the size of the lesion and its association with other malformations.

4.1.2.1. Management

Small sized ACC, located laterally to the median line, is usually a unique congenital anomaly and does not require further evaluation. In sizeable defects, located on the median line, with a membranous appearance that raises the suspicion of a simultaneously damage of the skull and dura mater, cerebral and spinal MRI are recommended. A subjacent neural tube defect must be confirmed or excluded. Treatment for ACC is usually conservative [7].

4.1.2.2. Prognosis

The outcome is usually very good, small defects evolving toward healing within a few weeks through progressive epithelization and atrophic, hairless scarring [8]. In rare cases, hemorrhage and local infections may appear. Large defects of the scalp can be surgically repaired using autologous or biological grafts.

If aplasia cutis congenita is associated with other anomalies, the outcome depends on their severity.

Deep and small defects of the scalp and skull close spontaneously during the first year of life. Larger-sized defects require surgical correction.

Scalp defects that interest the skull and dura mater can be complicated by sagittal sinus thrombosis and are associated with a mortality rate greater than 50%.

4.1.3. Mild micrognathia

Micrognathia is a rather frequent clinical craniofacial abnormality, caused by congenital mandibular hypoplasia (**Figure 2**). It is usually associated with a deficient gonial angle, ascending ramus, and mandibular corpus.



Figure 2. Mild micrognathia associated with retrognathia.

It can appear as a minor and isolated abnormality, or may be severe, as part of a genetic syndrome, frequently causing postnatal complications.

Congenital mandibular hypoplasia occurs either through intrauterine deformation or malformative mechanisms, as a result of a primary intrinsic growth disorder [12, 13].

The mandible is formed from the neural crest, beginning with the onset of the 4th week of gestation, the cells migrating to the upcoming region of the head and neck and with the initiation of the formation of the gill arches. From the first branching arch, two prominences develop, the mandibular and the maxillary one. The mandibular protrusion will form the mandible, and the jaw will form the jaw bone, the zygomatic bone and the squamous part of the temporal bone.

It is likely that congenital mandibular hypoplasia results from poor or insufficient development of the neural crest, or by means of altered migration process to the first branch of the gill, during the 4th week of gestation.

The diagnosis of micrognathia in neonates requires a careful clinical evaluation, to identify other associated craniofacial abnormalities, such as cleft palate or the coexistence of other congenital anomalies. The maxillary, the zygomatic bone, the temporal bone, the cranial vault and the cervical spine represent the other anatomical regions that can be affected.

In the clear majority of cases that include, among the first clinical signs – micrognathia, the diagnosis of genetic syndromes can be suspected on clinical examination. Subsequently, the case requires confirmation by genetic testing, as in deletion syndrome 22q11 cases.

Approximately 60 syndromes associated with micrognathia have been described, such as [12]:

Aneuploidic syndromic

- Trisomy 9
- Trisomy 13
- Trisomy 18

Non Aneuploidic syndromic

- Fryns syndrome
- Goldenhar syndrome (hemifacial microsomia)
- Hydroletharus syndrome
- Lethal multiple pterygium syndrome
- Nager syndrome
- Pena Shokeir syndrome
- Pierre Robin sequence
- Seckel syndrome
- Smith Lemli Opitz syndrome
- Stickler syndrome
- TAR syndrome
- Treacher Collins syndrome (mandibulofacial dysostosis)

Micrognathia can result in a malocclusion (poor bite), where the teeth and jaws do not line up properly, or in more severe cases, in difficulties in breathing or swallowing. Underdeveloped mandibles can also cause severe psychological and functional impact in the growing of the child, and may be associated with life-threatening complications such as obstructive sleep apnea [12].

4.2. Minor eye anomalies

Although there is a wide variety of ocular morphology (in terms of gender, ethnicity and age), a careful analysis of some dysmorphological entities and objective measurements during the clinical examination can help diagnose some features outside of the normal standards, which may help identifying a syndrome.

4.2.1. Brushfield spots

Brushfield spots are white, yellow-colored spots on the anterior surface of the iris or small white-gray areas around the pupil.

Brushfield spots are observed in 20% of normal neonates, regardless of the color of their eyes. 85% of people with blue eyes show these spots (**Figure 3**).

They are also very common (80%) in the iris of children with trisomy 21. In children with Down syndrome and brown eyes, these spots are visible in 15–17% of cases only, being masked by normal pigmented cells. In cases with black eyes, they cannot be identified.

Brushfield spots should be differentiated from normal stromal condensation called “Kun-
kmann Wolffian bodies”, which are light-colored, located peripherally in the iris and are not considered to be ocular dysmorphisms.

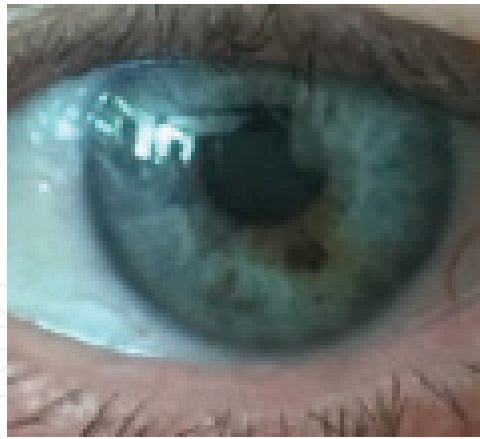


Figure 3. Brushfield spot.

4.2.2. Inner epicanthal fold

Epicanthal fold represents the oblique or vertical skin fold [14], which starts from the upper eyelid to the lower eyelid, covering the inner corner of the eye and it is most frequently bilateral (**Figure 4**). This feature is also named *plica palpebronasalis* or the historically Mongolian fold.

These skin folds appear through the excessive development of the skin across the nasal bridge. This excess skin presents a certain tension determined by the ectopic orbicularis oculi muscle fibers and connective tissue [15], leading to residual horizontal skin over the nasal bridge.

One of the main facial features that is often closely associated with the epicanthic fold is the elevation of the nasal bridge [16].

Factors influencing this facial trait are: geographical ancestry, age and certain pathological conditions such as blepharophimosis, palpebral ptosis.

The epicanthic fold may be an isolated congenital anomaly, or it may be a manifestation of other syndromes [17, 18]. Approximately 60% of people with Down syndrome have this fold, named “the Mongoloid fold” by John Langdon Down. In Zellweger’s syndrome, epicanthic folds are present and prominent [19]. Other pathological conditions that highlight this epicanthic fold are the fetal alcohol syndrome, phenylketonuria, Turner syndrome and Smith-Lemli-Opitz syndrome.

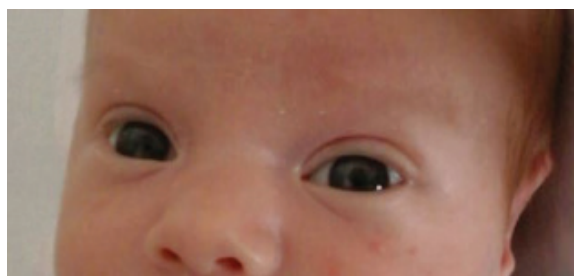


Figure 4. Inner epicanthal fold.

Four types of epicanthic folds [20] have been identified:

1. Epicanthus tarsalis: the fold is most prominent along the upper eyelid - the normal anatomical variant of the Asian eyelid
2. Epicanthus inversus: the fold is most prominent along lower eyelid - associated with blepharophimosis syndrome
3. Epicanthus palpebralis: involves both upper and lower eyelids
4. Epicanthus superciliaris: the fold originates from the brow and follows down to the lacrimal sac

The evolution of epicanthic folds is favorable: a mild degree of epicanthus disappears most frequently with further development of the nose and massive facial bone [20, 21].

Surgical correction is only occasionally required. One of the surgical indications is in the case of epicanthus inversus, which does not resolve on its own with further growth and development of the face [15].

4.2.3. Telecanthus and hypertelorism

Telecanthus is the increased distance between the medial canthi of both eyes, with normal interpupillary distance. This condition is different to hypertelorism, which refers to an increased distance between the orbits [22].

Telecanthus may appear secondary to obstetrical traumas such as naso-orbito-ethmoidal fractures, and it may be an ethnic marker. It could also represent the expression of sinus or orbital tumors, or it may be associated with syndromes such as:

- Sinus polyps – Kartagener syndrome
- Down syndrome
- Turner syndrome
- Klinefelter syndrome
- Fetal alcohol syndrome
- Cri du chat syndrome
- Dubowitz syndrome
- Noonan syndrome
- SHORT syndrome

Hypertelorism is a clinical sign in a wide range of affections and syndromes such as:

- Edwards syndrome
- 1q21.1 duplication syndrome

- Basal cell nevus syndrome
- DiGeorge syndrome
- Loeys-Dietz syndrome
- Apert syndrome
- Neurofibromatosis
- Leopard syndrome
- Crouzon syndrome
- Wolf-Hirschhorn syndrome
- Andersen-Tawil syndrome
- Waardenburg syndrome
- Cri du chat syndrome

Since hypertelorism is a facial dysmorphism associated with a large and diverse number of congenital disorders and syndromes, the mechanism of hypertelorism is heterogeneous.

A number of theories have attempted to pinpoint this anomaly, such as: the early ossification of the lower wings of the sphenoid, the increasing width of the ethmoid sinuses, the formation and abnormal development of the skull, which can be seen in syndromes such as Apert and Crouzon [22].

4.2.4. Slanting of palpebral fissures

In the normal eye, the eyelids are generally positioned so that the lateral canthus is about 1 mm higher than the medial canthus. The palpebral slant is the direction of the slant of a line that goes from the outer corner of the eye to the inner corner.

The upper or lower slant of the palpebral fissure can be a genetic or ethnic feature (Asian population), but there are a number of conditions and syndromes manifested through this anomaly, isolated or in association with others, such as the Treacher Collins syndrome, Franceschetti (oculo-mandibulo-facial) syndrome, Down syndrome, fetal alcohol syndrome or other genetic disorders.

The identification of an abnormal slant of the palpebral fissure requires a thorough medical examination with an analysis of family history, a physical exam to detect other associated disorders/abnormalities and paraclinical investigations (karyotype), enzyme assays and metabolic studies [23].

4.3. Minor ear anomalies

The incidence of ear malformations is approximately 1 in 3800 newborns [24] and accounts for 50% of all ENT (Ear, Nose, and Throat) malformations. The most common malformations are unilateral and localized in the outer and middle ear.

Auricular malformations in newborns may be genetic (associated with syndromes or not, with family history, spontaneous mutations) or intrauterine (acquired by deformation mechanisms).

External ear malformations may involve the orientation, position, size, and external configuration of the pinna. The absence of the external ear can be identified (anotia).

4.3.1. Preauricular and auricular ear tags and pits

Auricular and preauricular ear tags and pits (**Figures 5 and 6**) are frequent findings on routine neonatal physical examinations, occurring at a frequency of 1 in 12,500 births [25]. The incidence of spontaneous formation of external ear pits in the non-syndromic population ranges between 0.3 and 1.3%, it equally affects both sexes and it has no race predilection. The incidence of unilateral preauricular sinus is 1.3% and that of bilateral preauricular sinus is 0.3%. The rate of genetic transmission of bilateral preauricular sinus was higher in children with a parent with this condition, compared to the cases of unilateral preauricular sinus.

The ear begins to develop in the 6th week of gestation, from the first and second branchial arches. A series of 6 mesenchymal proliferations is formed, known as hillocks of His, which subsequently fuse to form the definitive auricle. The first three hillocks are derived from the first branchial arch and form the tragus, crus of the helix and helix, and the other three hillocks are derived from the second arch and form the antihelix, scapha, and the lobule.

Auricular fistulas may be caused by faulty or incomplete fusion of the hillocks or by localized folding of the ectoderm. Genetic tests suggest that preauricular fistula appears due to an abnormality in chromosome 8q11.1-q13.3 [25].

Preauricular tags may be caused by supernumerary development of the first 3 hillocks of the first branchial arch.

Auricular fistulas are small, pigmented, benign congenital formations [26], located in the tegument and auricular and periauricular soft tissues, anywhere along a line drawn from the tragus to the angle of the mouth. They were first described by Van Heusinger in 1864.

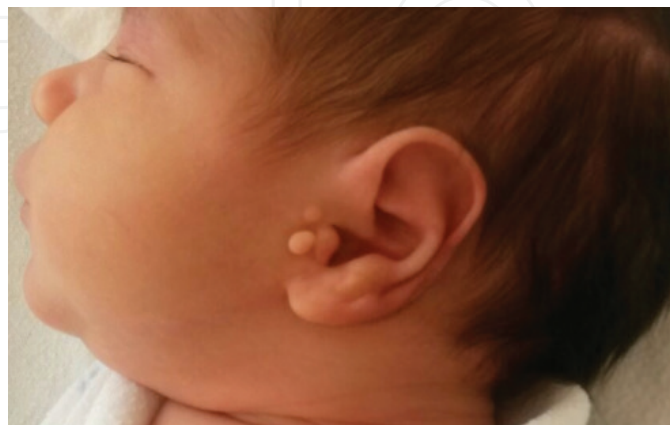

Figure 5. Preauricular tag.

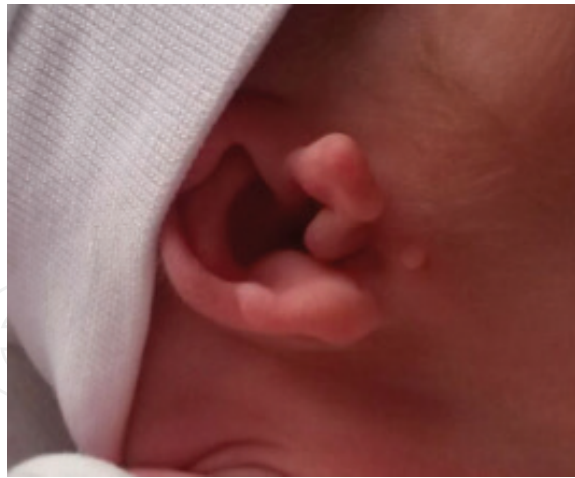

Figure 6. Preauricular tag.

Auricular fistulas are small pits/openings, located anywhere at the anterior margin of the auricle, from crus of the helix to helix, and are lined by squamous epithelium.

These auricular abnormalities can be found in isolation or as part of a genetic syndrome. All newborns will need a hearing assessment later because outer ear abnormalities can be associated with additional abnormalities such as shape abnormalities (helical ear pits), asymmetry, posterior angulation, small size, absent tragus, and narrow external auditory meatus [26], middle or inner ear malformations, and with progressive hearing loss.

These patients should be examined for any other malformations in an attempt to include the anomaly in a genetic syndrome such as [2, 26–29]:

- **Craniofacial microsomia:** association of auricular nodules with other external ear abnormalities, progressive hearing loss, palatoschisis, maxillary and/ or mandibular hypoplasia and renal abnormalities. These children require audiological assessment and renal ultrasonography, and from the point of view of genetic diagnosis, karyotype testing.
- **Branchio-oto renal syndrome (BOR):** the association of auricular fistulae with other outer ear abnormalities, renal abnormalities and Brachial cleft fistulae. These children require auditory and renal echography, and from the point of view of genetic diagnosis, EYA1, SIX5, SIX1 sequencing is required.
- **Beckwith-Wiedemann syndrome:** auricular fistulae associated with ear lobe asymmetry
- **Oculo-auriculo-vertebral dysplasia (Goldhar Syndrome):** associates auricular nodules, upper eyelid coloboma, outer ear deformities and vertebral abnormalities
- **Chromosome arm 11q duplication syndrome:** Preauricular tags or pits
- **Chromosome arm 4p deletion syndrome:** Preauricular dimples or skin tags
- **Chromosome arm 5p deletion syndrome:** Preauricular tags

De novo appearance of these auricular abnormalities associated with those on the face and neck may be related to the use of propylthiouracil in early pregnancy to treat maternal hyperthyroidism [30].

When auricular fistulae and nodules are isolated, no further evaluation is required for these children [2].

Most cases with typical location of auricular and preauricular fistulas are asymptomatic and do not require surgery. They can retain epithelial and sebum debris, and can evolve to subcutaneous cysts or infection. This may in turn lead to cellulitis or abscess, and may require aspiration of the collection if the antibiotic therapy is not responding. In cases of recurrent cyst infection, surgical excision of the cyst and the fistula tract is indicated. A preauricular fistulae may vary in length, may have a sinuous tract or may be extensively branched. If there are auricular fistulas and subcutaneous cysts, they adhere to the auricular perichondritis. Thus, complete elimination of the fistula or cyst should also include a portion of the auricular perichondritis at the base of the lesion [26]. Auricular and preauricular nodules can be excised for esthetic reasons.

4.3.2. Microtia

Microtia is a congenital anomaly characterized by the underdevelopment of the outer ear, while anotia is the complete absence of the ear. Because microtia and anotia have the same origin, they can be described as microtia-anotia [31].

Microtia can be unilateral or bilateral and its frequency is of approximately 1–3 to every 10,000 births [32]. In the case of unilateral microtia, the right ear is most frequently affected [31].

Etiologically, the administration of the teratogenic agent called isotretinoin (Accutane®) during pregnancy may lead to these congenital auricular abnormalities (anotia/microtia).

The pathogenesis of microtia is heterogeneous, and there have been indications of unique genetic mutations or its presence as a family trait [33].

Microtia has a broad spectrum of phenotypic aspects, from the uncomplicated hereditary one, (which is transmitted as a dominant feature, and it is most often harmless), to severe, complicated forms of hearing loss. From a clinical point of view, four grades of microtia have been described:

- **Grade I:** A less than complete development of the external ear with identifiable structures and a small but present external ear canal
- **Grade II:** A partially developed ear (usually the top portion is underdeveloped) with a stenotic external ear canal producing a conductive hearing loss
- **Grade III:** the most common form of microtia: Absence of the external ear with a small peanut-like vestige structure and an absence of the external ear canal and ear drum.
- **Grade IV:** Absence of the total ear or anotia.

Isolated microtia is relatively common, but it can be found in newborns in association with other facial dysmorphisms, such as hemifacial microsomia, Goldenhar syndrome or Treacher

Collins syndrome [34], jaw deformities, vertebral anomalies [35], heart defects, limb abnormalities, renal abnormalities and holoprosencephaly [32, 36].

Auricular atresia is the underdevelopment of the middle ear and auditory canal, and it occurs relatively frequently in conjunction with microtia, since newborns with microtia have no external opening to the ear canal, although the cochlea and the other internal ear structures are usually present. The degree of microtia usually correlates to the grade of underdevelopment of the middle ear [37, 38].

The assessment of newborns and infants with microtia-anotia should include a thorough clinical examination for the detection of associated structural defects, pediatric audiological test, multi-disciplinary consultation with the genetic specialist, pediatric otolaryngologist, and pediatric plastic surgeon.

4.3.2.1. Management

A minor anomaly does not require surgical correction. When the auricle is very deformed or absent (grades III and IV), reconstruction is often required for esthetic reasons. Most reconstructive interventions are recommended after the age of 6–10 years old, when the ear pavilion has 80% of the size of an adult ear.

The management of a microtia case associated with an auditory meatus defect is performed by long term periodic audiological monitoring, especially if there is an atresia of the auditory meatus, with the possible placement of an amplification device, especially in the case of the bilateral forms [39].

The surgical procedure for restoring the pinna is complex and is performed in several stages, with esthetic results that vary greatly, as the outer ear structure is difficult to duplicate [40]. A plastic surgical alternative is the use of a synthetic prosthetic pinna or a pinna obtained via the three-dimensional printing technology, but the research is still underway [41].

4.3.3. Macrotia

Macrotia refers to an oversized or enlarged but well-developed auricle without any other malformations of the ear (**Figure 7**). The most exaggerated portion of the ear is the scaphoid fossa. The condition is usually bilateral and symmetric.

Generally, it has an autosomal dominant pattern of transmission and an unknown pathogenesis [42].

Macrotia is commonly associated with the following syndromes:

- Marfan Syndrome: large auricle with dropped, floppy cartilage
- Fragile X-syndrome: macrotia with floppy cartilage, associated with mild or profound X-linked retardation [43].
- Cerebro-oculo-facial-skeletal syndrome (COFS): macrotia associated with neurogenic arthrogyrosis, microcephaly, micro-ophthalmia.

- Variant of De Lange type 2 syndrome [44]: characterized by macrotia associated with severe microcephaly, mild mental retardation, muscular hypotonia and dysmorphic faces (flat profile, mild ptosis, short nose with a large tip and anteverted nares, narrow mouth, retrognathism).

4.3.3.1. Management

Otoplasty can improve the shape, position and proportion of the ear. It is a reconstructive surgery procedure that attempts to harmonize the ratio between ear and face.

4.4. Minor skin anomalies

4.4.1. Capillary hemangioma

It is a congenital vascular abnormality which consists of an agglomeration of neo-formation capillary vessels, manifested in the form of variable reddish-purple patches (**Figures 8 and 9**). These patches are mainly located on the face, neck and lips, but they can appear on any area of the body. They are diagnosed by clinical inspection.

Capillary hemangiomas occur only in the layers of the skin, and they do not develop in depth. They generally appear within a few weeks after birth, but they may appear in infants too and most frequently disappear spontaneously in 1–2 years. A special form of this anomaly is the 'birthmark', the clinical form that appears on the nape or covers a portion of the face and has a violet color [45, 46].

4.4.1.1. Management

Capillary hemangiomas are prone to irritation and ulceration. Each lesion must be evaluated individually, and the practitioner may opt to treat it selecting an alternative therapeutic route.

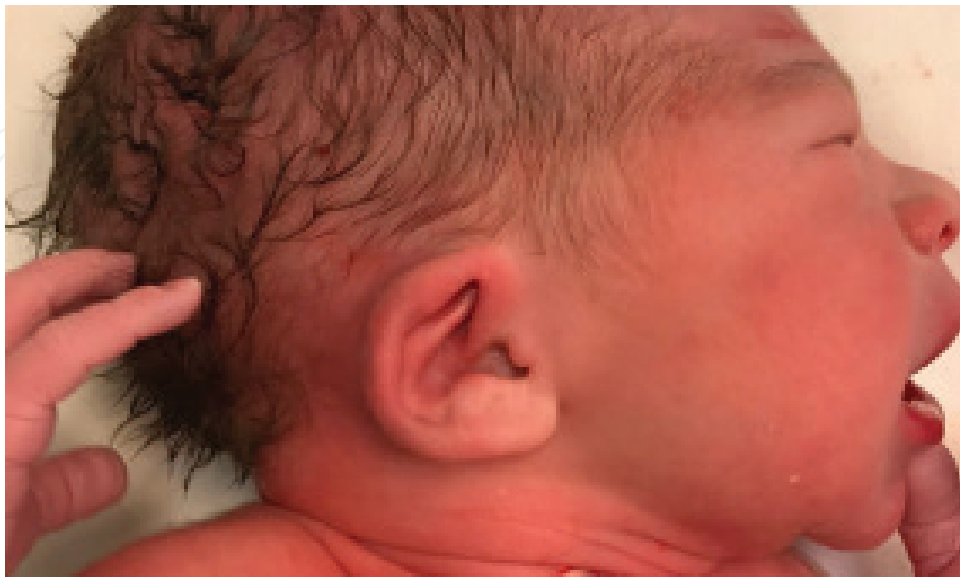

Figure 7. Bilateral macrotia with abnormal shape of the auricle.

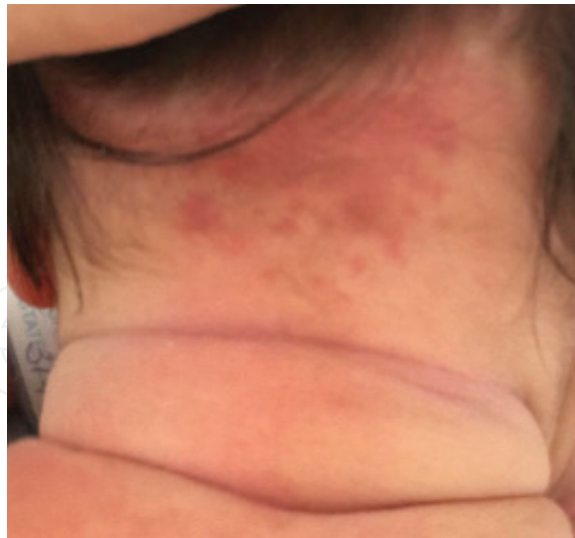

Figure 8. Capillary hemangioma – Posterior neck.

The treatment can be surgical and dermatological-medical and may consist of the surgical excision of hemangiomas, laser pulses, cryosurgery and systemic administration of glucocorticoids. Oral propranolol may be administered in order to reduce the size of hemangiomas may be a therapeutic option [47].

4.4.2. Mongolian spots (*Africans, Americans, Asians*)

Mongolian Spots, also known as Mongolian Blue Spots or congenital dermal melanocytosis, represent a congenital condition characterized by the presence of smooth spots, irregular-shaped with wavy borders, dark blue to brown, with a normal skin texture [48]. They may be present from birth or may appear within the first few weeks of life during the neonatal period.

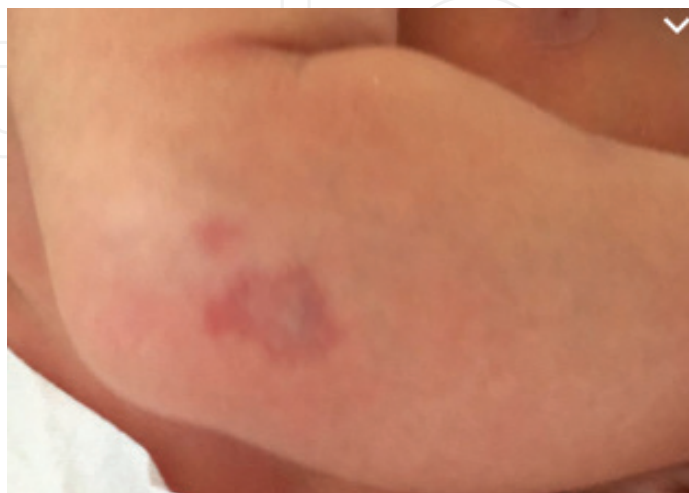

Figure 9. Capillary hemangioma – Forearm.

Mongoloid Spots represent an agglomeration of dermal melanocytes and is not a clinical sign associated with a disease or syndrome.

Depending on the location of melanocytes on the surface of the skin, the coloration of the Mongoloid Spots change. If they are superficially located, the color of the spots is brown, and the deeper they are, the color tends more and more to have a blue shade [48, 49].

Mongoloid Spots are most commonly diagnosed at birth due to specific coloration and localization, and no additional investigation methods are required. They are found with a frequency of 90% in the black population and the Native Americans, in about 80% of Asian infants, 70% of Hispanic individuals and in a reduced proportion of 5–10% of Caucasian children [48, 49]. Incidence is lower in preterm infants compared to full-term infants, and in terms of gender distribution, the incidence is higher in boys.

Most spots are located on the buttocks, lumbosacral (**Figure 10**), deltoid and dorsal region, on the limbs and in rare cases on the face or on the occipital region. There may be single or multiple spots, ranging in size from 1 to 2 cm to tens of cm [50].

4.4.2.1. Management

No treatment is recommended, as Mongoloid spots generally disappear spontaneously at the age of 1–4 years, most frequently in the first year of life. If they do not disappear until puberty, they remain permanent, a situation that occurs in approximately 5% of cases [51].

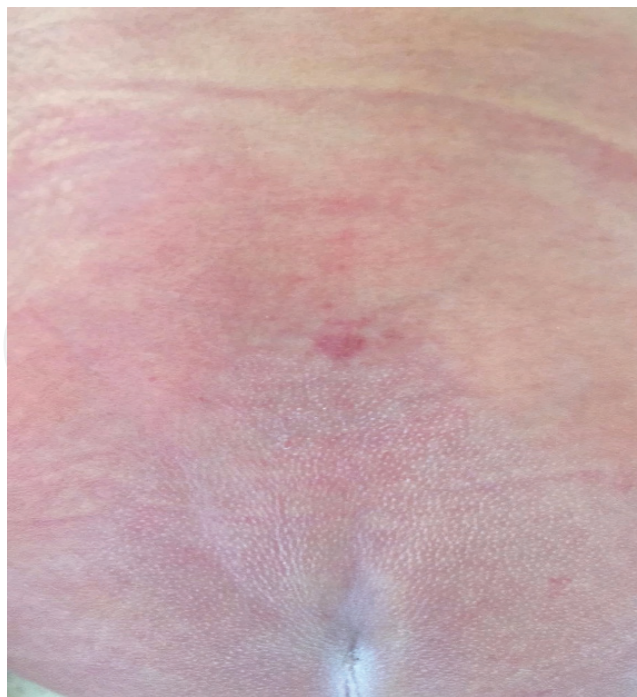

Figure 10. Mongoloid spot – Lumbosacral region.

4.4.3. *Cutis marmorata telangiectatica congenita*

Cutis marmorata telangiectatica congenita is a rare congenital vascular disorder that manifests itself by affecting the blood vessels of the skin by alternating a vascular network with a vasodilation and vasoconstriction process which gives the skin a marbled appearance. It is accentuated by cold temperatures, but it does not disappear when exposed to warmer temperatures [52].

It should not be confused with *Cutis Marmorata*, which is a normal, adaptive, physiological response of the newborn to exposure to low temperatures. This disorder is due to a neurological and vascular immature system, it varies between the constriction and dilation of blood vessels, and it occurs most frequently in the hands and feet.

Very few cases of *cutis marmorata telangiectatica congenita* have been reported worldwide - less than 100 cases [53], but in reality it is more common than that. Mild forms are not that rare, but they are not reported [54].

The pathophysiological mechanisms are still unclear, with most cases occurring sporadically, although rare cases were reported in some families. Studies indicate the primary involvement of capillaries, venules and veins, and possibly arterioles and lymphatic vessels.

The hypothetical mechanisms that have been proposed are environmental factors, peripheral neural dysfunctions, failure of the development of mesodermic vessels in an early embryonic stage and autosomal dominant inheritance with incomplete penetrance [52, 55].

Diagnosis: skin manifestations may be associated with the asymmetry of extremities, macrocephaly, glaucoma, cutaneous atrophy, chronic skin ulcerations, neurological anomalies, vascular anomalies (nevus flammeus, Sturge-Weber syndrome, Klippel-Trénauna syndrome, Adams Oliver syndrome), psychomotor and /or mental retardation [56].

Management: in general, there is no treatment for this condition, but the associated anomalies can be treated. In the case of limb asymmetry, without motor dysfunction, there is the possibility of inserting an "elevation" device for the shorter leg during early childhood. Laser therapy has not been successful in the treatment of this vascular skin disorder, possibly due to many dilated capillaries and veins in the deep layers of the skin.

Prognosis: the prognosis is favorable in most cases, when patients experience an isolated cutaneous abnormality. In most cases, the marbled appearance regresses spontaneously during the first year of life due to the normal maturation process, with the thickening of the epidermis and dermis. In fewer cases, lesions can continue for up to 10 years or throughout the patient's life.

4.4.4. *Pigmentary nevi*

Pigmentary nevi, also known as melanocytic nevi, are benign neoplasms present from birth - congenital melanocytic nevi may develop throughout life.

Pigmentary nevi appear with a high frequency as uniform, beige, brown or skin-color formations, sometimes protruding, circular or oval, with regular, smooth, well-defined margins, of 6 mm in diameter [57, 58].

Histopathologically, they are cellular (melanocyte) benign clusters that change very little in life, have a slow growth, and never invade the surrounding tissues. The number of nevi is influenced both genetically - the family history is very important - and from the sun exposure of the infant [59].

Congenital pigmentary nevi over 20 cm in diameter have an increased risk of malignancy.

Pigmentary nevi are commonly diagnosed clinically or using the dermatoscope.

The management of pigmentary nevi depends on the type of nevus and the degree of uncertainty of the diagnosis. Benign ones require nothing else than monitoring after the neonatal period [60, 61], while those with special characteristics - asymmetry, uneven, irregular margins, color variations, diameter > 6 mm - very rare cases, require biopsy with histopathology, immunohistochemistry and electron microscopy [57, 62].

4.5. Minor hand anomalies

4.5.1. *Camptodactyly*

Camptodactyly is the irreversible flexion of one or both interphalangeal joints at the level of one or more fingers, being most frequently a congenital condition.

It can be diagnosed antenatally [63–65] “in utero” or postnatally, being a clinically obvious deformity, which subsequently requires imaging investigations. An abnormal insertion of lumbrical and flexor digitorum tendons of the hand is often noted.

Camptodactyly may occur sporadically, de novo or by autosomal dominant inheritance.

It may be an isolated clinical manifestation or clinical expression in syndromes such as Trisomy 18 and 13, Freeman Sheldon Syndrome, Pena Shokeir Syndrome, CACP Syndrome (Camptodactyly, Arthropathy, Coxa vara, Pericarditis), arthrogryposis [63, 65–67].

4.5.2. *Clinodactyly*

Clinodactyly is a congenital malformation consisting of the lateral deflection of the fingers by affecting the first interphalangeal joint, which interests any finger, especially the pollex and the auricular fingers (the fifth finger), (**Figure 11**).

Clinodactyly is a descriptive term, which refers to a radial angulation at a common interphalangeal joint in radio-ulnar or palmar planes, and can often be a normal anatomical variant.

The incidence varies, ranging between 1 and 18%, as it is most frequently under-reported.

Clinodactyly may be a very common isolated clinical manifestation in the context of a family history [68] - with autosomal recessive inheritance, but it may also occur in several syndromes, in association with other locomotor abnormalities or in other organs and systems.

Clinodactyly is seen in over 60% of children with Down syndrome [63], Klinefelter syndrome, trisomy 18, Turner syndrome, Cornelia de Lange Syndrome, Feingold Syndrome, Roberts Syndrome, Russell-Silver Syndrome or Fanconi Syndrome. It may also be a clinical manifestation associated with other abnormalities such as macrodystrophia lipomatosa and brachydactyly type A3.

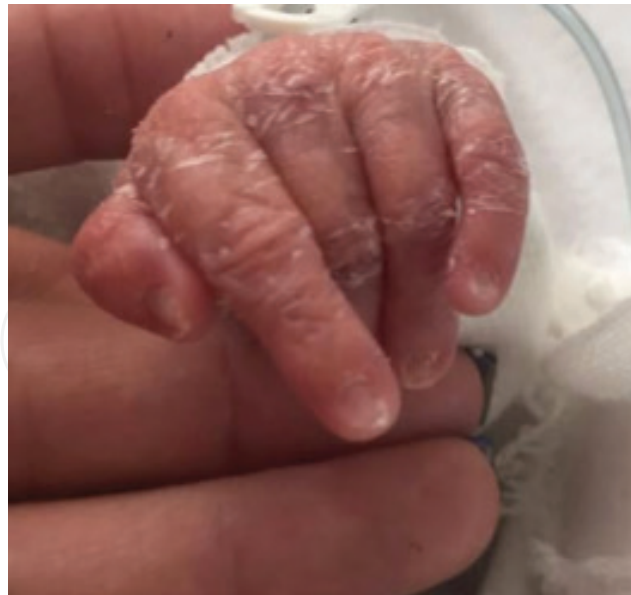

Figure 11. Clinodactyly of the fifth finger.

Considering the presence of this sign in multiple chromosomal anomalies, some authors consider it a “soft sign”, if detected in an antenatal ultrasound scan.

If the clinodactyly is isolated, it has an excellent prognosis.

Usually, the treatment is not necessary. If necessary - because of emotional stress due to esthetic reasons or the impairment of the fine hand movements - the treatment is surgical [69]. For surgery, preoperative radiographs of the pollex are performed, establishing the size of the graft and the degree of angulation necessary to restore the normal function of the distal phalange.

4.5.3. Polydactyly

It is one of the most common congenital abnormalities of upper limbs, seen in all ethnicities, and it refers to the presence of additional fingers, being usually bilateral [70]. Most often, polydactyly affects the upper and lower limbs synchronously. Supernumerary fingers do not usually have adequate muscle connections [71, 72].

The classification of this condition is based on the location of the additional fingers, the polydactyly being:

- Postaxial (duplicated finger V),
- Mesoaxial/central (duplication of fingers II, III, IV),
- Preaxial (duplicated thumb),
- Mixed.

Polydactyly may appear isolated, *de novo*, sometimes autosomal dominant inherited or may be associated with syndromes [73, 74] such as Bardet-Biedl Syndrome, Carpenter Syndrome, Elis-Van Creveld Syndrome, Fanconi Syndrome, Greig Syndrome, Holt-Oram Syndrome, Meckel-Gruber

Syndrome, Pallister-Hall Syndrome, Smith-Lemli-Opitz Syndrome, Trisomy 13, Trisomy 18, Short Rib Polydactyly Syndrome Type I (Saldino-Noonan Type) (Majewski type), Trisomy 21, Townes-Brocks Syndrome.

Usually, polydactyly is diagnosed antenatally, but if it is postnatally discovered, it requires paraclinical investigations in order to be included in one of the genetic syndromes, except for cases of family history. The investigations are performed using imaging techniques (MRI, CT scan, ultrasound examination), followed by genetic consultation in case of association with other malformations. The most commonly associated malformations are syndactyly, hypoplasia or aplasia of long bones, hydrocephalus, microcephaly, spina bifida, ventricular septal defect, atrial septal defect, esophageal atresia, duodenal atresia, anal imperfection, abdominal wall defects, renal agenesis, polycystic kidney disease, hydronephrosis, diaphragmatic hernia, anophthalmia, cheilopalatoschisis.

In the case of isolated polydactyly, no treatment is required. If this anomaly affects the mobility and gross/fine movements of the fingers/hands, the treatment is always surgical.

4.6. Minor foot anomalies

4.6.1. *Partial syndactyly of the second and third toe*

Syndactyly is one of the most common congenital limb malformations involving the fusion of two or more fingers due to the failure of separation process during the development of limbs in the first trimester. In the lower limbs, the most common location is between the second and the third finger [75].

It is a heterogeneous clinical phenotype, as it may be: unilateral or bilateral, symmetrical or asymmetrical, partial or complete, cutaneous or bony, involving only the phalanges and/ or metatarsal bone, or may extend to tarsal bones or even the calf bones.

Partial syndactyly of the second and third toe may appear as a clinically isolated phenotype (the most common is zygodactyly) [75] or may be associated with syndromes such as:

- Pfeiffer syndrome [76–79] - type V acrocephalopolysyndactyly has as its etiology a dominant autosomal genetic defect in which mutations occur in the FGFR1 gene (fibroblast growth factor receptor 1) and in the FGFR2 gene (fibroblast growth factor receptor 2). In this syndrome, the partial syndactyly of the second and third toe is accompanied by other malformations such as craniosynostosis, facial hypoplasia, hypertelorism, brachydactyly.
- Carpenter syndrome - type II acrocephalopolysyndactyly is an autosomal recessive genetic disorder in which mutations occur in RAB23, a hydrolysis involved in transmembrane regulation [80]. Carpenter syndrome associates, besides partial syndactyly and polydactyly, with auricular, cardiac and genital abnormalities.
- Smith-Lemli-Opitz syndrome is an autosomal recessive genetic disorder of cholesterol biosynthesis [81]. This syndrome associates with syndactyly and microcephaly, micrognathia, genital malformations, auricular malformations, autism spectrum disorders.

Partial syndactyly of the second and third toe does not affect the motor function, and therefore does not require correction.

4.6.2. *Dysplastic nails*

Insufficient development of nails [82] may occur in isolation or in many genetic malformations such as:

- Simpson-Golabi-Behmel Syndrome (Bulldog Syndrome). The most common etiology of this syndrome is the mutations in the GPC3 gene to chromosome X [83]. Nail hypoplasia is accompanied by other clinical manifestations such as macrosomia, hypertelorism, polydactyly, macrostomia, macroglossia.
- Fetal Alcohol Syndrome [84]. Prenatal exposure to alcohol causes numerous fetal malformations, including nail dysplasia accompanied by: microcephaly, facial hirsutism, short palpebral fissures.
- Fryns Syndrome. This syndrome is a genetic disorder inherited in an autosomal recessive manner, in which dysplastic nails occur along with other minor and major malformations such as diaphragmatic hernia, hirsutism, distal phalangeal hypoplasia, Dandy-Walker malformation, agenesis of corpus callosum.

4.6.3. *Phalanx anomalies: digital deformities*

The small bones and soft tissues of the feet can be affected by systemic disorders, and frequently, the findings are quite unique and virtually help diagnose some genetic or metabolic disorders [85]. Sometimes the changes in the structural bones of the feet, metacarpals and metatarsals, or the phalangeal units are so astonishing that they ensure the diagnosis of peculiar and rare syndromes.

There are many disorders – some genetic, some neoplastic, some inflammatory – which sometimes produce extraordinary changes in the patient's feet. In some cases, phalanx abnormalities occur as a result of the sucking of the finger by the fetus, causing elongation and hypertrophy (Figures 12 and 13).

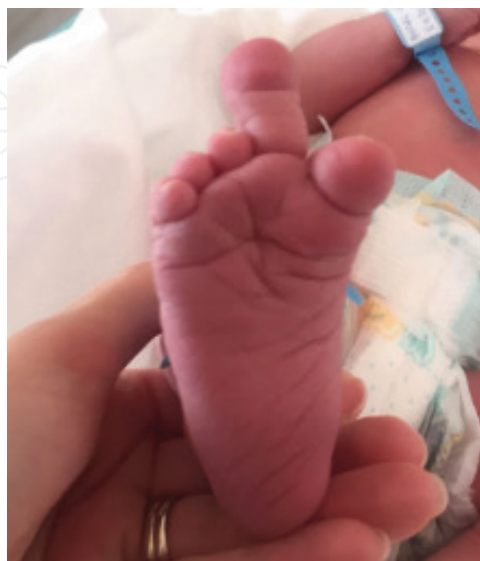

Figure 12. Phalanx anomalies.

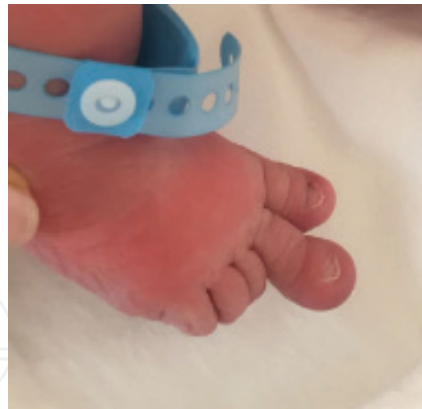

Figure 13. Phalanx anomalies.

A small listing includes synovial chondromatosis, fibrous dysplasia, tumoral calcinosis, Maffucci syndrome, Ollier's disease, hereditary multiple osteocartilaginous exostosis, type 1 neurofibromatosis, pigmented villonodular synovitis, hyperparathyroidism, or gout.

Author details

Simona Vlădăreanu^{1*}, Mihaela Boț¹, Costin Berceanu², Claudia Mehedințu¹ and Simona Popescu¹

*Address all correspondence to: simconst69@gmail.com

1 University of Medicine and Pharmacy "Carol Davila", Bucharest, Romania

2 University of Medicine and Pharmacy of Craiova, Romania

References

- [1] Tewari VV, Mehta R, Tewari K. Dysmorphic neonate: An approach diagnostic in the current era. *Pediatric Dimensions*. ISSN: 2397-950X
- [2] Jones LK, Adam MP. Evaluation and diagnosis of the dysmorphic infant. *Clinics in Perinatology*. 2015 Jun;**42**(2):243-248. DOI: 10.1016/j.clp.2002.002
- [3] Adam M, Hudgins L. The importance of minor anomalies in the evaluation of the newborn. *NeoReviews*. 2003;**4**:e99-e104
- [4] Lobo I, Zhaurova K. Birth defects: Causes and statistics. *Nature Education*. 2008;**1**(1):18
- [5] Shapira M, Borochowitz ZU. Asymmetric crying facies. *NeoReviews*. 2009;**10**:e502-e509
- [6] Cancrini C, Puliafito P, Digilio MC, et al. Clinical features and follow-up in patients with 22q11.2 deletion syndrome. *The Journal of Pediatrics*. 2014;**164**:1475-1480

- [7] Tollefson MM. Aplasia cutis congenita. *NeoReviews*. 2012;**13**:e285-e292
- [8] Wan J. Aplasia Cutis Congenita. *Medscape*. Updated: May 12, 2017
- [9] Yoshihara A, Noh J, Yamaguchi T, et al. Treatment of graves' disease with antithyroid drugs in the first trimester of pregnancy and the prevalence of congenital malformation. *The Journal of Clinical Endocrinology and Metabolism*. 2012;**97**:2396-2403
- [10] Cohen I, Silberstein E, Perez Y, et al. Autosomal recessive Adams-Oliver syndrome caused by homozygous mutation in EOGT, encoding an EGF domain-specific O-GlcNAc transferase. *European Journal of Human Genetics*. 2014;**22**:374-378
- [11] Carey J. Trisomy 18 and 13 syndromes. In: Cassidy S, Allanson J, editors. *Management of Genetic Syndromes*. 3rd. New York: John Wiley & Sons; 2010. pp. 807-823
- [12] Kumar P, Burton B. Congenital Malformation. Evidence-Based Evaluation and Management. McGrawHill Medical 2008. 0-07-159356-X. Chapter 14. Micrognathia. Pg 101-104
- [13] Sperber GH. Craniofacial Development. London: BC Decker Inc; 2001. pp. 127-138
- [14] Bowling B. Congenital malformations: Epicanthic folds. In: Kanski's Clinical Ophthalmology: A Systematic Approach. 8th ed. S.l.: Elsevier; 2016. p. 57
- [15] Li G, Wu Z, Tan J, Ding W, Luo M. Correcting Epicanthal folds by using asymmetric Z-plasty with a two curve design. *Journal of Plastic, Reconstructive & Aesthetic Surgery*. 2016;**69**(3):438-440. Web. 20 Apr. 2017
- [16] Montagu A. *Growing Young*. N.Y: McGraw Hill; 1989. p. 40
- [17] Hammer. In: McPhee SJ, Gary D, editors. "Pathophysiology of Selected Genetic Diseases". *Pathophysiology of Disease: An Introduction to Clinical Medicine*. 6th ed. New York: McGraw-Hill Medical; 2010. Chapter 2. ISBN: 978-0-07-162167-0
- [18] Pham V. *Common Otolaryngological Congenital Abnormalities*. UTMB, Dept. of Otolaryngology; 2010
- [19] Kalyanasundaram S. Peroxisomal disorder-unusual presentation as failure to thrive in early infancy. *Indian Journal of Pediatrics*. 2010;**77**:1151-1152
- [20] Foster JA et al. *Basic and Clinical Science Course: Section 7*. American Academy of Ophthalmology; 2016-2017
- [21] Goldberger E. Epicanthus and its variants among Caucasians. *Archives of Ophthalmology*. 1936;**16**(3):506-515. Web. 20 Apr. 2017
- [22] Bentz LM, by Renato Ocampo, John A. Persing. *Pediatric Plastic Surgery, Hypertelorism*
- [23] Dollfus H, Verloes A. Developmental anomalies of the lids. In: Hoyt CS, Taylor D, editors. *Pediatric Ophthalmology and Strabismus*. 4th ed. Elsevier Saunders; 2013:chap 18
- [24] Bartel-Friedrich S, Wulke C. Classification and diagnosis of ear malformation. *GMS Current Topics in Otorhinolaryngology - Head and Neck Surgery*. 2007;**6**: Doc05. Published online 2008 Mar 14

- [25] Zou F, Peng Y, Wang X, et al. A locus for congenital preauricular fistula maps to chromosome 8q11.1-q13.3. *Journal of Human Genetics*. 2003;**48**(3):155-158
- [26] Ostrower ST, Bent JP. Preauricular Cysts, Pits, and Fissures. *Otolaryngology and Facial Plastic Surgery*. Medscape; Updated: Feb 07, 2017
- [27] Heike CL, Hing AV, Aspinall CA, et al. Clinical care in craniofacial microsomia: A review of current management recommendations and opportunities to advance research. *American Journal of Medical Genetics. Part C, Seminars in Medical Genetics*. 2013;**163C**:271-282
- [28] Kugelman A, Tubi A, Bader D, et al. Pre-auricular tags and pits in the newborn. *The Journal of Pediatrics*. 2002;**141**:388-391
- [29] Wang RY, Earl DL, Ruder RO, et al. Syndromic ear anomalies and renal ultrasounds. *Pediatrics*. 2001;**108**:e32-e32
- [30] Andersen SL, Olsen J, Wu CS, et al. Severity of birth defects after propylthiouracil exposure in early pregnancy. *Thyroid*. 2014 Jun 25
- [31] De la Cruz A, Kesser BW (1999). "Management of the unilateral atretic ear". In Pensak M. *Controversies in Otolaryngology – Head and Neck Surgery*. New York: Thieme Medical Publishers. pp. 381-385
- [32] Harris J, Källén B, Robert E. The epidemiology of anotia and microtia. *Journal of Medical Genetics*. 1996;**33**(10):809
- [33] Luquetti DV, Heike CL, Hing AV, Cunningham ML, Cox TC. Microtia: Epidemiology & genetics. *American Journal of Medical Genetics. Part A*. 2012 Jan;**158A**(1):124-139
- [34] Katsanis SH, Cutting GR (July 2004). "Treacher Collins Syndrome". *GeneReviews*
- [35] Brent B. Auricular repair with autogenous rib cartilage grafts: Two decades of experience with 600 cases. *Plastic and Reconstructive Surgery*. 1992;**90**(3):355-374
- [36] Llano-Rivas I, González-del Angel A, del Castillo V, et al. Microtia: A clinical and genetic study at the National Institute of pediatrics in Mexico City. *Archives of Medical Research*. 1999;**30**:120
- [37] Kountakis SE, Helidonis E, Jahrsdoerfer RA. Microtia grade as an indicator of middle ear development in aural atresia. *Archives of Otolaryngology – Head & Neck Surgery*. 1995;**121**(8):885-886
- [38] Jahrsdoerfer RA, Kesser BW. Issues on aural atresia for the facial plastic surgeon. *Facial Plastic Surgery*. 1995;**11**(4):274-277
- [39] Eavey RD. Ear malformations. What a pediatrician can do to assist with auricular reconstruction. *Pediatric Clinics of North America*. 1996;**43**:1233
- [40] Brent B. Technical advances in ear reconstruction with autogenous rib cartilage grafts: Personal experience with 1200 cases. *Plastic and Reconstructive Surgery*. 1999;**104**(2):319
- [41] Reiffel AJ, Kafka C, Hernandez KA, Popa S, Perez JL, Zhou S, Pramanik S, Brown BN, Ryu WS, Bonassar LJ, Spector JA. High-fidelity tissue engineering of patient-specific auricles for reconstruction of pediatric microtia and other auricular deformities. *PLoS One*. 2013;**8**(2):e56506 Epub 2013 Feb 20

- [42] Buyse ML. Birth Defect. Encyclopedia Blackwell Scientific Publishing; 1990. p. 590
- [43] Iubbs HA. A marker X chromosome. American Journal of Human Genetics. 1969;**21**:231
- [44] Verloes A, Lesenfants S, Philippet B, Iyawa A, Laloux F, Koulischer L. Genetic Counseling. 1996;**7**(4):277-282
- [45] Rapini RP, Bologna JL, Jorizzo JL. Dermatology: 2-Volume Set. St. Louis: Mosby; 2007. ISBN: 1-4160-2999-0
- [46] James W, Berger T, Elston D. Andrews' Diseases of the Skin: Clinical Dermatology. 10th ed. Saunders; 2005
- [47] Chinnadurai S, Fonnesbeck C, Snyder KM, Sathe NA, Morad A, Likis FE, McPheeters ML. Pharmacologic interventions for infantile hemangioma: A meta-analysis. Pediatrics. February 2016:137
- [48] Congenital Dermal Melanocytosis (Mongolian Spots): <http://emedicine.medscape.com/article/1068732oveview>
- [49] Montegudo B, Labandeira J, León-Muiños E, Carballeira I, Corrales A, Cabanillas M. Prevalence of birthmarks and transient skin lesions in 1000 Spanish newborns. Actas Dermo-Sifiliográficas. 2011 May;**102**(4):264-269
- [50] Kanada KN, Merin MR, Munden A, Friedlander SF. A prospective study of cutaneous findings in newborns in the United States: Correlation with race, ethnicity, and gestational status using updated classification and nomenclature. The Journal of Pediatrics. 2012 Aug.;**161**(2):240-245
- [51] Ashrafi MR, Shabani R, Mohammadi M, Kavusi S. Extensive Mongolian spots: A clinical sign merits special attention. Pediatric Neurology. 2006 Feb;**34**(2):143-145
- [52] Amitai DB, Fichman S, Merlob P, et al. Cutis marmorata telangiectatica congenita: Clinical findings in 85 patients. Pediatric Dermatology. 2000 Mar-Apr;**17**(2):100-104
- [53] Torrelo A, Zambrano A, Happle R. Cutis marmorata telangiectatica congenita and extensive mongolian spots: Type 5 phacomatosis pigmentovascularis. The British Journal of Dermatology. 2003 Feb;**148**(2):342-345
- [54] Petrozzi JW, Rahn EK, Mofenson H, et al. Cutis marmorata telangiectatica congenita. Archives of Dermatology. 1970 Jan;**101**(1):74-77
- [55] Bormann G, Wohlrab J, Fischer M, et al. Cutis marmorata telangiectatica congenita: Laser doppler fluxmetry evidence for a functional nervous defect. Pediatric Dermatology. 2001Mar-Apr;**18**(2):110-113
- [56] Melani L, Antiga E, Torchia D, et al. Cutis marmorata telangiectatica congenita and chronic autoimmune urticaria in a young man. The Journal of Dermatology. 2007 Mar;**34**(3):210-213
- [57] Ancillary Techniques in Diagnosing Melanocytic Lesions. Melanocytic Lesions - Springer. DOI: 10.1007/978-1-4939-0891-2
- [58] Dysplastic(Atypical)Nevi.MelanocyticLesions-Springer.DOI:10.1007/978-1-4939-0891-2

- [59] Benign Neoplasias and Hyperplasias of Melanocytes. Fitzpatrick's Dermatology in General Medicine. Chapter 122. The McGraw-Hill Companies, Inc; 2012. ISBN: 978-0-07-166904-7
- [60] Neonatal, Pediatric, and Adolescent Dermatology. Fitzpatrick's Dermatology in General Medicine. Chapter 107. The McGraw-Hill Companies, Inc; 2012. ISBN: 978-0-07-166904-7
- [61] Rigel Darrell S, Julie R, Robert F. The evolution of melanoma diagnosis: 25 years beyond the ABCDs. CA: a Cancer Journal for Clinicians. 2016;**60**(5):301-316. ISSN: 1542-4863. PMID: 20671054. DOI: 10.3322/caac.20074
- [62] Scope A, Marchetti MA, Marghoob AA, Dusza SW, Geller AC, Satagopan JM, Weinstock MA, Berwick M, Halpern AC. The study of nevi in children: Principles learned and implications for melanoma diagnosis. Journal of the American Academy of Dermatology. 2016;**75**(4):813-823. PMC: 5030195. PMID: 27320410. DOI: 10.1016/j.jaad.2016.03.027
- [63] Rypens F, Dubois J, Garel L, et al. Obstetric US: Watch the fetal hands. Radiographics;**26**(3): 811-829. DOI: 10.1148/rg.263055113
- [64] Schmitt R, Lanz U, Buchberger W. Diagnostic Imaging of the Hand. Thieme Medical Pub; 2008 ISBN:1588904539
- [65] Gupta P, Sharma JB, Sharma R, et al. Antenatal ultrasound and MRI findings of Pena-Shokeir syndrome. Archives of Gynecology and Obstetrics. 2010. DOI: 10.1007/s00404-010-1703-y
- [66] Bahabri SA, Suwairi WM, Laxer RM, et al. The camptodactyly-arthropathy-coxa vara-pericarditis syndrome: Clinical features and genetic mapping to human chromosome 1. Arthritis and Rheumatism. 1998;**41**(4):730-735. DOI: 10.1002/1529-0131(199804)41:4<730::AID-ART22>3.0.CO;2-Y
- [67] Leung AK, Kao CP. Familial clinodactyly of the fifth finger. Journal of the National Medical Association. 2003;**95**(12):1198-1200
- [68] Eggermann T, Begemann M, Spengler S, et al. Genetic and epigenetic findings in silver-Russell syndrome. Pediatric Endocrinology Reviews. 2010;**8**(2):86-93
- [69] Flatt AE. The troubles with pinkies. Proceedings (Baylor University Medical Center). 2005;**18**(4):341-344
- [70] Castilla EE, Lugarinho da Fonseca R, da Graca Dutra M, et al. Epidemiological analysis of rare polydactylies. American Journal of Medical Genetics. Nov 1996;**65**(4):295-303
- [71] Sadler TW. Langman's Embriologie Medicala editia a X a
- [72] Kumar P, Burton BK. Congenital malformations, Evidence based Evaluation and Management
- [73] Zhou GX, Dai L, Zhu J, et al. Epidemiological analysis of polydactylies in Chinese perinatals. Sichuan Da Xue Xue Bao. Yi Xue Ban. Sep 2004;**35**(5):708-710
- [74] Castilla EE, Lugarinho R, da Graca Dutra M, et al. Associated anomalies in individuals with polydactyly. American Journal of Medical Genetics. Dec 1998;**80**(5):459-465

- [75] Malik S. Syndactyly: Phenotypes, genetics and current classification. *European Journal of Human Genetics*. 2012 Aug;**20**(8):817-824. DOI: 10.1038/ejhg.2012.14
- [76] Vogels A, Fryns JP. Pfeiffer syndrome. *Orphanet Journal of Rare Diseases*. 2006;**1**:19. DOI: 10.1186/1750-1172-1-19
- [77] Muenke M, Schell U, Hehr A, Robin NH, Losken HW, Schinzel A, et al. A common mutation in the fibroblast growth factor receptor 1 gene in Pfeiffer syndrome. *Nature Genetics*. 1994;**8**(3):269-274. DOI: 10.1038/ng1194-269
- [78] Rutland P, Pulleyn LJ, Reardon W, Baraitser M, Hayward R, Jones B, et al. Identical mutations in the FGFR2 gene cause both Pfeiffer and Crouzon syndrome phenotypes. *Nature Genetics*. 1995;**9**(2):173. DOI: 10.1038/ng0295-173
- [79] Schell U, Hehr A, Feldman GJ, Robin NH, Zackai EH, de Die-Smulders C, et al. Mutations in FGFR1 and FGFR2 cause familial and sporadic Pfeiffer syndrome. *Human Molecular Genetics*. 1995;**4**(3):323-328. DOI: 10.1093/hmg/4.3.323
- [80] Perlyn C, Marsh J. Craniofacial dysmorphology of carpenter syndrome: Lessons from three affected siblings. *Plastic and Reconstructive Surgery*. March 2008;**121**(3):971-981. PMID: 18317146. DOI: 10.1097/01.prs.0000299284.92862.6c
- [81] Nowaczyk MJM, Wayne JS. The Smith-Lemli-Opitz syndrome: A novel metabolic way of understanding developmental biology, embryogenesis, and dysmorphology. *Clinical Genetics*. 2001;**59**(6):375-386. PMID: 11453964. DOI: 10.1034/j.1399-0004.2001.590601.x
- [82] D'Souza SW, Robertson IG, Donnai D, Mawer G. Fetal phenytoin exposure, hypoplastic nails, and jitteriness. *Archives of Disease in Childhood*. 1991 Mar;**66**(3):320-324
- [83] DeBaun MR, Ess J, Saunders S. Simpson Golabi Behmel syndrome: Progress toward understanding the molecular basis for overgrowth, malformation, and cancer predisposition. *Molecular Genetics and Metabolism*. 2001;**72**(4):279-286. PMID: 11286501. DOI: 10.1006/mgme.2001.3150
- [84] Committee to Study Fetal Alcohol Syndrome, Division of Biobehavioral Sciences and Mental Disorders, Institute of Medicine. *Fetal Alcohol Syndrome: Diagnosis, Epidemiology, Prevention, and Treatment*. Washington, D.C.: National Academy Press; 1995. ISBN: 0-309-05292-0
- [85] Mankin HJ, Jupiter J, Trahan CA. Hand and foot abnormalities associated with genetic diseases. *Hand (New York, N.Y.)*. 2011 Mar;**6**(1):18-26. Published online 2010 Oct 26. DOI: 10.1007/s11552-010-9302-8

