

We are IntechOpen, the world's leading publisher of Open Access books Built by scientists, for scientists

4,800

Open access books available

122,000

International authors and editors

135M

Downloads

Our authors are among the

154

Countries delivered to

TOP 1%

most cited scientists

12.2%

Contributors from top 500 universities



WEB OF SCIENCE™

Selection of our books indexed in the Book Citation Index
in Web of Science™ Core Collection (BKCI)

Interested in publishing with us?
Contact book.department@intechopen.com

Numbers displayed above are based on latest data collected.
For more information visit www.intechopen.com



Robotic Hiatal Hernia Repair

Konstantinos Konstantinidis,
Michael Konstantinidis, Savvas Hirides and
Petros Hirides

Additional information is available at the end of the chapter

<http://dx.doi.org/10.5772/intechopen.71164>

Abstract

Robotic surgery has revolutionized medicine during the last 16 years by transformation of the classic operating theaters into computer-mediated working stations. Numerous procedures have been proved to be feasible and safe by using the continuously evolving, various robotic platforms. From the early beginnings of this revolution, challenging operations such as those concerning the gastroesophageal junction, especially in super-obese patients or during redo operations, proved out to have certain benefits when performed robotically, both for patients as well as for surgeons.

Keywords: robotic surgery, gastroesophageal reflux, cruroplasty, Nissen fundoplication, Toupet fundoplication

1. Introduction

From the early introduction of robotic surgical systems, upper gastrointestinal (GI) surgery has been one of the most promising areas of application. Numerous reports for successful robotic hiatal hernia and gastroesophageal reflux disease (GERD) surgery have been published [1–6]. Nissen fundoplication is the most commonly performed fundoplication. Partial fundoplications can be performed by adjusting the extent of the wrap. In any case, the main stages of the operation are performed according to the following description of the robotic Nissen fundoplication.

Indications:

- Symptomatic sliding hiatal hernia—GERD, esophagitis
 - Paraesophageal hernia
-

Contraindications:

- Nonspecific
- Intolerance to anesthesia or laparoscopy. Bleeding tendency
- Relative: morbid obesity. Previous operations in the upper abdomen. Strictures from extensive esophagitis

Patient preparation:

- Gastrographin swallow
- Upper GI endoscopy (EGD)
- Esophageal manometry
- 24-h pH testing (not obligatory if patient presents with typical symptomatology)
- NPO for at least 8 h before the operation
- Admission at the day of surgery
- CXR, ECG, CBC, APTT, and INR at the day of surgery
- Preoperative antibiotic coverage (single dose at induction of anesthesia)

Operating room setup:

- da Vinci crew – technical support always necessary to be present
- Laparoscopic set availability (for the rare event of conversion)

Positioning of the patient and the robot:

- Anti-trendelenburg (**Image 1**)
- Robot comes in line with the camera port and the hiatus (**Image 2**)
- The surgeon should ensure continuous communication with the bedside assistants
- Bedside assistants should be experienced laparoscopic surgeons with certified training in the use of robotics

Pneumoperitoneum and trocar sites:

- 12 mm incision, 8 cm below the xiphoid and two fingerbreadths laterally to the midline (toward the left side of the patient)
- Pneumoperitoneum induction is done by using the Hasson technique. Alternatively, pneumoperitoneum may be induced by OptiView trocar (camera arm) by using 0° laparoscopic

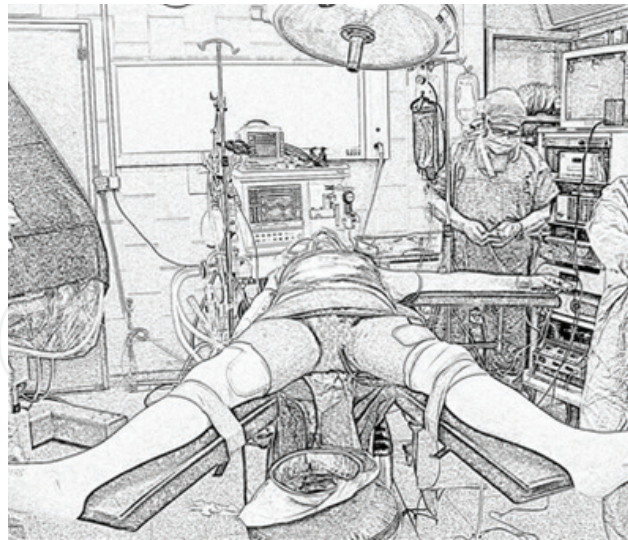


Image 1. Patient in supine position with legs apart.

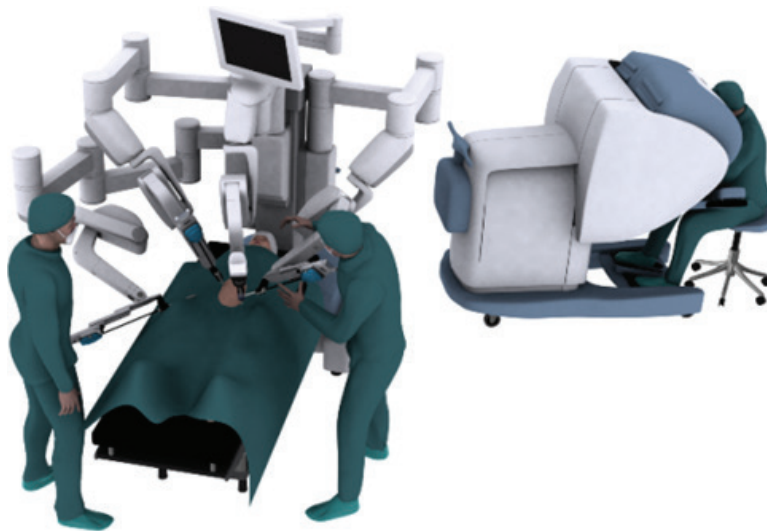


Image 2. Positioning of the robot and team. The robot should be positioned at an axis created by the camera port and the hiatus. The surgeon should ensure continuous communication with the bedside assistants.

camera. In this case, make sure to recognize all layers of the anterior abdominal wall (subcutaneous fat, anterior sheath, muscular layer, and posterior sheath)

- Initial check of the abdomen to exclude other pathology can be performed with laparoscopic maneuvers, by holding the robotic camera and rotating to all four abdominal quadrants
- Three additional robotic trocars (8 mm) are inserted: left (Arm 1) and right (Arm 2) mid-clavicular and right anterior axillary line (fourth arm for retracting the liver). Incisions for trocars #1 and #2 should be done at least 3–4 cm below the costal margins and at an 8 cm distance from the camera port. A sterilized ruler may be used to confirm correct distance between ports

- One or even two (especially in the initial experience of the team) 5 mm assistant trocars can be added according to the needs of the operation. The first one is placed between camera port and trocar #1. The second one is placed between camera port and trocar #2 (Image 3a and 3b)

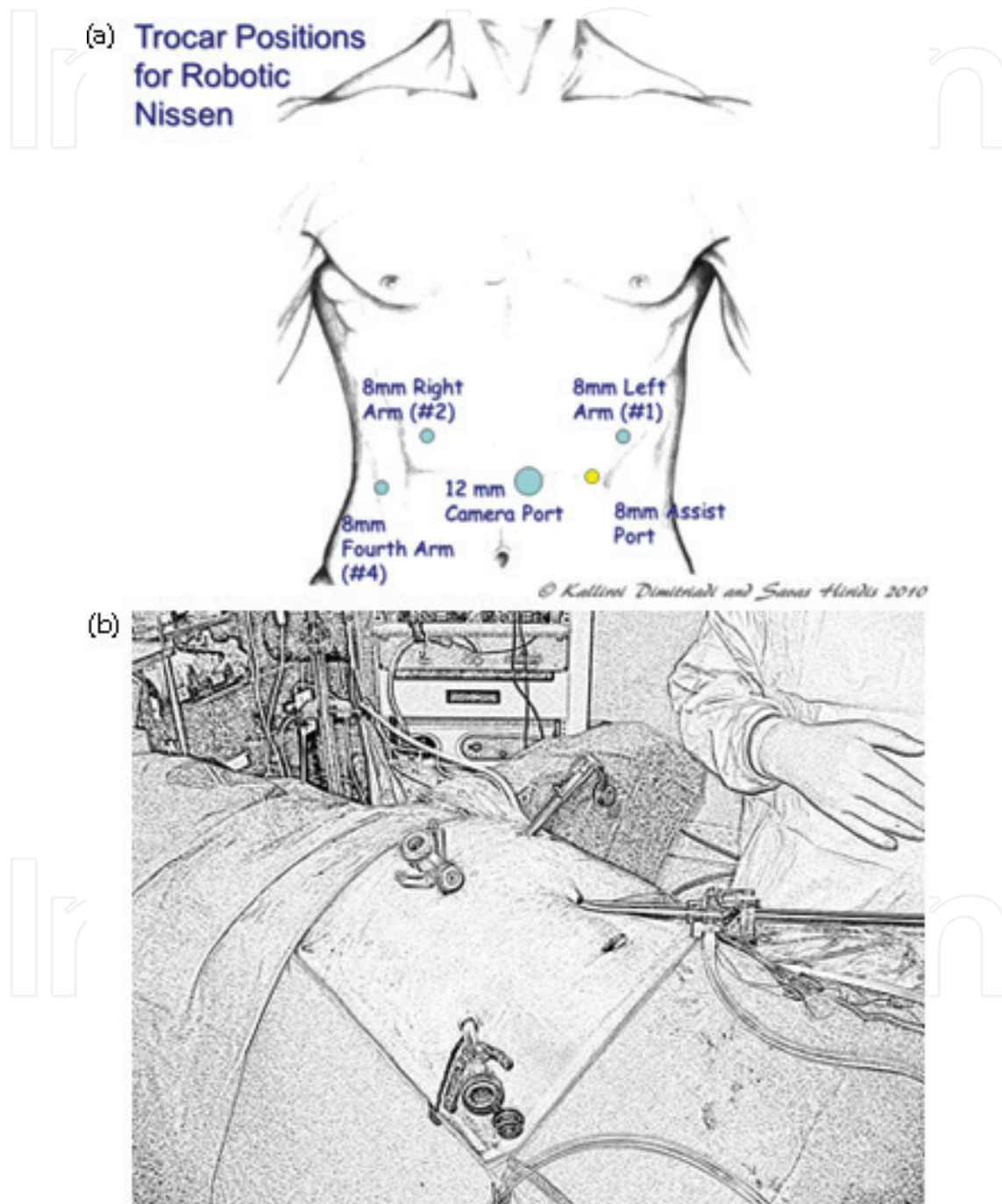


Image 3. (a) Trocar positions for robotic Nissen. (b) Initial check of the abdomen with conventional laparoscopy, using the robotic camera.

2. Console setup parameters

In the present systems, setup of the console parameters remains quite simple and is usually done before the operation with the assistance of technical staff responsible for the system. The surgeon must adjust the position of his chair, his arm-rest and the lenses in order to achieve the optimal ergonomics. In the end, he can save these settings in his account, so that the system restores exactly the same position every time he logs in. Using the TilePro System, you may import images of patient's preoperative exams within the system for final considerations.

3. Stages of the procedure

3.1. Exposure

Install the liver retractor on Arm 4 and slowly retract the liver, exposing the gastroesophageal junction. Retraction of the liver is accomplished using Arm 4 with the Robotic Graptor. Alternatively, a bowel grasper can be used. Ask the bedside assistant to insert a laparoscopic grasper through the left lateral 5 mm port and retract the stomach laterally and inferiorly. This traction is mandatory throughout the whole procedure for the proper exposure of the gastroesophageal junction (**Image 4**).

3.2. Dissection in the lesser omentum

Install the Cadere forceps on Arm 2 and the Monopolar Hook Cautery on Arm 1 (remember to use a reducer if the 5 mm Hook Cautery will be used). By gentle traction of the lesser omentum, create a window between the stomach and the liver edge (hepatogastric ligament), just

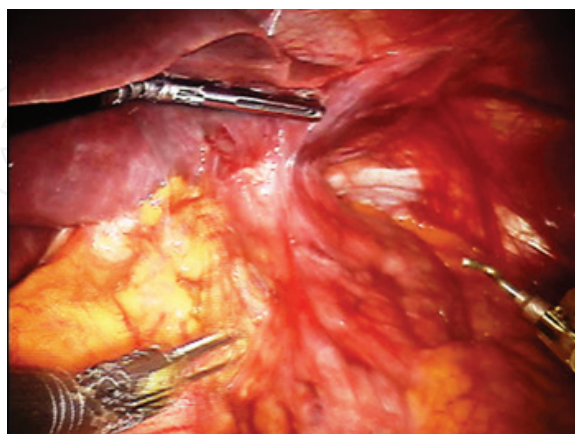


Image 4. Retraction of the liver using Arm 4 with the robotic Graptor. Retraction of the stomach is accomplished by a laparoscopic grasper from the bedside assistant.

above the caudate lobe of the liver. Beware to protect the right (hepatic) branch of the vagus nerve or any ectopic left hepatic arteries (that can be found next to the right branch), as you proceed proximally (**Image 5**).

3.3. Dissection at the crura and around the esophagus

As soon as the crural region was reached, careful dissection and stripping of the crura should take place. We usually dissect the right crus first. Dissection proceeds slowly with division of the superior portion of the phrenoesophageal ligament and toward the anterior surface of the left crus. Beware to protect the anterior branch of the vagus nerve, although stable traction ensured by the assistant trocar usually make it easily visible. Avoid grasping the esophagus at all times during the operation. Instead remember to ask for more traction on the stomach as the mobilization proceeds, exerted from the laparoscopic grasper of the bedside assistant. After complete dissection around the crura, mobilization of the esophagus is initiated by division of the numerous short adhesions to the crura. Extending this dissection as proximally as possible to ensure an adequate part of movable esophagus (at least 4 cm of esophagus should be able to move below the diaphragm without any tension). At this phase, a paraesophageal lipoma may be met, usually situated between the esophagus and the left crus. This is often rather voluminous and bleeds easily. Gently grasp with the robotic forceps (Arm #2) and pull back inside the abdominal cavity, while cauterizing any adhesions with the monopolar hook (Arm #1). After completion of the dissection, excise the lipoma and leave it under the liver but remember to remove before ending the operation (**Image 6**).

3.4. Creating the posterior window

Ask the bedside assistant to expose the angle between the right crus and the esophagus and start dissecting around the esophagus in a posterior direction. Take your time here because

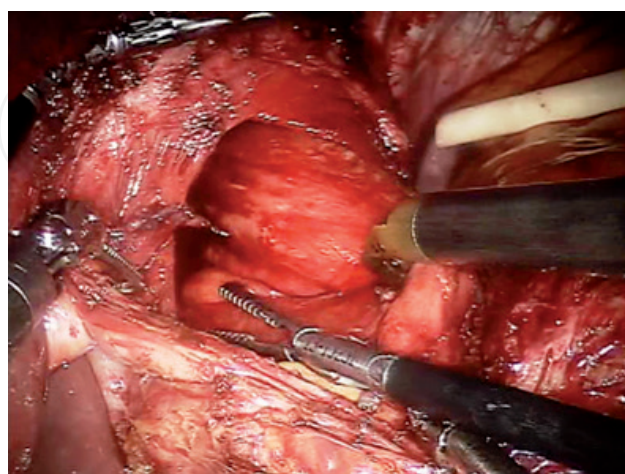


Image 5. View of the field after complete dissection of the hepatogastric ligament. On the left, the right crus is fully exposed. Inferiorly, the hepatic branch of the vagus nerve has been preserved.

apart from hurting esophagus itself, it is crucial to recognize and dissect the posterior branch of the vagus nerve at this point. Control any minor bleeding by using the robotic bipolar forceps. Avoid using monopolar for hemostasis (**Image 7**).

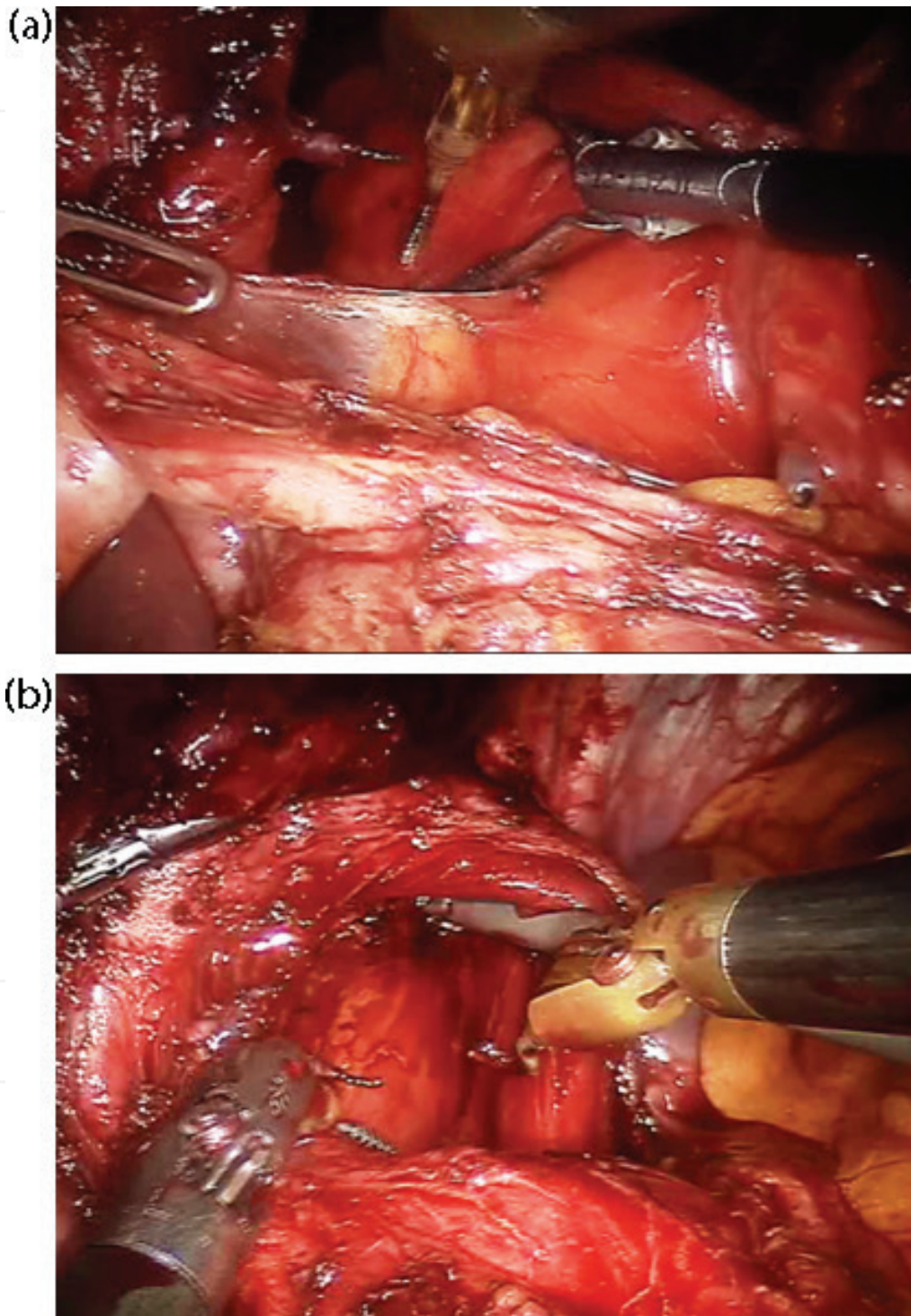


Image 6. (a) After complete dissection around the crura, mobilization of the esophagus is initiated by division of the numerous short adhesions to the crura. (b) Exposure of the left crus and dissection of its attachments to the lower esophagus.

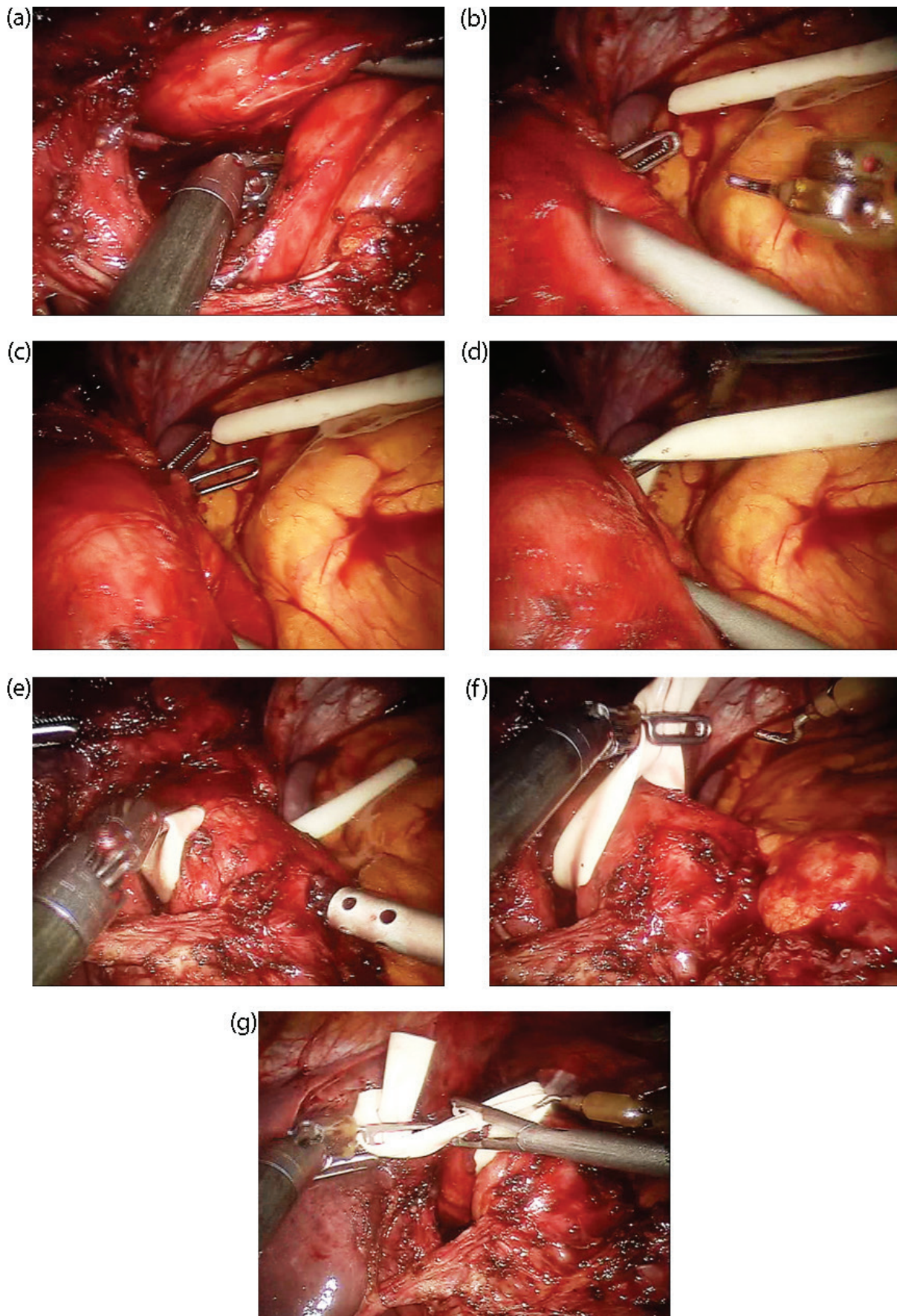


Image 7. (a-g): Snapshots from various phases of encircling the esophagus with a penrose drain by using the robotic grasper.

At this point, ask the bedside assistant to introduce a short penrose drain through one of the robotic ports (usually #1). He should be aware that by this maneuver, pneumoperitoneum may be lost, so he must be fast but safe. Alternatively, he may use the 5 mm valve to introduce the drain without air loss.

Pass the robotic forceps slowly around the esophagus and grasp the penrose. By a backward movement, this should encircle the esophagus. The assistant secures the penrose with a hemolock clip and makes traction again by holding the penrose. Revise the crural dissection once again.

3.5. Division of short gastric veins

For adequate mobilization of the fundus, this is usually necessary. Your assistants should change the robotic monopolar with the robotic ultrasonic scissors (or Vessel Sealer) at this point. Approximately at one-third of the greater curvature length, make a window entering the omental bursa. Proceed cephalad with slow division of the short gastrics until the penrose drain at the gastroesophageal junction is met. Soft adhesions of the posterior gastric wall to the pancreas should be divided as needed. This part of the operation may be particularly troublesome and needs additional care as one proceeds proximally in tight proximity to the spleen, which can be easily injured. Use your second arm to gently retract the stomach and ask the bedside assistant to retract the omentum laterally. In this way, you should always find the correct plane to divide the short gastrics. In case of a minor hemorrhage, do not hesitate to put a sponge inside. This may immediately clean the field and help you identify the bleeding source (**Image 8**).

3.6. Suturing the crura

Now, proceed to close the defect of the hiatal hernia.

Many authors suggest that a Nr.48-50 bougie should be in place while closing the crural defect. The authors have stopped using a bougie for Nissen funduplications, early in their experience (**Image 9**).

Ask the assistant to pull the stomach laterally and superiorly in order to expose lower junction of the crura. Also, ask him to introduce a short piece of suture through port #1 (No. 2-0, nonabsorbable suture, 15 cm for every two stitches) and to change your robotic instruments with robotic needle holders. Suture the crura with thick bites and make sure to include the peritoneum to strengthen the suture. In addition, the use of pledgets is also advisable, especially in large defects. Use a figure-of-eight type of suturing. Usually 2–3 sutures are adequate. Robotic suturing is performed in an open-surgery fashion, that is, you simply rotate one arm around the other holding the end of the stitch. Laparoscopic suturing skills are not necessary for this phase of the operation.

3.7. Creating the wrap

Push part of the fundus toward the posterior window and then use the robotic forceps (Arm #2) to pull the fundus behind the esophagus. Do not try to do this in one step because the instrument may easily injure the gastric wall. Ask the bedside assistant to hold the fundus at this position and reposition your forceps by a larger (more secure) bite. Now pull the rest

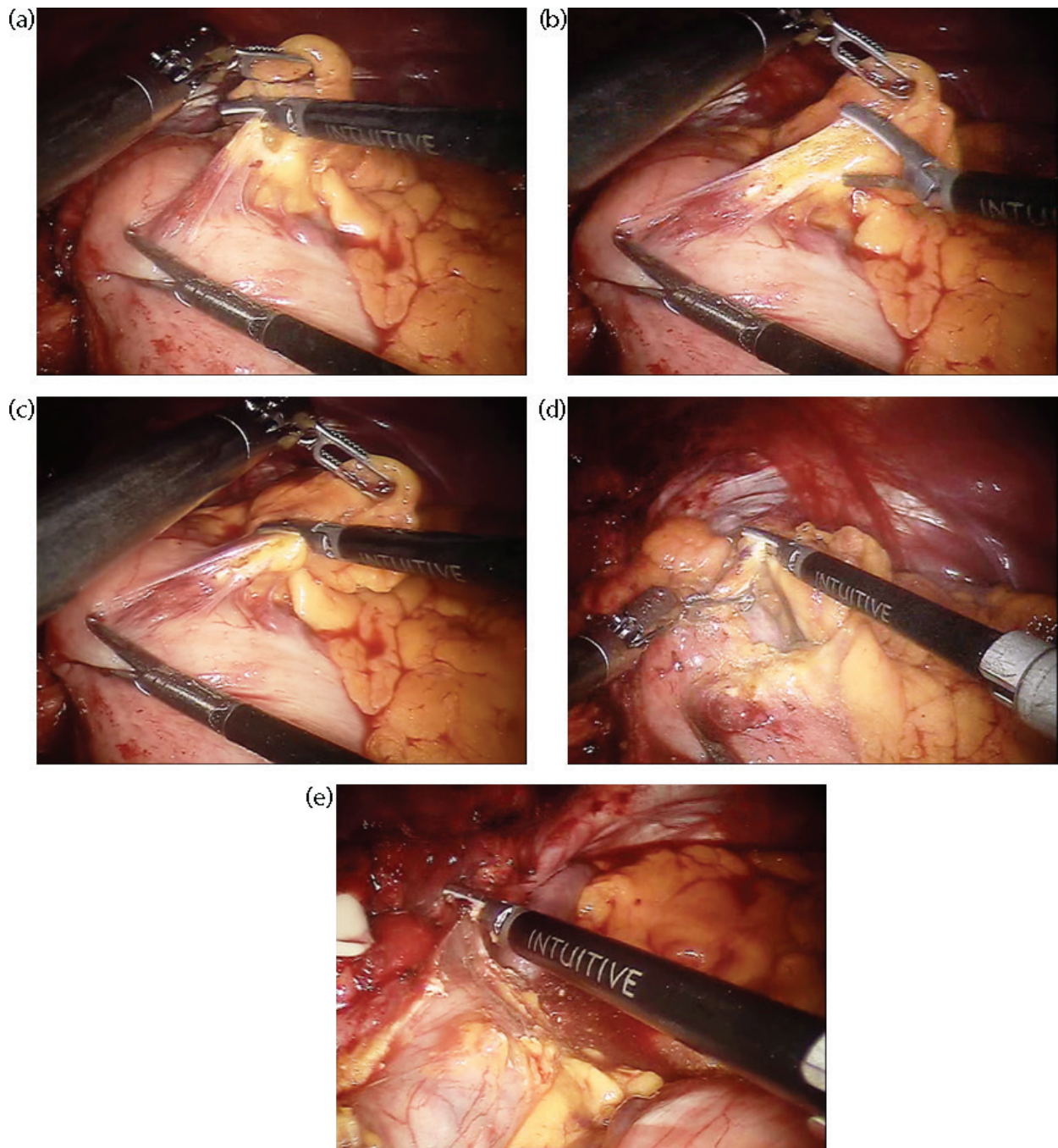


Image 8. (a-e): Snapshots from various phases of mobilizing the gastric fundus by division of the short gastrics. Note the difficulty as the dissection proceeds proximally and closer to the spleen.

of the fundus and bring it in front of the esophagus. You may assess tension of the wrap by gently pulling and pushing the fundus around the esophagus as you hold it at this point (shoe-shine maneuver). If your mobilization is adequate, the wrap should stay around the esophagus, else it may return at its initial position, outside the posterior window, which denotes that further posterior dissection may be necessary (**Image 10**).

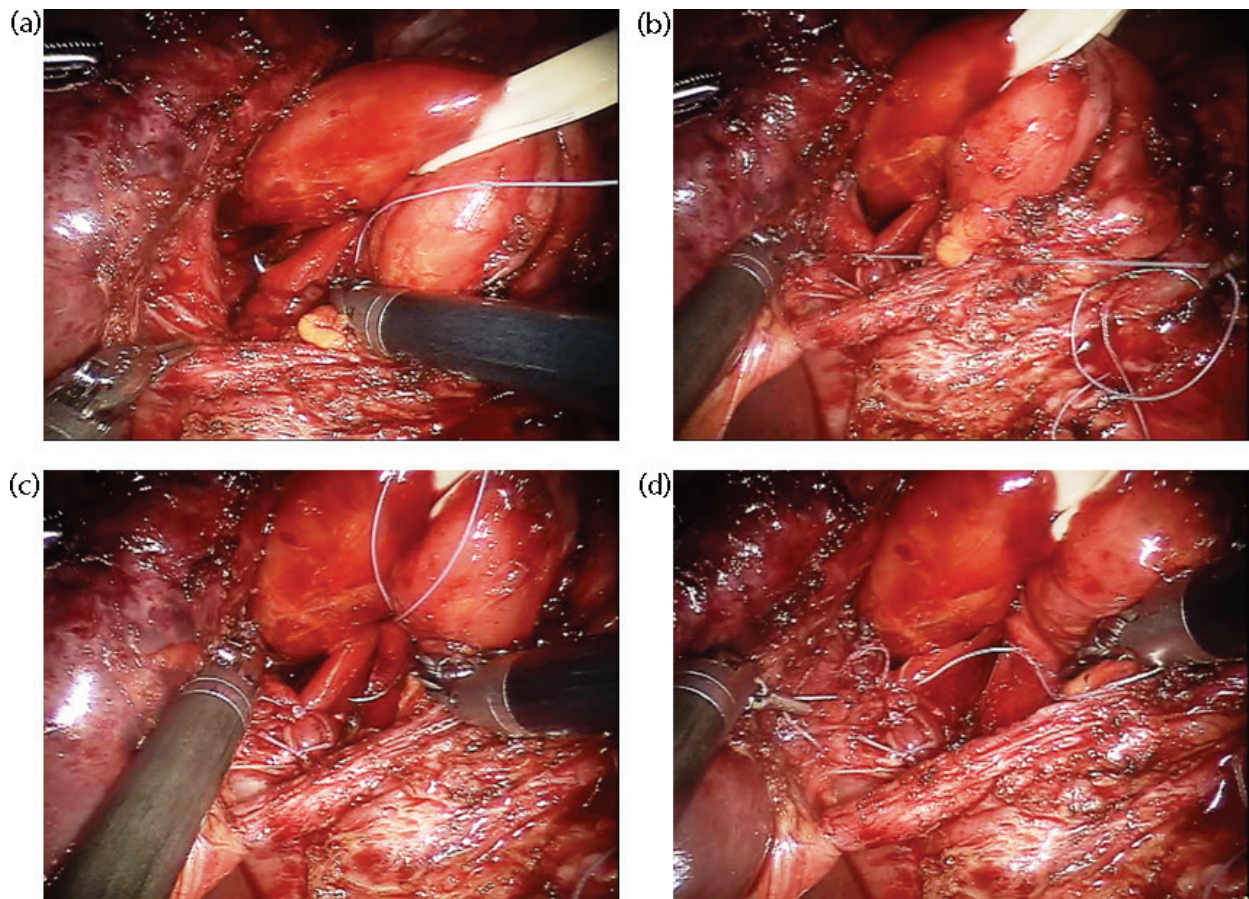


Image 9. (a-d): Snapshots from various phases of closing the defect by suturing the crura.

3.8. Anchoring the wrap

Assess the anterior surface of the stomach in order to anchor your wrap properly. Remove any large lipomas near the point of anchoring by using the ultrasonic scissors (or the newer Vessel Sealer). After that using the maneuvers described above, introduce once again a suture of the same nonabsorbable material and ask for the robotic needle holders in your hands. Approximate the left to the right part of the fundus and suture them together making a figure-of-eight stitch. These stitches should pass through all gastric wall layers and part of the anterior esophagus should be included with partial thickness bites. Many authors suggest securing the wrap to the diaphragm using two coronal sutures (left and right). This is not included in the standard technique of the authors. After completion of the anchoring, the assistant's 5 mm grasper should be able to pass below the wrap (maneuver to make sure that a "floppy Nissen" has been accomplished) (**Image 11**).

3.9. Final check and removal of instruments

Irrigation and suction is not necessary if no bleeding occurred during surgery. Remember to remove any material used during the procedure (failed clips, sponges, periesophageal

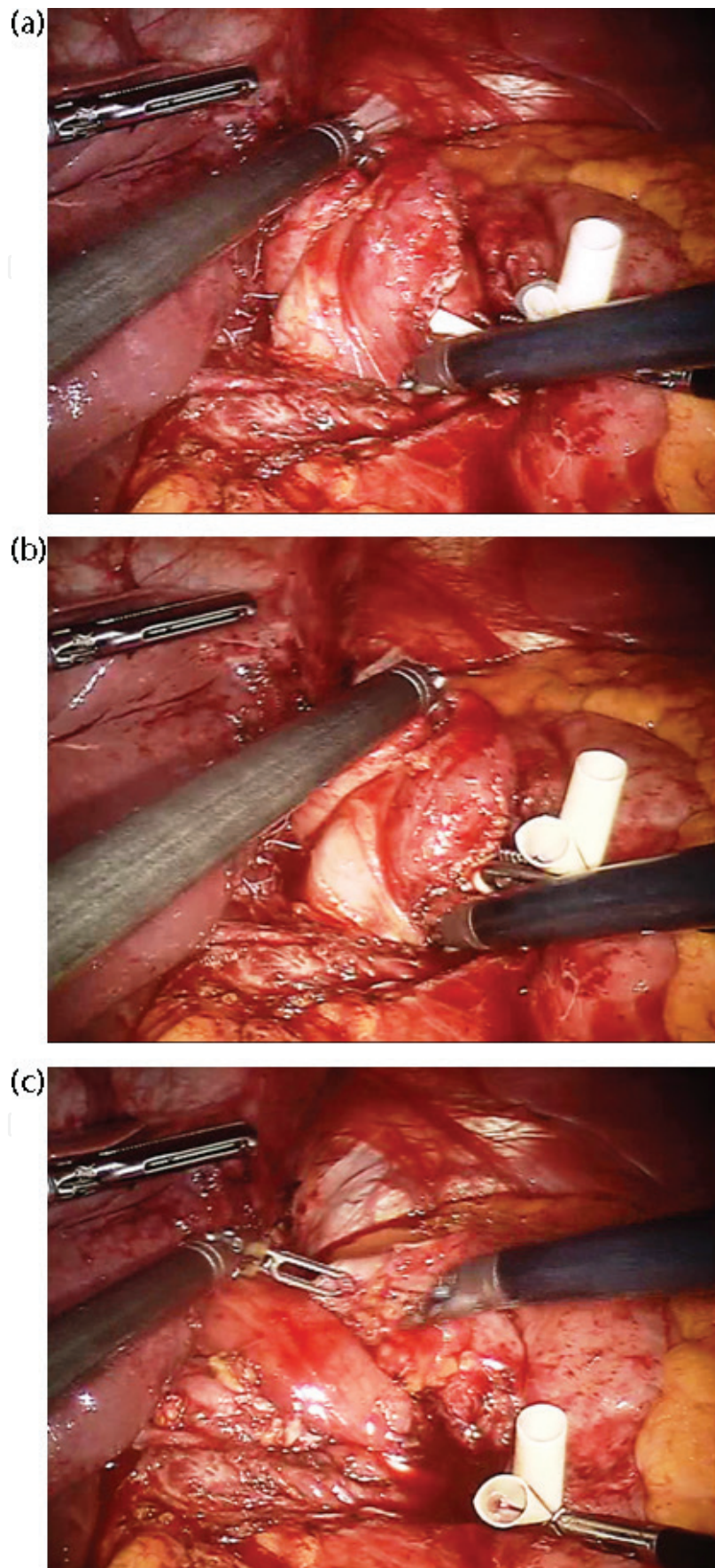


Image 10. (a-c): Mobilization is adequate because the wrap remains around the esophagus after cessation of the traction.

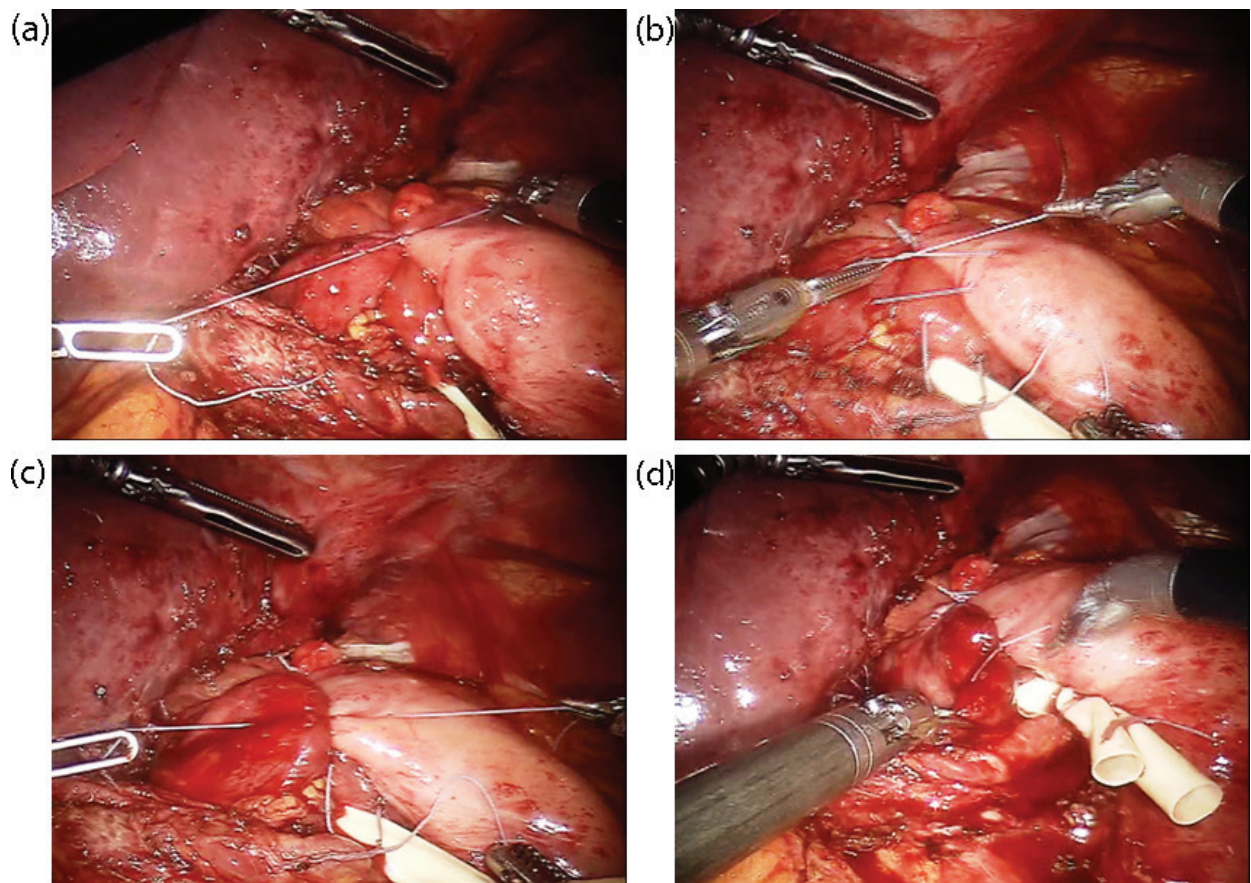


Image 11. (a-d): Snapshots from suturing the wrap for fixation in its final position.

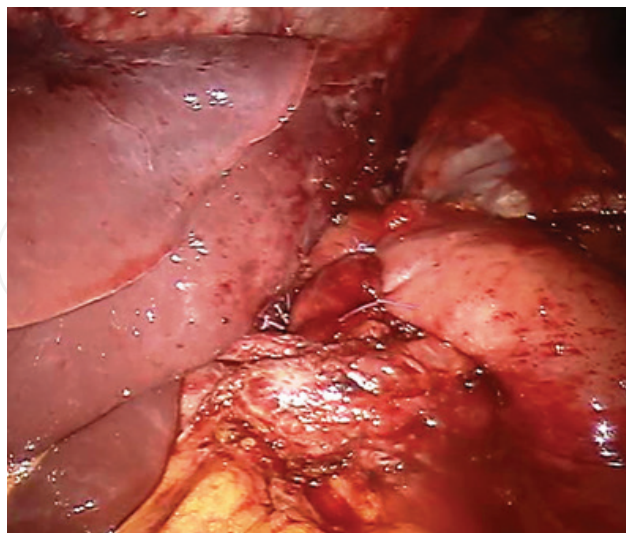


Image 12. Final result of the operation.

lipomas, lymph nodes, etc.) at this stage. Remove all instruments under direct vision, starting by the liver retractor which must be followed to the deep-seated fourth port in the right lower abdominal wall (**Image 12**).

3.10. Skin closure and wound dressings

If an OptiView technique was used for pneumoperitoneum at the beginning, there is no need for fascial closure. In case of open (Hasson) technique, a single figure-of-eight fascial suture is enough. Monofilament suture materials have been used to close the skin intradermally. Apply steri-strips and cover with water-resistant dressings.

4. Special considerations and hazards

- The large paraesophageal hernia

In the challenging case of large paraesophageal hernia, the technical difficulty of the operation rises significantly, and an experienced team should be called in. Soon after initial dissection at the crural region or even before this, assessment of the herniated content should be established. An effort to reduce the herniated viscera should be tried after complete adhesiolysis around the esophagus. Careful separation of the hernia sac and mobilization of the large accompanying lipoma should be anticipated in addition to the standard phases of the operation. Injury to the esophagus, to the vagal branches, or significant hemorrhage can occur during these stages.

- The short esophagus

Patients with advanced gastroesophageal reflux disease may present with a short esophagus. In practice, the surgeon should be able to differentiate between a truly short esophagus and an apparently short esophagus, which is more common and means that esophageal mobilization should be performed. The robotic system permits fine dissection in the narrow paraesophageal spaces even high in the mediastinum. Thus, the myth of a short esophagus should be treated with extensive mediastinal dissection of the lower esophagus (which according to the authors is usually enough), before a lengthening procedure is considered (Collis gastroplasty).

5. Postoperative management

- After completion of the operation, all port sites are injected with a solution of 20 ml of ropivacaine hydrochloride (2 mg/ml).
- The nasogastric tube is usually removed at the end of the operation.
- Normally, on the night of surgery, patients can receive oral fluids and should be mobilized.
- After a normal postoperative course, patients can usually be discharged within 48 h.
- Soft diet is suggested for the first 10 days after the operation.

6. Future perspectives – single-site robotic Nissen

Single-site robotic Nissen was reported using da Vinci straight instruments through laparoscopic single-site trocars [7, 8]. In May 2011, Konstantinidis et al. reported the first single-site robotic Nissen using the single-site curved instruments. The port was placed two fingerbreadths above the umbilicus and laterally to the midline. A cholecystectomy took place using the same trocar, before attempting the fundoplication. Although some exposure problems were recorded, the procedure was completed uneventfully. Single-incision surgery may prove to give an additional benefit to the use of robotics in surgery by providing steady three-dimensional image and intuitive instrumentation through a single 2.5 cm incision. Results of robotic fundoplication have been promising from numerous studies [9–15]; but up to now, supporters failed to publish an evidence-based proof of its superiority versus existing laparoscopic techniques [16–18].

Author details

Konstantinos Konstantinidis, Michael Konstantinidis, Savvas Hirides* and Petros Hirides

*Address all correspondence to: savashiridis@yahoo.com

Athens Medical Center, Greece

References

- [1] Margaron FC, Oiticica C, Lanning DA. Robotic-assisted laparoscopic Nissen fundoplication with gastrostomy preservation in neurologically impaired children. *Journal of Laparoendoscopic & Advanced Surgical Techniques Part A*. 2010 Jun;**20**(5):489-492. PMID:20518687[PubMed - indexed for MEDLINE]
- [2] DeUgarte DA, Hirschl RB, Geiger JD. Robotic repair of congenital paraesophageal hiatal hernia. *Journal of Laparoendoscopic & Advanced Surgical Techniques Part A*. 2009 Apr;**19**(Suppl 1):S187-S189. PMID:19331624[PubMed - indexed for MEDLINE]
- [3] Draaisma WA, Gooszen HG, Consten EC, Broeders IA. Mid-term results of robot-assisted laparoscopic repair of large hiatal hernia: a symptomatic and radiological prospective cohort study. *Surgical Technology International*. 2008;**17**:165-170. PMID:18802897[PubMed - indexed for MEDLINE]
- [4] Hartmann J, Jacobi CA, Menenakos C, Ismail M, Braumann C. Surgical treatment of gastroesophageal reflux disease and upside-down stomach using the Da Vinci robotic system. A prospective study. *Journal of Gastrointestinal Surgery*. 2008 Mar;**12**(3):504-509. Epub 2007 Nov 20. PMID:18027060[PubMed - indexed for MEDLINE]

- [5] Braumann C, Menenakos C, Rueckert JC, Mueller JM, Jacobi CA. Computer-assisted laparoscopic repair of “upside-down” stomach with the Da Vinci system. *Surgical Laparoscopy Endoscopy & Percutaneous Techniques*. 2005 Sep;**15**(5):285-289. PMID:16215489[PubMed - indexed for MEDLINE]
- [6] Hanisch E, Markus B, Gutt C, Schmandra TC, Encke A. [Robot-assisted laparoscopic cholecystectomy and fundoplication – Initial experiences with the Da Vinci system]. *Chirurg*. 2001 Mar;**72**(3):286-288. German. PMID:11317449[PubMed - indexed for MEDLINE]
- [7] Markar SR, Karthikesalingam AP, Hagen ME, Talamini M, Horgan S, Wagner OJ. Robotic vs. laparoscopic Nissen fundoplication for gastro-oesophageal reflux disease: systematic review and meta-analysis. *The International Journal of Medical Robotics*. 2010 Jun;**6**(2):125-131. Review. PMID:20506440[PubMed - indexed for MEDLINE]
- [8] Allemann P, Leroy J, Asakuma M, Al Abeidi F, Dallemagne B, Marescaux J. Robotics may overcome technical limitations of single-trocar surgery: An experimental prospective study of Nissen fundoplication. *Archives of Surgery*. 2010 Mar;**145**(3):267-271. PMID:20231627[PubMed - indexed for MEDLINE] Free Article
- [9] Ceccarelli G, Patrìti A, Biancafarina A, Spaziani A, Bartoli A, Bellochi R, Casciola L. Intraoperative and postoperative outcome of robot-assisted and traditional laparoscopic Nissen fundoplication 1. *European Surgical Research*. 2009;**43**(2):198-203. Epub 2009 Jun 10
- [10] Albassam AA, Mallick MS, Gado A, Shoukry M. Nissen fundoplication, robotic-assisted versus laparoscopic procedure: A comparative study in children. *European Journal of Pediatric Surgery*. 2009 Oct;**19**(5):316-319. Epub 2009 Jun 9. PMID:19513968[PubMed - indexed for MEDLINE]
- [11] Müller-Stich BP, Reiter MA, Mehrabi A, Wente MN, Fischer L, Köninger J, Gutt CN. No relevant difference in quality of life and functional outcome at 12 months' follow-up-a randomised controlled trial comparing robot-assisted versus conventional laparoscopic Nissen fundoplication. *Langenbeck's Archives of Surgery*. 2009 May;**394**(3):441-446. Epub 2009 Jan 23. PMID:19165497[PubMed - indexed for MEDLINE]
- [12] Copeland DR, Boneti C, Kokoska ER, Jackson RJ, Smith SD. Evaluation of initial experience and comparison of the da Vinci surgical system with established laparoscopic and open pediatric Nissen fundoplication surgery. *Journal of the Society of Laparoendoscopic Surgeons*. 2008 Jul-Sep;**12**(3):238-240. PMID:18765044[PubMed - indexed for MEDLINE] Free PMC Article
- [13] Meehan JJ, Meehan TD, Sandler A. Robotic fundoplication in children: resident teaching and a single institutional review of our first 50 patients. *J Pediatr Surg*. 2007 Dec;**42**(12):2022-2025. PMID:18082700[PubMed - indexed for MEDLINE]
- [14] Müller-Stich BP, Reiter MA, Wente MN, Bintintan VV, Köninger J, Büchler MW, Gutt CN. Robot-assisted versus conventional laparoscopic fundoplication: Short-term outcome of a pilot randomized controlled trial. *Surgical Endoscopy*. 2007 Oct;**21**(10):1800-1805. Epub 2007 Mar 13. PMID:17353978[PubMed - indexed for MEDLINE]

- [15] Heemskerk J, van Gemert WG, Greve JW, Bouvy ND. Robot-assisted versus conventional laparoscopic Nissen fundoplication: A comparative retrospective study on costs and time consumption. *Surgical Laparoscopy Endoscopy & Percutaneous Techniques*. 2007 Feb;**17**(1):1-4. PMID:17318044[PubMed - indexed for MEDLINE]
- [16] Draaisma WA, Ruurda JP, Scheffer RC, Simmermacher RK, Gooszen HG, Rijnhart-de Jong HG, Buskens E, Broeders IA. Randomized clinical trial of standard laparoscopic versus robot-assisted laparoscopic Nissen fundoplication for gastro-oesophageal reflux disease. *The British Journal of Surgery*. 2006 Nov;**93**(11):1351-1359
- [17] Nakadi IE, Mélot C, Closset J, DeMoor V, Bétroune K, Feron P, Lingier P, Gelin M. Evaluation of da Vinci Nissen fundoplication clinical results and cost minimization. *World Journal of Surgery*. 2006 Jun;**30**(6):1050-1054
- [18] Morino M, Pellegrino L, Giaccone C, Garrone C, Rebecchi F. Randomized clinical trial of robot-assisted versus laparoscopic Nissen fundoplication. *The British Journal of Surgery*. 2006 May;**93**(5):553-558

