

We are IntechOpen, the world's leading publisher of Open Access books Built by scientists, for scientists

4,800

Open access books available

122,000

International authors and editors

135M

Downloads

Our authors are among the

154

Countries delivered to

TOP 1%

most cited scientists

12.2%

Contributors from top 500 universities



WEB OF SCIENCE™

Selection of our books indexed in the Book Citation Index
in Web of Science™ Core Collection (BKCI)

Interested in publishing with us?
Contact book.department@intechopen.com

Numbers displayed above are based on latest data collected.

For more information visit www.intechopen.com



The Role of the Magnetic Resonance Imaging for the Accurate Management of Focal Therapy with High-Intensity Focused Ultrasound for the Localized Prostate Cancer

Sunao Shoji and Akira Miyajima

Additional information is available at the end of the chapter

<http://dx.doi.org/10.5772/intechopen.71996>

Abstract

The concept of the currently attracted focal therapy is to treat clinical significant cancer with minimal invasion of health-related functions such as urethra, sphincter, neurovascular bundle, and bladder neck. The patients' criteria have been decided with pathologic tumor features characterized according to a combination of cancer core length and Gleason grade with prostate biopsy. Because the area involved in a single treatment using high-intensity focused ultrasound (HIFU) is extremely small, only minor temperature changes are observed outside of the focal zone. HIFU has been considered as an attractive therapeutic modality for the focal treatment of the prostate with the aim of curing the cancer while preserving continence and erectile function. Clinical trials of focal ablation of prostate cancer with HIFU have been reported. In our protocol, magnetic resonance imaging (MRI) has played a major role in the diagnosis of the spatial location of the significant cancer, treatment planning, and the evaluation of the treatment efficacy and recurrence after the treatment. In the chapter in "MR Imaging," we want to present the role of MRI in the accurate management of focal therapy with HIFU for the localized prostate cancer.

Keywords: prostate cancer, focal therapy, magnetic resonance imaging, high-intensity focused ultrasound

1. Introduction

High-intensity focused ultrasound (HIFU) produces ultrasound waves generated by a spherical transducer, delivering ultrasonic energy to pinpoint foci millimeters in diameter [1]. The thermal and mechanical effects of HIFU cause destruction within prostate tissue [2, 3]. Specifically,

coagulative degeneration quickly develops and is a primary mechanism for decreasing blood flow [3, 4]. Cavitation, a mechanical effect of HIFU, occurs because of the rapid cycling from compression to refraction by the ultrasound waves and results in the formation of microbubbles in tissue. When these bubbles reach the size of resonance, they collapse and produce high-pressure shock waves, destroying adjacent tissue [5]. Clinically, HIFU energy is delivered in a pulsed mode, and pulses are defined by treatment cycles and energy intensity in watts. Pulse characteristics define the size of the ablation area, including necessary margins to ensure full tumor coverage. The resulting tissue effects are a function of the frequency (wavelength) and intensity (I , in W/cm^2) of the applied energy. Intensity is a function of the excitation (voltage) and duration of the energy pulse. The exact size of the ablated area depends on the type of device used, shape of the piezoceramic working element of the transducer, ultrasound frequency and duration of pulsed energy applied, degree of sonication absorption by the tumor tissue, and focal intensity achieved.

Because the area involved in a single treatment using HIFU is extremely small, only minor temperature changes are observed outside of the focal zone [3], making it an attractive therapeutic modality for focal treatment of the prostate, with the aim of curing the cancer while preserving continence and erectile function. Clinical trials of focal ablation of prostate cancers with HIFU have been reported [6–11]. In the management of the focal therapy, MRI has the role in the localization of the targeted lesion, the evaluation of the treatment effectiveness, and the local recurrence after the treatment.

2. The technology of the HIFU in the treatment of the prostate cancer

After the early studies for the treatment of organ-confined prostate cancer, the Sonablate[®] device and Ablatherm[®] device have been further enhanced to include treatment planning capabilities and improved therapeutic technologies.

In the treatment planning, the Sonablate[®] transrectal HIFU probes use proprietary transducer technology with low-energy ultrasound (4 MHz) for imaging of the prostate and high-energy ablative pulses (site intensity: 1300–2200 W/cm^2) for treatment delivery. For the Ablatherm[®] device, the transrectal HIFU probes use 7.5 MHz pulses for imaging of the prostate and 3 MHz for the delivery of high-energy ablative pulses (site intensity, 1300–2200 W/cm^2). In recent applications of HIFU, the treatment range was planned using a MRI-TRUS fusion image. Additionally, reconstructed three-dimensional (3D) planning modes have been integrated into the SB 500 V4 and AB integrated devices, facilitating accurate planning of treatment range. Because of the inherent technology of HIFU treatments, there is no need to puncture the prostate during treatment; however, this makes accurate treatment planning essential for successful focal HIFU therapy.

In the treatment, intraoperative images are available during the procedure. The “popcorn” phenomena formed by the cavitations of tissue may act as an indicator of treatment efficacy. The SB500 tissue change monitoring system (TCM) predicts treatment efficacy by calculation of radio frequency signal from an area of interest and classifies it based on a 3-color system; green: insufficient change to cure, yellow: moderate change, and orange: large change. Based

on the color indicated on the treated area, intraoperative retreatment for an insufficiently treated zone (green area) would then be performed. A recent development in the field of adaptive treatment planning is the Focal One[®]. This device has a dynamic focusing transducer made of 16 isocentric rings and allows the user to electronically steer the ultrasound beam and move the focal point of the transducer to a maximum of eight different points (32–67 mm from the transducer).

3. The role of MRI in the management of focal therapy

3.1. The localization of the clinically significant cancer in the prostate with MRI-TRUS fusion image-guided prostate biopsy

Multiparametric MRI (mpMRI) improves the imaging of the clinically significant prostate cancer in the prostate [12, 13], and the information of mpMRI has been used for the precise diagnosis and localization of the clinically significant prostate cancer. MRI-TRUS fusion image-guided biopsy achieved accurate prostate biopsy based on MRI, combining the superior sensitivity of MRI for targeting cancer-suspicious lesions with the practicality and familiarity of TRUS. With the MRI-TRUS fusion devices, the stored MRI and real-time TRUS are superimposed using computer software to enable targeted biopsy of cancer-suspicious lesions [14]. MRI-TRUS fusion biopsy device “BioJet[®]” was approved by FDA after the evaluation of the accuracy with phantoms. We reported the BioJet[®] experience of the usefulness of the precise diagnosis of the clinically significant cancer [15]. In the 30 patients from whom whole-mount specimens were taken, we found 43 clinically significant cancers, of which 41 (95%) had been detected by both the targeted and systematic biopsies. The median major diameter of significant cancers in the whole-gland specimens was 12 (range: 5–28) mm; lesions ≤ 10 mm represented 59% of the significant cancers ($n = 24$). Of the significant cancers ≤ 10 mm ($n = 24$) in whole-mount specimens, 96% ($n = 23$) were correctly diagnosed by biopsy. Gleason scores and locations of biopsy-proven significant cancers corresponded to histopathological findings for the whole-mount specimens, since the localization of the clinically significant cancer in the prostate is important for the precise focal therapy. Since February 2016, the biopsy with BioJet was approved as the advance medical technique by Japanese Ministry of Health, Labor, and Welfare.

3.2. The evaluation of the effectiveness and the local recurrence of the prostate cancer after the focal therapy with HIFU

The treated areas with HIFU in the prostate appear as nonenhanced areas on contrast-enhanced T1-weighted MRI, and subsequent transrectal biopsies have been able to remove homogenous necrotic tissue sections from the nonenhanced area [16]. Therefore, contrast-enhanced MRI has been considered to be the evaluation method of choice to demonstrate the effectiveness of HIFU for localized prostate cancer. We reported the time-dependent changes in blood flow within the prostate treated with HIFU on contrast-enhanced MRI between postoperative days 1 and 14 [16]. In addition, pathological analysis showed vessel damage with coagulative degeneration and detachment of vascular endothelial cells in HIFU-treated prostate tissue [16]. Previous studies [5] have shown that these time-dependent changes in blood flow within the prostate are likely due to the primary thermal effects induced on the tissue and

vessel damage by coagulative degeneration in the prostate and that cavitation rapidly induces the detachment of vascular endothelial cells, gradually decreasing blood flow secondary to vessel obstruction. Future large-scale studies should investigate the most appropriate timing of contrast-enhanced MRI for precise feedback regarding the effectiveness of HIFU. Using the contrast-enhanced MRI, the evaluation of the effectiveness and the local recurrence of the prostate cancer needs to be evaluated after the focal therapy with HIFU.

4. The original protocol and the early experience of the focal therapy for the prostate cancer in our institution

Since 2016, the patients with low- and intermediate-risk group who were diagnosed the spatial localization of the prostate significant cancer in the prostate were recruited prospectively. The spatial localization of the significant cancer was diagnosed with MRI-transrectal ultrasound (TRUS) fusion image-guided transperineal prostate biopsy using the BioJet[®] system (D&K Technologies GmbH, Barum, Germany). The focal therapy was performed to the significant cancer detected regions with transrectal HIFU using Sonablate[®] 500 (SonaCare medical, Indianapolis, IN, USA). To evaluate the efficacy of the treatment, serum prostate-specific antigen (PSA) kinetics and three-dimensional (3D) reconstructed multiparametric MRI were analyzed (**Figure 1**). To evaluate the invasiveness, questionnaires (IPSS, QOL, OABSS, IIEF-5, SF-36 Japanese version 2) and uroflowmetry were performed. Adverse event was evaluated with Common Terminology Criteria for Adverse Events (CTCAE) ver.4.0. Fifteen patients with median age of 64 years (48–79) and median PSA of 7.2 ng/ml (4.67–15.99) were treated. All men (15 of 15 patients) had pad-free/leak-free continence at 1 and 3 months after the treatment. The proportion of men with erections sufficient for penetration was not changed from 73% (11 of 15 patients) to 73%. Catheterization was within 24 hours after the treatment in all patients. The median PSA of the patients significantly dropped from 7.2 to 1.76 ng/ml ($p = 0.001$) at 3 months after the treatment. The contrast-enhanced MRI and dynamic MRI showed the disappearance of blood flow in all targeted regions of the prostate with 3D evaluation of the MRI. There was no significant difference between before and after the treatment at 3 months in urinary symptoms (IPSS change, $p = 0.3$, QOL change $p = 0.7$, OABSS change, $p = 0.6$, max flow rate change, $p = 0.6$, residual urine change, $p = 0.1$), erectile function (IIEF-5 change, $p = 0.6$), and QOL (SF-36 change in all domains). Urinary tract infection with

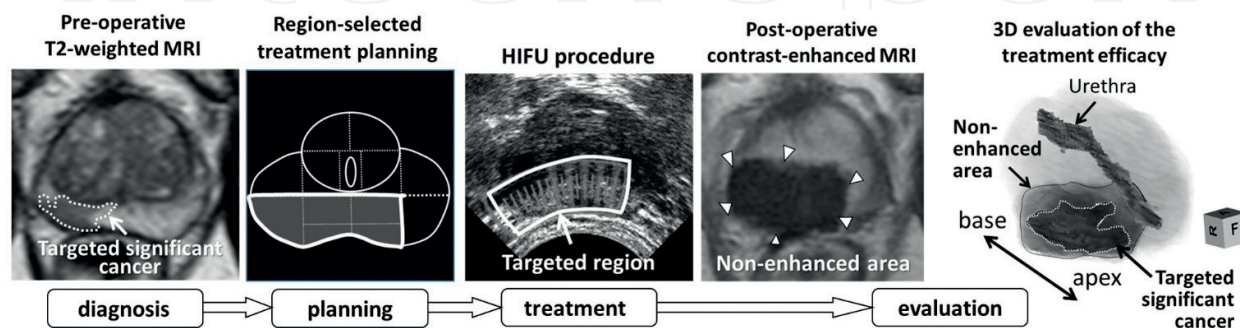


Figure 1. The protocol schema of focal HIFU treatment for the prostate cancer in our institution.

CTCAE Grade 2 was found in one patient (6.7%). In conclusion, the anatomical region selected focal therapy with HIFU would have potential to provide promising results with accurate treatment for the significant cancer and low morbidity.

5. Conclusion

MRI has the role of the management of the focal therapy with HIFU. Clinical trials have shown potential for effective focal treatment with HIFU-localized prostate cancer. Further oncological and functional outcomes in the patients treated with focal therapy with HIFU would be expected.

Acknowledgements

We like to offer our special thanks to Tomohisa Machida for creating pathological specimens and Akio Hashimoto and Tomoya Nakamura for MRI shooting in our institution.

Author details

Sunao Shoji^{1*} and Akira Miyajima²

*Address all correspondence to: sunashoj@mail.goo.ne.jp

1 Department of Urology, Tokai University Hachioji Hospital, Tokyo, Japan

2 Department of Urology, Tokai University School of Medicine, Kanagawa, Japan

References

- [1] Fry WJ, Barnard JW, Fry EJ, et al. Ultrasonic lesions in the mammalian central nervous system. *Science*. 1955;**122**:517-518
- [2] Chapelon JY, Margonari J, Vernier F, et al. In vivo effects of high-intensity ultrasound on prostatic adenocarcinoma dunning R3327. *Cancer Research*. 1992;**52**:6353-6357
- [3] Madersbacher S, Pedevilla M, Vingers L, et al. Effect of high-intensity focused ultrasound on human prostate cancer in vivo. *Cancer Research*. 1995;**55**:3346-3351
- [4] Serrone J, Kocaeli H, Douglas Mast T, et al. The potential applications of high-intensity focused ultrasound (HIFU) in vascular neurosurgery. *Journal of Clinical Neuroscience*. 2012;**19**:214-221
- [5] Wu F, Chen WZ, Bai J, et al. Pathological changes in human malignant carcinoma treated with high-intensity focused ultrasound. *Ultrasound in Medicine & Biology*. 2001;**27**:1099-1106

- [6] Ahmed HU, Freeman A, Kirkham A, et al. Focal therapy for localized prostate cancer: A phase I/II trial. *The Journal of Urology*. 2011;**185**:1246-1254
- [7] Ahmed HU, Hindley RG, Dickinson L, et al. Focal therapy for localised unifocal and multifocal prostate cancer: A prospective development study. *The Lancet Oncology*. 2012;**13**:622-632
- [8] El Fegoun AB, Barret E, Prapotnich D, et al. Focal therapy with high-intensity focused ultrasound for prostate cancer in the elderly. A feasibility study with 10 years follow-up. *International Brazilian Journal of Urology*. 2011;**37**:213-219; discussion 220-2
- [9] Muto S, Yoshii T, Saito K, et al. Focal therapy with high-intensity-focused ultrasound in the treatment of localized prostate cancer. *Japanese Journal of Clinical Oncology*. 2008;**38**: 192-199
- [10] Shoji S, Nakano M, Fujikawa H, et al. Urethra-sparing high-intensity focused ultrasound for localized prostate cancer: Functional and oncological outcomes. *International Journal of Urology*. 2015;**22**:1043-1049
- [11] Van Velthoven R, Aoun F, Limani K, et al. Primary zonal high intensity focused ultrasound for prostate cancer: Results of a prospective phase IIa feasibility study. *Prostate Cancer*. 2014;**2014**(756189)
- [12] Moore CM, Kasivisvanathan V, Eggener S, et al. Standards of reporting for MRI-targeted biopsy studies (START) of the prostate: Recommendations from an international working group. *European Urology*. 2013;**64**:544-552
- [13] Sciarra A, Panebianco V, Ciccariello M, et al. Value of magnetic resonance spectroscopy imaging and dynamic contrast-enhanced imaging for detecting prostate cancer foci in men with prior negative biopsy. *Clinical Cancer Research*. 2010;**16**:1875-1883
- [14] Dickinson L, Ahmed HU, Allen C, et al. Magnetic resonance imaging for the detection, localisation, and characterisation of prostate cancer: Recommendations from a European consensus meeting. *European Urology*. 2011;**59**:477-494
- [15] Shoji S, Hiraiwa S, Ogawa T, et al. Accuracy of real-time magnetic resonance imaging-transrectal ultrasound fusion image-guided transperineal target biopsy with needle tracking with a mechanical position-encoded stepper in detecting significant prostate cancer in biopsy-naive men. *International Journal of Urology*. 2017;**24**:288-294
- [16] Shoji S, Tonooka A, Hashimoto A, et al. Time-dependent change of blood flow in the prostate treated with high-intensity focused ultrasound. *International Journal of Urology*. 2014;**21**:942-945