

# We are IntechOpen, the world's leading publisher of Open Access books Built by scientists, for scientists

4,800

Open access books available

122,000

International authors and editors

135M

Downloads

Our authors are among the

154

Countries delivered to

TOP 1%

most cited scientists

12.2%

Contributors from top 500 universities



WEB OF SCIENCE™

Selection of our books indexed in the Book Citation Index  
in Web of Science™ Core Collection (BKCI)

Interested in publishing with us?  
Contact [book.department@intechopen.com](mailto:book.department@intechopen.com)

Numbers displayed above are based on latest data collected.  
For more information visit [www.intechopen.com](http://www.intechopen.com)



---

# The Advancement of Postmortem Investigations in Sudden Cardiac Death

---

Kawthar Braysh, Raymond Zerbe,  
Roselyn Jurjus Zein, Doureid Oueidat, Jihad Hawi,  
Luk Oke and Abdo Jurjus

Additional information is available at the end of the chapter

<http://dx.doi.org/10.5772/intechopen.71555>

---

## Abstract

Sudden cardiac death (SCD) is a major public health issue accounting for 15–20% of all-cause deaths. Several pathologies have been associated with sudden cardiac arrest. Clinical autopsies have always contributed to invention of novel strategies for SCD prevention. One of the serious challenges that pathologists are facing is the significant decline of the overall autopsy rate. Many reasons have been associated with this change, most importantly, the evolution process in the postmortem investigation tools. However, cardiologists seem unsatisfied with the new non-invasive imaging techniques and still believe in the traditional autopsy as a gold standard in diagnosis of cardiovascular diseases. In this chapter, we focused on the importance of autopsy in the prevention of SCD by shedding a light on guidelines of minimum requirement for routine autopsy investigation of SCD (including macroscopic, histological, toxicological and molecular examination). We also gave insight into the new radiological techniques, their advantages and related diagnostic pitfalls as compared to that of conventional autopsy. Thus, providing a comprehensive understanding on the advancement of postmortem examination will help improve the minimum standards of routine autopsy practice, develop new guidelines for radiological examination and prevent the growing heterogeneity of the pathologies underlying SCD.

**Keywords:** autopsy practice, postmortem investigations, sudden cardiac death, coronary heart diseases, channelopathies, cardiomyopathies, non-invasive imaging techniques, toxicology

---

## 1. Introduction

Sudden cardiac death (SCD) is a term used to describe an unpredicted death of a person as a consequence of a cardiovascular event, with or without an existence of an underlying cardiac pathology [1]. It is considered as a major health problem worldwide accounting for 15–20% of all deaths [2]. This incident is associated with the development of a ventricular tachycardia (VT) which then progresses into a ventricular fibrillation (VF) and eventually asystole is followed [1]. This arrhythmic disturbance explains the rapidity of the death. SCD is generally observed in older people; nevertheless, a considerable rate has been seen in young people who are harboring an inherited cardiac lesion [2]. Identifying patients at risk of SCD is the most challenging task clinicians often face, because the great majority of SCD victims who suffer from cardiac diseases are only discovered through postmortem microscopic and macroscopic examinations when the incident of sudden death has already occurred without the presence of any previous clinical manifestations [3]. The underlying cardiac causes of SCD include coronary artery diseases (CAD), valvular heart diseases, cardiomyopathy syndromes, infiltrative diseases of the myocardium, myocarditis, infective endocarditis, inherited ion channels defects and congenital heart diseases [4, 5]. Epidemiologically, CAD is responsible for 80% of the cases of SCD, cardiomyopathies account for 10–15% of the cases, while 5–10% of SCD are caused by inherited cardiac disorders, such as coronary artery anomalies or cardiac channelopathies [6]. Coronary atherosclerosis is the most common cause of SCD in individuals aged 35 years and above, with men having a higher risk of SCD than women [4], while cardiomyopathies, especially hypertrophic cardiomyopathy (HCM), ion channels defects and coronary artery anomalies are the leading causes of SCD in adults younger than 35 years old [7]. However, in children, myocarditis and congenital heart diseases are the chief causes of SCD [4]. Besides, other non-cardiac pathologies can sometimes trigger SCD. It has been noted that patients with chronic kidney disease, obstructive sleep apnea and seizure disorders had a higher risk of developing SCD [2]. The use of medications that can have cardiac effects have been linked to many cases of SCD, such as the antipsychotic medications, some antihistamine drugs, macrolides antibiotics [8], and drugs of abuse; therefore, toxicological substances should always be considered by forensic doctors and screening tests should always be done [9]. The prevention of SCD is a field that is continuously studied [10]; however, its rate remains high despite the various preventive measures. Commonly used approaches include the use of pharmacological interventions and implantable cardioverter-defibrillator (ICD) [10]. An important measure for prevention is to identify those at risk of a SCD, Framingham risk score is a commonly used method, it is recommended as a routine screening method in males in their 40s and in postmenopausal women. It calculates an individual risk of CAD substrate based on multiple variables like age, sex, smoking, blood pressure, LDL levels, body mass index (BMI) and diabetes; consequently, labeling people who might require preventive interventions. The role of ECG in identifying future victims is still uncertain; however, its role in prediction of SCD in those with identified genetic arrhythmic disease is clear, mostly in Long QT Syndrome. Actually the degree of QT interval prolongation positively correlates with the risk [11]. Additionally, screening young athletes for a hidden cardiac pathology has become increasingly demanded before starting physical activity, as SCD can be precipitated during sport, and ECG is one of the most commonly first-line screening tool along with physical examination that are encouraged to be practiced methods in young individuals before engaging in sport activities.

Positive results are followed by non-invasive imaging techniques like echo, CT, MRI among others or invasive ones like angiography and electrophysiological studies [12].

## **2. Management of a SCD from the forensic angle**

The practice in postmortem examination involves a detailed patient and family history, questioning regarding the patient's condition before death, as well as, macroscopic and histological studies of the heart with investigations of other organs to exclude non-cardiac causes of death, followed by a genetic testing of a blood sample. Then a complete clinical and genetic testing is done on family members who are at risk [13]. Generally, the autopsy protocols of SCD start with a macroscopic study of the heart, if the cause is identified no further testing is required. However, a negative macroscopic testing is followed by either a histological or a genetic testing depending on the victim's age. Histological testing is the next step in victims more than 30 years old with a negative macroscopic study, a positive test requires no further steps, while a negative one is followed by a genetic study. On the other hand, genetic testing is done as the next step on victims less than 30 years old with a negative macroscopic study [14]. When dealing with a heart autopsy, several steps are required; the pericardium should be checked for abnormalities, the pulmonary arteries should be examined for the presence of an embolus, and the patterns of origins of coronary arteries and their distributions are thoroughly investigated to determine a possible luminal obstruction. In addition, the ventricles are studied to determine chamber size, the valve, wall thickness, and the presence of zones of new or old infarcts [15] and to assess for the intactness of the papillary muscles and the chordae tendineae [9]. The left and right atria should be opened and their respective cavities should be thoroughly investigated and the assessment of the patency of the foramen ovale is followed [9]. Once the heart is evacuated from blood, multiple measurements are taken including the heart weight, its wall thickness and its dimensions [9]. Histological investigations are carried by examining the obtained tissues after staining with hematoxylin and eosin and Masson trichrome stain [16]. A negative autopsy is defined as the absence of any identifiable structural heart defect, with a negative histological and toxicological testing. The presence of a negative autopsy is a strong indicator of the presence of an inherited cardiac arrhythmic disease, this usually require a genetic testing on the victim, a process commonly termed as the molecular autopsy [13]. While the routine postmortem examination still possesses an essential role in the investigation of SCD, nowadays, the use of non-invasive imaging techniques such as multi-detector computed tomography (MDCT), CT angiography, and cardiac magnetic resonance imaging (MRI) [17] has shown its significance in diagnosing structural causes of cardiac death. It has also overcome some families' religious objections [13].

## **3. Autopsy examination for SCD**

### **3.1. Macroscopic studies**

Macroscopic examination of the heart helps in the identification of structural causes of SCD. Autopsy findings in SCD due to CAD include an alteration in the plaque structure such as

thrombus formation or plaque disruption such as fissuring or hemorrhage. Plaque rupture is the primary event that initiates the process of thrombus formation leading to acute coronary syndrome and SCD [18, 19]. Stenosis of more than 75% of the arterial lumen has been noted in a great proportion of individuals who have survived from a sudden cardiac arrest [18]. The development of collateral circulation in chronic ischemic heart disease patients has a protective role as it provides blood to areas distal to a stenotic region [18]. Hypertrophic cardiomyopathy (HCM), an autosomal dominant disease which occurs due to mutations in genes coding for sarcomere proteins, can be present in SCD of young individuals. Moreover, mutations in  $\alpha$ -tropomyosin and beta myosin heavy gene have the greatest risk of causing SCD [18]. Morphologically, it is characterized by left ventricular (LV) wall thickness, asymmetrical septal hypertrophy and mid-ventricular obstruction. On the other hand, dilated cardiomyopathy, which has both a genetic and non-genetic components, is associated with dilation of the left and right ventricles, thrombi may be observed in the cardiac chambers, and wall thickness may be increased or decreased [20]. Arrhythmogenic right ventricular dysplasia is another type of cardiomyopathy that can be associated with SCD; it is heritable disease with an autosomal dominant pattern whose genetic mutation has been localized on chromosome 1. Exercise is a common trigger of arrhythmia in these patients. Cardiac atrophy is seen in autopsy as a result of myocyte apoptosis [18]. Myocarditis, an inflammatory process in the myocardium, is a common cause of SCD; autopsy can show ventricular dilation with a mottled appearance along with scarring, fibrosis and minor coronary occlusion [21]. Infective endocarditis is another infectious cardiac disease which can induce SCD due to many causes. On gross examination of the heart, one can detect the presence of a vegetation on the infected valve, erosion of the underlying tissue, the chordae tendineae may be disrupted resulting in their rupture [5]. Congenital heart diseases occupy a high rank in the causes of SCD in children, with coarctation of the aorta (CoA) and transposition of the great vessels in the forefront [22]. In coarctation of the aorta, stenosis is observed proximal to the ductus arteriosus and distal to the left subclavian artery, this impedes the normal flow of blood through the aorta. Simultaneous cardiac anomalies can also accompany CoA, bicuspid aortic valve is being the most common, therefore, a close examination of the heart is required [23, 24]. In transposition of the great arteries an atypical origin of the arteries is seen at the base of the heart [23].

### 3.2. Microscopic investigations

In cases related to myocardial infarction in SCD, it is important to highlight the fact that histological defects differ based on the date of infarction [25]. Routine Hematoxylin and Eosin (H&E) stain will detect signs of cellular death and necrosis after 6 to 8 hours of ischemia. These signs include myofiber eosinophilia, elongation of sarcomeres and nuclei, wavy fibers, interstitial edema and contraction band. Therefore, if SCD occurs in early ischemia before this time frame, these changes will not be detected neither histologically nor macroscopically. From this perspective, many studies have suggested the role of histochemical and immunohistochemical staining in the detection of early ischemia. C5b-C9 complex, which is the last creation of the activated complement cascade that forms the membrane attack complex (MAC), is a specific marker for early necrosis. Other markers being tested include complement proteins like C1, C3, C8, C9 and inflammatory mediators such as CD15, IL-1, IL-6, TNF-, IL-15, IL-8, MCP-1,

CD18 as well as tryptase which have shown positive results in early hours of ischemia. It has been documented by several studies on human as well on animal models that myoglobin and troponins especially troponin T are lost during the early stages of myocardial ischemia and observing their absence using immunohistochemical staining is a useful test in detecting early infarction [26]. Moreover, Microscopic findings in HCM include myocardial fiber disarray and myocytes hypertrophy which is associated with 4 fold increase in cell and nuclear size. An abnormal thickening of the coronary arterioles can also be noted [27, 28]. Identifying myocarditis as a cause in SCD is often a difficult process as the microscopic findings are not always accurate. Based on the principal type of infiltrating inflammatory cells, it can be classified into lymphocytic, neutrophilic, eosinophilic and giant cell types. Diffuse inflammation with myocytes necrosis and conduction system damage is the microscopic findings that have the highest probability of diagnosing myocarditis as a cause of death [21]. Histologically, the classic findings of vegetation in infective endocarditis are tissue infiltration of neutrophils and fibrin deposition along with the implicated bacteria can be identified using gram stain. In rare cases, a vegetative embolus may lodge in a coronary artery which can be the cause of SCD, in these circumstances the embolus has the same characteristic microscopic picture of the original vegetation [5]. The hearts of patients who suffered from arrhythmogenic right ventricular dysplasia exhibit microscopic features of fat infiltrating the myocardium, fibrofatty replacement along with patchy areas of myocarditis [18]. In cases of rare cardiomyopathies such as those associated with mitochondrial and storage diseases, an electron microscopy is usually required [9].

### 3.3. Toxicological studies in SCD

Toxicological examination is also mandatory and scientifically a useful tool to determine the causes of SCD. Toxicological analysis can identify if sudden death is triggered by administration of toxic substances. This latter could be prescribed and non-prescribed medications, illicit or recreational drugs that are widely abused by athletes or young individuals [29]. The rising use of recreational drugs among adolescents and young adults is a common phenomenon seen worldwide. Cocaine is a well-known stimulant drug of abuse that is linked to cardiac death, along with amphetamines. Their respective mechanisms of action are similar as they both cause the release of catecholamines such as norepinephrine, dopamine and serotonin leading to coronary vasospasm and thrombus formation. This combination of adverse effects can lead to myocardial ischemia and infarction in the absence of atherosclerosis [30]. Cannabis is another commonly abused drug that it is becoming more legalized in many countries. Although its associated side effects are typically low, it causes cardiovascular side effects. Cannabis raises the blood pressure and heart rate and can induce arrhythmia and myocardial ischemia [31]. In rare instances, the occurrence of SCD in acute cannabis intoxication has been described. It has been also demonstrated that some drugs have been strongly associated with SCD including the antipsychotic medications. Their proposed mechanism of action is associated with the development of myocarditis and the ability to cause a prolongation in QT interval which then progresses into a life-threatening arrhythmia [32]. Referring to the guidelines adapted by the Society of Forensic Toxicologists and the American Academy of Forensic Sciences [33], multiple samples should be studied including heart blood, peripheral blood collected from the femoral vein, urine or bile. Hair from the back of

the scalp or pubic hair should also be used for doing toxicological analysis [9]. Therefore, toxicological analysis is to be considered as a cornerstone in postmortem studies, in order to screen for potential ingestion of medications that are linked to cardiac side effects and to look for possible intoxication of drug of abuse.

### 3.4. Molecular studies of cardiac autopsy

The causes of SCD, which remain unidentified after complete autopsy procedures including the macroscopic, microscopic and toxicological examinations, are classified as sudden arrhythmic death syndromes. At this point, molecular testing plays a critical role in identifying the SCD in victims of structurally normal heart. Sudden arrhythmic death syndromes (SAD) are defined as genetic heart diseases that cause sudden death in young people that apparently look healthy. They are classified into two subcategories: (1) cardiac channelopathies that are caused by mutations affecting different cardiac membrane channels such as Long QT syndrome (LQTS), Short QT syndrome (SQTS), and Brugada syndrome (BrS) or cellular structure resulting in dysregulated Ca<sup>2+</sup> release including catecholaminergic polymorphic ventricular tachycardia (CPVT) [34, 35], and (2) cardiomyopathies such as hypertrophic cardiomyopathy (HCM), dilated cardiomyopathy (DCM), arrhythmogenic cardiomyopathy (AC) and others. At least 64 genes have been identified to cause cardiomyopathies syndromes [36]. Although cardiomyopathies usually depict distinct structural alterations on autopsy, some cases, especially in children may present a structurally normal heart [14]. This is in contrast with inherited diseases of conduction (LQTS, BrS) that do not show any structural abnormalities on autopsy, making it a challenging task to the pathologist to detect the causes of SCD [13]. LQTS are characterized by QT interval on ECG that leads to the development of syncope and arrhythmic disturbances which are directly linked to SCD such as torsade de pointes. The majority of LQTS is autosomal dominant. There are 14 types of LQTS that have been identified based on the gene involved and location of mutation. For instance, KCNQ1 mutation is associated with the development of LQTS1, KCNH2 with LQTS2 and SCN5A with LQTS3. It has been indicated that LQTS1 is triggered by exercising such as swimming, LQTS2 by sudden loud noises such as alarms, while LQTS3 occurs during sleep or at rest [34, 35]. SQTS is considered as the severest condition of cardiac channelopathies. It is characterized by K<sup>+</sup> channel gain-of-function mutations. Additionally, BrS also can cause SCD in 4–12% of the cases. It is characterized by genetic mutation targeting Na<sup>+</sup> channels [34, 35]. Its ECG pattern is associated with an elevated ST segment that develops either unexpectedly or as a result of the administration of sodium channel blockers [37]. BrS is associated with monomorphic ventricular tachycardia that usually occurs during sleep, at rest or in case of severe fever. Unlike LQTS, data available on gene specific prognostication and risk stratification are very limited in the case of SQTS and BrS [34, 35]. On the other side, CPVT is a significant cause of sudden unexplained death. It is most common among young males. Individuals with CPVT show normal resting ECG with functionally and structurally normal heart. They can develop syncope as a result of physical activity, a strong emotional stimulus or SD secondary to Catecholaminergic Polymorphic Ventricular Tachycardia (CPVT). The current genetic techniques allow us to unmask the etiology behind SCD. The detection of an underlying genetic mutation facilitates the process of detecting people at risk in order to take preventive measures [14]. Polymerase chain reaction (PCR) is one example of the postmortem molecular investigation techniques. It involves the amplification of

a specific DNA sequence by an enzymatic reaction. It consists of multiple rounds of heat denaturation, annealing of primers and a DNA polymerase dependent chain elongation [3] of a blood sample collected in postmortem exam for genetic testing or from a fixed tissue sample [38]. This molecular technique, could detect mutations in the genes coding for potassium channels (KCNQ1, KCNH2), sodium channels (SCN5A), and the RYR2 gene which causes tachycardia (CPVT) [39, 40]. The provided table (**Table 1**) shows the 90 implicated genes for the most common inherited

---

#### A. Cardiomyopathies

##### a. Dilated cardiomyopathy

- ATP-binding cassette, subfamily C (CFTR/MRP), member 9 [ABCC9]
- Bcl2-associated athanogene 3 [BAG3]
- Desmin [DES]
- Dystrophin muscular dystrophy [DMD]
- Emerin (Emery-Dreifuss muscular dystrophy) [EMD]
- Eyes absent homolog 4 (Drosophila) [EYA4]
- Fukuyama-type congenital muscular dystrophy (fukutin)1 [FCMD]
- Integrin-linked kinase ILK
- Lamin A/C [LMNA]
- Myopalladin [MYPN]
- Presenilin 1 [PSEN1]
- Presenilin 2 [PSEN2]
- RNA-binding motif protein 20 [RBM20]
- Sarcoglycan, d (dystrophin-associated glycoprotein) [SGCD]
- Tafazzin [TAZ]

##### b. Hypertrophic cardiomyopathy

- Calreticulin 3 [CALR3]
- Frataxin [FXN]
- GATA-binding protein 4 GLA galactosidase, a [GATA4]
- Jagged 1 [JAG1]
- Junctophilin 2 [JPH2]
- Myosin, light chain 2, regulatory, cardiac, slow [MYL2]
- Myosin, light chain 3, alkali; ventricular, skeletal, slow [MYL3]
- Myomesin 1, 185 kDa [MYOM1]
- Myozenin 2 [MYOZ2]
- Protein kinase, AMP-activated, 2 noncatalytic subunit [PRKAG2]
- Protein tyrosine phosphatase, nonreceptor type 11 [PTPN11]
- V-raf-1 murine leukemia viral oncogene homolog 1 [RAF1]

##### c. Arrhythmogenic cardiomyopathy

- Desmocollin 2 [DSC2]



- Desmoglein 2 [DSG2]
- Desmoplakin [DSP]
- Junction plakoglobin [JUP]
- Phospholamban [PLN]
- Transforming growth factor, [b3 TGFB3]
- Transmembrane protein 43 [TMEM43]

## B. Channelopathies

### a. Long QT syndrome (LQTS)

- A kinase (PRKA) anchor protein (yotiao) 9 [AKAP9]
- Ankyrin 2 [ANK2]
- Calmodulin 2 [CALM2]
- Caveolin 3 [CAV3]
- Potassium voltage-gated channel, Isk-related family, member 1 [KCNE1]
- Potassium voltage-gated channel, Isk-related family, member 2 [KCNE2]
- Potassium voltage-gated channel, subfamily H (eag-related), member 2 [KCNH2]
- Potassium inwardly rectifying channel, subfamily J, member 2 [KCNJ2]
- Potassium inwardly rectifying channel, subfamily J, member 5 [KCNJ5]
- Potassium voltage-gated channel, KQT-like subfamily, member 1 [KCNQ1]
- Sodium channel, voltage-gated, type IV, b [SCN4B]
- Syntrophin, a 1 [SNTA1]

### b. Brugada syndrome (BrS)

- Calcium channel, voltage-dependent, a 2/d subunit 1 [CACNA2D1]
- Calcium channel, voltage-dependent, b 2 subunit [CACNB2]
- Glycerol-3-phosphate dehydrogenase 1-like [GPD1L]
- Calcium channel, voltage-dependent, b 2 subunit [CACNB2]
- Hyperpolarization-activated cyclic nucleotide-gated potassium channel 4 [HCN4]
- Potassium voltage-gated channel, Shal-related family, member 3 [KCND3]
- Potassium voltage-gated channel, Isk-related family, member 3 [KCNE3]
- Potassium inwardly rectifying channel, subfamily J, member 8 [KCNJ8]
- RAN guanine nucleotide release factor [RANGRF]
- Sodium channel, voltage-gated, type I, b [SCN1B]
- Sodium channel, voltage-gated, type III, b [SCN3B]

### c. Catecholaminergic polymorphic ventricular tachycardia (CPVT)

- Triadin [TRDN]
- Ryanodine receptor 2 (cardiac) [RYR2]
- Calmodulin 1 [CALM1]

---

**Table 1.** Common genetic mutations associated with inherited cardiac diseases.

channelopathies and cardiomyopathies. On the other hand, next whole-exome sequencing (WES) is a new available genetic testing technique that may become an important part in post mortem studies in the future [41]. This technique allows us to study the whole genetic library of an individual DNA sample, which is more effective and better than studying a specific gene. To ensure that an adequate WES testing is being performed, it is recommended to use about 5 to 10 ml of blood collected for DNA testing or 5 g of tissue extracted from the heart or spleen [36]. Next Generation Sequencing (NGS) is also new available genetic sequencing technique for detecting channelopathies associated-mutations, which has a sensitivity of 72% for LQTS cases [42]. Thus, molecular autopsy has taken a major part in revealing the gene mutations associated with cardiac channelopathies and other inherited heart diseases and provided evidence for the importance of cardiological assessment for first-degree family members after SCD in order to prevent future tragedies [43].

#### **4. Non-invasive imaging techniques in SCD**

Minimally invasive or non-invasive autopsy methods have been recently developed and implemented to substitute clinically invasive autopsy. Computed tomography (CT) and Magnetic resonance imaging (MRI) are two imaging modalities that are increasingly used in post-mortem investigation of SCD [17]. Cardiac MRI is considered as reference for ventricular function assessment and risk stratification measurement [44]. The introduction of post mortem computed tomography coronary angiography (PMCTA) has also been shown to be a very powerful tool in demonstrating the patency of the coronaries, identifying stenotic defects in the coronaries and guiding sampling for histology. It enables the detection and documentation of coronary artery calcification. On the other hand, post mortem magnetic resonance (PMMR) has shown its significant diagnostic ability in postmortem autopsy, mainly in assessing the heart valves, myocardial wall thickness, and ischemic changes [45]. Despite the great advantages of these techniques, one adverse event is thrombi dislodgement and the inability to differentiate between pre and post mortem thrombi. Moreover, their high cost and the need of well-trained physicians in this radiological field is also another pitfall [17]. Recent studies have been conducted by Ampazoni et al. on the PMMR to assess its importance as an alternative or an adjuvant to traditional autopsy. Results show that cardiac parameters measured by PMMR may differ from the measures obtained by autopsy and forensic pathologists should be aware of these differences. Additionally, there is no conventional value for wall thickness and valves circumferences when measured by PMMR, thus further research is required to get cutoff values [45].

#### **5. Conventional autopsy vs. non-invasive imaging examination**

Several studies have reinforced the importance of autopsy in investigating the cause behind sudden unexplained death, the nature of cardiac disease in case of SCD, the underlying mechanism, whether it is arrhythmic or mechanical or it originates from genetic mutations, and the possibility of illicit drug abuse [9]. Autopsy is also of vital importance in providing accurate epidemiological data and data for evaluating of the quality of care, identifying and

elucidating new pathological findings, evaluating new medical interventions, improving post-marketing surveillance for adverse effects of drugs, devices, and procedures, improving cardiovascular diseases research and offering powerful tools for education [46, 47]. However, many pitfalls and limitations are encountered with the use of non- forensic autopsies in modern medicine. One of these major challenges is the significant decline of autopsy rate, wherein autopsies are performed after less than 10% of all U.S death. In fact, studies have shown that clinicians and pathologists have no more incentives to perform the autopsy and they are focusing on the new imaging approaches [48]. The most significant consequence of this shift is the increased frequency of clinical diagnostic discrepancies of class I and class II. These errors include the misdiagnosed or undiagnosed conditions that likely lead to patients death (class I) or do not affect the survival (class II), excluding the over or delayed diagnosis [49]. The autopsy rate has declined over the last decades for a number of reasons. The lack of the financial support and direct reimbursement of the pathologists on their services is the major driving force to this decline. The change in economic landscape has led both the public and the private healthcare sectors to increase focus on cost control [48]. For instance, the lack of funding from insurance companies and other payers for advocating postmortem genetic testing made the molecular autopsy less frequent or less practiced by forensic pathologists [47]. More importantly and in the line of autopsy practice, pathologists are facing difficulties in the lack of standardizations of sudden death coding and the variation of SD definition among different regions and countries that hinder their task in determining the precise cause of sudden death. Additionally, the inconsistency in the routine autopsy practice among hospitals, university medical centers and forensic medicine institutes has also been a central issue. This is strongly associated with the inaccurate autopsy reports that are difficult to interpret and do not precisely resolve the diagnostic questions. It has been demonstrated that the quality of the autopsy report was judged to be satisfactory in 52%, good or excellent in a further 23%; but was poor or unacceptable in 26% [50], suggesting that only half of the autopsies are satisfactory and have answered the basic clinical question over the cause of death. But the much more important observed phenomenon is the criteria variation of report formulation. As mentioned, part of the autopsy reports are categorized as good which means that the autopsy report fulfills its main purpose of documenting the cause of death but without much elaboration or details, while unacceptable reports are those that appear to be evidently wrong [50]. For this purpose, the Association for European Cardiovascular Pathology has developed guidelines for autopsy investigation for SCD cases. Basso C et al., have described in details autopsy procedures that should be followed in order to represent the minimum standard that is required in the routine autopsy practice for the adequate assessment of SCD including standard gross examination of the heart, histological sampling, toxicology and molecular examination [9]. Similarly for the case of autopsy reports, there should be nationally uniform criteria and standards for reporting autopsy findings. This includes the diagnostic level of autopsy investigation and the definition of what a postmortem examination comprises. They should also be standardized in topics according to a diagnostic hierarchy that takes into consideration both the logical sequence of events that led to death and the organs involved [50]. On the other side, the introduction of the alternative postmortem imaging techniques has recently replaced to a great extent the use of clinical autopsy. These radiological examination tools have become more feasible for the physicians so that they are no more obliged to ask for consent from victim's next of kin which is often refused

by bereaved families due to cultural and religious objections. Forensic specialists have proved the high diagnostic performance of these postmortem imaging tools in forensic studies. Nevertheless, cardiologists seem unsatisfied with the diagnosis reports of these techniques and they find it hard to replace the conventional autopsy. They consider that the diagnostic accuracy of the imaging tools alone is insufficient for detecting the exact cause of SCD and still believe in autopsy as the gold standard. Misinterpretation is one of the major pitfalls of radiological examination. Radiological findings cannot sometimes distinguish the presence of possible artifacts. These artifacts could be incidental and unrelated to the cause of death [51]. Sometimes postmortem changes can also limit specific imaging diagnosis and interfere with the radiological results such as in thrombosis [52]. Additionally, there are still no gold standards that currently exist for postmortem radiological examination of cardiovascular pathologies.

## 6. Conclusion

Postmortem radiology is a promising approach but currently cannot replace conventional autopsy. In brief, we can conclude that advances in diagnostic technology have not reduced the value of the autopsy and the goal-directed autopsy remains a vital component in the assurance of good medical care [53]. More studies and research are still warranted to establish the validity and limitations of postmortem radiology in the identification of SCD. In the meantime, the use of non-invasive imaging approach should accompany and complement conventional autopsy procedures in order to enhance a significant advancement in the post-mortem investigation of SCD (Figure 1).

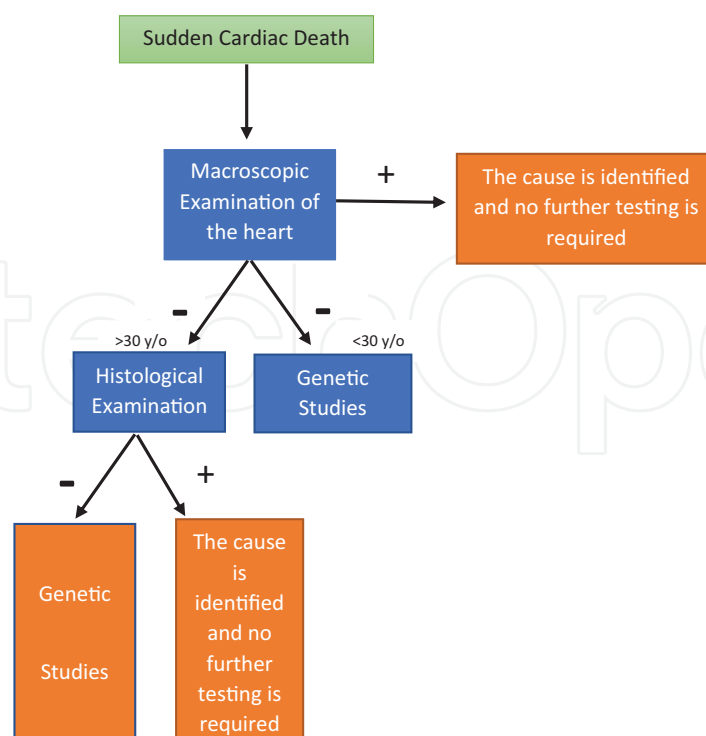


Figure 1. The appropriate steps when dealing with sudden cardiac Death.

## Author details

Kawthar Braysh<sup>1</sup>, Raymond Zerbe<sup>1</sup>, Rosalyn Jurjus Zein<sup>2</sup>, Doureid Oueidat<sup>1</sup>, Jihad Hawi<sup>3</sup>, Luk Oke<sup>4</sup> and Abdo Jurjus<sup>1\*</sup>

\*Address all correspondence to: aj00@aub.edu.lb

1 Department of Anatomy, Cell Biology and Physiological Sciences, American University of Beirut, Beirut, Lebanon

2 Department of Anatomy and Regenerative Biology, School of Medicine and Health Sciences, George Washington University, Washington DC, USA

3 Department of Biomedical Sciences, Faculty of Medicine and Medical Sciences, Balamand University, Lebanon

4 American Center for Investigative Cardiology Silver Spring, Maryland, USA

## References

- [1] Lopshire JC, Zipes DP. Sudden cardiac death: Better understanding of risks, mechanisms, and treatment. *Circulation*. 2006;**114**(11):1134-1136. DOI: 10.1161/CIRCULATIONAHA.106.647933
- [2] Hayashi M, Shimizu W, Albert CM. The spectrum of epidemiology underlying sudden cardiac death. *Circulation Research*. 2015;**116**(12):1887-1906. DOI: 10.1161/CIRCRESAHA.116.304521
- [3] Basso C, Calabrese F, Corrado D, Thiene G. Postmortem diagnosis in sudden cardiac death victims: Macroscopic, microscopic and molecular findings. *Cardiovascular Research*. 2001;**50**(2):290-300
- [4] Virmani R, Burke AP, Farb A. Sudden cardiac death. *Cardiovascular Pathology*. 2001;**10**(5): 211-218
- [5] Castelli JB, Almeida G, Siciliano RF. Sudden death in infective endocarditis. *The Journal Autopsy and Case Reports*. 2016;**6**(3):17-22
- [6] Wilhelm M, Bolliger SA, Bartsch C, Fokstuen S, et al. Sudden cardiac death in forensic medicine – Swiss recommendations for a multidisciplinary approach. *Swiss Medical Weekly*. 2015;**w14129**:145. DOI: 10.4414/smw.2015.14129
- [7] Finocchiaro G, Papadakis M, Sharma S, Sheppard M. Sudden cardiac death. *European Heart Journal*. 2017;**38**(17):1280-1282. DOI: 10.1093/eurheartj/ehx194
- [8] Glassman AH, Bigger JT Jr. Antipsychotic drugs: Prolonged QTc interval, torsade de pointes, and sudden death. *The American Journal of Psychiatry*. 2001;**158**(11):1774-1782. DOI: 10.1176/appi.ajp.158.11.1774

- [9] Basso C, Burke M, Fornes P, Gallagher PJ, de Gouveia RH, Sheppard M, Thiene G, van der Wal A, Association for European Cardiovascular Pathology. Guidelines for autopsy investigation of sudden cardiac death. *Virchows Archiv*. 2008 Jan;**452**(1):11-18. Epub 2007 Oct 20. DOI: 10.1007/s00428-007-0505-5
- [10] Fishman GI, Chugh SS, Dimarco JP, Albert CM, et al. Sudden cardiac death prediction and prevention: Report from a National Heart, Lung, and Blood Institute and Heart Rhythm Society workshop. *Circulation*. 2010 Nov 30;**122**(22):2335-2348. DOI: 10.1161/CIRCULATIONAHA.110.976092
- [11] Wellens HJ, Schwartz PJ, Lindemans FW, Buxton AE, et al. Risk stratification for sudden cardiac death: Current status and challenges for the future. *European Heart Journal*. 2014;**35**(25):1642-1651. DOI: 10.1093/eurheartj/ehu176
- [12] Thiene G, Corrado D, Rigato I, Basso C. Why and how to support screening strategies to prevent sudden death in athletes. *Cell and Tissue Research*. 2012;**348**(2):315-318. DOI: 10.1007/s00441-012-1398-4
- [13] Semsarian C, Ingles J, Wilde AA. Sudden cardiac death in the young: The molecular autopsy and a practical approach to surviving relatives. *European Heart Journal*. 2015; **36**(21):1290-1296. DOI: 10.1093/eurheartj/ehv063
- [14] Goldman AM, Behr ER, Semsarian C, Bagnall RD, Sisodiya S, Cooper PN. Sudden unexpected death in epilepsy genetics: Molecular diagnostics and prevention. *Epilepsia*. 2016;**57**:17-25. DOI: 10.1111/epi.13232
- [15] Bailey D. Guidelines on Autopsy Practice: Sudden Death with Likely Cardiac Pathology; 2015
- [16] Di Gioia CR, Autore C, Romeo DM, Ciallella C, et al. Sudden cardiac death in younger adults: Autopsy diagnosis as a tool for preventive medicine. *Human Pathology*. 2006;**37**(7):794-801. DOI: 10.1016/j.humpath.2006.03.008
- [17] Michaud K, Grabherr S, Jackowski C, Bollmann MD, Doenz F, Mangin P. Postmortem imaging of sudden cardiac death. *International Journal of Legal Medicine*. 2014 Jan;**128**(1):127-137. DOI: 10.1007/s00414-013-0819-6
- [18] Zipes DP, Wellens HJ. Sudden cardiac death. *Circulation*. 1998;**98**(21):2334-2351
- [19] Carrizo S, Peinado RP, Sanchez-Recalde A, Ruiz-Garcia J, et al. Clinical and angiographic characteristics of patients with acute coronary syndrome associated with sudden cardiac death. *Hellenic Journal of Cardiology*. 2015;**56**(2):136-141
- [20] Hashimura H, Kimura F, Ishibashi-Ueda H, Morita Y, et al. Radiologic-pathologic correlation of primary and secondary cardiomyopathies: MR imaging and histopathologic findings in hearts from autopsy and transplantation. *Radiographics*. 2017;**37**(3):719-736. DOI: 10.1148/rg.2017160082
- [21] Li L, Zhang Y, Burke A, Xue A, et al. Demographic, clinical and pathological features of sudden deaths due to myocarditis: Results from a state-wide population-based autopsy study. *Forensic Science International*. 2017;**272**:81-86. DOI: 10.1016/j.forsciint.2016.12.037

- [22] Lynge TH, Jeppesen AG, Winkel BG, Sondergaard L, Risgaard B, Tfelt-Hansen J. Decline in incidence of sudden cardiac death caused by congenital heart disease after implementation of nationwide prenatal ultrasound screening: A nationwide study. *Circulation*. 2016;**134**(1). DOI: A14270
- [23] Erickson KL. An approach to the examination of the fetal congenitally malformed heart at autopsy. *Journal of Fetal Medicine*. 2015;**2**(3):135-141
- [24] Sadeghpour A, Alizadehasl A, Mahdavi M. Coarctation of the aorta. In: Sadeghpour A, Kyavar M, Alizadehasl A, editors. *Comprehensive Approach to Adult Congenital Heart Disease*. London: Springer; 2014, p. 289-297
- [25] Takahashi Y, Sano R, Takahashi K, Kominato Y, et al. Use of postmortem coronary computed tomography angiography with water-insoluble contrast medium to detect stenosis of the left anterior descending artery in a case of sudden death. *Legal Medicine (Tokyo)*. 2016;**19**:47-51. DOI: 10.1016/j.legalmed.2016.02.003
- [26] Mondello C, Cardia L, Ventura-Spagnolo E. Immunohistochemical detection of early myocardial infarction: A systematic review. *International Journal of Legal Medicine*. 2017;**131**(2):411-421. DOI: 10.1007/s00414-016-1494-1
- [27] Sabater-Molina M, Pérez-Sánchez I, Hernández Del Rincón JP, Gimeno JR. Genetics of hypertrophic cardiomyopathy: A review of current state. *Clinical Genetics*. 2017. DOI: 10.1111/cge.13027
- [28] Tavora F, Cresswell N, Li L, Ripple M, Fowler D, Burke A. Morphologic features of exertional versus nonexertional sudden death in patients with hypertrophic cardiomyopathy. *The American Journal of Cardiology*. 2010;**105**(4):532-537. DOI: 10.1016/j.amjcard.2009.10.022
- [29] Kennedy MC, Lawrence C. Anabolic steroid abuse and cardiac death. *The Medical Journal of Australia*. 1993;**158**(5):346-348
- [30] Fischbach P. The role of illicit drug use in sudden death in the young. *Cardiology in the Young*. 2017;**27**(S1):S75-S79. DOI: 10.1017/S1047951116002274
- [31] Hartung B, Kauferstein S, Ritz-Timme S, Daldrup T. Sudden unexpected death under acute influence of cannabis. *Forensic Science International*. 2014;**237**:e11-e13. DOI: 10.1016/j.forsciint.2014.02.001
- [32] Straus SM, Bleumink GS, Dieleman JP, van der Lei J, et al. Antipsychotics and the risk of sudden cardiac death. *Archives of Internal Medicine*. 2004;**164**(12):1293-1297
- [33] SOFT/AAFS Forensic Laboratory Guidelines. 2006. Available from: [http://www.softtox.org/files/Guidelines\\_2006\\_Final.pdf](http://www.softtox.org/files/Guidelines_2006_Final.pdf)
- [34] Behere SP, Weindling SN. Inherited arrhythmias: The cardiac channelopathies. *Annals of Pediatric Cardiology*. 2015;**8**(3):210-220. DOI: 10.4103/0974-2069.164695
- [35] Schwartz PJ, Ackerman MJ, George Jr AL, Wilde AM. Impact of genetics on the clinical management of channelopathies. *Journal of the American College of Cardiology*. 2013;**62**(3):169-180. DOI: doi.org/10.1016/j.jacc.2013.04.044

- [36] Loporcaro CG, Tester DJ, Maleszewski JJ, Kruisselbrink T, Ackerman MJ. Confirmation of cause and manner of death via a comprehensive cardiac autopsy including whole exome next-generation sequencing. *Archives of Pathology & Laboratory Medicine*. 2014;**138**(8):1083-1089. DOI: 10.5858/arpa.2013-0479-SA
- [37] Lahrouchi N, Behr ER, Bezzina CR. Next-generation sequencing in post-mortem genetic testing of young sudden cardiac death cases. *Frontiers in Cardiovascular Medicine*. 2016;**3**:13. DOI: 10.3389/fcvm.2016.00013
- [38] Bagnall RD, Ingles J, Yeates L, Berkovic SF, Semsarian C. Exome sequencing-based molecular autopsy of formalin-fixed paraffin-embedded tissue after sudden death. *Genetics in Medicine*. 2017. DOI: 10.1038/gim.2017.15
- [39] Semsarian C, Ingles J. Molecular autopsy in victims of inherited arrhythmias. *Journal of Arrhythmia*. 2016 Oct;**32**(5):359-365
- [40] Bagnall RD, Semsarian C. Role of the molecular autopsy in the investigation of sudden cardiac death. *Progress in Pediatric Cardiology*. 2017;**45**:17-23. DOI: doi.org/10.1016/j.ppedcard.2017.02.005
- [41] Sanchez O, Campuzano O, Fernández-Falgueras A, Sarquella-Brugada G, et al. Natural and undetermined sudden death: Value of post-mortem genetic investigation. *PLoS One*. 2016 Dec 8;**11**(12):e0167358. DOI: 10.1371/journal.pone.0167358
- [42] Lieve KV, Williams L, Daly A, Richard G, Bale S, Macaya D, Chung WK. Results of genetic testing in 855 consecutive unrelated patients referred for long QT syndrome in a clinical laboratory. *Genetic Testing and Molecular Biomarkers*. 2013;**17**(7):553-561. DOI: 10.1089/gtmb.2012.0118
- [43] Torkamani A, Muse ED, Spencer EG, Rueda M, Wagner GN, Lucas JR, Topol EJ. Molecular autopsy for sudden unexpected death. *Journal of the American Medical Association*. 2016;**316**(14):1492-1494. DOI: 10.1001/jama.2016.11445
- [44] Sparrow PJ, Merchant N, Provost YL, Doyle DJ, Nguyen ET, Paul NS. CT and MR imaging findings in patients with acquired heart disease at risk for sudden cardiac death. *Radiographics*. 2009;**29**(3):805-823. DOI: 10.1148/rg.293085715
- [45] Ampanozi G, Hatch GM, Flach PM, Thali MJ, Ruder TD. Postmortem magnetic resonance imaging: Reproducing typical autopsy heart measurements. *Legal Medicine (Tokyo)*. 2015;**17**(6):493-498. DOI: 10.1016/j.legalmed.2015.10.008
- [46] Saad R, Yamada AT, Pereira da Rosa FH, Gutierrez PS, Mansur AJ. Comparison between clinical and autopsy diagnoses in a cardiology hospital. *Heart*. 2007;**93**(11):1414-1419
- [47] Shojania KG, Burton EC. The vanishing nonforensic autopsy. *The New England Journal of Medicine*. 2008;**358**(9):873-875. DOI: 10.1056/NEJMp0707996
- [48] Nemetz PN, Tanglos E, Sands LP, Fisher WP Jr, Newman WP 3rd, Burton EC. Attitudes toward the autopsy—an 8-state survey. *MedGenMed*. 2006 Sep 21;**8**(3):80



- [49] Graber ML. The incidence of diagnostic error in medicine. *BMJ Quality and Safety*. 2013 Oct;**22**(Suppl 2):ii21-ii27. DOI: 10.1136/bmjqs-2012-001615
- [50] A Report of the National Confidential Enquiry into Patient Outcome and Death (2006) – The Coroner’s Autopsy: Do we Deserve Better?. Available from: <http://www.ncepod.org.uk/2006Report/Downloads/Coronial%20Autopsy%20Report%202006.pdf>
- [51] Shriki JE, Shinbane J, Lee C, Khan AR, Burns N, Hindoyan A, Wilcox A. Incidental myocardial infarct on conventional nongated CT: A review of the spectrum of findings with gated CT and cardiac MRI correlation. *AJR. American Journal of Roentgenology*. 2012;**198**(3):496-504. DOI: 10.2214/AJR.11.7683
- [52] Roberts IS, Benamore RE, Benbow EW, Lee SH, et al. Post-mortem imaging as an alternative to autopsy in the diagnosis of adult deaths: A validation study. *Lancet*. 2012 Jan 14;**379**(9811):136-142. DOI: 10.1016/S0140-6736(11)61483-9
- [53] Goldman L, Sayson R, Robbins S, Cohn LH, Bettmann M, Weisberg M. The value of the autopsy in three medical eras. *The New England Journal of Medicine*. 1983 Apr 28;**308**(17):1000-1005