

We are IntechOpen, the world's leading publisher of Open Access books Built by scientists, for scientists

4,800

Open access books available

122,000

International authors and editors

135M

Downloads

Our authors are among the

154

Countries delivered to

TOP 1%

most cited scientists

12.2%

Contributors from top 500 universities



WEB OF SCIENCE™

Selection of our books indexed in the Book Citation Index
in Web of Science™ Core Collection (BKCI)

Interested in publishing with us?
Contact book.department@intechopen.com

Numbers displayed above are based on latest data collected.
For more information visit www.intechopen.com



Assessment of Human Sperm Cells Morphological Parameters

Kristina Lasiene

Additional information is available at the end of the chapter

<http://dx.doi.org/10.5772/intechopen.71413>

Abstract

The quality of spermatozoa has a direct influence on the fertilization and developmental competence of embryos. The aim of this work was to review the methods of spermatozoa morphology assessment, features of the normal spermatozoa and the reasons of their several abnormalities. Three methods can be used for the evaluation of spermatozoa morphology in the *in vitro* fertilization (IVF) laboratory: (1) light microscopy of stained spermatozoa, (2) motile sperm organelle morphology examination (MSOME) and (3) polarized light microscopy. The analysis of spermatozoa morphology includes the assessment of head, neck, midpiece and tail. Morphologically abnormal spermatozoa are categorized into subgroups according to the defects of the head, neck, midpiece and/or tail. Before IVF and intracytoplasmic sperm injection (ICSI), the quality of spermatozoa must be estimated exactly, because this has the high influence on embryo development. Therefore the analysis of the morphological parameters of spermatozoa using the light microscopy, MSOME, in combination with precise head birefringence detection using the polarized microscopy, could give the best fertilization rate and embryo quality after IVF and ICSI.

Keywords: abnormalities, human, morphology, normal, spermatozoa

1. Introduction

The development of *in vitro* produced human embryos is directly dependent on the quality of the oocytes and spermatozoa which are used for *in vitro* fertilization (IVF) and intracytoplasmic sperm injection (ICSI). The examination of oocyte and spermatozoa morphology is currently considered to be a tool devoted to the fertility prognosis. Morphology of spermatozoa has been recognized as the best predictor of outcome for natural fertilization, intrauterine insemination and IVF. The spermatozoa morphology also plays a significant role in ICSI outcome [1].

The aim of this work was to review the methods of spermatozoa morphology assessment, features of the normal spermatozoa and the reasons of their various abnormalities.

2. Semen collection and analysis

The sample of semen should be collected after 2–7 days of sexual abstinence. The first ejaculate gives a correct conclusion in at least 85% of cases. It is helpful to examine two or three samples to obtain more precise data [2, 3].

Semen analysis includes:

- Spermatozoa analysis (number, vitality, motility, morphology),
- Immunological analysis (anti-spermatozoa antibodies detection),
- Seminal fluid analysis (biochemical markers of accessory glands secretions) [3].

2.1. Evaluation of the spermatozoa morphology

2.1.1. Light microscopy of stained spermatozoa

The light microscopy of stained spermatozoa is the fundamental and commonly used method for evaluation of spermatozoa morphology. Two techniques can be used for this evaluation: (1) the microscopic analysis of stained samples as visual observations of spermatozoa (manual method) and (2) computerized analysis. Primarily for both methods, the stained smears of semen must be prepared. The droplet of the semen sample are smeared on a glass slide, dried in the air and fixed. The smears must be stained for providing sharp contrast for defining the spermatozoa outline and cell details. There are a lot of methods for the staining of human and animal spermatozoa. World Health Organization recommends three routine staining methods for the evaluation of morphology of human spermatozoa: Papanicolaou, Shorr or Diff-Quik (Rapidiff) [3, 4]. Some laboratories use a new stain Sperm-Blue[®] successfully [5, 6].

The stained smears are analyzed by the magnification 1000× with oil immersion. Using a manual method, the laboratory technician examines 200 spermatozoa and categorizes each spermatozoon as normal or abnormal. Subsequently, the anomalies are classified using strictly defined criteria. The measurement of spermatozoa can be performed using the ocular micrometer. By computerized analysis method, various computer analyzing programs, systems and modules categorize and measure automatically different morphological features of each selected spermatozoon [5, 7–11].

A few classifications of human spermatozoa morphology have been originated and used worldwide: MacLeod's [12], David's [13, 14], Dusseldorf [15, 16], Strict (Tygerberg's) criteria [17, 18] and others. The World Health Organization (WHO) confirmed the Strict (Tygerberg's) criteria as conventional standard for spermatozoa morphology [4].

2.1.2. Motile sperm organelle morphology examination (MSOME)

This method is used for evaluating the morphology of the live (non-fixed, non-stained) spermatozoa before the ICSI. Using the high magnification ($6000\times$ and more) by the inverted computerized microscope, it is possible to observe the morphological abnormalities in spermatozoa, which are not visible with magnification $400\times$ (**Figure 1**). The neck, tail, midpiece, mitochondria, acrosome and post-acrosomal lamina and the nucleus of spermatozoon are morphologically examined in live motile spermatozoa [19–25].

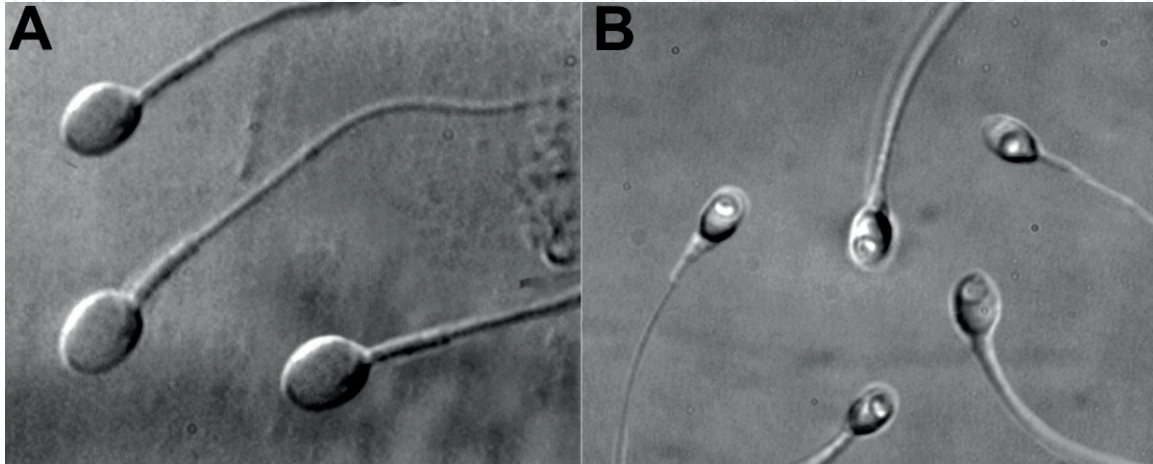


Figure 1. Spermatozoa morphology using MSOME ([19], open access). (A) Normal spermatozoa observed at high magnification ($8400\times$); (B) spermatozoa with large nuclear vacuoles observed at high magnification ($8400\times$).

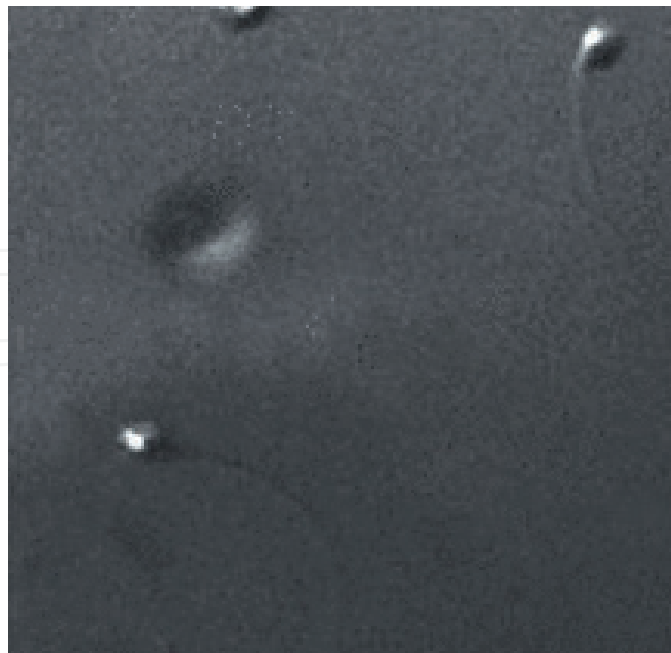

Figure 2. The birefringence of human spermatozoa ([26], with permission).

2.1.3. Polarized light microscopy

An estimation of head birefringence by polarized light using polarized microscope method is used for analysis of live spermatozoa morphological quality. This birefringence is associated with sub-acrosomal protein filaments and nucleoprotein filaments (**Figure 2**). The presence of birefringence in the head indicates the good morphology of a spermatozoon [26–31].

3. Morphology of the normal spermatozoon

The analysis of spermatozoa morphology includes the assessment of head, neck, midpiece and tail. The analysis of the head includes the assessment of head shape and size, nucleus shape and size, acrosomal area (acrosomal index) and acrosomal vacuoles. The shape, size and cytoplasmic droplets are analyzed in the midpiece, principal and terminal pieces of tail (**Table 1**).

The acrosomal vacuoles are concentrated between the inner and outer acrosomal membranes. They present the migration of acrosin to the spermatozoon surface and may be the earliest event characterizing the beginning of the acrosome reaction. The presence of these vacuoles is considered as a significant marker of successful fertilization of oocytes *in vitro* [37, 38].

Normal human spermatozoa carry the X or the Y chromosome. Measuring the spermatozoa sorted by the polymerase chain reaction (PCR) sexing, Cui [39] estimated that the X chromosome-bearing spermatozoa have significantly greater head length, neck and tail length, head perimeter and head area than Y chromosome-bearing spermatozoa. The neck and tail were

	Features		References
Head	Shape	Oval	[4]
	Size	Length 4–5 μm , width 2.5–3.5 μm , length-width ratio 1.5–1.75	
	Acrosomal size	40–70% of total head area	
	Nucleus shape	Smooth, symmetric and oval	[1, 32, 33]
	Nucleus size	Length $4.75 \pm 0.28 \mu\text{m}$, width $3.28 \pm 0.20 \mu\text{m}$	
	Nuclear inside	No regional nuclear disorders, ≤ 1 vacuole that occupies less than 4% of the nuclear area	
Neck		No abaxial implantation	[18]
Midpiece of tail	Shape	Slender	[1, 32–34]
	Size	Length 7–8 μm , width $< 1 \mu\text{m}$	
	Attachment	Axially attached to the head	
	Cytoplasmic droplets	No cytoplasmic droplets and/or disorders or less than half size of normal head	
	Mitochondria	Not fragmented or damaged	
Principal and terminal pieces of tail	Shape	Straight, uniform, and thinner than the midpiece, uncoiled	[34–36]
	Size	Length 45–50 μm , tail/head length ratio 10.3 ± 0.2	

Table 1. Features of morphologically normal spermatozoon.

	Papanicolaou	Rapidiff®	SpermBlue®	Fresh
Length (µm)	4.28 ± 0.27a	5.17 ± 0.27b	4.73 ± 0.27c	4.79 ± 0.26
Width (µm)	2.65 ± 0.19a	3.12 ± 0.21b	2.75 ± 0.24a	2.82 ± 0.23
Area (µm ²)	9.26 ± 0.99a	12.87 ± 1.19b	10.47 ± 1.21c	—
Perimeter (µm)	11.83 ± 0.69a	14.33 ± 0.75b	12.99 ± 0.80c	—
Ellipticity	1.63 ± 0.11	1.68 ± 0.10	1.75 ± 0.13	1.73 ± 0.12
Width/length ratio	0.62 ± 0.04	0.60 ± 0.04	0.58 ± 0.04	0.59 ± 0.04
Elongation	0.23 ± 0.03	0.25 ± 0.03	0.27 ± 0.03	0.26 ± 0.03
Roughness	0.83 ± 0.02	0.79 ± 0.02	0.78 ± 0.03	—
Regularity	0.96 ± 0.01	0.98 ± 0.01	0.97 ± 0.02	—
Acrosome coverage (%)	32.76 ± 7.43	23.73 ± 7.97	46.29 ± 8.63	—

Table 2. The comparison of sperm head morphometry for the three staining techniques and spermatozoa of fresh semen (mean ± SD) [42].

also significantly longer in X chromosome-bearing spermatozoa. A difference of volume of X- and Y-bearing spermatozoa heads is associated with the difference of DNA content (3.5–4%) [40].

Therefore, the morphometric parameters of normal spermatozoon can differ according to staining method of sperm smear [11, 41]. Maree with co-authors [42] maintained that fixatives and stains can change the size of spermatozoa. They reported that morphometric parameters of SpermBlue® stained spermatozoa head differed least from parameters of fresh non-stained spermatozoa (**Table 2**). Also the results can differ according the technician [17].

The live morphologically normal spermatozoa can be selected by sperm head birefringence for ICSI. Two types of head birefringence are ascertained on the basis of acrosome integrity: (1) partial head birefringence in acrosome-reacted spermatozoa and (2) total head birefringence in acrosome-non-reacted spermatozoa. Using acrosome-reacted spermatozoa shows better ICSI results [28–30]. Spermatozoa with partial head birefringence can present lower ratio of DNA fragmentation and higher ratio of normal nucleus [29]. In other hand, spermatozoa with nuclear vacuoles and DNA fragmentation can show the normal head birefringence. And otherwise, some spermatozoa with normal MSOME morphology and without DNA fragmentation can show no birefringence. Therefore the scientists recommend combining MSOME with evaluation of the head birefringence. It was determined that the lowest amount of DNA fragmentation occurs in sperm selected by MSOME and birefringence, compared to sperm selected *via* just one of the two methods alone [43].

4. Morphological abnormalities of spermatozoa

The abnormalities in morphology of spermatozoa have a negative effect on the outcome of IVF and ICSI. Morphologically abnormal spermatozoa analyzed by light microscopy or MSOME are categorized into subgroups according to the defects of the head, neck, midpiece and/or tail.

4.1. Abnormalities of the head

Spermatozoa, with head size and shape abnormalities (large, small, tapered, pyriform, round and amorphous heads), vacuolated heads, heads with small acrosomal area (<40% of head area), with double or multiple heads and without head are often found in the semen samples (**Figure 3**).

The cause of acephalic spermatozoa can be biallelic *SUN5* mutations or homozygous deletion of *SUN5* or mutation of *BRDT* and other genes [44–46].

Large-headed (macrocephalous) spermatozoa are defined as those with a length > 4.7 μm and a width > 3.2 μm . Large head can indicate insufficient shrinking of the nucleus, abnormally

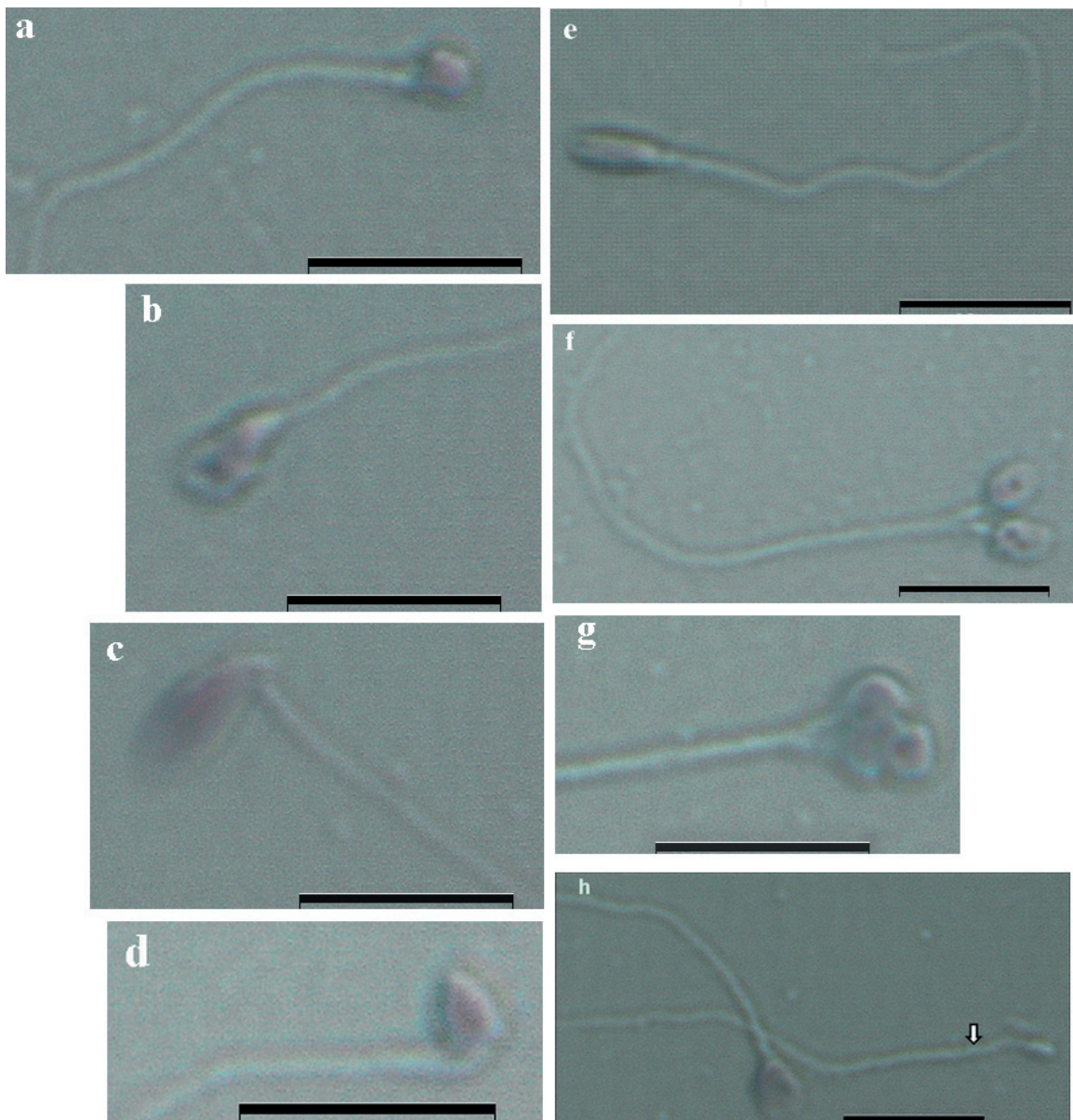


Figure 3. Spermatozoa with abnormal head morphology. (a) Round head; (b) amorphous head; (c) large head and bent neck; (d) small tapered head and bent neck; (e) elongated head; (f) two-headed; (g) multiple-headed and (h) acephalic spermatozoon (arrow). Bar = 10 μm .

condensed chromatin, diploidy and aneuploidy of spermatozoa. Detailed genetic analysis shows that large-headed spermatozoa of some patients can have the homozygous mutation (*c.144delC*) in the *Aurora kinase C (AURKC)* gene. These spermatozoa of *AURKC*-deficient patients cannot complete meiosis in the absence of functional *AURKC*. Therefore they can be tetraploid [47–50].

Small-headed (microcephalous) spermatozoa are defined as those with a length < 3.5 μm and a width < 2.5 μm . These spermatozoa can have the excessive shrunk nucleus and abnormally condensed chromatin and fragmented DNA. They may also present with very small, abnormally formed acrosomes [51, 52].

Elongated-headed spermatozoa are described as being a head length > 5 μm with a width < 3 μm or a length of <5 μm and a width of <2 μm . Pyriform heads are also included under elongation of spermatozoa. Elongation of head is generally recognized as a stress-induced sperm morphology aberration, and is prevalent especially in male accessory gland infections and in the presence of a varicocele. An abnormally elongated nucleus shape of these spermatozoa is related with defects in the nuclear membrane, an increased frequency of chromosomal aneuploidies and altered chromatin compaction. Also anomalies of the neck region, persistence of cytoplasmic residues can often exist in these spermatozoa [52, 53].

Globozoospermia (round-headed sperm syndrome) is genetically determined abnormalities of spermatozoa. This disorder is classified into two categories: (1) total and (2) partial *globozoospermia*. In the total *globozoospermia*, the spermatozoa are easily recognizable by their small, round head shape, high DNA fragmentation and the absence of the acrosome. Owing to the absence of acrosomes, the spermatozoa do not contain acrosomal enzymes. Therefore they are unable to bind and penetrate the *zona pellucida* and fuse with the oolemma of the oocyte. In the case of the partial *globozoospermia*, spermatozoa show the oval head shape with less condensed chromatin, a partially present or remnants of acrosome and a disorganized midpiece. Mitochondria are present not only in the midpiece, but in the spermatozoa head too [52, 54–56].

Amorphous-headed spermatozoa indicate the chromosome 18 disomy and sex chromosome aneuploidy. Also, the high incidence of amorphous heads is relative to other abnormal head forms [57].

Multiple-headed spermatozoa have two or more closed or dissociated heads with or without an acrosome or midpiece. Disorders of movement and fragmented DNA are appropriated for these spermatozoa [51].

Human spermatozoa heads often contain vacuoles. They are not visible on standard magnification and can be observed using MSOME method only. According to their size, vacuoles are divided into three types: (1) large (>50% of surface area), (2) medium (50–25% of surface area) and (3) small (<25% of surface area of total sperm head). Based on the location, they are classified as acrosomal, equatorial and post-acrosomal. Also according to the size and the number of vacuoles in the head of one spermatozoon, they can be classified into three categories: (1) one small vacuole, (2) multiple sporadic vacuoles of various sizes and (3) one large vacuole. Head vacuoles are non-acrosomal origin large nuclear indentations of various sizes and positions, packed with membranous material organized in membrane whorls. Vacuoles

cannot be considered as degenerative structures but can be regarded as a normal feature of the sperm head and does not affect ICSI outcomes. Therefore, some vacuoles can include vacant or low density DNA or show DNA fragmentation or abnormal chromatin compaction. Large vacuoles in the nucleus can indicate aneuploidy, fragmented DNA and chromatin condensation defects in the cell [24, 55, 58–63].

4.2. Abnormalities of the tail

Spermatozoa without tail or with the neck and midpiece defects (bent neck, asymmetrical insertion of the midpiece into the head, thick or irregular midpiece and abnormally thin midpiece) and principal and terminal pieces of tail defects (short, multiple, hairpin, broken, coiled, bent tail and tails of irregular width) are often found in the semen samples (**Figure 4**).

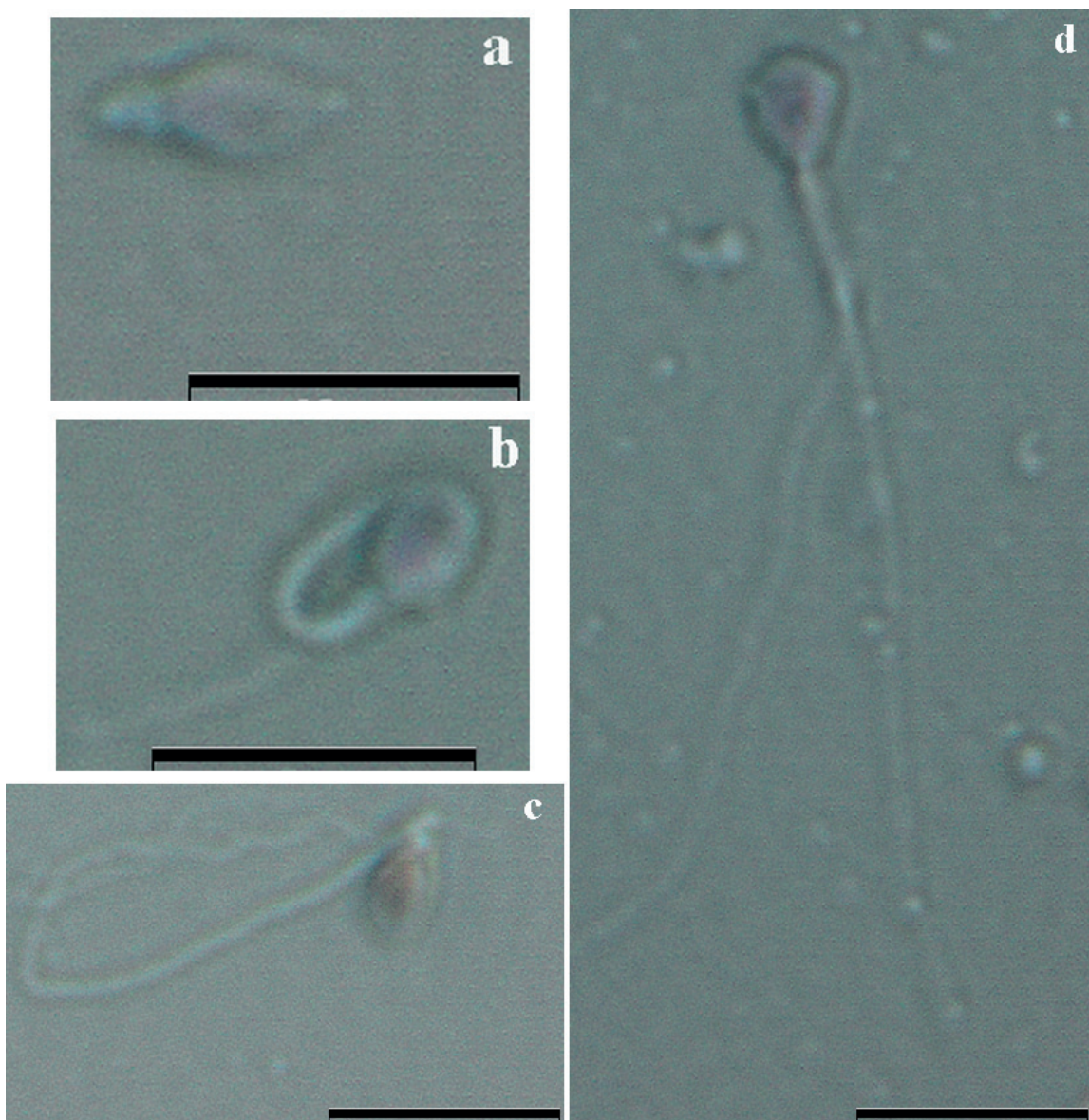


Figure 4. Spermatozoa with abnormal neck and tail morphology. (a) Absent tail; (b) coiled tail; (c) bent neck and (d) two-tailed spermatozoon. Bar = 10 μm .

All abnormalities of spermatozoa neck and tail reduce their motility and therefore have the negative influence on fertilization of oocyte.

Bent necks are associated with DNA fragmentation. Abnormal tails (two-tailed, bent tails, irregular tails) are associated to chromosome 13 disomy, supernumerary chromosomal abnormalities and the cytoskeletal abnormalities (including centriolar defects) [57].

The absence of a tail, the short and broken tail may be related to axonemal abnormalities that are only visible with electron microscopy, and an unknown genetic origin of these abnormalities could be hypothesized [64, 65]. Coiled tails of spermatozoa can be associated with varicocele and epididymal dysfunction [66, 67].

The spermatozoa can often have cytoplasmic droplets and cytoplasmic residues. Cytoplasmic droplets are small, regular osmotically sensitive vesicles which are located at the neck as opposed to the end of the annulus (**Figure 5**). Cytoplasmic droplets of normal human spermatozoa are still present after ejaculation and have no negative influence on cell function.

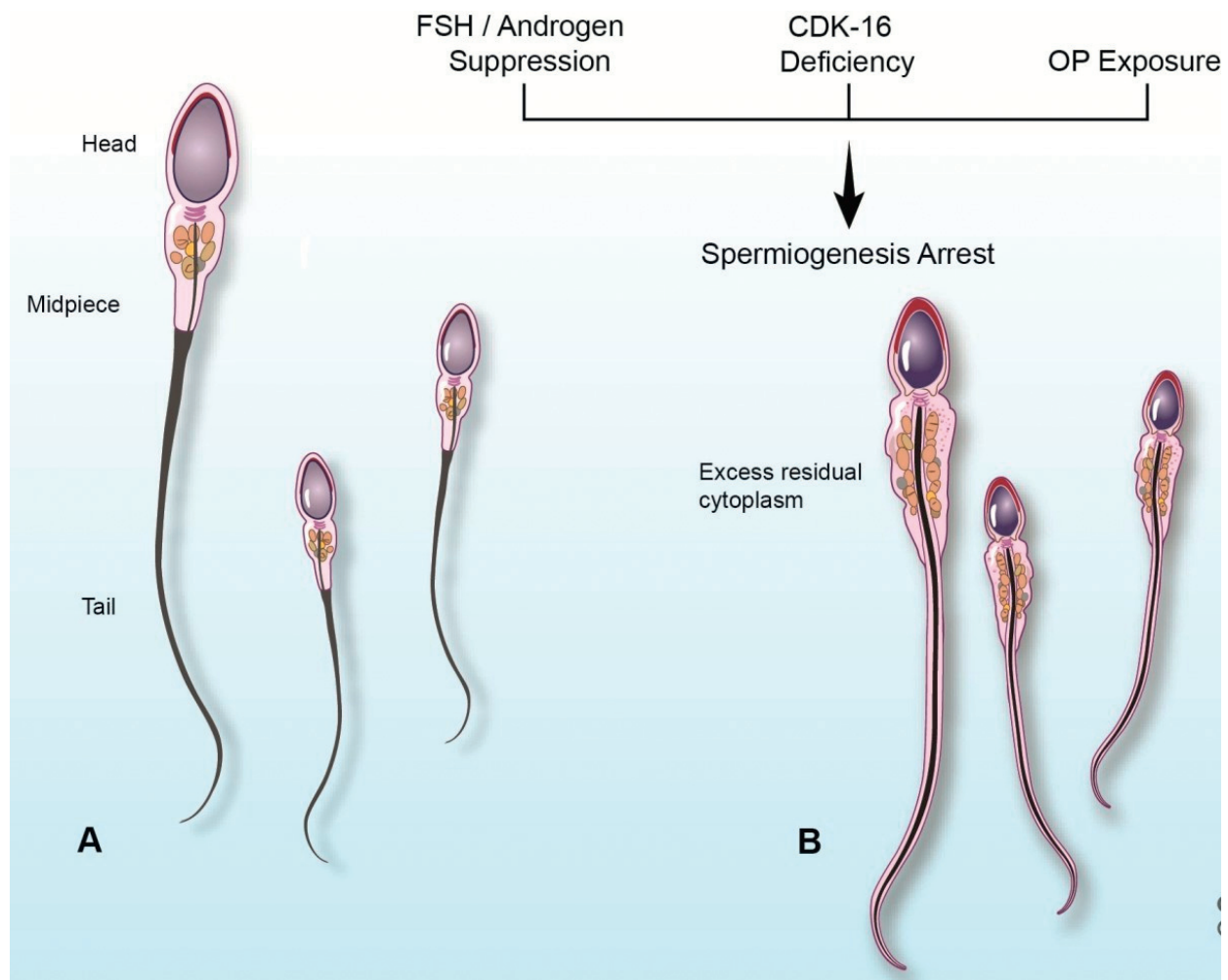


Figure 5. Cytoplasmic droplets and residual cytoplasm structure ([68], open access). (A) Spermatozoa with cytoplasmic droplets and (B) spermatozoa with residual cytoplasm.

Cytoplasmic residues are large, irregular material along the midpiece and can indicate the abnormal spermiogenesis (**Figure 6**). They form as an outcome of incomplete cytoplasmic extrusion during spermiogenesis in the causes of suppression of FSH and/or androgens, deficiency of cyclin-dependent kinase 16 (*CDK16*) and organophosphorus pesticide (OP) exposure. In comparison to the cytoplasmic droplet, cytoplasmic residues contain major quantity of cytoplasmic enzymes, which produce pathological amounts of reactive oxygen species. These species can negatively affect spermatozoa function including peroxidative damage to the cell membrane, DNA damage, mitochondrial dysfunction, impaired interaction with the female reproductive tract and lead to male infertility [1, 32, 52, 68, 69].

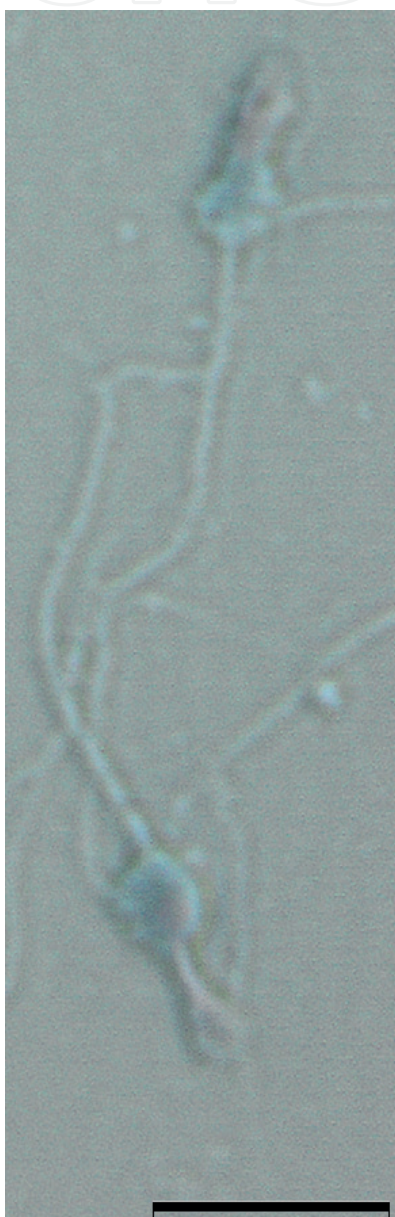


Figure 6. The residual cytoplasm on the spermatozoa tail. Bar = 10 μm .

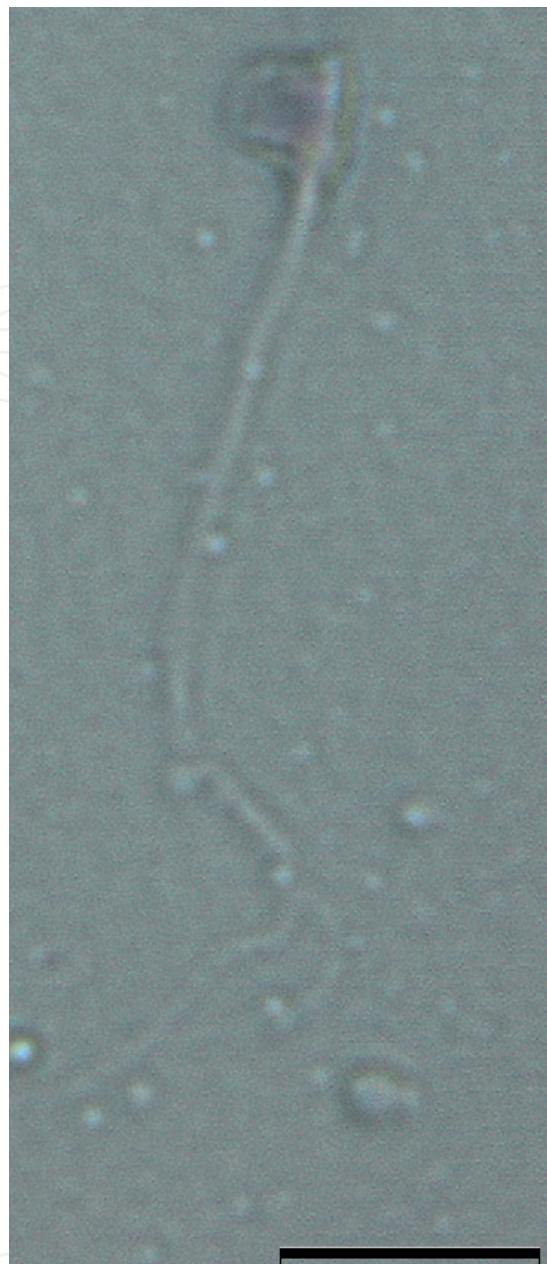


Figure 7. Spermatozoon with multiple abnormalities. Round head, bent neck and duplicate tail. Bar = 10 μ m.

Multiple morphological abnormalities in the same patient's spermatozoa tail structure and ultrastructure which impair motility can show the mutation of some genes (*DNAH1*, *DNAJB13*, *CFAP43* and *CFAP44*) [70–73].

The morphologically abnormal spermatozoon can have multiple defects too (**Figure 7**). The most irregularly shaped, multi-tailed spermatozoa is associated with severe male infertility. The multiple gene mutations, high rates of polyploidy and aneuploidy and reduced motility of spermatozoa have been described in these cases [48, 49].

5. Conclusion

The morphology of spermatozoa has a direct influence on the fertilization and developmental competence of embryos. A normal semen sample must have >30% of morphologically normal spermatozoa. Considering on the morphological study of patients spermatozoa, researchers, practitioners and WHO have defined the prognosis of IVF treatment. Excellent prognosis is expected when >14% of normal spermatozoa were found in the semen sample. When 4–14% of normal spermatozoa were found, the IVF prognosis is good. When prognosis is poor (<4% of normal spermatozoa were found in the semen), the ICSI should be recommended for these patients [3, 18, 74–76].

Therefore the analysis of the morphological parameters of spermatozoa using the light microscopy, MSOME, in combination with precise head birefringence detection using the polarized microscopy, could give the best fertilization rate and embryo quality after IVF and ICSI.

Author details

Kristina Lasiene

Address all correspondence to: kristina.lasiene@lsmuni.lt

Department of Histology and Embryology, Academy of Medicine, Lithuanian University of Health Sciences, Kaunas, Lithuania

References

- [1] Berkovitz A, Eltes F, Yaari S, Katz N, Barr I, Fishman A, Bartoov B. The morphological normalcy of the sperm nucleus and pregnancy rate of intracytoplasmic injection with morphologically selected sperm. *Human Reproduction*. 2005;**20**:185-190. DOI: 10.1093/humrep/deh545
- [2] Rylander L, Wetterstrand B, Haugen TB, Malm G, Malm J, Bjørsvik C, Henrichsen T, Saether T, Giwercman A. Single semen analysis as a predictor of semen quality: Clinical and epidemiological implications. *Asian Journal of Andrology*. 2009;**11**:723-730. DOI: 10.1038/aja.2009.64
- [3] World Health Organization. WHO Laboratory Manual for the Examination and Processing of Human Semen. 5th ed. Cambridge University Press; 2010. 271 p
- [4] World Health Organization. WHO Laboratory Manual for the Examination of Human Semen and Semen-Cervical Mucus Interaction. 4th ed. Cambridge University Press; 1999. 138 p

- [5] van der Horst G, Maree L. SpermBlue: A new universal stain for human and animal sperm which is also amenable to automated sperm morphology analysis. *Biotechnic & Histochemistry* 2009;**84**:299-308. DOI: 10.3109/10520290902984274
- [6] Rapid SpermBlue® Protocol [Internet]. Available from: <http://www.microopticsl.com/products/disposables/morphology/spermblue/>
- [7] Auger J. Assessing human sperm morphology: Top models, underdogs or biometrics? *Asian Journal of Andrology*. 2010;**12**:36-46. DOI: 10.1038/aja.2009.8
- [8] Bellastella G, Cooper TG, Battaglia M, Ströse A, Torres I, Hellenkemper B, Soler C, Sinisi AA. Dimensions of human ejaculated spermatozoa in Papanicolaou-stained seminal and swim-up smears obtained from the Integrated Semen Analysis System (ISAS®). *Asian Journal of Andrology*. 2010;**12**:871-879. DOI: 10.1038/aja.2010.90
- [9] Blanchard M, Haguenoer K, Apert A, Poret H, Barthélémy C, Royère D, Guérif F. Sperm morphology assessment using David's classification: Time to switch to strict criteria? Prospective comparative analysis in a selected IVF population. *International Journal of Andrology*. 2011;**34**:145-152. DOI: 10.1111/j.1365-2605.2010.01066.x
- [10] Butts IA, Ward MA, Litvak MK, Pitcher TE, Alavi SM, Trippel EA, Rideout RM. Automated sperm head morphology analyzer for open-source software. *Theriogenology*. 2011;**76**:1756-1761. DOI: 10.1016/j.theriogenology.2011.06.019
- [11] Soler C, De Monserrat JJ, Gutierrez R, Nunez J, Nunez M, Sancho M, Perez-Sanchez F, Cooper TG. Use of the sperm-class analyser for objective assessment of human sperm morphology. *International Journal of Andrology*. 2003;**26**:262-270. DOI: 10.1046/j.1365-2605.2003.00422.x
- [12] MacLeod J. Human seminal cytology as a sensitive indicator of the germinal epithelium. *International Journal of Fertility*. 1964;**9**:281-295
- [13] Jouannet P, Ducot B, Feneux D, Spira A. Male factors and the likelihood of pregnancy in infertile couples. I. Study of sperm characteristics. *International Journal of Andrology*. 1988;**11**:379-394. DOI: 10.1111/j.1365-2605.1988.tb01011.x
- [14] Auger J, Eustache F, David G. Standardisation de la classification morphologique des spermatozoïdes humains selon la méthode de David modifiée. *Andrologie*. 2000;**10**:358-373. DOI: 10.1007/BF03034491
- [15] Hofmann N, Freundl G, Florack M, Die Formstörungen d. Spermatozoen im sperma und zervikalschleim als spiegel testikularer erkrankungen. *Der Gynäkologe*. 1985;**18**:189-192
- [16] Hofmann N, Hilscher B. Use of aniline blue to assess chromatin condensation in morphologically normal spermatozoa in normal and infertile men. *Human Reproduction*. 1991;**6**:979-982. DOI: 10.1093/oxfordjournals.humrep.a137472
- [17] Kruger TF, Ackerman SB, Simmons KF, Swanson RJ, Brugo SS, Acosta AA. A quick, reliable staining technique for human sperm morphology. *Archives of Andrology*. 1987;**18**:275-277. DOI: 10.3109/01485018708988493

- [18] Menkveld R, Stander FS, Kotze TJ, Kruger TF, Van Zyl JA. The evaluation of morphological characteristics of human spermatozoa according to stricter criteria. *Human Reproduction*. 1990;**5**:586-592. DOI: 10.1093/oxfordjournals.humrep.a137150
- [19] Akl LD, Oliveira JB, Petersen CG, Mauri AL, Silva LF, Massaro FC, Baruffi RL, Cavagna M, Franco JG Jr. Efficacy of the motile sperm organelle morphology examination (MSOME) in predicting pregnancy after intrauterine insemination. *Reproductive Biology and Endocrinology*. 2011;**9**:120. DOI: 10.1186/1477-7827-9-120
- [20] Antinori M, Licata E, Dani G, Cerusico F, Versaci C, d'Angelo D. Intracytoplasmic morphologically selected sperm injection: A prospective randomized trial. *Reproductive Biomedicine Online*. 2008;**16**:835-841. DOI: 10.1016/S1472-6483(10)60150-2
- [21] Nadalini M, Tarozzi N, Distratis V, Scaravelli G, Borini A. Impact of intracytoplasmic morphologically selected sperm injection on assisted reproduction outcome: A review. *Reproductive Biomedicine Online*. 2009;**19**:S45-S55. DOI: 10.1016/S1472-6483(10)60283-0
- [22] Sermondade N, Hafhouf E, Dupont C, Bechoua S, Palacios C, Eustache F, Poncelet C, Benzacken B, Lévy R, Sifer C. Successful childbirth after intracytoplasmic morphologically selected sperm injection without assisted oocyte activation in a patient with globozoospermia. *Human Reproduction*. 2011;**26**:2944-2949. DOI: 10.1093/humrep/der258
- [23] Sermondade N, Sifer C. Motile sperm organelle morphology examination: Toward a consensus? *Gynécologie, Obstétrique & Fertilité*. 2011;**39**:309-314. DOI: 10.1016/j.gyobfe.2011.03.014
- [24] Silva LF, Oliveira JB, Petersen CG, Mauri AL, Massaro FC, Cavagna M, Baruffi RL, Franco JG Jr. The effects of male age on sperm analysis by motile sperm organelle morphology examination (MSOME). *Reproductive Biology and Endocrinology*. 2012;**10**:19. DOI: 10.1186/1477-7827-10-19
- [25] Boitrelle F, Guthauser B, Alter L, Bailly M, Bergere M, Wainer R, Vialard F, Albert M, Selva J. High-magnification selection of spermatozoa prior to oocyte injection: Confirmed and potential indications. *Reproductive Biomedicine Online*. 2014;**28**:6-13. DOI: 10.1016/j.rbmo.2013.09.019
- [26] Ghosh S, Chattopadhyay R, Bose G, Ganesh A, Das S, Chakravarty BN. Selection of birefringent spermatozoa under Polscope: Effect on intracytoplasmic sperm injection outcome. *Andrologia*. 2012;**44**:734-738. DOI: 10.1111/j.1439-0272.2011.01258.x
- [27] Gianaroli L, Magli MC, Collodel G, Moretti E, Ferraretti AP, Baccetti B. Sperm head's birefringence: A new criterion for sperm selection. *Fertility and Sterility*. 2008;**90**:104-112. DOI: 10.1016/j.fertnstert.2007.05.078
- [28] Gianaroli L, Magli MC, Ferraretti AP, Crippa A, Lappi M, Capitani S, Baccetti B. Birefringence characteristics in sperm heads allow for the selection of reacted spermatozoa for intracytoplasmic sperm injection. *Fertility and Sterility*. 2010;**93**:807-813. DOI: 10.1016/j.fertnstert.2008.10.024

- [29] Petersen CG, Vagnini LD, Mauri AL, Massaro FC, Cavagna M, Baruffi RL, Oliveira JB, Franco JG Jr. Relationship between DNA damage and sperm head birefringence. *Reproductive Biomedicine Online*. 2011;**22**:583-589. DOI: 10.1016/j.rbmo.2011.03.017
- [30] Magli MC, Crippa A, Muzii L, Boudjema E, Capoti A, Scaravelli G, Ferraretti AP, Gianaroli L. Head birefringence properties are associated with acrosome reaction, sperm motility and morphology. *Reproductive Biomedicine Online*. 2012;**24**:352-359. DOI: 10.1016/j.rbmo.2011.12.013
- [31] Collodel G, Iacoponi F, Mazzi L, Terzuoli G, Pascarelli NA, Moretti E. Light, polarizing, and transmission electron microscopy: Three methods for the evaluation of sperm quality. *Systems Biology in Reproductive Medicine*. 2013;**59**:27-33. DOI: 10.3109/19396368.2012.724518
- [32] Bartoov B, Berkovitz A, Eltes F, Kogosowski A, Menezo Y, Barak Y. Real-time fine morphology of motile human sperm cells is associated with IVF-ICSI outcome. *Journal of Andrology*. 2002;**23**:1-8. DOI: 10.1002/j.1939-4640.2002.tb02595.x
- [33] Ubaldi F, Rienzi L. Morphological selection of gametes. *Placenta*. 2008;**29**:S115-S120. DOI: 10.1016/j.placenta.2008.08.009
- [34] Oliveira JB, Massaro FC, Mauri AL, Petersen CG, Nicoletti AP, Baruffi RL, Franco JG Jr. Motile sperm organelle morphology examination is stricter than Tygerberg criteria. *Reproductive Biomedicine Online*. 2009;**18**:320-326. DOI: 10.1016/S1472-6483(10)60088-0
- [35] Gergely A, Kovanci E, Senturk L, Cosmi E, Vigue L, Huszar G. Morphometric assessment of mature and diminished-maturity human spermatozoa: Sperm regions that reflect differences in maturity. *Human Reproduction*. 1999;**14**:2007-2014. DOI: 10.1093/humrep/14.8.2007
- [36] Celik-Ozenci C, Catalanotti J, Jakab A, Aksu C, Ward D, Bray-Ward P, Demir R, Huszar G. Human sperm maintain their shape following decondensation and denaturation for fluorescent in situ hybridization: Shape analysis and objective morphometry. *Biology of Reproduction*. 2003;**69**:1347-1355. DOI: 10.1095/biolreprod.103.019596
- [37] Tesarik J, Drahorad J, Peknicova J. Subcellular immunochemical localization of acrosin in human spermatozoa during the acrosome reaction and zona pellucida penetration. *Fertility and Sterility*. 1988;**50**:133-141. DOI: 10.1016/S0015-0282(16)60021-3
- [38] El-Ghobashy AA, West CR. The human sperm head: A key for successful fertilization. *Journal of Andrology*. 2003;**24**:232-238. DOI: 10.1002/j.1939-4640.2003.tb02667.x
- [39] Cui KH. Size differences between human X and Y spermatozoa and prefertilization diagnosis. *Molecular Human Reproduction*. 1997;**3**:61-67. DOI: 10.1093/molehr/3.1.61
- [40] van Munster EB, Stap J, Hoebe RA, te Meerman GJ, Aten JA. Difference in volume of X- and Y-chromosome-bearing bovine sperm heads matches difference in DNA content. *Cytometry*. 1999;**35**:125-128. DOI: 10.1002/(SICI)1097-0320(19990201)35:23.0.CO;2-H
- [41] Henkel R, Schreiber G, Sturmhoefel A, Hipler UC, Zermann DH, Menkveld R. Comparison of three staining methods for the morphological evaluation of human spermatozoa. *Fertility and Sterility*. 2008;**89**:449-455. DOI: 10.1016/j.fertnstert.2007.03.027

- [42] Maree L, du Plessis SS, Menkveld R, van der Horst G. Morphometric dimensions of the human sperm head depend on the staining method used. *Human Reproduction*. 2010;**25**:1369-1382. DOI: 10.1093/humrep/deq075
- [43] Garolla A, Cosci I, Menegazzo M, De Palo R, Ambrosini G, Sartini B, Pizzol D, Foresta C. Sperm selected by both birefringence and motile sperm organelle morphology examination have reduced deoxyribonucleic acid fragmentation. *Fertility and Sterility*. 2014;**101**:647-652. DOI: 10.1016/j.fertnstert.2013.11.029
- [44] Zhu F, Wang F, Yang X, Zhang J, Wu H, Zhang Z, Zhang Z, He X, Zhou P, Wei Z, Gecz J, Cao Y. Biallelic SUN5 mutations cause autosomal-recessive acephalic spermatozoa syndrome. *American Journal of Human Genetics*. 2016;**99**:942-949. DOI: 10.1016/j.ajhg.2016.08.004
- [45] Elkhatib RA, Paci M, Longepied G, Saias-Magnan J, Courbiere B, Guichaoua MR, Levy N, Metzler-Guillemain C, Mitchell MJ. Homozygous deletion of SUN5 in three men with decapitated spermatozoa. *Human Molecular Genetics*. 2017. DOI: 10.1093/hmg/ddx200
- [46] Li L, Sha Y, Wang X, Li P, Wang J, Kee K, Wang B. Whole-exome sequencing identified a homozygous BRDT mutation in a patient with acephalic spermatozoa. *Oncotarget*. 2017;**8**:19914-19922. DOI: 10.18632/oncotarget.15251
- [47] Benzacken B, Gavelle FM, Martin-Pont B, Dupuy O, Lièvre N. Familial sperm polyploidy induced by genetic spermatogenesis failure: Case report. *Human Reproduction*. 2001;**16**:2646-2651. DOI: 10.1093/humrep/16.12.2646
- [48] Guthauser B, Pollet-Villard X, Boitrelle F, Vialard F. Is intracouple assisted reproductive technology an option for men with large-headed spermatozoa? A literature review and a decision guide proposal. *Basic and Clinical Andrology*. 2016;**26**:8. DOI: 10.1186/s12610-016-0035-6
- [49] Dieterich K, Soto Rifo R, Faure AK, Hennebicq S, Ben Amar B, Zahi M. Homozygous mutation of AURKC yields large-headed polyploid spermatozoa and causes male infertility. *Nature Genetics*. 2007;**39**:661-665. DOI: 10.1038/ng2027
- [50] Dieterich K, Zouari R, Harbuz R, Vialard F, Martinez D, Bellayou H, Prisant N, Zoghmar A, Guichaoua MR, Koscinski I, Kharouf M, Noruzinia M, Nadifi S, Sefiani A, Lornage J, Zahi M, Viville S, Sèle B, Jouk PS, Jacob MC, Escalier D, Nikas Y, Hennebicq S, Lunardi J, Ray PF. The Aurora Kinase C c.144delC mutation causes meiosis I arrest in men and is frequent in the North African population. *Human Molecular Genetics*. 2009;**18**:1301-1309. DOI: 10.1093/hmg/ddp029
- [51] Gandini L, Lombardo F, Paoli D, Caponecchia L, Familiari G. Study of apoptotic DNA fragmentation in human spermatozoa. *Human Reproduction*. 2000;**15**:830-839. DOI: 10.1093/humrep/15.4.830
- [52] Menkveld R. Clinical significance of the low normal sperm morphology value as proposed in the fifth edition of the WHO Laboratory Manual for the Examination and Processing of Human Semen. *Asian Journal of Andrology*. 2010;**12**:47-58. DOI: 10.1038/aja.2009.14

- [53] Prisant N, Escalier D, Soufr JC, Morillon M, Schoevaert D. Ultrastructural nuclear defects and increased chromosome aneuploidies in spermatozoa with elongated heads. *Human Reproduction*. 2007;**22**:1052-1059. DOI: 10.1093/humrep/del481
- [54] Dam AH, Ramos L, Dijkman HB, Woestenenk R, Robben H, van den Hoven L, Kremer JA. Morphology of partial Globozoospermia. *Journal of Andrology*. 2011;**32**:199-206. DOI: 10.2164/jandrol.109.009530
- [55] Gatimel N, Léandri RD, Foliguet B, Bujan L, Parinaud J. Sperm cephalic vacuoles: New arguments for their non acrosomal origin in two cases of total globozoospermia. *Andrology*. 2013;**1**:52-56. DOI: 10.1111/j.2047-2927.2012.00011.x
- [56] Perrin A, Coat C, Nguyen MH, Talagas M, Morel F, Amice J, De Braekeleer M. Molecular cytogenetic and genetic aspects of globozoospermia: A review. *Andrologia*. 2013;**45**:1-9. DOI: 10.1111/j.1439-0272.2012.01308.x
- [57] Tang SS, Gao H, Zhao Y, Ma S. Aneuploidy and DNA fragmentation in morphologically abnormal sperm. *International Journal of Andrology*. 2010;**33**:e163-e179. DOI: 10.1111/j.1365-2605.2009.00982.x
- [58] Kaneko S, Yoshida J, Takamatsu K. Low density regions of DNA in human sperm appear as vacuoles after translucent staining with reactive blue 2. *Journal of Medical Diagnostic Methods*. 2013;**2**:145. DOI: 10.4172/2168-9784.1000145
- [59] Berkovitz A, Eltes F, Ellenbogen A, Peer S, Feldberg D, Bartoov B. Does the presence of nuclear vacuoles in human sperm selected for ICSI affect pregnancy outcome? *Human Reproduction*. 2006;**21**:1787-1790. DOI: 10.1093/humrep/del049
- [60] Kacem O, Sifer C, Barraud-Lange V, Ducot B, De Ziegler D, Poirot C, Wolf JP. Sperm nuclear vacuoles, as assessed by motile sperm organellar morphological examination, are mostly of acrosomal origin. *Reproductive BioMedicine Online*. 2010;**20**:132-137. DOI: 10.1016/j.rbmo.2009.10.014
- [61] Perdrix A, Travers A, Clatot F, Sibert L, Mitchell V, Jumeau F, Macé B, Rives N. Modification of chromosomal architecture in human spermatozoa with large vacuoles. *Andrology*. 2013;**1**:57-66. DOI: 10.1111/j.2047-2927.2012.00016.x
- [62] Franco JG Jr, Mauri AL, Petersen CG, Massaro FC, Silva LF, Felipe V, Cavagna M, Pontes A, Baruffi RL, Oliveira JB, Vagnini LD. Large nuclear vacuoles are indicative of abnormal chromatin packaging in human spermatozoa. *International Journal of Andrology*. 2012;**35**:46-51. DOI: 10.1111/j.1365-2605.2011.01154.x
- [63] Tanaka A, Nagayoshi M, Tanaka I, Kusunoki H. Human sperm head vacuoles are physiological structures formed during the sperm development and maturation process. *Fertility and Sterility*. 2012;**98**:315-320. DOI: 10.1016/j.fertnstert.2012.04.034
- [64] Moretti E, Pascarelli NA, Federico MG, Renieri T, Collodel G. Abnormal elongation of midpiece, absence of axoneme and outer dense fibers at principal piece level, supernumerary microtubules: A sperm defect of possible genetic origin? *Fertility and Sterility*. 2008;**90**:1201.e3-e8. DOI: 10.1016/j.fertnstert.2007. 11.050

- [65] Mitchell V, Sigala J, Ballot C, Jumeau F, Barbotin AL, Duhamel A, Rives N, Rigot JM, Escalier D, Peers MC. Light microscopy morphological characteristics of the sperm flagellum may be related to axonemal abnormalities. *Andrologia*. 2015;**47**:214-220. DOI: 10.1111/and.12249
- [66] Pelfrey RJ, Overstreet JW, Lewis EL. Abnormalities of sperm morphology in cases of persistent infertility after vasectomy reversal. *Fertility and Sterility*. 1982;**38**:112-114. DOI: 10.1016/S0015-0282(16)46407-1
- [67] Yeung CH, Tüttelmann F, Bergmann M, Nordhoff V, Vorona E, Cooper TG. Coiled sperm from infertile patients: Characteristics, associated factors and biological implication. *Human Reproduction*. 2009;**24**:1288-1295. DOI: 10.1093/humrep/dep017
- [68] Rengan AK, Agarwal A, van der Linde M, du Plessis SS. An investigation of excess residual cytoplasm in human spermatozoa and its distinction from the cytoplasmic droplet. *Reproductive Biology and Endocrinology*. 2012;**10**:92. DOI: 10.1186/1477-7827-10-92
- [69] Cooper TG, Yeung CH, Fetic S, Sobhani A, Nieschlag E. Cytoplasmic droplets are normal structures of human sperm but are not well preserved by routine procedures for assessing sperm morphology. *Human Reproduction*. 2004;**19**:2283-2288. DOI: 10.1093/humrep/deh410
- [70] Amiri-Yekta A, Coutton C, Kherraf ZE, Karaouzène T, Le Tanno P, Sanati MH, Sabbaghian M, Almadani N, Sadighi Gilani MA, Hosseini SH, Bahrami S, Daneshpour A, Bini M, Arnoult C, Colombo R, Gourabi H, Ray PF. Whole-exome sequencing of familial cases of multiple morphological abnormalities of the sperm flagella (MMAF) reveals new DNAH1 mutations. *Human Reproduction*. 2016;**31**:2872-2880. DOI: 10.1093/humrep/dew262
- [71] El Khouri E, Thomas L, Jeanson L, Bequignon E, Vallette B, Duquesnoy P, Montantin G, Copin B, Dastot-Le Moal F, Blanchon S, Papon JF, Lorès P, Yuan L, Collot N, Tissier S, Faucon C, Gacon G, Patrat C, Wolf JP, Dulioust E, Crestani B, Escudier E, Coste A, Legendre M, Touré A, Amselem S. Mutations in DNAJB13, encoding an HSP40 family member, cause primary Ciliary dyskinesia and male infertility. *American Journal of Human Genetics*. 2016;**99**:489-500. DOI: 10.1016/j.ajhg.2016.06.022
- [72] Tang S, Wang X, Li W, Yang X, Li Z, Liu W, Li C, Zhu Z, Wang L, Wang J, Zhang L, Sun X, Zhi E, Wang H, Li H, Jin L, Luo Y, Wang J, Yang S, Zhang F. Biallelic Mutations in CFAP43 and CFAP44 Cause Male Infertility with Multiple Morphological Abnormalities of the Sperm Flagella. *American Journal of Human Genetics*. 2017;**100**:854-864. DOI: 10.1016/j.ajhg.2017.04.012
- [73] Wang X, Jin H, Han F, Cui Y, Chen J, Yang C, Zhu P, Wang W, Jiao G, Wang W, Hao C, Gao Z. Homozygous DNAH1 frameshift mutation causes multiple morphological anomalies of the sperm flagella in Chinese. *Clinical Genetics*. 2017;**91**:313-321. DOI: 10.1111/cge.12857
- [74] Kruger TF, Menkveld R, Stander FS, Lombard CJ, Van der Merwe JP, van Zyl JA, Smith K. Sperm morphologic features as a prognostic factor in *in vitro* fertilization. *Fertility and Sterility*. 1986;**46**:1118-1123. DOI: 10.1016/S0015-0282(16)49891-2

- [75] Kruger TF, Acosta AA, Simmons KF, Swanson RJ, Matta JF, Oehninger S. Predictive value of abnormal sperm morphology in *in vitro* fertilization. *Fertility and Sterility*. 1988;**49**:112-117. DOI: 10.1016/S0015-0282(16)59660-5
- [76] Grow DR, Oehninger S, Seltman HJ, Toner JP, Swanson RJ, Kruger TF, Muasher SJ. Sperm morphology as diagnosed by strict criteria: Probing the impact of teratozoospermia on fertilization rate and pregnancy outcome in a large *in vitro* fertilization population. *Fertility and Sterility*. 1994;**62**:559-567. DOI: 10.1016/S0015-0282(16)56946-5

IntechOpen

