

We are IntechOpen, the world's leading publisher of Open Access books Built by scientists, for scientists

5,300

Open access books available

130,000

International authors and editors

155M

Downloads

Our authors are among the

154

Countries delivered to

TOP 1%

most cited scientists

12.2%

Contributors from top 500 universities



WEB OF SCIENCE™

Selection of our books indexed in the Book Citation Index
in Web of Science™ Core Collection (BKCI)

Interested in publishing with us?
Contact book.department@intechopen.com

Numbers displayed above are based on latest data collected.
For more information visit www.intechopen.com



Interstitial Pneumonia Associated with Connective Tissue Disease: A Comprehensive Overview and an Insight into the Pathogenesis

Akira Takeda and Yoshiki Ishii

Additional information is available at the end of the chapter

<http://dx.doi.org/10.5772/intechopen.70864>

Abstract

Interstitial pneumonia (IP) refers to involvement of the lung parenchyma by varying degrees of inflammation and fibrosis, in contrast to airspace disease typically seen in bacterial pneumonia. IP lies in the center of a heterogenous group of diffuse interstitial lung diseases (ILDs), either idiopathic or linked to underlying disorders. One of the major categories of disorders frequently associated with IP is a connective tissue disease (CTD), in which autoimmune-mediated tissue injury leads to multiple organ impairment. Today, IP represents the most critical pulmonary complication in CTD, resulting in significant morbidity and mortality. Despite growing understanding of the pathology of IPs, as well as the accumulating knowledge from both basic and clinical studies of CTDs, the pathogenesis of CTD-associated IP remains unclear. This chapter will provide an overview of the general understanding of ILD and illustrate the current state of knowledge on IP associated with CTD, in order to fully comprehend the entirety of its complex pictures. Moreover, we will propose a new insight into the immune pathogenesis of CTD-IP by presenting evidence which robustly indicates that T cells trigger initial development of IP in polymyositis/dermatomyositis, suggesting potential approaches for controlling such particular T cells in therapeutic interventions for IP.

Keywords: interstitial pneumonia, interstitial lung disease, connective tissue disease, polymyositis/dermatomyositis, T lymphocyte, T cell receptor, antigen-driven mechanisms

1. Introduction

The term “Interstitial pneumonia” (IP) is used to describe noninfectious, inflammatory lung disorders characterized by the histologic abnormalities with diffuse interstitial fibrosis involving alveolar walls. In contrast to airspace disease typically seen in bacterial pneumonia, IP

refers to involvement of the lung parenchyma by varying combination of fibrosis and inflammation [1, 2]. IP is included in the “interstitial lung disease” (ILD), i.e., a heterogeneous group of diffuse parenchymal lung disorders, either idiopathic or associated with injurious or inflammatory causes, in which the major site of damage is the lung interstitium [3]. Customarily, the designations IP and ILD are sometimes used interchangeably. To be accurate, however, ILD comprises a broader range of lung diseases which involves the pulmonary interstitium, including drug-induced pneumonitis and eosinophilic pneumonia, etc. Primarily, IP refers to the particular disease entities which belong to idiopathic interstitial pneumonia (IIP) defined by the 2002 and 2012 American Thoracic Society/European Respiratory Society (ATS/ERS) classification [1–4]. IIP was categorized into several forms of IPs, afterward each histopathologic pattern of which has been applied to the ILD associated with underlying diseases as well; the details of these will be described later.

From the pathophysiological perspective, the pulmonary interstitium consists of area with minimal connective tissue matrix between the capillaries and the alveolar space that allows close apposition of gas and blood flow leading to efficient gas exchange. If any injury from a specific exposure of chemicals or proteins, an autoimmune-mediated inflammation, or unknown etiology occurs and persists, the lung may respond to the damage by repairing process with increased interstitial tissue resulting in histological remodeling. Thus, ILDs may cause serious pulmonary dysfunction, which is often associated with substantial morbidity and poor prognosis.

ILD comprises a variety of disorders with diverse backgrounds. A part of ILD has no identifiable underlying cause and is regarded as idiopathic, whereas it is often associated with a specific environmental exposure or with underlying diseases such as connective tissue disease (CTD) [1]. The CTDs are a group of systemic, inflammatory, autoimmune disorder, in which autoimmune-mediated tissue injury leads to multiple organ impairment including respiratory system. Today, IP or ILD is one of the most serious pulmonary complications associated with CTDs, resulting in significant morbidity and mortality [5]. Despite growing, understanding of the details of pathology in IPs, as well as accumulating evidences which support an association between IP with CTD and the presence of autoantibodies, the pathogenesis of CTD-associated IP remains unclear.

During the last years, we have been exploring the possible involvement of adaptive immunity in the pathogenesis of IP associated with CTDs, and we found intriguing evidence which strongly suggests a pivotal role of T cells in triggering the development of pulmonary alveolitis through antigen-driven immune responses in early stage IP [6, 7]. In this chapter, first, we will overview the current concepts of ILD as well as CTD-associated IP, in order to comprehend the whole picture including pathological features. Then, novel findings demonstrated in our recent studies of IP associated with polymyositis/dermatomyositis will be discussed.

2. Understanding of interstitial lung disease

2.1. The concept of interstitial lung disease

ILD, also known as diffuse parenchymal lung disease (DPLD), is a generic term encompassing a broad spectrum of heterogeneous lung disorders, either idiopathic or associated with injurious

or inflammatory causes, in which the major site of damage is the lung interstitium [1–3]. Because of the nature of DPLD which involves the interstitium, the ILDs share common radiologic, pathologic, and clinical manifestations. Clinically, exertional dyspnea and nonproductive cough are most common manifestations. Bilateral inspiratory fine crackles, most prominent at the lung bases, are usually audible on auscultation. Clubbed fingers characterized by hypertrophy and enlargement of the distal phalanges of the hands are often seen and reported in 30–50% of patients with IPF (idiopathic pulmonary fibrosis; to be mentioned later) [8]. Clinical features suggestive of rheumatic disorders, such as arthralgia, Raynaud's phenomenon, and skin manifestations, might be observed in the setting of an underlying CTD. The plain chest radiograph shows reduced lung volumes with bilateral reticular or reticulonodular opacities. High-resolution computed tomography (HRCT), which offers better definition of the characteristic details of lung parenchyma, can reveal usually bilateral, peripheral, and basilar predominant abnormalities with reticulonodular infiltrates, often with honeycombing and cystic changes by IP type to be described later. Although chest radiography is less useful than HRCT in the detailed evaluation, it is helpful for evaluating disease distribution and its serial change during patient follow up [8]. Physiologically, the patients demonstrate diminished diffusion capacity (decreased DLco) with usually restrictive impairment in pulmonary function tests.

2.2. Classification of interstitial lung disease

Figure 1 provides an overview of the classification of ILD, based on the 2002 and 2012 the American Thoracic Society/European Respiratory Society (ATS/ERS) classification statements [1–3]. Briefly, ILDs consist of disorders of known causes (underlying diseases, environmental, or drug related) as well as disorders of unknown causes. The latter include idiopathic interstitial pneumonias (IIPs), granulomatous lung disorders (e.g., sarcoidosis), and other forms of orphan ILD, i.e., lymphangioleiomyomatosis (LAM), pulmonary Langerhans cell histiocytosis/histiocytosis X (PLCH), and eosinophilic pneumonia. Thus, the ILDs comprise a variety of disorders with diverse backgrounds. Whereas a part of ILD has no identifiable underlying cause, often, it is associated with a specific environmental exposure or with underlying CTD [5]. ILDs are classified according to specific clinical, radiological, and histopathological features. The ILDs, however, frequently have similar clinical features. As ILDs are often uneasy to distinguish each other, the updated guidelines in the 2013 ATS/ERS classification statement underlined the importance of multidisciplinary diagnosis (MDD) facilitated by professional experts [2, 3]. Adequate presentation and discussion of clinical and radiological data are essential for an accurate MDD. Among diagnostic modalities, high-resolution computed tomography (HRCT) makes it possible to characterize ILD with great precision. Surgical lung biopsy also remains the gold standard for evaluation of ILD.

2.3. Classification of idiopathic interstitial pneumonia

As noted above, if ILD is found to have no association with specific causes, such as chemical exposure, underlying systemic diseases, or genetic causes, the disease is classified as “idiopathic interstitial pneumonia” (IIP). IIPs are a heterogenous group of nonneoplastic disorders involving damage to the lung parenchyma with varying patterns of inflammation and fibrosis. The interstitium includes the space between epithelial and endothelial basement membranes and is the primary site of injury in IIPs. Frequently affecting not only the interstitium, but IIPs

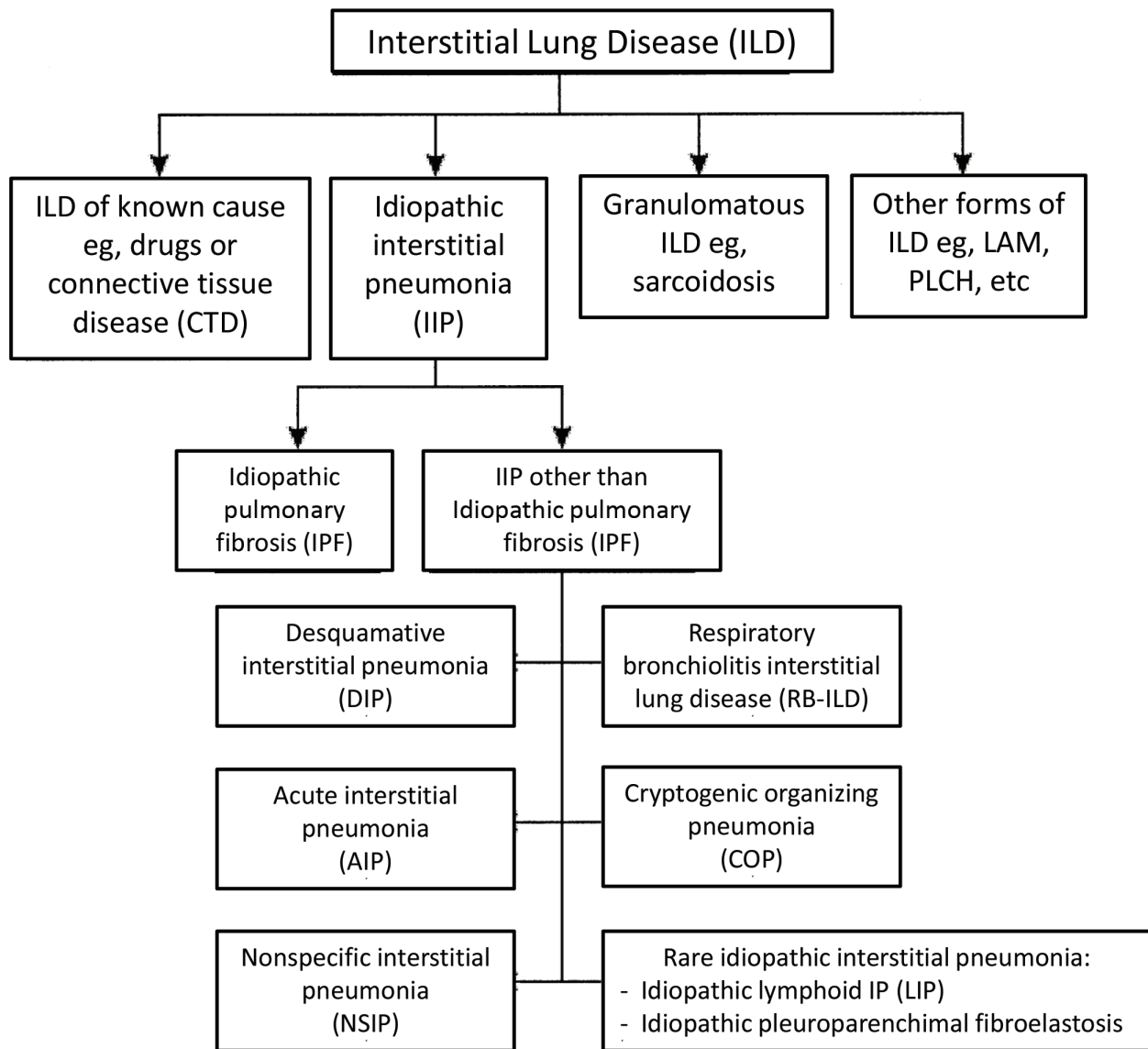


Figure 1. Classification of interstitial lung disease. Interstitial lung diseases (ILDs), also termed as diffuse parenchymal lung diseases (DPLDs), consist of disorders of known causes (connective tissue diseases, environmental, or drug related) as well as disorders of unknown cause. The latter include idiopathic interstitial pneumonias (IIPs), granulomatous lung disorders (e.g., sarcoidosis), and other forms of interstitial lung disease (ILD) including lymphangioleiomyomatosis (LAM), pulmonary Langerhans cell histiocytosis/histiocytosis X (PLCH), and eosinophilic pneumonia. The idiopathic interstitial pneumonias (IIPs) are further categorized as idiopathic pulmonary fibrosis (IPF), nonspecific interstitial pneumonia (NSIP), cryptogenic organizing pneumonia (COP), acute interstitial pneumonia (AIP), respiratory bronchiolitis interstitial lung disease (RB-ILD), or desquamative interstitial pneumonia (DIP). Lymphoid interstitial pneumonia (LIP) is occasionally associated with other disease processes, such as connective tissue diseases or immunosuppression while idiopathic LIP is rare.

may also involve the airspace, peripheral airways, and vessels, along with their respective epithelial and endothelial linings [1, 2].

As shown in **Figure 1**, the IIPs are further categorized into “idiopathic pulmonary fibrosis” (IPF), “nonspecific interstitial pneumonia” (NSIP: further subdivided into cellular and fibrotic NSIP), “cryptogenic organizing pneumonia” (COP), “acute interstitial pneumonia” (AIP), “respiratory

bronchiolitis interstitial lung disease” (RB-ILD), or “desquamative interstitial pneumonia” (DIP) [1, 2]. “Lymphoid interstitial pneumonia” (LIP) is occasionally associated with other processes, such as connective tissue diseases or immunosuppression, while idiopathic LIP is rare. Among the IIPs, idiopathic pulmonary fibrosis (IPF) is the most common prototypic IIP. “Usual interstitial pneumonia” (UIP) is the pathologic pattern of lung injury seen in IPF. Categorization of major IIP and corresponding histological patterns defining each entity are shown in **Table 1** [2].

2.3.1. The importance of HRCT findings in the classification and diagnosis of interstitial lung disease

The ATS/ERS/JRS/ALAT 2011 guidelines for IPF have assigned a primary diagnostic role to HRCT, and the HRCT criteria outlined was the same as those in the revised guideline published in 2015 [8–10]. The diagnosis of IPF should be based on the exclusion of other known causes of ILDs (environmental exposures, drugs, and CTDs) and presence of UIP on HRCT; UIP is characterized on HRCT by the presence of reticular abnormalities with subpleural and basal distribution, honeycombing with or without traction bronchiectasis, and absence of features inconsistent with UIP such as extensive ground-glass opacities, diffuse mosaic attenuation, profuse micronodules, and consolidations. Certain HRCT features predict histopathologic patterns of the different forms of ILD. **Table 2** outlines the classification of histological and corresponding radiological patterns defining each entity of IIP, which is also applicable to CTD-associated ILD, to be explained later [5, 11].

Category	Clinical–radiologic–pathologic diagnoses	Associated radiologic and/or pathologic morphologic patterns
Chronic fibrosing IP	Idiopathic pulmonary fibrosis (IPF)	Usual interstitial pneumonia (UIP)
	Idiopathic nonspecific interstitial pneumonia (NSIP)	Nonspecific interstitial pneumonia (NSIP)
Smoking-related IP*	Respiratory bronchiolitis-interstitial lung disease (RB-ILD)	Respiratory bronchiolitis-ILD (RB-ILD)
	Desquamative interstitial pneumonia (DIP)	Desquamative interstitial pneumonia (DIP)
Acute/subacute IP	Cryptogenic organizing pneumonia (COP)	Organizing pneumonia (OP)
	Acute interstitial pneumonia (AIP)	Diffuse alveolar damage (DAD)

Definition of abbreviation: IP = interstitial pneumonia.
 *Desquamative interstitial pneumonia can occasionally occur in nonsmokers.
 Adapted from Travis et al. [2].

Table 1. Categorization of major IIP.

3. Clinical landscape of interstitial lung disease in connective tissue disease

The connective tissue disease (CTD) is a systemic, inflammatory, autoimmune disorder characterized by immune-mediated multiple organ dysfunction. The category of CTD includes a

variety of diseases: rheumatoid arthritis (RA), systemic lupus erythematosus (SLE), systemic sclerosis (Scleroderma, SSc), polymyositis/dermatomyositis (PM/DM), and a group of vasculitides. The CTD-related disorders such as Sjögren's syndrome (SS), mixed connective tissue disease (MCTD), etc., are also captured under the extended umbrella of CTD, as they share similar features. Involvement of the respiratory system occurs in those diseases and may be often major contributor to significant morbidity and mortality [5]. The clinical presentation is variable, ranging from cough, dyspnea, pleuritic pain to abnormal diffuse lung shadows on chest X-ray, in addition to clinical features suggestive of rheumatic disorders, i.e., arthralgia, Raynaud's phenomenon, and skin rashes. Some patients may have presentations dominated by pulmonary manifestations over those of autoimmune disease. Thus, it is crucial for physicians to carefully evaluate the evidence of underlying CTDs in all patients who present with ILD.

3.1. Prevalence of ILD

ILD, especially IP, is one of the most common and clinically important complications of the various CTDs and the CTD-related disorders of which the most often implicated disorders

Pattern	Histology	CT features
UIP	Subpleural and peripheral fibrosis. Temporal and spatial heterogeneity. Scattered <i>fibroblastic foci</i> and honeycombing are key features	Basal, subpleural reticulation and honeycombing; traction bronchiectasis; little, if any, ground-glass attenuation
NSIP	Uniform interstitial involvement by variable degrees of degrees of fibrosis and inflammation. Honeycombing is rare	Bilateral patchy ground-glass opacities admixed with reticulation and traction bronchiectasis/bronchiolectasis. Little or no honeycombing. Usually, predominantly basal
OP	Connective tissue plugs within small airways and air spaces (Masson bodies). In its "pure" form, little or no inflammation or fibrosis in the surrounding interstitium	Airspace consolidation, with a predominantly basal/peripheral or peribronchovascular distribution. Bands with air bronchograms and a perilobular pattern can also be seen
DIP	Extensive macrophage accumulation within the distal air spaces. Mild interstitial involvement	Patchy ground-glass opacities. Microcystic change can be seen within the ground-glass, Basal, peripheral distribution frequent
LIP	Bronchiolocentric lymphoid tissue hyperplasia	Ground-glass attenuation is the predominant finding, with thin-walled cysts frequently present. Lung nodules and septal thickening may also be seen
RB-ILD	Bronchiolocentric macrophage accumulation. Mild bronchiolar fibrosis	Centrilobular nodules, ground glass opacities. Diffuse or upper lung distribution
DAD	In the acute phase: hyaline membrane, edema. In the organizing phase: airspace and interstitial organization	Acute phase: diffuse ground-glass opacities and consolidation in dependent areas. Organizing phase: reticular pattern, traction bronchiectasis and architectural distortion

Abbreviation: DIP, desquamative interstitial pneumonia; NSIP, non-specific interstitial pneumonia; UIP, usual interstitial pneumonia; OP, organizing pneumonia; DAD, diffuse alveolar damage; RB-ILD, respiratory bronchiolitis interstitial lung disease; LIP, lymphocytic interstitial pneumonia.

Adapted from de Lauretis et al. [11].

Table 2. Classification of histological and radiological patterns for IP.

are SSc, RA, PM/DM, Sjögren’s syndrome (SS), mixed connective tissue disease (MCTD), and SLE, according to prevalence [12, 13]. The frequency of ILD in CTDs is presented in **Table 3** [12]. Essentially, as every component of the lungs is a potential target for CTDs, there is a wide variety of pulmonary manifestations associated with the diseases [13].

3.2. Multidisciplinary diagnostic approach

Though the prevalence of ILD in CTDs varies based on patient selection and methods used for detection, the percentage appears to be higher than previously regarded. ILD may precede the extrapulmonary manifestations of CTD as a *forme fruste* of systemic disease, in some patients by years, while the rheumatic symptoms predate ILD in others [14–16]. Sometimes, it makes the distinction between idiopathic pulmonary fibrosis (IPF) and CTD-related ILD difficult [11, 16]. Despite similarities in clinical and pathologic presentation, the prognosis and treatment of CTD-associated ILD can differ greatly from that of other forms of ILD such as IPF [13, 16, 17]. Therefore, early detection of pulmonary involvement and early accurate diagnosis of CTDs are both important for initiating appropriate intervention. The multidisciplinary diagnostic team (MDD team), including a pulmonologist, a pathologist, and a rheumatologist, can contribute to it; a report indicates that 50% of patients referred with an initial concern for IPF had their diagnosis changed to a CTD-ILD after combined evaluation by the specialists [12].

The evaluation of ILD in patients with CTD is complex due to the heterogeneity of CTDs, the varied types and severity of ILD, and also the fact that ILD may be identified at any point in time in these patients. Fischer, et al. emphasize the importance of cross-disciplinary collaboration and thorough evaluations, which are needed either when CTD patients develop ILD or when encountering ILD patients with possible occult CTD [18]. The detection of occult CTD in patients with “idiopathic” ILD requires careful attention to historical clues, subtle physical examination findings, and autoantibody profiles, as well as radiologic and histopathological features. Such evaluation can be optimized by a multidisciplinary approach in collaboration with specialists including radiologists, pathologists, and rheumatologists. The standard clinical approach for evaluating patients with ILD for CTDs is well summarized by Vij R and Strek ME in their review [5].

Connective tissue disease	Frequency of ILD	Patterns
Systemic sclerosis	45% (clinically significant)	NSIP 80–90%, UIP 10–20%, OP, DAD
Rheumatoid arthritis	5–58%	UIP 50–60%, NSIP 30–60%, OP, LIP, DAD, DIP
Polymyositis/dermatomyositis	30–70%	NSIP, OP, UIP, DAD
Sjögren’s syndrome	Up to 25%	NSIP, OP, UIP, LIP
Systemic lupus erythematosus	2–8%	NSIP, OP, UIP, DAD
Mixed connective tissue disease	20–60%	NSIP, OP, UIP, DAD

Modified from Castelino et al. [12].

Table 3. Features of ILD associated with CTD.

3.3. Laboratory tests and biomarkers

Since the spectrum of ILD associated with CTD is broad, careful evaluation for autoantibodies or other serologic tests in conjunction with clinical features of autoimmune disease is crucial [19, 20]. Because of the variable incidence and outcome of ILD in CTD, biomarkers including autoantibodies are critical for diagnosis, prognosis, patient subtyping, and predicting response to treatment. Major autoantibodies and serologic tests commonly available for the evaluation of CTD-ILDs include antinuclear antibody (ANA), anti-double-stranded DNA, anti-ribonucleoprotein (anti-RNP) antibody, anti-Smith (anti-Sm) antibody, anti-scleroderma-70 (Scl-70) antibody, anti-Ro (SS A), anti-La (SS B), anti-Jo-1 antibody, rheumatoid factor (RF), and anti-cyclic citrullinated peptide antibody (ACPA) [5].

Some of the established biomarkers include lung epithelium-specific proteins [20]. Evidence indicates that repetitive injuries to alveolar epithelial cells (AEC) and airway Club cells trigger an exaggerated wound healing response. During the process, while AEC type I cells undergo apoptosis, regenerated hyperplastic AEC type II cells produce a vast array of cytokines, growth factors, and release surfactant proteins and mucins [21]. Surfactant proteins (SP-A and SP-D) and KL-6 in the serum are useful biomarkers, which have been well established for various ILDs. SP-D and SP-A, secreted by AEC II and airway Club cells, are surfactant lipoproteins and phospholipids which stabilize alveolar surface tension, playing an important role in the lung host defense system [22]. SP-D serum levels are more sensitive than SP-A in detecting ILD as defined by CT but less specific [23]. KL-6 is a high-molecular-weight mucin-like glycoprotein, now classified as MUC1, which is highly expressed by AEC II and bronchiolar epithelial cells and increases following cellular injury and/or regeneration [24]. KL-6 has profibrotic and antiapoptotic effects on lung fibroblasts [25]. Serum KL-6 has been shown to be elevated not only in IIP but also in CTD-ILD, as well as hypersensitivity pneumonitis, drug-induced pneumonitis, etc. [24, 26].

There are a number of principal autoantibodies which have been validated for the clinical use. Antinuclear antibody (ANA) determined by an immunofluorescence assay is most versatile, presenting with several major patterns; mainly homogeneous (associated with ANAs against double strand (ds) DNA in SLE and histones), speckled/peripheral (less specific), and nuclear (most often associated with limited scleroderma). ANA titer higher than 1–160 is regarded as significant in most laboratories [27]. When using enzyme immunoassay (EIA) and enzyme-linked immunosorbent assay (ELISA) for ANAs, we can detect single autoantigens such as dsDNA, Smith antigen, scleroderma (Scl-70) (also termed topoisomerase-1), SSA/Ro, SSB/La, etc. [27]. Some of the recent, newly developed autoantibodies with distinct clinical and immunological characteristics will be explained later.

3.4. Undifferentiated connective tissue disease (UCTD) and interstitial pneumonia with autoimmune features (IPAF)

Besides classical, well-established CTDs, increasing attention has been paid to pulmonary involvement in undifferentiated CTD (UCTD) [15, 17, 28–30]. UCTD has been generally defined as a condition that presents with signs and symptoms suggestive of CTDs along with

positive ANA but does not fulfill any rheumatology classification criteria for specific CTDs [30, 31]. Mosca et al. reported that 60% of patients with UCTD remain undifferentiated. When evolution to defined CTD occurs, it usually does within the first 5 years of disease. UCTD may develop into any of the CTDs, most often into SLE [29]. There are a large number of patients, in whom the IP appears to be the lone part for the clinically predominant manifestation of an occult CTD with subtle clinical features that suggest an autoimmune process but not meet established criteria for CTD, raising a controversy over the strategies for identification and classification of these patients. Well-organized prospective studies have been needed to better understand this entity of the lung disease and distinguish it from the ILD with well-defined CTD or IIP. Proposed terminology to classify such patients includes “undifferentiated CTD” [31], “lung-dominant CTD” [15], and “autoimmune-featured ILD” [32]. Recently, the “ATS/ERS Task Force on Undifferentiated Forms of CTD-associated ILD” created consensus regarding the nomenclature and classification criteria for patients with IIP and features of autoimmunity and proposed the term “interstitial pneumonia with autoimmune features” (IPAF). The classification criteria require evidence of IP and are organized around three central domains: a clinical domain consisting of specific extra-thoracic features, a serologic domain consisting of specific autoantibodies, and a morphologic domain consisting of specific chest imaging, histopathologic, or pulmonary physiologic features [33]. Currently, it is not yet clear whether IPAF is a distinct phenotype of ILD or simply a part of IIP. Adopting IPAF classification may provide platform for the future study of a more uniform cohort, and prospective survey will be needed in determining efficacy of therapy and outcomes for the patients [34].

4. Pulmonary histopathology in connective tissue disease

The underlying pathology in CTD-associated ILD can be dominated by inflammation or fibrosis or by a combination of both with distinct radiologic and histopathologic patterns [12]. Classification of histological and radiological patterns developed for IIPs is applied to CTD-ILD [1, 5, 11]. The radiological and corresponding histological patterns defining each entity of CTD-associated IP are summarized in **Table 2** [11]. Although there is substantial histological overlap among the pulmonary manifestations of different CTDs and with other etiologies, certain histologic patterns may favor one CTD over another, and occasionally distinctive histologic clues may be present [35, 36]. It is possible in many cases to confirm CTD-ILD and guide patient management using histologic features. Pulmonary histopathology is thus helpful, and surgical lung biopsy remains the gold standard for evaluation of CTD-associated ILD [35]. ILD can present acutely or chronically, with acute presentations being more common in SLE and PM/DM. Histological patterns of CTD-associated IP include, most frequently, nonspecific interstitial pneumonia (NSIP), usual interstitial pneumonia (UIP), organizing pneumonia (OP), diffuse alveolar damage (DAD), and lymphocytic interstitial pneumonia (LIP). By contrast, desquamative interstitial pneumonia (DIP) and respiratory bronchiolitis-associated interstitial pneumonia (RB-ILD) are uncommon forms of IP in CTD. Both, typically affecting cigarette smokers, share overlapping clinicopathological features and have a relatively better prognosis than UIP.

4.1. Nonspecific interstitial pneumonia (NSIP)

In the history of classification, the recognition that the cases of ILD exist from which lung biopsy samples do not fit into any well-defined histologic patterns of idiopathic IP led to proposals of the terms “unclassified interstitial pneumonia” by Kitaichi in 1990 [37] and “nonspecific interstitial pneumonia/fibrosis (NSIP)” by Katzenstein and Fiorelli in 1994 [38]. This novel concept has helped to identify a group of ILDs with a more favorable prognosis and which needs to be distinguished from IPF/UIP, while also having different characteristics from DIP, AIP, and COP [1]. Katzenstein, in her large study of 64 such cases, utilized the descriptive term “nonspecific interstitial pneumonia/fibrosis (NSIP),” which was characterized by varying proportions of interstitial inflammation and fibrosis that appeared to be occurring over a single time span (i.e., a temporally uniform process). NSIP may have varying etiologies, including underlying CTD as well as organic dust or other exposures [38]. Subsequent intensive studies in collaboration with pathologists and radiologists have endorsed its differentiation from other types of IP, gaining the term NSIP, a broad acceptance [39, 40]. NSIP pattern of lung injury, itself further subdivided into cellular and fibrotic NSIP, is the most common pattern of IP in all CTDs except for RA, in which UIP pattern pathology may be more common [41, 42]. NSIP lung injury is characterized by diffuse, although often variable, alveolar septal thickening due to collagen deposition. The amount of associated interstitial inflammation varies, but in most cases, it consists of mild patchy lymphoplasmacytic infiltrate. Although NSIP is not a pattern specific to CTD-IP, there are several histologic clues which support CTD, and when found, make the diagnosis of CTD-IP more likely [35].

- Involvement of multiple lung components: concurrent involvement of alveolar septal interstitium, airways, vessels, and pleura is an important clue to the diagnosis of CTD-IP and can be helpful in differentiation of it from IPF.
- Interstitial fibrosis with overlapping NSIP and UIP: a histologic overlap of UIP and NSIP patterns is frequently shown in CTD, although similar findings may be seen in some variants of chronic hypersensitivity pneumonia, etc.
- Lymphoid aggregates: formation of prominent lymphoid aggregates, often with germinal centers, is a characteristic feature of CTD-IP, classically seen in RA and Sjögren’s syndrome.

4.2. Usual interstitial pneumonia (UIP)

UIP is the prototype of histopathology which characterizes IPF, a chronic form of idiopathic interstitial lung disease [1, 2]. UIP pattern is often encountered in CTD-IP, with more prevalence in advanced cases. This pattern is classically identified by its patchy nature (spatial heterogeneity) and chronic active appearance (temporal heterogeneity). Fibrosis is accentuated in the subpleural regions with microscopic honeycombing observed as irregular airspaces surrounded by dense fibrosis. Fibroblast foci (regions of new fibrosis) are found at the interface between central and peripheral regions [35]. While primary UIP pattern is found in 13–56% of RA-ILD cases, some studies have reported that the most frequent histologic pattern of ILD among RA patients is NSIP, followed closely by UIP, accounting for 30–67% and 13–57% of RA-ILD, respectively [36]. Studies of PM/DM-ILD identified an UIP pattern in 5–33% of cases.

In SSc-ILD, UIP pattern was found in 15% in one study and 26% in another. UIP pattern has also been reported in 17% of Sjögren's syndrome cases in a study. Whereas idiopathic pulmonary fibrosis (IPF) is a progressively deteriorating ILD, in which the characteristic histological pattern of IPF is UIP; interestingly, a UIP pattern is associated with a significantly better survival in CTD compared to the IPF [43]. Histologically, CTD-associated UIP biopsies had fewer fibroblastic foci, smaller honeycombing spaces, higher numbers of germinal centers, and higher inflammation scores than IPF/UIP biopsies [44].

4.3. Diffuse alveolar damage (DAD)

Since 1935, when Louis Hamman and Arnold Rich described four patients with acute respiratory failure of unknown etiology, the existence of cases which manifest acute respiratory failure with bilateral lung infiltrates has been recognized [45]. All four patients died and were revealed at autopsy to have a distinctive pathology that in modern times is recognized as the organizing stage of diffuse alveolar damage (DAD). This acute idiopathic respiratory condition was subsequently given the eponym Hamman-Rich syndrome. Although the histology of DAD was described even earlier, the term of "diffuse alveolar damage" (DAD) was presented by Katzenstein, et al. in their comprehensive review with their own data [46]. They concluded that endothelial and alveolar cell injury leads to fluid and cellular exudation, with hyaline membranes and edema being well-known features.

The term "acute interstitial pneumonia" (AIP) was introduced in 1986 by Katzenstein et al. for cases identical to the Hamman-Rich syndrome to lay emphasis on the fact that the condition is an acute form of idiopathic interstitial lung disease, clinically and histologically distinct from chronic forms, the prototype of which is IPF [47]. The prognosis of AIP is dismal and the mortality high. Today, AIP is defined by the following key elements: acute onset of respiratory symptoms typically resulting in acute respiratory failure; bilateral lung infiltrates on radiographs; the absence of identifiable etiology; and histological documentation of DAD [1, 47, 48]. Whereas the term AIP is applied when DAD is of unknown etiology, similar injury due to a known cause is generally referred to as DAD (stating the cause or the underlying disease).

DAD is thus a histologic pattern of injury usually associated with a life-threatening acute or subacute presentation which often correlates with the clinical entity of acute respiratory distress syndrome (ARDS) [49]. In earliest phase, the histology of DAD comprises alveolar septal edema and fibrin deposition in airspace. Over hours to days, these changes are accompanied by fibroplasia in alveolar septa, accumulation of alveolar macrophages (including foam cells), and formation of hyaline membranes [50]. Organizing thrombi are often found in small to medium-sized arteries. Within days to weeks after injury, airspace plugs of organizing pneumonia and type II pneumocytes hyperplasia on alveolar surfaces become prominent, representing a histologic pattern described as "organizing DAD."

Besides AIP, infection is the most important etiology to exclude in patients in whom a diagnosis of AIP is clinically considered. Infectious etiology includes fungi, pneumocystis organisms, and viruses such as cytomegalovirus (CMV), etc. Despite prominent neutrophilia observed in bronchoalveolar lavage (BAL) fluid samples, there is usually a paucity of inflammatory cells on histologic sections in case of AIP. If prominent acute inflammation is seen, particularly in

the airspaces, it raises suspicion of infection. Other clues to specific etiologies include viral cytopathic changes observed in some viral pneumonias (e.g., cytomegalovirus, respiratory syncytial virus, adenovirus); food or other foreign material (with or without giant cell reaction) suggesting aspiration; and prominent eosinophilia suggesting a primary eosinophilic disorder such as eosinophilic granulomatosis with polyangiitis (EGPA/Churg–Strauss syndrome) or acute eosinophilic pneumonia [35].

CTDs are another major group of diseases that may manifest pathologically as DAD. To identify CTD as an etiology of DAD in patients, exclusion of other possible cause must be established. Of note, DAD usually occurs in patients with established CTD-ILD but also can occasionally be the presenting manifestation of the disease [51]. In CTD patients who initially present with DAD, rheumatologic manifestations and serological tests should help to establish the correct diagnosis. In patients with CTD on immunosuppressive therapy, infectious etiology and drug toxicity should be considered as a potential cause of DAD. In SLE, cases of diffuse alveolar hemorrhage commonly show histological features of DAD [52]. In PM/DM, an older case series found DAD pattern in 4 of 15 cases (27%); a more recent series identified DAD in 2 of 70 cases (3%), possibly reflecting improvements in diagnosis and treatment of this disease [53, 54]. A study suggests that DAD is more common in DM-ILD than in PM-ILD [55]. In RA, one study reported primary DAD pattern found in 2 of 33 cases (6%) [56]. In a more recent study of CTD-associated DAD, RA accounted for five of nine cases; in four cases, DAD occurred in patients with established, pre-existing RA-ILD, whereas one manifested as a *de novo* presentation [51].

4.4. Organizing pneumonia (OP)

While OP is characterized by fibrosis and chronic inflammation like IP, it differs in that the reaction affects predominantly the airspaces rather than the interstitium; this disorder is not an interstitial process [57]. However, many include OP in the classification of IP [40]. OP is histologically characterized by consolidation of airspaces by rounded branching polypoid plugs of granulation tissue [35]. This airspace organization is usually found in the alveoli as well as terminal airways. Pure involvement of airways is rare, and thus, it should raise suspicion of a primary small airway disease. Alveolar macrophages with foamy cytoplasm are often found; however, this nonspecific finding may also be observed in cases of aspiration or drug toxicity. Usually, there are not abundant neutrophils in the histology of OP. If prominent inflammation, particularly involving the airspaces, is found, it should raise suspicion of infection as a cause. Also, when eosinophils are prominent in the airspace, suspicion of a primary eosinophilic disorder, e.g., EGPA/Churg–Strauss syndrome, eosinophilic pneumonia, etc., or a drug adverse reaction must be raised. Overall, a predominant OP pattern, if encountered, accounts for a broad range of differential diagnosis to be considered, which include CTD, infectious pneumonia (particularly viral or atypical bacterial), aspiration, and drug toxicity. Thus, after all diagnostic exclusion is made, cryptogenic organizing pneumonia (COP) is determined as the diagnosis.

In many cases of CTD, the associated ILD may demonstrate focal lesions of OP pattern superimposed on a background of the other patterns of IP, frequently seen in NSIP. Therefore, true OP is less common in CTD-ILD. Among the RA-ILD, one study reported a primary OP pattern in 2 of 18 cases of RA-ILD (11%), and another stated 6 of 40 cases (15%) [42, 56]. Of

note, OP can occasionally be the inaugural manifestation of RA [58]. In PM/DM-ILD, OP is common; OP as the primary pattern was present in 6 of 15 cases (40%) in one series, 5 of 13 (38%) in another [53, 59]. In a study of cases with Sjögren's syndrome reported, OP was found in 4 of 18 biopsies (22%) in the series [51]. By contrast, OP is a very rare manifestation in SSc; detected only in 1 of 80 cases in a large series [60].

4.5. Lymphocytic interstitial pneumonia (LIP)

The term "lymphocytic interstitial pneumonia" (LIP) refers to a pattern of IP in cases with diffuse and marked thickening of alveolar septal interstitium predominantly by dense lymphocytic infiltrate [61]. The infiltrate is polyclonal and may be admixed with variable numbers of plasma cells and macrophages. Germinal centers are frequently present. Histologically, LIP overlaps with follicular bronchiolitis and nodular lymphoid hyperplasia. When present, LIP pattern may raise concern for a possible lymphoproliferative process, which should be ruled out using appropriate immunohistochemical studies and flow cytometric analyses [35]. It should be noted that LIP has been associated with some viral infections, particularly human immunodeficiency virus. Classically, LIP was well-recognized in Sjögren's-associated ILD, where it was initially reported in at least 25% of cases based on a series of 12 biopsies [62]. A more recent study identified LIP primary pattern in 3 of 18 cases of Sjögren's-ILD (17%) [51].

5. Characteristic of interstitial lung disease in major connective tissue disease

5.1. Interstitial lung disease in systemic sclerosis

SSc is recognized as the CTD with the highest prevalence of ILD, ranging from 40 to 80%, depending on the modalities used for ascertainment [63]. The frequency of ILD varies according to patient selection, subsets of skin disease extent and ethnicity. In a large autopsy study, ILD was the most common pulmonary lesion in SSc, being found in >70% of the cases, and arteriolar thickening, described as medial hypertrophy or concentric intimal proliferation, was the most specific lesion in the lungs suggestive of pulmonary hypertension, being noted in 29% of the patients [64]. SSc, classically "scleroderma," is defined by the presence of major criteria; i.e., skin thickening proximal to metacarpo-phalangeal joints and minor criteria; i.e., sclerodactyly, esophageal involvement, and lung fibrosis [65]. It is subdivided into a limited cutaneous form, including CREST (Calcinosis, Raynaud's syndrome, Esophageal dysmotility, Sclerodactyly, Telangiectasia) syndrome and a diffuse cutaneous form (diffuse SSc has skin sclerosis proximal to elbows and knees), with varying degrees of skin, esophageal, lung, cardiac, and vascular involvement. Both forms can be progressive in nature.

As mentioned above, pulmonary manifestations in SSc include ILD and vascular disorder manifesting as pulmonary arterial hypertension (PAH). Today, both pulmonary complications are the leading cause of morbidity and mortality in patients with SSc. In line with SSc as the vasculature disorder, ranging from Raynaud's phenomenon to PAH and renal crisis,

nailfold capillary microscopy is now a well-established measure to evaluate capillary damage or abnormality [66]. The capillary changes observed in digits can be a predictor of severe vascular complications, being helpful in recognizing early disease [67].

In the context of autoantibodies, anti-nuclear antibodies (ANA) are found in the majority of SSc patients although not in every case. In 2013, the novel classification criteria of American College of Rheumatology (ACR)/European League against Rheumatism (EULAR) collaborative initiative for SSc incorporated three major autoantibodies [68]. These antibodies with high specificity for SSc are against topoisomerase (ATA or anti Scl-70), anticentromere antibodies (ACA), and anti-RNA polymerase III (ARA). They are closely related to distinct disease patterns; anti-topoisomerase antibodies are strongly associated with ILD, whereas anticentromere antibodies are highly predictive of the absence of significant lung fibrosis but associated with development of pulmonary hypertension [69]. Anticentromere antibodies, which are frequently found among Caucasians (20–35%), are strongly indicative of a limited form disease referred as CREST syndrome [69]. The other major autoantibody, anti-RNA polymerase III, is linked to diffuse skin disease and renal crisis, with less significant lung fibrosis. This antibody has another aspect that may herald paraneoplastic SSc [70]. While almost all patients with anti-topoisomerase antibodies have some extent of ILD, more than half of the SSc patients with ILD are negative for this antibody.

The most common pattern of ILD in SSc is fibrotic NSIP which manifests as dense, paucicellular interstitial fibrosis that maintains the underlying architecture [60, 71, 72]. As the lung disease progresses, the areas of fibrosis may become confluent and appear as honeycomb. SSc patients may also present with typical UIP pattern with temporal and spatial heterogeneity, in contrast to the diffuse and uniform fibrosis of NSIP. In most SSc patients, ILD remains stable without treatment despite having some degree of lung fibrosis. However, some proportions of the SSc patients develop significant and progressive ILD. In SSc-associated ILD, placebo-controlled randomized trials, named the Scleroderma Lung Study (SLS) and the fibrosing alveolitis scleroderma trial (FAST), have been performed, suggesting certain effectiveness of immunosuppressive therapy in preventing further decline in patients with progressive ILD to be mentioned later [73, 74].

5.2. Interstitial lung disease in rheumatoid arthritis

RA is the most common CTD, occurring in 1–2% of the population, more frequently in women. Although RA is primarily characterized by synovial inflammation which leads an erosive inflammatory polyarthropathy, predominantly affecting the distal joints, extra-articular manifestations are seen in approximately half of patients with RA. Extra-articular manifestations include subcutaneous nodules, skin ulceration, scleritis/episcleritis, pericarditis, splenomegaly, and a variety of pleuro-pulmonary abnormalities.

Lung disease accounts for 10–20% of mortality in RA, second only to cardiac disease [75–77]. Airway, pleural, vascular, and parenchymal involvement can occur in RA patients, as well as pulmonary disorders indirectly associated with RA such as opportunistic infections and drug-induced lung disease. All pleuro-pulmonary manifestations in RA are more common in males;

ILD affects men twice as commonly as women. The prevalence of ILD ranges widely from 5 to 58% in various reports [78–80]. It is difficult to confirm the exact prevalence because it depends on modalities of ascertainment and patient selection such as autopsy, hospital, and community-based studies. In a study of 36 patients with new onset RA, abnormalities consistent with ILD were found in 58% of patients; physiology 22%, chest X ray 6%, HRCT 33%, BAL 52%, and 99mTc-DTPA radionuclide scan 15% [81]. Smoking is a significant risk factor for ILD; an odds ratio of 3.8 for ILD was observed in RA patients with a smoking history >25 pack years [82].

In the context of histological patterns, the predominant ILD histology in RA patients is NSIP (cellular or, more commonly, fibrotic NSIP), followed closely by UIP, accounting for 30–67% and 13–57% of RA-associated ILD, respectively [42, 44, 59, 83–85]. Some studies have noted greater incidence of UIP histology in RA-ILD found in up to 56% of patients in a series [42]. These NSIP and UIP patterns are followed by organizing pneumonia (OP). There is evidence suggesting that a UIP pattern may be associated with a worse survival than fibrotic NSIP in cases of RA, in contrast with the other CTDs. A pattern of DAD/acute interstitial pneumonia (AIP) is infrequent but may occur as fulminant ILD manifestation of RA, which can develop in a previously normal lung or as the presenting pattern of a previously undiagnosed ILD. The characteristic CT pattern of DAD includes widespread ground glass with/without areas of dependent consolidation, although a similar pattern could represent opportunistic or viral infection and acute heart failure.

5.3. Interstitial lung disease in polymyositis/dermatomyositis

Idiopathic inflammatory myopathy (IIM), a group of systemic autoimmune disorders that affect skeletal muscles and other organs, comprises three major categories: polymyositis (PM), dermatomyositis (DM), and inclusion body myositis (IBM). PM and DM are sometimes recognized together as they share similar clinical signs and symptoms with exception of cutaneous manifestations such as “heliotrope rash” on the upper eyelids, “mechanic’s hands” on the fingers, and “Gottron papules” on the dorsal surface of the hands seen in DM. Pathologically, however, these are distinct entities; PM is T cell-mediated diseases, where CD8-positive cytotoxic T cells invade muscle fibers expressing MHC class I antigens, whereas DM is characterized by a complement-mediated microangiopathy [86–88].

The diagnosis of PM/DM is made on the basis of clinical features and examinations, which include symmetrical proximal muscle weakness, elevated serum muscle enzymes, characteristic electromyographic alterations, muscle biopsy histopathology consistent with myositis, and for DM, typical cutaneous manifestations mentioned above and less-specific skin rashes. Moreover, muscle magnetic resonance imaging (MRI) and ultrasound (US) have been also introduced in the diagnostic work up of patients with inflammatory myopathies. Classification criteria for PM/DM date back to initial publications by Medsger et al. [89]. Since, in 1975, Bohan and Peter classified myositis, their criteria have been widely used [90, 91]. However, it demonstrated poor specificity and cannot distinguish PM from IBM or some forms of dystrophies for instance. Thus, several diagnostic criteria for inflammatory myopathies have been proposed with little acceptance, including recent muscle-biopsy-based diagnostic criteria [92]. Further prospective studies are required to develop improved and universal classification criteria.

Several neuromuscular diseases which may mimic PM/DM and should be considered in the differential diagnosis include drug or toxic myopathies (alcohol, colchicine, statins, etc.), endocrine myopathies (hyper-hypothyroidism), metabolic myopathies, mitochondrial myopathies, muscular dystrophies, infectious myositis, neuropathies, paraneoplastic syndromes, other connective tissue disorders, amyloidosis, and sarcoidosis [93]. Muscular dystrophies, where an increase of creatine kinase (CK), electrodiagnostic, and bioptic abnormalities similar to PM/DM may be present, can be distinguished from DM/PM by the positive family history, the relatively early insidious onset, and slow progression. Iatrogenic myopathy is secondary to corticosteroids use, where CK is normal and the histological examination shows atrophic changes of muscle fibers. Other diseases to consider in the differential diagnosis are endocrine or dysionemia-induced myopathies. Rheumatic polymyalgia (polymyalgia rheumatica) is characterized by normal CK and histological absence of inflammatory abnormalities. Infectious myositis especially viral and parasitic myositis are characterized by a diffuse muscular involvement and a subacute or chronic course. Bacterial myositis is localized and acute. Among other rare inflammatory myopathies, nodular focal myositis is considered as a variant of PM/DM and may present at onset (As localized, a differential diagnosis with muscular cancers and/or thrombophlebitis must be considered). Eosinophilic myositis, characterized by muscle eosinophil infiltrate, may be part of a hypereosinophilic syndrome (pneumonia, endocardial and myocardial fibrosis, and peripheral neuropathy, etc.) or be associated with eosinophilic fasciitis. Granulomatous myositis can be isolated or in the context of granulomatous syndromes, such as sarcoidosis or Crohn's disease; the main histological finding is the presence of granulomatous lesions which may contain epithelioid cells, histiocyte, and Langerhans giant cells. In the differential diagnoses of IBM, polyneuropathy and amyotrophic lateral sclerosis have also to be considered [93, 94].

Concerning extra-muscular involvement, respiratory disease is a major cause of morbidity and mortality in PM/DM [53, 95–100]. PM/DM-associated pulmonary disorders may manifest as ILD and as a consequence of respiratory muscle weakness leading to hypoventilation or aspiration pneumonia. ILD is the most common extra-muscular complication in PM/DM and have been recognized in 30–70% of the patients [100–102]. The reported prevalence varies depending on the modalities or tests for detection and patient selections. Since Tazelaar et al. reported a histopathological study of lung biopsy specimens in patients with PM/DM in terms of treatment responses and survivals, histopathology fairly serves relevant clinical decisions [53]. As for the prevalence of the different histopathologic patterns, NSIP is by far the most frequent finding, followed by DAD, UIP, and OP [54, 103–107]. Our study with HRCT scans of 14 cases of histologically proven NSIP associated with PM/DM showed that the predominant features were of reticular and/or ground-glass opacities with or without consolidation. Reticular and ground-glass opacities predominated in the lower zone of each lung, and consolidation predominated at the lung periphery [108].

In the context of subtypes of PM/DM, the following concepts of amyopathic dermatomyositis and anti-synthetase syndrome warrant particular attentions.

5.4. Amyopathic dermatomyositis

Clinically amyopathic dermatomyositis (CADM), which is characterized by the cutaneous findings of DM with no muscle involvement or only minimal weakness, affects approximately 20% of patients with DM [109, 110]. Patients with CADM have a greater risk of developing ILD, especially prone to rapidly progressive lung disease corresponding to DAD [111, 112]. Anti-melanoma differentiation-associated gene 5 (MDA5) antibodies (also referred to as anti-CADM-140 antibodies) were identified in the serum from patients with CADM by firstly immunoprecipitation assays [113]. The presence of anti-MDA5 antibodies is strongly associated with DM, especially with CADM, and rapidly progressive ILD, which are thus associated with particularly poor clinical outcomes.

5.5. Anti-synthetase syndrome (ASS)

A subset of patients may manifest a clinical syndrome known as “anti-synthetase syndrome (ASS),” which is characterized by the presence of one of the anti-aminoacyl-t-RNA synthetase (ARS) antibodies such as anti-Jo-1, anti-PL-7, anti-PL-12, anti-EJ, anti-OJ, and anti-KS, together with stigmata of PM/DM including myositis, ILD, polyarthritis, fever, Raynaud’s phenomenon, and mechanic’s hand [114, 115]. Anti-Jo-1, the first anti-ARS antibody, is the best understood of the anti-synthetase antibodies, with a strong correlation with ILD in patients with PM/DM; the incidence of ILD approaches 90% [116, 117].

5.6. Myositis-specific autoantibodies and myositis-associated autoantibodies

Circulating autoantibodies directed against nuclear or cellular components are frequently detected in patients with PM or DM. These antibodies are categorized into two groups; one is specific to PM/DM, whereas the other is found in overlap syndrome with myositis. Targoff et al. designated these two categories of autoantibodies as “myositis-specific antibodies; MSAs” and “myositis-associated antibodies; MAAs,” respectively [114]. Classical autoantibodies such as anti-aminoacyl transfer RNA synthetases (ARS) antibodies, anti-signal recognition particle (SRP) antibodies [118, 119], and Mi-2 antibodies are classified as MSAs, where especially anti-Mi-2 antibodies are DM specific [120]. Later, the new DM specific antibodies have been disclosed. These include the antibodies directed against melanoma differentiation-associated gene5 (MDA5) (anti-CADM-140 antibody, mentioned above) [113, 121, 122], transcriptional intermediary factor-1-gamma (anti-p155 antibody) [123, 124], NXP-2 (anti-NMP-2 antibody) [125, 126], and small ubiquitin-like modifier activating enzyme (anti-SAE antibody) [127]. Usually, MSAs are distinct, and their presence is mutually exclusive.

Because of their strong associations with a pattern of clinical features, such as myopathy, skin lesions, and ILD, these novel autoantibodies are useful biomarkers for classifying disease subgroups, predicting future organ involvement, and forecasting the prognosis of patients with PM/DM [114, 128–131]. The autoantibodies are detectable in PM/DM; both MSA and MAA are listed and summarized in **Table 4** [102]. The pathogenetic mechanisms of expression of such autoantibodies are still awaited to be illuminated.

Autoantibodies	Antibody target	Frequency in polymyositis/ADM/JDM %	Frequency of ILD in adult /juvenile myositis %	Clinical spectrum	
				In adulthood	In childhood
Myositis- specific autoantibodies (MSA)					
<i>Anti-t-RNA synthetase</i>		29/20/5			
Anti-Jo1 (PL1)	Histidyl-ARS	21/11/<3	66/63	Arthralgia, fever, RP, mechanic's hand, puffy finger	Arthralgia, fever, RP, mechanic's hand, sclerodactyly
Anti- PL7	Threonyl-ARS	5/2/<1	84/63		
Anti- PL12	Alanyl-ARS	2/3/<1			
Anti-KS	Asparaginy-ARS	<1			
Anti-OJ	Isoleucyl-ARS	<1			
Anti-EJ	Glycyl-ARS	<1			
Anti-SC	Lysyl-ARS	<1			
Anti-JS	Glutaminy-ARS	<1			
Anti-YRS(Ha)	Tyrosyl-ARS	<1	<1		
Anti-Zo	Phenylalanyl-ARS	<1			
Dermatomyositis Specific autoantibodies					
Anti-Mi2	Nucleosome remodeling deacetylase complex	1/9/4-10	4/0	Classical DM without extramuscular involvement	Mild or moderate JDM
Anti-NXP2(MJ,p140)	Nuclear matrix protein 2	10/0-3/12-25	0/25	DM without extramuscular involvement, calcinosis	Mild or moderate JDM
Anti-MDA5(CADM-140)	Melanoma differentiation-associated gene encoding RNA helicase	<1/14-46/7	Europe:60; Asia:90/ Europe:19; Asia:53	Amyopathic DM, severe cutaneous ulcers, rapidly progressive ILD	Severe cutaneous ulcers, RP-ILP, mediastinal emphysema
Anti-TIF1 γ (p1555/140)	Transcriptional intermediary factor 1 γ	<1/10-30/14-29	<10/3	Cancer associated DM in 78% of cases	Mild or moderate JDM

Autoantibodies	Antibody target	Frequency in polymyositis/ADM/JDM %	Frequency of ILD in adult /juvenile myositis %	Clinical spectrum	
				In adulthood	In childhood
Other MSA					
Anti-SRP	Signal recognition particle	5/1/<3	15/0	Necrotising myopathy	Severe JPM
Anti-HMGR(200-100)	3-hydroxy-3-methylglu taryl-coenzyme A reductase	10/<1/unknown	Unknown	Necrotising myopathy	Unknown
Anti-SAE	Small ubiquitin-like modifier activating enzymes	<1/5-10/1-9		DM	Unknown
Myositis associated autoantibodies					
Anti-RO/SSA	RNP complexes with small cytoplasmic RNAs(hy-RNA)	12/13/0			
Anti-U1RNP	70 KDa,A and C polypeptides of U1 snRNP	5/6/6	7	DM, fever, RP, sclerodactyly	
Anti-PM/Scl(75 and 100 Kda)	PM/Scl complex encompassing C1D,PM-SCI-100 and PM-SCI-75 proteins of the human exosome	6/9/4	38	Fever, RP, sclerodactyly	
Anti-Ku	80 and 70 KDa DNA binding dimeric protein	2/1/0	27	Fever, RP, sclerodactyly	

ADM: adult dermatomyositis; JDM: juvenile dermatomyositis; ILD: interstitial lung disease; SRP: signal recognition particle; ARS: aminoacyl-t-RNA synthetase; RP: Raynaud's phenomenon; DM: dermatomyositis specific rash; RP-ILP: rapidly progressive ILD; JPM: juvenile poly myositis
 Adapted from Lega et al. [120].

Table 4. Autoantibodies in polymyositis/dermatomyositis.

6. Pathogenesis of interstitial pneumonia associated with connective tissue disease

6.1. Classic mechanisms in the pathogenesis of interstitial pneumonia in connective tissue disease

Numbers of studies on the pathogenesis of IP have been performed in SSc as well as in mouse models of IP, providing evidence for plausible mechanisms that may lead to pulmonary fibrosis in CTD. This is natural because, among the whole CTDs, SSc has the highest prevalence of IP, and currently, the lung disease consists the major cause of death in patients with SSc, being shifted away from mortality due to renal crisis which was more common in the past. The high morbidity and mortality due to IP in SSc have been eliciting not only multidisciplinary clinical studies but also basic researches. Many lines of evidence acquired from the studies on SSc, and relevant researches on fibrosis have been implying the following potential scenario of classic mechanisms in the pathogenesis of CTD-IP [12, 132, 133].

6.1.1. Mediators eliciting and perpetuating interstitial pneumonia in systemic sclerosis

The key mechanisms in CTD-IP involve an interplay between various cell types and humoral factors; the pathogenesis is initiated by microvascular injury, leading to endothelial cell damage and alveolar epithelial injury [12, 132, 133]. This is followed by activation of the coagulation cascade, release of various cytokines, e.g., IL-1, IL-4, IL-6, IL-13, chemokines, and lysophosphatidic acid (LPA), and growth factors including transforming growth factor beta (TGF- β), connective tissue growth factor (CTGF), and insulin-like growth factor (IGF-1), which leads to activation of fibroblasts, resulting in the development of fibrosis [12, 132, 134]. Many epithelial-derived factors influence the behavior of fibroblasts, with soluble mediators known to exhibit profibrotic activities [134]. The pivotal mediator of fibrosis is the multifunctional cytokine, TGF- β , which, along with platelet-derived growth factor, endothelin-1 (ET-1), plays a major role in the pathogenesis of SSc. There is evidence that epithelial-to-mesenchymal transdifferentiation (EMT) occurs in lung fibrosis, and this process is mediated by TGF- β and potentially ET-1 [135, 136]. TGF- β responses are mediated by canonical Smad signaling [137]. Binding of TGF- β to its receptor elicits signaling through phosphorylation and nuclear translocation of cytoplasmic Smad protein, triggering transcription of genes such as type I collagen, fibronectin, α -smooth muscle actin, and CTGF, which promote fibrogenesis [138]. ET-1 is a potent vasoconstrictor produced by endothelial cells, epithelial cells, and mesenchymal cells. ET-1 binds to ET-1A and ET-1B receptors, recruits fibroblasts, stimulates extracellular matrix production, and also stimulates TGF- β production in lung fibroblasts [139]. Elevated levels of ET-1 have been found in the blood vessels, lung, kidneys, and skin of SSc patients [140]. LPA is produced by activated platelets and fibroblasts. The LPA receptor is expressed in fibroblasts, endothelial cells, and epithelial cells. Both are involved in the development of lung fibrosis in mouse model of IPF, suggesting LPA mediates fibroblast recruitment [141]. IGFs have been implicated in pulmonary fibrosis because increased levels of IGF-1 are detected in the serum as well as in the BAL of SSc patients [142]. CTGF, also

known as CCN2, which plays a pivotal role in the stimulation of extracellular matrix production and myofibroblast differentiation, is involved in angiogenesis and forming the connective tissue [143]. The levels are elevated in the skin and lungs from SSc patients as well as in the sera [144].

The earliest events of the parenchymal lung involvement in CTD include inflammation and associated alveolar epithelial injury which occurs due to undetermined causes or can be caused by some environmental pathogens. The alveolar epithelial damage and inflammation let resident fibroblasts of pulmonary interstitium to locate to the alveolar wall, and the fibroblasts become activated through a variety of mediators such as TGF- β [145, 146]. The activation of resident fibroblasts was shown to be induced by the recruitment of active TGF- β from the lung tissue [147]. The resident lung fibroblasts play a pivotal role in lung fibrosis, and they are considered to be a more primitive or less differentiated lineage of fibroblasts that are prepared for repair at injury response [148]. The recruitment of activated fibroblasts and myofibroblasts that produce large amount of extracellular matrix proteins occurs in the process. These population of cells are not only derived from resident interstitial fibroblasts but also come from circulating progenitor cells which include mesenchymal stem cells recruited from the bone marrow and cells of a monocyte lineage that localize to the lung [149]. Myofibroblasts persist as critical profibrotic cells in affected lung tissue. It is conceivable that minor injury and subsequent disease process lead to the development of a lung microenvironment prone to fibrosis. That series of events results in an accumulation of constituents of the extracellular matrix (ECM), which remodels normal tissue architecture, which in turn culminates in pulmonary organ failure. Essentially, the lung is primed to develop fibrosis in response to injury, and it is likely that the intrinsic response is more severe in CTDs than normal individuals. Thus, in SSc, such genetic or intrinsic differences can be reflected to the serological phenotypes such as the expression of autoantibodies. Patients with SSc having anti-topoisomerase antibodies are liable to develop significant lung fibrosis, while those with anti-RNA polymerase III antibodies are less [150].

6.1.2. Involvement of immune mechanisms in interstitial pneumonia in systemic sclerosis

The immune system is also implicated in the pathology of SSc. Several lines of evidence suggest that a specific population of activated T cells exhibiting type 2 helper T (Th2) phenotype potentially mediates tissue fibrosis, secreting IL-4 and IL-13 both of which activate fibroblasts and collagen production by inducing TGF- β [151]. In SSc, T cells with memory phenotype were found in lung biopsy specimens from patients with lung involvement [152]. In some studies reported, increased numbers of lung memory CD8 T cells are associated with more severe pulmonary fibrosis [153–155]. Luzina et al. have shown an increase in CD8 T cells in the lungs of SSc patients by using T cells isolated from BAL fluid and demonstrated that a subset of patients at higher risk of progressive lung disease had activated, long-lived CD8 T cells which could promote fibrosis through production of profibrotic factors such as IL-4 and oncostatin M, as well as activation of TGF- β [156]. Regulatory T cells (Tregs) which maintain self tolerance can be impaired in their ability to suppress CD 4 effector T cells [157]. Currently, the precise knowledge of the role of effector cells in innate and adaptive immune system in

SSc-associated IP is rather insufficient. More fundamental investigations in this aspect are needed to address to many queries as to the whole scenario of the development of IP in CTDs.

Besides, as concerns idiopathic pulmonary fibrosis (IPF), the latest evidence of immune mechanisms in IPF was reviewed in the recent literature, which includes involvement of both innate immunity and adaptive immunity at several levels of the processes toward development of fibrinogenesis in the human lung of IPF or in its model mice, as summarized in **Table 5** [158]. Briefly, in adaptive immune system, the role of T cells seems complex and subset dependent; Th2 and Th17 cells were shown to promote pulmonary fibrosis, although Th1, Th22, and $\gamma\delta$ -T cells have been found to attenuate fibrotic disease. Treg and Th9 subsets have been proposed to exert both anti- and profibrotic effects. In innate immunity, M2 macrophages and neutrophils have been suggested to enhance pulmonary fibrosis, whereas M1 macrophages were assigned a protective role, but contradictory findings have also been described [158].

After all, a variety of studies on the pathogenesis of IPF have been conducted, and many experimental models were generated to explore the mechanisms. However, it is yet highly questionable whether the evidence provided from the studies of IPF is applicable to the etiology of CTD-associated IP. Furthermore, it is still unclear whether the animal models such as the mouse bleomycin model can truly replicate the autoimmune progressive forms of the ILDs seen in human CTDs.

6.2. A new insight into the pathogenesis of interstitial pneumonia in connective tissue disease: “T cells trigger interstitial pneumonia in polymyositis/dermatomyositis”

We have speculated that exploring the early immune phases of IP in the lung would be the most direct approach to understand the pathogenesis before more complex secondary immune responses occur in the evolution of IP [6, 7]. PM/DM is one of the major CTD, of which the most critical problem is pulmonary involvement. As mentioned before, ILD, mainly IP, often severe and progressive, has been recognized in 30–70% of PM/DM patients and is frequently associated with a dismal prognosis. While the presence of myositis-specific autoantibodies, such as Jo-1 and activated T cell muscle infiltrates, suggests autoimmune mechanisms in the etiology of PM, the pathogenesis of the associated IP remains undefined. We encountered two cases of early-stage PM-associated IP, of which we had an opportunity of investigating the fresh lung tissues obtained by video-assisted thoracoscopic (VATS) biopsy performed for the sake of histopathological diagnosis toward treatment options. Since this is the clear and robust demonstration of the pivotal role of T cells in CTD-IP, we herein present the details of our study with two cases of early-stage PM-associated IP both suggesting that T cells contribute to the early phase of the development of IP. Lung tissue was utilized with the approval of the institutional review board.

6.2.1. Analysis in cases of interstitial pneumonia associated with polymyositis/dermatomyositis

Patient A was a 51-year-old woman with no tobacco history and no family history of lung diseases, referred to our clinic for evaluation of arthralgia and myalgia. At 49 years, the patient

Cells and mediators	Description
Immune cells	
T cells	Th1 cytokines (IFN- γ and IL-12) attenuate PF, Th2 cytokines (IL-4, IL-5 and IL-13) enhance PF, Th17 cells enhance PF, Tregs and Th9 (IL-9) have both pro- and antifibrotic roles in PF; Th22 (IL-22) and $\gamma\delta$ -T cells have an antifibrotic role in PF.
Macrophages	M1 macrophages induce myofibroblast apoptosis and digest ECM by activation of MMPs. M2 macrophages recruit and activate fibroblast through TGF- β 1 and PDGF secretion. M2 macrophages further produce TIMPs and inhibit degradation of ECM. Both Macrophages phenotypes (M1/M2) can exert pro- and antifibrotic effects.
Neutrophils	Neutrophils produce elastase, MMPs, and TIMPs. Neutrophil elastase activates TGF- β and recruits inflammatory cells to the lung, thereby promoting PF.
Fibrocytes	Fibrocytes produce ECM, cross-linking enzymes, chemokines, growth factors, and MMPs, and promote PF. Fibrocytes secrete paracrine mediators, which activate resident fibroblasts to promote PF. Fibroblasts can differentiate into fibroblasts and myofibroblasts.
Cytokines	
IL-1 β	Profibrotic effects of IL-1 β , mediated through IL-1R/MyD88 signaling pathway.
IL-13	IL-13 differentiates human lung fibroblast to myofibroblast through a JNK-dependent pathway.
IL-17	IL-17 interacts/cooperates with TGF- β signaling to promote PF.
TGF- β 1	TGF- β promote EMT through SMAD-2/3 signaling pathways. TGF- β 1 induces PF through ERK, MAPK, PI3K/Akt, and Rho-like GTPase pathways. TGF- β 1 differentiates fibroblasts into and increase ECM accumulation.
PDGF	PDGF stimulates fibroblasts and increase ECM gene expression in fibroblasts.
Chemokines	
CCL2	CCL2 increase fibrocyte recruitment and differentiation into fibroblasts, resulting in excessive collagen deposition. CCL2 activates M2 macrophage activation and promote PF.
CCL17	CCL17 promotes PF through the recruitment of CCR4 ⁺ Th2 cells and alveolar macrophages.
CCL18	CCL18 increase collagen production in lung fibroblasts through ERK1/2, PKC α , and Sp1/Smad3 signaling pathways.
CXCL 12	CXCL 12 recruits fibrocytes and activates the Rac1/ERK and JNK signaling pathways to induce AP-1 activation and CTGF expression in fibroblasts

Definition of abbreviations: Ap-1, activator protein 1; CCL, CC chemokine; CTGF, connective tissue growth factor; CXCL, CXC chemokine ligand; ECM, extracellular matrix; EMT, epithelial-mesenchymal transition; ERK, extracellular signal-regulated kinase; IL-1R1, IL-1 receptor 1; JNK, c-Jun N-terminal kinases; MAPK, mitogen-activated protein kinase; MMP, matrix metalloproteinase; MyD88, myeloid differentiation primary response gene 88; PDGF, platelet-derived growth factor; PF, pulmonary fibrosis; PI3K, phosphatidylinositol 3-kinase; PKC, protein kinase C; Rac 1, Ras-related C3 botulinum toxin substrate 1; SMAD, SMA/MAD homology; Sp1, specificity protein 1; TGF, transforming growth factor; TIMP, tissue inhibitors of metalloproteinase; Tregs regulatory T cells.

Adapted from Kolahian et al. [158].

Table 5. Possible immune mechanisms for pulmonary fibrosis.

noticed Raynaud's phenomenon and polyarthralgia, for which she was given low-dose prednisolone with clinical improvement. Two months before the referral, she developed polyarthralgia and myalgia. On physical examination, the patient had no skin lesions but presented with fine crackles audible on inspiration in both lower lung fields. Erythrocyte sedimentation

rate (ESR) was 135 mm/hr, and C-reactive protein (CRP) level was 1.2 mg/dL (reference range: 0.0–0.4). Rheumatoid factors (RFs), speckled anti-nuclear factors (ANFs), and anti-histidyl-t-RNA synthetase (Jo-1) antibodies were positive, while anti-ribonucleoprotein (RNP) and anti-scleroderma-70 (scl-70) antibody assays were negative. Levels of lactate dehydrogenase (LDH, 798 IU/L) (reference range: 109–435), creatine kinase (CK, 559 IU/L) (reference range: 44–140), and myoglobin (120 ng/mL) (reference range: 28–60) were elevated. Muscle strength was nearly normal, but electromyogram showed myogenic patterns in the muscle groups of the upper limb girdle bilaterally. Muscle biopsy revealed lymphocyte infiltration into myofibrils and muscle atrophy, consistent with PM. Arterial blood gas analysis demonstrated a pH of 7.413; partial pressure of carbon dioxide (PCO_2), 44.6 Torr; partial pressure of oxygen (PO_2), 84.3 Torr; and bicarbonate (HCO_3^-) concentration, 28.4 mmol/L. Pulmonary function tests revealed a restrictive pattern; vital capacity (VC) was 74.8%, and diffusing capacity (DLco) was 13.44 mL/min/mmHg (67.3%). Analysis of bronchoalveolar lavage fluid (BAL) showed 75% macrophages, 15% neutrophils, and 10% lymphocytes. Human leukocyte antigen (HLA) serotypes were as follows: A2, A26, B15, Cw1, Cw9, DR14, DR8, DR52, DQ7, and DQ6. Chest radiography and chest computed tomography (CT) revealed mild, subpleural, linear, and reticular opacities in posterior and lateral areas of both lungs (**Figure 2a**). The patient underwent video-assisted thoracoscopic (VATS) lung biopsy for histopathologic diagnosis and therapeutic planning. Biopsy specimens from anterior basal segment (S8) and lateral basal segment (S9) of the right lower lobe revealed an early usual IP (UIP) pattern, demonstrating heterogeneous lesions with residual air spaces and early fibrotic changes, surrounded by mild alveolitis with mononuclear cell infiltrations. Based on these clinical and histopathologic findings, the patient was diagnosed with interstitial pneumonia associated with PM. She was subsequently treated with methylprednisolone pulse therapy (1 g/day for 3 days) followed by oral prednisolone (30 mg/day). Over 10 months, the dose of prednisolone was tapered to 12.5 mg/day with excellent control of progression of pulmonary lesions and myositis.

Patient B was a 43-year-old woman, a lifetime nonsmoker, referred to our clinic for arthralgia and myalgia. The patient had developed Raynaud's phenomenon 6 months prior to this presentation. On physical examination, she had swollen fingers, with no skin rash. Fine crackles were heard on inspiration in the lower lung fields. No muscle weakness was apparent, but thorough examination revealed myositis. Laboratory data were as follows: LDH level, 616 IU/L; CK level, 410 IU/L; and CRP level, 0.4 mg/dL. Histological examination of muscle biopsy specimen showed mononuclear cell infiltrates in muscle tissue, consistent with PM. Assays for RF, anti-dsDNA antibodies, anti-Jo-1 antibodies, anti-centromere antibodies, and anti-scl-70 antibodies were negative. ANF (speckled pattern) and anti-ribonucleoprotein (RNP) antibodies were positive. Arterial blood gas analysis was unremarkable. Pulmonary function testing showed a restrictive pattern; VC, 70.6%, and DLco, 14.71 mL/min/mmHg (77.2%). BAL analysis demonstrated 67% macrophages, 11% neutrophils, and 22% lymphocytes. HLA serotypes were as follows: A24, A26, B15, B61, Cw10, DR9, DR53, and DQ9. Chest radiography and CT revealed subpleural and basilar linear and reticular opacities with ground glass attenuation (**Figure 2b**). Histopathological examination of lung specimens from VATS biopsy of superior (S4) and anterior basal (S8) segments of the left lower lobe disclosed a nonspecific IP (NSIP) pattern. Specimens showed mild and homogeneous changes with

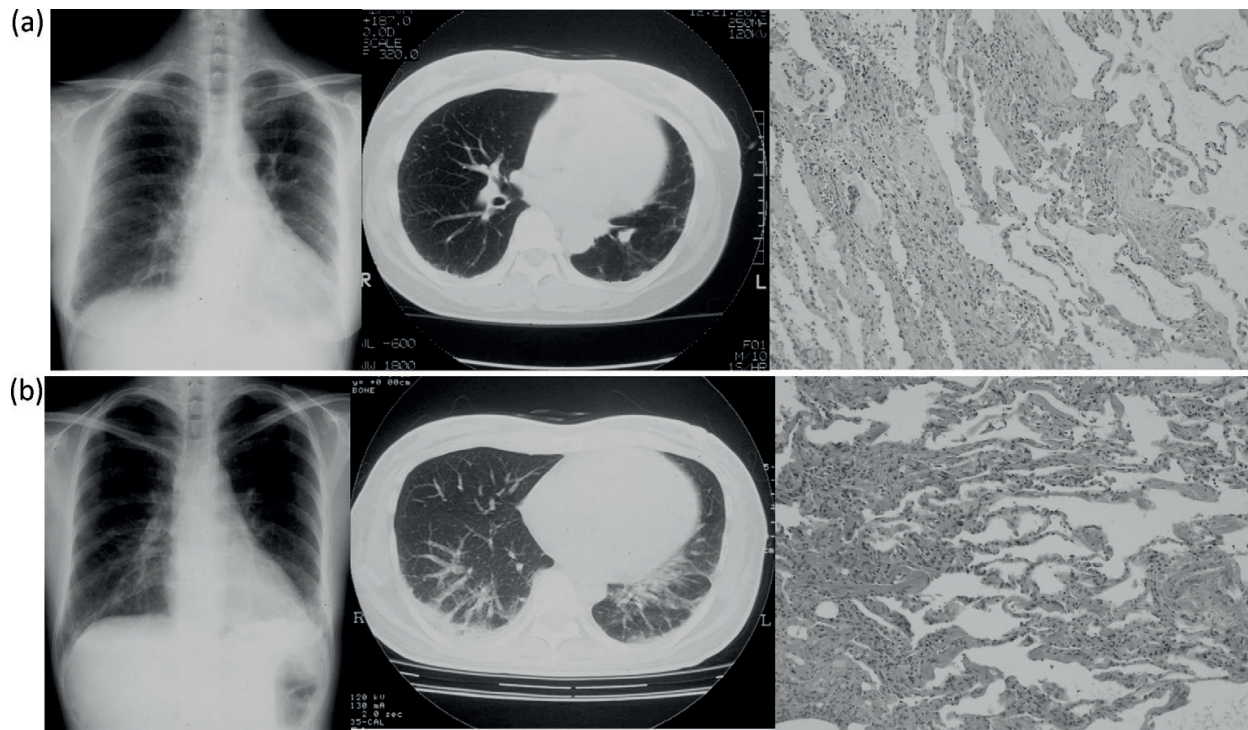


Figure 2. (a) Chest radiography, CT, and photomicrograph of patient A. Chest X-ray and HRCT of patient A show subpleural mild linear and reticular opacities in posterolateral lung. Lung biopsy from patient A depicts heterogeneous lesions including residual air spaces and early fibrotic changes with fibroblastic foci, mild alveolitis with thickened alveolar walls, and mononuclear cell infiltrations (hematoxylin and eosin stain, original magnification $\times 200$). (b). Chest radiography, CT, and photomicrograph of patient B. Chest X-ray and HRCT of patient B show thickened interlobular septa with bibasilar and subpleural ground glass opacities. Lung biopsy from patient B depicts mild, homogeneous changes with partial inflammatory thickening of the alveolar wall, with granulation tissues in alveolar spaces, fibrosis, and inflammatory cell infiltrates (hematoxylin and eosin stain, original magnification $\times 200$).

partial inflammatory thickenings of the alveolar wall, with granulation tissues in alveolar spaces, fibrosis, and inflammatory-cell infiltrations. Clinical and histopathologic findings lead to a diagnosis of IP associated with PM. She was subsequently given pulse therapy with methylprednisolone (1 g/day for 3 days) followed by oral prednisolone (50 mg/day), which was effective in ceasing active myositis and IP. When the dose of prednisolone had been tapered to 30 mg/day after 4 months, respiratory function testing showed that %VC and DLco had improved to 79.0% and 17.56 mL/min/mmHg (90.7%), respectively.

Immunohistochemical analysis was performed on lung-infiltrating cells utilizing biopsy specimens. Substantial infiltrations of mononuclear cells were noted in both patient A (UIP pattern) and patient B (NSIP pattern). The mononuclear cells were predominantly CD3⁺ T cells, accompanied by a subtle infiltration of B cells (CD20⁺), and a minimal number of monocytes (CD19⁺). Of infiltrating T cells, CD4⁺ cells were predominant compared to CD8⁺ cells in both cases. We then analyzed T cell receptor α -chain variable region (TCR V α) and TCR β -chain variable region (TCR V β) repertoires of T cells infiltrating the lung tissues using an adaptor ligation polymerase chain reaction (PCR)-based microplate hybridization assay [159]. Quantitative assay has been used in many previous studies, and accuracy and reproducibility of this assay have been validated [160, 161]. Briefly, total RNA was extracted with TRIzol

Reagent (Invitrogen, USA) from lung tissues obtained by VATS biopsy. Complementary DNA (cDNA) was synthesized with reverse transcriptase (Superscript II) and BSL-18E primer adaptor. Universal adaptor primers were ligated to the cDNA, and PCR was performed with the universal primer and primers specific for TCR C α or C β chains. PCR products were biotinylated by amplification with 5'-biotin primer and the universal primer. The biotinylated PCR products were hybridized on microplate wells immobilized with various oligo probes specific for TCR V α or V β region sequences. Finally, the amount of biotinylated product bound to each probe was measured by quantitative enzyme-linked immunosorbent assay (ELISA) with alkaline phosphatase streptavidin. The results of quantitative analysis of TCR V α or TCR V β usage in patient A and B are shown in **Figure 3a** and **b**, respectively. The open column and solid column indicate the frequencies of TCR V α /V β repertoires in the lung tissue and the peripheral blood lymphocytes (PBLs), respectively. We found that the usage of repertoires of TCR V α /V β in the lung differed from those in PBL, with certain TCR V gene families detected more frequently from lung tissue. In patient A, TCR repertoires of VA2.1, VA8.1, VB4.1, and VB24.1 were predominantly expressed in the lung compared to PBL, while TCR V repertoires VA23.1 and VB13.1 were more frequently expressed in lung tissue from patient B. As expected, no TCR signals were detected on normal lung tissue obtained from patients without IP using the same method (data not shown).

6.2.2. Discussion

IP associated with PM/DM is recognized as a critical complication due to its association with poor disease prognosis. In this study, we investigated T cells infiltrates by analyzing the TCR repertoire usage in lung tissue in two patients with PM-associated early IP. Both patients showed marked lymphocytes aggregates, predominantly CD3⁺ T cells, at IP lesion sites. In addition, the analysis of TCR V α /V β repertoire usage indicated a modest accumulation of T cells expressing selected TCR V-gene segments, which differed distinctly from those of PBL. These findings strongly suggest pathogenic involvement of organ-specific oligoclonal T cell accumulation in development of PM-associated IP. Since TCR diversifies with disease progression due to the phenomenon of "determinant spreading" in which autoreactive T cell responses, initiated by a single antigenic epitope, evolve into multiepitopic responses, we considered it important to perform TCR analysis from lung tissue in the earliest stage of IP [162]. Regarding differences in predominant TCR V gene usage between the two cases, we suspect this is due to HLA differences. A previous study on lung TCR repertoire in patients with PM by Englund et al. reported selective TCR V gene usage, characterized by a panel of TCR-specific monoclonal antibodies on flow cytometry [163]. However, that study used BAL fluid rather than lung tissue in which infiltrating T cells may be more directly involved in the disease process. Although we also tried to analyze TCR repertoire from BAL fluid, the data were inconclusive due to lack of TCR signals along with background noise from RNA debris. To our knowledge, this is the first robust demonstration of the presence of selective TCR V gene usage and its differential expression in lung tissues of patients with PM using both lung biopsy tissue from early IP and PBL. Because our study involved only two cases, these findings should be confirmed in a larger study. However, we believe these findings strongly suggest that T cells which are recruited into the lung may be exposed to autoantigens, selectively expanding by antigen-driven responses. Further studies are needed to identify T cell epitopes

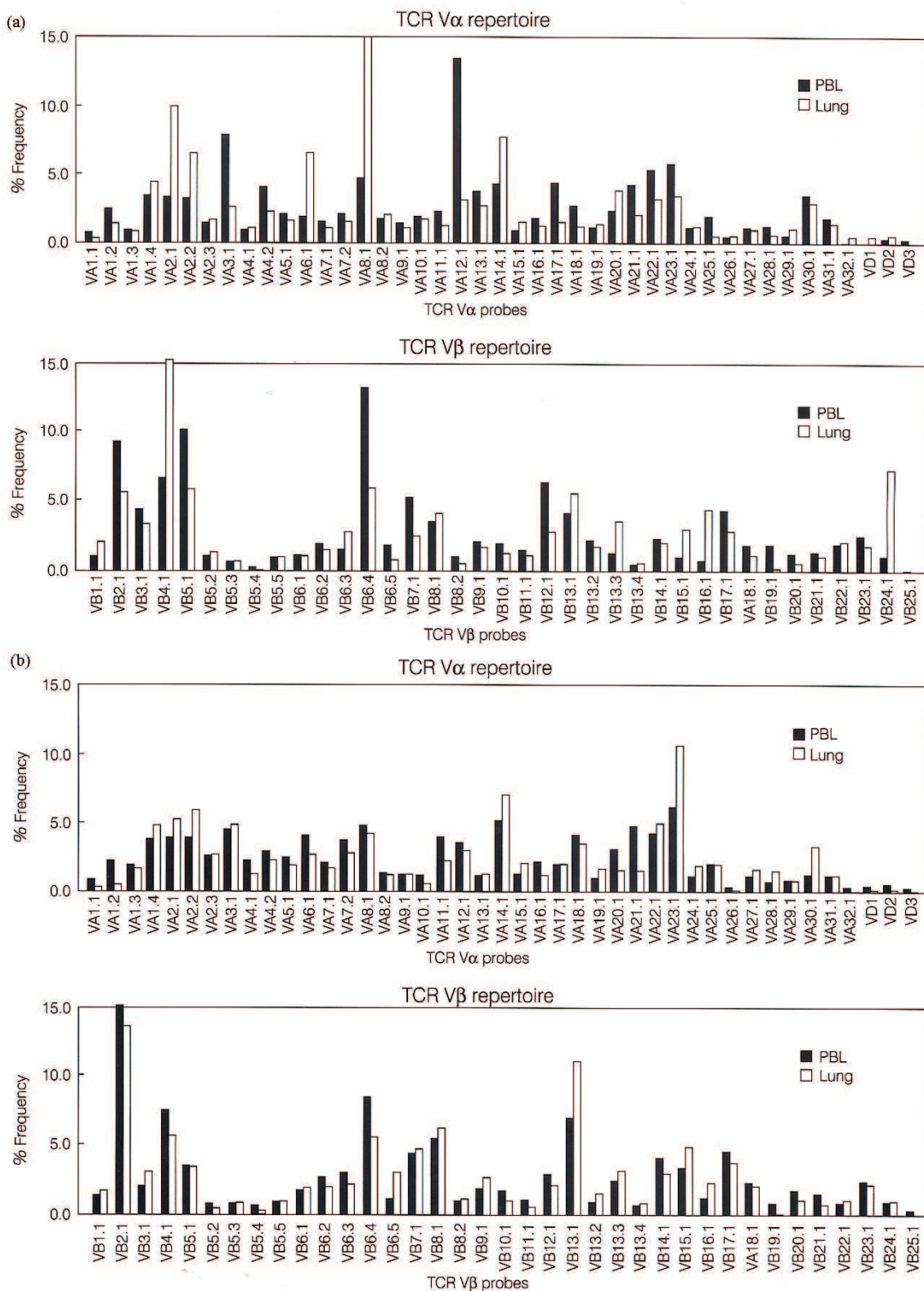


Figure 3. (a) Quantitative analysis of TCR repertoires: TCR V α gene usage (top) and TCR V β gene usage (bottom) in patient A. Solid and open bars indicate frequencies of TCR V α /V β repertoires in PBL and lung tissue, respectively. VA2.1 and VA8.1 and VB4.1 and VB24.1 repertoires predominate in lung tissue compared with PBL. (b). Quantitative analysis of TCR repertoires: TCR V α gene usage (top) and TCR V β gene usage (bottom) in patient B. Solid and open bars indicate frequencies of TCR V α /V β repertoires in PBL and lung tissue, respectively. VA23.1 and VB13.1 repertoires are more frequent in lung tissue compared with PBL.

of the pathogenic antigens, which may potentially lead to the development of antigen-specific, molecular-targeted therapies, such as the induction of anergy by peptide analogues similar in structure to culprit antigens [164, 165].

Thus, as a result, the T cell receptor (TCR) repertoire study combined with histological analysis demonstrated substantial CD3+ T cell lung infiltrates with specific oligoclonal TCR usage that differed from those in PBL, suggesting a pivotal role for T cells in the pathogenesis of PM-associated IP via antigen-driven immune mechanisms.

7. Management of interstitial pneumonia associated with connective tissue disease

Because of the wide variation in manifestations of ILD in the autoimmune disease of CTD, no simple management strategy is adequate for every possible clinical setting. While a part of patients with CTD-associated ILD have limited and stable disease, not always requiring treatment, the significant proportions have severe and progressive disease which necessitates prompt and appropriate treatment. Essentially, nevertheless, general therapeutic principles in CTDs can be applied to many situations including acute and chronic disease. These include use of corticosteroids, azathioprine (AZA), cyclophosphamide (CYC), methotrexate (MTX), mycophenolate mofetil (MMF), and calcineurin inhibitors [13]. Although there are no specific guidelines for the management of CTD-ILD, general strategies recommended for IPF of IIP are also often applied in some cases of CTD-ILD. Emerging treatments with effects in IPF, e.g., Pirfenidone (a pyridine showing both anti-inflammatory and anti-fibrotic effects) and Nintedanib (a small-molecule tyrosine kinase inhibitor targeting VEGF-, FGF-, PDGF-receptors) may offer additional treatment options, though the efficacy has not been evaluated in CTD-ILD [166]. Basically, in contrast to the dismal prognosis in IPF/UIP of IIP with a median survival since diagnosis of 2–3 years, clinical experience in managing patients has taught us that immunosuppressive drugs in CTD-associated ILDs are capable of benefiting a significant proportion of patients, particularly those with certain histological patterns of disease.

With regard to the clinical study, there have been only two randomized placebo-controlled trials investigating the effect of immunosuppressive treatment in SSc-associated ILD. Briefly, the Scleroderma Lung Study (SLS) and the Fibrosing Alveolitis Scleroderma Trial (FAST), evaluated CYC (given orally at 2 mg/kg for 1 year in SLS and intravenously at a dose of 600 mg/m² monthly for 6 months, followed by oral AZA for the following 6 months in FAST) for SSc-ILD [72, 73]. Both studies found a slower decline in forced vital capacity (FVC) in the CYC group compared with placebo. Intravenous CYC elicited a lower rate of bone marrow toxicity, severe infections, and gonadal failure compared to oral administration, likely due to higher cumulative dose acquired by daily oral administration [167]. Six months after quitting of immunosuppressant, the recovery in FVC fell into baseline, suggesting the requirement of prolonged immunosuppression therapy to maintain stability of lung function [168]. However, it should be noted that, despite studies supporting the benefit of CYC therapy in preventing deterioration in the lung function and premature death in patients with SSc-ILD,

recent systematic review and meta-analysis of RCTs and observational prospective cohort studies failed to validate any clinically significant improvement in pulmonary function in SSc patients treated with CYC [169, 170].

In PM/DM-associated ILD, high-dose steroid is often the first-line drug, although no definite therapeutic recommendation for the disease has been established yet. The other drugs most frequently used are AZA, MMF, hydroxychloroquine, MTX, CYC, and calcineurin inhibitors, e.g., cyclosporine A (CSA) and tacrolimus (TAC). Rituximab, anti-CD20 monoclonal antibody therapy, has lately emerged as a promising remedy of biologics in patients who have failed conventional immunosuppression treatments [171, 172]. Among a variety of immunosuppressants, the efficacy of calcineurin inhibitors for the treatment of PM/DM-associated ILD should be highlighted. CSA, which inhibits T cell proliferation and T cell-mediated cytokine productions at the transcriptional level, has begun to be used for PM/DM-ILD since the 1980s [173–175]. In 1998, the first nation-wide survey for the treatment with CSA in IP associated with CTDs was conducted in Japan, and the efficacy of a combination therapy with CSA and corticosteroids in PM/DM associated IP was indicated [176]. A number of retrospective and open-label studies have supported the benefit of CSA for the treatment of ILD with PM/DM [177–181]. Takada et al. published a retrospective multicenter study of 38 cases with acute ILD with PM/DM, whereas it was shown that the combination therapy with CSA and corticosteroids started from the early phase of ILD is superior to corticosteroid monotherapy [178]. Today, calcineurin inhibitors are widely used especially in Japan as both an induction and maintenance therapy for PM/DM-ILD, generally resulting in favorable prognostic outcomes. The appropriate serum concentration of CSA to ensure a maximal effect as well as to avoid toxicity in patients with PM/DM-ILD should reach approximately 150 ng/mL and 1000 ng/mL, at trough and at 2 hours after administration, respectively [179]. Another calcineurin inhibitor, TAC, which is a 100-fold potent T cell inhibitor compared to CSA, was also introduced into the treatment for PM/DM-ILD, and its efficacy and tolerability have been demonstrated in retrospective studies and case series since the report by Oddis et al. in 1999 [182–185]. Ochi, et al. described a superior effect of TAC used in two myositis patients with progressive ILD who failed CYC and corticosteroid treatment but successfully recovered with TAC, showing significant improvement in symptoms and radiologic changes [183]. The appropriate tacrolimus trough level for the treatment of ILD in PM/DM patients have not been established by clinical trials, but it is usually set as 5–20 ng/mL on the basis of data from renal and bone marrow transplantation [186].

Given the treatment-effect heterogeneity of the lung disease observed in PM/DM, it is important to prepare novel therapeutics for the challenging cases of ILD which are refractory to conventional formulas. Recently, Suda et al. reported the effectiveness of multitarget therapy for the ILD in two cases of anti-MDA5 antibody-positive DM which is known to be associated with progressive ILD and sometimes has a lethal outcome despite strong immunosuppressive therapy including CYC [187]. They used TAC and mizoribine (MZR, an inosine monophosphate dehydrogenase inhibitor) in combination with corticosteroids. MZR is a nucleoside of the imidazole class, with the same mechanism as MMF: selective inhibition of lymphocyte proliferation by blocking inosine monophosphate dehydrogenase [188]. The safety and steroid-sparing effects of MZR have been shown in various CTDs, and the efficacy of multitarget therapy using TAC and MZR was reported for systemic lupus erythematosus [189, 190].

8. Conclusions

Despite increased recognition of CTD-associated ILD and its prognostic significance, the pathologic mechanisms that lead to the considerable pulmonary changes are not yet fully defined, and thus, the only limited progress has been so far made in the therapeutic domains. Immunosuppression therapy remains the mainstay of treatment for CTD-ILD. To generate significant advances in therapeutic intervention strategy, fundamental understanding of the pathogenesis of CTD-ILD is essential. As noted, we had an opportunity to carefully study the cases of early-stage IP associated with PM by utilizing lung biopsy tissue and PBLs. The T cell receptor (TCR) repertoire study combined with histological analysis demonstrated substantial CD3+ T cell lung infiltrates with specific oligoclonal TCR usage that differed from those in PBL, suggesting a pivotal role for T cells in the pathogenesis of PM-associated IP via antigen-driven immune responses. The results imply potential elucidation of specific antigen(s) that oligoclonal, lung-infiltrating T cells recognize, which may provide novel insights into the development of immunospecific treatments such as molecular-targeted or specific T cell-targeted therapeutics.

Disclosure statement

The authors have declared no conflicts of interest.

Patient consent

The authors have declared in the published articles that the informed consent was obtained from the patients.

Ethical approval

The authors have declared in the published articles that the protocols were approved by the institutional review board.

Author details

Akira Takeda^{1*} and Yoshiki Ishii²

*Address all correspondence to: akitake@iuhw.ac.jp

1 Division of Clinical Immunology & Rheumatology, International University of Health and Welfare Hospital, Nasu-Shiobara, Tochigi, Japan

2 Department of Pulmonary Medicine and Clinical Immunology, Dokkyo University School of Medicine, Mibu, Tochigi, Japan

References

- [1] American Thoracic Society. European Respiratory Society: American Thoracic Society/European Respiratory Society international multidisciplinary consensus classification of the idiopathic international pneumonias. *American Journal of Respiratory and Critical Care Medicine*. 2002;**165**:277-304
- [2] Travis WD, Costabel U, Hansell DM, King TE Jr, Lynch DA, Nicholon AG, Ryerson CJ, Ryu JH, Selman M, Wells AU, Behr J, Bouros D, Brown KK, Colby TV, Collard HR, Cordeiro CR, Cottin V, Crestani B, Drent M, Dudden RF, Egan J, Flaherty K, Hogaboam C, Inoue Y, Johkoh T, Kim DS, Kitaichi M, Loyd J, Martinez FJ, Myers J, Myers J, Protzko S, Raghu G, Richeldi L, Sverzellati N, Swigris J, Valeyre D, on behalf of the ATS/ERS committee on idiopathic interstitial pneumonias. An official American Thoracic Society/European Respiratory Society statement: Update of the international multidisciplinary classification of the idiopathic international pneumonias. *American Journal of Respiratory and Critical Care Medicine*. 2013;**188**:733-748. DOI: 10.1164/rccm.201308-1483ST
- [3] Margaritopoulos GA, Romagnoli M, Poletti V, Siafakas NM, Wells AU, Antoniou KM. Recent advances in the pathogenesis and clinical evaluation of pulmonary fibrosis. *European Respiratory Review*. 2012;**21**:48-56. DOI: 10.1183/09059180.00007611
- [4] Antoniou KM, Margaritopoulos GA, Tomassetti S, Bonella F, Costabel U, Poletti V. Interstitial lung disease. *European Respiratory Review*. 2014;**23**:40-54. DOI: 10.1183/09059180.00009113
- [5] Vij R, Strek ME. Diagnosis and treatment of connective tissue disease-associated interstitial lung disease. *Chest*. 2013;**143**:813-824. DOI: 10.1378/chest.12-0741
- [6] Fukushima Y, Takeda A, Matsutani T, Fukushima F, Furihata T, Maezawa R, Miyoshi M, Hirata H, Sugiyama K, Okada M, Fukuda T. Involvement of antigen-driven mechanisms in interstitial pneumonia with polymyositis. *Rheumatology*. 2013;**52**:1537-1540. DOI: 10.1093/rheumatology/ket003
- [7] Takeda A, Fukushima Y, Matsutani T, Rokutanda R, Suyama Y, Kishimoto M, Yamaguchi K-I, Okada M. Implication of antigen-driven mechanisms in the pathogenesis of interstitial pneumonia associated with polymyositis. *Frontiers in Immunology*. 2013; 15th International Congress of Immunology (ICI). DOI: 10.3389/conf.fimmu.2013.02.00414 (published online: Aug 22, 2013)
- [8] Nakamura Y, Suda T. Idiopathic pulmonary fibrosis: Diagnosis and clinical manifestations. *Circulatory Respiratory and Pulmonary Medicine*. 2015;**9**(S1):163-171. DOI: 10.4137/CCRPM.S39897
- [9] Raghu G, Collard HR, Egan JJ, et al. ATS/ERS/JRS/ALAT Committee on Idiopathic Pulmonary Fibrosis. An official ATS/ERS/JRS/ALAT statement: Idiopathic pulmonary fibrosis: Evidence-based guidelines for diagnosis and management. *American Journal of Respiratory and Critical Care Medicine*. 2011;**183**:788-824

- [10] Raghu G, Rochweg B, Zhang Y, et al. American Thoracic Society; European Respiratory Society; Japanese Respiratory Society; Latin American Thoracic Association. An official ATS/ERS/JRS/ALAT clinical practice guideline: Treatment of idiopathic pulmonary fibrosis. An update of the 2011 clinical practice guideline. *American Journal of Respiratory and Critical Care Medicine*. 2015; **192**:e3-19. DOI: 10.1164/rccm.201506-1063ST
- [11] de Lauretis A, Veeraraghavan S, Renzoni E. Aspects of interstitial lung disease: Connective tissue disease-associated interstitial lung disease: How does it differ from IPF? How should the clinical approach differ? *Chronic Respiratory Disease*. 2011; **8**:53-82. DOI: 10.1177/1479972310393758
- [12] Castellino FV, Varga J. Interstitial lung diseases: Evolving concepts of pathogenesis and management. *Arthritis Research & Therapy*. 2010; **12**(4):213. DOI: 10.1186/ar3097
- [13] Mathai SC, Danoff SK. Management of interstitial lung disease associated with connective tissue disease. *BMJ*. 2016; **352**:h6819. DOI: 10.1136/bmj.h6819
- [14] Cottin V. Interstitial lung diseases: Are we missing formes frustes of connective tissue disease? *The European Respiratory Journal*. 2006; **28**:893-896
- [15] Fischer A, West SG, Swigris JJ, et al. Connective tissue disease-associated interstitial lung disease: A call for clarification. *Chest*. 2010; **138**:251-256
- [16] Bryson T, Sundaram B, Khanna D, Kazerooni E. Connective tissue disease-associated interstitial lung disease: Similarity and difference. *Seminars in Ultrasound, CT and MRI*. 2014; **35**:29-38
- [17] Fischer A, du Bois R. Interstitial lung disease in connective tissue disorders. *Lancet*. 2012; **380**:689-698.
- [18] Fischer A, Richeldi L. Cross-disciplinary collaboration in connective tissue disease-related lung disease. *Seminars in Respiratory and Critical Care Medicine*. 2014; **35**:159-165
- [19] Tzelepis GE, Toya SP, Moutsopoulos HM. Occult connective tissue diseases mimicking idiopathic interstitial pneumonias. *European Respiratory Review*. 2008; **31**:11-20
- [20] Bonella F, Costabel U. Biomarkers in connective tissue disease-associated interstitial lung disease. *Seminars in Respiratory and Critical Care Medicine*. 2014; **35**:181-220
- [21] Prasse A, Muller-Quernheim J. Non-invasive biomarkers in pulmonary fibrosis. *Respirology*. 2009; **14**(6):788-795
- [22] Pastva AM, Wright JR, Williams KL. Immunomodulatory roles of surfactant protein A and D: Implications in lung disease. *Proceedings of the American Thoracic Society*. 2007; **4**(3):252-257
- [23] Takahashi H, Kuroki Y, Tanaka H, et al. Serum levels of surfactant proteins A and D are useful biomarkers for interstitial lung disease in patients with progressive systemic sclerosis. *American Journal of Respiratory and Critical Care Medicine*. 2000; **162**(1):258-263
- [24] Ishikawa N, Hattori N, Yokoyama A, Kohno N. Utility of KL-6/MUC1 in the clinical management of interstitial lung diseases. *Respiratory Investigation*. 2012; **50**(1):3-13

- [25] Ohshimo S, Yokoyama A, Hattori N, Ishikawa N, Hirasawa Y, Kohno N. KL-6, a human MUC1 mucin, promotes proliferation and survival of lung fibroblasts. *Biochemical and Biophysical Research Communications*. 2005;**338**(4):1845-1852
- [26] Yamane K, Ihn H, Kubo M, et al. Serum levels of KL-6 as a useful marker for evaluating pulmonary fibrosis in patients with systemic sclerosis. *The Journal of Rheumatology*. 2000;**27**(4):930-934
- [27] Papiris SA, Kagouridis K, Bouros D. Serologic evaluation in idiopathic interstitial pneumonias. *Current Opinion in Pulmonary Medicine*. 2012;**18**(5):433-440
- [28] Lunardi F, Balestro E, Nordio B, et al. Undifferentiated connective tissue disease presenting with prevalent interstitial lung disease: Case report and review of literature. *Diagnostic Pathology*. 2011;**6**:50
- [29] Olson AL, Brown KK, Fischer A. Connective tissue disease-associated lung disease. *Immunology and Allergy Clinics of North America*. 2012;**32**(4):513-536
- [30] Mosca M, Tani C, Bombardieri S. Undifferentiated connective tissue diseases (UCTD): A new frontier for rheumatology. *Best Practice & Research. Clinical Rheumatology*. 2007;**21**(6):1011-1023
- [31] Kinder BW, Collard HR, Koth L, et al. Idiopathic nonspecific interstitial pneumonia: Lung manifestation of undifferentiated connective tissue disease? *American Journal of Respiratory and Critical Care Medicine*. 2007;**176**:691-697
- [32] Vij R, Noth I, Strek ME. Autoimmune-featured interstitial lung disease: A distinct entity. *Chest*. 2011;**140**:1292-1299
- [33] Fischer A, Antoniou KM, Brown KK, et al. ERS/ATS Task Force on Undifferentiated Forms of CTD-ILD. An official European Respiratory Society/American Thoracic Society research statement: Interstitial pneumonia with autoimmune features. *The European Respiratory Journal*. 2015;**46**(4):976-987. DOI: 10.1183/13993003.00150-2015
- [34] Collins BF, Spiekerman CF, Shaw MA, Ho LA, Hayes J, Spada CA, Stamato CM, Raghu G. Idiopathic interstitial pneumonia associated with autoantibodies a large case series followed over 1 year. *Chest*. 2017;**152**(1):103-112. DOI: [org/10.1016/j.chest.2017.03.004](http://dx.doi.org/10.1016/j.chest.2017.03.004)
- [35] Urisman A, Jones KD. Pulmonary pathology in connective tissue disease. *Seminars in Respiratory and Critical Care Medicine*. 2014;**35**:201-212
- [36] Vivero M, Padera RF. Histopathology of lung disease in connective tissue diseases. *Rheumatic Diseases Clinics of North America*. 2015;**41**:197-211
- [37] Kitaichi M. Pathologic features and the classification of interstitial pneumonia of unknown etiology. *Bulletin of the Chest Disease Research Institute, Kyoto University*. 1990;**23**:1-18
- [38] Katzenstein A-LA, Fiorelli RF. Non-specific interstitial pneumonia/fibrosis. Histologic patterns and clinical significance. *The American Journal of Surgical Pathology*. 1994;**18**:136-147

- [39] Nagai S, Kitaichi K, Itoh H, Nishimura K, Izumi T, Colby TV. Idiopathic nonspecific interstitial pneumonia/fibrosis: Comparison with idiopathic pulmonary fibrosis and BOOP. *The European Respiratory Journal*. 1998;**12**:1010-1019
- [40] Travis WD, Matsui K, Moss J, Ferrans VJ. Idiopathic nonspecific interstitial pneumonia: Prognostic significance of cellular and fibrosing patterns: Survival comparison with usual interstitial pneumonia and desquamative interstitial pneumonia. *The American Journal of Surgical Pathology*. 2000;**24**:19-33
- [41] Tanaka N, Kim JS, Newell JD, Brown KK, Cool CD, Meehan R, et al. Rheumatoid arthritis-related lung disease: CT findings. *Radiology*. 2004;**232**:81-91
- [42] Lee HK, Kim DS, Yoo B, Seo JB, Rho JY, et al. Histopathologic pattern and clinical features of rheumatoid arthritis-associated interstitial lung disease. *Chest*. 2005;**127**:2019-2027
- [43] Park LH, Kim DS, Park I, Jang SJ, Kitaichi M, Nicholson AG, et al. Prognosis of fibrotic interstitial pneumonia: Idiopathic versus collagen vascular disease-related subtypes. *American Journal of Respiratory and Critical Care Medicine*. 2007;**175**:705-711
- [44] Song JW, Do K, Kim M, Jang SJ, Colby TV, Kim DS. Pathologic differences between idiopathic and collagen vascular disease-related usual interstitial pneumonia. *Chest*. 2009;**136**:23-30
- [45] Hamman L, Rich AR. Fulminating diffuse interstitial fibrosis of the lungs. *Transactions of the American Clinical and Climatological Association*. 1935;**51**:154-163
- [46] Katzenstein A-LA, Bloor CM, Leibow AA. Diffuse alveolar damage – the role of oxygen, shock, and related factors: A review. *The American Journal of Pathology*. 1976;**85**(1):209-228
- [47] Katzenstein A-LA, Myers JL, Mazur MT. Acute interstitial pneumonia: A clinicopathologic, ultrastructural, and cell kinetic study. *The American Journal of Surgical Pathology*. 1986;**10**(4):256-267
- [48] Mukhopadhyay S, Parambil JG. Acute interstitial pneumonia (AIP): Relationship to Hamman-Rich syndrome, diffuse alveolar damage, and acute respiratory distress syndrome (ARDS). *Seminars in Respiratory and Critical Care Medicine*. 2012;**33**:476-485
- [49] Tomashefski JF Jr. Pulmonary pathology of acute respiratory distress syndrome. *Clinics in Chest Medicine*. 2000;**21**(3):435-466
- [50] Brower RG, Matthay MA, Morris A, Schoenfeld D, Thompson BT, Wheeler A. Acute Respiratory Distress Syndrome Network. Ventilation with lower tidal volumes for acute lung injury and acute respiratory distress syndrome. *The New England Journal of Medicine*. 2000;**342**(18):1301-1308
- [51] Parambil JG, Myers JL, Ryu JH. Diffuse alveolar damage: Uncommon manifestation of pulmonary involvement in patients with connective tissue diseases. *Chest*. 2006;**130**(2):553-558
- [52] Zamora MR, Warner ML, Tuder R, Schwarz KI. Diffuse alveolar hemorrhage and systemic lupus erythematosus. Clinical presentation, histology, survival, and outcome. *Medicine (Baltimore)*. 1997;**76**(3):192-202

- [53] Tazelaar HD, Viggiano RW, Pickersgill J, Colvy TV. Interstitial lung disease in polymyositis/dermatomyositis. Clinical features and prognosis as correlated with histologic findings. *The American Review of Respiratory Disease*. 1990;**141**(3):727-733
- [54] Douglas WW, Tazelaar HD, Hartman TE, et al. Polymyositis/dermatomyositis-associated interstitial lung disease. *American Journal of Respiratory and Critical Care Medicine*. 2001;**164**(7):1182-1185
- [55] Fujisawa T, Suda T, Nakamura Y, et al. Differences in clinical features and prognosis of interstitial lung diseases between polymyositis and dermatomyositis. *The Journal of Rheumatology*. 2005;**32**(1):58-64
- [56] Yousem SA, Colvy TV, Carrington CB. Lung biopsy in rheumatoid arthritis. *The American Review of Respiratory Disease*. 1985;**131**(5):770-777
- [57] Katzenstein A-LA, Myers JL. Nonspecific interstitial pneumonia and the other idiopathic interstitial pneumonias: Classification and diagnostic criteria. *The American Journal of Surgical Pathology*. 2000;**24**(1):1-3
- [58] Henriot AC, Diot E, Marchand-Adam S, et al. Organizing pneumonia can be the inaugural manifestation in connective tissue diseases, including Sjögren's syndrome. *European Respiratory Review*. 2010;**19**(116):161-163
- [59] Tansey D, Wells AU, Colby TV, et al. Variations in histological patterns of interstitial pneumonia between connective tissue disorders and their relationship to prognosis. *Histopathology*. 2004;**44**(6):585-596
- [60] Bouros D, Wells AU, Nicholson AG, et al. Histopathologic subsets of fibrosing alveolitis in patients with systemic sclerosis and their relationship to outcome. *American Journal of Respiratory and Critical Care Medicine*. 2002;**165**(12):1581-1586
- [61] Nicholson AG. Lymphocytic interstitial pneumonia and other lymphoproliferative disorders in the lung. *Seminars in Respiratory and Critical Care Medicine*. 2001;**22**(4):409-422
- [62] Deheinzelin D, Cpelozzi VL, Kairalla RA, BarbasFilho JV, Saldiva PH, de Carvalho CR. Interstitial lung disease in primary Sjögren's syndrome. Clinical-pathological evaluation and response to treatment. *American Journal of Respiratory and Critical Care Medicine*. 1996;**154**:794-799.
- [63] Steen VD. Clinical manifestations of systemic sclerosis. *Seminars in Cutaneous Medicine and Surgery*. 1998;**17**:48-54 A comprehensive review of the general clinical features of systemic sclerosis
- [64] D'Angelo WA, Fries JF, Masi AT, et al. Pathologic observations in systemic sclerosis (scleroderma). A study of fifty-eight autopsy cases and fifty-eight matched controls. *The American Journal of Medicine*. 1969;**46**:428-440
- [65] Gabrielli A, Avvedimento EV, Krieg T. Scleroderma. *The New England Journal of Medicine*. 2009;**360**(19):1989-2003

- [66] Cutolo M, Sulli A, Smith V. Assessing microvascular changes in systemic sclerosis diagnosis and management. *Nature Reviews Rheumatology*. 2010;**6**(10):578-587
- [67] Huguhe M, Herrick AL. Raynaud's phenomenon. *Best Practice & Research. Clinical Rheumatology*. 2016;**30**(1):112-132
- [68] van den Hoogen F, Khanna D, Fransen J, et al. 2013 classification criteria for systemic sclerosis: An American College of Rheumatology/European League against Rheumatism collaborative initiative. *Arthritis and Rheumatism* 2013;**65**(11):2737-2747
- [69] Reveille JD, Solomon DH. Evidence-based guidelines for the use of immunologic tests: Anticentromere, Scl-70, and nucleolar antibodies. *Arthritis and Rheumatism*. 2003;**49**:399-412
- [70] Shah AA, Hummers LK, Casciola-Rosen L, et al. Examination of autoantibody status and clinical features associated with cancer risk and cancer-associated scleroderma. *Arthritis and Rheumatism*. 2015;**67**(4):1053-1061
- [71] Parra ER, Otani LH, de Carvalho EF, et al. Systemic sclerosis and idiopathic interstitial pneumonia: Histomorphometric differences in lung biopsies. *Jornal Brasileiro de Pneumologia* 2009;**35**:529-540
- [72] Fujita J, Yoshinouchi T, Ohtsuki Y, et al. Non-specific interstitial pneumonia as pulmonary involvement of systemic sclerosis. *Annals of the Rheumatic Diseases*. 2001;**60**:281-283
- [73] Tashkin DP, Elashoff R, Clements PJ, Goldin J, Roth MD, Furst DE, et al. Cyclophosphamide versus placebo in scleroderma lung disease. *The New England Journal of Medicine*. 2006;**354**:2655-2666
- [74] Hoyles RK, Ellis RW, Wellsbury J, Lees B, Newlands P, Goh NS, et al. A multicenter, prospective, randomized, double-blind, placebo-controlled trial of and intravenous cyclophosphamide followed by oral azathioprine for the treatment of pulmonary fibrosis in scleroderma. *Arthritis and Rheumatism*. 2006;**54**:3962-3970
- [75] Kelly C, Hamilton J. What kills patients with rheumatoid arthritis? *Rheumatology (Oxford)*. 2007;**46**(2):183-184
- [76] Bongartz T, Nannini C, et al. Incidence and mortality of interstitial lung disease in rheumatoid arthritis: A population-based study. *Arthritis and Rheumatism*. 2010;**62**(6):1583-1591
- [77] Turesson C. Extra-articular rheumatoid arthritis. *Current Opinion in Rheumatology*. 2013;**25**(3):360-366
- [78] Hyland RH, Gordon DA, Broder I, Davies GM, Russell ML, Hutcheon MA, et al. A systematic controlled study of pulmonary abnormalities in rheumatoid arthritis. *The Journal of Rheumatology*. 1983;**10**:395-405
- [79] Jurik AG, Davidsen D, Graudal H. Prevalence of pulmonary involvement in rheumatoid arthritis and its relationship to some characteristics of the patients. A radiological and clinical study. *Scandinavian Journal of Rheumatology*. 1982;**11**:217-224

- [80] Gabbay E, Tarala R, Will R, Carroll G, Adler B, Cameron D, Lake FR. Interstitial lung disease in recent onset rheumatoid arthritis. *American Journal of Respiratory and Critical Care Medicine*. 1997;**156**:528-535
- [81] Youssef AA, Machaly SA, El-Dosoky ME, El-Maghraby NM. Respiratory symptoms in rheumatoid arthritis: Relation to pulmonary abnormalities detected by high-resolution CT and pulmonary functional testing. *Rheumatology International*. 2012;**32**(7):1985-1995
- [82] Saag KG, Cerhan JR, Kolluri S, Ohashi K, Hunninghake GW, Schwartz DA. Cigarette smoking and rheumatoid arthritis severity. *Annals of the Rheumatic Diseases*. 1997;**56**:463-469
- [83] Cipriani NA, Streck M, Noth I, et al. Pathologic quantification of connective tissue disease-associated versus idiopathic usual interstitial pneumonia. *Archives of Pathology & Laboratory Medicine*. 2012;**136**:1253-1258
- [84] Yoshinouchi T, Ohtsuki Y, Fujita J, et al. Nonspecific interstitial pneumonia pattern as pulmonary involvement of rheumatoid arthritis. *Rheumatology International*. 2005;**26**:121-125
- [85] Nakamura Y, Suda T, Kaida Y, et al. Rheumatoid lung disease: Prognostic analysis of 54 biopsy-proven cases. *Respiratory Medicine*. 2012;**106**:1164-1169
- [86] Cherin P, Herson S, Crevon MC, et al. Mechanisms of lysis by activated cytotoxic cells expressing perforin and granzyme-B genes and the protein TIA-1 in muscle biopsies of myositis. *The Journal of Rheumatology*. 1996;**23**:1135-1142
- [87] Dalakas MC. Molecular immunology and genetics of inflammatory muscle diseases. *Archives of Neurology*. 1998;**55**:1509-1512
- [88] Chevrel G, Page G, Miossec P. Novel aspects on the contribution of T cells and dendritic cells in the pathogenesis of myositis. *Autoimmunity*. 2006;**39**(3):171-176
- [89] Medsger TA Jr, Dawson WN Jr, Masi AT. The epidemiology of polymyositis. *The American Journal of Medicine*. 1970;**48**:715-723
- [90] Bohan A, Peter JB. Polymyositis and dermatomyositis (first part). *The New England Journal of Medicine*. 1975;**292**:344-347
- [91] Bohan A, Peter JB. Polymyositis and dermatomyositis (second part). *The New England Journal of Medicine*. 1975;**292**:403-407
- [92] Dalakas MC, Hohlfield R. Polymyositis and dermatomyositis. *Lancet*. 2003;**362**:971-982
- [93] Briani C, Doria A, Sarzi-Puttini P, Dalakas MC. Update on idiopathic inflammatory myopathies. *Autoimmunity*. 2006;**39**(3):161-170
- [94] Nirmalanathan N, Holton JL, Hanna MG. Is it really myositis? A consideration of the differential diagnosis. *Current Opinion in Rheumatology*. 2004;**16**:684-691
- [95] Dickey BF, Myers AR. Pulmonary disease in polymyositis/dermatomyositis. *Seminars in Arthritis and Rheumatism*. 1984;**14**:60-76

- [96] Lakhanpal S, Lie JT, Conn DL, WJ M. Pulmonary disease in polymyositis/dermatomyositis: A clinicopathological analysis of 65 autopsy cases. *Annals of the Rheumatic Diseases*. 1987;**46**:23-29
- [97] Marie I, Hatron PY, Hachulla E, Wallaert B, Michon-Pasturel U, Devulder B. Pulmonary involvement in polymyositis and in dermatomyositis. *The Journal of Rheumatology*. 1998;**25**:1336-1343
- [98] Marie I, Hachulla E, Hatron PY, Hellot MF, Levesque H, Devulder B, Courtois H. Polymyositis and dermatomyositis: Short term and longterm outcome, and predictive factors of prognosis. *The Journal of Rheumatology*. 2001;**28**:2230-2237
- [99] Marie I, Hachulla E, Chèrin P, Dominique S, Hatron P, Hellot MF, et al. Interstitial lung disease in polymyositis and dermatomyositis. *Arthritis and Rheumatism*. 2002;**47**:614-622
- [100] Fathi M, Lundberg IE, Tornling G. Pulmonary complications of polymyositis and dermatomyositis. *Seminars in Respiratory and Critical Care Medicine*. 2007;**28**:451-458
- [101] Connors GR, Christopher-Stine L, Oddis CV, et al. Interstitial lung disease associated with the idiopathic inflammatory myopathies: what progress has been made in the past 35 years? *Chest*. 2010;**138**:1464-1474
- [102] Lega J-C, Reynaud Q, Belot A, Fabien N, Durieu I, Cottin V. Idiopathic inflammatory myopathies and the lung. *European Respiratory Review*. 2015;**24**:216-238. DOI: 10.1183/16000617.00002015
- [103] Cottin V, Thivolet-Bèjui F, Reynaud-Gaubert M, Cadranel J, Delaval P, Ternamian PJ, et al. Groupe d'Études et de Recherche sur les Maladies "Orphelines" Pulmonaires. Interstitial lung disease in amyopathic dermatomyositis, dermatomyositis and polymyositis. *The European Respiratory Journal*. 2003;**22**:245-250
- [104] Devaraj A, Wells AU, Hansell DM. Computed tomographic imaging in connective tissue diseases. *Seminars in Respiratory and Critical Care Medicine*. 2007;**28**:389-397
- [105] Ikezoe J, Johkoh T, Kohno N, Takeuchi N, Ichikado K, Nakamura H. High-resolution CT findings of lung disease in patients with polymyositis and dermatomyositis. *Journal of Thoracic Imaging*. 1996;**11**:250-259
- [106] Mino M, Noma S, Taguchi Y, Tomii K, Kohri Y, Oida K. Pulmonary involvement in polymyositis and dermatomyositis: Sequential evaluation with CT. *American Journal of Roentgenology*. 1997;**169**:83-87
- [107] Akira M, Hara H, Sakatani M. Interstitial lung disease in association with polymyositis/dermatomyositis: Long-term follow-up CT evaluation in seven patients. *Radiology*. 1999;**210**:333-338
- [108] Arakawa H, Yamada H, Kurihara Y, Nakajima Y, Takeda A, Fukushima Y, Fujioka M. Nonspecific interstitial pneumonia associated with polymyositis and dermatomyositis: Serial high-resolution CT findings and functional correlation. *Chest*. 2003;**123**(4):1096-1103. DOI: 10.1378/chest.123.4.1096

- [109] Euwer RL, Sontheimer RD. Amyopathic dermatomyositis: A review. *The Journal of Investigative Dermatology*. 1993;**100**(1):124S-127S
- [110] Sontheimer RD. Would a new name hasten the acceptance of amyopathic dermatomyositis (dermatomyositis sine myositis) as a distinctive subset within the idiopathic inflammatory dermatomyopathies spectrum of clinical illness? *Journal of the American Academy of Dermatology*. 2002;**46**:626-636
- [111] Suda T, Fujisawa T, Enomoto N, et al. Interstitial lung diseases associated with amyopathic dermatomyositis. *The European Respiratory Journal*. 2006;**28**(5):1005-1012
- [112] Ye S, Chen XX, Lu XY, et al. Adult clinically amyopathic dermatomyositis with rapid progressive interstitial lung disease: A retrospective cohort study. *Clinical Rheumatology*. 2007;**26**(10):1647-1654
- [113] Sato S, Hirakata M, Kuwana M, et al. Autoantibodies to a 140-kd polypeptide, CADM-140, in Japanese patients with clinically amyopathic dermatomyositis. *Arthritis and Rheumatism*. 2005;**52**(5):1571-1576
- [114] Targoff IN. Immune manifestations of inflammatory muscle disease. *Rheumatic Diseases Clinics of North America*. 1994;**20**(4):857-880
- [115] Yoshifuji H, Fujii T, Kobayashi S, Imura Y, Fujita Y, Kawabata D, Usui T, Tanaka M, Nagai S, Umehara H, Mimori T. Anti-aminoacyl-tRNA synthetase antibodies in clinical course prediction of interstitial lung disease complicated with idiopathic inflammatory myopathies. *Autoimmunity*. 2006;**39**(3):233-241
- [116] Nishikai M, Reichlin M. Heterogeneity of precipitating antibodies in polymyositis and dermatomyositis. Characterization of the Jo-1 antibody system. *Arthritis and Rheumatism*. 1980;**23**(8):881-888
- [117] Yoshida S, Akizuki M, Mimori T, et al. The precipitating antibody to an acidic nuclear protein antigen, the Jo-1, in connective tissue diseases. A marker for a subset of polymyositis with interstitial pulmonary fibrosis. *Arthritis and Rheumatism*. 1983;**26**:604-611
- [118] Reeves WH, Nigam SK, Blobel G. Human autoantibodies reactive with the signal-recognition particle. *Proceedings of the National Academy of Sciences of the United States of America*. 1986;**83**(24):9507-9511
- [119] Okada N, Mimori T, Mukai R, Kashiwagi H, Hardin JA. Characterization of human autoantibodies that selectively precipitate the 7SL RNA component of the signal recognition particle. *Journal of Immunology*. 1987;**138**(10):3219-3223
- [120] Targoff IN, Reichlin M. The association between Mi-2 antibodies and dermatomyositis. *Arthritis and Rheumatism*. 1985;**28**(7):796-803
- [121] Nakashima R, Imura Y, Kobayashi S, et al. The RIG-I-like receptor IFIH1/MDA5 is a dermatomyositis-specific autoantigen identified by the anti-CADM-140 antibody. *Rheumatology (Oxford)*. 2010;**49**(3):433-440

- [122] Sato S, Hoshino K, Satoh T, Fujita T, Kawakami Y, Kuwana M. RNA helicase encoded by melanoma differentiation associated gene 5 is a major autoantigen in patients with clinically amyopathic dermatomyositis: Association with rapidly progressive interstitial lung disease. *Arthritis and Rheumatism*. 2009;**60**(7):2193-2200
- [123] Targoff IN, Mamyrova G, Trieu EP, et al. Childhood Myositis Heterogeneity Study Group; International Myositis Collaborative Study Group. A novel autoantibody to a 155-kd protein is associated with dermatomyositis. *Arthritis and Rheumatism*. 2006;**54**(11):3682-3689
- [124] Kaji K, Fujimoto M, Hasegawa M, et al. Identification of a novel autoantibody reactive with 155 and 140 kDa nuclear proteins in patients with dermatomyositis: An association with malignancy. *Rheumatology (Oxford)*. 2007;**46**(1):25-28
- [125] Genth E, Mierau R, Genetzky P, et al. Immunogenetic associations of scleroderma related antinuclear antibodies. *Arthritis and Rheumatism*. 1990;**33**(5):657-665
- [126] Kuwana M, Okano Y, Kaburaki J, Tojo T, Medsger TA Jr. Racial differences in the distribution of systemic sclerosis-related serum antinuclear antibodies. *Arthritis and Rheumatism* 1994;**37**(6): 902-906.
- [127] Betteridge ZE, Gunawardena H, Chinoy H, et al. UK Adult Onset Myositis Immunogenetic Collaboration. Clinical and human leucocyte antigen class II haplotype associations of autoantibodies to small ubiquitin-like modifier enzyme, a dermatomyositis-specific autoantigen target, in UK Caucasian adult-onset myositis. *Annals of the Rheumatic Diseases*. 2009;**68**(10):1621-1625
- [128] Nakashima R, Mimori T. Clinical and pathophysiological significance of myositis-specific and myositis-associated autoantibodies. *International Journal of Clinical Rheumatology*. 2010;**5**(5):523-536
- [129] Sato S, Kuwana M. Utility of dermatomyositis-specific autoantibodies for diagnosis and clinical subsetting. *International Journal of Clinical Rheumatology*. 2015;**10**:257-271. DOI: 10.2217/ijr.15.27
- [130] Hozumi H, Fujisawa T, Nakashima R, Johkoh T, Sumikawa H, Murakami A, Enomoto N, Inui N, Nakamura Y, Hosono Y, Imura Y, Mimori T, Suda T. Comprehensive assessment of myositis-specific interstitial lung disease. *Respiratory Medicine*. 2016;**121**:91-99
- [131] Satoh M, Tanaka S, Ceribelli A, Calise SJ, Chan EK. A comprehensive overview on myositis-specific antibodies: New and old biomarkers in idiopathic inflammatory myopathy. *Clinical Reviews in Allergy & Immunology*. 2017;**52**:1-19
- [132] Abraham DJ, Krieg T, Distler J, Distler O. Overview of pathogenesis of systemic sclerosis. *Rheumatology (Oxford)*. 2009;**48**(Suppl. 3):iii3-iii7. DOI: 10.1093/rheumatology/ken481 (published online: May 28, 2009)
- [133] Wells AU, Denton CP. Interstitial lung disease in connective tissue disease – mechanisms and management. *Nature Reviews Rheumatology*. 2014;**10**:728-739. DOI: 10.1038/nrrheum.2014.149

- [134] Denton CP. Therapeutic targets in systemic sclerosis. *Arthritis Research & Therapy*. 2007;9(Suppl. 2):S6. DOI: 10.1186/ar2190
- [135] Kim KK, Kugler MC, Wolters PJ, et al. Alveolar epithelial cell mesenchymal transition develops in vivo during pulmonary fibrosis and is regulated by the extracellular matrix. *Proceedings of the National Academy of Sciences of the United States of America*. 2006;103:13180-13185
- [136] Jain R, Shaul PW, Borok Z, Willis BC. Endothelin-1 induces alveolar epithelial mesenchymal transition through endothelin type A receptor-mediated production of TGF-beta 1. *American Journal of Respiratory Cell and Molecular Biology*. 2007;37:38-47
- [137] Mauviel A. Transforming growth factor-beta: A key mediator of fibrosis. *Methods in Molecular Medicine*. 2005;117:69-80
- [138] Varga J, Abraham D. Systemic sclerosis: A prototypic multisystem fibrotic disorder. *The Journal of Clinical Investigation*. 2007;117:557-567
- [139] Clozel M, Salloukh H. Role of endothelin in fibrosis and anti-fibrotic potential of bosentan. *Annals of Medicine*. 2005;37:2-12
- [140] Abraham DJ, Vancheeswaran R, Dashwood MR, et al. Increased levels of endothelin-1 and differential endothelin type A and B receptor expression in scleroderma-associated fibrotic lung disease. *The American Journal of Pathology*. 1997;151:831-841
- [141] Tager AM, LaCamera P, Shea BS, Campanella GS, Selman M, Zhao Z, Polosukhin V, Wain J, Karimi-Shah BA, Kim ND, Hart WK, Pardo A, Blackwell TS, Xu Y, Chun J, Luster AD. The lysophosphatidic acid receptor LPA1 links pulmonary fibrosis to lung injury by mediating fibroblast recruitment and vascular leak. *Nature Medicine*. 2008;14:45-54
- [142] Hamaguchi Y, Fujimoto M, Matsushita T, Hasegawa M, Takehara K, Sato S. Elevated serum insulin-like growth factor (IGF-1) and IGF binding protein-3 levels in patients with systemic sclerosis: Possible role in development of fibrosis. *The Journal of Rheumatology*. 2008;35:2363-2371
- [143] Perbal B. CCN proteins: Multifunctional signaling regulators. *Lancet*. 2004;363:62-64
- [144] Ponticos M, Holmes AM, Shi-wen X, Leoni P, Khan K, Rajkumar VS, Hoyles RK, Bou-Gharios G, Black CM, Denton CP, Abraham DJ, Leask A, Lindahl GE. Pivotal role of connective tissue growth factor in lung fibrosis: MAPK dependent transcriptional activation of type I collagen. *Arthritis and Rheumatism*. 2009;60:2142-2155
- [145] Hoyles RK, et al. Fibroblast-specific perturbation of transforming growth factor β signaling provides insight into potential pathogenic mechanisms of scleroderma-associated lung fibrosis: Exaggerated response to alveolar epithelial injury in a novel mouse model. *Arthritis and Rheumatism*. 2008;58:1175-1188
- [146] Christmann RB, Wells AU, Capelozzi VL, Silver RM. Gastroesophageal reflux incites interstitial lung disease in systemic sclerosis: Clinical, radiologic, histopathologic, and treatment evidence. *Seminars in Arthritis and Rheumatism*. 2010;40:241-249

- [147] Walker N, et al. Resident tissue-specific mesenchymal progenitor cells contribute to fibrogenesis in human lung allografts. *The American Journal of Pathology*. 2011; **178**:2461-2469
- [148] Hoyles RK, et al. An essential role for resident fibroblasts in experimental lung fibrosis is defined by lineage-specific deletion of high-affinity type II transforming growth factor β receptor. *American Journal of Respiratory and Critical Care Medicine*. 2011; **183**:249-261
- [149] Borie R, et al. Detection of alveolar fibrocytes in idiopathic pulmonary fibrosis and systemic sclerosis. *PLoS One*. 2013; **8**:e53736. DOI: 10.1371/journal.pone.0053736 (published online: Jan 16, 2013)
- [150] Nihtyanova SI, et al. Prediction of pulmonary complications and long-term survival in systemic sclerosis. *Arthritis & Rheumatology*. 2014; **66**:1625-1635
- [151] Wynn TA. Fibrotic disease and the TH1/TH2 paradigm. *Nature Reviews. Immunology*. 2004; **4**:583-594
- [152] Wells AU, Lorimer S, Majumdar S, Harrison NK, Corrin B, Black CM, et al. Fibrosing alveolitis in systemic sclerosis: Increase in memory T-cells in lung interstitium. *The European Respiratory Journal*. 1995; **8**:266-271
- [153] Yurovsky VY, Wigley FM, Wise RA, White B. Skewing of the CD8-T cell repertoire in the lungs of systemic sclerosis patients. *Human Immunology*. 1996; **48**:84-97
- [154] Atamas SP, Yurovsky VV, Wise R, Wigley FM, Goter Robinson CJ, Henry P, et al. Production of type 2 cytokines by CD8+ lung cells is associated with greater decline in pulmonary function in patients with systemic sclerosis. *Arthritis and Rheumatism*. 1999; **42**:1168-1178
- [155] Yamadori I, Fujita J, Kajitani H, Bando S, Tokuda M, Yang Y, et al. Lymphocyte subsets in lung tissues of non-specific interstitial pneumonia and pulmonary fibrosis associated with collagen vascular disorders: Correlation with CD4/CD8 ratio in bronchoalveolar lavage. *Lung*. 2000; **178**:361-370
- [156] Luzina IG, Atamas SP, Wise R, Wigley FM, et al. Occurrence of an activated, profibrotic pattern of gene expression in lung CD8+ T cells from scleroderma patients. *Arthritis and Rheumatism*. 2003; **48**:2262-2274
- [157] Radstake TR, van Bon L, Broen J, et al. Increased frequency and compromised function of T regulatory cells in systemic sclerosis (SSc) is related to a diminished CD69 and TGFbeta expression. *PLoS One* 2009; **4**(6): e5981–e5992. DOI: 10.1371/journal.pone.0005981
- [158] Kolahian S, Fernandez IE, Eickelberg O, Hartl D. Immune mechanisms in pulmonary fibrosis. *American Journal of Respiratory Cell and Molecular Biology*. 2016; **55**:309-322
- [159] Matsutani T, Yoshioka T, Tsuruta Y, et al. Analysis of TCRAV and TCRBV repertoires in healthy individuals by microplate hybridization assay. *Human Immunology*. 1997; **56**:57-69

- [160] Hirokawa M, Matsutani T, Saitoh H, et al. Distinct TCRAV and TCRBV repertoire and CDR3 sequence of T lymphocytes clonally expanded in blood and GVHD lesions after human allogeneic bone marrow transplantation. *Bone Marrow Transplantation*. 2002;**30**:915-923
- [161] Matsutani T, Ohashi Y, Yoshioka T, et al. Skew in T-cell receptor usage and clonal T-cell expansion in patients with chronic rejection of transplanted kidneys. *Transplantation*. 2003;**75**:398-407
- [162] Lehmann PV, Sercarz EE, Forsthuber T, et al. Determinant spreading and the dynamics of the autoimmune T-cell repertoire. *Immunology Today*. 1993;**14**:203-208
- [163] Englund P, Wahlstrom J, Fathi M, et al. Restricted T cell receptor BV gene usage in the lungs and muscles of patients with idiopathic inflammatory myopathies. *Arthritis and Rheumatism*. 2007;**56**:372-383
- [164] Wucherpfennig KW, Ota K, Endo N, et al. Shared human T cell receptor V β usage to immunodominant regions of myelin basic protein. *Science*. 1990;**248**:1016-1019
- [165] Kaushansky N, Kerlero de Rosbo N, Zilkha-Falb R, et al. Multi-epitope-targeted immune-specific therapy for a multiple sclerosis-like disease via engineered multi-epitope protein is superior to peptides. *PLoS One*. 2011;**6**:e27860. DOI: 10.1371/journal.pone.0027860 (published online: Nov 29, 2011)
- [166] Rosas IO, Kaminski N. Update in diffuse parenchymal lung disease 2013. *American Journal of Respiratory and Critical Care Medicine*. 2015;**191**:270-274. DOI: 10.1164/rccm.201405-0856UP
- [167] Haubitz M, Schellong S, Gobel U, Schurek HJ, Schaumann D, Koch KM, et al. Intravenous pulse administration of cyclophosphamide versus daily oral treatment in patients with antineutrophil cytoplasmic antibody-associated vasculitis and renal involvement: A prospective, randomized study. *Arthritis and Rheumatism*. 1998;**41**:1835-1844
- [168] Tashkin DP, Elashoff R, Clements PJ, Roth MD, Furst DE, Silver RM, et al. Scleroderma Lung Study Research Group. Effects of 1-year treatment with cyclophosphamide on outcomes at 2 years in scleroderma lung disease. *American Journal of Respiratory and Critical Care Medicine*. 2007;**176**:1026-1034
- [169] Poormoghim H, Moradi Lakeh M, et al. Cyclophosphamide for scleroderma lung disease: A systematic review and meta-analysis. *Rheumatology International*. 2012;**32**:2431-2444
- [170] Giacomelli R, Liakouli V, Berardicurti O, Ruscitti P, Di Benedetto P, Carubbi F, Guggino G, Di Bartolomeo S, Ciccia F, Triolo G, Cipriani P. Interstitial lung disease in systemic sclerosis: Current and future treatment. *Rheumatology International*. 2017;**37**:853-863. DOI: 10.1007/s00296-016-3636-7
- [171] Sem M, Molberg O, Lund MB, Gran JT. Rituximab treatment of the anti-synthetase syndrome: A retrospective case series. *Rheumatology (Oxford)*. 2009;**48**:968-971

- [172] Oddis CV, Reed AM, Aggarwal R, et al. RIM Study Group. Rituximab in the treatment of refractory adult and juvenile dermatomyositis and adult polymyositis: A randomized, placebo-phase trial. *Arthritis and Rheumatism*. 2013;**65**:314-324. DOI: 10.1002/art.37754
- [173] Gruhn WB, Diaz-Buxo JA. Cyclosporine treatment of steroid resistant interstitial pneumonitis associated with dermatomyositis/polymyositis. *The Journal of Rheumatology*. 1987;**14**:1045-1047
- [174] Maeda K, Kimura R, Komuta K, Igarashi T. Cyclosporine treatment for polymyositis/dermatomyositis: Is it possible to rescue the deteriorating cases with interstitial pneumonitis? *Scandinavian Journal of Rheumatology*. 1997;**26**(1):24-29
- [175] Nawata Y, Kurasawa K, Takabayashi K, Miike S, Watanabe N, Hiraguri M, Kita Y, Kawai M, Saito Y, Iwamoto I. Corticosteroid resistant interstitial pneumonitis in dermatomyositis/polymyositis: Prediction and treatment with cyclosporine. *The Journal of Rheumatology*. 1999;**26**(7):1527-1533
- [176] Harigai M, Hara M, Kamatani N, Kashiwazaki S. Nation-wide survey for the treatment with cyclosporin A of interstitial pneumonia associated with collagen diseases. *Ryūmachi*. 1999;**39**:819-828
- [177] Nagasaka K, Harigai M, Tateishi M, Hara M, Yoshizawa Y, Koike T, Miyasaka N. Efficacy of combination treatment with cyclosporin A and corticosteroids for acute interstitial pneumonitis associated with dermatomyositis. *Modern Rheumatology*. 2003;**13**:231-238
- [178] Takada K, Nagasaka K, Miyasaka N. Polymyositis/dermatomyositis and interstitial lung disease: A new therapeutic approach with T-cell-specific immunosuppressants. *Autoimmunity*. 2005;**38**(5):383-392
- [179] Koreeda Y, Higashimoto I, Yamamoto M, Takahashi M, Kaji K, Fujimoto M, Kuwana M, Fukuda Y. Clinical and pathological findings of interstitial lung disease patients with anti-aminoacyl-t RNA synthetase autoantibodies. *Internal Medicine*. 2010;**49**(5):361-369
- [180] Cavagna L, Caporali R, Abdi-Ali L, Dore R, Meloni F, Montecucco C. Cyclosporine in anti-Jo1-positive patients with corticosteroid-refractory interstitial lung disease. *The Journal of Rheumatology*. 2013;**40**:484-492
- [181] Nagai K, Takeuchi T, Kotani T, Hata K, Yoshida S, Isoda K, Fujiki Y, Shiba H, Makino S, Hanafusa T. Therapeutic drug monitoring of cyclosporine microemulsion in interstitial pneumonia with dermatomyositis. *Modern Rheumatology*. 2011;**21**(1):32-36
- [182] Oddis CV, Sciruba FC, Elmagd KA, Starzl TE. Tacrolimus in refractory polymyositis with interstitial lung disease. *Lancet*. 1999;**353**(9166):1762-1763
- [183] Ochi S, Nanki T, Takada K, Suzuki F, Komano Y, Kubota T, Miyasaka N. Favorable outcomes with tacrolimus in two patients with refractory interstitial lung disease associated with polymyositis/dermatomyositis. *Clinical and Experimental Rheumatology*. 2005;**23**:707-710

- [184] Wilkes MR, Sereika SM, Fertig N, Lucas MR, Oddis CV. Treatment of antisynthetase-associated interstitial lung disease with tacrolimus. *Arthritis and Rheumatism*. 2005; **52**(8):2439-2446
- [185] Kurita T, Yasuda S, Oba K, Odani T, Kono M, Otomo K, Fujieda Y, Oku K, Bohgaki T, Amengual O, Horita T, Atsumi T. The efficacy of tacrolimus in patients with interstitial lung diseases complicated with polymyositis or dermatomyositis. *Rheumatology (Oxford)*. 2015;**54**(1):39-44. DOI: 10.1093/rheumatology/keu166
- [186] Kurita T, Yasuda S, Amengual O, Atsumi T. The efficacy of calcineurin inhibitors for the treatment of interstitial lung disease associated with polymyositis/dermatomyositis. *Lupus*. 2015;**24**:3-9. DOI: 10.1177/0961203314554849
- [187] Suda M, Kataoka Y, Tomishima Y, Jinta T, Rokutanda R, Kishimoto M, Okada M. Effectiveness of multi-target therapy in anti-melanoma differentiation-associated gene 5 antibody-positive dermatomyositis with early-stage interstitial lung disease. *Scandinavian Journal of Rheumatology*. Jun 26, 2017:1-2. DOI: 10.1080/03009742.2017.1314004 (published online: Jun 26, 2017)
- [188] Ishikawa H. Mizoribine and mycophenolate mofetil. *Current Medicinal Chemistry*. 1999;**6**:575-597
- [189] Rokutanda R, Kishimoto M, Ohde S, Shimizu H, Nomura A, Suyama Y, Ohara Y, Yamaguchi K, Okada M. Safety and efficacy of mizoribine in patients with connective tissue diseases other than rheumatoid arthritis. *Rheumatology International*. 2014; **34**:59-62
- [190] Nomura A, Shimizu H, Kishimoto M, Suyama Y, Rokutanda R, Ohara Y, Yamaguchi K, Okada M. Efficacy and safety of multitarget therapy with mizoribine and tacrolimus for systemic lupus erythematosus with or without active nephritis. *Lupus*. 2012; **21**:1444-1449

IntechOpen

