

We are IntechOpen, the world's leading publisher of Open Access books Built by scientists, for scientists

4,800

Open access books available

122,000

International authors and editors

135M

Downloads

Our authors are among the

154

Countries delivered to

TOP 1%

most cited scientists

12.2%

Contributors from top 500 universities



WEB OF SCIENCE™

Selection of our books indexed in the Book Citation Index
in Web of Science™ Core Collection (BKCI)

Interested in publishing with us?
Contact book.department@intechopen.com

Numbers displayed above are based on latest data collected.
For more information visit www.intechopen.com



Traumatic Axonal Injury in Patients with Mild Traumatic Brain Injury

Sung Ho Jang

Additional information is available at the end of the chapter

<http://dx.doi.org/10.5772/intechopen.70988>

Abstract

Mild traumatic brain injury (TBI) is a subtype of TBI that is classified by the severity of head trauma, whereas traumatic axonal injury (TAI) is a diagnostic term with a pathological meaning. In this chapter, TAI in patients with mild TBI is described in terms of definition, history, and diagnostic approach. The presence of TAI in patients with mild TBI has been demonstrated by autopsy studies since the 1960s. However, because conventional brain CT or MRI are not powered with contrast resolution to determine TAI in mild TBI, diagnosis of TAI in live patients with mild TBI was impossible. Since the introduction of diffusion tensor imaging, hundreds of studies have demonstrated TAI in live patients with mild TBI in the 2000s. The precise diagnosis of TAI in patients with mild TBI is clinically important for proper management and prognosis prediction following mild TBI. Several requirements are necessary for diagnosis of TAI in mild TBI: first, head trauma history; second, development of new clinical symptoms and signs after head trauma; third, evidence of TAI of the neural tracts on diffusion tensor imaging or diffusion tensor tractography; and fourth, coincidence of the newly developed clinical features and the function of injured neural tracts.

Keywords: diffusion tensor imaging, diffusion tensor tractography, mild traumatic brain injury, traumatic axonal injury, concussion

1. Introduction

Traumatic brain injury (TBI) is a major cause of disability in adults, and is classified as mild, moderate, and severe according to the severity of head trauma [1]. Mild TBI poses a significant public health problem: it composes 70–90% of all TBI [1–4]. The incidence of hospital-treated patients with mild TBI is 100–300/100,000 population although the true population-based rate including mild TBI not treated in hospitals is estimated above 600/100,000 [1–4]. Mild TBI

Pathoanatomy			
Diffuse		Focal	
Concussion		Contusion	
Traumatic axonal injury/diffuse axonal injury		Penetrating	
Blast		Hematoma	
Abusive head trauma		<ul style="list-style-type: none"> - Epidural - Subarachnoid - Subdural - Intraventricular - Intracerebral 	
Severity of head trauma	Loss of consciousness	Post-traumatic amnesia	Glasgow Coma Scale
Mild	≤30 min	≤24 hours	13–15
Moderate	>30 min, ≤24 hours	>24 hours, ≤7 days	9–12
Severe	> 24 hours	>7 days	3–8

Table 1. Traumatic brain injury subtypes.

and concussion (a transient disorder of brain function without long-term sequelae) have been used interchangeably, although the two terms have different definitions and belong to different subtypes of TBI (**Table 1**) [5–7].

Since the 1980s, the term “traumatic axonal injury (TAI)” that describes impaired axoplasmic transports, axonal swelling and disconnection after the head trauma, including mild TBI, has been used in pathological studies using animal brain [8–11]. Since the 1960s, pathological studies using autopsy reported axonal injury in patients with mild TBI or concussion [12–14]. However, because conventional brain CT or MRI are not powered with contrast resolution to determine TAI in mild TBI, diagnosis of TAI in live patients with mild TBI was impossible for a long time. Since the development of diffusion tensor imaging (DTI) in the 2000s, many researchers demonstrated TAI in live patients with mild TBI [15–85]. Because mild TBI and TAI are different TBI subtypes, the precise diagnosis of TAI in patients with mild TBI is clinically important for proper management and prognosis prediction (**Table 1**) [6, 7].

In this chapter, TAI in patients with mild TBI is described in terms of definition, history, and diagnostic approach.

2. Traumatic axonal injury in patients with mild traumatic axonal injury

2.1. Definition and problem of the term “mild traumatic brain injury”

The American Congress of Rehabilitation Medicine in 1993 defined mild TBI as a traumatically induced physiological disruption of brain function resulting from the head being struck or

striking an object, or an acceleration and deceleration movement of the brain, as manifested by at least one of the following: any period of loss of consciousness up to 30 min, post-traumatic amnesia not exceeding 24 hours, and an initial Glasgow Coma Scale score of 13–15 [86–89]. Blast may also cause mild TBI [90].

Opinions critical of the use of the term “mild TBI,” as indicating a benign condition, have been expressed [5, 91, 92]. In 2012, Rapp et al. insisted that mild TBI is a category mistake because of the heterogeneity of the clinical population and features, and the complex idiosyncratic time course of the appearance of these deficits in patients with mild TBI [92]. Subsequently, McMahon et al. reported that the term “mild TBI” is a misnomer because some of the patients with mild TBI show severe neurological sequelae [91]. In 2015, Sharp and Jenkins insisted that mild TBI is not always a benign condition as its name implies and patients with mild TBI sometimes fail to recover [5]. These critical opinions appear to stem from the observations of concurrent TAI in patients with mild TBI that cannot be detected on conventional brain CT or MRI. Such lesions have been described by hundreds of DTI studies since the 2000s [15–85].

2.2. Definition and diagnostic history of traumatic axonal injury in mild TBI

Neural axons in the white matter are particularly vulnerable to diffuse head trauma due to mechanical loading of the brain during TBI [8, 93]. TAI, a pathological term, is defined as tearing of axons due to indirect shearing forces during acceleration, deceleration, and rotation of the brain, or direct head trauma [6, 9, 10, 15–23, 94, 95].

Since the 1980s, many researchers, including Povlishock, have used the term “TAI” in their pathological studies using animal brain [8–11]. In the human brain, several studies have demonstrated trauma-related axonal injury in pathological autopsy studies of patients who died of other causes following TBI, including concussion or mild TBI, since the middle of the last century [12–14, 96]. However, due to insensitivity of conventional brain MRI for detection of TAI in mild TBI, diagnosis of TAI in live patients with mild TBI was impossible for a long time. In the 1990s, the development of DTI opened a new era for diagnosis of the subcortical white matter pathology in the live human brain. Because DTI provides invaluable information about subcortical white matter that cannot be obtained by conventional MRI, DTI was initially used to detect white matter pathology undetectable by conventional CT or MRI in brain pathologies such as cerebral palsy, hypoxic-ischemic brain injury, and congenital brain disease [97–99]. Since Arfanakis’s study in 2002, TAI has been demonstrated in hundreds of DTI studies in mild TBI [15–85]. As a result, DTI become an important diagnostic tool for TAI in patients with mild TBI, particularly in patients whose conventional brain CT or MRI is negative.

The history of the use of term TAI with regard to the term “diffuse axonal injury (DAI)” has given rise to some confusion [6]. Adams et al. began to use the term “DAI” by defining DAI as the presence of microscopic axonal injury in the white matter of the cerebral hemisphere, corpus callosum, and brainstem caused by mechanical forces during head injury [100–102]. After that, instead of DAI, “TAI” or “diffuse TAI” was used to correct the mistaken term “diffuse” (because the distribution of the lesions of axonal injury is not diffuse but multifocal), and to include the meaning of trauma in terms of the etiology of axonal injury [6–8, 93]. Generally, the traditional definition of DAI indicates patients in profound and prolonged coma at the onset of

head trauma, and who suffer a poor outcome [6–8, 93, 102, 103]. Because more restricted patterns of axonal injury than the traditional DAI were detected in milder TBI with the development of DTI, the term “TAI” is used for these more limited injuries: in practice, TAI indicates milder injury than DAI [6–8, 93, 98, 103].

2.3. Comparison of diffusion tensor imaging and diffusion tensor tractography in detecting TAI in mild TBI

The left corticospinal tract shows partial tearing (arrow) at the subcortical white matter. When a researcher measures diffusion tensor imaging parameters using the region of interest (ROI) method, if the ROI is placed in the partially torn area (B), traumatic axonal injury of the left corticospinal tract can be detected, whereas if the ROI is placed in the normal-appearing area (D), traumatic axonal injury of the left corticospinal tract cannot be detected.

Two methods are used to detect TAI in mild TBI: (1) region of interest (ROI) method: measurement of DTI parameters in a certain ROI of the brain, and (2) diffusion tensor tractography (DTT) for the neural tracts (**Figure 1**). DTT allows for visualization and estimation of the neural tracts three dimensionally by reconstruction from DTI data: measurement of DTT parameters and configurational analysis of the reconstructed neural tracts [19, 20, 24–56, 61, 72, 98]. Many more studies have used the ROI method than DTT; however, this method can yield false results for the following reasons. First, high individual variability of the anatomical location of the neural tracts in the human brain can lead to measurement of DTI parameters in a false location for the target neural tract, especially in compact areas such as the corona radiata, posterior limb of the internal capsule, or brainstem [104]. In addition, the results can differ depending on whether a ROI is placed in a TAI lesion (for example, a partially torn area) or normal-appearing area. For example, when a neural tract was partially torn by TAI following mild TBI, if the ROI was placed in the normal-appearing area, TAI cannot be detected using the ROI method although this patient had TAI following mild TBI (**Figure 1**). Second, high interanalyzer variability of the ROI method can lead to false results [105].

By contrast, DTT for reconstruction of the neural tracts usually employs a combined ROI method that reconstructs only neural fibers passing more than two ROI areas. The ROI areas and reconstruction conditions for the neural tracts are well defined for each neural tract [6, 50, 106–113]. High repeatability and reliability of DTT method for the neural tracts have been demonstrated in many studies [6, 24, 50, 106–111, 113]. Therefore, experienced analyzers can reconstruct the neural tracts without significant inter- and intra-analyzer variation. The main advantage of DTT over DTI is that the entire neural tract can be evaluated in terms of DTT parameters, including fractional anisotropy, mean diffusivity and tract volume, and configurational analysis. Fractional anisotropy value indicates the degree of directionality of microstructures, such as axons, myelin, and microtubules, while mean diffusivity value suggests the magnitude of water diffusion [114]. Tract volume is determined by counting the number of voxels contained within a neural tract [114]. Therefore, a significant decrement of fractional anisotropy or tract volume, or increment of mean diffusivity compared with normal subjects, indicates injury of a neural tract. In addition, on configuration analysis of the

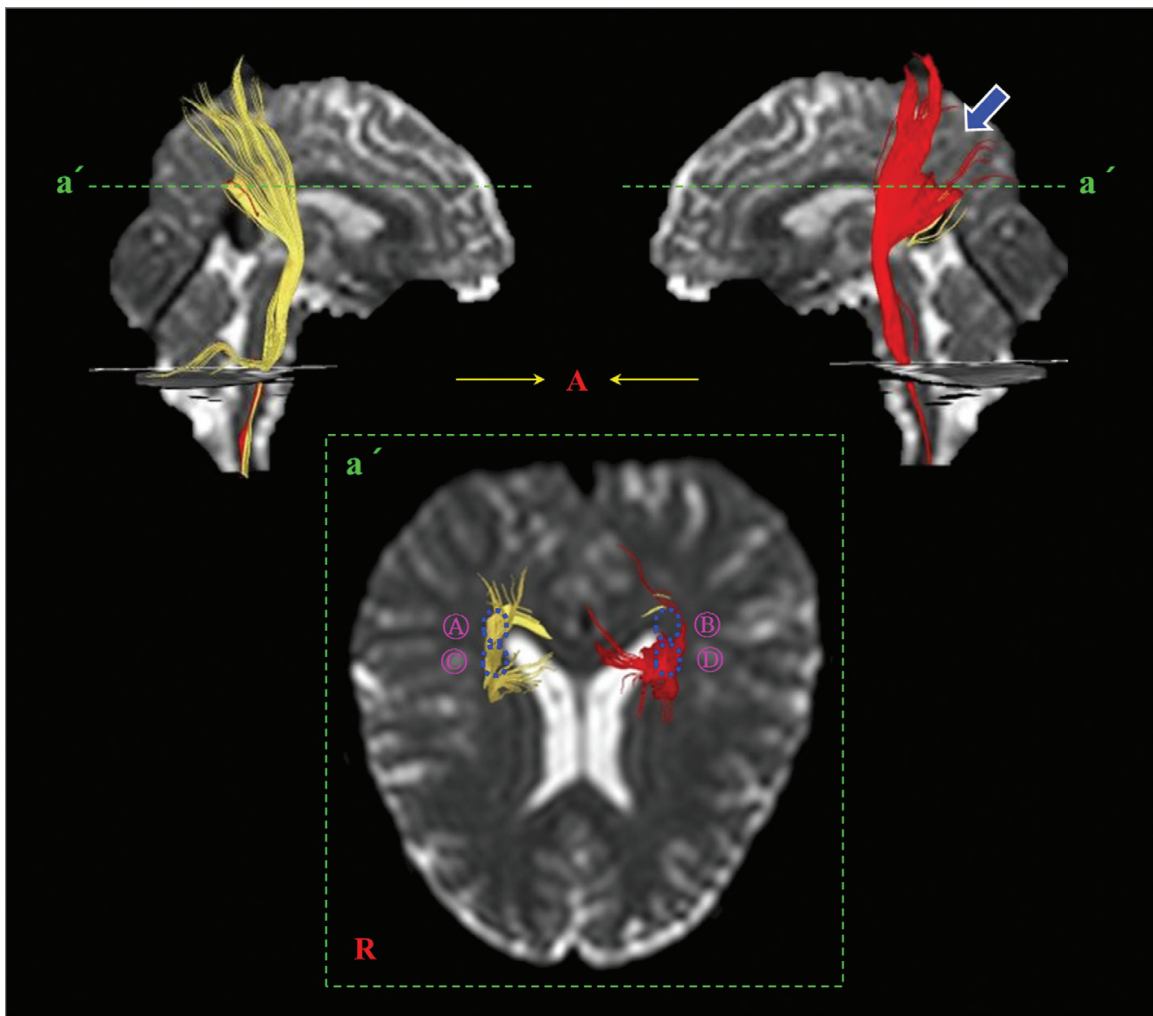


Figure 1. Possible false measurement of diffusion tensor imaging parameters in a partially torn corticospinal tract in a patient with mild traumatic brain injury.

reconstructed neural tracts, abnormal findings including tearing, narrowing, or discontinuation have been used to detect TAI of the neural tracts in patients with mild TBI (**Figure 2**) [19, 20, 24, 26–37, 39–56]. As a result, DTT would be better than DTI to detect TAI in a neural tract in an individual patient. More than 30 papers have demonstrated TAI in individual patients with mild TBI in the corticospinal tract, corticoreticulospinal tract, spinothalamic tract, fornix, cingulum, optic radiation, ascending reticular activating system, papez circuit, pre-fronto-thalamic tracts, inferior cerebellar peduncle, corticofugal tracts from the secondary motor area, arcuate fasciculus, corticobulbar tract, and dentatorubrothalamic tract [19, 20, 24, 26–37, 39–56]. However, DTT may underestimate the neural tracts due to regions of fiber complexity and crossing that can prevent full reflection of the underlying fiber architecture [105, 115, 116]. In addition, TAI on DTT often cannot be discriminated from abnormalities by previous head trauma, other concurrent neurological diseases, aging, or immaturity, although some findings suggest characteristic features of TAI in several neural tracts [26, 28, 29, 39, 48, 51–54].

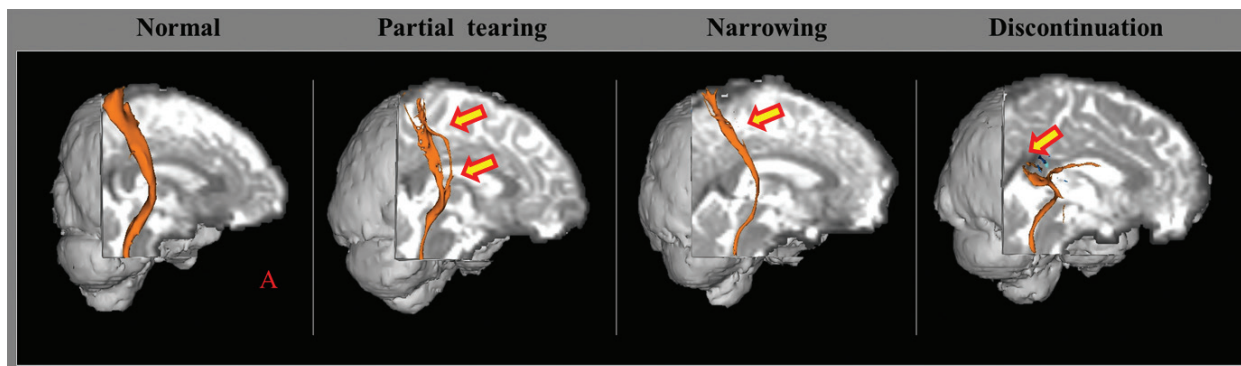
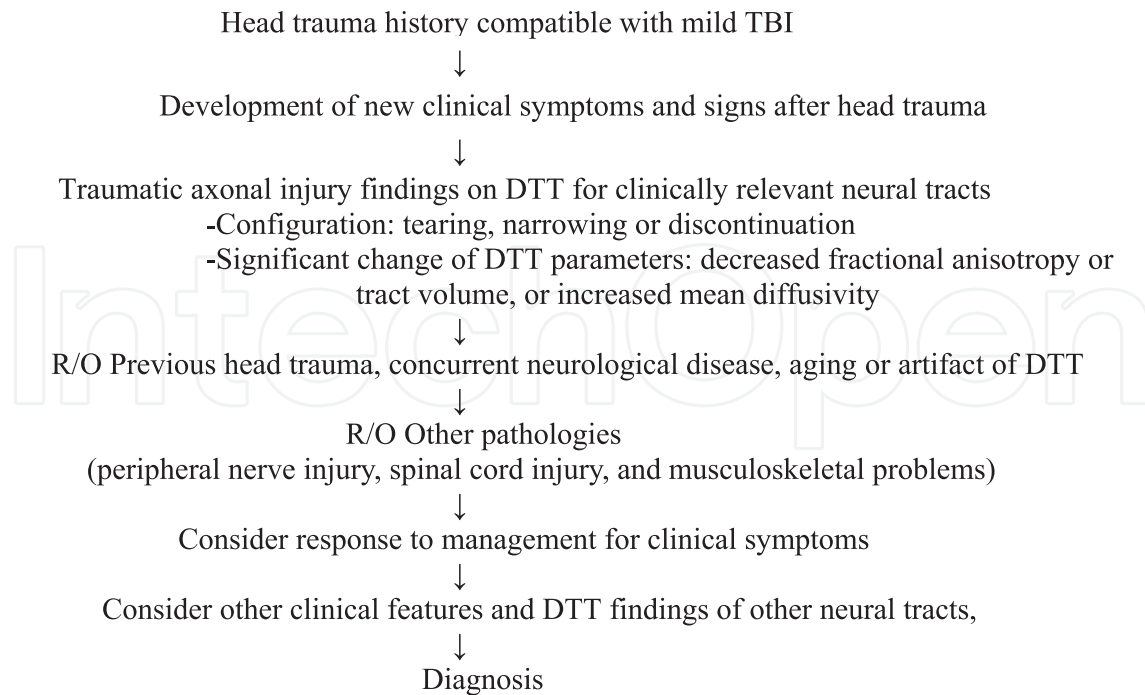


Figure 2. Configurational analysis of the spinothalamic tract in patients with mild traumatic brain injury.

2.4. Diagnostic approach of traumatic axonal injury in patients with mild TBI

TAI is a diagnostic term with a pathological meaning; therefore, pathological study by brain biopsy is required to confirm TAI of a neural tract in patients with mild TBI. However, performing brain biopsy for an injured neural tract in patients with mild TBI is impossible because mild TBI is not a life-threatening disease like, for example, brain tumor. The sensitivity and specificity of DTT for diagnosis of TAI of a neural tract in patients with mild TBI can be calculated only through direct comparison of DTT findings of an injured tract with the pathological results of brain tissue, if we accept the latter as the diagnostic “gold standard.” As a result, precise demonstration of sensitivity and specificity of DTT for diagnosis of TAI of an injured neural tract in live patients with mild TBI is impossible. However, in 2007, Mac Donald et al. demonstrated that TAI on pathological and DTI results agree in a mouse model of mild TBI that showed normal findings on conventional MRI [117]. They concluded that DTI is highly sensitive for detection of TAI and conventional MRI is not as sensitive as DTI for axonal injury [117].

There are more than 30 recent papers that reported TAI in individual patients with mild TBI using DTT [19, 20, 24, 26–37, 39–56]. The methods to diagnose TAI of the neural tracts of the above studies can be summarized as follows (**Flow Sheet 1**). First, head trauma history compatible with mild TBI is required. According to the definition of mild TBI from the American Congress of Rehabilitation Medicine, the patient must have a head trauma history with three conditions of mild TBI: loss of consciousness, post-traumatic amnesia, and Glasgow Coma Scale [86]. If a patient did not suffer loss of consciousness, any alteration in mental state (feeling dazed, disoriented, or confused) at the time of the accident is necessary. Second, development of new clinical symptoms and signs after head trauma is required. The patient must show new clinical features after the head trauma, which were never observed before the head trauma. The possibility of delayed onset of the clinical symptom due to secondary axonal injury that refers to a condition in which axons were not damaged at the time of injury, but undergo axonal injury caused by the sequential neural injury process of an injured neural tract, should also be considered [9, 10, 24, 26, 27]. Third, evidence of TAI of a neural tract on DTT is required [19, 20, 24, 26–37, 39–56]. TAI of a neural tract can be detected by configuration (tearing, narrowing, or discontinuation) or DTT parameters (significant decrement of fractional anisotropy or tract volume, or increment of mean diffusivity) on DTT for a neural



Flow Sheet 1. Diagnostic approach of traumatic axonal injury of a neural tract in patients with mild traumatic brain injury.

tract (**Figure 2**). Fourth, DTT abnormality by previous head trauma, concurrent neurological disease, aging, immaturity, or artifact of DTT should be ruled out. In addition, the newly developed clinical features and the function of the injured neural tracts must coincide. Fifth, other pathologies including peripheral nerve injury, spinal cord injury, and musculoskeletal problems should be ruled out through other studies such as electromyography study, radiological study, or ultrasonography. Additionally, improvement of a clinical symptom with management of an injured neural tract could be an additional evidence for TAI. For example, when a patient develops central pain due to injury of the spinothalamic tract following mild TBI, and if the patient's pain improves with the administration of specific drugs for central pain, it would be an additional evidence for TAI in this patient. In addition, the clinical features and DTT findings of other neural tracts should be considered because TAI usually occurs in multiple neural tracts following diffuse head trauma like mild TBI [29, 30, 34].

For example, a 43-year-old female patient suffered injury from a car accident. She hit her head on the seats with acceleration-deceleration injury while sitting in a passenger seat in a minibus after a collision with a car from behind. She had no head trauma history, and findings were consistent with the three conditions of mild TBI [86, 87]. Since the head trauma, she noticed memory impairment, mild weakness of both hands, and central pain of the entire body. On DTT, the injuries of cingulum (discontinuations of both anterior cingula), the fornix (discontinuation of the left fornical crus), corticospinal tract (partial tearing at the subcortical white matter of both corticospinal tracts), and spinothalamic tract (partial tearing of the left spinothalamic tract) were detected (**Figure 3**). In this patient, TAI by this car accident was confidently diagnosed by the head trauma history, development of new clinical features, and injury evidence of the various neural tracts on DTT. The patient provided written informed consent.

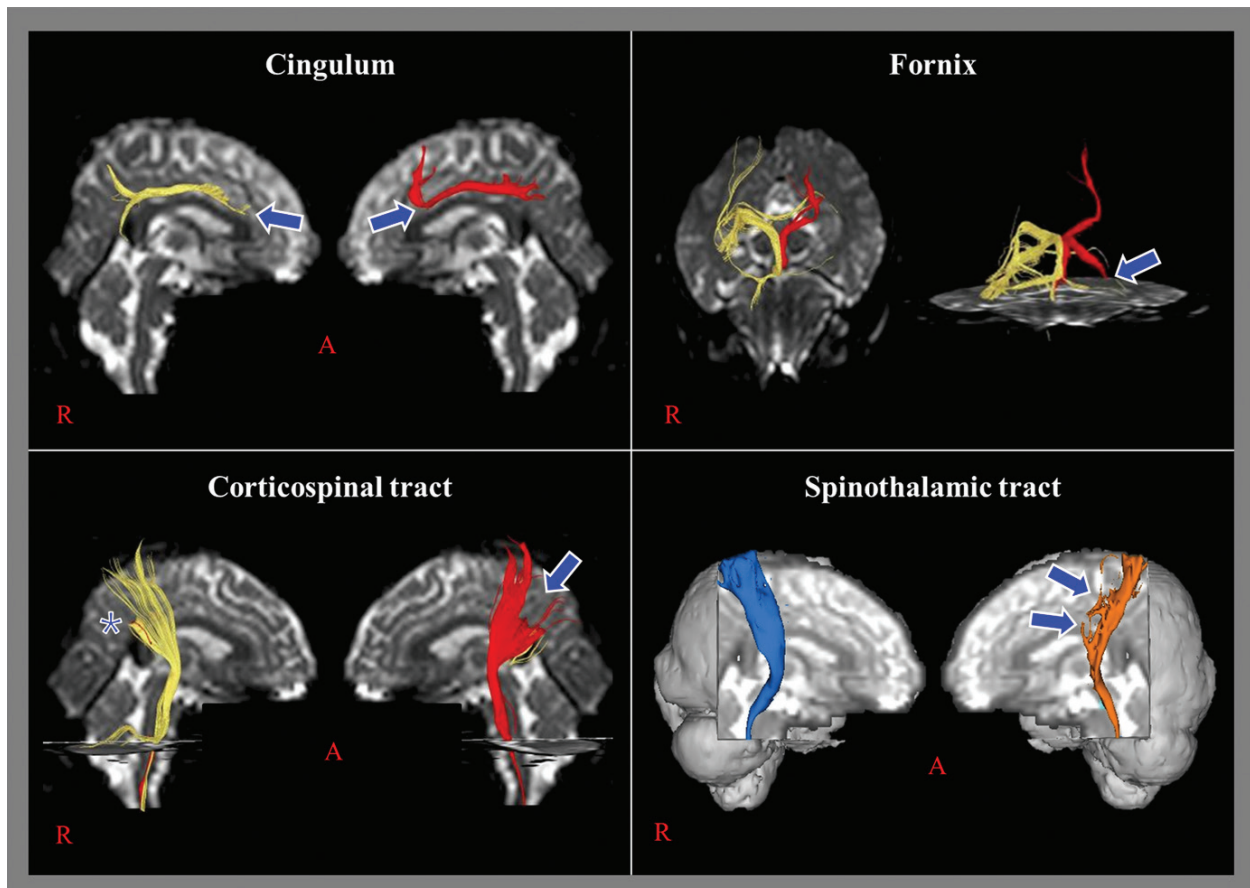


Figure 3. Traumatic axonal injuries of several neural tracts in a patient with mild traumatic brain injury. (->:traumatic axonal injury, *suspicious traumatic axonal injury).

3. Conclusion

In this chapter, TAI in patients with mild TBI is described in terms of definition, history, and diagnostic approach. Precise diagnosis of TAI in patients with mild TBI is clinically important. The introduction of DTI has enabled diagnosis of TAI in the live patients with mild TBI [15–85]. Several requirements are necessary for diagnosis of TAI in patients with mild TBI: head trauma history, development of new clinical symptoms and signs after head trauma, evidence of TAI of the neural tracts on DTI or DTT, and coincidence of the newly developed clinical features and the function of injured neural tracts. DTT seems a better tool than the ROI method on DTI to locate partial injury in a neural tract in an individual patient, because DTT can evaluate the entire neural tract. Limitations of DTT should be considered, although the reconstruction methods of various neural tracts have been well defined, and high repeatability and reliability of these methods have been demonstrated [6, 24, 50, 105–111, 113, 115, 116, 118, 119]. Further studies of the diagnostic criteria for TAI with sensitivity, specificity, and reliability in mild TBI should be encouraged.

Acknowledgements

This work was supported by the National Research Foundation (NRF) of Korea Grant funded by the Korean Government (MSIP) (2015R1A2A2A01004073).

Author details

Sung Ho Jang

Address all correspondence to: strokerehab@hanmail.net

Department of Physical Medicine and Rehabilitation, College of Medicine, Yeungnam University and Daemyungdong, Namku, Taegu, Republic of Korea

References

- [1] Decuyper M, Klimo P Jr. Spectrum of traumatic brain injury from mild to severe. *The Surgical Clinics of North America*. 2012;**92**:939-957. DOI: 10.1016/j.suc.2012.04.005
- [2] Kraus JF, Nourjah P. The epidemiology of mild, uncomplicated brain injury. *The Journal of Trauma*. 1988;**28**:1637-1643. DOI: 10.1097/00005373-198812000-00004
- [3] De Kruijk JR, Twijnstra A, Leffers P. Diagnostic criteria and differential diagnosis of mild traumatic brain injury. *Brain Injury*. 2001;**15**:99-106. DOI: 10.1080/026990501458335
- [4] Cassidy JD, Carroll LJ, Peloso PM, Borg J, von Holst H, Holm L, Kraus J, Coronado VG. Incidence, risk factors and prevention of mild traumatic brain injury: Results of the WHO Collaborating Centre Task Force on Mild Traumatic Brain Injury. *Journal of Rehabilitation Medicine* 2004;**28**:28-60. DOI: 10.1080/16501960410023732
- [5] Sharp DJ, Jenkins PO. Concussion is confusing us all. *Practical Neurology*. 2015;**15**:172-186. DOI: 10.1136/practneurol-2015-001087
- [6] Jang SH. Diagnostic history of traumatic axonal injury in patients with cerebral concussion and mild traumatic brain injury. *Brain & Neurorehabil*. 2016;**9**:1-8. DOI: 10.12786/bn.2016.9.e1
- [7] Saatman KE, Duhaime AC, Bullock R, Maas AI, Valadka A, Manley GT, Workshop Scientific T, Advisory PM. Classification of traumatic brain injury for targeted therapies. *Journal of Neurotrauma*. 2008;**25**:719-738. DOI: 10.1089/neu.2008.0586
- [8] Maxwell WL, Povlishock JT, Graham DL. A mechanistic analysis of nondisruptive axonal injury: A review. *Journal of Neurotrauma*. 1997;**14**:419-440. DOI: 10.1089/neu.1997.14.419

- [9] Povlishock JT. Traumatically induced axonal injury: Pathogenesis and Pathobiological implications. *Brain Pathology*. 1992;**2**:1-12
- [10] Povlishock JT, Christman CW. The pathobiology of traumatically induced axonal injury in animals and humans: A review of current thoughts. *Journal of Neurotrauma*. 1995;**12**:555-564. DOI: 10.1089/neu.1995.12.555
- [11] Povlishock JT, Becker DP, Cheng CL, Vaughan GW. Axonal change in minor head injury. *Journal of Neuropathology and Experimental Neurology*. 1983;**42**:225-242. DOI: 10.1097/00005072-198305000-00002
- [12] Oppenheimer DR. Microscopic lesions in the brain following head injury. *Journal of Neurology, Neurosurgery, and Psychiatry*. 1968;**31**:299-306. DOI: 10.1136/jnnp.31.4.299
- [13] Blumbergs PC, Scott G, Manavis J, Wainwright H, Simpson DA, McLean AJ. Staining of amyloid precursor protein to study axonal damage in mild head injury. *Lancet*. 1994;**344**:1055-1056. DOI: 10.1016/s0140-6736(94)91712-4
- [14] Bigler ED. Neuropsychological results and neuropathological findings at autopsy in a case of mild traumatic brain injury. *Journal of the International Neuropsychological Society*. 2004;**10**:794-806. DOI: 10.1017/S1355617704105146
- [15] Arfanakis K, Houghton VM, Carew JD, Rogers BP, Dempsey RJ, Meyerand ME. Diffusion tensor MR imaging in diffuse axonal injury. *AJNR – American Journal of Neuroradiology*. 2002;**23**:794-802
- [16] Inglese M, Makani S, Johnson G, Cohen BA, Silver JA, Gonen O, Grossman RI. Diffuse axonal injury in mild traumatic brain injury: A diffusion tensor imaging study. *Journal of Neurosurgery*. 2005;**103**:298-303. DOI: 10.3171/jns.2005.103.2.0298
- [17] Niogi SN, Mukherjee P, Ghajar J, Johnson C, Kolster RA, Sarkar R, Lee H, Meeker M, Zimmerman RD, Manley GT, McCandliss BD. Extent of microstructural white matter injury in postconcussive syndrome correlates with impaired cognitive reaction time: A 3T diffusion tensor imaging study of mild traumatic brain injury. *AJNR – American Journal of Neuroradiology*. 2008;**29**:967-973. DOI: 10.3174/ajnr.A0970
- [18] Shenton ME, Hamoda HM, Schneiderman JS, Bouix S, Pasternak O, Rathj Y, Vu MA, Purohit MP, Helmer K, Koerte I, Lin AP, Westin CF, Kikinis R, Kubicki M, Stern RA, Zafonte R. A review of magnetic resonance imaging and diffusion tensor imaging findings in mild traumatic brain injury. *Brain Imaging and Behavior*. 2012;**6**:137-192. DOI: 10.1007/s11682-012-9156-5
- [19] Jang SH, Kim SY. Injury of the corticospinal tract in patients with mild traumatic brain injury: A diffusion tensor tractography study. *Journal of Neurotrauma*. 2016;**33**:1790-1795. DOI: 10.1089/neu.2015.4298
- [20] Yang DS, Kwon HG, Jang SH. Injury of the thalamocingulate tract in the papez circuit in patients with mild traumatic brain injury. *American Journal of Physical Medicine & Rehabilitation*. 2016;**95**:E34-E38. DOI: 10.1097/Phm.0000000000000413

- [21] Jang SH, Kim TH, Kwon YH, Lee MY, Lee HD. Postural instability in patients with injury of corticoreticular pathway following mild traumatic brain injury. *American Journal of Physical Medicine & Rehabilitation*. 2016;**95**:580-587. DOI: 10.1097/Phm.0000000000000446
- [22] Jang SH, Lee AY, Shin SM. Injury of the arcuate fasciculus in the dominant hemisphere in patients with mild traumatic brain injury a retrospective cross-sectional study. *Medicine*. 2016;**95**:e3007. DOI: 10.1097/MD.00000000000003007
- [23] Jang SH, Kwon HG. Injury of the ascending reticular activating system in patients with fatigue and hypersomnia following mild traumatic brain injury two case reports. *Medicine*. 2016;**95**:e2628. DOI: 10.1097/md.00000000000002628
- [24] Seo JP, Jang SH. Injury of the spinothalamic tract in a patient with mild traumatic brain injury: Diffusion tensor tractography study. *Journal of Rehabilitation Medicine*. 2014;**46**:374-377. DOI: 10.2340/16501977-1783
- [25] Kim JH, Ahn SH, Cho YW, Kim SH, Jang SH. The relation between injury of the spinothalamic tract and central pain in chronic patients with mild traumatic brain injury. *The Journal of Head Trauma Rehabilitation*. 2015;**30**:E40-E46. DOI: 10.1097/Htr.0000000000000121
- [26] Jang SH, Kwon HG. Degeneration of an injured spinothalamic tract in a patient with mild traumatic brain injury. *Brain Injury*. 2016;**30**:1026-1028. DOI: 10.3109/02699052.2016.1146961
- [27] Jang SH, Lee HD. Central pain due to spinothalamic tract injury caused by indirect head trauma following a pratfall. *Brain Injury*. 2016;**30**:933-936. DOI: 10.3109/02699052.2016.1146966
- [28] Jang SH, Seo YS. Central pain due to spinothalamic tract injury by head trauma caused by a falling object. *Ann Rehabil Med*. 2016;**10**:1149-1150. DOI: 10.5535/arm.2016.40.6.1149
- [29] Jang SH, Lee HD. Severe and extensive traumatic axonal injury following minor and indirect head trauma. *Brain Injury*. 2017;**31**:416-419. DOI: 10.1080/02699052.2016.1239274
- [30] Jang SH, Ahn SH, Cho YW, Lim JW, Cho IT. Diffusion tensor tractography for detection of concomitant traumatic brain injury in patients with traumatic spinal cord injury. *The Journal of Head Trauma Rehabilitation*. 2017. DOI: 10.1097/HTR.0000000000000300 [Epub ahead of print]
- [31] Jang SH, Kim SH, Seo JP. Spinothalamic tract injury due to primary brainstem injury: A case report. *American Journal of Physical Medicine & Rehabilitation*. 2016;**95**:E42-E43. DOI: 10.1097/Phm.0000000000000414
- [32] Jang SH, Kwon HG. Apathy due to injury of the prefrontocaudate tract following mild traumatic brain injury. *American Journal of Physical Medicine & Rehabilitation*. 2017;**96**:E130-E133. DOI: 10.1097/Phm.0000000000000630
- [33] Jang SH, Kwon HG. Aggravation of excessive daytime sleepiness concurrent with aggravation of an injured ascending reticular activating system in a patient with mild traumatic brain injury: A case report. *Medicine (Baltimore)*. 2017;**96**:e5958. DOI: 10.1097/MD.00000000000005958

- [34] Jang SH, Kwon HG. Akinetic mutism in a patient with mild traumatic brain injury: A diffusion tensor tractography study. *Brain Injury*. 2017;1-5. DOI: 10.1080/02699052.2017.1288265
- [35] Jang SH, Kwon HG. Diffuse injury of the papez circuit by focal head trauma: A diffusion tensor tractography study. *Acta Neurologica Belgica*. 2017;**117**:389-391. DOI: 10.1007/s13760-016-0665-7
- [36] Jang SH, Kwon HG. Injury of the ascending reticular activating system in patients with fatigue and hypersomnia following mild traumatic brain injury: Two case reports. *Medicine (Baltimore)*. 2016;**95**:e2628. DOI: 10.1097/MD.0000000000002628
- [37] Jang SH, Kwon HG. Injury of the dentato-rubro-thalamic tract in a patient with mild traumatic brain injury. *Brain Injury*. 2015;**29**:1725-1728. DOI: 10.1097/MD.0000000000007220
- [38] Jang SH, Lee AY, Shin SM. Injury of the arcuate fasciculus in the dominant hemisphere in patients with mild traumatic brain injury: A retrospective cross-sectional study. *Medicine (Baltimore)*. 2016;**95**:e3007. DOI: 10.1097/MD.0000000000003007
- [39] Jang SH, Lee HD. Compensatory neural tract from contralesional fornical body to ipsilesional medial temporal lobe in a patient with mild traumatic brain injury: A case report. *American Journal of Physical Medicine & Rehabilitation*. 2016;**95**:e14-e17. DOI: 10.1097/PHM.0000000000000390
- [40] Jang SH, Lee HD. Weak phonation due to injury of the corticobulbar tract in a patient with mild traumatic brain injury. *Neural Regeneration Research*. [In press]
- [41] Jang SH, Seo JP. Damage to the optic radiation in patients with mild traumatic brain injury. *Journal of Neuro-Ophthalmology*. 2015;**35**:270-273. DOI: 10.1097/WNO.0000000000000249
- [42] Jang SH, Seo JP. Motor execution problem due to injured corticofugal tracts from the supplementary motor area in a patient with mild traumatic brain injury. *American Journal of Physical Medicine & Rehabilitation*. 2017. DOI: 10.1097/phm.0000000000000699 [Epub ahead of print]
- [43] Jang SH, Seo WS, Kwon HG. Post-traumatic narcolepsy and injury of the ascending reticular activating system. *Sleep Medicine*. 2016;**17**:124-125. DOI: 10.1016/j.sleep.2015.09.020
- [44] Jang SH, Seo YS. Dysarthria due to injury of the corticobulbar tract in a patient with mild traumatic brain injury. *American Journal of Physical Medicine & Rehabilitation*. 2016;**95**:E187-E187. DOI: 10.1097/Phm.0000000000000519
- [45] Jang SH, Yi JH, Kwon HG. Injury of the dorsolateral prefronto-thalamic tract in a patient with depression following mild traumatic brain injury: A case report. *Medicine*. 2016;**95**:e5009. DOI: 10.1097/MD.0000000000005009
- [46] Jang SH, Yi JH, Kwon HG. Injury of the inferior cerebellar peduncle in patients with mild traumatic brain injury: A diffusion tensor tractography study. *Brain Injury*. 2016;**30**:1271-1275. DOI: 10.1080/02699052.2016.1178805

- [47] Jang SH, Kwon HG. Injury of the papez circuit in a patient with traumatic spinal cord injury and concomitant mild traumatic brain injury. *Neural Regeneration Research*. [In press]
- [48] Kim JW, Lee HD, Jang SH. Severe bilateral anterior cingulum injury in patients with mild traumatic brain injury. *Neural Regeneration Research*. 2015;**10**:1876-1878. DOI: 10.4103/1673-5374.170321
- [49] Kwon HG, Jang SH. Delayed gait disturbance due to injury of the corticoreticular pathway in a patient with mild traumatic brain injury. *Brain Injury*. 2014;**28**:511-514. DOI: 10.3109/02699052.2014.887228
- [50] Lee HD, Jang SH. Injury of the corticoreticular pathway in patients with mild traumatic brain injury: A diffusion tensor tractography study. *Brain Injury*. 2015;**29**:1219-1222. DOI: 10.3109/02699052.2015.1045028
- [51] Lee HD, Jang SH. Changes of an injured fornix in a patient with mild traumatic brain injury: Diffusion tensor tractography follow-up study. *Brain Injury*. 2014;**28**:1485-1488. DOI: 10.3109/02699052.2014.930178
- [52] Seo JP, Jang SH. Traumatic axonal injury of the corticospinal tract in the subcortical white matter in patients with mild traumatic brain injury. *Brain Injury*. 2015;**29**:110-114. DOI: 10.3109/02699052.2014.973447
- [53] Jang SH, Lee HD. Abundant unusual neural branches from the fornix in patients with mild traumatic brain injury: A diffusion tensor tractography study. *Brain Injury*. 2017;1-4. DOI: 10.1080/02699052.2017.1350997
- [54] Yeo SS, Jang SH. Neural reorganization following bilateral injury of the fornix crus in a patient with traumatic brain injury. *Journal of Rehabilitation Medicine*. 2013;**45**:595-598. DOI: 10.2340/16501977-1145
- [55] Jang SH, Kwon HG. Selective injury of fornical column in a patient with mild traumatic brain injury. *American Journal of Physical Medicine & Rehabilitation*. 2015;**94**:E86. DOI: 10.1097/Phm.0000000000000317
- [56] Jang SH, Kim SH, Seo JP. Recovery of an injured cingulum concurrent with improvement of short-term memory in a patient with mild traumatic brain injury. *Brain Injury*. [In press]
- [57] Jang SH, Park SM, Kwon HG. Relation between injury of the periaqueductal gray and central pain in patients with mild traumatic brain injury: Observational study. *Medicine*. 2016;**95**:e4017. DOI: 10.1097/MD.00000000000004017
- [58] Jang SH, Yi JH, Kim SH, Kwon HG. Relation between injury of the hypothalamus and subjective excessive daytime sleepiness in patients with mild traumatic brain injury. *Journal of Neurology, Neurosurgery, and Psychiatry*. 2016;**87**:1260-U1134. DOI: 10.1136/jnnp-2016-31309
- [59] Jang SH, Lee HD. Diffusion tensor tractography studies on mechanisms of recovery of injured fornical crus: A mini-review. *Neural Regeneration Research*. [In press]

- [60] Jang SH, Kim TH, Kwon YH, Lee MY, Lee HD postural instability in patients with injury of corticoreticular pathway following mild traumatic brain injury. *American Journal of Physical Medicine & Rehabilitation*. 2016;**95**:580-587. DOI: 10.1097/PHM.0000000000000446
- [61] MM D'S, Trivedi R, Singh K, Grover H, Choudhury A, Kaur P, Kumar P, Tripathi RP. Traumatic brain injury and the post-concussion syndrome: A diffusion tensor tractography study. *Indian J Radiol Imaging*. 2015;**25**:404-414. DOI: 10.4103/0971-3026.169445
- [62] Khong E, Odenwald N, Hashim E, Cusimano MD. Diffusion tensor imaging findings in post-concussion syndrome patients after mild traumatic brain injury: A systematic review. *Frontiers in Neurology*. 2016;**7**:156. DOI: 10.3389/fneur.2016.00156
- [63] Asken BM, DeKosky ST, Clugston JR, Jaffee MS, Bauer RM. Diffusion tensor imaging (DTI) findings in adult civilian, military, and sport-related mild traumatic brain injury (mTBI): A systematic critical review. *Brain Imaging and Behavior*. 2017. DOI: 10.1007/s11682-017-9708-9
- [64] Alhilali LM, Delic JA, Gumus S, Fakhran S. Evaluation of white matter injury patterns underlying neuropsychiatric symptoms after mild traumatic brain injury. *Radiology*. 2015;**277**:793-800. DOI: 10.1148/radiol.2015142974
- [65] Churchill NW, Caverzasi E, Graham SJ, Hutchison MG, Schweizer TA. White matter microstructure in athletes with a history of concussion: Comparing diffusion tensor imaging (DTI) and neurite orientation dispersion and density imaging (NODDI). *Human Brain Mapping*. 2017;**38**:4201-4211. DOI: 10.1002/hbm.23658
- [66] Delano-Wood L, Bangen KJ, Sorg SF, Clark AL, Schiehser DM, Luc N, Bondi MW, Werhane M, Kim RT, Bigler ED. Brainstem white matter integrity is related to loss of consciousness and postconcussive symptomatology in veterans with chronic mild to moderate traumatic brain injury. *Brain Imaging and Behavior*. 2015;**9**:500-512. DOI: 10.1007/s11682-015-9432-2
- [67] Edlow BL, Copen WA, Izzy S, Bakhadirov K, van der Kouwe A, Glenn MB, Greenberg SM, Greer DM, Wu O. Diffusion tensor imaging in acute-to-subacute traumatic brain injury: A longitudinal analysis. *BMC Neurology* 2016;**16**:2. DOI: 10.1186/s12883-015-0525-8
- [68] Ewing-Cobbs L, Johnson CP, Juranek J, DeMaster D, Prasad M, Duque G, Kramer L, Cox CS, Swank PR. Longitudinal diffusion tensor imaging after pediatric traumatic brain injury: Impact of age at injury and time since injury on pathway integrity. *Human Brain Mapping*. 2016;**37**:3929-3945. DOI: 10.1089/neu.2016.4584
- [69] Genc S, Anderson V, Ryan NP, Malpas CB, Catroppa C, Beauchamp MH, Silk TJ. Recovery of white matter following pediatric traumatic brain injury depends on injury severity. *Journal of Neurotrauma*. 2017;**34**:798-806. DOI: 10.1089/neu.2016.4584
- [70] Hashim E, Caverzasi E, Papinutto N, Lewis CE, Jing RW, Charles O, Zhang SD, Lin A, Graham SJ, Schweizer TA, Bharatha A, Cusimano MD. Investigating microstructural abnormalities and neurocognition in sub-acute and chronic traumatic brain injury patients with normal-appearing white matter: A preliminary diffusion tensor imaging study. *Frontiers in Neurology*. 2017;**8**:97. DOI: 10.3389/fneur.2017.00097

- [71] Hu H, Zhou Y, Wang Q, Su SS, Qiu YM, Ge JW, Wang Z, Xiao ZP. Association of abnormal white matter integrity in the acute phase of motor vehicle accidents with post-traumatic stress disorder. *Journal of Affective Disorders*. 2016;**190**:714-722. DOI: 10.1016/j.jad.2015.09.044
- [72] Kasahara K, Hashimoto K, Abo M, Senoo A. Voxel- and atlas-based analysis of diffusion tensor imaging may reveal focal axonal injuries in mild traumatic brain injury – comparison with diffuse axonal injury. *Magnetic Resonance Imaging*. 2012;**30**:496-505. DOI: 10.1016/j.mri.2011.12.018
- [73] Lancaster MA, Olson DV, McCrea MA, Nelson LD, LaRoche AA, Muftuler LT. Acute white matter changes following sport-related concussion: A serial diffusion tensor and diffusion kurtosis tensor imaging study. *Human Brain Mapping*. 2016;**37**:3821-3834. DOI: 10.1002/hbm.23278
- [74] Leh SE, Schroeder C, Chen JK, Chakravarty MM, Park MTM, Cheung B, Huntgeburth SC, Gosselin N, Hock C, Ptito A, Petrides M. Microstructural integrity of hippocampal subregions is impaired after mild traumatic brain injury. *Journal of Neurotrauma*. 2017;**34**:1402-1411. DOI: 10.1089/neu.2016.4591
- [75] Lopez KC, Leary JB, Pham DL, Chou YY, Durney J, Chan L. Brain volume, connectivity, and neuropsychological performance in mild traumatic brain injury: The impact of post-traumatic stress disorder symptoms. *Journal of Neurotrauma*. 2017;**34**:16-22. DOI: 10.1089/neu.2015.4323
- [76] Mayinger MCM-BK, Hufschmidt J, Muehlmann M. Brain volume, connectivity, and neuropsychological performance in mild traumatic brain injury s: A longitudinal diffusion tensor imaging study. *Brain Imaging and Behavior*. 2017 [Epub ahead of print]
- [77] Meier TB, Bergamino M, Bellgowan PSF, Teague TK, Ling JM, Jeromin A, Mayer AR. Longitudinal assessment of white matter abnormalities following sports-related concussion. *Human Brain Mapping*. 2016;**37**:833-845. DOI: 10.1002/hbm.23072
- [78] Messe A, Caplain S, Paradot G, Garrigue D, Mineo JF, Ares GS, Ducreux D, Vignaud F, Rozec G, Desal H, Pelegrini-Issac M, Montreuil M, Benali H, Lehericy S. Diffusion tensor imaging and white matter lesions at the subacute stage in mild traumatic brain injury with persistent neurobehavioral impairment. *Human Brain Mapping*. 2011;**32**:999-1011. DOI: 10.1002/hbm.21092
- [79] Miller DR, Hayes JP, Lafleche G, Salat DH, Verfaellie M. White matter abnormalities are associated with chronic postconcussion symptoms in blast-related mild traumatic brain injury. *Human Brain Mapping*. 2016;**37**:220-229. DOI: 10.1002/hbm.23022
- [80] Miller DRHJ, Lafleche G, Salat DH, Verfaellie M. White matter abnormalities are associated with overall cognitive status in blast-related mTBI. *Brain Imaging and Behavior*. 2016;**11**:1129-1138. DOI: 10.1007/s11682-016-9593-7
- [81] Mu W, Catenaccio E, Lipton ML. Neuroimaging in blast-related mild traumatic brain injury. *The Journal of Head Trauma Rehabilitation*. 2017;**32**:55-69. DOI: 10.1097/HTR.000000000000213

- [82] Oehr L, Anderson J. Diffusion-tensor imaging findings and cognitive function following hospitalized mixed-mechanism mild traumatic brain injury: A systematic review and meta-analysis. *Archives of Physical Medicine and Rehabilitation*. 2017. DOI: 10.1016/j.apmr.2017.03.019 [Epub ahead of print]
- [83] Strain J, Didehban N, Cullum CM, Mansinghani S, Conover H, Kraut MA, Hart J, Womack KB. Depressive symptoms and white matter dysfunction in retired NFL players with concussion history. *Neurology*. 2013;**81**:25-32. DOI: 10.1212/WNL.0b013e318299ccf8
- [84] Ware JB, Biester RC, Whipple E, Robinson KM, Ross RJ, Nucifora PG. Combat-related mild traumatic brain injury: Association between baseline diffusion-tensor imaging findings and long-term outcomes. *Radiology*. 2016;**280**:212-219. DOI: 10.1148/radiol.2016151013
- [85] Wilde EA, Li XQ, Hunter JV, Narayana PA, Hasan K, Biekman B, Swank P, Robertson C, Miller E, McCauley SR, Chu ZD, Faber J, McCarthy J, Levin HS. Loss of consciousness is related to white matter injury in mild traumatic brain injury. *Journal of Neurotrauma*. 2016;**33**:2000-2010. DOI: 10.1089/neu.2015.4212
- [86] Mild Traumatic Brain Injury Committee. Definition of mild traumatic brain injury. *The Journal of Head Trauma Rehabilitation*. 1993;**8**:86-87. DOI: 10.1097/00001199-199309000-00010
- [87] Alexander MP. Mild traumatic brain injury: Pathophysiology, natural history, and clinical management. *Neurology*. 1995;**45**:1253-1260. DOI: 10.1212/wnl.45.7.1253
- [88] Carroll LJ, Cassidy JD, Holm L, Kraus J, Coronado VG. Methodological issues and research recommendations for mild traumatic brain injury: The who collaborating centre task force on mild traumatic brain injury. *Journal of Rehabilitation Medicine*. 2004;**36**:113-125. DOI: 10.1080/16501960410023877
- [89] Levin HS, Diaz-Arrastia RR. Diagnosis, prognosis, and clinical management of mild traumatic brain injury. *Lancet Neurology*. 2015;**14**:506-517. DOI: 10.1016/S1474-4422(15)00002-2
- [90] Rosenfeld JV, McFarlane AC, Bragge P, Armonda RA, Grimes JB, Ling GS. Blast-related traumatic brain injury. *Lancet Neurology*. 2013;**12**:882-893. DOI: 10.1016/S1474-4422(13)70161-3
- [91] McMahan P, Hricik A, Yue JK, Puccio AM, Inoue T, Lingsma HF, Beers SR, Gordon WA, Valadka AB, Manley GT, Okonkwo DO. Symptomatology and functional outcome in mild traumatic brain injury: Results from the prospective track-TBI study. *Journal of Neurotrauma*. 2014;**31**:26-33. DOI: 10.1089/neu.2013.2984
- [92] Rapp PE, Curley KC. Is a diagnosis of "mild traumatic brain injury" a category mistake? *Journal of Trauma and Acute Care Surgery*. 2012;**73**:S13-S23. DOI: 10.1097/TA.0b013e318260604b
- [93] Johnson VE, Stewart W, Smith DH. Axonal pathology in traumatic brain injury. *Experimental Neurology*. 2013;**246**:35-43. DOI: 10.1016/j.expneurol.2012.01.013
- [94] Buki A, Povlishock JT. All roads lead to disconnection? Traumatic axonal injury revisited. *Acta Neurochirurgica*. 2006;**148**:181-193. DOI: 10.1007/s00701-005-0674-4

- [95] Parizel PM, Ozsarlak, Van Goethem JW, van den Hauwe L, Dillen C, Verlooy J, Cosyns P, De Schepper AM, Imaging findings in diffuse axonal injury after closed head trauma. *European Radiology*. 1998;**8**:960-965. DOI: 10.1007/s003300050496
- [96] Rand CW, Courville CB. Histologic changes in the brain in cases of fatal injury to the head; alterations in nerve cells. *Archives of Neurology and Psychiatry*. 1946;**55**:79-110. DOI: 10.1001/archneurpsyc.1946.02300130003001
- [97] Basser PJ, Mattiello J, LeBihan D. MR diffusion tensor spectroscopy and imaging. *Biophysical Journal*. 1994;**66**:259-267. DOI: 10.1016/S0006-3495(94)80775-1
- [98] Shenton ME, Hamoda HM, Schneiderman JS, Bouix S, Pasternak O, Rathi Y, Vu MA, Purohit MP, Helmer K, Koerte I, Lin AP, Westin CF, Kikinis R, Kubicki M, Stern RA, Zafonte R. A review of magnetic resonance imaging and diffusion tensor imaging findings in mild traumatic brain injury. *Brain Imaging and Behavior*. 2012;**6**:137-192. DOI: 10.1007/s11682-012-9156-5
- [99] Lee AY, Shin DG, Park JS, Hong GR, Chang PH, Seo JP, Jang SH. Neural tracts injuries in patients with hypoxic ischemic brain injury: Diffusion tensor imaging study. *Neuroscience Letters*. 2012;**528**:16-21. DOI: 10.1016/j.neulet.2012.08.053
- [100] Blumbergs PC. Changing concepts of diffuse axonal injury. *Journal of Clinical Neuroscience*. 1998;**5**:123-124. DOI: 10.1016/S0967-5868(98)90026-1
- [101] Adams JH, Doyle D, Ford I, Gennarelli TA, Graham DI, McLellan DR. Diffuse axonal injury in head injury: Definition, diagnosis and grading. *Histopathology*. 1989;**15**:49-59. DOI: 10.1111/j.1365-2559.1989.tb03040.x
- [102] Adams JH, Graham DI, Murray LS, Scott G. Diffuse axonal injury due to nonmissile head injury in humans. *Annals of Neurology*. 1982;**12**:557-563. DOI: 10.1002/ana.410120610
- [103] Hill CS, Coleman MP, Menon DK. Traumatic axonal injury. Mechanisms and translational opportunities. *Trends in Neurosciences*. 2016;**39**:311-324. DOI: 10.1016/j.tins.2016.03.002
- [104] Jang SH. A review of corticospinal tract location at corona radiata and posterior limb of the internal capsule in human brain. *NeuroRehabilitation*. 2009;**24**:279-283. DOI: 10.3233/Nre-2009-0479
- [105] Lee SK, Kim DI, Kim J. Diffusion-tensor MR imaging and fiber tractography: A new method of describing aberrant fiber connections in developmental CNS anomalies – response. *Radiographics*. 2005;**25**:53-65. DOI: 10.1148/rg.251045085
- [106] Brandstack N, Kurki T, Laalo J, Kauko T, Tenovuo O. Reproducibility of tract-based and region-of-interest DTI analysis of long association tracts. *Clinical Neuroradiology*. 2016;**26**:199-208. DOI: 10.1007/s00062-014-0349-8
- [107] Wang JY, Abdi N, Bakhadirov K, Diaz-Arrastia R, Devous MD. A comprehensive reliability assessment of quantitative diffusion tensor tractography. *NeuroImage*. 2012;**60**:1127-1138. DOI: 10.1016/j.neuroimage.2011.12.062

- [108] Hasan KM, Kamali A, Abid H, Kramer LA, Fletcher JM, Ewing-Cobbs L. Quantification of the spatiotemporal microstructural organization of the human brain association, projection and commissural pathways across the lifespan using diffusion tensor tractography. *Brain Structure & Function*. 2010;**214**:361-373. DOI: 10.1007/s00429-009-0238-0
- [109] Danielian LE, Iwata NK, Thomasson DM, Floeter MK. Reliability of fiber tracking measurements in diffusion tensor imaging for longitudinal study. *NeuroImage*. 2010;**49**:1572-1580. DOI: 10.1016/j.neuroimage.2009.08.062
- [110] Malykhin N, Concha L, Seres P, Beaulieu C, Coupland NJ. Diffusion tensor imaging tractography and reliability analysis for limbic and paralimbic white matter tracts. *Psychiatry Research*. 2008;**164**:132-142. DOI: 10.1016/j.psychres.2007.11.007
- [111] Wakana S, Caprihan A, Panzenboeck MM, Fallon JH, Perry M, Gollub RL, Hua K, Zhang J, Jiang H, Dubey P, Blitz A, van Zijl P, Mori S. Reproducibility of quantitative tractography methods applied to cerebral white matter. *NeuroImage* 2007;**36**:630-644. DOI: 10.1016/j.neuroimage.2007.02.049
- [112] Mori S, Crain BJ, Chacko VP, van Zijl PC. Three-dimensional tracking of axonal projections in the brain by magnetic resonance imaging. *Annals of Neurology* 1999;**45**:265-269. DOI: 10.1002/1531-8249(199902)45:2<265::aid-ana21>3.0.co;2-3
- [113] Danielian LE, Iwata NK, Thomasson DM, Floeter MK. Reliability of fiber tracking measurements in diffusion tensor imaging for longitudinal study. *NeuroImage*. 2010;**49**:1572-1580. DOI: 10.1016/j.neuroimage.2009.08.062
- [114] Basser PJ, Jones DK. Diffusion-tensor MRI: Theory, experimental design and data analysis – A technical review. *NMR in Biomedicine*. 2002;**15**:456-467. DOI: 10.1002/nbm.783
- [115] Yamada K, Sakai K, Akazawa K, Yuen S, Nishimura T. MR tractography: A review of its clinical applications. *Magnetic Resonance in Medical Sciences*. 2009;**8**:165-174. DOI: 10.2463/mrms.8.165
- [116] Parker GJ, Alexander DC. Probabilistic anatomical connectivity derived from the microscopic persistent angular structure of cerebral tissue. *Philosophical Transactions of the Royal Society of London. Series B, Biological Sciences*. 2005;**360**:893-902. DOI: 10.1098/rstb.2005.1639
- [117] Mac Donald CL, Dikranian K, Bayly P, Holtzman D, Brody D. Diffusion tensor imaging reliably detects experimental traumatic axonal injury and indicates approximate time of injury. *The Journal of Neuroscience*. 2007;**27**:11869-11876. DOI: 10.1523/JNEUROSCI.3647-07.2007
- [118] Kwon HG, Choi BY, Kim SH, Chang CH, Jung YJ, Lee HD, Jang SH. Injury of the cingulum in patients with putaminal hemorrhage: A diffusion tensor tractography study. *Frontiers in Human Neuroscience*. 2014;**8**:366. DOI: 10.3389/fnhum.2014.00366
- [119] Jang SH, Kwon HG. The ascending reticular activating system from pontine reticular formation to the hypothalamus in the human brain: A diffusion tensor imaging study. *Neuroscience Letters*. 2015;**590**:58-61. DOI: 10.1016/j.neulet.2015.01.071