

# We are IntechOpen, the world's leading publisher of Open Access books Built by scientists, for scientists

**4,800**

Open access books available

**122,000**

International authors and editors

**135M**

Downloads

Our authors are among the

**154**

Countries delivered to

**TOP 1%**

most cited scientists

**12.2%**

Contributors from top 500 universities



**WEB OF SCIENCE™**

Selection of our books indexed in the Book Citation Index  
in Web of Science™ Core Collection (BKCI)

Interested in publishing with us?  
Contact [book.department@intechopen.com](mailto:book.department@intechopen.com)

Numbers displayed above are based on latest data collected.

For more information visit [www.intechopen.com](http://www.intechopen.com)



---

# Neonatal Osteomyelitis

---

Ursula Kiechl-Kohlendorfer and Elke Griesmaier

Additional information is available at the end of the chapter

<http://dx.doi.org/10.5772/54320>

---

## 1. Introduction

Acute osteomyelitis, although a rare complication in neonates, is a diagnostic and therapeutic challenge. Due to their immature immune response neonates are more susceptible to osteomyelitis than are older children. Preterm infants are at high risk for osteomyelitis because of frequent blood drawing, invasive monitoring/procedures and intravenous drug administration [1,2]. Early diagnosis of neonatal osteomyelitis might be difficult because of the paucity of clinical signs and symptoms, but has to be included in the differential diagnosis when late-onset or prolonged neonatal sepsis is present, as outcome is dependent on rapid diagnosis and immediate start of treatment.

## 2. Epidemiology

In Western countries the incidence of osteomyelitis and septic arthritis is 5-12 per 100.000 infants [3]. The overall incidence rate for bone and joint infections is 0.12 per 1000 live births and 0.67 per 1000 neonatal intensive care (NICU) admissions [4], with a mortality rate of 7.3% [5]. Some recent studies have reported an estimated incidence of 1-7 per 1000 hospital admissions for neonatal osteomyelitis [6,7]. In a review of more than 300 cases of neonatal osteomyelitis male infants are seen to predominate over females (1.6:1) and preterm infants to be at higher risk than term infants [8-10]. Risk factors for osteomyelitis and septic arthritis in preterm infants are mostly iatrogenic, including invasive procedures, intravenous or intra-arterial catheters, parenteral nutrition, ventilatory support, and bacteremia with nosocomial pathogens [11,12]. Two subgroups of neonates are affected: premature neonates with prolonged hospitalization and otherwise healthy newborns presenting within 2 to 4 weeks of discharge [13].

## 3. Microbiology

Neonatal osteomyelitis arises as a consequence of hematogenous spread of microorganisms, which is the most common route of infection. In preterm infants, neonatal osteomyelitis

frequently results from directly inoculated bacteria (secondary to heel or venipuncture, umbilical catheterization, infected cephalhematoma, etc.) [14,15]. Premature rupture of membranes and transplacental infection have also been described as risk factors for neonatal osteomyelitis [16].

The most common bacterial pathogen causing osteomyelitis in children is *Staphylococcus aureus* in all age groups [17]. Group B streptococcus (*Streptococcus agalactiae*) and gram-negative organisms (*E. coli* and *Klebsiella pneumoniae*) are also important bacteria in the neonatal period [16,18,19]. Community-acquired strains of methicillin-resistant *Staphylococcus aureus* have emerged as being relevant in recent years and cause serious infections in the neonate [12,20,21].

#### **4. Pathogenesis**

Hematogenous infection of the long bones, which are most frequently affected, begins in the capillary loops of the metaphysis, adjacent to the cartilaginous growth plate (physis). These areas are very susceptible to hematogenous infection, because of its high vascularity and because the blood flow within the vessels is slow [22]. Bacteria can pass through gaps from the sinusoidal veins to the capillaries into the tissue, where they are provided an ideal environment to grow, resulting in abscess formation. These abscesses frequently rupture into the joint [23]. In neonates acute hematogenous osteomyelitis and septic arthritis co-exist in up to 76% of all cases as a result of this unique vascular anatomy of the epiphysis; the bone marrow compartment is seldom involved [10,24]. The epiphysis receives its blood supply directly from metaphyseal blood vessels (transphyseal vessels) and the adjacent cartilaginous growth plate is traversed by capillaries, allowing spread of the pathogenic bacteria to the physis, epiphysis and joint and resulting in slipped epiphyses, fractures, premature physeal closure and chronic infection (Figure 1) [25].

Characteristics of the neonatal bone prevent many of the features of chronic osteomyelitis: cortical sequestra are often completely absorbed due to extensive bone blood supply in the newborn and, in addition, efficient vasculature of the inner layer of the periosteum encourages early development of new bone formation [26,27]. Complete destruction of joints is rare, but serious growth disturbances may occur.

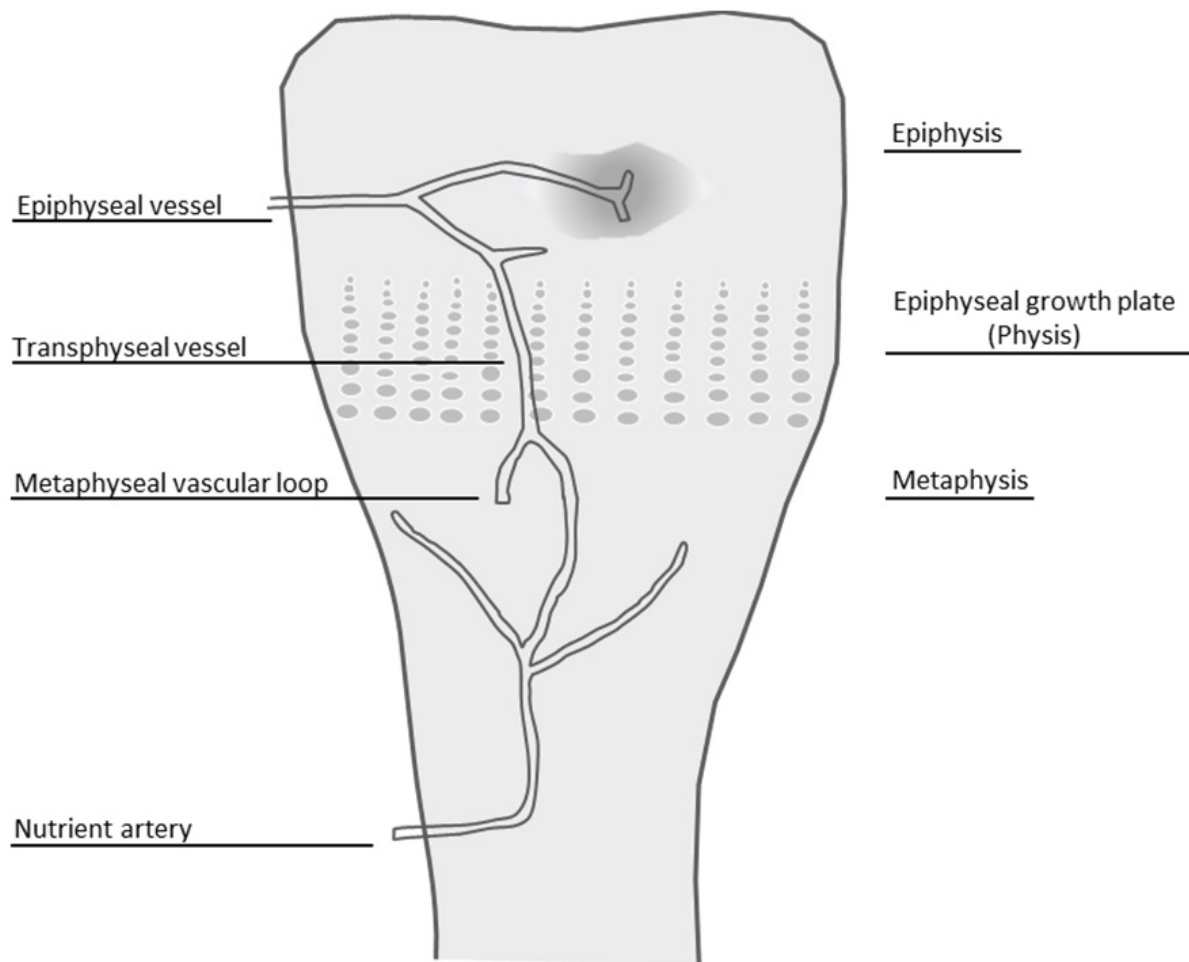
#### **5. Diagnosis**

Diagnosis of osteomyelitis in the neonate can be challenging and is often delayed, as it is rare in the neonatal period and frequently presents with non-specific signs of illness. Diagnosis is based on clinical signs and symptoms, laboratory findings, radiological and microbiological criteria.

##### **5.1. Clinical signs and symptoms**

In general, two distinct clinical syndromes have been postulated to be associated with neonatal osteomyelitis: 1) a benign form, with little or no evidence of infection other than

local swelling, and 2) a severe form, with the predominant manifestation of a sepsis-like syndrome with multiple bone sites being noted as manifestations [28]. In neonates, almost half of all cases involve two or more bones.



**Figure 1.** Anatomic depiction of blood supply to the epiphysis and metaphysis in the developing bone that influences the progression of osteomyelitis in the neonate (modified and redrawn from Kaye JJ et al, [53]).

Clinical symptoms and signs of osteomyelitis in the neonate are at first frequently nonspecific and mild. They may include temperature instability, feeding intolerance, irritability or reduced movement, frequently giving rise to the suspicion of secondary sepsis. Fever is a rare condition that could be explained by a rather poorly developed immune system. As the disease progresses, more specific signs may become present, including disability, local swelling or erythema. Focal tenderness over a long bone should catch the physician's attention. In some cases subcutaneous abscess formation prompts the diagnosis of osteomyelitis. Hip, knee and shoulder are most frequently involved [7,28,29].

## 5.2. Laboratory findings

In general, there is no specific laboratory test for osteomyelitis. Neonates with osteomyelitis frequently show normal leukocyte counts and erythrocyte sedimentation rates in the first

days. Thus, normal values do not preclude the diagnosis [30]. The C-reactive protein (CRP) is a rapid indicator of systemic inflammation and tissue damage, is useful as acute phase reactant, but not specific for skeletal infection. Procalcitonin has also been described as a potential marker in the diagnosis of osteomyelitis in children, but needs to be investigated in larger trials, especially in newborns [31,32]. Elevated values of CRP and erythrocyte sedimentation rates could be used to monitor response to therapy or identify complications.

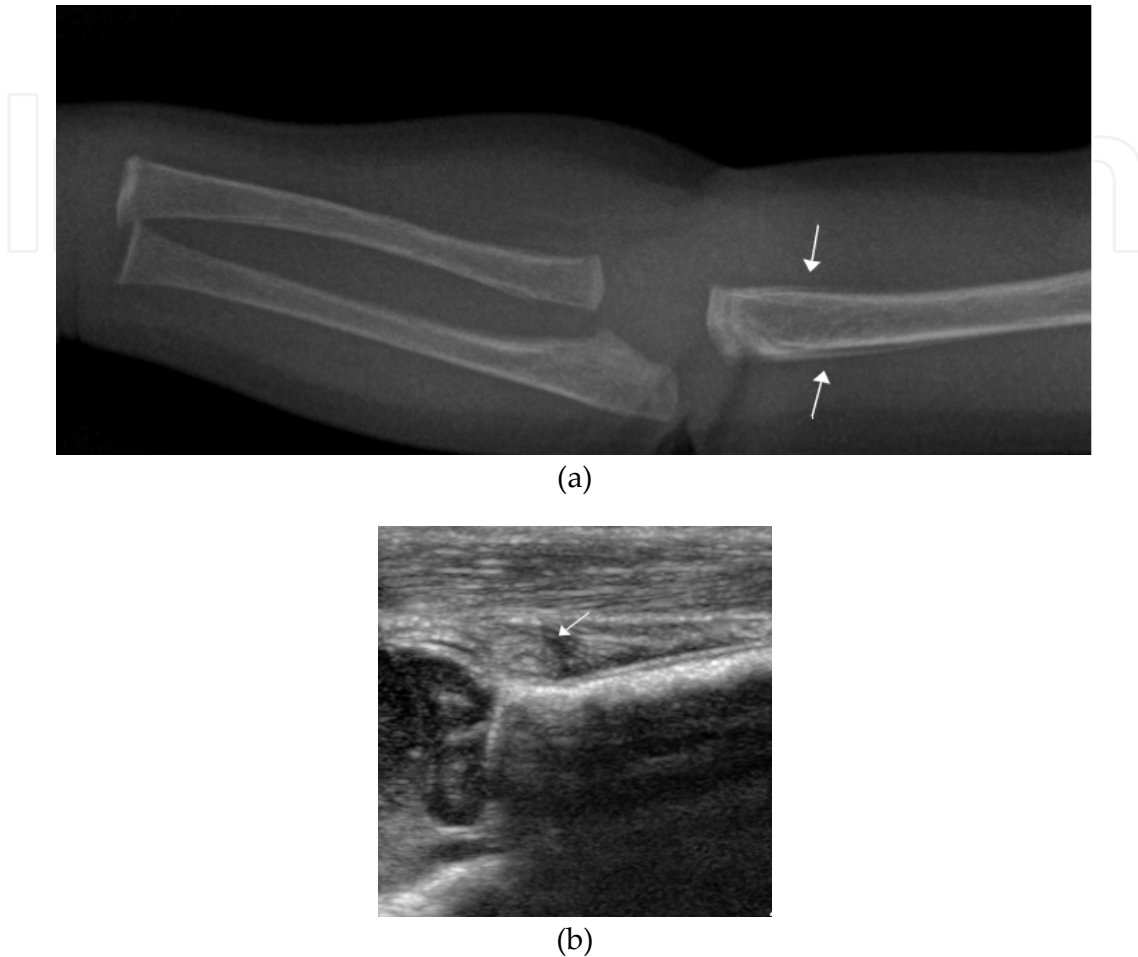
### 5.3. Imaging techniques

Radiological investigations confirm the suspicion of neonatal osteomyelitis, define the infection site, differentiate between unifocal and multifocal disease patterns and identify secondary complications. Computed tomography, magnetic resonance imaging, ultrasound, radiography and bone scintigraphy scanning have been reported to be useful in detecting osteomyelitis. However, awareness of radiation exposure, need for sedation and transfer to another unit must be considered in the selection of technique.

Radiographs should be the first diagnostic assessment to be performed in patients with suspected osteomyelitis, because they may suggest the correct diagnosis and exclude other pathologic conditions (Figure 2a). However, the specificity of plain radiographs for detecting osteomyelitis is greater (75% to 83%) than its sensitivity (43% to 75%) [33]. Plain radiography can show soft tissue swelling and destroyed fascial planes within days after onset of infection, but may be subtle and not obvious until day 5 to 7 in children [34]. In the neonate even soft tissue swelling may not be present, because subcutaneous fat is lacking and fascial planes are poorly defined. Joint effusions might be suspected if widening of the joint space or bulging of the soft tissues is detected. Additional early changes are as follows: periosteal thickening/elevation, lytic lesions, osteopenia, loss of trabecular architecture, and new bone apposition [35]. Of importance, destructive bone changes do not appear until 7 to 14 days of disease [25].

Predominately in children, ultrasound can detect features of acute osteomyelitis several days earlier, than radiographs [34]. Even though findings may not be specific and standardized reports for neonates with osteomyelitis are lacking, ultrasound should be taken into account as a useful additional diagnostic tool for the early detection and management of osteomyelitis in neonates as it has many advantages: it is non-invasive, readily accessible, performed bedside, of minimal discomfort for the patient, does not use ionizing radiation and does not need sedation [36,37]. Even though ultrasound cannot exclude the diagnosis of osteomyelitis, its main value lies in its ability to identify involvement of the adjacent soft tissue (subperiosteal fluid collection or abscess formation), periosteal thickening or elevation, joint effusions and irregularities or interruptions of the cortical bone (Figure 2b) [38,39]. Color Doppler imaging further supports the diagnostic assessment, showing coexisting presence of hyperemia surrounding the periosteum and soft tissue abscess formation. Ultrasound can also be used to image guided-needle aspiration of the subperiosteal fluid for pathogenic organism isolation or subperiosteal abscess drainage. Furthermore, ultrasound has been described as being helpful in differentiating between

epiphyseal separation and subluxation following septic arthritis [40]. However, ultrasound cannot exclude the diagnosis of acute osteomyelitis, and thus further imaging diagnostics may be required [41,42].



**Figure 2.** Acute osteomyelitis of the right humerus. **a)** periosteal elevation and soft tissue swelling **b)** joint effusion and synovial thickening

Magnetic resonance imaging (MRI) has high specificity (94%) and sensitivity (97%) for the diagnosis of acute osteomyelitis, showing changes as early as day 3 to 5 after the onset of infection [43,44]. MRI gives excellent tissue characterization and high resolution, showing detailed anatomic presence of the inflammatory process and its complications (abscess formation, physeal involvement, septic arthritis), further allowing the assessment of involvement of the growth plate and epiphysis. MRI has been proven useful in the diagnosis of clinically suspected osteomyelitis in children [45-48], but for its use in neonatology it has several limitations: first and foremost the need for sedation and transfer to the MRI unit.

Three-phase bone imaging, using technetium 99m is very sensitive (90%-95%) for the detection of acute osteomyelitis in the early stages of disease and allows detection within 24 to 48 hours after onset of symptoms [34,49]. Bone scintigraphy is especially useful for detecting multiple foci of infection or if the infection site is poorly localized. Technetium-99

methylenediphosphonate accumulates in areas of increased bone turnover and is for now the preferred agent of choice for radionuclide bone imaging. In neonates bone scintigraphy is the subject of controversy: only a few reports support its use and have shown that sensitivity is much lower, than in older infants because of poor bone mineralization [18,48,50].

## 6. Treatment

Successful cure of osteomyelitis during the newborn period is dependent on a fast and true diagnosis and sufficient treatment. Empirical selection of antibiotic therapy depends on the age and the clinical situation of the infant. Antimicrobial therapy should be started as soon as the diagnosis is made and directed against the most common bacterial isolates responsible for hematogenous osteomyelitis according to age group. Delay in therapy commencement increases the risk for complications. If a definitive organism is isolated, antimicrobial treatment should be accordingly adjusted.

For neonates an empiric regimen should include excellent coverage against *S. aureus*, group B streptococcus and enteric gram-negative bacteria, thus consisting of a third-generation cephalosporin (cefotaxime) plus an antistaphylococcal agent (amoxicillin). Infants at risk for hospital-acquired infection (methicillin-resistant or coagulase negative *Staphylococcus aureus*) should receive vancomycin instead of amoxicillin.

Duration of treatment depends on the extent of infection, the clinical response and the presence of underlying risk factors [51]. In the case of unifocal osteomyelitis continuation of treatment for six weeks and in the case of complex disease, defined as multifocal, significant bone destruction, resistant unusual pathogen, septic shock, continuation for more than six weeks to months might be required. Antimicrobial treatment is frequently administered intravenously for two to three weeks and then switched to oral medication [52]. Surgery is indicated to drain acute abscesses or when no improvement is achieved with antibiotic treatment.

## 7. Prognosis

Several studies have documented poor outcome even with modern treatment facilities. In neonates the reported incidence of permanent sequelae varies from 6% to 50% [2,11]. Neonatal osteomyelitis can lead to permanent joint disabilities, disturbances in bone growth secondary to damage to the cartilaginous growth plate, limb-length discrepancies, arthritis, decreased range of motion and pathologic fractures [51].

## 8. Conclusion

Neonatal osteomyelitis, although a rare complication, remains a diagnostic and therapeutic challenge and poses the infant at high risk for long term morbidity. Osteomyelitis should be considered in newborn infants presenting with clinical signs of sepsis, but lacking an

obvious focus, in order to facilitate early diagnosis and prompt initiation of appropriate therapy.

## Author details

Ursula Kiechl-Kohlendorfer and Elke Griesmaier

*Department of Pediatrics II,  
Medical University of Innsbruck,  
Innsbruck, Austria*

## 9. References

- [1] Lim MO, Gresham EL, Franken EA Jr, Leake RD. Osteomyelitis as a complication of umbilical artery catheterization. *Am J Dis Child.* 1977;131(2):142-4.
- [2] Williamson JB, Galasko CS, Robinson MJ. Outcome after acute osteomyelitis in preterm infants. *Arch Dis Child.* 1990;65:1060-2.
- [3] Rasool MN. Hematogenous osteomyelitis of the calcaneus in children. *J Pediatr Orthop.* 2001;21(6):738-43.
- [4] Ho NK, Low YP, See HF. Septic arthritis in the newborn--a 17 years' clinical experience. *Singapore Med J.* 1989;30(4):356-8.
- [5] Caksen H, Oztürk MK, Uzüm K, Yüksel S, Ustünbaş HB, Per H. Septic arthritis in childhood. *Pediatr Int.* 2000;42(5):534-40.
- [6] Goldmann DA, Durbin WA Jr, Freeman J. Nosocomial infections in a neonatal intensive care unit. *J Infect Dis.* 1981;144(5):449-59.
- [7] Berberian G, Firpo V, Soto A, Lopez Mañan J, Torroija C, Castro G, Polanuer P, Espinola C, Piñeiro JL, Rosanova MT. Osteoarthritis in the neonate: risk factors and outcome. *Braz J Infect Dis.* 2010;14(4):413-8.
- [8] De Boeck H. Osteomyelitis and septic arthritis in children. *Acta Orthop Belg.* 2005;71(5):505-15.
- [9] Krogstad P. Osteomyelitis and septic arthritis. In: Feigin RD, Cherry JD, Demmler GJ, et al., eds. *Textbook of Pediatric Infectious Diseases.* Fifth edition. Philadelphia: Saunders 2004: 713–36.
- [10] Fox L, Sprunt K. Neonatal osteomyelitis. *Pediatrics.* 1978;62(4):535-42.
- [11] Frederiksen B, Christiansen P, Knudsen FU. Acute osteomyelitis and septic arthritis in the neonate, risk factors and outcome. *Eur J Pediatr.* 1993;152(7):577-80.
- [12] Ish-Horowicz MR, McIntyre P, Nade S. Bone and joint infections caused by multiply resistant *Staphylococcus aureus* in a neonatal intensive care unit. *Pediatr Infect Dis J.* 1992;11(2):82-7.
- [13] Dessì A, Crisafulli M, Accossu S, Setzu V, Fanos V. Osteo-articular infections in newborns: diagnosis and treatment. *J Chemother.* 2008;20(5):542-50.



- [14] Bergdahl S, Ekengren K, Eriksson M. Neonatal hematogenous osteomyelitis: risk factors for long-term sequelae. *J Pediatr Orthop*. 1985;5(5):564-8.
- [15] Wong M, Isaacs D, Howman-Giles R, Uren R. Clinical and diagnostic features of osteomyelitis occurring in the first three months of life. *Pediatr Infect Dis J*. 1995;14(12):1047-53.
- [16] Liao SL, Lai SH, Lin TY, Chou YH, Hsu JF. Premature rupture of the membranes: a cause for neonatal osteomyelitis? *Am J Perinatol*. 2005;22(2):63-6.
- [17] Asmar BI. Osteomyelitis in the neonate. *Infect Dis Clin North Am*. 1992;6(1):117-32.
- [18] McPherson DM. Osteomyelitis in the neonate. *Neonatal Netw*. 2002;21(1):9-22.
- [19] Qadir M, Ali SR, Lakhani M, Hashmi P, Amirali A. Klebsiella osteomyelitis of the right humerus involving the right shoulder joint in an infant. *J Pak Med Assoc*. 2010;60(9):769-71.
- [20] Saavedra-Lozano J, Mejías A, Ahmad N, Peromingo E, Ardura MI, Guillen S, Syed A, Cavuoti D, Ramilo O. Changing trends in acute osteomyelitis in children: impact of methicillin-resistant *Staphylococcus aureus* infections. *J Pediatr Orthop*. 2008;28(5):569-75.
- [21] Korakaki E, Aligizakis A, Manoura A, Hatzidaki E, Saitakis E, Anatoliotaki M, Velivasakis E, Maraki S, Giannakopoulou C. Methicillin-resistant *Staphylococcus aureus* osteomyelitis and septic arthritis in neonates: diagnosis and management. *Jpn J Infect Dis*. 2007;60(2-3):129-31.
- [22] Green NE, Edwards K. Bone and joint infections in children. *Orthop Clin North Am*. 1987;18(4):555-76.
- [23] Ogden JA, Light TR. Pediatric osteomyelitis: III. anaerobic microorganisms. *Clin Orthop Relat Res*. 1979;(145):230-6.
- [24] Bergdahl S, Ekengren K, Eriksson M. Neonatal hematogenous osteomyelitis: risk factors for long-term sequelae. *J Pediatr Orthop*. 1985;5(5):564-8.
- [25] Blickman JG, van Die CE, de Rooy JW. Current imaging concepts in pediatric osteomyelitis. *Eur Radiol*. 2004;14 Suppl 4:L55-64.
- [26] Green WT, Shannon JG. Osteomyelitis of infants: a disease different from osteomyelitis of older children. *Arch Surg*. 1936;32:462.
- [27] Trueta J. Three types of acute haematogenous osteomyelitis. *J Bone Joint Surg Br*. 1959;41:671.
- [28] Overturf G, Marcy M. Bacterial infections of the bones and joints. In: Remington J and Klein J editors. *Infectious diseases of the fetus and newborn infant*, 5<sup>th</sup> edition 2001 WB Saunders. Chapter 23; 1019-103.
- [29] Al Saadi MM, Al Zamil FA, Bokhary NA, Al Shamsan LA, Al Alola SA, Al Eissa YS. Acute septic arthritis in children. *Pediatr Int*. 2009;51(3):377-80.
- [30] Mok PM, Reilly BJ, Ash JM. Osteomyelitis in the neonate. Clinical aspects and the role of radiography and scintigraphy in diagnosis and management. *Radiology*. 1982;145(3):677-82.

- [31] Butbul-Aviel Y, Koren A, Halevy R, Sakran W. Procalcitonin as a diagnostic aid in osteomyelitis and septic arthritis. *Pediatr Emerg Care* 2005;21(12):828-23.
- [32] Faesch S, Cojocar B, Hennequin C, Pannier S, Glorion C, Lacour B, Chéron G. Can procalcitonin measurement help the diagnosis of osteomyelitis and septic arthritis? A prospective trial. *Ital J Pediatr*. 2009;35(1):33.
- [33] Christian S, Kraas J, Conway WF. Musculoskeletal infections. *Semin Roentgenol*. 2007;42(2):92-101.
- [34] Pineda C, Espinosa R, Pena A. Radiographic imaging in osteomyelitis: the role of plain radiography, computed tomography, ultrasonography, magnetic resonance imaging, and scintigraphy. *Semin Plast Surg*. 2009;23(2):80-9.
- [35] Kothari NA, Pelchovitz DJ, Meyer JS. Imaging of musculoskeletal infections. *Radiol Clin North Am*. 2001;39(4):653-71.
- [36] Mah ET, LeQuesne GW, Gent RJ, Paterson DC. Ultrasonic features of acute osteomyelitis in children. *J Bone Joint Surg Br*. 1994;76(6):969-74.
- [37] Howard CB, Einhorn M, Dagan R, Nyska M. Ultrasound in diagnosis and management of acute haematogenous osteomyelitis in children. *J Bone Joint Surg Br*. 1993;75(1):79-82.
- [38] Abiri MM, Kirpekar M, Ablow RC. Osteomyelitis: detection with US. *Radiology*. 1989;172(2):509-11.
- [39] Zawin JK, Hoffer FA, Rand FF, Teele RL. Joint effusion in children with an irritable hip: US diagnosis and aspiration. *Radiology*. 1993;187(2):459-63.
- [40] Vasquez M. Osteomyelitis in children. *Current Opinions in Pediatrics*, 2002;14: 112-5. 7
- [41] Kleinman PK. A regional approach to osteomyelitis of the lower extremities in children. *Radiol Clin North Am*. 2002;40(5):1033-59.
- [42] Pineda C, Vargas A, Rodríguez AV. Imaging of osteomyelitis: current concepts. *Infect Dis Clin North Am*. 2006;20(4):789-825.
- [43] Mandell GA. Imaging in the diagnosis of musculoskeletal infections in children. *Curr Probl Pediatr*. 1996;26(7):218-37.
- [44] Kocher MS, Lee B, Dolan M, Weinberg J, Shulman ST. Pediatric orthopedic infections: early detection and treatment. *Pediatr Ann*. 2006;35(2):112-22.
- [45] Dangman BC, Hoffer FA, Rand FF, O'Rourke EJ. Osteomyelitis in children: gadolinium-enhanced MR imaging. *Radiology*. 1992;182(3):743-7.
- [46] Mazur JM, Ross G, Cummings J, Hahn GA Jr, McCluskey WP. Usefulness of magnetic resonance imaging for the diagnosis of acute musculoskeletal infections in children. *J Pediatr Orthop*. 1995;15(2):144-7.
- [47] Oudjhane K, Azouz EM. Imaging of osteomyelitis in children. *Radiol Clin North Am*. 2001;39(2):251-66.
- [48] Jaramillo D, Treves ST, Kasser JR, Harper M, Sundel R, Laor T. Osteomyelitis and septic arthritis in children: appropriate use of imaging to guide treatment. *AJR Am J Roentgenol*. 1995;165(2):399-403.

- [49] Ranson M. Imaging of pediatric musculoskeletal infection. *Semin Musculoskelet Radiol.* 2009;13(3):277-99.
- [50] Guilbert J, Meau-Petit V, de Labriolle-Vaylet C, Vu-Thien H, Renolleau S. Coagulase-negative staphylococcal osteomyelitis in preterm infants: a proposal for a diagnostic procedure. *Arch Pediatr.* 2010;17(10):1473-6.
- [51] Gutierrez K. Bone and joint infections in children. *Pediatr Clin North Am.* 2005;52(3):779-94.
- [52] Faust SN, Clark J, Pallett A, Clarke NM. Managing bone and joint infection in children. *Arch Dis Child.* 2012 Jun;97(6):545-53.
- [53] Kaye JJ, Winchester PH, Freiburger RH. Neonatal septic "dislocation" of the hip: true dislocation or pathological epiphyseal separation. *Radiology* 1975;114:671-674).