

We are IntechOpen, the world's leading publisher of Open Access books Built by scientists, for scientists

4,800

Open access books available

122,000

International authors and editors

135M

Downloads

Our authors are among the

154

Countries delivered to

TOP 1%

most cited scientists

12.2%

Contributors from top 500 universities



WEB OF SCIENCE™

Selection of our books indexed in the Book Citation Index
in Web of Science™ Core Collection (BKCI)

Interested in publishing with us?
Contact book.department@intechopen.com

Numbers displayed above are based on latest data collected.
For more information visit www.intechopen.com



Neuroblastoma: The Clinical Aspects

Neema Bhat and Lisa McGregor

Additional information is available at the end of the chapter

<http://dx.doi.org/10.5772/intechopen.70486>

Abstract

Neuroblastoma is a predominantly pediatric cancer, arising from the primordial neural crest cells that form the sympathetic nervous system. The prognosis for patients with neuroblastoma can vary from uniform survival in low risk patients to fatality in patients with high risk disease. This chapter gives a brief overview of the epidemiology, genetics, clinical presentation, diagnosis, and discussion of the various staging systems and risk classifications of neuroblastoma. We also briefly describe our understanding of the conventional and novel treatment modalities available and their effects on the current prognosis of patients with neuroblastoma. The purpose of this chapter is to serve as a brief overview of the clinical aspects of neuroblastoma, to serve as a foundation of knowledge for scientists aspiring to develop new therapeutic modalities for this dreadful pediatric disease.

Keywords: neuroblastoma, epidemiology, clinical presentation, diagnosis, clinical staging and risk stratification, prognosis, current treatment modalities, novel and targeted therapy

1. Introduction

Neuroblastoma is a neoplasm arising from the primordial neural crest cells that form the sympathetic nervous system. It is a cancer predominantly seen in pediatric patients. It is the most common extracranial malignancy of childhood and the most common solid tumor of infancy [1]. It is one of the most enigmatic tumors with extremely heterogeneous clinical behavior that ranges from spontaneous regression to metastatic disease refractory to therapy. It accounts for about 7% of all childhood malignancies; however 10% of childhood cancer related mortality. Treatment approaches have been based on presence or absence of specific clinical or biologic factors. Although substantial progress has been made in the treatment and outcomes for low and intermediate risk neuroblastoma, success in therapy of high risk neuroblastoma remains

evasive and complicated. Patients with low and intermediate risk neuroblastoma have an overall survival rate exceeding 90% and are now moving toward minimization of therapy [2]. However in spite of standard therapy for high risk neuroblastoma patients involving multi-agent chemotherapy induction, surgery and external beam radiotherapy, myeloablative chemotherapy with autologous hematopoietic stem cell rescue and biologic agents, only 50% of patients with newly diagnosed high risk disease will survive [2].

1.1. Origin and embryology

The neural crest is an embryonic structure formed at the beginning of the 4th week of human development. These cells migrate to the trunk to form the sympathetic ganglia and adrenal medulla, however little is known about the molecular events governing the formation and migration of these cells.

However it is important to note that although Neuroblastoma tumors can have neural crest cell traits, they also share properties of extra-adrenal chromaffin cells as reviewed in [3].

1.2. Epidemiology

The incidence of neuroblastoma is 10.5 per million children between 0 and 14 years of age in North America and Europe. There is a slight male preponderance of 1.2:1.0 [1]. The median age of diagnosis for neuroblastoma in patients is 19 months (ranging from 0 to 4 years). In fact one study reported that 16% of infant neuroblastomas were diagnosed during the 1st month of life (i.e. neonatal) and 41% during the first 3 months [4]. Less than 5% of neuroblastomas are diagnosed at 10 years of age or older [5]. Although there are no significant geographic variations in the incidence, African American and Native American patients are more likely to have high risk disease features and poor outcomes due to genetic differences [6].

1.3. Genetics

Genetics form a major part of risk stratification, targeted treatment and prognosis markers for neuroblastoma. Although *MYCN* amplification was found as early as in 1983, the finding of further genes involved in oncogenesis took much longer [7]. However, over the past decade this has changed significantly, due to the advances made in exome and whole-genome sequencing [7]. In addition to *MYCN*, two other oncogenes, *ALK* [8] and *LIN28B* [9] were also found to be amplified, although in much lower frequency.

1.4. Oncodriver genes in neuroblastoma

1.4.1. *MYCN*

Karyotyping on neuroblastoma was frequently found to reveal gene amplifications. The *MYC* related oncogene *MYCN* (2p24) was originally identified by Schwab and colleagues [10, 11] as a target of this amplification event. It was later found that amplification of *MYCN* is associated with advanced stages of disease, unfavorable biologic features and poor prognosis [12, 13].

It was also found to be independently associated with poor outcome in otherwise favorable patient groups [14, 15]. At present, the *MYCN* gene status is determined routinely at diagnosis for therapy planning. Fluorescent in situ hybridization is the preferred technique for detection of *MYCN* amplification. Most groups define amplification as >4 times the number of *MYCN* copies as compared to a control probe. In most tumors with *MYCN* amplification, the copy number is often as high as 50–400 copies/cell. *MYCN* amplification has been found to be a mutation present at diagnosis and not one that is acquired with tumor progression. *MYCN* is a member of the proto-oncogene family and is responsible for expression of approximately 15% of all human genes. Hence overexpression causes a significant impact on cell behaviors.

1.4.2. *ALK*

The developing nervous system has been found to express a cell surface receptor tyrosine kinase controlled by the *ALK* (Anaplastic Lymphoma Kinase) gene [16]. Germline *ALK* mutations are the major cause of hereditary neuroblastoma as described below, however somatically acquired *ALK*-activating mutations are also found as oncogenic drivers in 8–10% of sporadic neuroblastoma [16]. In combination with tumors that also exhibit *MYCN* amplification, 10–14% of neuroblastoma tumors have an *ALK* alteration that may serve as a novel therapeutic target. Crizotinib (one of the first *ALK* inhibitors) is currently being tested in neuroblastoma [17].

1.5. Hereditary predisposition to neuroblastoma and associated syndromes

The incidence of familial neuroblastoma is estimated to be 1–2% [1]. It is very unusual for an individual neuroblastoma patient to have a family history positive for neuroblastoma [18]. Analysis of rare family pedigree charts, are strongly supportive of an autosomal dominant inheritance with incomplete penetrance [8, 19]. Familial disease has the same diverse clinical behavior as sporadic neuroblastoma, ranging from aggressive progression to spontaneous regression. Genetic cases most often are seen to have multifocal and/or bilateral adrenal primary tumors. The median age of onset for familial neuroblastoma is at around 9 months of age. Familial neuroblastoma patients differ from their sporadic counterparts in that they are diagnosed at an earlier age and/or with multiple primary tumors and are associated with other cancer predisposition syndromes [20–22].

Missense, nonsense and polyalanine repeat expansion mutations in *PHOX2B* were collectively found to be responsible for approximately 5% of hereditary neuroblastomas [23]. *PHOX2B* is a homeobox gene and is a key regulator of normal autonomic nervous system development and inactivating mutations of this gene account for this rare field defect of sympathoadrenal tissues.

Detailed studies involving familial pedigrees identified germ line mutations in the tyrosine kinase domain of the Anaplastic Lymphoma Kinase (*ALK*) oncogene [24]. Sporadic neuroblastoma tumors also can harbor *ALK* abnormalities in about 8–12% cases. Hence, collectively, gain of function mutations in *ALK* or inactivating mutations of *PHOX2B* account for 80–85% of hereditary neuroblastomas. Therefore genetic testing for mutations in these two

genes should be strongly considered in a patient who has a family history of neuroblastoma or has evidence of multiple primary tumors like bilateral adrenal tumors. If these mutations are found, these patients should be followed by appropriate genetic counseling and should be closely monitored as per cancer surveillance protocols. However there are still 15–20% of hereditary neuroblastoma cases still unaccounted for by these mutations, making it likely that one or more additional predisposition genes perhaps remain to be discovered.

From literature and multiple case reviews and review of family pedigree charts, it is now known that neuroblastoma can occur in other neural crest disorders (like Hirschsprung disease, Central Hypoventilation Syndrome and Neurofibromatosis NF1) [20]. These conditions have been given the collective term Neurocristopathy syndromes and can have difference therapeutic implications.

In addition to the Neurocristopathy syndromes, NB cases are also seen in other familial cancer syndromes like Beckwith-Weidemann syndrome (art2ref38), Noonan syndrome, Li-Fraumeni syndrome [25, 26], Fanconi anemia and other chromosomal breakage syndromes [21, 27].

2. Clinical presentation

Clinical presentation in patients with neuroblastoma varies based on the primary tumor locations which may occur anywhere along the sympathetic chain and on the extent of disease. The clinical presentation can be varied and is a combination of symptoms from the primary tumor and metastatic disease.

2.1. Localized disease

Most of the primary tumors arise in the abdomen (75%) of which a vast majority of them involve the adrenal gland. Frequency of adrenal tumors in older children is higher (40%) compared to infants (25%), infants tend to have more cervical and thoracic tumors [18].

Patients with primary adrenal tumors may have a varying range of symptoms from being asymptomatic or can be associated with hypertension, abdominal pain, distension and constipation. Sudden hemorrhage into the tumor may cause sudden severe abdominal pain due to stretching of the tumor capsule. If primary tumors arise from the organ of Zuckerkandl, bladder and bowel symptoms may also be seen due to direct compression.

Primary thoracic tumors may be discovered as incidental findings or can be asymptomatic. Higher thoracic and cervical masses can also lead to Horner's syndrome (associated with unilateral ptosis, miosis and anhidrosis), superior vena cava syndrome or respiratory distress due to pressure on surrounding structures.

Paraspinal tumors can also have epidural or intradural extension and can cause symptoms from compression of nerve roots and spinal cord. These symptoms can include paraplegia, bladder or bowel dysfunction or radicular nerve pain. Spinal cord compression can become a medical emergency in some patients with neuroblastoma (**Table 1**).

| Location of tumor or area of metastatic involvement | Signs and symptoms |
|---|---|
| Abdomen/pelvis | Distension, constipation, urinary retention, pain, hypertension (due to renal vein compression) |
| Thorax | Respiratory distress, superior vena cava syndrome, Horner's syndrome |
| Neck | Swelling |
| Presacral/paraspinal tumors | Urinary retention, paraplegia/paresis, clonus |
| Metastases | Bone pain, irritability, cytopenias (anemia causing pallor, petechiae), periorbital ecchymoses, weight loss, fever |
| 4S/4M metastases | Hepatomegaly, hyperbilirubinemia, coagulopathy, bluish skin nodules, respiratory distress due to abdominal distension |
| Paraneoplastic syndromes | VIP secreting tumors: intractable diarrhea OMS: myoclonic jerking and random eye movements |

Table 1. Neuroblastoma symptomatology.

2.2. Metastatic disease

Approximately half of the patients present with metastasis. Metastasis can be lymphatic or hematogenous. Distant metastatic sites include cortex of bones, bone marrow, liver and non-contiguous lymph nodes. Neuroblastoma usually spreads to metaphyseal, skull and orbital bones. This can hence lead to symptoms of periorbital ecchymosis (raccoon eyes), proptosis and visual impairment. Children with metastatic tumors can be quite ill appearing at presentation as opposed to the relative benign nature of presentation of children with localized disease and can have fever, generalized body pain (due to bony metastases), weight loss and irritability. Other sites of distant metastasis can be in the lungs or intracranial. Clinical syndromes or paraneoplastic syndromes known to be associated with the presentation of neuroblastoma are summarized in **Table 2**.

2.3. Stage 4S neuroblastoma

The strikingly different phenotype of neuroblastoma is called 4S (S: special). It is a unique presentation of neuroblastoma seen in infants. This is seen to occur in about 5% cases of neuroblastoma [18]. These infants usually have small localized primary tumors; however have diffuse metastatic involvement at presentation. Metastatic sites can include diffuse involvement of liver, hepatomegaly, sometimes significant enough to cause respiratory compromise, diffuse subcutaneous nodules due to metastasis to skin, metastases to the bone marrow.

2.4. Paraneoplastic syndromes

There are two well described, but rare paraneoplastic syndromes associated with neuroblastoma, secretory diarrhea (due to production of vasoactive intestinal peptide from the tumor) and opsoclonus myoclonus ataxia syndrome (OMS). OMS consists of opsoclonus

| Eponym | Features associated with syndrome |
|--------------------------------------|---|
| Pepper syndrome | Involvement of the liver with metastatic disease with or without respiratory distress |
| Horner syndrome | Unilateral ptosis, myosis, and anhidrosis associated with a thoracic or cervical primary tumor. Symptoms tend to persist following tumor resection |
| Hutchinson syndrome | Limping and irritability in young child seen with bone and bone marrow metastases |
| Opsoclonus myoclonus ataxia syndrome | Random eye movement and myoclonic jerking in the presence or absence of cerebellar ataxia. Usually associated with a biologically favorable and differentiated tumor. The condition is thought to be immune mediated. It may not resolve with tumor removal, and exhibits progressive neuropsychological sequelae |
| Kerner-Morrison syndrome | Intractable secretory diarrhea due to tumor secretion of vasointestinal peptides |
| Neurocristopathy syndrome | Neuroblastoma associated with other neural crest disorders, including congenital hypoventilation syndrome or Hirshprung disease. Germline mutations in the paired homeobox gene PHOX2B have been identified in a subset of such patients |

Adapted from Ref. [57]. For references, please refer to text.

Table 2. Syndromes associated with neuroblastoma.

(conjugate, multidirectional, chaotic eye movements), myoclonus (non-epileptic limb jerking) and ataxia (loss of balance). Between 1 and 3% of patients with neuroblastoma can have OMS [28, 29]. In most patients, the syndrome itself leads to the diagnosis of neuroblastoma; however it may rarely occur after tumor resection or even at relapse. In at least half of the children affected, OMS is associated with underlying occult or clinically apparent neuroblastoma. Hence, a thorough diagnostic evaluation for neuroblastoma at presentation is necessary in all patients with OMS, after exclusion of central nervous system pathology. A few previously reported series [28, 30, 31] show that 90% of patients presenting with OMS were without metastases at diagnosis, compared to 40–50% with metastases in non-OMS patients. OMS is thought to be due to an antineural antibody that cross-reacts with the antigen on both neuroblastoma and the normal nervous system tissue. Tumor biology, including MYCN copy number and Shimada histopathologic classification are usually favorable in OMS patients, which correlates with the excellent survival rate found in patients with OMS and neuroblastoma [28].

Treatment has been documented with various agents including glucocorticoids, adrenocorticotrophic hormone and intravenous immunoglobulin [29]. However almost 80% of patients will experience relapse of symptoms with weaning of treatment measures or with a viral syndrome. OMS can also be associated with long term chronic neurological complications.

Treatment resistant secretory diarrhea is seen in approximately 4% of patients with neuroblastoma and thought to be due to overproduction of vasoactive intestinal peptide (VIP) by maturing neuroblastoma cells [32, 33]. It is associated with chronic watery diarrhea and failure to thrive. It usually resolves after surgical removal of the primary tumor.

3. Diagnosis

3.1. Diagnostic criteria

Diagnosis of neuroblastoma is most commonly established from histopathologic evaluation of the primary tumor tissue. Most cases can be differentiated based on hematoxylin and eosin staining especially if features of neuronal differentiation are present. In case of minimal differentiation, immunohistochemical staining for neuron-specific enolase, chromogranin A and/or synaptophysin are used.

Diagnosis of neuroblastoma can also be established by a combination of tumor cells detected in the bone marrow and elevated catecholamines or their metabolites [vanillylmandelic acid (VMA), homovanillic acid (HVA) and dopamine]. Urinary VMA and HVA should both be measured for diagnostic purposes and for undifferentiated tumors dopamine may be measured.

3.2. Clinical disease assessment

Clinical evaluation of disease includes cross-sectional imaging of the primary tumor by magnetic resonance imaging (MRI) or computed tomography (CT). This imaging determines the size of the primary tumor, regional extent of the disease, distant metastatic spread to neck, chest, abdomen and pelvis. Bilateral bone marrow biopsies are required to assess for presence of tumor cells in the bone marrow. Radioiodine labeled metaiodobenzylguanidine (MIBG) is a nonrepinephrine analog that selectively concentrates in sympathetic nervous tissues. It can be used to detect primary tumor as well as detect occult soft tissue disease in addition to osteomedullary disease [34]. In the scenario that MIBG is unavailable, technetium bone scan can also be used to detect bony metastases (however is not as sensitive or specific as MIBG). Bone scan or FDG-PET scan are used to assess metastatic disease in patients whose tumors are not MIBG avid.

4. Staging and risk stratification

4.1. Staging

Until recently, the criteria for staging at diagnosis were based on the International Neuroblastoma Staging System (INSS) as shown in **Table 3** [35]. INSS stages 1–3 have localized tumors classified based on the amount of resection, invasion and nodal involvement. Stage 4 is defined as distant metastases; 4S is characterized by metastases to the liver, skin, and/or marrow in infants and is usually associated with favorable biological features and can undergo spontaneous regression.

In 2009, the International Neuroblastoma Risk Group's (INRG) stratification system was developed by a major consortium of North America, Europe, Japan, and Australia. The INRG

| Stage | Description of disease and extension |
|-------|--|
| 1 | Localized tumor with complete gross excision, with or without microscopic residual disease representative ipsilateral lymph nodes negative for tumor microscopically (nodes attached to and removed with the primary tumor may be positive) |
| 2A | Localized tumor with incomplete gross resection; representative ipsilateral nonadherent lymph nodes negative for tumor microscopically |
| 2B | Localized tumor with or without complete gross excision, with ipsilateral nonadherent lymph nodes positive for tumor; enlarged contralateral lymph nodes must be negative microscopically |
| 3 | Unresectable unilateral tumor infiltrating across the midline*, with or without regional lymph node involvement; or localized unilateral tumor with contralateral regional lymph node involvement; or midline tumor with bilateral extension by infiltration (unresectable) or by lymph node involvement |
| 4 | Any primary tumor with dissemination to distant lymph nodes, bone, bone marrow, liver, skin, and/or other organs (except as defined for stage 4S) |
| 4S | Localized primary tumor (as defined for stage 1, 2A or 2B) with dissemination limited to skin, liver, and/or bone marrow# (limited to infants <1 year of age) |

*The midline is the vertebral column. Tumors originating on one side and crossing the midline must infiltrate to or beyond the opposite side of the vertebral column.

#Marrow involvement in 4S should be minimal (<10% of total nucleated cells identified as malignant on bone marrow aspirate or biopsy). More extensive marrow involvement is stage 4.

Data adapted from Ref. [58].

Table 3. International Neuroblastoma Risk Group Staging System (INSS).

staging system is based on imaging criteria and the extent of locoregional disease is determined by the presence or absence of image-defined risk factors. And the extent of locoregional disease is determined by the presence or absence of image-defined risk factors [36] as shown in **Table 4**.

4.2. Risk stratification

Neuroblastoma is classified into low risk, intermediate risk, and high risk based on multiple factors including clinical and biological factors that have been shown to predict prognosis and the risk of recurrence. These factors include age, stage, histology, DNA index, and MYCN amplification (MYCNA) and are used to assign treatment groups by the Children's Oncology Group [1]. The INRG developed classification system defines similar cohorts using the INRG database of 8800 patients treated between 1990 and 2002. This now helps facilitate comparisons across international clinical trials (**Table 5**) [37].

4.2.1. Prognostic variables of neuroblastoma

Multiple variables are used for risk prediction and as prognostic markers of neuroblastoma. The most commonly used prognostic markers used in all cooperative groups are discussed here.

Stage: Stage of the disease using the INSS system has been correlated with patient outcome and used by all cooperative groups to risk stratify. Most patients with INSS stage 1 are cured by surgery alone, and most patients with stage 4 require highly intensive, multimodality therapy.

For the stages in between, therapy is based on other biologic factors. As the genetic and biologic characteristics of neuroblastoma are better defined, we will likely rely more on them and less on the disease stage or histology.

Ipsilateral tumor extension within two body compartments

Neck-chest, chest-abdomen, abdomen-pelvis

Neck

Encases carotid and/or vertebral artery and/or internal jugular vein; extends to skull base; compresses trachea

Cervicothoracic junction

Encases brachial plexus roots or subclavian vessels and/or vertebral or carotid artery; compresses trachea

Thorax

Encases the aorta and/or major branches; compresses trachea and/or principal bronchi; lower mediastinal tumor infiltrating costovertebral junction between T9 and 12

Thoracoabdominal

Encases the aorta and/or vena cava

Abdomen/pelvis

Infiltrates the porta hepatis and/or the hepatoduodenal ligament; encases branches of the superior mesenteric artery at the mesenteric root or origin of celiac axis and/or superior mesenteric artery; invades one or both renal pedicles; encases aorta and/or vena cava or iliac vessels, crossing sciatic notch

Intraspinal tumor extension whatever the location provided that

More than one-third of the spinal canal in the axial plane invaded and/or the perimedullary leptomeningeal spaces not visible and/or the spinal cord signal abnormal

Infiltration of adjacent organs/structures

Pericardium, diaphragm, kidney, liver, duodeno-pancreatic block, and mesentery

IDRFs are used to determine the ability to completely resect locoregional tumors at diagnosis based on surgical risk factors that can be defined by IDRFs detected on cross-sectional imaging with CT and/or MRI

Data adapted from Ref. [59].

Table 4. Image defined risk factors.

| Stage | Description |
|-------|--|
| L1 | Localized tumor not involving vital structures as defined by the list of image-defined risk factors and confined to one body compartment |
| L2 | Locoregional tumor with presence of one or more IDRFs |
| M | Distant metastatic disease (except stage MS) |
| MS | Metastatic disease in children younger than 18 mo. with metastases confined to skin, liver, and/or bone marrow |

Data adapted from Ref. [59].

Table 5. International risk group staging system (INRGSS).

| INRG stage | Age (months) | Histology | Grade of tumor differentiation | MYCN | 11q aberration | Ploidy | Pretreatment risk group |
|------------|--------------|---|--|-----------------|----------------|--------|-----------------------------|
| L1/L2 | | GN maturing, GNB intermixed | | | | | Very low |
| L1 | | Any, except GN maturing or GNB intermixed | | | | | Very low High |
| L2 | <18 M | Any, except GN maturing or GNB intermixed | | NA | No Yes | | Low Intermediate |
| | ≥18M | GNB nodular neuroblastoma | Differentiating Poorly differentiated or undifferentiated | NA Amplified | Yes | | Low Intermediate High |
| M | <18 | | | NA | | HD | Low |
| | <12 | | | NA | | D | Intermediate |
| | 12–<18 | | | NA | | D | Intermediate |
| | <18 | | | Amplified | | | High |
| | ≥18 | | | | | | High |
| MS | <18 | | | NA | No Yes | | Very low High High |

Classification schema is based on analysis of 8800 patients in the INRG database (1990–2002). Risk groups are very low risk (5-year event-free survival [EFS] >85%); low risk (5-year EFS >75–85%); IR (5-year EFS 50–75%); HR (5-year EFS <50%).

Abbreviations: GN: ganglioneuroma; GNB: ganglioneuroblastoma; INRG: International Neuroblastoma Risk Group; NA: not amplified; HD: hyperdiploid; D: diploid.

Adapted from Ref. [60].

Table 6. International Neuroblastoma Risk Group pretreatment classification scheme.

Age: Age was one of the first and most important prognostic factors identified. Patients younger than 18 months of age have a much better prognosis compared to the older patients [38, 39], especially for patients between 12 and 18 months of age with biologically favorable disease. Older children, adolescents and young adults have a more indolent course and far worse outcomes [40].

Pathology: Shimada proposed a histology-based classification of tumors into “favorable” and “unfavorable” by combining age with extent of tumor differentiation, Schwannian components in tumor and degree of mitosis [1].

Biologic factors: Current risk stratification for neuroblastoma includes *MYCN* copies by fluorescent in situ hybridization, DNA ploidy by flow cytometry and tumor histology. *MYCN* (*MYCN* amplification) is defined as greater than 10 copies and is detected in almost 20% of neuroblastoma tumors with a higher incidence in INSS stages 3 and 4, but only 5% of stages

1, 2 and 4S [36]. Multiple studies so far have demonstrated that patients with *MYCNA* have a significantly worse outcome [14, 15, 41].

A systematic review from a literature search of prognostic tumor markers in neuroblastoma was published, and reported 31 important prognostic factors each reported in five or more papers [42]. Meta-analysis of these markers showed that *MYCN* and DNA ploidy had the strongest prognostic impact. Most neuroblastomas have a nuclear DNA content in the diploid range. Tumors from patients who have lower stages of disease will often be hyperdiploid (DNA index > 1) or near triploid. DNA content is most significant as a prognostic marker in infants and patients with localized disease [1]. Other most commonly deleted chromosomal regions in neuroblastoma include 1p, 4p, 11q, 14q. Recurrent mutations are not frequent in neuroblastoma. Hence the identification of genes and signaling pathways with altered expression continue to be discovered and used to add additional value to prognostic factors and therapeutic targets involved in neuroblastoma apoptosis, drug resistance, angiogenesis, metastasis and inflammation [3, 43].

These factors were then combined to form a pre-treatment Risk Group Stratification as shown in **Table 6**.

5. Conventional treatment of neuroblastoma

The diagnosis and treatment of neuroblastoma is a multidisciplinary approach. Risk stratification is the first and most important step of treatment planning. It includes surgical biopsy especially to assess tumor genetic and histologic features, most importantly in patients less than 18 months with metastatic disease.

5.1. Treatment of low and intermediate risk neuroblastoma

Patients with low- or intermediate-risk neuroblastoma have excellent outcomes, and a series of cooperative group trials evaluating reductions in therapy using risk-based treatment approaches for these children has led to decreased therapy-related toxicities and improved outcomes. Survival rates for patients with INSS stage 1 disease are excellent with surgery alone and rare recurrences can be cured easily with salvage chemotherapy [44]. Survival rate for these groups with surgery alone is as high as 95%. For patients with INSS stage 1, 2A, 2B chemotherapy is reserved for patients with localized neuroblastoma with life threatening symptoms, or even for patients who experience recurrence or progressive disease.

Stage 4S neuroblastoma without *MYCNA*, undergo spontaneous regression. Chemotherapy or even low dose radiation can be used for large tumors causing symptoms or massive hepatomegaly [45].

Patients with intermediate risk disease which includes patients with INSS stage 3 and infants with stage 4/M and favorable biologic features are treated with regimens using surgical resection and moderate dose chemotherapy as the backbone. Patients with favorable tumor characteristics

including infants with stage 4/M without MYCNA, the survival rates for surgery combined with moderate dose chemotherapy is greater than 90% [46].

5.2. Treatment of high risk neuroblastoma

Current treatment strategies for high risk neuroblastoma consist of three phases: induction phase, which consists of removal of gross tumor and achieving local control. The second phase of consolidation is to treat remaining chemotherapy-exposed cells to achieve lowest possible residual disease. Post-consolidation or maintenance phase is finally for treatment of the minimal residual disease. A general overview of the current day standard of care treatment strategy is described in **Figure 1**.

5.2.1. Induction therapy

Standard Children's Oncology Group (COG) induction regimens include various combinations of alkylators, anthracyclines, topoisomerase I and II inhibitors, platinum compounds delivered in 21 day cycles for 5–6 cycles. A successful induction which leads to complete remission (CR) or very good partial remission (VGPR) has been shown to correlate with improved overall survival. Following five cycles of induction chemotherapy, local control of primary tumor site is achieved with a combination of aggressive surgical resection and radiation therapy to the surgical bed. Surgery is performed after four to six cycles of induction chemotherapy to improve resectability and minimize surgery related complications. Complete tumor resection appears to correlate with improved local control and also significantly improved event-free survival (EFS) [47].

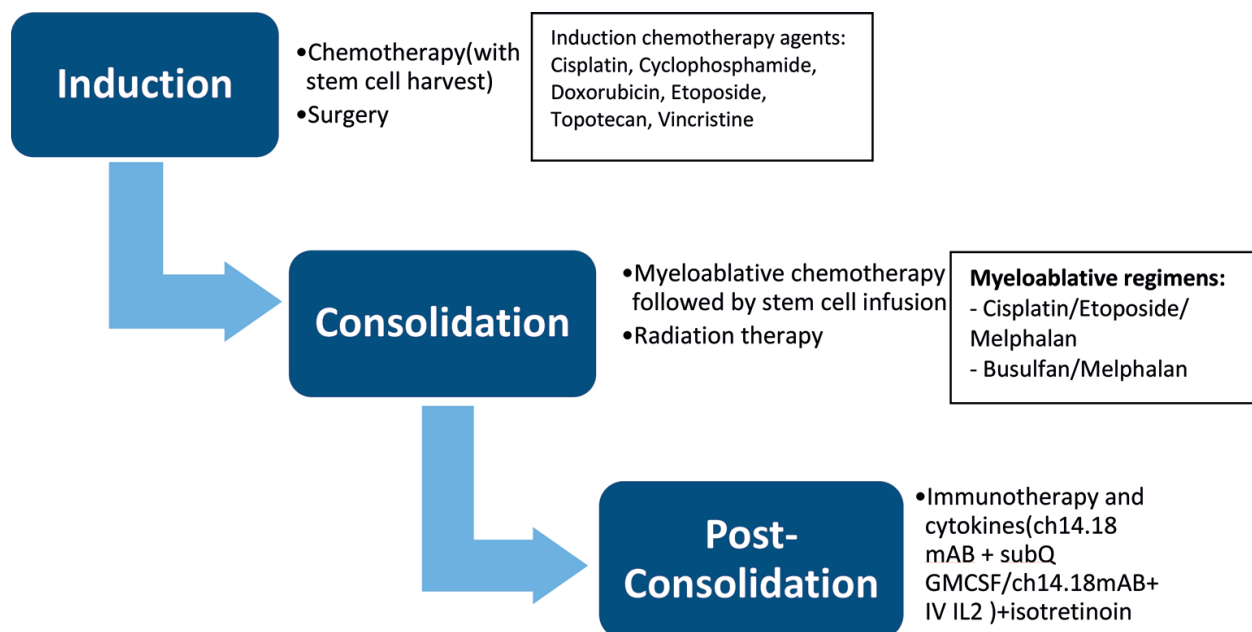


Figure 1. Treatment strategy currently used for patients with high risk neuroblastoma. ch14.18: chimeric 14.18, mAB: monoclonal antibody, GMCSF: granulocyte-macrophage colony stimulating factor, IL-2: interleukin-2.

5.2.2. Consolidation therapy

Several clinical trials performed in North America, Germany and Europe over the past 20 years has demonstrated improved outcomes following myeloablative therapy with autologous stem cell rescue. A Cochrane systems meta-analysis review by Yalçın et al. revealed that myeloablative chemotherapy has improved EFS [48]. The North American groups have traditionally used cyclophosphamide/etoposide/Melphalan for chemotherapy, whereas the European group (SIOPEN) data results suggest that patients randomized to the Busulfan/Melphalan arm had superior outcomes [49]. Another Children’s Oncology Group Study ANBL0532 also studied differences in outcomes between patients receiving single vs tandem myeloablative transplants (**Figure 2**) and found that 3-year event-free survival was significantly better in the tandem group than in the single group (61.4% vs 48.4%; $P = 0.0081$). There was a nonsignificant trend toward better 3-year overall survival in the tandem group than in the single group before immunotherapy (74.0% vs 69.1%; $P = 0.1850$).

Consolidation therapy also consists of radiation to the primary site, as neuroblastoma is one of the most radio-sensitive pediatric tumors. Doses of 2160 cGy (centiGray) in daily 180 cGy fractions to the primary sites decreases local recurrence rates [50]. Radiation is also delivered to MIBG-avid metastatic sites, with a recent report suggesting that non-irradiated lesions have a higher risk of involvement at the time of relapse [51].

5.2.3. Post-consolidation biologic and immunotherapies

Following surgery and high dose chemotherapy followed by autologous stem cell rescue, treatment with synthetic retinoid isotretinoin (cis-retinoic acid) showed significantly promising

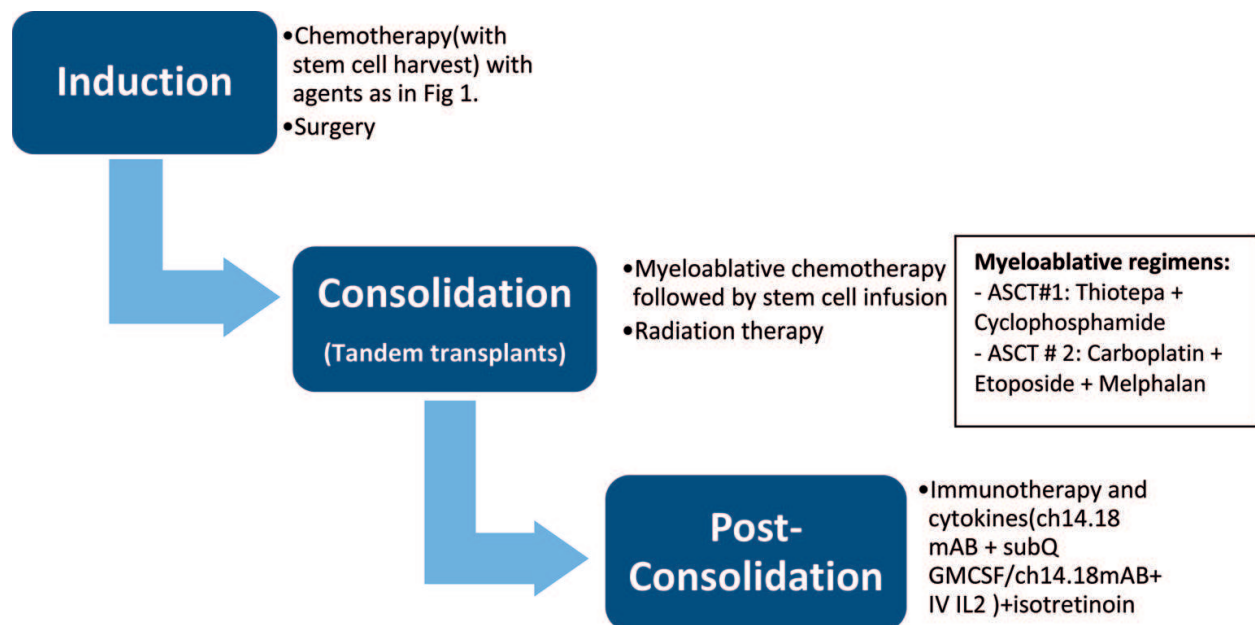


Figure 2. Tandem autologous stem cell transplant regimen used for patients with high risk neuroblastoma. ASCT: autologous stem cell transplant, ch14.18: chimeric 14.18, mAB: monoclonal antibody, GMCSF: granulocyte-macrophage colony stimulating factor, IL-2: interleukin-2.

results and is hence an established as standard of care [52]. Another randomized control trial also demonstrated that the addition of anti-GD2 chimeric monoclonal antibody (mAB) with cytokines (granulocyte-macrophage colony stimulating factor and interleukin 2) improved survival [53]. Additional studies have also shown the benefit of immunotherapy at diagnosis as well as first recurrence of disease. However this regimen has multiple side effects: fever, allergic reactions, hypotension, pain, capillary leak syndrome.

In spite of all the therapeutic modalities explained above directed at high risk neuroblastoma, even-free survival for these patients is only 40–50%. In the INRG data set, overall survival for patients who relapse after treatment for low/intermediate risk disease was 65%, 5 years after recurrence, but for patients with high risk/metastatic disease, the 5-year overall survival was only 8% after recurrence. There is hence a real need for potential new targeted therapy and also alternative therapies to improve chemo-sensitivity in these patients with high risk neuroblastoma.

6. Novel therapeutic interventions

Relapse strategies are divided into chemotherapy, immunotherapy, MIBG/radioisotopes and targeted therapies. These therapies are mostly being tested in Phase I and II trials in patients with recurrent or relapsed neuroblastoma.

6.1. Immunotherapeutic targets

Due to the initial success of passive immunotherapy with anti-GD2 antibody chimeric 14.18 in high risk neuroblastoma, there has been a surge in the development of additional immunotherapeutic modalities. Clinical trials evaluating anti-GD2 therapeutics and chemotherapy (irinotecan plus temozolomide; COG ANBL1221) or the immunostimulatory molecule lenalidomide are under way. Additional pilot studies evaluating monoclonal antibody 1A7 as a surrogate GD2 vaccine and active immunization against GD2 and GD3 combined with the immunostimulant beta-glucan in patients with complete or very good partial remission have shown encouraging results. There is also increasing interest in chimeric antigen receptor expressing autologous T cells for cellular-based therapy in neuroblastoma [54]. In addition to chimeric T cells, infusions of natural killer cells, dendritic cells are also under investigation, especially in patients with relapsed disease.

6.2. Targeted radiotherapy

^{131}I -mIBG (^{131}I iodized- metaiodobenzylguanidine) is a beta particle-emitting norepinephrine analog which is taken up by cells expressing the norepinephrine transporter. It has been one of the earliest and most successful therapies for relapsed neuroblastoma. ^{131}I -mIBG has the properties of excellent tumor targeting, the potential of delivering high levels of absorbed radiation to tumors in soft tissue, bone and bone marrow. It is also rapidly cleared by the kidneys, hence making it an ideal therapeutic agent in mIBG-avid neuroblastoma and pheochromocytoma. Previously, studied as an agent in patients with relapsed or refractory disease, it is now being

incorporated as part of induction therapy in those with mIBG-avid neuroblastoma. After years of being studied to establish safety and efficacy, ^{131}I -mIBG therapies is now being studied in combination with other chemotherapy agents, radio sensitizers, hyperbaric oxygen, gene therapy or ionizing radiation from external beam radiation. A brilliant review of this subject is presented in the article by Streby et al. [55]. A recent Children's Oncology Group Study is investigating the effects of administering ^{131}I I-mIBG in combination with induction chemotherapy (in patients with mIBG sensitive tumors at diagnosis).

6.3. Molecular guided targeted therapy

Several potential molecular targets and inhibitors are now being tested especially in preclinical and Phase I trials. A small subset of ALK aberrant tumors can be targeted with ALK inhibitors [16]. For patients harboring *MYCNA*, preclinical studies are suggestive of bromodomain and extraterminal domain inhibitors (BET inhibitors) inducing cell death by interfering with *MYCN* transcription [56].

Other agents that target cell cycle, angiogenesis and cell differentiation are also currently under investigation and awaiting further preclinical and preliminary clinical studies.

Due to the variety of therapy options that are under study, it appears that most future clinical trials will incorporate a salient novel agent in combination with common chemotherapy as backbone regimens.

Author details

Neema Bhat* and Lisa McGregor

*Address all correspondence to: neema.bhat@outlook.com

Penn State Health Center, Hershey, Pennsylvania, USA

References

- [1] Irwin MS, Park JR. Neuroblastoma: Paradigm for precision medicine. *Pediatric Clinics of North America*. 2015 Feb;**62**(1):225-256
- [2] Park JR, Bagatell R, London WB, Maris JM, Cohn SL, Mattay KK, et al. Children's Oncology Group's 2013 blueprint for research: Neuroblastoma. *Pediatric Blood & Cancer*. 2013 Jun;**60**(6):985-993
- [3] Cheung N-KV, Dyer MA. Neuroblastoma: Developmental biology, cancer genomics and immunotherapy. *Nature Reviews Cancer*. 2013 Jun;**13**(6):397-411
- [4] Dhir S, Wheeler K. Neonatal neuroblastoma. *Early Human Development*. 2010 Oct;**86**(10):601-605

- [5] Heck JE, Ritz B, Hung RJ, Hashibe M, Boffetta P. The epidemiology of neuroblastoma: A review. *Paediatric and Perinatal Epidemiology*. 2009 Mar;**23**(2):125-143
- [6] Johnson KA, Aplenc R, Bagatell R. Survival by race among children with extracranial solid tumors in the United States between 1985 and 2005. *Pediatric Blood & Cancer*. 2011 Mar;**56**(3):425-431
- [7] Speleman F, Park JR, Henderson TO. Neuroblastoma: A tough nut to crack. American Society of Clinical Oncology educational book. American Society of Clinical Oncology Meeting. 2016;**35**:e548-e557
- [8] Mossé YP, Laudenslager M, Longo L, Cole KA, Wood A, Attiyeh EF, et al. Identification of ALK as a major familial neuroblastoma predisposition gene. *Nature*. 2008 Oct 16;**455**(7215):930-935
- [9] Molenaar JJ, Domingo-Fernández R, Ebus ME, Lindner S, Koster J, Drabek K, et al. LIN28B induces neuroblastoma and enhances MYCN levels via let-7 suppression. *Nature Genetics*. 2012 Nov;**44**(11):1199-1206
- [10] Schwab M, Alitalo K, Klempnauer KH, Varmus HE, Bishop JM, Gilbert F, et al. Amplified DNA with limited homology to myc cellular oncogene is shared by human neuroblastoma cell lines and a neuroblastoma tumour. *Nature*. 1983 Sep 15;**305**(5931):245-248
- [11] Schwab M, Varmus HE, Bishop JM, Grzeschik KH, Naylor SL, Sakaguchi AY, et al. Chromosome localization in normal human cells and neuroblastomas of a gene related to c-myc. *Nature*. 1984 Mar 15;**308**(5956):288-291
- [12] Seeger RC, Brodeur GM, Sather H, Dalton A, Siegel SE, Wong KY, et al. Association of multiple copies of the N-myc oncogene with rapid progression of neuroblastomas. *The New England Journal of Medicine*. 1985 Oct 31;**313**(18):1111-1116
- [13] Schmidt ML, Lukens JN, Seeger RC, Brodeur GM, Shimada H, Gerbing RB, et al. Biologic factors determine prognosis in infants with stage IV neuroblastoma: A prospective Children's Cancer Group study. *Journal of Clinical Oncology : Official Journal of the American Society of Clinical Oncology*. 2000 Mar;**18**(6):1260-1268
- [14] Maris JM, Hogarty MD, Bagatell R, Cohn SL. Neuroblastoma. *The Lancet London England*. 2007 Jun 23;**369**(9579):2106-2120
- [15] Huang M, Weiss WA. Neuroblastoma and MYCN. *Cold Spring Harbor Perspectives in Medicine*. 2013 Oct 1;**3**(10):a014415
- [16] Carpenter EL, Mossé YP. Targeting ALK in neuroblastoma—Preclinical and clinical advancements. *Nature Reviews. Clinical Oncology*. 2012 May 15;**9**(7):391-399
- [17] Mossé YP, Lim MS, Voss SD, Wilner K, Ruffner K, Laliberte J, et al. Safety and activity of crizotinib for paediatric patients with refractory solid tumours or anaplastic large-cell lymphoma: A Children's Oncology Group phase 1 consortium study. *The Lancet Oncology*. 2013 May;**14**(6):472-480

- [18] Pizzo PA PD. Neuroblastoma. In: Principles and Practice of Pediatric Oncology. 7th ed. Philadelphia: Lippincott Williams & Wilkins; 2016. pp. 777-778
- [19] Kushner BH, Gilbert F, Helson L. Familial neuroblastoma. Case reports, literature review, and etiologic considerations. *Cancer*. 1986 May 1;57(9):1887-1893
- [20] Rohrer T, Trachsel D, Engelcke G, Hammer J. Congenital central hypoventilation syndrome associated with Hirschsprung's disease and neuroblastoma: Case of multiple neurocristopathies. *Pediatric Pulmonology*. 2002 Jan;33(1):71-76
- [21] Bissig H, Staehelin F, Tolnay M, Avoledo P, Richter J, Betts D, et al. Co-occurrence of neuroblastoma and nephroblastoma in an infant with Fanconi's anemia. *Human Pathology*. 2002 Oct;33(10):1047-1051
- [22] Perri P, Longo L, McConville C, Cusano R, Rees SA, Seri M, et al. Linkage analysis in families with recurrent neuroblastoma. *Annals of the New York Academy of Sciences*. 2002 Jun;963:74-84
- [23] Perri P, Bachetti T, Longo L, Matera I, Seri M, Tonini GP, et al. PHOX2B mutations and genetic predisposition to neuroblastoma. *Oncogene*. 2005 Apr 21;24(18):3050-3053
- [24] Janoueix-Lerosey I, Lequin D, Brugières L, Ribeiro A, de Pontual L, Combaret V, et al. Somatic and germline activating mutations of the ALK kinase receptor in neuroblastoma. *Nature*. 2008 Oct 16;455(7215):967-970
- [25] Rossbach H-C, Baschinsky D, Wynn T, Obzut D, Sutcliffe M, Tebbi C. Composite adrenal anaplastic neuroblastoma and virilizing adrenocortical tumor with germline TP53 R248W mutation. *Pediatric Blood & Cancer*. 2008 Mar;50(3):681-683
- [26] Birch JM, Alston RD, McNally RJ, Evans DG, Kelsey AM, Harris M, et al. Relative frequency and morphology of cancers in carriers of germline TP53 mutations. *Oncogene*. 2001 Aug 2;20(34):4621-4628
- [27] Reid S, Schindler D, Hanenberg H, Barker K, Hanks S, Kalb R, et al. Biallelic mutations in PALB2 cause Fanconi anemia subtype FA-N and predispose to childhood cancer. *Nature Genetics*. 2007 Feb;39(2):162-164
- [28] Matthay KK, Blaes F, Hero B, Plantaz D, De Alarcon P, Mitchell WG, et al. Opsoclonus myoclonus syndrome in neuroblastoma a report from a workshop on the dancing eyes syndrome at the advances in neuroblastoma meeting in Genoa, Italy, 2004. *Cancer Letters*. 2005 Oct 18;228(1-2):275-282
- [29] Gorman MP. Update on diagnosis, treatment, and prognosis in opsoclonus-myoclonus-ataxia syndrome. *Current Opinion in Pediatrics*. 2010 Dec;22(6):745-750
- [30] Krug P, Schleiermacher G, Michon J, Valteau-Couanet D, Brisse H, Peuchmaur M, et al. Opsoclonus-myoclonus in children associated or not with neuroblastoma. *European Journal of Paediatric Neurology: EJPN: Official Journal of the European Paediatric Neurology Society*. 2010 Sep;14(5):400-409

- [31] Plantaz D, Michon J, Valteau-Couanet D, Coze C, Chastagner P, Bergeron C, et al. Opsoclonus-myoclonus syndrome associated with non-metastatic neuroblastoma. Long-term survival. Study of the French Society of Pediatric Oncologists. *Archives de Pédiatrie Organe Officiel De La Société Française De Pédiatrie*. 2000 Jun;**7**(6):621-628
- [32] El Shafie M, Samuel D, Klippel CH, Robinson MG, Cullen BJ. Intractable diarrhea in children with VIP-secreting ganglioneuroblastomas. *Journal of Pediatric Surgery*. 1983 Feb;**18**(1):34-36
- [33] Scheibel E, Rechnitzer C, Fahrenkrug J, Hertz H. Vasoactive intestinal polypeptide (VIP) in children with neural crest tumours. *Acta Paediatrica Scandinavica*. 1982 Sep;**71**(5):721-725
- [34] Sharp SE, Trout AT, Weiss BD, Gelfand MJ. MIBG in neuroblastoma diagnostic imaging and therapy. *Radiographics: A Review Publication of the Radiological Society of North America, Inc*. 2016 Feb;**36**(1):258-278
- [35] Park JR, Eggert A, Caron H. Neuroblastoma: Biology, prognosis, and treatment. *Hematology/Oncology Clinics of North America*. 2010 Feb;**24**(1):65-86
- [36] Cohn SL, Pearson ADJ, London WB, Monclair T, Ambros PF, Brodeur GM, et al. The International Neuroblastoma Risk Group (INRG) classification system: An INRG Task Force report. *Journal of Clinical Oncology: Official Journal of the American Society of Clinical Oncology*. 2009 Jan 10;**27**(2):289-297
- [37] Pinto NR, Applebaum MA, Volchenbom SL, Matthay KK, London WB, Ambros PF, et al. Advances in risk classification and treatment strategies for neuroblastoma. *Journal of Clinical Oncology: Official Journal of the American Society of Clinical Oncology*. 2015 Sep 20;**33**(27):3008-3017
- [38] Schmidt ML, Lal A, Seeger RC, Maris JM, Shimada H, O'Leary M, et al. Favorable prognosis for patients 12 to 18 months of age with stage 4 nonamplified MYCN neuroblastoma: A Children's Cancer Group Study. *Journal of Clinical Oncology: Official Journal of the American Society of Clinical Oncology*. 2005 Sep 20;**23**(27):6474-6480
- [39] George RE, London WB, Cohn SL, Maris JM, Kretschmar C, Diller L, et al. Hyperdiploidy plus nonamplified MYCN confers a favorable prognosis in children 12 to 18 months old with disseminated neuroblastoma: A Pediatric Oncology Group study. *Journal of Clinical Oncology: Official Journal of the American Society of Clinical Oncology*. 2005 Sep 20;**23**(27):6466-6473
- [40] Mossé YP, Deyell RJ, Berthold F, Nagakawara A, Ambros PF, Monclair T, et al. Neuroblastoma in older children, adolescents and young adults: A report from the International Neuroblastoma Risk Group project. *Pediatric Blood & Cancer*. 2014 Apr;**61**(4):627-635
- [41] Maris JM. Recent advances in neuroblastoma. *The New England Journal of Medicine*. 2010 Jun 10;**362**(23):2202-2211

- [42] Vo KT, Matthay KK, Neuhaus J, London WB, Hero B, Ambros PF, et al. Clinical, biologic, and prognostic differences on the basis of primary tumor site in neuroblastoma: A report from the International Neuroblastoma Risk Group project. *Journal of Clinical Oncology*. 2014 Oct 1;**32**(28):3169-3176
- [43] Cole KA, Maris JM. New strategies in refractory and recurrent neuroblastoma: Translational opportunities to impact patient outcome. *Clinical Cancer Research: An Official Journal of the American Association for Cancer Research*. 2012 May 1;**18**(9): 2423-2428
- [44] Perez CA, Matthay KK, Atkinson JB, Seeger RC, Shimada H, Haase GM, et al. Biologic variables in the outcome of stages I and II neuroblastoma treated with surgery as primary therapy: A children's cancer group study. *Journal of Clinical Oncology: Official Journal of the American Society of Clinical Oncology*. 2000 Jan;**18**(1):18-26
- [45] Nickerson HJ, Matthay KK, Seeger RC, Brodeur GM, Shimada H, Perez C, et al. Favorable biology and outcome of stage IV-S neuroblastoma with supportive care or minimal therapy: A Children's Cancer Group study. *Journal of Clinical Oncology: Official Journal of the American Society of Clinical Oncology*. 2000 Feb;**18**(3):477-486
- [46] Meany HJ, London WB, Ambros PF, Matthay KK, Monclair T, Simon T, et al. Significance of clinical and biologic features in Stage 3 neuroblastoma: A report from the International Neuroblastoma Risk Group project. *Pediatric Blood & Cancer*. 2014 Nov;**61**(11):1932-1939
- [47] von Allmen D, Davidoff AM, London WB, Van Ryn C, Haas-Kogan DA, Kreissman SG, et al. Impact of extent of resection on local control and survival in patients from the COG A3973 study with high-risk neuroblastoma. *Journal of Clinical Oncology: Official Journal of the American Society of Clinical Oncology*. 2017 Jan 10;**35**(2):208-216
- [48] Yalçın B, Kremer LCM, van Dalen EC. High-dose chemotherapy and autologous haematopoietic stem cell rescue for children with high-risk neuroblastoma. *Cochrane Database of Systematic Reviews*. 2015 Oct 5;**10**:CD006301
- [49] PL012 influence of surgical excision on survival of patients with high risk neuroblastoma. Report from Study 1 of Siop Europe (Siopen) Keith holmes, SIOPEN, London, United Kingdom
- [50] Haas-Kogan DA, Swift PS, Selch M, Haase GM, Seeger RC, Gerbing RB, et al. Impact of radiotherapy for high-risk neuroblastoma: A Children's Cancer Group study. *International Journal of Radiation Oncology, Biology, Physics*. 2003 May 1;**56**(1):28-39
- [51] Polishchuk AL, Li R, Hill-Kayser C, Little A, Hawkins RA, Hamilton J, et al. Likelihood of bone recurrence in prior sites of metastasis in patients with high-risk neuroblastoma. *International Journal of Radiation Oncology, Biology, Physics*. 2014 Jul 15;**89**(4):839-845
- [52] Matthay KK, Reynolds CP, Seeger RC, Shimada H, Adkins ES, Haas-Kogan D, et al. Long-term results for children with high-risk neuroblastoma treated on a randomized trial of myeloablative therapy followed by 13-cis-retinoic acid: A children's oncology

group study. *Journal of Clinical Oncology: Official Journal of the American Society of Clinical Oncology*. 2009 Mar 1;**27**(7):1007-1013

- [53] Yu AL, Gilman AL, Ozkaynak MF, London WB, Kreissman SG, Chen HX, et al. Anti-GD2 antibody with GM-CSF, interleukin-2, and isotretinoin for neuroblastoma. *The New England Journal of Medicine*. 2010 Sep 30;**363**(14):1324-1334
- [54] Louis CU, Savoldo B, Dotti G, Pule M, Yvon E, Myers GD, et al. Antitumor activity and long-term fate of chimeric antigen receptor-positive T cells in patients with neuroblastoma. *Blood*. 2011 Dec 1;**118**(23):6050-6056
- [55] Streby KA, Shah N, Ranalli MA, Kunkler A, Cripe TP. Nothing but NET: A review of norepinephrine transporter expression and efficacy of ¹³¹I-mIBG therapy. *Pediatric Blood & Cancer*. 2015 Jan;**62**(1):5-11
- [56] Henssen A, Althoff K, Odersky A, Beckers A, Koche R, Speleman F, et al. Targeting MYCN-driven transcription by BET-bromodomain inhibition. *Clinical Cancer Research: An Official Journal of the American Association for Cancer Research*. 2016 May 15;**22**(10):2470-2481
- [57] Castleberry RP. Biology and treatment of neuroblastoma. *Pediatric Clinics of North America*. 1997;**44**:919-937
- [58] Brodeur GM, Pritchard J, Berthold F, et al. Revisions of the international criteria for neuroblastoma diagnosis, staging, and response to treatment. *Journal of Clinical Oncology*. 1993;**11**(8):1466-1477
- [59] Monclair T, Brodeur GM, Ambros PF, et al. The International Neuroblastoma Risk Group (INRG) staging system: An INRG task force report. *Journal of Clinical Oncology*. 2009;**27**(2):298-303
- [60] Cohn SL, Pearson AD, London WB, et al. The International Neuroblastoma Risk Group [INRG] classification system: An INRG task force report. *Journal of Clinical Oncology*. 2009;**27**(2):295

IntechOpen