

We are IntechOpen, the world's leading publisher of Open Access books Built by scientists, for scientists

4,800

Open access books available

122,000

International authors and editors

135M

Downloads

Our authors are among the

154

Countries delivered to

TOP 1%

most cited scientists

12.2%

Contributors from top 500 universities



WEB OF SCIENCE™

Selection of our books indexed in the Book Citation Index
in Web of Science™ Core Collection (BKCI)

Interested in publishing with us?
Contact book.department@intechopen.com

Numbers displayed above are based on latest data collected.
For more information visit www.intechopen.com



Thyroid Cancers: Considerations, Classifications, and Managements

Mohammad Hossein Khosravi, Ali Kouhi, Masoumeh Saeedi, Ali Bagherihagh and Mohammad Hosein Amirzade-Iranaq

Additional information is available at the end of the chapter

<http://dx.doi.org/10.5772/intechopen.70128>

Abstract

Rapidly increasing trend of thyroid cancer incidence has turned this disease into a global concern. An estimated number of 64,300 new cases of thyroid cancer occurred in men and women in 2016, which represents 3.8% of all new cancer cases of USA (<https://seer.cancer.gov/statfacts/html/thyro.html>). Thus, there is a high possibility for every physician to encounter a case of thyroid cancer during his/her professional lifetime. In this chapter, we clarified epidemiology, different categories, and new approaches toward diagnosis and management of thyroid cancer.

Keywords: thyroid cancer, epidemiology, differentiated thyroid cancer, undifferentiated thyroid cancer, thyroid nodule

1. Detailed epidemiology of thyroid cancer

As the most common endocrine cancer and fifth most common cancer in women, thyroid cancer includes approximately 1–1.5% of all new cases of cancer diagnosed annually in the USA based on previous data [1–3]. Thyroid cancer is more prevalent among women and those with positive family history of thyroid disease. Some prior studies have reported a worldwide increasing trend for thyroid cancer incidence in recent decades [4]. Annual percent change (APC) is a commonly used indicator for the assessment of changes in incidence. Based on US National Cancer Institute's Surveillance, Epidemiology, and End Results (SEER) program, it has been reported 2.4% from 1980 to 1997 and 6.6% from 1997 to 2009 in both genders for thyroid cancer (data available at <http://seer.cancer.gov/statfacts/html/thyro.html>).

According to 2009–2013 data, the rate of new cases of thyroid cancer was 13.9 per 100,000 men and women per year (**Figure 1**). **Table 1** summarizes number of new cases per 100,000 persons by race/ethnicity and sex. A recently published study on adolescent cancer incidence during 1975–2012 has reported a 2.12% increase for females and 1.59% for males between 15 and 19 years of age [5]. However, there is a study indicating that thyroid cancer incidence trend has slowed following release of American Thyroid Association (ATA) guideline in 2009 [6, 7]. It has been reported that overall thyroid cancer incidence had an increasing trend about 8% per year from 2000 to 2009. But APC showed a deceleration about 3% in men and 2.8% in women, which was confined to tumors less than 2.9 cm of size for women [7].

Also, thyroid cancer-related mortality was estimated to consist 0.3% of all cancer-related deaths in 2016. A 5-year survival rate of 98.1% has been reported for thyroid cancer. Despite increasing trend of incidence, thyroid cancer mortality has a relatively stable rate about 0.5 cases per 100,000 persons both from 1973 to 2002 and 2009 to 2013 [8, 9].

In conclusion, it seems that thyroid cancer has been following an increasing trend in the past decades; although the reason has been remained controversial. Some scientists believe

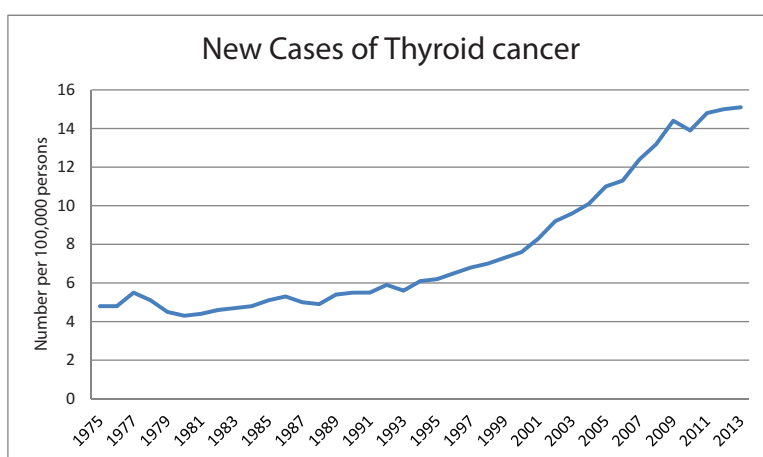


Figure 1. Thyroid cancer incidence in time (<http://seer.cancer.gov/statfacts/html/thyro.html>).

Races	Male	Female
All races	6.9	20.6
White	7.4	21.9
Black	3.6	12.4
Asian/Pacific Islander	6.5	19.9
American Indian/Alaska Native	3.6	13.6
Hispanic	5.0	18.6
Nonhispanic	7.4	21.3

Table 1. Number of new cases of thyroid cancer per 100,000 persons by race/ethnicity and sex.

that modern diagnostic techniques and strategies or in the other words “overdiagnosis” is in charge for this increasing trend [8, 10]. Others believe that environmental factors such as various irradiations and changes in lifestyle can be considered as the reasons for this true increase [11–14]. Regardless of the nature, this increase has turned thyroid cancer to a world-wide health problem, which involves more attention and efforts toward diagnosis and proper management.

2. Categories of thyroid malignancies

Three are some different classifications for thyroid cancers. Previously and more commonly, thyroid gland malignancies were used to be categorized to three types: differentiated thyroid cancers (such as papillary and follicular thyroid cancers), anaplastic carcinomas, and rare types of thyroid cancer (like medullary thyroid cancer). A newly released classification categorizes thyroid malignancies to two main follicular-derived and neuroendocrine C-cell-derived types [1], which will be discussed in detail in following lines. **Figure 2** illustrates this classification in order for better clarification.

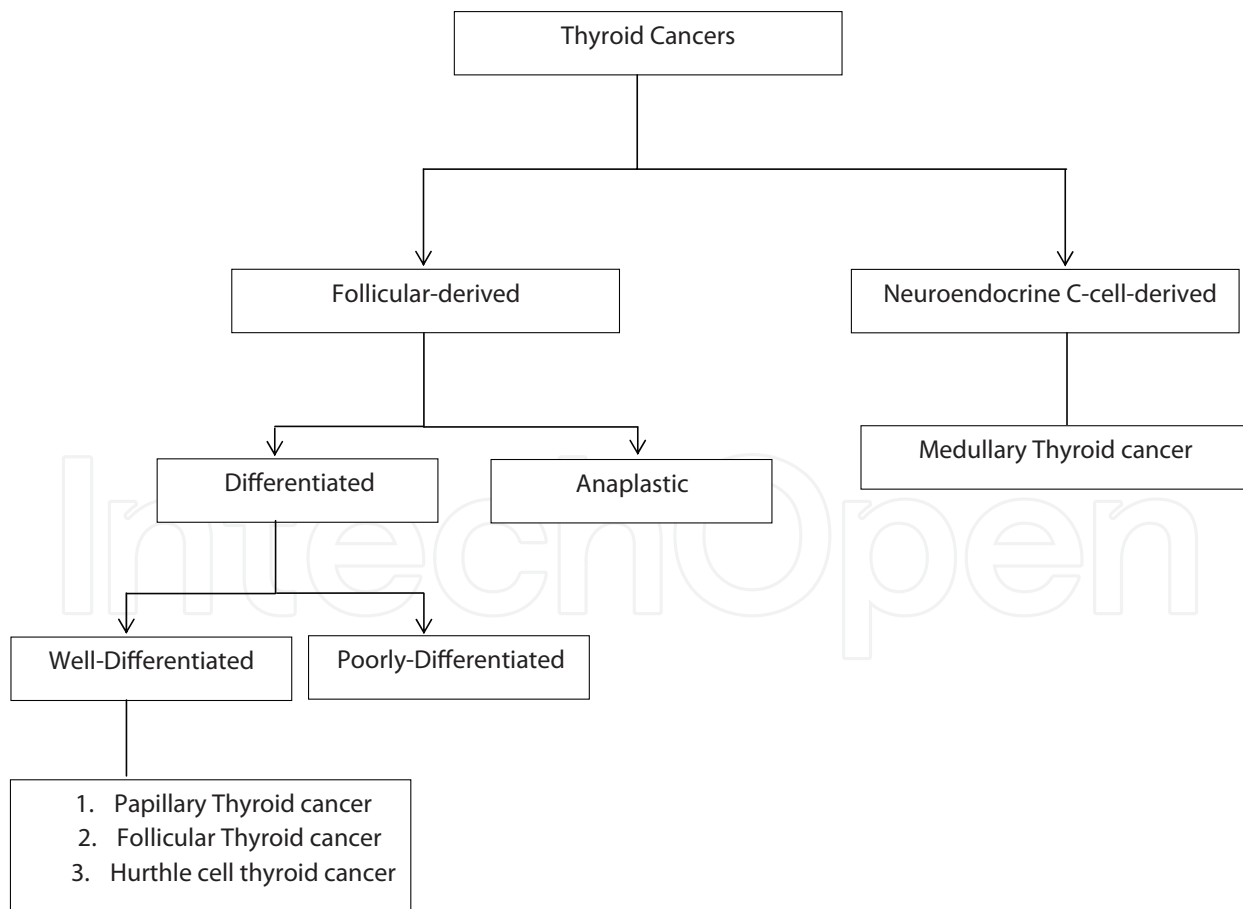


Figure 2. Classification of thyroid malignancies.

2.1. Follicular-derived thyroid cancers

Follicular-derived thyroid cancers have two main subtypes: differentiated and anaplastic cancers.

2.1.1. Differentiated thyroid cancers

Consisting approximately 95% of all thyroid cancers, differentiated thyroid cancer is the most prevalent type of these cancers [15], which is raised from thyroid follicular epithelial cells. There are two main subtypes for differentiated thyroid cancers: well-differentiated and poorly differentiated thyroid cancers. Papillary thyroid cancer, follicular thyroid cancer, and Hurthle cell carcinoma (HCC) are under category of well-differentiated thyroid cancers (WDTC).

2.1.1.1. Papillary thyroid cancer

Accounting for 70–90% of well-differentiated thyroid cancers and 80–85% of follicular cell-derived thyroid cancers [16], papillary thyroid cancers (PTCs) are the most prevalent type of thyroid cancers [17]. Incidence of papillary thyroid cancer has increased along with recent increase in incidence of thyroid cancers. Experts believe that this increase is related to higher detection and diagnosis rates; because PTCs are more easily diagnosed with ultrasound and diagnostic tests such as fine needle aspiration (FNA) cytology in comparison with follicular carcinomas [18].

PTC is mostly diagnosed at the mean age of 45 years old; however the incidence increases with increase in age [19]. Papillary thyroid cancer can also occur in children [19, 20].

There are several known risk and etiologic factors for papillary thyroid carcinoma such as radiation exposure, nitrate, unknown environmental pollutants, and endogenous factors like obesity, high levels of thyroid stimulating hormone (TSH), and presence of Hashimoto's thyroiditis [4]. Based on a meta-analysis, each 5-unit increase in body mass index (BMI), 5 kg increase in weight, 5 cm increase in waist or hip circumference, and 0.1 unit increase in waist-to-hip ratio were associated with 30, 5, 5, and 14% greater risks of thyroid cancer, respectively [21]. Estrogen is also another potential risk factor for papillary thyroid carcinoma, which justifies the sex difference for thyroid nodules and carcinoma [22]. Hepatitis C infection has been mentioned as a potential risk factor for thyroid cancer; however, more studies are needed to confirm this association [23]. It is not exactly clear that which factor(s) are important and mainly contributed to the recent increase in thyroid cancer incidence.

Papillary thyroid cancer has the best overall prognosis [1]; however, there are some static and dynamic prognostic factors, which influence this prognosis [24]. Static prognostic factors help with decision-making on therapeutic strategies and are usually based on patient's background or findings of preoperative imaging studies, intra-operative, and post-operative pathological findings.

Static prognostic factors are subdivided into three classification regarding the time of evaluation; pre-, intra-, and post-operative.

1. Pre- or intra-operative prognostic factors:

- Age: although the age has been considered by approved classification systems like age, metastases, extent and size (AMES); metastasis, age, invasion, completeness, and size (MACIS); and Union for International Cancer Control (UICC) tumor, nodes, metastasis (TNM) classification, its exact role as a prognostic factor has remained controversial [25–27]. Most of the previous studies have indicated that recurrence and mortality are higher in elderly patients [27–33]. On the other hand, it has been reported that younger PTC patients have lower disease-free survival (DFS) than middle-aged patients.
 - Gender: prognostic value of male gender has been questioned in recently published studies [24]; however, approved in some previous ones [18]. It has been concluded that male gender has a moderate prognostic value in PTC patients; however, there are studies with contrast findings [34].
 - Size of tumor: the fact that larger tumors are associated with higher mortality and poor prognosis has been long determined. AMES has marked tumor size more than 5 cm as high risk and UICC set two cut off at 2 and 4 cm [25, 27]. Most of the recent studies have set the cut off at 3–4 cm according to prognosis of PTC patients [25, 27–30, 35].
 - Extrathyroid extension: it is one of the most important prognostic factors for PTC [36]. Grossly significant extrathyroid extension based on intra-operative evidences is one of the most reliable prognostic factors.
 - Clinical lymph node metastasis: not only the presence of lymph node metastasis is important, but the number and size of metastasis are also among determining prognostic factors [36].
2. Distant metastasis at diagnosis: it is considered as the strongest predicting factor for carcinoma-related death of PTC patients [18, 24].

Post-operative prognostic factors:

- Ki-67 labeling index: Ki-67 is a molecular marker indicating high level of proliferative activity in carcinoma. Ki-67 labeling index (LI) is generally low in PTC patients; however patients with high Ki-67 labeling index are more likely to show recurrence or persistent disease and to die from carcinoma [24, 37]. High Ki-67 LI is considered as an independent prognostic factor for DFS and cause-specific survival (CSS) [37, 38].
- BRAF V600E mutation: many previous studies have mentioned that PTC with BRAF mutation is more aggressive, associated with more recurrence, and has poorer prognosis [18, 39–42]. It has been shown that PTCs with BRAF V600E mutation and negative for X-linked inhibitor of apoptosis protein (XIAP) have higher chance of recurrence [18]. So, simultaneous evaluation of BRAF V600E mutation and XIAP expression is suggested as a better predictor of cancer recurrence [43].
- Poor differentiation and aggressive variants: patients with poorly differentiated PTC are known for their poor prognosis [24]. Poorly differentiated papillary thyroid carcinoma has been discussed as a separate section.

Dynamic prognostic factors are based on changes in serum thyroglobulin (Tg) and thyroglobulin antibody (TgAb) after total thyroidectomy, which help with estimation of recurrence and cause-specific survival (CSS) of PTC patients.

- Tg-doubling time (Tg-DT): for the first time in 2011, Tg-doubling time was proposed as a dynamic prognostic factor [44]. Tg-DT was recognized as an independent prognostic factor for both DFS and CSS of patients, whereas a short Tg-DT time (less than 1 year) is an indicator of poor prognosis. It was mentioned that Tg-DT is inversely linked to Ki-67 LI and so measurement of Ki-67 may give us information upon post-operative Tg status, Tg-DT, and prognosis of patients [37].

Post-operative Tg status is also related to patients' age; so that a shorter Tg-DT (less than 2 years) is observed in old patients [45]. In conclusion, Tg-DT is a very convenient marker for the prediction of patients' prognosis in real-time and decision-making on use of molecular target agents.

- Pre- and post-operative values of TgAb: Tg-DT is not useful in TgAb positive patients, because serum Tg levels are not reliable in the presence of TgAb. Patients whose TgAb levels decrease less than 50% or increase in post-operative (total thyroidectomy) period are more likely to develop a recurrence of disease [46, 47].

2.1.1.1.1. Staging

American Joint Committee on Cancer (AJCC, <https://cancerstaging.org>) has divided staging of differentiated thyroid cancers as two groups; in patients under 45 years old and in those 45 years and older. As described previously, younger patients are less likely to die from differentiated thyroid cancers; so all patients younger than 45 years are stage I if they have no distant metastasis and stage II if they have distant metastasis.

Papillary thyroid cancer in patients younger than 45:

- **Stage I (Any T, Any N, M0):** the tumor can be of any size (any T) and may or may not have spread to nearby lymph nodes (any N). It has not spread to distant sites (M0).
- **Stage II (Any T, Any N, M1):** the tumor can be of any size (any T) and may or may not have spread to nearby lymph nodes (any N). It has spread to distant sites (M1).

Papillary thyroid cancer in patients 45 years and older:

Stage I (T1, N0, M0): the tumor is 2 cm or less across and has not grown outside the thyroid (T1). It has not spread to nearby lymph nodes (N0) or distant sites (M0).

Stage II (T2, N0, M0): the tumor is more than 2 cm but not larger than 4 cm across and has not grown outside the thyroid (T2). It has not spread to nearby lymph nodes (N0) or distant sites (M0).

Stage III: one of the following applies:

T3, N0, M0: the tumor is larger than 4 cm across or has grown slightly outside the thyroid (T3), but it has not spread to nearby lymph nodes (N0) or distant sites (M0).

T1–T3, N1a, M0: the tumor is of any size and may have grown slightly outside the thyroid (T1–T3). It has spread to lymph nodes around the thyroid in the neck (N1a) but not to other lymph nodes or to distant sites (M0).

Stage IVA: one of the following applies:

T4a, any N, M0: the tumor is any size and has grown beyond the thyroid gland and into nearby tissues of the neck (T4a). It might or might not have spread to nearby lymph nodes (any N). It has not spread to distant sites (M0).

T1 to T3, N1b, M0: the tumor is any size and might have grown slightly outside the thyroid gland (T1–T3). It has spread to certain lymph nodes in the neck (cervical nodes) or to lymph nodes in the upper chest (superior mediastinal nodes) or behind the throat (retropharyngeal nodes) (N1b), but it has not spread to distant sites (M0).

Stage IVB (T4b, Any N, M0): the tumor is of any size and has grown either back toward the spine or into nearby large blood vessels (T4b). It might or might not have spread to nearby lymph nodes (any N), but it has not spread to distant sites (M0).

Stage IVC (Any T, Any N, M1): the tumor is of any size and might or might not have grown outside the thyroid (any T). It might or might not have spread to nearby lymph nodes (any N). It has spread to distant sites (M1).

2.1.1.1.2. Management

The optimal management of papillary thyroid cancer has remained controversial as the available data on the best approach for management are related to retrospective evaluations, large national registry studies, and meta-analysis but not randomized clinical trials (RCTs) [48–50]. Only RCTs are able to exactly determine the optimal treatment, such as extent of surgery, in PTC patients. It has been estimated that a large number about 3000 to 5000 patients are needed to be randomized for evaluation of cause-specific mortality, which is not actually possible.

Decision-making for primary treatment are depended on preoperative assessments such as clinical, imaging and histological evaluations. Treatment choices are based on location and extent of disease.

Figure 3 illustrates algorithm for primary treatment of patients with differentiated thyroid carcinomas. Recommendations of 2015 American Thyroid Association (ATA) guidelines are excellent reference as they are more conservative than before [51].

According to this guideline, unifocal tumors which are smaller than 4cm with no evidence of extrathyroidal extension or lymph node metastasis are resolvable by lobectomy. Previous studies have shown that bilateral or unilateral resections are associated with similar long-term survival [48, 52–54]. For patients with papillary microcarcinoma (less than 1 cm) without evidence of cervical lymph node metastasis, nonsurgical management is considered as an option [55, 56].

Surgical and pathological findings are applied shortly after surgery for decision-making on the possible need for thyroid hormone replacement therapy or radioiodine ablation or both. This assessment is based on well-known TNM staging which determines mortality but

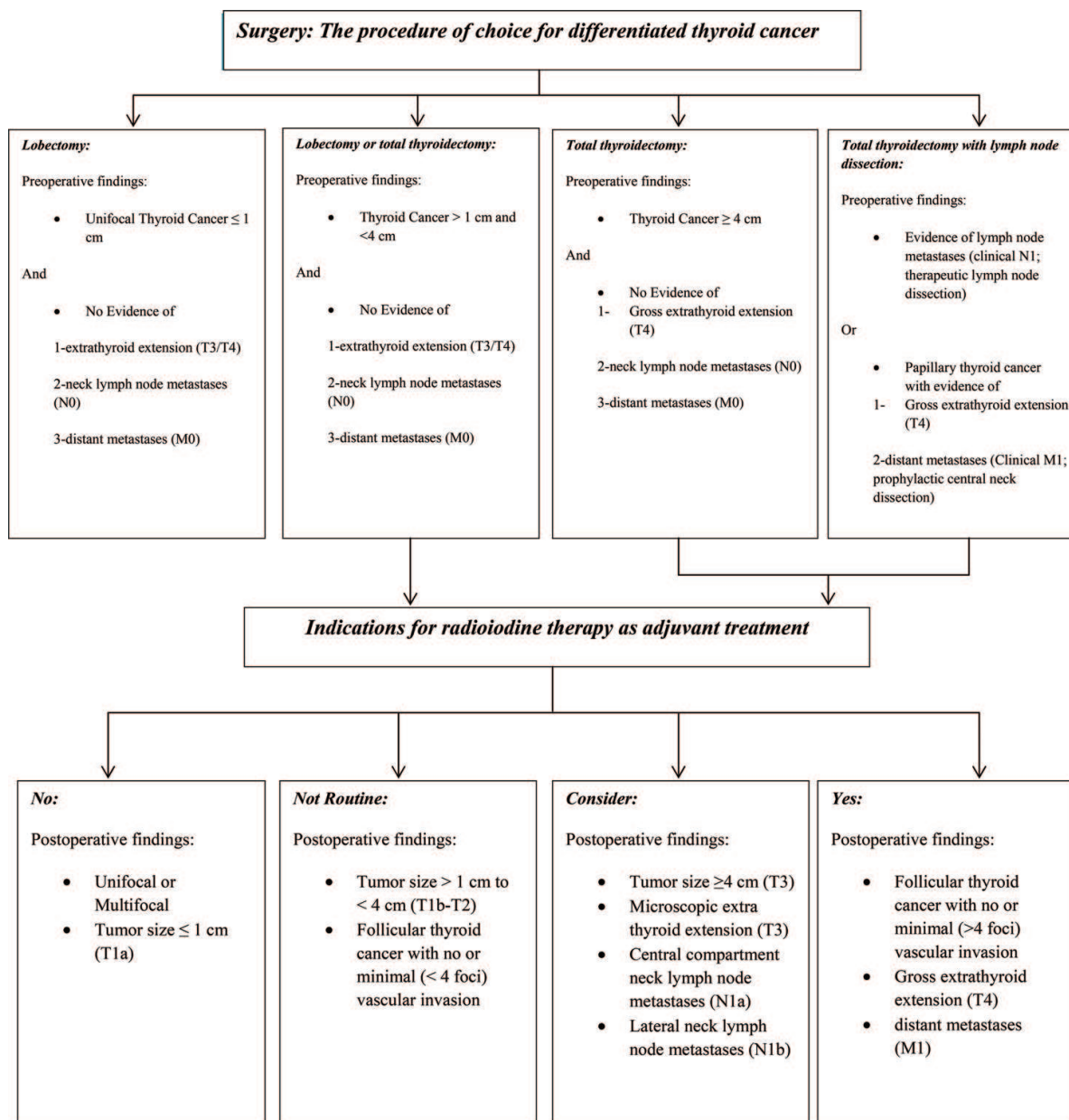


Figure 3. Primary treatment of patients with differentiated thyroid carcinoma.

not the risk of recurrence. Recurrence assessment system proposed by 2015 ATA guideline (Tables 2 and 3) is a reliable predictor for the course of differentiated thyroid carcinoma treated with thyroidectomy alone or radioiodine remnant ablation [57–60].

Radioiodine therapy (RAI Tx): Previously application of radioactive iodine was justified by the need for elimination thyroid normal tissue remnants. It is also considered as adjuvant treatment for destroying occult neoplastic cells within the thyroid remnant or throughout the body. This issue has been challenged recently because of short-term morbidity and possible increased risk of second cancers [6, 61]. Recent recommendations believe in individualized use of RAI Tx (Figure 3). It can also be used in detection of distant metastasis as well as a treatment. Unfortunately this strategy is not effective in radioiodine refractory patients.

At the time of primary treatment

(1) ATA low risk ($\leq 5\%$ recurrence)

Papillary thyroid cancer

- Intrathyroid tumor
- Clinical N0 or five or fewer lymph node micrometastases (<0.2 cm in largest diameter)
- *V600EBRAF*-mutated microcarcinoma

Follicular thyroid cancer

- Intrathyroid tumor
- Capsular invasion and no or minimal (<4 foci) vascular invasion

(2) ATA intermediate risk (5–20% recurrence)

Papillary thyroid cancer

- Minimal extrathyroid extension
- Aggressive histology
- Vascular invasion
- Clinical N1 or more than five lymph node metastases (<3 cm in largest diameter)
- *V600EBRAF*-mutated, intrathyroid, 1–4 cm, primary tumor
- *V600EBRAF*-mutated microcarcinoma, multifocal with extrathyroid extension

(3) ATA high risk (>20% recurrence)

Papillary thyroid cancer

- Gross extrathyroid extension
- Distant metastases
- Lymph node metastasis at least 3 cm in largest diameter

Follicular thyroid cancer

- >4 foci of vascular invasion
-

Table 2. Recurrence risk stratification at the time of primary treatment as a function of the response to treatment.

TSH suppression: TSH stimulates proliferation of normal thyrocytes and some malignant cells; so TSH suppression has been used as a treatment after surgery [62]. This approach significantly decreases mortality and recurrence in DTC [63]. The exact amount of needed suppression is not clear but studies show that reducing TSH level to less than 0.1mU/L improves clinical outcome; however moderate reductions are beneficial [64, 65]. This treatment may have some complications like osteoporosis in postmenopausal women or angina and atrial fibrillation in elderly patients; so the risk of complications should be weighed against the risk of proliferation of malignant cells [66].

2.1.1.2. Follicular thyroid cancer

Including approximately 10–15% of well-differentiated thyroid carcinomas, follicular thyroid cancer (FTC) is defined as ‘A malignant epithelial tumor showing follicular cell differentiation and lacking the diagnostic nuclear features of papillary thyroid carcinoma’ (PTC) [67].

During follow-up

(1) Excellent response (1–4% recurrence)

- Imaging negative for disease recurrence
- Serum thyroglobulin concentration lower than 0.2 ng/mL basal or higher than 1 ng/mL TSH stimulated

(2) Indeterminate response (15–20% recurrence)

- Nonspecific findings on imaging studies
- Serum thyroglobulin 0.2–1 ng/mL basal or 1–10 ng/mL TSH stimulated, or thyroglobulin antibodies stable or decreasing

(3) Biochemical incomplete response (20% recurrence)

- Imaging negative for disease recurrence
- Serum thyroglobulin concentration higher than 1 ng/mL basal or higher than 10 ng/mL TSH stimulated, or increasing thyroglobulin antibody concentrations

(4) Structural incomplete response (50–85% recurrence)

- Structural (neck ultrasound, CT, or MRI) or functional (whole-body scan or ¹⁸F-fluorodeoxyglucose PET) evidence of disease in imaging studies
-

Table 3. Recurrence risk stratification over time as a function of the response to treatment.

Patients' age, size and staging of the tumor, responsiveness to radioiodine therapy and completeness of surgery are among prognostic factors of FTC. Minimally invasive carcinomas have better prognosis than widely invasive carcinomas [68, 69].

2.1.1.2.1. Staging

As a differentiated thyroid cancer, staging of follicular thyroid cancer is the same with papillary thyroid carcinoma based on American Joint Committee on Cancer (AJCC).

2.1.1.2.2. Management

As a differentiated thyroid cancer, management of follicular thyroid carcinoma is compatible with those of papillary thyroid carcinoma.

2.1.1.3. Hurthle cell carcinoma

Oncocytic follicular cells of thyroid, known as Hurthle cells, which were first described by Karl Hürthle are the origin of Hurthle cell carcinoma (HCC) [70, 71]. They can be found in both benign and malignant conditions of thyroid. Histologic differentiation between Hurthle cell adenoma and carcinoma can be definitely made only after the evaluation of resection specimen by the presence or absence of vascular or capsular invasion, which is the hallmark of HCC [72]. HCC represents 3% of all thyroid cancers [73].

There are two types of Hurthle cell carcinoma; minimally invasive carcinomas are fully encapsulated tumors with microscopically identifiable foci of capsular or vascular invasion

(<4 foci) and widely invasive tumors, which have extensive vascular invasion (>4 foci) and extrathyroidal invasion. Patients with minimally invasive carcinomas usually experience a better prognosis [73]. Overall, older patients and those with larger tumor size, extrathyroidal extension, and not undergoing surgery have reduced survival [74]. A previous study indicated that in patients with widely invasive HCC, stages III–IV are independent risk factors for recurrence or death. Five-year risk of recurrence or death was reported 0% in women with stages I–II compared to 17% in men. However, it was 91% among men with stages III–IV disease comparing to 74% of women in the same stage of disease [75].

Stratification of risk of recurrence for HCC based on ATA (American Thyroid Association) guideline [51]:

- Low risk: intrathyroidal encapsulated tumors with minor capsular or vascular invasion (<4 foci) or ≤ 5 metastatic lymph nodes where the foci of metastases are <0.2 cm.
- Intermediate risk: vascular invasion, minimal extrathyroidal extension, or >5 metastatic lymph nodes (0.2–3 cm).
- High risk: macroscopic extrathyroidal extension, incomplete tumor resection, distant metastases, or metastatic lymph nodes >3 cm.

2.1.1.3.1. Staging

As a differentiated thyroid cancer, staging of follicular thyroid cancer is the same with papillary thyroid carcinoma based on American Joint Committee on Cancer (AJCC).

2.1.1.3.2. Management

As other differentiated thyroid cancers, the main treatment for HCC is surgery. Since the preoperative diagnosis of HCC is impossible by cytology, determining the initial extent of surgery and whether further surgical resection (completion thyroidectomy) involves postoperative histological evaluation [70]. So, the first step is a thyroid lobectomy in the primary surgery unless the pathological features guide us to total thyroidectomy. Presence of dominant contralateral nodule, nodule size greater than 4 cm or preexisting diminished thyroid hormone production requiring thyroid hormone therapy are another indication for total thyroidectomy [51].

TSH suppression: Goal of TSH suppression depends on the risk of recurrence. Completely resected minimally invasive HCC is categorized as low risk and then does not require TSH suppression therapy. Patients with incomplete response to therapy should have TSH levels less than 0.1 mU/L unless there is a contraindication. Patients with incomplete biochemical response to therapy or high-risk HCC and an excellent or indeterminate response to therapy should have TSH levels between 0.1 and 0.5 mU/L considering the risk of TSH suppression and trend of thyroglobulin levels over time.

Radioiodine therapy (RAI Tx): Benefit of RAI Tx for HCC patients has remained as a question because a small number of studies have evaluated this treatment. Generally, RAI Tx is not routinely recommended for patients at low risk of recurrence.

External beam radiation therapy (EBRT): In patients with clinically evident gross extrathyroidal extension that is incompletely resected, external beam radiation therapy (EBRT) can be considered as a treatment option. However, potential benefit of radiation should be weighed against potential complications, such as dental decay, tracheal stenosis, esophageal stricture, osteonecrosis, fibrosis, and xerostomia [76].

2.1.1.4. Poorly differentiated thyroid cancer

Introduced by Sakamoto et al., this group of thyroid cancers fall between well-differentiated thyroid cancers (WDTC) and anaplastic thyroid cancer (ATC) in terms of both morphologic appearance and biologic behavior [77, 78]. They account for up to 10% of all thyroid cancers and have a higher incidence in Europe than in the United States with a male-to-female ratio of 1:2 [77, 79, 80]. Poorly differentiated thyroid carcinoma (PDTC) may represent intermediate entities of the progression of WDTC to ATC [78, 81–83]. PDTCs have a high recurrence rate despite appropriate treatment. These types of cancers have more aggressive pattern than typical papillary thyroid cancer.

The most challenging issue in diagnosis of PDTC is lack of a precise definition. So, in 2006 a group of experts set diagnostic criteria for PDTC in Turin, Italy [84]. As the most acceptable criteria, the 2006 Turin criteria are as following:

- (1) A solid/trabecular/insular pattern of growth
- (2) Absence of conventional nuclear features of papillary carcinoma
- (3) Presence of at least one of the following features: convoluted nuclei, mitotic activity ($\geq 3 \times 10$ HPF), necrosis

PDTCs are usually at an advanced stage, usually extrathyroidal extension and extensive local invasion, at the time of diagnosis [85]. They can be metastasized to regional lymph nodes (50–85%), and distantly (36–85%), most commonly to the lung (14–54%), and bones (18–33%) [86, 87]. Survival rates are remarkably lower than in patients with WDTC [85, 87, 88]. Patients more than 45 years of age and those with cervical lymph node invasion, tumor necrosis, local recurrence, mitotic index greater than 3 per 10 high-power fields, tumor size greater than 4 cm, and distant metastasis at the time of diagnosis have poorer prognosis [89–92][13, 31–34].

2.1.1.4.1. Management

Since PDTC is rare, the best treatment option for treatment remains inconclusive. Most previous studies are agreed with total thyroidectomy with lymph node dissection because of aggressive nature of these tumors. More than 50% of PDTCs have regional nodal metastasis; so central compartment with modified radical neck dissection is considered [93]. Application of radioiodine therapy (RAI), external beam radiation therapy (EBRT), or chemotherapy has remained controversial [77].

2.1.2. Anaplastic thyroid cancer (undifferentiated thyroid cancer)

Anaplastic thyroid cancer (ATC) is a rare and lethal form of thyroid cancer, which is responsible for 1.7–2% of all thyroid cancers. It usually involves patients in their sixth or seventh decade of life and has a median survival of 5 months and less than 20% of patients are alive 1 year after diagnosis. Geographical prevalence of ATC has a wide range from 1.3 to 9.8% [94–96].

ATC is considered to be originally derived from follicular cells resulted from dedifferentiation. About 80% of ATC presents in patients with long-standing goiter, which is possibly in the setting of an undiagnosed well-differentiated thyroid cancer [95]. In most of the cases, ATC usually presents with a rapidly enlarging neck mass and local symptoms such as neck pain, dysphagia, dyspnea, and hoarseness [97]. Symptoms can be related to invasion of tumor to neighboring structures such as recurrent laryngeal nerve (RLN), parasympathetic chain (causing Horner's syndrome), or even carotid arteries (causing stroke). About 40% of patients usually present with lymphadenopathy and up to 43% have distant metastasis, most commonly to the lung followed by bone and brain at the time of diagnosis [98].

A variety of previous studies have evaluated prognostic factors of ATC [99–102]. These prognostic factors include patients' age, tumor size, and clinical stage. Ages more than 70, acute onset of symptoms, white blood cell count (WBC) more than 10000, tumor size more than 5 cm, T4b and distant metastasis are associated with increased mortality and poor prognosis [102].

A majority of patients will finally die from ATC and should be aware of the prognosis by a thorough discussion in order to have information on the impact of disease on their quality of life and also the potential benefit of participating in clinical trials [97]. The physician should also hold discussions around "do not resuscitate" (DNR) or "allow natural death" (AND) with patients to decrease ambiguity in emergency situations, which require life-supporting procedures such as intubation.

2.1.2.1. Staging

American Joint Committee on Cancer (AJCC) considers all anaplastic thyroid cancers as T4 and Stage IV at the time of diagnosis reflecting the poor prognosis of this cancer.

Stage IVA (T4a, Any N, M0): the tumor is still within the thyroid (T4a). It might or might not have spread to nearby lymph nodes (any N), but it has not spread to distant sites (M0).

Stage IVB (T4b, Any N, M0): the tumor has grown outside the thyroid (T4b). It might or might not have spread to nearby lymph nodes (any N), but it has not spread to distant sites (M0).

Stage IVC (Any T, Any N, M1): the tumor might or might not have grown outside of the thyroid (any T). It might or might not have spread to nearby lymph nodes (any N). It has spread to distant sites (M1).

2.1.2.2. Management

ATC raises both diagnostic and therapeutic challenges. This is because of rarity of the disease and also lack of expression of thyroid and epithelial cell markers in anaplastic cancer

cells [103]. In addition, ATC cells present in a variety of histology and morphology abnormalities which causes delay in diagnosis and consequently in treatment. As the diagnosis is established, staging should be done as well as the assessment of airway by fiberoptic laryngoscopy.

Referring the patient to a center with experience with anaplastic thyroid cancer is highly recommended. An expert head and neck surgeon should assess the patient to determine if the primary tumor is resectable. Early after resection, external beam radiation with radiosensitizing drugs, like taxanes with or without platin or anthracycline (chemoradiation). Palliative chemoradiation is suggested for patients with unresectable primary tumors but without distant metastases.

Patients with advanced disease (stage IVC) are the most challenging ones. Treating physician should balance local control of primary tumor and treatment of distant metastases. If the airway is at risk, the chemoradiation should be started. Patients in whom the airway is not at risk or is stabilized by tracheostomy should preferably be enrolled in a clinical trial or undergo systemic chemotherapy by cytotoxic drugs [1].

Recently, targeted treatment has been suggested; for example prescription of *BRAF* inhibitors in patients with *BRAF*^{V600E}-mutated anaplastic thyroid cancer [103]. Dabrafenib, which is a selective *BRAF* inhibitor, trametinib, lenvatinib, rapamycin, and microtubule inhibitors are among the drugs being evaluated in ATC patients.

Patients and their family members should be informed of poor prognosis of the disease. Some patients should be transferred to a sanatorium if they do not wish to be treated or their performance is poor.

2.2. Neuroendocrine C-cell–derived thyroid cancer

Accounting for 1–2% of all thyroid cancers, medullary thyroid cancer is relatively uncommon [15]. Medullary thyroid cancer (MTC) is originated from parafollicular neuroendocrine cells, in contrast with differentiated thyroid cancer. It occurs either sporadic (in 75% of cases) or in a hereditary form (multiple endocrine neoplasia type 2, MEN2), due to germline mutations in the *RET* proto-oncogene [104]. As most of the thyroid cancers, MTC usually presents as a solitary thyroid nodule in patients in fourth or sixth decade of life [105]. Since it metastasizes frequently, neck lymphadenopathy is usually the first manifestation. Most (70%) of the patients with palpable MTC have evidence of cervical node involvement at the time of surgery [106]. A classic thyroid nodule associated with flushing and diarrhea is suggestive of widespread metastatic disease. About 25% of MTC cases occur in patients with an inherited multiple endocrine neoplasia syndrome [105].

2.2.1. Staging

Stage I (T1, N0, M0): the tumor is 2 cm or less across and has not grown outside the thyroid (T1). It has not spread to nearby lymph nodes (N0) or distant sites (M0).

Stage II: one of the following applies:

T2, N0, M0: the tumor is more than 2 cm but is not larger than 4 cm across and has not grown outside the thyroid (T2). It has not spread to nearby lymph nodes (N0) or distant sites (M0).

T3, N0, M0: the tumor is larger than 4 cm or has grown slightly outside the thyroid (T3), but it has not spread to nearby lymph nodes (N0) or distant sites (M0).

Stage III (T1–T3, N1a, M0): the tumor is of any size and might have grown slightly outside the thyroid (T1–T3). It has spread to lymph nodes around the thyroid in the neck (N1a) but not to other lymph nodes or to distant sites (M0).

Stage IVA: one of the following applies:

T4a, any N, M0: the tumor is any size and has grown beyond the thyroid gland and into nearby tissues of the neck (T4a). It might or might not have spread to nearby lymph nodes (any N). It has not spread to distant sites (M0).

T1–T3, N1b, M0: the tumor is of any size and might have grown slightly outside the thyroid gland (T1–T3). It has spread to certain lymph nodes in the neck (cervical nodes) or to lymph nodes in the upper chest (superior mediastinal nodes) or behind the throat (retropharyngeal nodes) (N1b), but it has not spread to distant sites (M0).

Stage IVB (T4b, Any N, M0): the tumor is of any size and has grown either back toward the spine or into nearby large blood vessels (T4b). It might or might not have spread to nearby lymph nodes (any N), but it has not spread to distant sites (M0).

Stage IVC (Any T, Any N, M1): the tumor is of any size and might or might not have grown outside the thyroid (any T). It might or might not have spread to nearby lymph nodes (any N). It has spread to distant sites (M1).

2.2.2. Management

As other thyroid cancers, surgery is the mainstay for MTC management; however, imaging and diagnosis before surgery are necessary for determining the best surgical intervention [1]. As the diagnosis of MTC is made, the patient should undergo neck ultrasonography and tumor markers (calcitonin and carcinoembryonic antigen) evaluation.

In addition, it should be determined if the disease is sporadic or associated with MEN 2 syndrome, because patients with MEN 2 may have pheochromocytoma or primary hyperparathyroidism or both. So, biochemical testing should be considered for ruling out pheochromocytoma or primary hyperparathyroidism in MTC patients with unknown status of germline RET mutation. If the patient has primary hyperparathyroidism, a total thyroidectomy should be done including parathyroidectomy. For patients with pheochromocytoma, adrenalectomy should be prioritized to thyroidectomy. Patients with hereditary MTC should be referred to a genetic counselor so that only necessary family members undergo testing for lowering related costs [1]. Family members with germline RET mutation benefit from prophylactic thyroidectomy [105].

If preoperative calcitonin levels are higher than 146 pmol/L, work up should be done for distant metastatic disease [105]. This work up includes neck and chest CT and three-phase MRI of liver with contrast. Axial skeleton MRI is suggested for bone metastasis. Total thyroidectomy with bilateral central neck dissection is preferred for patients with no distant metastasis. Lateral neck dissection is recommended only if metastatic disease is suspected by neck ultrasound and confirmed by FNA cytology.

After surgery, patients need thyroid hormone replacement therapy but not TSH suppression as in high risk differentiated thyroid cancers. Calcitonin and carcinoembryonic antigen (CEA) should be checked not earlier than 3 months after surgery for determining if the patient has persistent disease.

External Beam radiation therapy (EBRT) should be limited in MTC patients, because it can limit further surgical interventions due to fibrosis as well as affecting the quality of life of patients.

Patients should be managed with active surveillance by both ultrasonography and serial evaluation of tumor markers to guide further surgical treatment. Patients with normal levels of tumor markers and imaging after surgery should be followed up annually and those with persistent tumor markers should be observed more closely. Patients with calcitonin and CEA doubling time within 6 months have a shorter overall survival time [107].

3. Assessment and treatment of thyroid nodules

Thyroid nodules are usually the first presenting feature of a thyroid cancer. So evaluation of thyroid nodules is of a great importance.

Size plays a notable role in determining the need of fine needle aspiration (FNA) for a thyroid nodule; however, ultrasound features can provide valuable clues regarding malignancy of nodules [108]. These are hypoechogenicity, a solid internal structure, irregular margins, microcalcifications, taller-than-wide shape, and evidence of extrathyroidal extension or cervical lymphadenopathy for papillary thyroid cancers. Nodules which do not have these characteristics can be followed up without FNA until the nodule remains small [1].

Follicular thyroid cancer and follicular variant of papillary thyroid cancers are more often round and isoechoic with regular margins. A larger size and increased intranodular vascularity on color or power Doppler imaging are also predictive of malignancy [109–112].

The 2015 ATA guideline has bolded the role of ultrasound in diagnosis and approach to thyroid nodules (**Figure 4**) [51]. Concurrent risk factors of thyroid cancer including cough, neck pain, change in voice, presence of a firm mass, history of childhood neck radiation, or familial thyroid cancer should be considered and in these cases FNA is recommended regardless of ultrasound characteristics. ATA recommends biopsy for nodules larger than 1 cm.

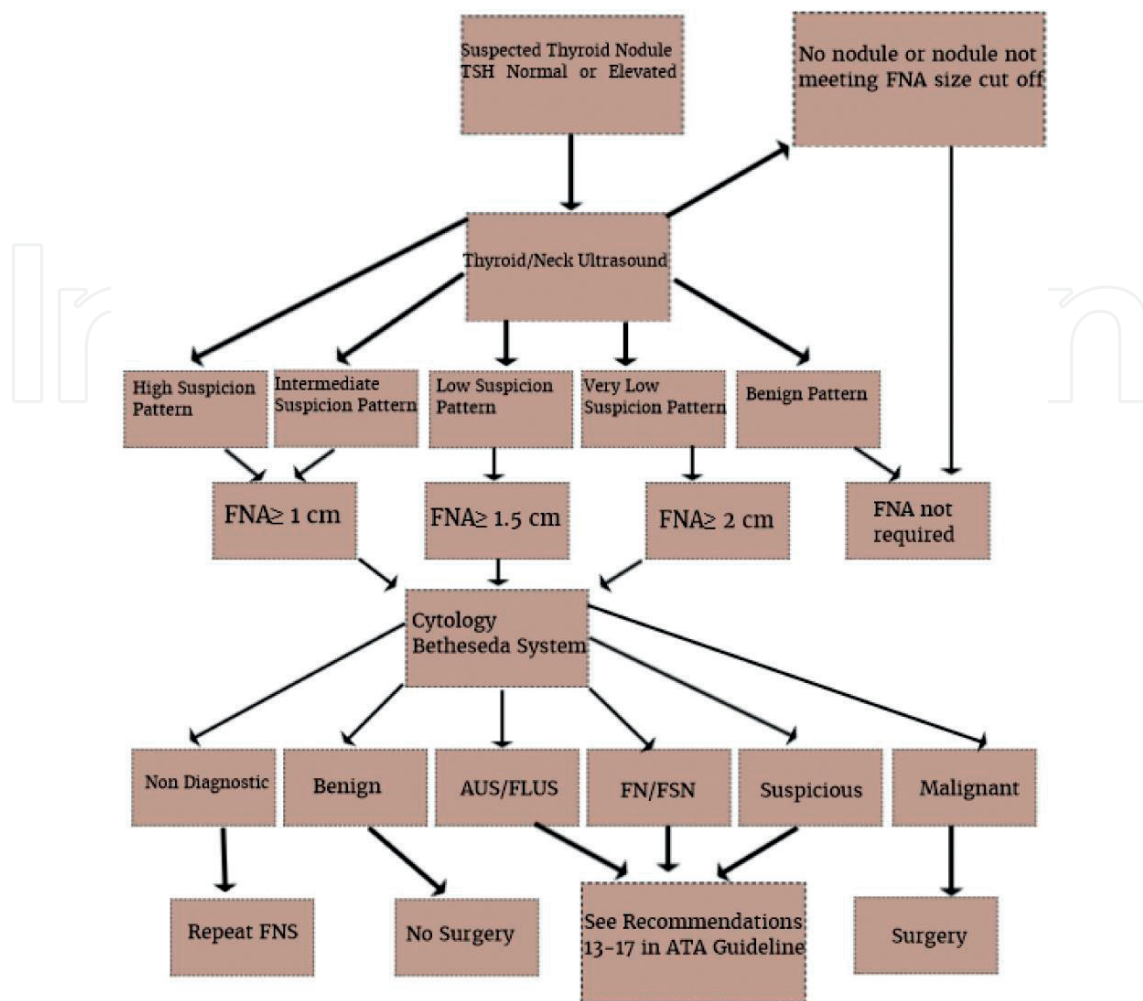


Figure 4. Approach to thyroid nodule based on ATA guideline [51].

Author details

Mohammad Hossein Khosravi^{1,2}, Ali Kouhi^{2,3}, Masoumeh Saeedi^{2,4}, Ali Bagherihagh^{2,4*} and Mohammad Hosein Amirzade-Iranaq^{5,2}

*Address all correspondence to: ali.bagherihagh@gmail.com

1 Student Research Committee (SRC), Baqiyatallah University of Medical Sciences, Tehran, Iran

2 International Otorhinolaryngology Research Association (IORA), Universal Scientific Education and Research Network (USERN), Tehran, Iran

3 Department of Otolaryngology Head and Neck Surgery, Otorhinolaryngology Research Center, Tehran University of Medical Sciences, Tehran, Iran

4 Department of Otorhinolaryngology-Head and Neck Surgery, Faculty of Medicine, Baqiyatallah University of Medical Sciences, Tehran, Iran

5 Student Research Committee, Shahid Sadoughi University of Medical Sciences, Yazd, Iran

References

- [1] Cabanillas ME, McFadden DG, Durante C. Thyroid cancer. *The Lancet*. 2016;388(10061):2016;2783-95
- [2] Curado M-P, Edwards B, Shin HR, Storm H, Ferlay J, Heanue M, et al. *Cancer Incidence in Five Continents, Volume IX*. IARC Press, International Agency for Research on Cancer; 2007
- [3] Jemal A, Siegel R, Xu J, Ward E. Cancer statistics, 2010. *CA: A Cancer Journal for Clinicians*. 2010;60(5):277-300
- [4] Pellegriti G, Frasca F, Regalbuto C, Squatrito S, Vigneri R. Worldwide increasing incidence of thyroid cancer: Update on epidemiology and risk factors. *Journal of Cancer Epidemiology*. 2013;1-10
- [5] Burkhamer J, Kriebel D, Clapp R. The increasing toll of adolescent cancer incidence in the US. *PLoS One*. 2017;12(2):e0172986
- [6] Cooper DS, Doherty GM, Haugen BR, Kloos RT, Lee SL, Mandel SJ, et al. Revised American Thyroid Association management guidelines for patients with thyroid nodules and differentiated thyroid cancer: The American Thyroid Association (ATA) guidelines taskforce on thyroid nodules and differentiated thyroid cancer. *Thyroid*. 2009;19(11):1167-1214
- [7] Shi LL, DeSantis C, Jemal A, Chen AY. Changes in thyroid cancer incidence, post-2009 American Thyroid Association guidelines. *The Laryngoscope*. 2017. DOI: 10.1002/lary.26473
- [8] Davies L, Welch HG. Increasing incidence of thyroid cancer in the United States, 1973-2002. *JAMA*. 2006;295(18):2164-2167
- [9] Davies L, Welch HG. Current thyroid cancer trends in the United States. *JAMA Otolaryngology–Head & Neck Surgery*. 2014;140(4):317-322
- [10] Grodski S, Brown T, Sidhu S, Gill A, Robinson B, Learoyd D, et al. Increasing incidence of thyroid cancer is due to increased pathologic detection. *Surgery*. 2008;144(6):1038-1043
- [11] Aschebrook-Kilfoy B, Ward MH, Sabra MM, Devesa SS. Thyroid cancer incidence patterns in the United States by histologic type, 1992-2006. *Thyroid*. 2011;21(2):125-134
- [12] Chen AY, Jemal A, Ward EM. Increasing incidence of differentiated thyroid cancer in the United States, 1988-2005. *Cancer*. 2009;115(16):3801-3807
- [13] Rego-Iraeta A, Pérez-Méndez LF, Mantinan B, Garcia-Mayor RV. Time trends for thyroid cancer in northwestern Spain: True rise in the incidence of micro and larger forms of papillary thyroid carcinoma. *Thyroid*. 2009;19(4):333-340
- [14] Simard EP, Ward EM, Siegel R, Jemal A. Cancers with increasing incidence trends in the United States: 1999 through 2008. *CA: A Cancer Journal For Clinicians*. 2012;62(2):118-128

- [15] Howlader N NA, Krapcho M, Miller D, Bishop K, Altekruse SF, Kosary CL, Yu M, Ruhl J, Tatalovich Z, Mariotto A, Lewis DR, Chen HS, Feuer EJ, Cronin KA, editors. SEER Cancer Statistics Review, 1975-2013. Bethesda, MD: National Cancer Institute; April 2016. http://seer.cancer.gov/csr/1975_2013/, based on November 2015 SEER data submission, posted to the SEER website
- [16] Dralle H, Machens A, Basa J, Fatourehchi V, Franceschi S, Hay ID, et al. Follicular cell-derived thyroid cancer. *Nature Reviews Disease Primers*. 2014;1:15077-
- [17] Dideban S, Abdollahi A, Meysamie A, Sedghi S, Shahriari M. Thyroid papillary microcarcinoma: Etiology, clinical manifestations, diagnosis, follow-up, histopathology and prognosis. *Iranian Journal of Pathology*. 2016;11(1):1
- [18] Kim WB. A closer look at papillary thyroid carcinoma. *Endocrinology and Metabolism*. 2015;30(1):1-6
- [19] Longo DL KD, Jameson JL, Fauci AS, Hauser SL, Loscalzo J. *Harrison's Principles of Internal Medicine*. 16th ed. New York:McGraw-Hill Publishers; 2012
- [20] Goldman L AD. *Cecil Medicine*. 23rd ed. Saunders Elsevier Publishers; 2007
- [21] Schmid D, Ricci C, Behrens G, Leitzmann M. Adiposity and risk of thyroid cancer: A systematic review and meta-analysis. *Obesity Reviews*. 2015;16(12):1042-1054
- [22] Derwahl M, Nicula D. Estrogen and its role in thyroid cancer. *Endocrine-Related Cancer*. 2014;21(5):T273-T283
- [23] Wang P, Jing Z, Liu C, Xu M, Wang P, Wang X, et al. Hepatitis C virus infection and risk of thyroid cancer: A systematic review and meta-analysis. *Arab Journal of Gastroenterology*. 2017;18(1):1-5
- [24] Ito Y, Miyauchi A, Kobayashi K, Kihara M, Miya A. Static and dynamic prognostic factors of papillary thyroid carcinoma [Review]. *Endocrine Journal*. 2014;61(12):1145-1151
- [25] Cady B, Rossi R. An expanded view of risk-group definition in differentiated thyroid carcinoma. *Surgery*. 1988;104(6):947-953
- [26] Hay ID, Bergstralh EJ, Goellner JR, Ebersold JR, Grant CS. Predicting outcome in papillary thyroid carcinoma: Development of a reliable prognostic scoring system in a cohort of 1779 patients surgically treated at one institution during 1940 through 1989. *Surgery-SAINTE LOUIS*. 1993;114:1050-
- [27] Sobin LHWCe. *UICC: TNM Classification of Malignant Tumors*. 7th ed. New York: Wiley-Liss; 2009
- [28] Ito Y, Ichihara K, Masuoka H, Fukushima M, Inoue H, Kihara M, et al. Establishment of an intraoperative staging system (iStage) by improving UICC TNM classification system for papillary thyroid carcinoma. *World Journal of Surgery*. 2010;34(11):2570-2580
- [29] Ito Y, Kudo T, Kobayashi K, Miya A, Ichihara K, Miyauchi A. Prognostic factors for recurrence of papillary thyroid carcinoma in the lymph nodes, lung, and bone: Analysis of 5,768 patients with average 10-year follow-up. *World Journal of Surgery*. 2012;36(6):1274-1278

- [30] Matsuzu K, Sugino K, Masudo K, Nagahama M, Kitagawa W, Shibuya H, et al. Thyroid lobectomy for papillary thyroid cancer: Long-term follow-up study of 1,088 cases. *World Journal of Surgery*. 2014;38(1):68-79
- [31] Mazurat A, Torroni A, Hendrickson-Rebizant J, Benning H, Nason RW, Pathak KA. The age factor in survival of a population cohort of well-differentiated thyroid cancer. *Endocrine Connections*. 2013;2(3):154-160
- [32] Siironen P, Louhimo J, Nordling S, Ristimäki A, Mäenpää H, Haapiainen R, et al. Prognostic factors in papillary thyroid cancer: An evaluation of 601 consecutive patients. *Tumor Biology*. 2005;26(2):57-64
- [33] Sugitani I, Kasai N, Fujimoto Y, Yanagisawa A. A novel classification system for patients with PTC: Addition of the new variables of large (3 cm or greater) nodal metastases and reclassification during the follow-up period. *Surgery*. 2004;135(2):139-148
- [34] Toniato A, Boschin I, Casara D, Mazzarotto R, Rubello D, Pelizzo M. Papillary thyroid carcinoma: Factors influencing recurrence and survival. *Annals of Surgical Oncology*. 2008;15(5):1518-1522
- [35] Herrera MF, López-Graniel CM, Saldaña J, Gamboa-Domínguez A, Richaud-Patín Y, Vargas-Vorackova F, et al. Papillary thyroid carcinoma in Mexican patients: Clinical aspects and prognostic factors. *World Journal of Surgery*. 1996;20(1):94-100
- [36] Ito Y, Miyauchi A, Kihara M, Kobayashi K, Miya A. Prognostic values of clinical lymph node metastasis and macroscopic extrathyroid extension in papillary thyroid carcinoma [Review]. *Endocrine Journal*. 2014;61(8):745-750
- [37] Miyauchi A, Kudo T, Hirokawa M, Ito Y, Kihara M, Higashiyama T, et al. Ki-67 labeling index is a predictor of postoperative persistent disease and cancer growth and a prognostic indicator in papillary thyroid carcinoma. *European Thyroid Journal*. 2013;2(1):57-64
- [38] Ito Y, Miyauchi A, Kakudo K, Hirokawa M, Kobayashi K, Miya A. Prognostic significance of ki-67 labeling index in papillary thyroid carcinoma. *World Journal of Surgery*. 2010;34(12):3015-3021
- [39] Elisei R, Viola D, Torregrossa L, Giannini R, Romei C, Ugolini C, et al. The BRAF V600E mutation is an independent, poor prognostic factor for the outcome of patients with low-risk intrathyroid papillary thyroid carcinoma: Single-institution results from a large cohort study. *The Journal of Clinical Endocrinology & Metabolism*. 2012;97(12):4390-4398
- [40] Guerra A, Fugazzola L, Marotta V, Cirillo M, Rossi S, Cirello V, et al. A high percentage of BRAFV600E alleles in papillary thyroid carcinoma predicts a poorer outcome. *The Journal of Clinical Endocrinology & Metabolism*. 2012;97(7):2333-2340
- [41] Kwak JY, Kim E-K, Chung WY, Moon HJ, Kim MJ, Choi JR. Association of BRAFV600E mutation with poor clinical prognostic factors and US features in Korean patients with papillary thyroid microcarcinoma 1. *Radiology*. 2009;253(3):854-860

- [42] O'Neill CJ, Bullock M, Chou A, Sidhu SB, Delbridge LW, Robinson BG, et al. BRAF V600E mutation is associated with an increased risk of nodal recurrence requiring reoperative surgery in patients with papillary thyroid cancer. *Surgery*. 2010;148(6):1139-1146
- [43] Yim JH, Kim WG, Jeon MJ, Han JM, Kim TY, Yoon JH, et al. Association between expression of x-linked inhibitor of apoptosis protein and the clinical outcome in a BRAFV600E-prevalent papillary thyroid cancer population. *Thyroid*. 2014;24(4):689-694
- [44] Miyauchi A, Kudo T, Miya A, Kobayashi K, Ito Y, Takamura Y, et al. Prognostic impact of serum thyroglobulin doubling-time under thyrotropin suppression in patients with papillary thyroid carcinoma who underwent total thyroidectomy. *Thyroid*. 2011;21(7):707-716
- [45] Miyauchi A, Kudo T, Kihara M, Higashiyama T, Ito Y, Kobayashi K, et al. Relationship of biochemically persistent disease and thyroglobulin-doubling time to age at surgery in patients with papillary thyroid carcinoma. *Endocrine Journal*. 2013;60(4):415-421
- [46] Kim WG, Yoon JH, Kim WB, Kim TY, Kim EY, Kim JM, et al. Change of serum antithyroglobulin antibody levels is useful for prediction of clinical recurrence in thyroglobulin-negative patients with differentiated thyroid carcinoma. *The Journal of Clinical Endocrinology & Metabolism*. 2008;93(12):4683-4689
- [47] Tsushima Y, Miyauchi A, Ito Y, Kudo T, Masuoka H, Yabuta T, et al. Prognostic significance of changes in serum thyroglobulin antibody levels of pre-and post-total thyroidectomy in thyroglobulin antibody-positive papillary thyroid carcinoma patients. *Endocrine Journal*. 2013;60(7):871-876
- [48] Adam MA, Pura J, Gu L, Dinan MA, Tyler DS, Reed SD, et al. Extent of surgery for papillary thyroid cancer is not associated with survival: An analysis of 61,775 patients. *Annals of Surgery*. 2014;260(4):601
- [49] Bilimoria KY, Bentrem DJ, Ko CY, Stewart AK, Winchester DP, Talamonti MS, et al. Extent of surgery affects survival for papillary thyroid cancer. *Annals of Surgery*. 2007;246(3):375-384
- [50] Lang BH-H, Ng S-H, Lau LL, Cowling BJ, Wong KP, Wan KY. A systematic review and meta-analysis of prophylactic central neck dissection on short-term locoregional recurrence in papillary thyroid carcinoma after total thyroidectomy. *Thyroid*. 2013;23(9):1087-1098
- [51] Haugen BR, Alexander EK, Bible KC, Doherty GM, Mandel SJ, Nikiforov YE, et al. 2015 American Thyroid Association management guidelines for adult patients with thyroid nodules and differentiated thyroid cancer: The American Thyroid Association guidelines task force on thyroid nodules and differentiated thyroid cancer. *Thyroid*. 2016;26(1):1-133
- [52] Barney BM, Hitchcock YJ, Sharma P, Shrieve DC, Tward JD. Overall and cause-specific survival for patients undergoing lobectomy, near-total, or total thyroidectomy for differentiated thyroid cancer. *Head & Neck*. 2011;33(5):645-649

- [53] Haigh PI, Urbach DR, Rotstein LE. Extent of thyroidectomy is not a major determinant of survival in low-or high-risk papillary thyroid cancer. *Annals of Surgical Oncology*. 2005;12(1):81-89
- [54] Mendelsohn AH, Elashoff DA, Abemayor E, St John MA. Surgery for papillary thyroid carcinoma: Is lobectomy enough? *Archives of Otolaryngology–Head & Neck Surgery*. 2010;136(11):1055-1061
- [55] Ito Y, Miyauchi A, Inoue H, Fukushima M, Kihara M, Higashiyama T, et al. An observational trial for papillary thyroid microcarcinoma in Japanese patients. *World Journal of Surgery*. 2010;34(1):28
- [56] Sugitani I, Toda K, Yamada K, Yamamoto N, Ikenaga M, Fujimoto Y. Three distinctly different kinds of papillary thyroid microcarcinoma should be recognized: Our treatment strategies and outcomes. *World Journal of Surgery*. 2010;34(6):1222-1231
- [57] Durante C, Montesano T, Attard M, Torlontano M, Monzani F, Costante G, et al. Long-term surveillance of papillary thyroid cancer patients who do not undergo postoperative radioiodine remnant ablation: Is there a role for serum thyroglobulin measurement? *The Journal of Clinical Endocrinology & Metabolism*. 2012;97(8):2748-2753
- [58] Fabián P, Erika A, Hernán T, Fernanda B, Carolina U. Biochemical persistence in thyroid cancer: Is there anything to worry about? *Endocrine*. 2014;46(3):532-537
- [59] Tuttle RM, Tala H, Shah J, Leboeuf R, Ghossein R, Gonen M, et al. Estimating risk of recurrence in differentiated thyroid cancer after total thyroidectomy and radioactive iodine remnant ablation: Using response to therapy variables to modify the initial risk estimates predicted by the new American Thyroid Association staging system. *Thyroid*. 2010;20(12):1341-1349
- [60] Vaisman F, Shaha A, Fish S, Michael Tuttle R. Initial therapy with either thyroid lobectomy or total thyroidectomy without radioactive iodine remnant ablation is associated with very low rates of structural disease recurrence in properly selected patients with differentiated thyroid cancer. *Clinical Endocrinology*. 2011;75(1):112-119
- [61] Sawka AM, Thabane L, Parlea L, Ibrahim-Zada I, Tsang RW, Brierley JD, et al. Second primary malignancy risk after radioactive iodine treatment for thyroid cancer: A systematic review and meta-analysis. *Thyroid*. 2009;19(5):451-457
- [62] Biondi B, Filetti S, Schlumberger M. Thyroid-hormone therapy and thyroid cancer: A reassessment. *Nature Reviews Endocrinology*. 2005;1(1):32-40
- [63] Mazzaferri EL, Kloos RT. Current approaches to primary therapy for papillary and follicular thyroid cancer. *The Journal of Clinical Endocrinology & Metabolism*. 2001;86(4):1447-1463
- [64] Carhill AA, Litofsky DR, Ross DS, Jonklaas J, Cooper DS, Brierley JD, et al. Long-term outcomes following therapy in differentiated thyroid carcinoma: NTCTCS registry analysis 1987-2012. *The Journal of Clinical Endocrinology & Metabolism*. 2015;100(9):3270-3279

- [65] Jonklaas J, Sarlis NJ, Litofsky D, Ain KB, Bigos ST, Brierley JD, et al. Outcomes of patients with differentiated thyroid carcinoma following initial therapy. *Thyroid*. 2006;16(12):1229-1242
- [66] Cooper DS, Biondi B. Subclinical thyroid disease. *The Lancet*. 2012;379(9821):1142-1154
- [67] DeLellis RA. Pathology and genetics of tumours of endocrine organs: Lyon: Oxford: IARC Press; Oxford University Press (distributor), 2004
- [68] Livolsi VA. Surgical pathology of the thyroid: Philadelphia:WB Saunders Company; 1990
- [69] Rosai J. Tumors of the thyroid gland. Atlas of Tumor Pathology. 1992
- [70] Ahmadi S, Stang M. Hürthle cell carcinoma: Current perspectives. *OncoTargets and Therapy*. 2016;9:6873
- [71] Hürthle K. Beiträge zur Kenntniss des Secretionsvorgangs in der Schilddrüse. *Archiv für die Gesamte Physiologie des Menschen und der Tiere*. 1894;56(1-3):1-44
- [72] Montone KT, Baloch ZW, LiVolsi VA. The thyroid Hürthle (oncocyctic) cell and its associated pathologic conditions: A surgical pathology and cytopathology review. *Archives of Pathology & Laboratory Medicine*. 2008;132(8):1241-1250
- [73] Hundahl SA, Fleming ID, Fremgen AM, Menck HR. A National Cancer Data Base report on 53,856 cases of thyroid carcinoma treated in the US, 1985-1995. *Cancer*. 1998;83(12):2638-2648
- [74] Goffredo P, Roman SA, Sosa JA. Hurthle cell carcinoma. *Cancer*. 2013;119(3):504-511
- [75] Chindris A-M, Casler JD, Bernet VJ, Rivera M, Thomas C, Kachergus JM, et al. Clinical and molecular features of Hürthle cell carcinoma of the thyroid. *The Journal of Clinical Endocrinology & Metabolism*. 2014;100(1):55-62
- [76] Schlumberger M, Challeton C, De Vathaire F, Travagli J-P. Radioactive iodine treatment and external radiotherapy for lung and bone metastases from thyroid carcinoma. *The Journal of Nuclear Medicine*. 1996;37(4):598
- [77] Patel KN, Shaha AR. Poorly differentiated thyroid cancer. *Current Opinion in Otolaryngology & Head and Neck Surgery*. 2014;22(2):121-126
- [78] Sakamoto A, Kasai N, Sugano H. Poorly differentiated carcinoma of the thyroid. A clinicopathologic entity for a high-risk group of papillary and follicular carcinomas. *Cancer*. 1983;52(10):1849-1855
- [79] Burman KD, Ringel MD, Wartofsky L. Unusual types of thyroid neoplasms. *Endocrinology and Metabolism Clinics of North America*. 1996;25(1):49-68
- [80] Sywak M, Pasiaka JL, Ogilvie T. A review of thyroid cancer with intermediate differentiation. *Journal of Surgical Oncology*. 2004;86(1):44-54

- [81] Carcangiu ML, Zamp G, Rosai J. Poorly differentiated (“insular”) thyroid carcinoma: A reinterpretation of Langhans’ “wuchernde Struma”. *The American Journal of Surgical Pathology*. 1984;8(9):655-668
- [82] Nishida T, Katayama S-i, Tsujimoto M, Nakamura J-i, Matsuda H. Clinicopathological significance of poorly differentiated thyroid carcinoma. *The American Journal of Surgical Pathology*. 1999;23(2):205-211
- [83] Sobrinho-Simoes M, Sambade C, Fonseca E, Soares P. Poorly differentiated carcinomas of the thyroid gland: A review of the clinicopathologic features of a series of 28 cases of a heterogeneous, clinically aggressive group of thyroid tumors. *International Journal of Surgical Pathology*. 2002;10(2):123-131
- [84] Volante M, Collini P, Nikiforov YE, Sakamoto A, Kakudo K, Katoh R, et al. Poorly differentiated thyroid carcinoma: The Turin proposal for the use of uniform diagnostic criteria and an algorithmic diagnostic approach. *The American Journal of Surgical Pathology*. 2007;31(8):1256-1264
- [85] Bongiovanni M, Sadow PM, Faquin WC. Poorly differentiated thyroid carcinoma: A cytologic-histologic review. *Advances in Anatomic Pathology*. 2009;16(5):283-289
- [86] Chao T-C, Lin J-D, Chen M-F. Insular carcinoma: Infrequent subtype of thyroid cancer with aggressive clinical course. *World Journal of Surgery*. 2004;28(4):393-396
- [87] Sanders Jr EM, LiVolsi VA, Brierley J, Shin J, Randolph GW. An evidence-based review of poorly differentiated thyroid cancer. *World Journal of Surgery*. 2007;31(5):934-945
- [88] Patel KN, Shaha AR. Poorly differentiated and anaplastic thyroid cancer. *Cancer Control*. 2006;13(2):119
- [89] Hannallah J, Rose J, Guerrero MA. Comprehensive literature review: Recent advances in diagnosing and managing patients with poorly differentiated thyroid carcinoma. *International Journal of Endocrinology*. 2013;1-7
- [90] Jung TS, Kim TY, Kim KW, Oh YL, Park DJ, Cho BY, et al. Clinical features and prognostic factors for survival in patients with poorly differentiated thyroid carcinoma and comparison to the patients with the aggressive variants of papillary thyroid carcinoma. *Endocrine Journal*. 2007;54(2):265-274
- [91] Volante M, Cavallo GP, Papotti M. Prognostic factors of clinical interest in poorly differentiated carcinomas of the thyroid. *Endocrine Pathology*. 2004;15(4):313-317
- [92] Walczyk A, Kowalska A, Sygut J. The clinical course of poorly differentiated thyroid carcinoma (insular carcinoma)—Own observations. *Endokrynologia Polska*. 2010;61(5):467-473
- [93] Wreesmann VB, Ghossein RA, Patel SG, Harris CP, Schnaser EA, Shaha AR, et al. Genome-wide appraisal of thyroid cancer progression. *The American Journal of Pathology*. 2002;161(5):1549-1556
- [94] Dijkstra B, Prichard R, Lee A, Kelly L, Smyth P, Crotty T, et al. Changing patterns of thyroid carcinoma. *Irish Journal of Medical Science*. 2007;176(2):87-90

- [95] O'Neill JP, Shaha AR. Anaplastic thyroid cancer. *Oral Oncology*. 2013;**49**(7):702-706
- [96] Smallridge RC, Copland J. Anaplastic thyroid carcinoma: Pathogenesis and emerging therapies. *Clinical Oncology*. 2010;**22**(6):486-497
- [97] Keutgen XM, Sadowski SM, Kebebew E. Management of anaplastic thyroid cancer. *Gland Surgery*. 2015;**4**(1):44-51
- [98] Kebebew E, Greenspan FS, Clark OH, Woeber KA, McMillan A. Anaplastic thyroid carcinoma. *Cancer*. 2005;**103**(7):1330-1335
- [99] Kihara M, Miyauchi A, Yamauchi A, Yokomise H. Prognostic factors of anaplastic thyroid carcinoma. *Surgery Today*. 2004;**34**(5):394-398
- [100] Kim TY, Kim KW, Jung TS, Kim JM, Kim SW, Chung KW, et al. Prognostic factors for Korean patients with anaplastic thyroid carcinoma. *Head & Neck*. 2007;**29**(8):765-772
- [101] Sugitani I, Kasai N, Fujimoto Y, Yanagisawa A. Prognostic factors and therapeutic strategy for anaplastic carcinoma of the thyroid. *World Journal of Surgery*. 2001;**25**(5):617-622
- [102] Sugitani I, Miyauchi A, Sugino K, Okamoto T, Yoshida A, Suzuki S. Prognostic factors and treatment outcomes for anaplastic thyroid carcinoma: ATC Research Consortium of Japan cohort study of 677 patients. *World Journal of Surgery*. 2012;**36**(6):1247-1254
- [103] Hyman DM, Puzanov I, Subbiah V, Faris JE, Chau I, Blay J-Y, et al. Vemurafenib in multiple nonmelanoma cancers with BRAF V600 mutations. *New England Journal of Medicine*. 2015;**373**(8):726-736
- [104] Raue F, Frank-Raue K. Epidemiology and clinical presentation of medullary thyroid carcinoma. *Medullary Thyroid Carcinoma*. Springer; 2015. pp. 61-90
- [105] Wells Jr SA, Asa SL, Dralle H, Elisei R, Evans DB, Gagel RF, et al. Revised American Thyroid Association guidelines for the management of medullary thyroid carcinoma: The American Thyroid Association Guidelines Task Force on medullary thyroid carcinoma. *Thyroid*. 2015;**25**(6):567-610
- [106] Moley JF. Medullary thyroid carcinoma: Management of lymph node metastases. *Journal of the National Comprehensive Cancer Network*. 2010;**8**(5):549-556
- [107] Meijer JA, Le Cessie S, Van Den Hout WB, Kievit J, Schoones JW, Romijn JA, et al. Calcitonin and carcinoembryonic antigen doubling times as prognostic factors in medullary thyroid carcinoma: A structured meta-analysis. *Clinical Endocrinology*. 2010;**72**(4):534-542
- [108] Akhavan A, Jafari SM, Khosravi MH, Khajepour H, Karimi-Sari H. Reliability of fine-needle aspiration and ultrasound-based characteristics of thyroid nodules for diagnosing malignancy in Iranian patients. *Diagnostic Cytopathology*. 2016 Apr 1;**44**(4):269-73
- [109] Fukunari N, Nagahama M, Sugino K, Mimura T, Ito K, Ito K. Clinical evaluation of color Doppler imaging for the differential diagnosis of thyroid follicular lesions. *World Journal of Surgery*. 2004;**28**(12):1261-1265

- [110] Lee SH, Baek JS, Lee JY, Lim JA, Cho SY, Lee TH, et al. Predictive factors of malignancy in thyroid nodules with a cytological diagnosis of follicular neoplasm. *Endocrine Pathology*. 2013;24(4):177-183
- [111] Lubitz CC, Faquin WC, Yang J, Mekel M, Gaz RD, Parangi S, et al. Clinical and cytological features predictive of malignancy in thyroid follicular neoplasms. *Thyroid*. 2010;20(1):25-31
- [112] Miyakawa M, Onoda N, Fukuda I, Takano K, Okamoto T, Obara T. Diagnosis of thyroid follicular carcinoma by the vascular pattern and velocimetric parameters using high resolution pulsed and power Doppler ultrasonography. *Endocrine Journal*. 2005;52(2):207-212