

# We are IntechOpen, the world's leading publisher of Open Access books Built by scientists, for scientists

4,800

Open access books available

122,000

International authors and editors

135M

Downloads

Our authors are among the

154

Countries delivered to

TOP 1%

most cited scientists

12.2%

Contributors from top 500 universities



WEB OF SCIENCE™

Selection of our books indexed in the Book Citation Index  
in Web of Science™ Core Collection (BKCI)

Interested in publishing with us?  
Contact [book.department@intechopen.com](mailto:book.department@intechopen.com)

Numbers displayed above are based on latest data collected.  
For more information visit [www.intechopen.com](http://www.intechopen.com)



---

# The Role of Physical Medicine and Rehabilitation in Shoulder Disorders

---

Raoul Saggini, Simona Maria Carmignano,  
Lucia Cosenza, Tommaso Palermo and  
Rosa Grazia Bellomo

Additional information is available at the end of the chapter

<http://dx.doi.org/10.5772/intechopen.70344>

---

## Abstract

Shoulder pain is a common problem and it is responsible for a high proportion of patients presenting to general practice, causing work absenteeism and claims for sickness. A lot of factors and conditions can contribute to shoulder pain. The most prevalent cause is rotator cuff tendinitis; its relevance is correlated not only to its high prevalence rate but also to the fact that is disabling, causing high direct and indirect cost in industrialized country. Other causes of shoulder pain are shoulder impingement syndrome, calcific tendonitis, frozen shoulder, etc. In this context, physical medicine and rehabilitation plays a fundamental role. The conservative approach consists of several interventions. The aim is to decrease shoulder pain and to regain shoulder function, with the goal to reduce the degree of impingement, decreasing swelling and inflammation, and to minimize the risk of further injuries. The purpose of this chapter is to give an overview about shoulder disorders and their conservative treatment by means of physical therapy.

**Keywords:** shoulder disorders, physical therapy, rehabilitation, rotator cuff, frozen shoulder, ESWT

---

## 1. Introduction

Shoulder pain is a widespread problem and is responsible for a high percentage of patients presenting to general practice, causing absenteeism and labor complaints for sickness [1].

A lot of factors and conditions may contribute to shoulder pain. The most common cause is rotator cuff tendinopathy; its importance is linked not only to its high prevalence rate, but also because it is a disabling condition, causing high costs for health service [2].

As mentioned, rotator cuff injury is one of the most common shoulder disorders. Among these, the most common are tendinosis, partial thickness tear, and complete rupture. The incidence of the cuff injuries varies from 5 to 39%; it increases in the elderly population, being approximately 6 and 30%, respectively in patients aged below and above 60 years [3].

In this context, physical medicine and rehabilitation plays a fundamental role. The conservative approach consists of several interventions. The aim of these is to decrease shoulder pain and to regain shoulder function, with the goal to reduce the degree of impingement, decreasing swelling and inflammation, and minimizing the risk of further injuries. Many studies have shown that conservative therapy is the first-line treatment for shoulder disorders, in fact rehabilitative approach allows a reduction in pain feeling and symptoms within few weeks [4].

In literature, several studies have proposed conservative treatment for shoulder diseases, such as non-steroidal anti-inflammatory drugs (NSAIDs), cortisone injections, stretching and strengthening exercises, manual therapy, and physical energies (cryotherapy, extracorporeal shock wave therapy (ESWT), laser therapy, ultrasounds, etc.) to reduce pain feeling and restore shoulder range of motion (ROM) and function.

The purpose of this chapter is to give an overview about shoulder disorders and their conservative treatment by means of physical therapy, reviewing scientific researches, and merging it with our experience in this field. Rehabilitation of shoulder disorders is not easy, because its complex function, which involves not only local structures integrity, but also biomechanics contribution, from other body subsystems. For this reason, it is important to highlight the need of establish a global rehabilitative approach.

## 2. Biomechanics

Understanding rotator cuff functions and shoulder biomechanics, it is crucial to understand shoulder disorders and their pathogenesis. The rotator cuff allows the stabilization of the glenohumeral joint, compressing the humeral head on the glenoid of the scapula [5, 6]. This mechanism is due to the equal and opposite action of the subscapularis anteriorly and infraspinatus and teres minor muscles posteriorly [7–10].

Scientific studies about shoulder biomechanics have explained precisely the contribution of every ligaments, tendons and muscles to shoulder stability. The action of rotator cuff is to compress the humeral head against scapular glenoid giving stabilization to the joint and allowing concentric rotation [6, 11–13]. Rotator cuff muscles play an important role in stabilizing glenohumeral joint through this compressive mechanism, in particular during mid-ranges motion in which ligaments are lax [14]. Concavity compression mechanism is also important at end-ranges of motion, during which rotator cuff muscles protects ligaments by limiting the range of motion [15, 16] and decreasing strain, usually increased when shoulder

reaches maximum abduction and extrarotation [14, 17, 18]. When shoulder joint is in neutral position, rotator cuff muscles contribute equally in providing anterior stability [19]. However, with glenohumeral joint in end-range abduction, subscapularis is a less effective stabilizer than other muscles, while the biceps brachii starts to play a role in joint stability [20].

The “concavity compression” is an important stability mechanism. The compression of the humeral head (convex), exercised by muscles of the rotator cuff, on the glenoid cavity (concave), maintains stable humeral epiphysis, in relation to translational forces. Resistance to joint subluxation is directly proportional to the depth of the articular concavity and to the compression force exerted by the muscles of the rotator cuff [15]. Concavity compression, providing stability of glenohumeral joint, also depends on the extension of glenoid’s articular surface (glenoid arc) available to accommodate humeral head [21].

Stabilization function is made evident when the disease is established; in fact, a rotator cuff tear results in the inefficiency of this mechanism with the consequent sliding of the humeral head upward. This is due to the action of the upper fibers of the deltoid muscle, resulting in a subacromial impingement [22].

The action of the rotator cuff muscles must be highly coordinated to be able to perform a specific movement. The muscles must work in coordination, as the rotation of the glenohumeral joint does not have a fixed axis [23].

Tension loads acting on rotator cuff tendons can be divided into two types: concentric and eccentric. Concentric ones are generated when humerus has the same direction of cuff muscle, as it happens during abduction against resistance. These loads are better tolerated by the cuff insertion, which clears the acromion at low angles of elevation, protecting it from impingement by the coracoacromial arch. Eccentric tension loads are produced when the arm movement is opposed to the direction of cuff muscles direction. This occurs in example during active resistance to a downward force applied on the humerus. In fact, when the humeral head rotates with respect of the scapula, bending loads stress cuff tendons; cuff elasticity permits to resist these loads. Rotator cuff tendons are also subjected to compressive loads; an upwardly load presses the cuff between the humeral head and the coracoacromial arch [24]. Furthermore, it has demonstrated a morphologic adaptation of the supraspinatus tendon with fibrocartilaginous areas in regions of compression, due to mechanical forces [25].

Every rotator cuff muscle origins on the scapula, which therefore influences the activity of these muscles. Therefore, rotator cuff performance is strictly related to the functional state of the scapula. When this bone is well stabilized, thus presenting the proper position in both static and dynamic tasks, it permits rotator cuff to work at an optimal level. However, alterations in scapular kinematics produce an unstable support to rotator cuff and consequently it affects the biomechanics of the shoulder. Scapular dysfunctions may be causative in rotator cuff disorders or may be the result of rotator cuff injuries, increasing the alteration [26].

Many authors have studied scapula kinematics in patients with rotator cuff diseases; alterations in scapular function have been found in most studies. In subjects with clinical symptoms or imaging demonstrating rotator cuff disorders, studies have demonstrated biomechanics alterations, especially scapular dyskinesia [27]. Possible alterations are not consistent, with

various combinations of changes like increase in upward rotation, decrease in posterior tilt and increase in internal rotation. However, the exact relationship between scapular dyskinesia and rotator cuff disorder is not completely clear; is dyskinesia a cause, an effect or a compensation? [26]

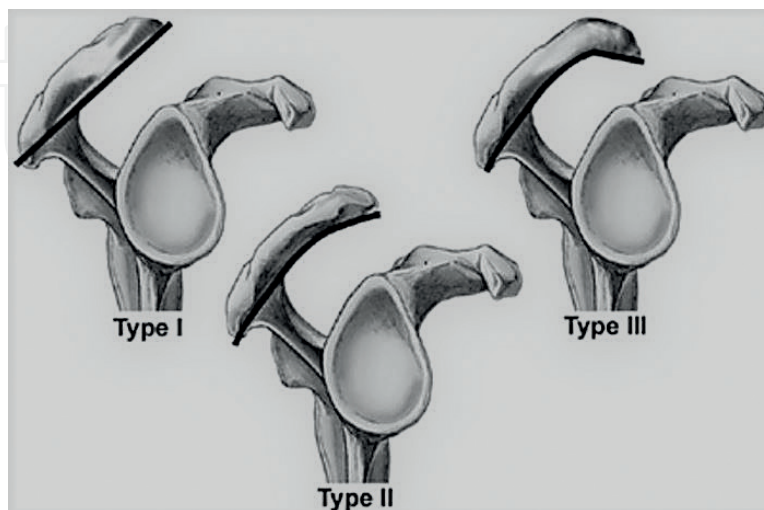
### 3. Shoulder disorders

Pathogenesis of rotator cuff injuries is not completely clear, but it may arise from extrinsic factors, impingement by structures surrounding the cuff, and intrinsic alterations of the tendon itself [28].

On the tendinous portion of the rotator cuff impingement by the coracoacromial ligament and the acromion itself is responsible for the characteristic “impingement syndrome”. A peculiar proliferative spur and ridge on the anterior lip and undersurface of the acromial anterior process has been found; furthermore, in many studies this area has shown erosions [4].

Anatomical changes may excessively narrow the subacromial space, in which rotator cuff tendons pass through, and include acromial shape variations (i.e. hooked acromion), orientation of the acromial angle or prominent osseous changes of the inferior portion of the acromion-clavicular joint [29]. In 1986, Bigliani [30] described the important role of acromion shape, as an extrinsic mechanism, in rotator cuff tendinopathy; acromion classified into three types based on different shapes (**Figure 1**): Flat (Type I), Curved (Type II) and Hooked (Type III).

Association between acromion shape and severity of rotator cuff disorder has been well documented, with a greater prevalence of hooked acromion in subjects with subacromial impingement syndrome and full thickness tears. Alterations of shoulder kinematics, postural abnormalities, rotator cuff muscles deficits and decreased extensibility of pectoralis minor are biomechanical factors which can lead to rotator cuff tendons compression [4]. In addition,



**Figure 1.** Bigliani classification for acromial in different shapes.

shoulder kinematic alterations can cause a dynamic reduction of the subacromial space (compressing rotator cuff tendons) due to a superior shift of the humeral head [31] or an altered scapula biomechanics that leads acromion sliding downwards [32].

Recent studies suggested that subacromial bursa is a pro-inflammatory membrane responsible for shoulder pain and other subacromial disorders. Blaine [33] demonstrated that inflammatory cytokines, such as Tumor necrosis factor (TNF), Interleukin 1 (IL-1), Interleukin 6 (IL-6), cyclooxygenase-1 (COX-1) and cyclooxygenase-2 (COX-2), increase in subacromial bursal in subjects suffering from bursitis and rotator cuff syndrome. It should also be pointed out that IL-1 and IL-6 play an important role as mediators of collagen catabolism [34].

Peritendinous alterations in rotator cuff disorders are thought to be a secondary phenomenon. Chandler [35] showed that the increased tension in the coracoacromial ligament, due to tendinopathy, stimulates the neoformation of bone on the underside of the acromion, which may result in an impingement syndrome leading to enthesopathy.

Acromial lateral sloping or glenoid version is structural features which play an important role in rotator cuff pathology as extrinsic factors. As mentioned in the previous paragraph, acromion shape influences supraspinatus tendon as it passes under the coracoacromial arch. Even a forward scapula posture, caused by forward head posture and increased kyphosis in combination, can reduce the subacromial space [36].

Intrinsic factors, causing rotator cuff tendinopathy, affect tendon morphology and performance. There is growing evidence in literature supporting the fundamental role of these mechanisms in shoulder disorders.

Intrinsic mechanisms, such as aging processes, poor vascularity and altered biology, lead to tendon degradation also influencing tensile forces and altering loads [37–40].

A reduction in vascular supply of tendons is implicated in rotator cuff tears pathogenesis. In 1934, Codman described for the first time the “critical zone” (1 cm<sup>2</sup> area between the insertion of supraspinatus tendon at greater tubercle and myotendinous junction) which represents the most common site for tendon injury due to its reduced vascularity [4].

Tendon degeneration is the expression of an increased production by tenocytes of metalloproteinase enzymes (MMP); this means that tendon tears are an active and cell-mediated process. The hypothesis is that rotator cuff tears are the results of an imbalance between tendon synthesis and degradation, maybe due to the failed regulation of MMP activity in response of repeated mechanical strains. Tendon degeneration is further evident as it has demonstrated an increase in sulfated glycosaminoglycans (GAG) in supraspinatus tendinosis [41]. Sulfated GAG are associated with acute inflammation and new matrix formation, as well as amyloid production. A study conducted by Cole [42] demonstrated that supraspinatus chronic tears were characterized by 70% amyloid deposition on tendon context, unlike only 25% in patients suffering from acute traumatic injuries.

Another feature that may lead to shoulder disorders is genetics; it seems to be related to the polymorphism of genes which regulates collagen synthesis, like the one found in Achilles tendinopathy. However, this is just a hypothesis since no genes were identified till now as risk factors for rotator cuff diseases [43–45].



Other factors can influence mechanical properties and tensile loads response including tendon geometry, due to collagen fiber alignment. Among tendon alterations, it is important to highlight tendon irregularity and thinning, observed in subjects suffering from degenerative rotator cuff tendinopathy; these conditions influence mechanical properties. Even aging has been observed to be a negative factor for tendon degeneration. Biomechanical studies showed a reduced elasticity and a decreased tensile strength in tendons with aging [4]. Histological studies about rotator cuff tendons showed degenerative changes (calcifications and fibrovascular proliferation) in elderly in comparison to young people, both groups without history of shoulder disorders. Furthermore, aging causes a reduction in total sulfated GAG and proteoglycans in supraspinatus tendon [46].

Other scientific researches demonstrated in elderly people a reduction of type I collagen and an increase in type III, weaker and more irregularly; however there is no consensus in literature whether these changes are related with aging or a secondary consequence of healing processes to repeated microtrauma (or overuse) [47].

An interesting classification is the one developed by Celli [48] that divides the old denomination "shoulder periarthritis" in four clinical presentations, depending on the type, localization and pain:

1. Acute anterior shoulder: where inflammation is limited to the supraspinatus tendon and/or to the long head of the biceps tendon.
2. Global acute shoulder: pain is acute and inflammation compromised subdeltoid bursa.
3. Chronic anterior shoulder: pain is chronic and localized on the anterior region.
4. Global chronic shoulder: even in this case the pain is chronic, but it affects the whole shoulder.

This classification has the advantage of easy application, but there is no immediate correlation with the cause of degeneration. The most common cause of shoulder pain is an inflammation of the bursae around the glenohumeral joint. The most affected is the subacromial bursa, located between the acromion and the tendons of rotator cuff, but also subdeltoid, subscapularis and subcoracoid bursae may be affected.

Pain is localized on the side of the proximal part of the arm, but it may also extend distally if the inflammatory process involves subdeltoid bursa, which often communicates with the subacromial one. Movements accentuate symptoms, particularly active abduction, that is markedly limited by pain.

### **3.1. Rotator cuff tendinosis**

The incidence of rotator cuff tendinopathy and degenerative tears increases in aging and it is 40% in subjects over 70 years of age [49].

Rotator cuff tendinosis is due to disorganization in collagen fibers morphology and to alterations in tendon ultrastructure. Earlier studies showed histopathological changes associated

with rotator cuff tendinosis: tendon fibers thinning and consequently ultrastructural alterations, cellular apoptosis, granulation tissue production and fibro-cartilaginous changes [50, 51]. The risk of progression, which can lead to full tendon rupture, is related to these histopathological changes.

Hyaline and myxoid degeneration, which can affect collagen fibers, already occur in the degenerated tendon. The consequence of this is a reduction in tensile resistance that predisposes the tendon to rupture [4].

In degenerated tendon, healing processes are altered. In fact, the standard composition and structure of the osteotendinous insertion site, with the transition from non-mineralized to mineralized fibrocartilage, is not achieved. The causes of this poor healing process are multifactorial, but correlated to an inadequate and disorganized expression of the cytokines responsible for the formation of the complex structure and composition of the enthesis [52].

Other factors that may influence healing processes are the presence of inflammatory cells in the osteotendinous insertion site and a small number of stem cells in the tendon-bone interface, which hamper physiological scar formation [53].

Healing process occurs in three steps:

Step 1. Inflammatory phase

Step 2. Repairing phase

Step 3. Remodeling phase

An alteration during one of these phases leads to a bad regenerative process. Recent studies demonstrated the importance of the inflammatory phase, during which there is an increase of neutrophils, macrophages and mast cells in rotator cuff lesions in animal and human models. Millar et al. [54] evaluated rotator cuff tendon samples taken by biopsy during repairing phase. They observed significant infiltration of mast cells and macrophages in earlier phase of tendinopathy. Subsequently macrophages produce transforming growth factor- $\beta$ 1 (TGF- $\beta$ 1), which stimulates collagen formation and proteinase activity.

Fibrovascular scar is probably produced during this phase thanks to the action of macrophages. During the repairing phase of healing process, fibroblasts activation determines the expression of various cytokines, such as basic fibroblast growth factor (bFGF), insulin-like growth factor (IGF-1), platelet-derived growth factor-b (PDGF-b), vascular endothelial growth factor (VEGF), bone morphogenic protein-12 (BMP-12), BMP-13 and BMP-14 [4].

### **3.2. Calcific tendonitis**

Calcific tendonitis can be potentially included in the sum of rotator cuff diseases. Its prevalence is estimated between 2.7 and 20% according to radiographies of asymptomatic adults. Usually occurs between the age of 40 and 50, with a higher prevalence in female sex and in sedentary workers. The probability of becoming symptomatic, both acute and chronic, has been estimated to be higher than 50% [52].



A 2009 study conducted by Maugars et al. [53] pointed out that between 7 and 17% of patients suffering from chronic shoulder pain was due to tendon calcification.

Calcific tendonitis is not simply a degenerative disorder, since calcification is not histologically associated with necrosis or tissue damage, but it is a cell-mediated process similar to an incomplete endochondral ossification.

One of the first authors to describe the calcium deposits cycle was Uthoff [55] who divided it into two phases: a formative and resorptive one. Other authors subdivided the cycle into three phases: pre-calcification (asymptomatic), calcification (impingement) and post-calcification (acute) [56].

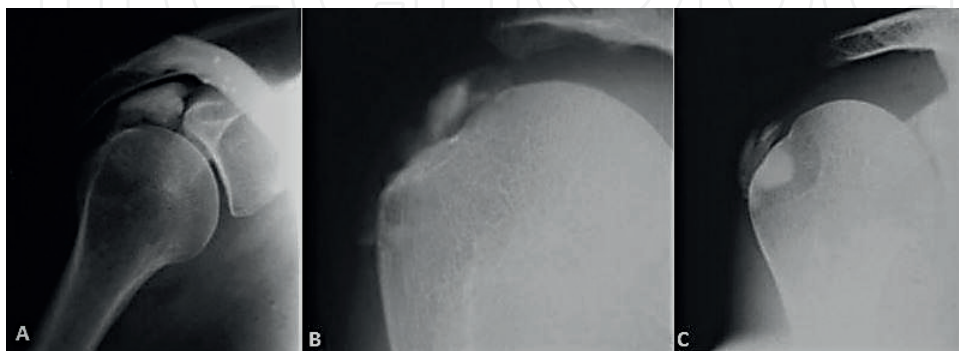
A more complete classification divided this cycle into four phases: pre-calcific phase, during which the fibrocartilaginous transformation occurs in the tendon context in a completely asymptomatic manner; formation phase that consists of the deposition of hydroxyapatite crystals within the tendon; re-absorbing phase, characterized by the release of these crystals and finally post calcific recovering phase.

It is therefore evident that there is currently no standardized histological classification for tendon calcifications in literature.

In concern to the radiographic aspects of calcification, many studies converge on Gartner's classification (1993), whereby three kinds of deposits can be identified. Type I refers to a well-defined and dense deposit, type II identifies a well-distinguished but radiotransparent deposit and finally, type III has a radiotransparent structure but with marginal margins [57].

In fact, the classification of the French Arthroscopic Society [58] also identifies three types of calcifications, indicating them with letters A, B and C (**Figure 2**), which reproduce the description of Gartner.

The authors discussed for a long time about the use of radiographic classification both to choose the most appropriate treatment and as an outcome to evaluate its beneficial effect. The fundamental concept is that radiographic classification is not sufficient on its own, but correlation with the clinical data is always necessary [59, 60].



**Figure 2.** Classification of calcifications by French Arthroscopic Society. A: Dense deposit and well-defined margins, C: nubecular deposit, margins not defined. B: intermediate between the two previous types.

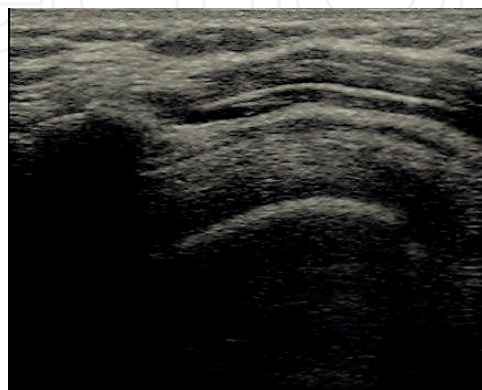
### 3.3. Subacromial bursitis and impingement

The subacromial bursa is the largest and most complicated bursa in human body. In a 1934 book [61], Codman affirmed that it behaves as a secondary scapula-humeral joint, although it is not composed of cartilage tissue. Therefore, he highlighted the functional issue of subacromial bursa. In 1972, Neer [62] further emphasized this point of view in his studies on impingement syndrome. Moreover, in other studies, he suggested that subacromial bursa is an inflammatory membrane that can lead to pain through nociceptors endings stimulation. Santavirta et al. [63] found a majority of CD-2 and CD-11b mononuclear cells in the bursa of patients suffering from subacromial bursitis. Yanagisawa [64] also demonstrated an increased expression of VEGF in patients with impingement syndrome, thus pointing out chronic inflammation and increased vascularity. Other studies [65] demonstrated the increased expression of pain mediators (substance P) in the subacromial space in subjects with impingement syndrome.

Despite these evidences about subacromial bursa, the changes in biochemical mediators expression, implicated in subacromial impingement syndrome pathogenesis, have not yet completely identified. These investigations were carried on to determine the role of subacromial bursa in impingement syndrome; the question is if the bursa behaves as a pathological or a reparative tissue.

During “bursitis” (**Figure 3**), there is a reduction of the overall subacromial space, which may lead to an increased compression of tissues inside. During subacromial impingement syndrome, it has been demonstrated tendons degeneration, due to inflammatory processes or tension overload in shoulder mobilization (e.g. during work activities) [4].

Impingement syndrome classification was first developed by Neer in 1983 [66] and it is based on histopathological damage of tissues. He defined this syndrome as a mechanical-compressive lesion of tissues of the subacromial space and he identified three progressive stages: first stage (“edema and hemorrhage stage”) is typical in patients aged 25 or less with a history of overhead use of the upper limb during sport or work; second stage is defined by further deterioration of rotator cuff tendons and subacromial bursa, and it usually affects 25–40 years old patients; last stage, the third one, is characterized by bone spurs and partial or full-thickness tendon rupture affecting subjects aged 40 or more.



**Figure 3.** Subacromial bursitis: ultrasound imaging.

### 3.4. Rotator cuff tears

Rotator cuff tears represent approximately one-third of medical visits for shoulder pain, but sometimes it is a problem difficult to diagnose. Among patients suffering from shoulder pain, rotator cuff tears are the most common cause, especially in subjects aged 60 or more [67]. The incidence of this pathology increases with age; moreover, studies on cadavers have noticed 30% of cases with rotator cuff tears [68]. As mentioned, literature agrees that the incidence increases with age. In particular, a study [69] noted that the incidence of asymptomatic tears in patients aged 50–59 years was 13%, between 60 and 69 years the incidence was 20%, among 70–79 years was 31% and over 80 years was 51%. Yamamoto et al. [67] observed a prevalence of full-thickness tears of 20.7% in a sample population, mean age 57.9 years, with or without symptoms. In a 2006 review of autopsy studies, evaluating 2553 shoulders (mean age 70.1 years), it observed a prevalence of 18.5% for partial-thickness tears and 11.8% for full lesions [68]. Rotator cuff tears are very common, so the pathological history and the clinical examination play a critical role, especially in subclinical cases.

Pathogenesis of rotator cuff tears is complex and multifactorial. For this reason, there are two different schools of thought, according to which tendon injuries can be due to intrinsic or extrinsic factors. Codman [61] had already described the intrinsic theory according to which tendon degenerates in the critical area of hypovascularity; this area is 1 cm from the insertion of supraspinatus to the humeral head. Besides this, due to its low vascularization, it is also an area with low healing capacity. According to extrinsic theory, the cuff tendons, flowing into the subacromial space (i.e. between the acromion, the coracoacromial ligament and the humeral head) can be compressed and then injured.

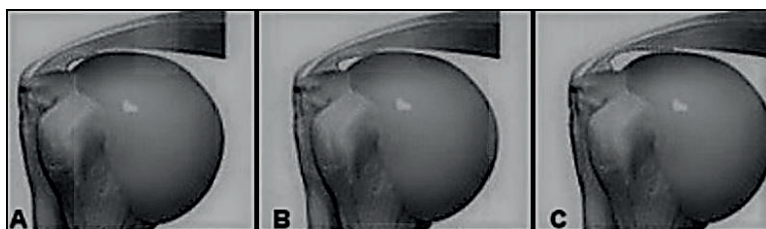
The majority of rotator cuff tears affected supraspinatus and infraspinatus tendons; these are described as postero-superior cuff tears. On the contrary, antero-superior tears are less common and typically extend anteriorly involving rotator interval or subscapularis tendon. Partial tears consist of a partial disruption of tendon fibers without communication among bursal and articular spaces.

The average normal thickness of rotator cuff tendons is between 8 and 12 mm. The depth of tear defines the degree of lesion. Codman classified tendon tears in three types [61]:

1. bursal-side tear (BT) confined to the bursal surface of the tendon;
2. intratendinous tear (IT), which is localized within tendon thickness and
3. joint-side tear (JT) located on the joint side of the tendon.

Another classification proposed by Neer [62] divided the condition of pain, inflammation, oedema and hemorrhage as stage I, tendinous fibrosis as stage II and fibers rupture as stage III.

Taking into account the average thickness of supraspinatus tendon, Ellman [70] classified rotator cuff tears (**Figure 4**): grade I consists of a tear depth lower than 3 mm (or involving less than 25% of tendon thickness); grade II characterized by a depth between 3 and 6 mm



**Figure 4.** Ellman classification of rotator cuff tears. A: grade I; B: grade II; C: grade III.

or 50% of thickness; grade III involves more than 6 mm or more than 50% of thickness. In full-thickness tears a complete fibers disruption brings to a direct communication between subacromial and glenohumeral spaces.

Further classifications of rotator cuff tears [4] are shown in **Tables 1–3**.

The greater the size of the lesion, the extent of retraction and the quantity of fatty muscle atrophy, the less the chance of healing from rotator cuff tear. The natural history of the lesion is the further increase in size over time. Therefore, for example, partial thickness tears become total lesions and, referring to Cofield’s classification (**Table 1**), small-sized tears tend to evolve toward massive lesions.

### 3.5. Frozen shoulder

Frozen shoulder, or adhesive capsulitis, is a painful and disabling condition of unknown etiology caused by a spontaneous contracture of the glenohumeral joint in absence of an evident previous event, resulting in reduction of joint motion [71]. This debilitating condition affects from 2 to 5% of the general population [72] and its prevalence increases to 10–38% in patients with comorbidities, such as hypothyroidism [73], diabetes, increased body mass index and cervical spondylosis [74]. This condition is more common in women and in non-dominant shoulders. The mean age of onset is 50–55 years [75].

The currently recognized classification (**Table 4**) identifies as a primary frozen shoulder a condition with any clearly identifiable etiopathogenetic cause, and as secondary a condition triggered by a well-defined cause. The last one, is further subdivided into intrinsic, extrinsic and systemic [76].

Neviaser describe this state as *adhesive capsulitis* to emphasize the inflammatory component affecting the capsule, multiregional areas of synovitis and synovial angiogenesis [77].

Small	<1 cm
Medium	1–3 cm
Large	3–5 cm
Massive	>5 cm

**Table 1.** Cofield classification (by tear size).

Stage 1	Proximal stump lies close to its bony insertion
Stage 2	Proximal stump retracted at level of humeral head
Stage 3	Proximal stump retracted at glenoid level

**Table 2.** Patte classification (by cuff tears retraction).

Stage	Muscle description
0	Completely normal muscle
I	Some fatty streaks
II	Amount of muscle is greater than fatty infiltration
III	Amount of muscle is equal to fatty infiltration
IV	Amount of fatty infiltration is greater than muscle

**Table 3.** Goutallier classification: by extent of fatty muscle degeneration.

Primary adhesive capsulitis	Secondary adhesive capsulitis		
Idiopathic (of unknown etiology or condition)	Systematic	Extrinsic	Intrinsic
	<ul style="list-style-type: none"> <li>• Thyroid disease</li> <li>• Hyperlipidemia</li> <li>• Hypoadrenalism</li> <li>• Chronic obstructive pulmonary disease (COPD)</li> <li>• Osteopenia/reduced bone mineral density</li> <li>• Duputreyn's disease</li> <li>• Ischemic heart conditions</li> <li>• Diabetes mellitus</li> </ul>	<ul style="list-style-type: none"> <li>• Cardiac or breast surgery</li> <li>• Cerebrovascular accident</li> <li>• Cervical radiculopathy</li> </ul>	<ul style="list-style-type: none"> <li>• Impingement</li> <li>• Tendinopathy</li> <li>• Osteoarthritis</li> <li>• Dislocation or shoulder trauma</li> </ul>

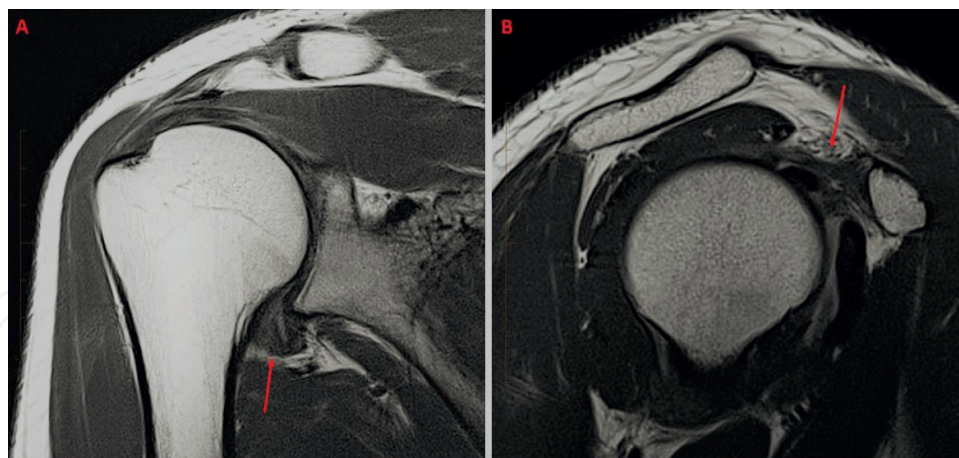
**Table 4.** Frozen shoulder classification.

Histological findings attribute to neoangiogenesis the growth of new nerves in the capsuloligamentous complex of these patients and this may be the explanation of the pain associated with capsulitis.

Immunocytochemical analysis on arthroscopy biopsy material revealed the presence of chronic inflammatory cells predominantly made up of mast cells, T cells, B cells and macrophages, as well as the presence of fibrosis that results from mast cell infiltrate, which typically regulate the proliferation of fibroblasts [78].

Frozen shoulder seems to be the result of failure of the healing process after an initial inflammatory phase, characterized by an excess of cytokines and growth factors with fibroblasts





**Figure 5.** Frozen shoulder at MRI. Coronal PD (A): thickening of the axillary recess of the glenohumeral joint; sagittal PD (B): inflammation in the rotator cuff interval.

accumulation that in part differentiate into myofibroblasts. They exert tractions on new collagen deposits with stiffening of the capsule [79].

The diagnosis is essentially clinical, based on the evidence of the reduction of the ROM (range of motion) in particular in extrarotation, elevation and intrarotation of the glenohumeral joint, in the absence of X-ray lesions. This is accompanied by pain at the insertion of the deltoid and muscular weakness [80]. Radiographic images are not helpful, unless in the case of associated pathologies, such as fractures, arthritis and metallic implants. In selected cases, with suspected association with rotator cuff tendinopathy or impingement syndrome, we can refer to magnetic resonance imaging (**Figure 5**) [81].

According to Neviasser et al. [80], the clinical presentation is indicative of the stage of the adhesive capsulitis:

Stage 1, preadventive stage: patients have mild pain at the end of the range of motion and this condition is often mistakenly diagnosed as impingement syndrome.

Stage 2, “freezing” stage: is often characterized by a high level of discomfort and a high level of pain and a progressive loss of ROM.

Stage 3, “frozen” stage: is characterized by significant stiffness, but less pain.

Stage 4, “thawing” stage: in this phase we have painless stiffness and motion that typically improves by remodeling.

#### 4. Clinical presentation

The diagnosis is based essentially on clinical examination, exclusion of other pathologies and normal glenohumeral radiographs. Initial evaluation of global postural assessment should be performed before focusing on the shoulder, because shoulder pain is often associated with thoracic

and cervical spine alignment that alters the scapula's rest position [82]. Postural abnormalities related to shoulder pain, include extension of the atlanto-occipital joints, reduction of physiological cervical lordosis, increase of dorsal kyphosis, protrusion (abduction) of the scapula with rotation downward and internal rotation of the humerus. All these results in neuromusculoskeletal changes.

A thorough collection of the patient's medical history is used to detect if pain origins really from shoulder whether it is a referred pain from other anatomical structures. It is frequently reported that the pain in the shoulder is actually coming from the cervical spine, in which case the irradiation along the upper limb pain, radicular pathology reaches generally until the hand and the fingers, while the pain that starts from the shoulder radiates up and not past the elbow.

The shoulder physical examination can be expressed in the following steps: inspection, palpation, mobility and specific functional tests. The inspection is usually negative, while palpation may aid in the diagnosis. Palpation should include all the articulation of the scapular girdle and all the rotator cuff muscles trying to overcome with appropriate manoeuvres the deltoid that covers a large part of the rotator cuff. During the palpation, must be taken simultaneously consider several aspects. They are: the tenderness, the swelling, changes in temperature, the deformity, both obvious and hidden, the muscle characteristics and the relations between the various structures. The motion of both shoulders should be assessed actively and passively. Forward elevation and elevation in the scapular plane as well as internal and external rotation with the arm at the side and in 90° of abduction should be performed.

Tests of affected muscles against resistance are imperative to formulate a correct diagnosis.

**Neer test:** the doctor is placed behind the patient, with one hand passively he raises his arm in internal rotation and abduction, while with the other stabilizes the scapula. If the patient refers pain in an arc of movement between 70° and 120°, the test shows a conflict between the greater tuberosity and the humeral the acromion.

**Hawkins test:** it is performed with arm at 90° of flexion front and elbow flexed to 90°; in this position the physician, in front of the patient and imprints an internal rotational movement of the glenohumeral joint. Pain located below the acromioclavicular joint with internal rotation is considered a positive test result and it is indicative of inflammation of the subacromial bursa or of an impingement of all structures that are located between the greater tubercle of the humerus and the coracohumeral ligament.

**Palm-up test:** the examiner contrasts the movement of the patient to elevate the arm with the elbow in extension and palm of the hand facing up. If the test shows pain is positive to a lesion of the long head of the humeral biceps.

**Jobe test:** the examiner stands in front of the patient keeps his arms positioned at 90° of abduction, 30° of anterior flexion and maximum intra-rotation (thumbs pointing to the ground). The examiner lowers arms against the patient's resistance against exerting a downward thrust. The test is positive for the supraspinatus muscle if the affected limb is lowered, regardless of whether or not the presence of pain.

Other tests can be used, such as Yocum test, the horizontal adduction test, the painful arc sign, the empty can test, the drop arm test, the Speed test, the Yergason test and the Pattes test.

Clinical evaluation can be completed with assessment scales like Constant-Murley scale [83, 84] or simple shoulder test (SST).

The Constant-Murley score is an ordinal scale used in all pathologies of shoulder (not only for the instability), with a score ranging from 0 to 100 (100 = normal shoulder). The scale investigates four areas through the pain (15 points), activities of daily living (20 points), strength (25 points) and the range of motion (40 points). In this way it achieved a full assessment of the level of pain and disability related to the activities of daily living.

The “simple shoulder test” (SST) is a binary scale used for all shoulder pathologies that involves the administration of 12 questions to the patient (normal score = 12). The questions are used to assess the perceived pain and the ability to perform certain activities of daily living. The DASH is halfway between a generic test (as the Short Form) and a specific test for the shoulder, it can be used to complete the assessment.

Imaging studies are commonly used to identify and differentiate the source of the injury.

## 5. Conservative approach

The conservative approach avails of different kind of treatments, whose main purpose is to reduce pain and other signs of inflammation, recover function and prevent further joint damage [85].

A great number of studies support the conservative approach as the main treatment for the mildest forms of shoulder pain due to adhesive capsulitis [86]. The natural course of the frozen shoulder leads to healing in more or less long times. To reduce pain faster and recover the articular functionality, we can intervene with several alone or combined therapies, such as physical therapy (ultrasound, lasers, hyperthermia, electro-analgesia and shock waves), intra-articular corticosteroid injection, intra-articular saline hydrodilatation with distention and eventual rupture of the glenohumeral joint capsule, intra-articular sodium hyaluronate injection into the glenohumeral joint, suprascapular nerve block, shoulder manipulation under anesthesia, oral corticosteroid or NSAIDs (non-steroidal anti-inflammatory drugs) and analgesics. In case of failure of these therapies, the alternative is to proceed with open or arthroscopic synovectomy and glenohumeral capsular releases [87–89].

### 5.1. Extracorporeal shock wave therapy

Since 1980, the extracorporeal impact waves have been used in different conditions, initially to destroy kidney stones. Investigating the side effects on the surrounding tissues, it was understood that they could also find use in the treatment of musculoskeletal disorders [90]. The effect on these tissues is dose-dependent: high doses tend to have destructive effects, low doses have regenerative effects [91].

All the principles that led the application of the ESWT since 1995 have been revised in a recent review, that has established new ones. The recommended energy limit should be beneath 0.28 mJ/mmq, above which necrotic effects prevail; ESWT is performed without anesthesia, even on larger areas; their application also on open growth plates seems to be safe [92].

The regenerative effect of ESWT is the consequence of the activation of gene expression for growth factors or cytokines and fibroblast proliferation. Mechanical stimulation is converted by tendon tissue in enhancement of TGF- $\beta$ 1 gene expression and increase of collagen I and collagen III [93].

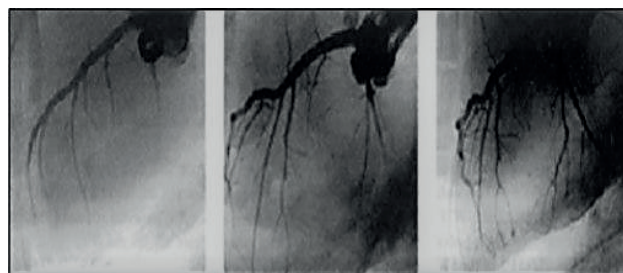
The phenomenon of mechanosensing is particularly clear in bone tissue, due to its structure and physiology: it acts like a piezoelectric. After ESWT exposure, bone shows: osteogenic differentiation of mesenchymal stem cells [94]; expression of nitric oxide synthase (eNOS), vascular endothelial growth factor (VEGF) that lead to neoangiogenesis and accelerate tissue regeneration and healing [95]; bone regeneration, starting from periosteum stimulation [96]; direct stimulation of osteoblasts and indirect reduction of osteoclasts activity [97].

In addition, the increase in NOS appears to be involved in another signaling pathway leading to the reduction of pro-inflammatory factors. It has been seen that NOS exerts an inhibitory action on nuclear factor kappa-light-chain-enhancer of activated B cells (NF- $\kappa$ B), hence the role in production of proinflammatory cytokine and leukocytes recruitment, generating pain and phlogosis, are blocked [98].

Other mechanism is the production of NO and VEGF resulting in neoangiogenesis (**Figure 6**) that improves blood supply promoting tissue repairing and wash-out of algogenic and noxious substances [99].

ESWT intervene in pain modulation also by release of endogenous analgesic substances P and calcitonine gene-related peptide (CGRP) and according to the gate control [100]. About the gate control, Saggini et al. [101], claim that a hyperstimulation-like shock waves, activate the descending inhibitory system, blocking following nociceptive stimuli in the posterior column of the spinal cord. In addition, ESWT modify substances P and CGRP levels, damaging peripheral small unmyelinated fibers, responsible of immediate release of the algogenic peptide. All these mechanisms make ESWT suitable to treat various musculoskeletal disorders, such as calcific tendonitis, epicondylitis, osteoarthritis and long bone fracture [102].

ESWT has proved to be a valid option in the treatment of calcifying tendinitis of the shoulder. A study based on a meta-analysis showed the power of ESWT to intervene in case of calcific



**Figure 6.** Coronary neovascularization after 4 weeks of shock wave therapy.



tendinitis, promoting resorption of the calcifications using high energy density (conventional limit set at 0.20 mJ/mm<sup>2</sup>, less than this intensity was labeled low-energy). Functional outcome (Constant-Murley score) and radiographic resorption (chance of complete resorption) of the deposits after 3 months, showed that high-energy ESWT is more effective than low-energy ESWT [103]. The effect on calcifications is not merely mechanical as in the case of kidney stones, but rather biochemical induces interstitial and extracellular changes, enhancing tissue regeneration [104].

Few studies specifically address the application of ESWT in frozen shoulder. One of the study [105], recruited 36 patients divided into 2 groups: one received shock waves (1200 shocks with energy between 0.1 and 0.3 mJ/mm<sup>2</sup>) and one sham. Pain and disability score were assessed with the Shoulder Pain and Disability Index (SPADI) questionnaire before and after the therapy, and 2 and 5 months after the treatment. The results show a positive effect on recovery of frozen shoulder that was faster than sham group.

Another research [106] compare ESWT (1000 shock waves, with energy between 0.01 and 0.16 mJ/mm<sup>2</sup>) with conservative physical therapy, both group treated twice a week for six weeks. Pain and function were assessed, respectively, with visual analogue scale (VAS) and patient-specific functional scales (PSFS). Both group showed significant decreases in VAS and PSFS, the ESWT group reported lower score then the control group.

ESWT is therefore a possible way to treat the frozen shoulder, especially if we consider the fact that it is a safe, non-invasive and low cost procedure.

## 5.2. Intra-articular injections

Intra-articular drug administration offers several advantages: increased bioavailability, reduced systemic effects and fewer side effects. Moreover, most joints can be accessed accurately, especially under ultrasound guidance [107].

Intra-articular injections into the glenohumeral joint are commonly performed to treat different conditions affecting this articulation, such as osteoarthritis, adhesive capsulitis and rheumatoid arthritis. Despite the widespread use of this treatment, there are no standard criteria for their performance [26].

With regard to this type of therapy applied to the treatment of shoulder pain, two substances are used: corticosteroids and hyaluronic acid [108]. The pharmacological properties of corticosteroids are well known, in accordance with them, this procedure is recommended in the acute phase. The risks associated with corticosteroid injection are limited if performed by experienced hands and in patients eligible for such procedure. Injection should be avoided in patients with septic arthritis, bacteremia and in immunocompromised patients [109].

The main purpose in treating the frozen shoulder is to reduce the loss of function and to give relief to pain that significantly limits movement. In the case of adhesive capsulitis, intra-articular administration of corticosteroids is generally associated with conventional physical therapy. A systematic review of 25 studies from 1947 to present, compares infiltrations with manipulation under anesthesia, physical therapy and distension of the joint capsule. In all



cases it is clear that intra-articular administration of corticosteroids improves and accelerates patients' healing. Long-term results about conventional therapies versus corticosteroids are comparable; due to understandable considering that adhesive capsulitis is a self-limiting pathology [110].

Another possible application of corticosteroids involves infiltration within the subacromial bursa; this method (**Figure 7**) is particularly useful in those cases of acute painful bursitis, in combination with other therapies aimed at treating the underlying cause.

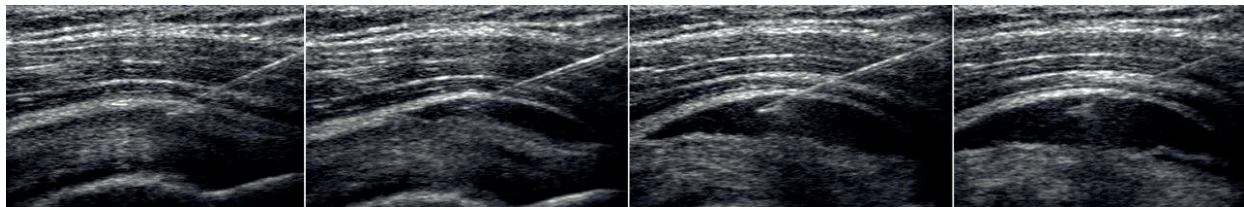
Besides the corticosteroids, whose action and effectiveness are widely dealt in literature, the use of the viscosupplementation with hyaluronic acid is becoming increasingly widespread [111]. Hyaluronic acid acts through different mechanisms when injected into the joint. It is an anionic, nonsulfated glycosaminoglycan distributed widely throughout connective, epithelial and neural tissues, is capable of retaining water and this contributes to cell adhesion, proliferation and migration. High local concentrations cause the release of growth factors, accelerating the tissue repair process [112]. The viscosupplementation is a way to restore rheological properties of the synovial fluid, enhancing viscoelastic properties of synovial fluid protecting cartilage from mechanical stress and reducing pain [113, 114].

In the tendinitis involving the rotator cuff, viscosupplementation, not only protects the joint surface, but also restores the homeostasis of the chondrocytes [115]. The hypothesis that hyaluronic acid also acts on pain modulation has been investigated and Mitsui et al. [116] demonstrate that hyaluronic acid inhibits not only expression of mRNA for proinflammatory cytokines, such as IL-1b, IL-6 and TNF-a, but also COX-2/PGE2 (Prostaglandin E2) production via CD44 in IL-1-stimulated subacromial-synovium fibroblasts. CD44 is also present on synoviocytes, so it is a target for pain reduction. The restoration of the viscoelastic barrier around the nociceptive afferent fibers, reduces pain, hindering interaction with nociceptive stimuli [117].

### 5.3. Rehabilitation

The rehabilitation program should always start from clinical evaluation, focusing on the status of functional deficiency, the range of motion and the pain elicited during evaluation [118]. The aim is to ensure long-term results in joint mobility, to reduce stiffness and improve function [119].

Maintaining the range of movements is essential to prevent adhesion and decrease impingement. To intervene on the strength of the rotator cuff muscles and on the scapula stabilizing muscles (anterior serratus, rhomboids, latissimus dorsi and trapezium) and the deltoid,



**Figure 7.** Sequence of subacromial bursa infiltration.


avoids the superior migration of the humeral head and the scapular instability, two conditions that occur in the impingement syndrome.

A deficit in neuromuscular control may cause abnormalities in the rotator cuff and scapulothoracic muscles. It has been postulated that proprioception can modulate the sensitivity of muscle spindles and help subjects to pay more attention to joint position [120].

Exercises that specifically generate higher level of activation of the rotator cuff, lower trapezius or serratus anterior, are open-chain exercises included full can, side lying external rotation, diagonal exercise and prone full can at 100° of abduction [121]. While the closed-chain exercises facilitate the co-contraction of shoulder muscles as well as strengthen the serratus anterior [122].

The brain guides motion tasks by interacting with external signals and proprioceptive stimuli. Therefore, stimuli integration takes place here and the center that generates an answer to them can be re-edited.

A possible way to reach this aim is the Multi-Joint System® (MJS), a system consisting of a multi-articulated arm run by the patient on the three planes of space (**Figure 8**). The patient receives feedback from a computer system connected to the robot arm and adjusts his movements, following predefined trajectories. In this way, the patient learns to perform all the



**Figure 8.** Multi-Joint System®.

peculiar movements of the glenohumeral joint, maintaining a proper position of the scapula and increasing the strength of the anterior serratus, rhomboid, latissimus dorsi, trapezius and deltoid. MJS grant a better control of shoulder movements with increased proprioception, sensitivity and shoulder joint motion in a multi-dimensional axial-type range [123, 124].

## Author details

Raoul Saggini<sup>1\*</sup>, Simona Maria Carmignano<sup>2</sup>, Lucia Cosenza<sup>2</sup>, Tommaso Palermo<sup>2</sup> and Rosa Grazia Bellomo<sup>3</sup>

\*Address all correspondence to: [saggini@unich.it](mailto:saggini@unich.it)

1 Department of Medical Oral and Biotechnological Sciences, School of Specialty in Physical and Rehabilitation Medicine, "Gabriele d'Annunzio" University, Chieti, Italy

2 School of Specialty in Physical and Rehabilitation Medicine, "Gabriele d'Annunzio" University, Chieti, Italy

3 Physical and Rehabilitation Medicine, Department of Medical Oral and Biotechnological Sciences, "Gabriele d'Annunzio" University, Chieti, Italy

## References

- [1] Clement ND, Nie YX, McBirnie JM. Management of degenerative rotator cuff tears: A review and treatment strategy. *Sports Medicine, Arthroscopy, Rehabilitation, Therapy & Technology*. 2012;4:48
- [2] Sher JS, Uribe JW, Posada A, Murphy BJ, Zlatkin MB. Abnormal findings on magnetic resonance images of asymptomatic shoulders. *Journal of Bone and Joint Surgery (American)*. 1995;77:10-15
- [3] Tempelhof S, Rupp S, Seil R. Age-related prevalence of rotator cuff tears in asymptomatic shoulders. *Journal of Shoulder and Elbow Surgery*. 1999;8:296-299
- [4] Berhart LV, editor. *Advances in Medicine and Biology*. New York: Nova Science Publisher Inc; 2016. 129-178 p
- [5] Bassett RW, Browne AO, Morrey BF, An KN. Glenohumeral muscle force and moment mechanics in a position of shoulder instability. *Journal of Biomechanics*. 1990;23:405-415
- [6] Karduna AR, Williams GR, Williams JL, Iannotti JP. Kinematics of the glenohumeral joint: Influences of muscle forces, ligamentous constraints and articular geometry. *Journal of Orthopaedic Research*. 1996;14:986-993
- [7] Lippitt S, Matsen F. Mechanisms of glenohumeral joint stability. *Clinical Orthopaedics and Related Research*. 1993;291:20-28

- [8] Soslowky LJ, Carpenter JE, Bucchieri JS, Flatow EL. Biomechanics of the rotator cuff. *Orthopedic Clinics of North America*. 1997;**28**:17-30
- [9] Wuelker N, Roetman B, Plitz W, Knop C. Function of the supraspinatus muscle in a dynamic shoulder model. *Unfallchirurg*. 1994;**97**:308-313
- [10] Sharkey NA, Marder RA, Hanson PB. The entire rotator cuff contributes to elevation of the arm. *Journal of Orthopaedic Research*. 1994;**12**:699-708
- [11] Howell SM, Galinat BJ, Renzi AJ, et al. Normal and abnormal mechanics of the glenohumeral joint in the horizontal plane. *Journal of Bone and Joint Surgery (American)*. 1988;**70**:227-232
- [12] Kelkar R, Wang VM, Flatow EL, et al. Glenohumeral mechanics: A study of articular geometry, contact and kinematics. *Journal of Shoulder and Elbow Surgery*. 2001;**10**:73-84
- [13] Poppen NK, Walker PS. Normal and abnormal motion of the shoulder. *Journal of Bone and Joint Surgery (American)*. 1976;**58**:195-201
- [14] Howell SM, Kraft TA. The role of the supraspinatus and infraspinatus muscles in glenohumeral kinematics of anterior shoulder instability. *Clinical Orthopaedics and Related Research*. 1991;**263**:128-134
- [15] Lippett S, Vanderhoof J, Harris SL, et al. Glenohumeral stability from concavity-compression: A quantitative analysis. *Journal of Shoulder and Elbow Surgery*. 1993;**2**:27-34
- [16] Neviasser RJ, Neviasser TJ, Neviasser JS. Anterior dislocation of the shoulder and rotator cuff rupture. *Clinical Orthopaedics and Related Research*. 1993;**291**:103-106
- [17] Apreleva M, Parsons IM, Pfaeffe J, et al. 3-D joint reaction forces at the glenohumeral joint during active motion. *Advanced Bioengineering*. 1998;**39**:33-34
- [18] Parsons IM, Apreleva M, Fu FH, et al. The effect of rotator cuff tears on reaction forces at the glenohumeral joint. *Journal of Orthopaedic Research*. 2002;**20**:439-446
- [19] Blaiser RB, Guldberg MS, Rothman ED. Anterior shoulder stability: Contributions of rotator cuff forces and the capsular ligaments in a cadaver model. *Journal of Shoulder and Elbow Surgery*. 1992;**1**:140-150
- [20] Itoi E, Newman SR, Kuechle DK, et al. Dynamic anterior stabilizers of the shoulder with the arm in abduction. *Journal of Bone and Joint Surgery (British)*. 1994;**76**:834-836
- [21] Lee SB, Kim KJ, O'Driscoll SW, et al. Dynamic glenohumeral stability provided by the rotator cuff muscles in the mid-range and end-range of motion: A study in cadavera. *Journal of Bone & Joint Surgery*. 2000;**82**:849-857
- [22] Harryman DT 2nd, Sidles JA, Clark JM, McQuade KJ, Gibb TD, Matsen FA 3rd. Translation of the humeral head on the glenoid with passive glenohumeral motion. *Journal of Bone and Joint Surgery (American)*. 1990;**72**:1334-1343
- [23] Rowlands LK, Wertsch JJ, Primack SJ, Spreitzer AM, Roberts MM. Kinesiology of the empty can test. *American Journal of Physical Medicine & Rehabilitation*. 1995;**74**:302-304



- [24] Sigholm G, Styf J, Korner L, Herberts P. Pressure recording in the subacromial bursa. *Journal of Orthopaedic Research*. 1988;**74**:302-304
- [25] Okuda Y, Gorski JP, An KN, Amadio PC. Biochemical, histological, and biomechanical analyses of canine tendon. *Journal of Orthopaedic Research*. 1987;**5**:60-68
- [26] Maffulli N, editor. *Rotator Cuff Tear*. Basel: Karger; 2012. 10-17, 27-29, 41-45, 90-93 p
- [27] McClure P, Michener LA, Karduna AR. Shoulder function and three-dimensional scapular kinematics in people with and without shoulder impingement syndrome. *Physical Therapy*. 2006;**86**:1075-1090
- [28] Maffulli N, Longo UG, Gougoulias N, Loppini M, Denaro V. Long-term health outcomes of youth sports injuries. *British Journal of Sports Medicine*. 2010;**44**:21-25
- [29] Gill TJ, McIrvine E, Kocher MS, Homa K, Mair SD, Hawkins R. The relative importance of acromial morphology and age with respect to rotator cuff pathology. *Journal of Shoulder and Elbow Surgery*. 2002;**11**:327-330
- [30] Bigliani LU, Morrison DS, April EW. The morphology of the acromion and its relationship to rotator cuff tears. *The Journal of Orthopaedic Translation*. 1986;**10**:228
- [31] Keener JD, Wei AS, Kim HM, Steger-May K, Yamaguchi K. Proximal humeral migration in shoulders with symptomatic and asymptomatic rotator cuff tears. *Journal of Bone and Joint Surgery (American)*. 2009;**91**:1405-1413
- [32] Ludewig PM, Cook TM. Alterations in shoulder kinematics and associated muscle activity in people with symptoms of shoulder impingement. *Physical Therapy*. 2000;**80**:276-291
- [33] Blaine TA, Cote MA, Proto A. Interleukin-1 $\beta$  stimulates stromal-derived factor-1 $\alpha$  expression in human subacromial bursa. *Journal of Orthopaedic Research*. 2011;**29**:1695-1699
- [34] Gotoh M, Hamada K, Yamakawa H. Interleukin-1-induced subacromial synovitis and shoulder pain in rotator cuff diseases. *Rheumatology (Oxford)*. 2001;**40**(9):995-1001
- [35] Chandler TJ. Shoulder strength, power, and endurance in college tennis players. *The American Journal of Sports Medicine*. 1992, July;**20**:455-458
- [36] Solem-Bertoft E, Thuomas KA, Westerberg CE. The influence of scapular retraction and protraction on the width of the subacromial space: An MRI study. *Clinical Orthopaedics and Related Research*. 1993;**296**:99-103
- [37] Biberthaler P, et al. Microcirculation associated with degenerative rotator cuff lesions. In vivo assessment with orthogonal polarization spectral imaging during arthroscopy of the shoulder. *Journal of Bone and Joint Surgery (American)*. 2003;**85**-A:475-480
- [38] Goodmurphy CW, Osborn J, Akesson EJ, Johnson S, Stanescu V, Regan, WD. Immunocytochemical analysis of torn rotator cuff tendon taken at the time of repair. *Journal of Shoulder and Elbow Surgery*. 2003;**12**:368-374



- [39] Rudzki JR, et al. Contrast-enhanced ultrasound characterization of the vascularity of the rotator cuff tendon: Age- and activity-related changes in the intact asymptomatic rotator cuff. *Journal of Shoulder and Elbow Surgery*. 2008;**17**:96S-100S
- [40] Huang CY, Wang VM, Pawluk RJ, Bucchieri JS, Levine WN, Bigliani LUJ. Inhomogeneous mechanical behavior of the human supraspinatus tendon under uniaxial loading. *Journal of Orthopaedic Research*. 2005;**23**:924-930
- [41] Seitz AL, McClure PW, Finucane S, Boardman ND, Michener LA. Mechanisms of rotator cuff tendinopathy: Intrinsic, extrinsic, or both? *Clinical Biomechanics*. 2011;**26**:1-12
- [42] Cole AS, Cordiner-Lawrie S, Carr AJ, Athanasou NA. Localised deposition of amyloid in tears of the rotator cuff. *The Journal of Bone and Joint Surgery*. 2001;**83**(4):561-564
- [43] Harvie P, Ostlere SJ, Teh J, McNally EG, Clipsham K, Burston BJ. Genetic influences in the aetiology of tears of the rotator cuff. Sibling risk of a fullthickness tear. *Journal of Bone and Joint Surgery (British)*. 2004;**86**:696-700
- [44] Mokone GG, Gajjar M, September AV, Schweltnus MP, Greenberg J, Noakes TD. The guanine-thymine dinucleotide repeat polymorphism within the tenascin-C gene is associated with achilles tendon injuries. *The American Journal of Sports Medicine*. 2005;**33**:1016-1021
- [45] September AV, Schweltnus MP, Collins M. Tendon and ligament injuries: The genetic component. *British Journal of Sports Medicine*. 2007;**41**:241-246
- [46] Rees JD, Maffulli N, Cook J. Management of tendinopathy. *The American Journal of Sports Medicine*. 2009;**37**(9):1855-1867
- [47] Bank RA, TeKoppele JM, Oostingh G, Hazleman BL, Riley GP. Lysylhydroxylation and non-reducible crosslinking of human supraspinatus tendon collagen: Changes with age and in chronic rotator cuff tendinitis. *Annals of the Rheumatic Diseases*. 1999;**58**:35-41
- [48] Celli L, editor. *The Shoulder: Periarticular Degenerative Pathology*. Vol. 1. Springer, Austria; 1990
- [49] Maffulli N, Wong J, Almekinders LC. Types and epidemiology of tendinopathy. *Clinics in Sports Medicine*. 2003;**22**:675-692
- [50] Millar NL, Wei AQ, Molloy TJ, Bonar F, Murrell GA. Cytokines and apoptosis in supraspinatus tendinopathy. *Journal of Bone and Joint Surgery (British)*. 2009, Mar;**91**(3):417-424
- [51] Harwood FL, Goomer RS, Gelberman RH, Silva MJ, Amiel D. Regulation of alpha(v) beta3 and alpha5beta1 integrin receptors by basic fibroblast growth factor and platelet-derived growth factor-BB in intrasynovial flexor tendon cells. *Wound Repair and Regeneration*. 1999;**7**:381-388
- [52] Speed CA, Hazleman BL. Calcific tendinitis of the shoulder. *The New England Journal of Medicine*. 1999;**340**(20):1582-1584
- [53] Maugars Y, Varin S, Gouin F, et al. Treatment of shoulder calcifications of the cuff: A controlled study. *Joint, Bone, Spine*. 2009;**76**(4):369-377

- [54] Millar NL, Hueber AJ, Reilly JH, et al. Inflammation is present in early human tendinopathy. *The American Journal of Sports Medicine*. 2010;**38**(10):2085-2091
- [55] Uthoff HK, Loehr JW. Calcific tendinopathy of the rotator cuff: Pathogenesis, diagnosis, and management. *The Journal of the American Academy of Orthopaedic Surgeons*. 1997;**5**:183-191
- [56] Rowe CR. Calcific tendinitis. *Instructional Course Lectures*. 1985;**34**:196-198
- [57] Gartner J. Tendinosis calcarea—Behandlungsergebnisse mit dem Needling. *Zeitschrift für Orthopädie und Ihre Grenzgebiete*. 1993;**131**(5):461-469
- [58] Clavert P, Sirveaux F. Les tendinopathies calcifiantes de l'épaule. *Revue de Chirurgie Orthopédique et Traumatologique*. 2008;**94**(8s):336-355
- [59] Serafini G, Sconfienza LM, Lacelli F, Silvestri E, Aliprandi A, Sardanelli F. Rotator cuff calcific tendonitis: Short-term and 10-year outcomes after two-needle US-guided percutaneous treatment-nonrandomized controlled trial. *Radiology*. 2009;**252**(1):157-164
- [60] Ogon P, Suedkamp NP, Jaeger M, Izadpanah K, Koestler W, Maier D. Prognostic factors in nonoperative therapy for chronic symptomatic calcific tendinitis of the shoulder. *Arthritis & Rheumatology*. 2009;**60**(10):2978-2984
- [61] Codman EA, editor. *The Shoulder*. Boston: Thomas Todd; 1934. 123-215 p
- [62] Neer CS. Anterior acromioplasty for the chronic impingement syndrome in the shoulder. *Journal of Bone and Joint Surgery (American)*. 1972;**87**:1399
- [63] Santavirta S, Konttinen Y, Antti-Poika I, Nordström D. Inflammation of the subacromial bursa in chronic shoulder pain. *Archives of Orthopaedic and Traumatic Surgery*. 1992;**111**:336-340
- [64] Yanagisawa K, Hamada K, Gotoh MT. Vascular endothelial growth factor (VEGF) expression in the subacromial bursa is increased in patients with impingement syndrome. *Journal of Orthopaedic Research*. 2001;**19**:448-455
- [65] Gotoh M, Hamada K, Yamakawa H, Inoue A, Fukuda H. Increased substance P in subacromial bursa and shoulder pain in rotator cuff diseases. *Journal of Orthopaedic Research*. 1998;**16**(5):618-621
- [66] Neer CS. Impingement lesions. *Clinical Orthopaedics and Related Research*. 1983;**173**:70-77
- [67] Yamamoto A, Takagishi K, Osawa T, Yanagawa T, Nakajima D, Shitara H. Prevalence and risk factors of a rotator cuff tear in the general population. *Journal of Shoulder and Elbow Surgery*. 2010;**19**:116-120
- [68] Reilly P. Dead man and radiologists don't lie: A review of cadaveric and radiological studies of rotator cuff tear prevalence. *Annals of the Royal College of Surgeons of England*. 2006;**88**:116-121

- [69] Ciccotti MA, Ciccotti MC, Ciccotti MG. Rotator cuff injury. *Current Sports Medicine Reports*. 2009;**8**:52-58
- [70] Ellman H. Diagnosis and treatment of incomplete rotator cuff tears. *Clinical Orthopaedics and Related Research*. 1990;(254):64-74
- [71] Cadogan A, Mohammed KD. Shoulder pain in primary care: Frozen shoulder. *Journal of Primary Health Care*. 2016;**8**(1):44-51
- [72] Neviasser AS, Hannafin JA. Adhesive capsulitis: A review of current treatment. *The American Journal of Sports Medicine*. 2010;**38**:2346-2356
- [73] Schiefer M, Teixeira PF, Fontenelle C. Prevalence of hypothyroidism in patients with frozen shoulder. *Journal of Shoulder and Elbow Surgery*. 2017;**26**(1):49-55
- [74] Li W, Lu N, Xu H, Wang H. Case control study of risk factors for frozen shoulder in China. *International Journal of Rheumatic Diseases*. 2015, Jun;**18**(5):508-513. DOI: 10.1111/1756-185X
- [75] ISAKOS Upper Extremity Committee Consensus Statement. *Shoulder Stiffness*. Berlin: Springer-Verlag. 2014
- [76] Zuckerman JD, Rokito A. Frozen shoulder: A consensus definition. *Journal of Shoulder and Elbow Surgery*, Elsevier. 2011;**20**(2):322-325
- [77] Neviasser JS. Adhesive capsulitis and the stiff and painful shoulder. *Orthopedic Clinics of North America*. 1980;**11**:327-331
- [78] Hand GC, Athanasou NA, Matthews T, Carr AJ. The pathology of frozen shoulder. *Journal of Bone and Joint Surgery (British)*. 2007;**89**:928-932
- [79] Bunker TD, Reilly J, Baird KS, Hamblen DL. Expression of growth factors, cytokines and matrix metalloproteinases in frozen shoulder. *Journal of Bone and Joint Surgery (British)*. 2000;**82**:768-773
- [80] Neviasser RJ, Neviasser TJ. The frozen shoulder: Diagnosis and management. *Clinical Orthopaedics*. 1987;**223**:59-64
- [81] Warner JJP. Frozen shoulder: Diagnosis and management. *Journal of the American Academy of Orthopaedic Surgeons*. 1997;**5**(3):130-140
- [82] Griegel-Morris P, Larson K, Mueller-Klaus K. Incidence of common postural abnormalities in the cervical, shoulder, and thoracic regions and their association with pain in two age groups of healthy subjects. *Physical Therapy*. 1992;**72**(6):425-431
- [83] Urvoy P, Boileau G, Berger M, et al. Confrontation e validation de plusieurs methods d'évaluation des resultants après chirurgie de la coiffe des rotateurs. *Revue de Chirurgie Orthopedique*. 1991;**77**:171-178
- [84] Beaton D, Richards RR. Assessing the reliability and responsiveness of five shoulder questionnaires. *Journal of Shoulder and Elbow Surgery*. 1998;**7**:565-572

- [85] McKee MD, Yoo DJ. The effect of surgery for rotator cuff disease on general health status. *Journal of Bone and Joint Surgery (American)*. 2000;**82**:970-979
- [86] Brox JI, Staff PH, Ljunggren AE, Brevik JI. Arthroscopic surgery compared with supervised exercises in patients with rotator cuff disease (stage II impingement syndrome). *BMJ*. 1993;**307**:899-903
- [87] Cho K, Song J, Lee H, Kim J, Rhee Y. The effect of subacromial bursa injection of hyaluronate in patients with adhesive capsulitis of shoulder joint: Multicenter, prospective study. *Journal of Korean Academy of Rehabilitation Medicine*. 2002;**26**:73-80
- [88] Tamai K, Mashitori H, Ohno W, Hamada J, Sakai H, Saotome K. Synovial response to intraarticular injections of hyaluronate in frozen shoulder: A quantitative assessment with dynamic magnetic resonance imaging. *Journal of Orthopaedic Science*. 2004;**9**:230-234
- [89] Tagliafico A, Serafini G, Sconfienza LM, et al. Ultrasound-guided viscosupplementation of subacromial space in elderly patients with cuff tear arthropathy using a high weight hyaluronic acid: Prospective open-label non-randomized trial. *European Radiology*. 2010;**21**:182-187
- [90] Graff J, Richter KD, Pastor J. Effect of high energy shock waves on bony tissue. *Urological Research*. 1988;**16**:252-258
- [91] Haupt G. Use of extracorporeal shock waves in the treatment of pseudarthrosis, tendinopathy and other orthopedic diseases. *The Journal of Urology*. 1997;**158**(1):4-11. DOI: 10.1097/00005392-199707000-00003
- [92] Lohrer H, Nauck T, Vasileios Korakakis V, Malliaropoulos N. Historical ESWT paradigms are overcome: A narrative review. *BioMed Research International*. 2016;**2016**:7
- [93] Chen YJ, Wang CJ, Yang KD, et al. Extracorporeal shock waves promote healing of collagenase-induced achilles tendinitis and increase TGF-beta1 and IGF-I expression. *Journal of Orthopaedic Research*. 2004;**22**(4):854-861
- [94] Wang FS, Yang KD, Chen RF, Wang CJ, Sheen-Chen SM. Extracorporeal shock wave promotes growth and differentiation of bone-marrow stromal cells towards osteoprogenitors associated with induction of TGF-beta1. *The Journal of Bone and Joint Surgery*. 2002, Apr;**84**(3):457-461
- [95] Wang FS, Wang CJ, Chen YJ, et al. Ras induction of superoxide activates ERK-dependent angiogenic transcription factor HIF-1alpha and VEGF-A expression in shock wave stimulated osteoblasts. *Journal of Biological Chemistry*. 2004;**279**:10331-10337
- [96] Kearney CJ, Hsu HP, Spector M. The use of extracorporeal shock wave stimulated periosteal cells for orthotopic bone generation. *Tissue Engineering*. 2012, Jul;**18**:1500-1508
- [97] Tamma R, dell'Endice S, Notarnicola A, Moretti L. Extracorporeal shock waves stimulate osteoblast activities. *Ultrasound Med Biol*. 2009, Dec;**35**(12):2093-2100

- [98] Wang CJ, Yang KD, Ko JY, Huang CC, Huang HY, Wang FS. The effects of shockwave on bone healing and systemic concentrations of nitric oxide (NO), TGF-b1, VEGF and BMP-2 in long bone non-unions. *Nitric Oxide*. 2009;**20**:298-303
- [99] Frairia R, Berta L. Biological effects of extracorporeal shock waves on fibroblasts. A Review. *Muscle, Ligaments and Tendons Journal*. 2011, Oct-Dec;**1**(4):138-147
- [100] Saggini R, Di Stefano A, Saggini A, Bellomo RG. Clinical application of shock wave therapy in musculoskeletal disorders: Part I. *Journal of Biological Regulators & Homeostatic Agents*. 2015;**29**(3):533-545
- [101] Saggini R, Buoso S, Pestelli G. *Dolore E Riabilitazione*. 1st ed. Minerva Medica, Torino, Italy. 2014
- [102] Schmitz C, Császár N, Milz S. Efficacy and safety of extracorporeal shock wave therapy for orthopedic conditions: A systematic review on studies listed in the PEDro database. *British Medical Bulletin*. 2015;**116**:115-138. DOI: 10.1093/bmb/ldv047
- [103] Mouzopoulos G, Stamatakos M, Mouzopoulos D, Tzurbakis M. Extracorporeal shock wave treatment for shoulder calcific tendonitis: A systematic review. *Skeletal Radiology*. 2007;**36**:803-811. DOI: 10.1007/s00256-007-0297-3
- [104] Notarnicola A, Moretti B. The biological effects of extracorporeal shock wave therapy (ESWT) on tendon tissue. *Muscles, Ligaments and Tendons Journal*. 2012;**2**(1):33-37
- [105] Vahdatpour B, Taheri P, Zade AZ, Moradian S. Efficacy of extracorporeal shock-wave therapy in frozen shoulder. *International Journal of Preventive Medicine*. 2014; **5**(7):875-881
- [106] Park C, Lee S, Yi CW, Lee K. The effects of extracorporeal shock wave therapy on frozen shoulder patients' pain and functions. *Journal of Physical Therapy Science*. 2015;**27**(12):3659-3661. DOI: 10.1589/jpts.27.3659
- [107] Evans CH, Kraus VB, Setton LA. Progress in intra-articular therapy. *Nature Reviews. Rheumatology*. 2014;**10**(1):11-22. DOI: 10.1038/nrrheum.2013.159
- [108] Gross C, Dhawan A, Harwood D. Glenohumeral joint injections. A review. *Sports Health*. 2013, Mar;**5**(2):153-159. DOI: 10.1177/1941738112459706
- [109] Wittich CM, Ficalora RD, Mason TG, Beckman TJ. Musculoskeletal injection. *Mayo Clinic Proceedings*. 2009;**84**(9):831-837
- [110] Song A, Higgins LD, Newman J, Jain NB. Glenohumeral corticosteroid injections in adhesive capsulitis: A systematic search and review. *PM & R : The Journal of Injury, Function, and Rehabilitation*. 2014;**6**(12):1143-1156
- [111] Kim YS, Park JY, Lee CS, Lee SJ. Does hyaluronate injection work in shoulder disease in early stage? A multicenter, randomized, single blind and open comparative clinical study. *Journal of Shoulder and Elbow Surgery*. 2012;**21**:722-727



- [112] Osti L, Berardocco M, di Giacomo V, Di Bernardo G, Oliva F, Berardi AC. Hyaluronic acid increases tendon derived cell viability and collagen type I expression in vitro: Comparative study of four different hyaluronic acid preparations by molecular weight. *BMC Musculoskeletal Disorders*. 2015;**16**:284
- [113] Mathieu P, Conrozier T, Vignon E, Rozand Y, Rinaudo M. Rheologic behavior of osteoarthritic synovial fluid after addition of hyaluronic acid: A pilot study. *Clinical Orthopaedics and Related Research*. 2009;**467**(11):3002-3009. DOI: 10.1007/s11999-009-0867-x
- [114] Speed CA. Fortnightly review: Corticosteroid injections in tendon lesions. *BMJ*. 2001;**323** (7309):382-386
- [115] Saggini R, Di Stefano A, Capogrosso F, et al. Viscosupplementation with hyaluronic acid or polynucleotides: Results and hypothesis for chondro-synchronization. *Clinical Trials Journals*. 2014;**4**:198. DOI: 10.4172/2167-0870.1000198
- [116] Mitsui Y, Gotoh M, Nakama K, et al. Hyaluronic acid inhibits mRNA expression of proinflammatory cytokines and cyclooxygenase-2/prostaglandin E2 production via CD44 in interleukin-1-stimulated subacromial synovial fibroblasts from patients with rotator cuff disease. *Journal of Orthopaedic Research*. 2008;**26**(7):1032-1037
- [117] Merolla G, Bianchi P, Porcellini G. Ultrasound-guided subacromial injections of sodium hyaluronate for the management of rotator cuff tendinopathy: A prospective comparative study with rehabilitation therapy. *Musculoskeletal Surgery*. 2013;**1**:49-56
- [118] Setuain I, Gonzalez-Izal M, Paularena A, Luque JL, Andersen LL, Izquierdo M. A protocol for a new methodological model for work-related shoulder complex injuries: From diagnosis to rehabilitation. *BMC Musculoskeletal Disorders*. 2017;**18**:70
- [119] Michener LA, Walsworth MK, Burnet EN. Effectiveness of rehabilitation for patients with subacromial impingement syndrome: A systematic review. *Journal of Hand Therapy*. 2004;**17**:152-164
- [120] Ashton-Miller JA, Wojtys EM, Huston LJ, Fry-Welch D. Can proprioception really be improved by exercises? *Knee Surgery, Sports Traumatology, Arthroscopy*. 2001;**9**: 128-136
- [121] Reinold MM, Escamilla RF, Wilk KE. Current concepts in the scientific and clinical rationale behind exercises for glenohumeral and scapulothoracic musculature. *The Journal of Orthopaedic and Sports Physical Therapy*. 2009;**39**:105-117
- [122] Myers JB, Oyama S. Sensorimotor training for shoulder injury: Literature review. *Athletic Training and Sports Health Care*. 2009;**1**:199-208
- [123] Righetti GA, Magagni M, Marcolini G, Pari M, Galassi R. Trattamento propriocettivo nei pazienti operati di lesione della cuffia dei rotatori. *European Journal of Physical and Rehabilitation Medicine*. 2008;**44**:1
- [124] Magagni GA, Righetti P, Mietti P, Marcolini M, Pari G, Galassi R. Nuovo sistema valutativo per la spalla. *European Journal of Physical and Rehabilitation Medicine*. 2008;**44**:1