

We are IntechOpen, the world's leading publisher of Open Access books Built by scientists, for scientists

4,800

Open access books available

122,000

International authors and editors

135M

Downloads

Our authors are among the

154

Countries delivered to

TOP 1%

most cited scientists

12.2%

Contributors from top 500 universities



WEB OF SCIENCE™

Selection of our books indexed in the Book Citation Index
in Web of Science™ Core Collection (BKCI)

Interested in publishing with us?
Contact book.department@intechopen.com

Numbers displayed above are based on latest data collected.
For more information visit www.intechopen.com



Cryotherapy for Common Premalignant and Malignant Skin Disorders

Sevgi Akarsu and Isil Kamberoglu

Additional information is available at the end of the chapter

<http://dx.doi.org/10.5772/intechopen.70286>

Abstract

Cryotherapy, also known as cryosurgery or cryoablation, is a common dermatological treatment that is an expanded area from benign to malignant lesions. The system has been designed as a localized freezing cold that causes the destruction of cell integrity. The treatment has been also used for all ages, which is not required to have a condition of wellness. It is convenient, fast, and easy to apply in clinics, and there is no need for anesthesia. Additionally, multiple lesions are also cured in the same sessions. After the treatment, recovery period has not taken much longer and also has simple adverse effects, which are tolerable. Lastly, cryotherapy has gained excellent cosmetic results. It is highly effective for actinic keratosis and is the treatment of choice for most old patients who show poor cooperation and recurrent multiple lesions. Additionally, due to increasing premalignant lesions all over the world associated with increasing age, it is a considerable choice for lentigo maligna and Bowen's disease. In non-melanoma skin cancers, it is also the most important option in patients who do not undergo surgery and when other options are not appropriate. In this chapter, the use of cryotherapy for premalignant and malignant cutaneous disorders has been mainly focused.

Keywords: cryotherapy, cryosurgery, treatment, cutaneous, premalignant, malignant, actinic keratosis, non-melanoma skin cancers

1. History

Cryotherapy (also called cryosurgery or cryoablation) method was produced by James Arnott in England in 1945 to reduce the size of cancerous cells based on the theory that cold blood cells destroy the cells. Campbell White of New York City used cryotherapy as the first dermatological

indication in early-stage epithelioma patients in 1890. Later in 1907, Whitehouse described the use of this method in different diseases such as pigmented nevus and lupus. In addition, he has published a case series of skin cancers in different face regions. Beyond these series, he described that the spray method is superior to cotton swab. Lortat Jacobs and Solente first described the name "La Cryotherapie," which compounds with carbon dioxide in 1930s. Earlier in 1960s, Cooper and Lee introduced the cryosurgery technique as cooper apparatus cooled using liquid nitrogen. In the course of time, this technique has improved and has transformed in the present day [1, 2].

2. Mechanisms of action in cutaneous cryotherapy

If we consider the mechanism, mainly -196°C was required to transmit the cold over tissues. When freezing shock has just reached tissues due to intracellular hyperosmotic conditions, damage of cells begin. Rapid electrolyte transfer has started, thereby increasing the intracellular component, which has been incriminated for the damage of cell proteins and enzyme systems. Thrombosis has been observed in microcirculation system as a factor of irreversible tissue loss even in mild freeze. Furthermore, inflammation converts necrosis finally [3, 4].

The size of ice crystals is important, and larger crystals cause greater damage. Rapid freezing speeds are required in the treatment of malignant lesions where cryosurgery is required. Speed is also required, and repetitions of sequence increase cell deaths. This issue is also useful for malignant ones [3, 4].

The mechanism of extinction has referred melanocyte between -4 and -7°C , whereas keratinocyte and connective tissue cell destruction occur only at -20°C . Regarding basic mechanism, this technique has been applied in lower temperature, which is also available for such dermatological conditions having high success rates [3].

3. Techniques of cutaneous cryotherapy

Technical modalities have been divided into three main groups which include contact, spray, and intralesional types. The frequency of these methods, which are written in an order, extends to benign and malignant lesions. Contact method is applied using a cotton applicator that is usually used for common warts. The most widely used technique in dermatology clinic is the spray form directed from a 90° angle at a distance of 1–2 cm. The newly developed one is the intralesional technique mainly used in malignant lesions and keloid scars. Intralesional cryotherapy is the preferred choice than other methods due to preserving epidermis and absence of hypopigmentation and scarring. Local anesthesia is usually not necessary but may be recommended if large areas are being treated [5].

Cryotherapy and cryosurgery are the modalities used interchangeably. If we enlighten the terminology, cryotherapy accurately freezes the lesion, but when combined with curettage, it gets its name as cryosurgery. Nevertheless, most clinicians unintentionally confuse each other.

4. Indications of cutaneous cryotherapy

The most common indications change from country to country due to the mean age of population, education levels, and capability of the physicians. In a comprehensive study conducted between 1993 and 2010 in the USA, the cryotherapy method is the most frequently used in actinic keratosis (AK), common warts, and seborrheic keratosis [6]. An article investigated in our country suggested that the most common indications are common warts, anogenital warts, callosity, and AK. An interesting point of this article is the use of cryotherapy on leishmania cases, and it achieved good results [7]. Generally, authors receive attention regarding physicians who have to determine how many cycles and how long duration are required for each lesion. Especially, some of the skin areas having a thin dermis should take lesser freezing time even if malignant lesions should be repeated for more than one cycle. Additionally, cryotherapy is also reliable in pregnant women with anogenital warts. As expected, a combination with various therapeutical methods increases the success rate. Different dermatological indications of cryotherapy are summarized in **Table 1**. Our clinical experiences in cryotherapy of seborrheic keratosis and verruca plantaris (which are commonly seen as benign lesions) are also demonstrated in **Figures 1** and **2**, respectively.

Cryotherapy is also being discussed as an alternative to surgery in patients with premalignant or malignant lesions. The interesting point involved in our review is that the frequency of using cryotherapy has doubled compared to the first 10 years (1988–2000) than the second

Benign lesions	Premalignant lesions	Malignant lesions
Acne scars	Actinic keratosis	Basal cell carcinoma
Angioma	Bowen's disease	Squamous cell carcinoma
Dermatofibroma	Lentigomaligna	Keratoacanthoma
Fibroma molle		Kaposi sarcoma
Myxoid cyst		Inoperable melanoma metastases
Molluscum contagiosum		
Hidradenitis suppurativa [72]		
Idiopathic guttate hypomelanosis [73]		
Keloid, hypertrophic scar		
Lentigo solaris		
Pyogenic granuloma		
Sebaceous hyperplasia		
Seborrheic keratosis		
Warts		
Xanthelasma palpebrarum [74]		

Table 1. Different indications of cutaneous cryotherapy [6, 7, 10, 28, 36, 43, 54, 65, 69, 70, 71, 75].

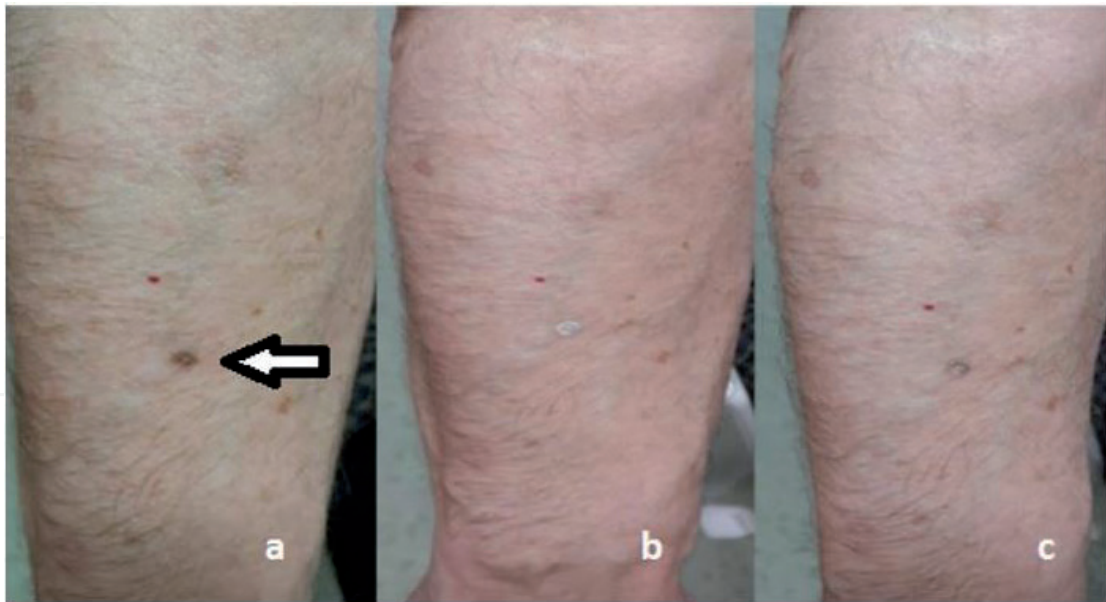

Figure 1. (a) Seborrheic keratosis in the right arm, (b) one cycle for 5–10-s freezing time via spray method, (c) before the second session of the treatment, reducing in size and fading in pigmentation of lesion.

decade (2008–2016). Additionally, it has been shown that the cryotherapy has lower cost than radiotherapy in patients who cannot undergo surgery in non-melanoma skin cancers. The average age increase in the second decade is also directly proportional to the increase in non-melanoma skin cancers [6]. For these reasons, the frequency of cryotherapy application in premalignant and malignant disorders may have been increased step by step over the years. In this chapter, premalignant and malignant cutaneous disorders have been mainly focused.

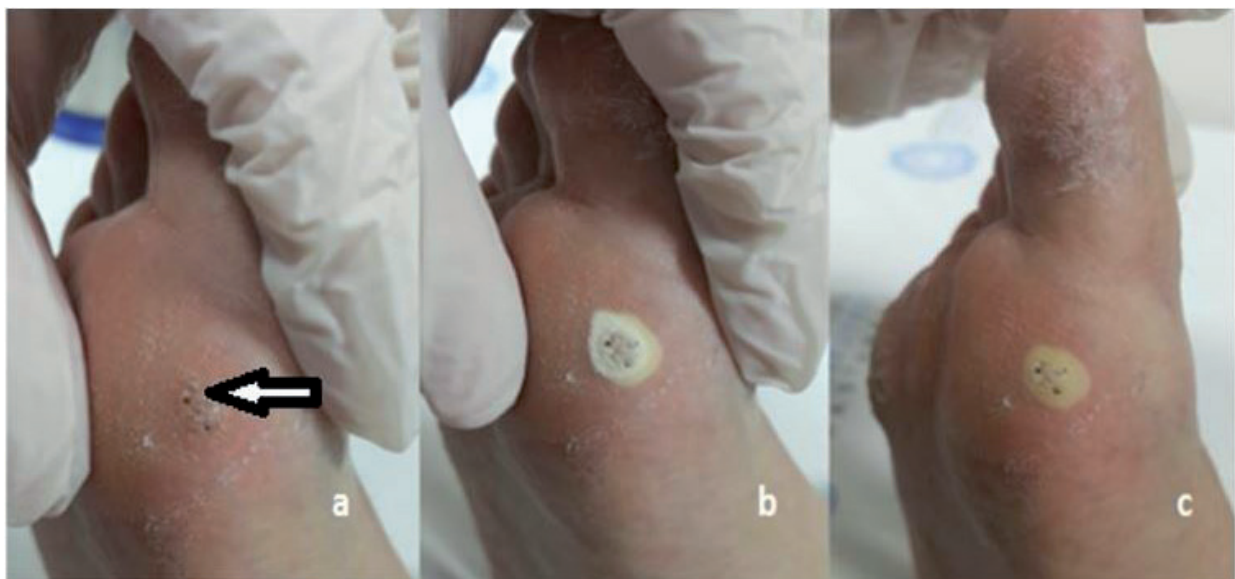


Figure 2. (a) Verruca plantaris in the sole of right foot, (b) two cycles for 15–20-s freezing time via spray method, (c) after 2 weeks, reduction in width and induration of lesion.

4.1. The use of cryotherapy in premalignant skin lesions

4.1.1. Actinic keratosis

AKs are common lesions consisting of epidermal keratinocytic dysplasia that are caused by chronic sun exposure. They are the most common premalignant skin lesions and clinically characterized by slow-growing, <1 cm, scaly, or hyperkeratotic papules in the areas exposed to the sun such as bald scalp, face, forearms, and hands. AKs are of public health importance because their presence is associated with the ability to progress to squamous cell carcinoma (SCC), especially when they are numerous and have coalesced into an area with severe photo-damage. Nevertheless, lesions occasionally have spontaneous remission. Utility of the cured AKs reduces the metastases, death ratio, and health economic expenditure [8–10].

Dermatologists have been treating patients with AKs for many years with cryotherapy. Treatment of these lesions with a simple and inexpensive method prevents converting non-melanoma skin cancers (especially SCC), which may be more complicated in the future. According to an Italian consensus, it is the first treatment option for AK patients with a high degree (Olsen 3) of clinical severity [11]. On behalf of the British Association of Dermatologists Therapy Guidelines, cryotherapy is a recommendation strength belonging to A group, which means there is good evidence to support the use of the procedure [10].

There was no clear consensus on the cryotherapy method of AK treatment all over the world. Numerous variables can influence the success of cryotherapy: the skill and experience of the physician, freezing time, freezing depth, the pressure of the liquid nitrogen set, the size of the orifice on the device, the distance between the lesion, the number of sessions, size, and the presence of hyperkeratotic lesions [12–14]. To get a point of view, Zouboulis published the meta-analysis via 26 studies which compared the regional regimens; they declared that the response rate depends on the clinicians' technique, freezing time, and extended area [13].

In this chapter, we focus on the most suitable method. As we wish to enlighten, we have evaluated a large number of group samples. Up to 98.8% cure rate has been reported, but more recent data indicate smaller cure rates [15]. Ianhez et al. had cryotherapy for 5–10 s in the form of two sessions between 5 and 50 tumors on the arm and face area of 92 patients at baseline and after 120 days. The same examiner counted the lesions before the treatment, at 120th and 300th days. After all, they found 57% reduction of lesion numbers. An interesting point of view was that higher education level of AK patients and lower number of lesions showed more successful results [12]. If we increase the sample size, Goldberg et al. performed a single session for 180 AK lesions for the same time as 5–10 s. At the end of 6 weeks, complete recovery was observed for all lesions. Though they occasionally focused on non-hyperkeratotic lesions, more success rates have been expected also due to freezing depth reaching the underlying lesions [14]. **Figure 3** shows the result of one-cycle cryotherapy of a patient with Bowenoid AK on the third week.

By the way, authors also investigated the freeze time for line of best fit. An article was investigated in Australia where 90 adult patients who had 421 eligible AK lesions were cured by cryotherapy. They found that higher freezing time is correlated with the higher complete

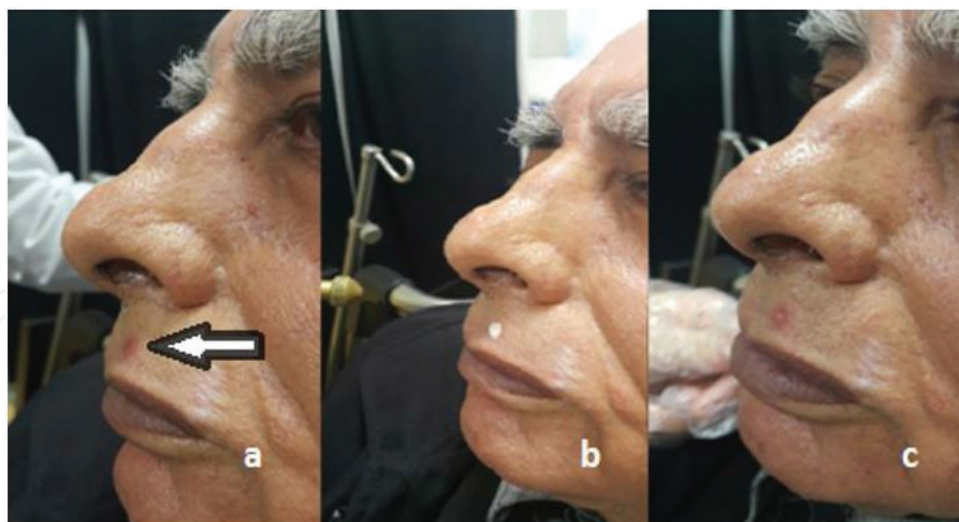


Figure 3. (a) Bowenoid AK lesion on the maxilla, (b) two cycles for 15–20-s freezing time via spray method, (c) before the third session of the treatment, reduction in size, erythema, and hyperkeratosis.

response of the lesion. Especially, the rates were 39% for 5 s, 69% for higher than 5 s, and 83% for higher than 20 s. If they achieved a regression analysis, they suggested the best time for the freezing time to be between 10 and 15 s as mentioned with maximum effect and also with minimum adverse effect. A higher than 30 s damages the dermis and causes scarring tissue and hypopigmentation [16]. As a common sense of clinicians, even though the exact regime does not exist, two cycles are always applied to get more effects.

When cryotherapy was compared with various methods, it has been observed that very different results were obtained. The first retrospective analysis was made in 1999 at 13 centers in 5 European countries by Szeimies et al. As population extended, 699 AK lesions were selected randomly to photodynamic therapy group (367 lesions) and cryosurgery group (332 lesions). They appraised that two modalities have similar complete response rates. Neither cryosurgery has superiorities to photodynamic therapy nor it has better cosmetic results. From this article, the suitability of cryotherapy has begun to be analyzed further [17]. Years later, Kaufman et al. also support this hypothesis in their reports involving more lesions [18]. Freeman et al. collated three groups of AK patients receiving photodynamic therapy (88 patients), cryotherapy (89 patients), and placebo (23 patients). The lesion response rates were found to be 91% in the photodynamic therapy group, 68% in the cryotherapy group, and 30% in the placebo group. As a result, photodynamic therapy has been considered as a better option than cryotherapy for complete lesion response as well as cosmetic outcome [19].

From a point of view, some authors analyzed the other optional modalities. From 1 to 3 years, clinical improvement of patients with 373 AK lesions treated by cryotherapy or 5-fluorouracil per group was investigated in Florida. As a result, cryotherapy was found to be doubly effective than 5-fluorouracil treatment when considering long-lasting comparability and also better cosmetic outcomes [20]. In addition, the efficacies of three different treatment modalities in patients with multiple AK lesions were compared by Krawtchenko et al. Nearly equal number of patients took one cryotherapy session, twice a day topical 5-fluorouracil during 4

weeks and topical imiquimod three times per week for 4 weeks. Patients were analyzed for clinical and histopathological evaluation at the 12th month. They could not determine the correlation between histopathological improvement (32%) and clinical improvement (68%) with the cryotherapy method. According to these values, half of the cases did not cure completely. Despite this, topical imiquimod application was the most effective method, and that also clinical (83%) and histopathological (73%) recovery rates were consistent with each other. Additionally, the patients' satisfaction ratio was found to be significantly higher than the cryotherapy and 5-fluorouracil application. They considered that 5-fluorouracil treatment is not acceptable for AK patients, howbeit topical imiquimod would be the top choice rather than cryotherapy [21].

To get another point of view, authorities have been seeking the correct combined treatment for AK patients for many years. Combination treatment modalities were inquired to manage both the lesion-directed and field-directed therapies. Regarding this, it is logical to combine with frequently used topical therapies including 5-fluorouracil, imiquimod, ingenol mebutate 0.05% gel, and diclofenac gel. All these agents cause some degree of localized inflammatory skin reaction mediated through a variety of biochemical pathways (interference with DNA synthesis, modification of immune response, and increased apoptosis through cyclooxygenase inhibition) and lead to elimination of the AK lesions [9]. Generally, the lowest irritation side effect has been seen with diclofenac gel treatment. As we consider to compare between the utility of combined or monotherapy; Berlin and Digel applied 3% diclofenac gel two weeks later than the cryosurgery and they had more adequate results than monotherapy [22]. After that, an article made in Italy enrolled 175 patients to configure out the results of monotherapy, cryotherapy, or 3% diclofenac gel, and combined therapy. The first group administered diclofenac gel twice a day for 12 weeks. The second group received two cycles of cryotherapy followed by diclofenac gel for 8 weeks. The last group was administered with two cycles of cryotherapy two times for 1 month. Nearly equal patients followed up for 2 years. They found that the first and third groups showed similar results but the response rate of the first group was slower. Besides that, the second group showed most effective results of nearly 100% of full recovery. That patients answered response for life quality index and so they responded cryotherapy has sufficiently improved the life quality index [23]. Clinicians should choose the modalities that are easy, effective, and not time consuming. Mastrolonardo et al. focused on the difficult recurrent AK lesions in a small group. They applied 3% diclofenac gel for 12 weeks so that the mean number reduced from 8 to 1. After that, they cured cryotherapy each 4 weeks for residual ones. For 10 months, no lesions were observed. They suggested that this combination therapy is remarkable for elder patients who show poor cooperation and recurrent multiple lesions [24]. Hashim et al. examined 16 patients who had cryotherapy; after that, half of them received ingenol mebutate 0.05% gel sequentially for 3 days. Although combined treatment had more side effects profile, which is also tolerable, statistically significant reduction of the lesions had also been observed [25]. In order to promote quantitative analysis for the validity of cryotherapy and 5-fluorouracil, combination treatment was made in 2004 firstly. A sample size of 70 patients per treatment group who took 5-fluorouracil regime for 1 week and residual lesions are treated with cryotherapy after 4 weeks. Jorizzo et al. calculated the proportion of validity with combined therapy. As a conclusion, they found significant difference

between combined therapy and monotherapy for 6 months. They mainly suggested that combined therapy is capable of increasing lesion-free period [26]. In another study, two groups included 30 patients with cryotherapy and 5-fluorouracil cream of 0.5%, and combination treatment efficacies were compared. After the application of cryotherapy, they used 5-fluorouracil cream once daily for 1 week. Besides that, they followed up for 26 weeks and claimed that no significant difference was found in terms of effectiveness. Despite the fact that adverse effects of 5-fluorouracil cream have been more commonly observed [27], recent research has shown that ingenol mebutate 0.05% gel and cryotherapy combination would be the future model for these patients [25]. In conclusion, clinicians should decide case by case due to age, health-care conditions, contraindications, and availability in AK cryotherapy.

4.1.2. Bowen's disease

Bowen's disease is characterized by enlarging well-demarcated erythematous plaque with an irregular border and crusting or scaling surface. It is a form of in situ SCC which behaves differently such as partial progression, minimal invasion, or spontaneous regression [28].

Plaza Lanza et al. compared the freezing ratio through the lesion and found that a single cycle is as efficacious as for two cycles [29]. Another article conducted by Holt found that they also have the same success using single 30-s cycle [30]. Graham and Clark reported one recurrence in 30 patients treated with a single period with the longest time as at least 90 s [31].

The rate of recurrence has been lower than expected. Recurrent lesions have been mostly invaded to dermis and cause SCC. Cox and Dyson demonstrated recurrence in five patients (6%) after a minimum of 1-year follow-up; one of these had a focus of invasive cancer [32]. Additionally, Morton et al. found two (10%) recurrences in the 1-year follow-up period [33].

In order to make shorter total imiquimod bout and milder cryotherapy effects compared with corresponding monotherapies, Gaitanis et al. published a series consisting of eight cases. They used two cycles of cryotherapy along meanly 15 s followed by the application of daily topical imiquimod. No recurrence was seen during the 6-month follow-up [34].

Ahmed et al. aimed to compare two strong options in patients with Bowen's disease, which occasionally mainstays in the lower leg region. Thirty-six patients were treated with cryotherapy via spray method giving two freeze-thaw cycles, each freeze cycle being maintained for 5–10 s. Forty-four patients were therapied with curettage and cautery, the margins beyond least 3-mm of clinically lesion-free skin area. As a result, curettage and cautery is a better modality because of shorter healing time, lesser pain evaluation, and fewer recurrence rates with significant differences [35].

4.1.3. Lentigo maligna

Lentigo maligna is a melanoma in situ which includes malignant cells but do not show invasion. The main reason of that is the long-term sun exposure, which also increased the risk of non-melanoma skin cancers. If middle-aged and elderly patients have larger than 1-cm atypical pigmented *macular* lesions, not in smooth surfaces, mainstays usually on the head

and neck should be checked up by the clinicians. There is a risk of conversion to malignant melanoma, and patients should be advised to undergo the surgery. As mentioned earlier, the mechanism of extinction between melanocyte of -4 to -7°C has formed the basis of the cryotherapy method in melanoma patients. However, in this method, the inability to scientifically determine the depth limit of the intervention restricts the number of patients. Beyond this reason, it is recommended to implement two cycles, for a long time and at least a distance of 1 cm from the lesion [36].

In a study conducted by Kuflick and Gage, 30 patients who had been diagnosed with lentigo maligna were treated with cryotherapy. At the end of the 3-year follow-up, only two lesions (6%) recurred [37]. In Brazil, 18 patients were diagnosed clinically and histopathologically as lentigo maligna was cured with cryotherapy by Moraes et al. Two freezing cycles were applied for 1 min each separated by thaw cycle of at least 2 min on a single session, and they also used spray method beyond a 1-cm area of vision border. In a 5-year period, they followed up at 6-month intervals. No recurrences or metastases were observed in any patient [38].

A case report is evaluated to propose cryoimmunological treatment of cryotherapy with imiquimod application in lentigo maligna lesions by Bassukas et al. A 78-year-old man who had been denied surgery was treated with 5% imiquimod cream once daily for 3 weeks. When erythema occurs, without cessation of the cream, they continued with cryotherapy via 20 s for two cycles. One year later, a cross check of the lesion was done, and they could not see any malignant cells. The patient became lesion free for 26 months after the treatment. They supposed that this combination therapy could be encouraging for lentigo maligna [39]. However, more research is needed as there are not many studies conducted on a sufficient number of people.

4.2. The use of cryotherapy in malignant skin lesions

4.2.1. Basal cell carcinoma

Basal cell carcinoma (BCC) is the most common cancer worldwide, which belongs to non-melanoma skin cancer group with SCC. BCC behaves as a slow-growing tumor impacting locally destructive cells and causing disfiguration for the metastasis that is very rare. Specifically, renal-transplant patients have an increased risk of developing BCC compared with the general population. Governments should keep in mind that treatment options should be increased to get either health or economic profits. As all you know, the gold standard is Mohs surgery, but as elderly people are not appropriate for this surgery, other methods should be used. The last publications have a few questions. According to the characteristic of the tumor, should elderly people prefer surgery or symptomatic destruction or is screening enough? [40–42].

Superficial and nodular BCCs have relatively well-defined borders, while morpheiform, micronodular, trabecular, infiltrative, and basosquamous BCCs are often irregular borders and are also more aggressive. The most commonly used approach of low-risk BCC (e.g., superficial BCC, nodulo-ulceratif BCC) is cryotherapy. The goal of the treatment is that clinicians should assess the margin of the lesion for complete removal. Because of that, invasion through the dermis, recurrent and aggressive types, larger than 2-cm lesion size and high-risk anatomic positions are contraindications of cryotherapy [43].

Compared with surgery, there are significant missing aspects. The most important ones are higher recurrence rates than surgery, lack of histologic confirmation of malignancy removal, recurrent carcinoma may be seen, hypertrophic scarring, and post-inflammatory pigment changes may occur. Nevertheless, there are some advantages also such as easy to apply, capable for elderly people, postoperative care not required, and life quality not affected [40].

Kuflik managed the widest and longest research in this regard, and overall 30-year cure rate was 98.6%. In this report, the freezing time and lesion width differ from 40 to 90 s and 1–1.5 cm, respectively. The cancer cells have been destroyed in the range of -50 to -60° . The most capable and acceptable procedure achieved satisfactory results. They also had a chance to follow-up the recurrence of lesions, so they declared that a 5-year cure rate of 522 cases was 99.0% [44]. Zacarian et al. reported an overall cure rate of 97.3% in 4228 non-melanoma skin carcinomas [45]. Samain et al. only focused on the mid-face BCC lesions and they investigated the 5-year recurrence ratio. They analyzed 138 patients with 144 BCC lesions and they presented 94% lesion-free ratio for 5 years. With reference to that, morpheiform BCC, which is theoretically a contraindication of cryosurgery, decreases the success ratio. Also, 55 lesions had curettage before cryotherapy that aims to increase the success rate by going deep into the lesion [46]. An article from Egypt used a different technique via intralesional cryoneedle, which had significant response rates and excellent outcomes as minimal or without scarring, erythema, and pigmentation changes for nodular and superficial BCC lesions [47]. Recently, one of the largest, prospective long-term follow-up series was conducted by Lindemalm-Lundstam and Dalenbäck. Like recent reports, they also found 97% complete response and good cosmetic results with the curettage and cryosurgery [48].

Actually in routine clinical practices, two cycles were applied to BCC lesions. Additionally, thaw time is approximately three times longer than freezing time to share out the lesion [13]. According to oncology guidelines, two freeze–thaw cycles with a tissue temperature of -50°C are recommended [49]. In order to estimate the reliability of sequence number, Mallon et al. treated 83 facial lesions with either one thaw 30-s cycle or second thaw 30-s cycle. They found that a double thaw cycle (95.3%) reliability ratio was higher than one cycle (79.4%) but also an interesting point is that one cycle is enough for trunk lesions [50].

Cryotherapy is an old but popular method for BCC treatment; there are some positive and negative value comparisons with other modalities. Kuijpers et al. compared a 5-year cure rate with either cryotherapy or surgical excision with small group, and they did not find statistically significant reduction of lesion number when surgical excision is chosen. Besides that, preferable reason for cryosurgery is better cosmetic outcomes than surgery. Regarding this, cryosurgery wounds generally heal with minimal tissue contraction and atrophy or scarring tissue is not commonly seen, resulting in good cosmetic results [51].

Actually, combined therapies, which were induced by immunological mechanism, are not used in non-melanoma cancers. Some authors worked on cryosurgery combination modalities such as photodynamic therapy or imiquimod cream once daily. Nakuci and Bassukas daily applied 5% imiquimod cream for 5 weeks, and at the second week, they performed cryosurgery. All 24 patients including 36 BCC lesions were satisfied with the cosmetic outcome and expressed their preference for this immunocryosurgery modality again as future choice

in the case of a tumor relapse [52]. On the other hand, Wang et al. found that photodynamic therapy and cryosurgery are comparable concerning efficacy but photodynamic therapy has better cosmetic results via assessment of a phase 3 clinical trial [53].

As a result of previous reports, cryosurgery is an effective method for BCC lesions with excellent cosmetic outcomes, causes higher life quality, and also is a practical approach that can implement in office conditions. Especially, superficial and nodular BCC lesions are suitable for this treatment. Future studies should focus on optimization of the treatment strategy for BCCs to administer standard immunocryosurgery.

4.2.2. Squamous cell carcinoma

SCC is the second most common cancer in the non-melanoma skin cancer class. SCC originates from keratinocytes due to cumulative sun exposure of skin. The lesions appear as papules or plaques which classified by skin-colored or pink, and smooth or hyperkeratotic. Ulceration may be present. The characteristic of SCC lesions is a high risk of distant metastasis causing higher mortality rates [54, 55].

SCCs are the most common malignancies in organ-transplant recipients. In immunocompromised patients, despite the clinical subtypes, it should be regarded as high-risk lesions. A survey was performed by dermatologists who treated organ-transplant recipients with squamous cell carcinoma. They first choose Mohs surgery among the patients and cryosurgery [56] as the second common therapy.

Curettage and cryosurgery arise from a variation of electrodesiccation and curettage, and offer a high cure rate for carefully selected superficial non-melanoma skin cancers. Peikert choose four subtypes of facial tumors consisting of superficial BCC (81 lesions), superficial BCC with papillary dermal invasion (2 lesions), SCC in situ (11 lesions), and SCC with papillary dermal invasion (6 lesions) which are smaller than 2 cm. They applied curettage after that one cycle 10-s cryotherapy, which has lesser freezing time for routine practices among the residual tissues. During the 5-year experience, only one recurrence of a superficial BCC on trunk was seen among 100 tumoral lesions [57]. For same samples, Nordin worked on a specific location as an auricula. They performed two sequence cryosurgery and curettage method. For 1-year follow-up, they did not see any metastasis and only one recurrence was determined in 60 non-melanoma skin cancer lesions [58].

Gonçalves described a new method of cryosurgery named as fractional cryosurgery. He dispensed hydrophilic gel between the center of the tumor and caused easing the calorie transfer. A cryoprobe was applied at the center of the tumor and did not require extending safety margin. A normal cryosurgery technique is based on freezing spray, which starts from the peripheral and goes through the center of the lesion. Despite this, they cured nine SCC lesions during the follow-up, which was 1 year for one patient and between 3 and 6 years for the remaining patients. They suggested that no recurrence was statistically significant; due to this, SCC lesions must be treated more aggressively. They also mentioned that larger than 15 mm of lesion width is required for another treatment in non-melanoma skin cancers [59].

It has been mentioned that keratoacanthoma should be accepted as low-risk SCC so that it has to be treated as SCC. The defining characteristic of keratoacanthoma is a symmetric inflammatory nodule with ulcerative debris originating from pilosebaceous glands. Although it has spontaneous regression also over 4–6 months, metastasis risk of SCC is enough to get adequate treatment. Some authors contented that this is a subtype of SCC, also [60, 61].

Chronic radiodermatitis can cause keratoacanthoma in professional physicians who did not protect themselves from the chronic X-ray exposure. Conejo-Mir et al. worked on noninvasive SCC lesions regarded as keratoacanthoma which located at the finger. They applied two-cycle 30-s cryotherapy for six patients. During 2 years of follow-up, no recurrence was seen and also the most relevant issue is that finger mobility had been protected in all patients [62].

Lee et al. reported using intralesional cryotherapy technique in four elderly patients with keratoacanthoma. After the local anesthesia, an 18-gauge needle was inserted into the lesion and two cycles were applied beyond 30–60 s. If the residual lesion was presumed, they also used spray cryotherapy for one to three cycles. All lesions had complete remission in 2 months. They argued that small lesions as smaller than 1 cm could have been curable. Intralesional method is superior than the other types due to cosmetic outcomes such as absence of hypopigmentation. However, it would be contraindicated in the anatomic locations where has risk of poor healing due to insufficient circulation [63].

A published case report regards subungual SCC treated first with Mohs surgery after which the residual tissue is destroyed via cryotherapy as two cycles in 90 s. In order to protect tissue integrity and phalanx function, using cryosurgery as an adjuvant may improve cure rates in some cases of SCC [64]. Cryosurgery is one of the suitable options when other options are not appropriate or adjuvant modality for highly invasive non-melanoma skin cancers.

4.2.3. *Kaposi sarcoma*

Kaposi sarcoma is a vascular tumor that has brownish red to bluish red cutaneous nodules that tended to enlarge into dome-shaped tumors. There are variable modalities used for the treatment of Kaposi sarcoma such as surgery, chemotherapy, cryotherapy, electrosurgery, laser, and radiation therapies.

Kutlubay et al. investigated 30 patients with Kaposi sarcoma in a retrospective cohort study. Nineteen (63%) of them completed response to cryotherapy [65]. In addition, Scheofer et al. and Avilés Izquierdo et al. found cryotherapy to be more effective in superficial and small Kaposi sarcoma lesions [66, 67].

4.2.4. *Inoperable malign melanoma metastases*

Although the main treatment option for malign melanoma patients is surgery, different alternatives can be used in cutaneous lesions and also metastases as some people could not be operated. Rivas-Tolosa et al. applied cryotherapy and topical 5% imiquimod treatment to 20 patients with locoregional cutaneous metastases of melanoma patients who could not undergo surgery. After an average of five sessions, 13 patients (65%) responded to treatment.

Eight (40%) of them have complete remission and the remaining five (25%) patients have partial response [68]. This is the first published pros and cons of the article regarding the life expectancy index of each decision.

5. Conclusion

Cryotherapy is also being discussed as an alternative to surgery in patients with premalignant or malignant skin lesions. The frequency of cryotherapy application has been increased step by step over the years correlated with older ages when such lesions occasionally occur. Response rates usually depend on the clinicians' technique, freezing time, and extended area. Mainly, non-hyperkeratotic lesions have more successful rates due to freezing depth reaching the underlying lesions. It is the first treatment of choice for AK patients. The authors compared the efficacy of modalities and they suggested that topical imiquimod or photodynamic therapy would be better choice rather than cryotherapy. Nevertheless, recent researches have shown that ingenol mebutate 0.05% gel and cryotherapy combination would be the future model for AK patients. Another premalignant lesion is Bowen's disease, which has also a higher risk of converting non-melanoma skin cancer and could be treated by cryotherapy, but cryotherapy-combined modalities (5-fluorouracil cream, curettage, and cautery) showed better results than monotherapy. An interesting point is that lentigo maligna patients are cured by cryotherapy as an alternative for surgery. In non-melanoma skin cancers, cryotherapy is an effective method with excellent cosmetic outcomes, thereby causing higher life quality. It is practical approach for patients who cannot undergo surgery that can implement in office conditions. Negative values of cryotherapy are considered as lack of histologic confirmation of malignancy removal, recurrent carcinoma may be seen, hypertrophic scarring, and post-inflammatory pigment changes may occur. Especially, superficial and nodular BCC lesions are suitable for this treatment. High risk of distant metastasis mostly of SCC lesions have limited the indications of cryosurgery. Regarding this, well-differentiated SCCs such as keratoacanthoma or SCC in situ lesions have benefits for this modality. Besides that, limited study has shown that cryotherapy could be an alternative treatment for Kaposi sarcoma or locoregional cutaneous metastasis of melanoma lesions. Cryotherapy is one of the suitable options when other options are not appropriate or adjuvant modality for highly invasive non-melanoma skin cancers. As a conclusion, future studies should focus on optimization of the treatment strategy in right-selected multitudinous populations to administer standard cryotherapy guidelines.

Author details

Sevgi Akarsu and Isil Kamberoglu*

*Address all correspondence to: isil.kamberoglu@gmail.com

Dermatology and Venerology Department, Dokuz Eylul University, Izmir, Turkey

References

- [1] Korpan NN. A history of cryosurgery: Its development and future. *Journal of American College of Surgery*. 2007;**204**(2):314-324. DOI: 10.1016/j.jamcollsurg.2006.11.006
- [2] Gage AA. History of cryosurgery. *Seminars in Surgical Oncology*. 1998;**14**(2):99-109
- [3] Kuflik EG. Cryosurgery for cutaneous malignancy: An update. *Dermatological Surgery*. 1997;**23**(11):1081-1087
- [4] Zouboulis CC. Principles of cutaneous cryosurgery: An update. *Dermatology*. 1999;**198**(2):111-117. DOI: 10.1159/000018084
- [5] Zimmerman EE, Crawford P. Cutaneous cryosurgery. *American Family Physician*. 2012;**86**(12):1118-1124
- [6] Farhangian ME, Snyder A, Huang KE, Doerfler L, Huang WW, Feldman SR. Cutaneous cryosurgery in the United States. *Journal of Dermatological Treatment*. 2016;**27**(1):91-94. DOI: 10.3109/09546634.2015.1054780
- [7] Afsar FS, Erkan CD, Karaca S. Clinical practice trends in cryosurgery: A retrospective study of cutaneous lesions. *Postepy Dermatologii i Alergologii*. 2015;**32**(2):88-93. DOI: 10.5114/pdia.2015.48048
- [8] Akarsu S, Ozbagcivan O, Ilknur T, Semiz F, Fetil E. Influence of demographic and clinical characteristics of actinic keratosis patients on illness perceptions and readiness to increase sun protection behaviours: An exploratory study. *Photodermatol Photoimmunol Photomed*. 2017 May;**33**(3):143-155. DOI: 10.1111/phpp.12295. Epub 2017 Feb 22
- [9] Ceilley RI, Jorizzo JL. Current issues in the management of actinic keratosis. *Journal of American Academy of Dermatology*. 2013;**68**(Suppl 1):S28-S38. DOI: 10.1016/j.jaad.2012.09.051
- [10] deBerker D, McGregor JM, Hughes BR. Guidelines for the management of actinic keratoses. *British Journal of Dermatology*. 2007;**156**(2):222-230. DOI:10.1111/j.1365-2133.2006.07692.x
- [11] Peris PG, Calzavara-Pinton PG, Neri L, Girolomoni G, Malara G et al. Italian expert consensus for the management of actinic keratosis in immunocompetent patients. *Journal of European Academy of Dermatology and Venereology*. 2016;**30**(7):1077-1084. DOI: 10.1111/jdv.13648
- [12] Ianhez M, Miot HA, Bagatin E. Liquid nitrogen for the treatment of actinic keratosis: A longitudinal assessment. *Cryobiology*. 2014;**69**(1):140-143. DOI: 10.1016/j.cryobiol.2014.06.006
- [13] Zouboulis CC. Is cryosurgery less effective than conservative regimens in the treatment of actinic keratoses? *Journal of European Academy of Dermatology and Venereology*. 2016;**30**(10):e50-e53. DOI: 10.1111/jdv.13294

- [14] Goldberg LH, Kaplan B, Vergilis-Kalner I, Landau J. Liquid nitrogen: Temperature control in the treatment of actinic keratosis. *Dermatological Surgery*. 2010;**36**(12):1956-1961. DOI: 10.1111/j.1524-4725.2010.01804.x
- [15] Schmitt AR, Bordeaux JS. Solar keratoses: Photodynamic therapy, cryotherapy, 5-fluorouracil, imiquimod, diclofenac, or what? Facts and controversies. *Clinics in Dermatology*. 2013;**31**(6):712-717. DOI: 10.1016/j.clindermatol.2013.05.007
- [16] Thai KE, Fergin P, Freeman M, Vinciullo C, Francis D, Spelman L, et al. A prospective study of the use of cryosurgery for the treatment of actinic keratoses. *International Journal of Dermatology*. 2004;**43**(9):687-692. DOI: 10.1111/j.1365-4632.2004.02056.x
- [17] Szeimies RM, Karrer S, Radakovic-Fijan S, Tanew A, Calzavara-Pinton PG, Zane C, et al. Photodynamic therapy using topical methyl 5-aminolevulinate compared with cryotherapy for actinic keratosis: A prospective, randomized study. *Journal of American Academy of Dermatology*. 2002;**47**(2):258-262
- [18] Kaufmann R, Spelman L, Weightman W, Reifenberger J, Szeimies RM, et al. Multicentre intraindividual randomized trial of topical methyl aminolevulinate-photodynamic therapy vs. cryotherapy for multiple actinic keratoses on the extremities. *British Journal of Dermatology*. 2008;**158**(5):994-999. DOI: 10.1111/j.1365-2133.2008.08488.x
- [19] Freeman M, Vinciullo C, Francis D, Spelman L, Nguyen R, Fergin P, et al. A comparison of photodynamic therapy using topical methyl aminolevulinate (metvix) with single cycle cryotherapy in patients with actinic keratosis: A prospective, randomized study. *Journal of Dermatological Treatment*. 2003;**14**(2):99-106
- [20] Chiarello SE. Cryopeeling (extensive cryosurgery) for treatment of actinic keratoses: An update and comparison. *Dermatological Surgery*. 2000;**26**(8):728-732
- [21] Krawtchenko N, Roewert-Huber J, Ulrich M, et al. A randomised study of topical 5% imiquimod vs. topical 5-fluorouracil vs. cryosurgery in immunocompetent patients with actinic keratoses: A comparison of clinical and histological outcomes including 1-year follow-up. *British Journal of Dermatology*. 2007;**157**(Suppl 2):34-40. DOI: 10.1111/j.1365-2133.2007.08271.x
- [22] Berlin JM, Digel DS. Diclofenac sodium 3% gel in the treatment of actinic keratosis post-cryosurgery. *Journal of Drugs in Dermatology*. 2008;**7**(7):669-673
- [23] Serena L, Mariateresa C, Maria Grazia F, Claudio L, Anna B, Massimiliano S. Actinic keratosis: Sequential treatment with cryotherapy and 3% sodium diclofenac gel. *Clin Exp Dermatol*. 2009 Jan;**34**(1):33-5. DOI: 10.1111/j.1365-2230.2008.02783.x. Epub 2008 Jun 25
- [24] Mastrolonardo M. Topical diclofenac 3% gel plus cryotherapy for treatment of multiple and recurrent actinic keratoses. *Clinical Experimental Dermatology*. 2009;**34**(1):33-35. DOI: 10.1111/j.1365-2230.2008.02783.x
- [25] Hashim PW, Nia JK, Singer S, Goldenberg G. An investigator-initiated study to assess the safety and efficacy of ingenol mebutate 0.05% gel when used after cryosurgery in the

treatment of hypertrophic actinic keratosis on dorsal hands. *The Journal of Clinical and Aesthetic Dermatology*. 2016;**9**(7):16-22

- [26] Jorizzo J, Weiss J, Furst K, VandePol C, Levy SF. Effect of a 1-week treatment with 0.5% topical fluorouracil on occurrence of actinic keratosis after cryosurgery: A randomized, vehicle-controlled clinical trial. *Archives of Dermatology*. 2004;**140**(7):813-816. DOI: 10.1001/archderm.140.7.813
- [27] Hoover WD 3rd, Jorizzo JL, Clark AR, Feldman SR, Holbrook J, Huang KE. Efficacy of cryosurgery and 5-fluorouracil cream 0.5% combination therapy for the treatment of actinic keratosis. *Cutis*. 2014;**94**(5):255-259
- [28] Cox NH, Eedy DJ, Morton CA. Guidelines for management of Bowen's disease: 2006 update. *British Journal of Dermatology*. 2007;**156**(1):11-21. DOI: 10.1111/j.1365-2133.2006.07610.x
- [29] Plaza Lanza M, Ralphs I, Dawber RPR. Cryosurgery for Bowen's disease of the skin. *British Journal of Dermatology*. 1980;**103**(Suppl. 18):14
- [30] Holt PJ. Cryotherapy for skin cancer: Results over a 5-year period using liquid nitrogen spray cryosurgery. *British Journal of Dermatology*. 1988;**119**:231-240
- [31] Graham GF, Clark LC. Statistical analysis in cryosurgery of skin cancer. *Clinical Dermatology*. 1990;**8**(1):101-107
- [32] Cox NH, Dyson P. Wound healing on the lower leg after radiotherapy or cryotherapy of Bowen's disease and other malignant skin lesions. *British Journal of Dermatology*. 1995;**133**(1):60-65
- [33] Morton CA, Whitehurst C, Moseley H, McColl JH, Moore JV, Mackie RM. Comparison of photodynamic therapy with cryotherapy in the treatment of Bowen's disease. *British Journal of Dermatology*. 1996;**135**(5):766-771
- [34] Gaitanis G, Mitsou G, Tsiouri G, Alexis I, Bassukas ID. Cryosurgery during imiquimod cream treatment ("immunocryosurgery") for Bowen's disease of the skin: A case series. *Acta Dermato-Venereologica*. 2010;**90**(5):533-534. DOI: 10.2340/00015555-0896
- [35] Ahmed I, Jones B, Holmes C, O'Callaghan C, Ilchyshyn A. Comparison of cryotherapy with curettage in the treatment of Bowen's disease: A prospective study. *British Journal of Dermatology*. 2000;**143**(4):759-766. DOI: 10.1046/j.1365-2133.2000.03772.x
- [36] Kasprzak JM, Xu YG. Diagnosis and management of lentigo maligna: A review. *Drugs Context*. 2015;**4**:212281. DOI: 10.7573/dic.212281
- [37] Kuflick EG, Gage AA. Cryosurgery for lentigo maligna. *Journal of American Academy of Dermatology*. 1994;**31**:75-78
- [38] Moraes AM, Pavarin LB, Herreros F, Aguiar Michelman F, Velho PE, Souza EM. Cryosurgical treatment of lentigo maligna. *Journal der Deutschen Dermatologischen Gesellschaft*. 2007;**5**(6):477-480. DOI: 10.1111/j.1610-0387.2007.06331.x

- [39] Bassukas ID, Gamvroulia C, Zioga A, Nomikos K, Fotika C. Cryosurgery during topical imiquimod: A successful combination modality for lentigo maligna. *International Journal of Dermatology*. 2008;**47**(5):519-521. DOI: 10.1111/j.1365-4632.2008.03562.x
- [40] Ceilley RI, Del Rosso JQ. Current modalities and new advances in the treatment of basal cell carcinoma. *International Journal of Dermatology*. 2006;**45**(5):489-498. DOI: 10.1111/j.1365-4632.2006.02673.x
- [41] Linos E, Chren MM. Is screening for basal cell carcinoma worthwhile? Too soon to tell. *British Journal of Dermatology*. 2016;**174**(6):1181-1182. DOI: 10.1111/bjd.14706
- [42] Telfer NR, Colver GB, Morton CA. Guidelines for the management of basal cell carcinoma. *British Journal of Dermatology*. 2008;**159**(1): 35-48. DOI: 10.1111/j.1365-2133.2008.08666.x
- [43] Martinez JC, Otley CC. The management of melanoma and nonmelanoma skin cancer: A review for the primary care physician. *Mayo Clinical Proceedings*. 2001;**76**(12):1253-1265. DOI: 10.4065/76.12.1253
- [44] Kuflik EG. Cryosurgery for skin cancer: 30-year experience and cure rates. *Dermatological Surgery*. 2004;**30**(2 pt 2):297-300
- [45] Zacarian SA. Cryosurgery of cutaneous carcinomas: An 18-year study of 3,022 patients with 4,228 carcinomas. *Journal of American Academy of Dermatology*. 1983;**9**:947-956
- [46] Samain A, Boullié MC, Duval-Modeste AB, Joly P. Cryosurgery and curettage-cryosurgery for basal cell carcinomas of the mid-face. *Journal of European Academy of Dermatology and Venereology*. 2015;**29**(7):1291-1296. DOI: 10.1111/jdv.12798
- [47] Weshahy AH, Abdel Hay RM, Metwally D, et al. The efficacy of intralesional cryosurgery in the treatment of small- and medium-sized basal cell carcinoma: A pilot study. *Journal of Dermatological Treatment*. 2015;**26**(2):147-150. DOI: 10.3109/09546634.2014.906037
- [48] Lindemalm-Lundstam B, Dalenbäck J. Prospective follow-up after curettage-cryosurgery for scalp and face skin cancers. *British Journal of Dermatology*. 2009;**161**(3):568-576. DOI: 10.1111/j.1365-2133.2009.09310.x
- [49] Avcı G. An Overview on Basal Cell Carcinoma,. *Skin Cancer Overview* Edited by Yaguang Xi, ISBN 978-953-307-746-8, 226 pages, Publisher: InTech, Chapters published December 16, 2011 under CC BY 3.0 license DOI: 10.5772/2440
- [50] Mallon E, Dawber R. Cryosurgery in the treatment of basal cell carcinoma. *Dermatological Surgery*. 1996;**22**:854-858
- [51] Kuijpers DIM, Thissen MRTM, Berretty PJM, Ideler FHLB, Nelemans PJ, et al. Surgical excision versus curettage plus cryosurgery in the treatment of basal cell carcinoma. *Dermatological Surgery*. 2007;**33**(5):579-587. DOI: 10.1111/j.1524-4725.2007.33117.x
- [52] Nakuci M, Bassukas ID. Office-based treatment of basal cell carcinoma with immunocryosurgery: Feasibility and efficacy. *Acta Dermatovenerologica Alpina, Pannonica et Adriatica*. 2013;**22**(2):35-38

- [53] Wang I, Bendsoe N, Klinteberg CA, Enejder AM, Andersson-Engels S, et al. Photodynamic therapy vs. cryosurgery of basal cell carcinomas: Results of a phase III clinical trial. *British Journal of Dermatology*. 2001;**144**(4):832-840
- [54] Sapijaszko M, Zloty D, Bourcier M, Poulin Y, Janiszewski P, Ashkenas J, et al. Non-melanoma skin cancer in Canada chapter 5: Management of squamous cell carcinoma. *Journal of Cutaneous Medical Surgery*. 2015;**19**(3):249-259. DOI: 10.1177/1203475415582318
- [55] Alam M, Ratner D. Cutaneous squamous-cell carcinoma. *New England Journal of Medicine*. 2001;**344**(13):975-983. DOI: 10.1056/NEJM200103293441306
- [56] Clayton AS, Stasko T. Treatment of nonmelanoma skin cancer in organ transplant recipients: Review of responses to a survey. *Journal of American Academy of Dermatology*. 2003;**49**(3):413-416
- [57] Peikert JM. Prospective trial of curettage and cryosurgery in the management of non-facial, superficial, and minimally invasive basal and squamous cell carcinoma. *International Journal of Dermatology*. 2011;**50**(9):1135-1138
- [58] Nordin P. Curettage-cryosurgery for non-melanoma skin cancer of the external ear: Excellent 5-year results. *British Journal of Dermatology*. 1999;**140**:291-293. DOI: 10.1111/j.1365-4632.2011.04969.x
- [59] Gonçalves JC. Fractional cryosurgery for skin cancer. *Dermatological Surgery*. 2009;**35**(11):1788-1796. DOI: 10.1111/j.1524-4725.2009.01292.x
- [60] Manstein CH, Fraunhoffer CJ, Besden JE. Keratoacanthoma: Is it a real entity? *Annals in Plastic Surgery*. 1998;**40**(5):469-472
- [61] Gleich T, Chiticariu E, Huber M, Hohl D. Keratoacanthoma: A distinct entity? *Experimental Dermatology*. 2016;**25**(2):85-91. DOI: 10.1111/exd.12880
- [62] Conejo-Mir JS, Moreno JC, Camacho F. Cryosurgical treatment of professional chronic radiodermatitis. *Dermatological Surgery*. 1997;**23**(6):483-486
- [63] Lee CN, Pan SC, Lee JY, Wong TW. Successful treatment of cutaneous squamous cell carcinoma with intralesional cryosurgery: Case report. *Medicine (Baltimore)*. 2016;**95**(39):e4991. DOI: 10.1097/MD.0000000000004991
- [64] Ruiz Santiago H, Morales-Burgos A. Cryosurgery as adjuvant to Mohs micrographic surgery in the management of subungual squamous cell carcinoma. *Dermatological Surgery*. 2011;**37**(2):256-258. DOI: 10.1111/j.1524-4725.2010.01860.x
- [65] Kutlubay Z, Küçüktaş M, Yardımcı G, Engin B, Serdaroğlu S. Evaluation of effectiveness of cryotherapy on the treatment of cutaneous Kaposi's sarcoma. *Dermatological Surgery*. 2013;**39**(10):1502-1506. DOI: 10.1111/dsu.12285
- [66] Scheofer H, Ochsendorf FR, Hochscheid I, Milbradt R. Facial Kaposi's sarcoma. Palliative treatment with cryotherapy, intralesional chemotherapy, low-dose roentgen therapy and camouflage. *Hautarzt*. 1991;**42**(8):492-498

- [67] Avilés Izquierdo JA, García-Andrade CR, Gómez-Cornejo LP, Lazaro Ochaíta P, de Portugal Alvarez J. Characteristics of Kaposi's sarcoma. A retrospective study in a reference hospital. *Anales de Medicina Interna*. 2003;**20**(4):170-174
- [68] Rivas-Tolosa N, Ortiz-Brugués A, Toledo-Pastrana T, Baradad M, Traves V, Soriano V et al. Local cryosurgery and imiquimod: A successful combination for the treatment of locoregional cutaneous metastasis of melanoma: A case series. *Journal of Dermatology*. 2016;**43**(5):553-556. DOI: 10.1111/1346-8138.13197
- [69] Wood LD, Stucki JK, Hollenbeak CS, Miller JJ. Effectiveness of cryosurgery vs curettage in the treatment of seborrheic keratoses. *JAMA Dermatology*. 2013 Jan;**149**(1):108-9. DOI: 10.1001/2013.jamadermatol.275
- [70] Gupta S, Sharma VK. Standard guidelines of care: Keloids and hypertrophic scars. *Indian Journal of Dermatology, Venereology and Leprology*. 2011;**77**(1):94-100. DOI: 10.4103/0378-6323.74968
- [71] Levy LL, Zeichner JA. Management of acne scarring, part II: A comparative review of non-laser-based, minimally invasive approaches. *American Journal of Clinical Dermatology*. 2012;**13**(5):331-340. DOI: 10.2165/11631410-000000000-00000
- [72] Pagliarello C, Fabrizi G, Feliciani C, Nuzzo S. Cryoinsufflation for Hurley stage II hidradenitis suppurativa: A useful treatment option when systemic therapies should be avoided. *JAMA Dermatology*. 2014;**150**(7):765-766. DOI: 10.1001/jamadermatol.2014.430
- [73] Laosakul K, Juntongjin P. Efficacy of tip cryotherapy in the treatment of idiopathic guttate hypomelanosis (IGH): A randomized, controlled, evaluator-blinded study. *Journal of Dermatological Treatment*. 2016;**23**:1-5. DOI: 10.1080/09546634.2016.1221498
- [74] Labandeira J, Vázquez-Osorio I, Figueroa-Silva O, Pereiro M Jr, Toribio J. Tolerability and effectiveness of liquid nitrogen spray cryotherapy with very short freeze times in the treatment of xanthelasma palpebrarum. *Dermatological Therapy*. 2015;**28**(6):346-350. DOI: 10.1111/dth.12254
- [75] Andrews MD. Cryosurgery for common skin conditions. *American Family Physician*. 2004;**69**(10):2365-2372

