

# We are IntechOpen, the world's leading publisher of Open Access books Built by scientists, for scientists

4,800

Open access books available

122,000

International authors and editors

135M

Downloads

Our authors are among the

154

Countries delivered to

TOP 1%

most cited scientists

12.2%

Contributors from top 500 universities



WEB OF SCIENCE™

Selection of our books indexed in the Book Citation Index  
in Web of Science™ Core Collection (BKCI)

Interested in publishing with us?  
Contact [book.department@intechopen.com](mailto:book.department@intechopen.com)

Numbers displayed above are based on latest data collected.  
For more information visit [www.intechopen.com](http://www.intechopen.com)



---

## **Bedside Procedure: Retained Central Venous Catheter**

---

Maureen E. Cheung, Logan T. Mellert and  
Michael S. Firstenberg

Additional information is available at the end of the chapter

<http://dx.doi.org/10.5772/intechopen.69748>

---

### **Abstract**

The placement of central venous catheters (CVC) is a common medical procedure and adjunct to current medical therapy. With millions of CVC placed yearly in the United States, complications occur. It is important to be aware of the potential immediate and long term complications associated with this procedure. In this chapter, a representative case of retained CVC guidewire is presented. Provider experience, appropriate patient selection and insertion technique can minimize the risk of immediate complication in most cases. A brief discussion of CVC complications with emphasis on guidewire malfunction is presented along with management and retrieval options.

**Keywords:** retained guidewire, central venous catheter, catheter complications, bedside procedures, J wire, guidewire fracture, intravascular foreign body

---

### **1. Introduction**

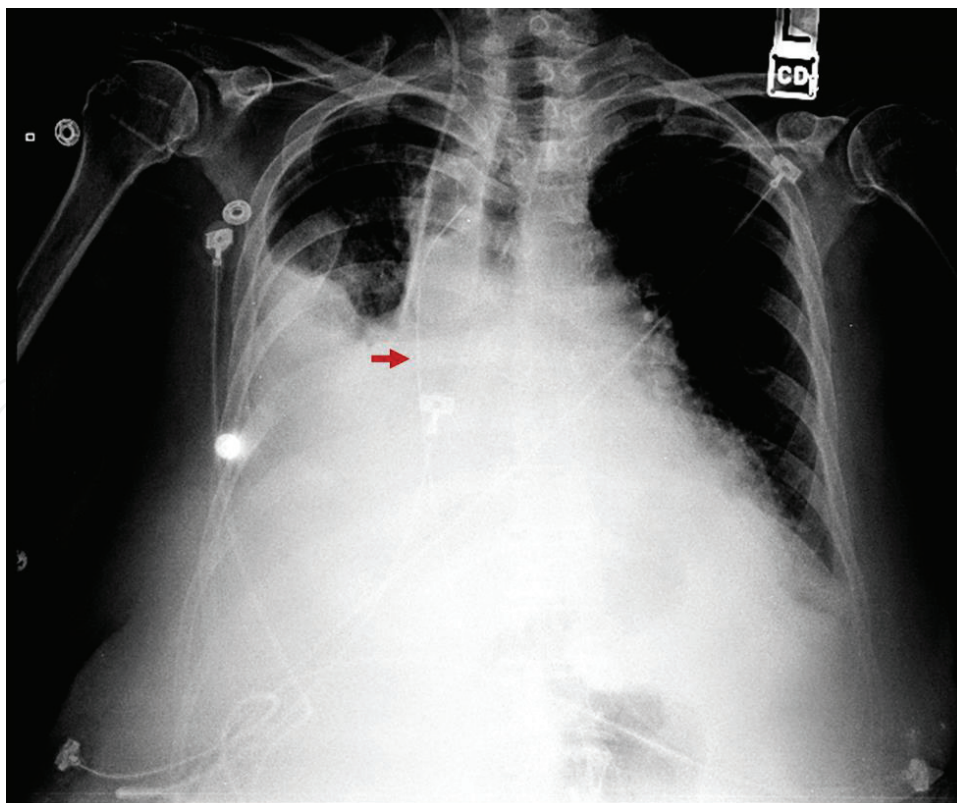
With more than 5 million central lines placed in the United States every year, complications are anticipated [1–4]. The most common immediate complications of central venous catheterization (CVC) include pneumothorax (incidence of 0.5–1.5%), arterial puncture (0.5–3.7%), and cardiac ectopy (0.9%) [1, 5, 6]. Retained guide wire is a recognized but rare complication during insertion of CVC. The estimated incidence is 0.05–0.1% during CVC insertion [7, 8]. Causes of retention include guide wire looping, entrapment, wedging within catheter and fracture during insertion [9–11]. While retained guide wire is a rare complication, it is entirely preventable except in cases of catastrophic equipment failure and is considered an unacceptable occurrence by physicians.

## 2. Vignette

A 69 year old female presents with pneumonia and sepsis. She is hypotensive and unresponsive to multiple fluid challenges. The placement of a CVC is necessary for norepinephrine infusion therapy. She has a past medical history of hypertension, diabetes mellitus (type II), and chronic obstructive pulmonary disease. Her past surgical is significant for laparoscopic cholecystectomy and Cesarean section. She denies a history of head/neck surgery or prior central venous instrumentation.

After obtaining consent, a right internal jugular (IJ) CVC is placed using ultrasound guidance. After gaining venous access, the guide wire is threaded. It initially passes easily but resistance is met at approximately 10 cm. An attempt is made to withdraw the guide wire, however significant resistance is met. After multiple attempts to withdraw and advance the guide wire, there is a sudden change in resistance and the guide wire is easily advanced. The remainder of the procedure is completed using the modified Seldinger technique and a triple lumen catheter is placed. All ports easily draw blood and flush with saline (**Figure 1**).

A post procedure chest X-ray is obtained. The tip of the catheter terminates in the mid-superior vena cava (SVC) and a linear hyperdensity within the right atrium is noted. This is approximately 8 cm in length and consistent with retained guide wire. You inspect the procedural guide wire and note that the distal end does not have its characteristic "J" bend.



**Figure 1.** Chest X-ray revealing a retained guide wire (arrow).

### 3. Discussion

When inserting a CVC, it is essential that the provider is experienced and has been appropriately trained, supervised, and privileged to perform the procedure. If the clinical scenario allows, informed consent should be obtained. An appropriate insertion site should then be selected. The modified Seldinger technique is utilized for catheter placement. If an IJ or subclavian (SC) catheter is inserted, chest X-ray is performed to confirm placement location and ensure no pneumothorax has developed [2, 6, 12–16].

#### 3.1. Indications and catheters

CVC are an important component of medical care. They provide temporary short-term or long-term vascular access and are used for hematologic sampling and monitoring, long-term antibiotic administrations, hemodialysis, and the delivery of caustic therapeutics such as vasopressors, total parenteral nutrition (TPN), and chemotherapy. During insertion and when not in use, these catheters are flushed to maintain patency. Flushes are usually a sterile saline or heparin saline solution which is injected to fill the catheter. If an institution utilizes heparin saline for flushes, care should be exercised to identify patients with contraindications to heparin such as history of hypersensitivity reaction, and heparin-induced thrombocytopenia (HIT) [17–19]. There are many devices available for central venous access but they are generally composed of silicone or polyurethane which allows for relative stiffness at room temperature and a softened state at body temperature [6, 11]. CVC can be broadly categorized into non-tunneled, tunneled, and implantable with ports.

Of these, non-tunneled CVC are the most frequently inserted. They are typically placed at bedside for short-term therapy (1–4 weeks) and in patients with significant physiologic distress [12]. The most frequent entry sites are the internal jugular (IJ), subclavian (SC), and femoral veins. Peripherally inserted central catheters (PICC) are similar to non-tunneled CVC. They are non-tunneled catheters placed at bedside, although generally in a more elective fashion. They are inserted through a peripheral arm or leg vein and advanced until the tip lies in the SVC. They are small-bore catheters that usually enter the system in the brachial, antecubital or long saphenous veins. They have the benefit of comfortable positioning for the patient and have lower reported infection rates than IJ, SC, or femoral catheters. PICCs have a smaller total diameter with only 1–2 lumens and slower maximum infusion rates [20]. Midline catheters are placed in the same entry sites as PICCs but terminate in the axillary vein. While still considered a short-term device, PICC and midline catheters are often maintained longer than a non-tunneled CVC due to their lower infection rates. In the literature, there is emphasis that these should still be considered a short-term catheter and to cautiously maintain them for >4 weeks [20].

Tunneled CVC are placed in a procedure or operating room utilizing fluoroscopy for visualized insertion. These catheters are tunneled through subcutaneous tissue and contain a Dacron cuff which causes fixation. The combination of tunneling and cuffed fixation creates physical barriers to infection, reducing infection rates and allowing for long term use of these

catheters. Implanted ports are also long-term devices placed in the operating room. They consist of a catheter and diaphragm which is accessed via cutaneous puncture. Inserted subcutaneously, ports are typically placed in upper anterior chest wall through an IJ or SC approach [12]. Once inserted, they have no externalized components allowing for the lowest infection rates amongst CVC [21]. For the purposes of this paper, we will briefly review relevant anatomy and insertion technique for non-tunneled IJ, SC, and femoral catheters. PICC and midline catheters are not addressed here as most hospitals have a dedicated team of providers who perform these insertions [22].

### 3.1.1. IJ catheterization

After selecting an appropriate access site, the care team should don hat and masks. The provider will then wash his/her hands and dress in sterile gown and gloves. The area is prepped and draped in normal sterile fashion with chlorhexidine solution. During the prep, the provider should examine the contents of the sterile central line insertion kit. Each hospital has its own standard CVC kit and it is important to be familiar with the equipment prior to proceeding. The catheter lumens are then flushed with sterile saline or heparin saline and compatibility of the needle, guidewire, and catheter should be confirmed. The contents of the kit should be organized in a fashion that allows for easy transition from one portion of the procedure to the next.

After sterile draping, the desired cannulation site is infiltrated with local anesthetic. If utilizing ultrasound, this should also be sterilely draped at this time. The provider will position themselves at the head of the bed with ultrasound in the nondominant hand. The patient is then placed in Trendelenburg position and the head rotated 30–45° away from the access side to allow access to the neck. Additional rotation of the head to the contralateral side does not aide the provider as it brings the sternocleidomastoid muscle into an anterior position over the IJ and increases the anterior-posterior overlap of the IJ with the carotid artery [2]. Therefore, only as much rotation as is needed to gain access to the neck is utilized.

Next, IJ and carotid artery are inspected sonographically. It is important to be familiar with regional anatomy and anatomic landmarks. For the IJ approach, the landmarks are the sternal and clavicular muscle heads of the sternocleidomastoid, and the clavicle. These borders create a triangle known as Sédillot's triangle. The carotid and IJ are identified slightly superior to the apex of the triangle. IJ is typically anterior/lateral and is easily compressed with ultrasound probe. For patients with difficult to identify IJ or complex anatomy, color doppler mode or duplex mode can be utilized for identification. Once identified, the large-caliber introducer needle is inserted through the skin at the apex of the triangle with approximately a 20–30° angle. While maintaining aspiration, it is advanced under direct visualization into the IJ. This is typically encountered 0.5 cm below the skin with the needle along an axis towards the ipsilateral nipple [2].

Once venous access is obtained, the US is set aside and the syringe is removed, taking care not to disturb the needle. With the J end of the guide-wire directed towards the midline, it is passed through the needle. It should thread smoothly and advance without resistance. If cardiac arrhythmia or ectopy is noted, immediately withdrawal the wire until it ceases. The

needle is then removed, maintaining continuous control of the wire. A stab incision is made at the insertion site. A dilator is then passed over the wire, dilating the subcutaneous tissue. This is removed and the catheter is threaded over the wire. At this point, it is necessary to back feed the wire proximally until control is regained from the distal aspect of the catheter port. Once obtaining control of the wire, the catheter is inserted over the wire into the vessel. The wire is then removed and blood return is confirmed from each port with a following flush. Ultrasound can be utilized to confirm placement within the IJ and examine the lung fields for violation. The catheter is then secured in place and a sterile occlusive dressing is applied. Prior to removal of any equipment, a final sharps count and examination of the guidewire should be performed to ensure complete retrieval of guidewire with J-shaped tip and no sharps were misplaced. An upright chest X-ray is then obtained to confirm placement and verify no pneumo or hemothorax.

### *3.1.2. SC catheterization*

A similar method is utilized for a SC approach [2, 12, 14–16]. A small shoulder roll may be placed between the shoulder blades to allow the shoulders to drop backwards. This maneuver exposes the necessary anatomy and brings the SC ventrally. If the shoulder roll is too large, the vein can collapse between the first rib and clavicle [1, 2]. Anatomic landmarks for SC access are the sternal notch, and the junction of the middle and medial third of the clavicle, near the deltopectoral groove. The provider will position him/herself on the side that is to be accessed. Following shoulder roll placement, the head is rotated slightly away from the side of insertion and the patient is placed into Trendelenburg position. The provider will place the nondominant index finger in the sternal notch and thumb on the clavicle above the deltopectoral groove. If accessing the right SC a right handed provider will turn their hips slightly towards the feet, if accessing the left their hips will be turned slightly towards the head; this allows comfortable positioning throughout the procedure. Local anesthetic is infiltrated and the access needle is inserted approximately 1–2 cm inferior and lateral to the junction of the middle and medial thirds of the clavicle. With continuous aspiration, the needle is directed medially and slightly cephalad in an axis towards the sternal notch and parallel to the floor. The needle may be “walked down” the clavicle if desired and passed beneath the clavicle with gentle downward pressure applied with the nondominant hand and advanced until venous blood is withdrawn. The syringe is then removed and the guidewire introduced with the J end directed caudally. The needle is removed; skin incised, and subcutaneous tract dilated. The catheter is then inserted over the guidewire again taking care to maintain continuous control of the wire throughout. The wire is removed, blood return verified and ports flushed. The catheter is secured and dressed. Post-procedural equipment verification is completed and an upright chest X-ray obtained.

### *3.1.3. Femoral vein catheterization*

In the case of femoral vein catheterization, ultrasound can aid in anatomic visualization, however, the procedure is typically performed with anatomic landmarks only [2, 14]. The femoral triangle is identified with superior border of the inguinal ligament, medial border of the adductor longus muscle and the lateral border of the sartorius muscle. Within the triangle,

the femoral vein is found medial to the common femoral artery, contained within the femoral sheath. It is important to remember that the inguinal ligament runs between the anterior superior iliac spine and the pubic tubercle and does not necessarily correspond to the “groin crease” [1, 2].

The most advantageous patient positioning is with the hip in a neutral or slightly abducted and externally rotated. Unlike the SC or IJ approach, the patient is placed supine or in slight reverse Trendelenburg position. The insertion site is identified by locating the arterial pulsation 1–2 cm below the inguinal ligament within the femoral triangle. The needle insertion site is approximately 1 cm medial to this maximal pulsation and the axis of insertion is cephalad and medially towards the umbilicus at a 45° angle from the skin. The femoral vein is typically encountered 2–4 cm below the skin and is accessed below the level of the inguinal ligament. The modified Seldinger technique is again utilized; post-procedure imaging is not typically indicated [2].

#### *3.1.4. Other considerations*

Each insertion site has advantages and disadvantages; appropriate selection is affected by patient and clinical factors. The IJ can be accessed under direct visualization with ultrasound guidance and has a lower pneumothorax and hemothorax rate than the SC approach. However, it can be difficult in certain subsets of patients. Those with limited neck mobility, history of neck surgery, cervical collar, substantial subcutaneous tissue or significant cervical kyphosis can make IJ placement challenging [1, 14]. The SC has lower rates of arterial puncture than femoral or IJ locations and the lowest infection rate of the three. The femoral site has the advantage of no hemothoraces or pneumothoraces. It is a relatively safe and accessible location which is typically distant from other monitoring devices and can be placed without interruption of intubation or cardiopulmonary resuscitation. Femoral catheterization allows for free motion of the upper extremities and neck. Despite this, it has the highest rate of infection, limits ambulation and has the highest risk of associated thrombus formation [2, 15].

For proper positioning of SC and IJ CVC, the distance between insertion site and the SVC-atrial junction is vital to appropriate positioning and the avoidance of inducing arrhythmias. In an American based prospective study, fluoroscopy was utilized to determine this distance. It was found that the distance for right IJ insertion averaged 16 cm, right SC averaged 18.4 cm, left IJ averaged 19.1 cm, and left SC 21.2 cm [23]. A South Korean retrospective review of patients with CVC who underwent chest CT revealed slightly shorter distances. They reported a right IJ of 15 cm, right SC 14 cm, left IJ 18 cm, and left SC 17 cm [24]. These distances should be considered when selecting and inserting a CVC to ensure appropriate placement.

## **3.2. Complications**

There are numerous case reports and case series documenting the potentially devastating complications of CVC. These include bleeding events, arterial puncture, infective sequela, cardiac conduction abnormalities, catheter malposition, thrombotic events, and mechanical device failure [1, 6, 25]. Identified risk factors for complications during CVC insertion are number of unsuccessful needle passes, inexperience of provider, body mass index >30

or <20, hypovolemia, large catheter size (specifically related to vascular complications), and previously failed catheterization attempts [1, 5, 25, 26]. When failed catheterization occurs, complications are reported as high as 28% [5]. Ultrasound assistance reduced immediate complications with the overall incidence decreased from 11.8 to 4–7% [5, 26]. In this section, the complications associated with CVC will be discussed briefly as well as advised action if they are encountered. The associated morbidity and mortality of these adverse events can be reduced with prompt recognition and appropriate action.

### 3.2.1. Bleeding events

Bleeding events include hemorrhage, hematoma, and hemothorax from arterial or venous injury. While uncommon, innominate, aortic, SVC, and right ventricular perforation are reported in the literature [25, 27–30]. In those cases, improper use of the dilator and guide-wire kinking were cited as the cause for injury [5, 25, 27, 28]. More common, is injury from puncture or cannulation of the carotid, subclavian, common femoral, or external iliac artery. The incidence of arterial injury from puncture ( $\leq 18$  G) is reported to be 4.2–9.3% and 0.1–1.0% from cannulation ( $>7$  Fr.) [25]. The majority of these injuries are identified at the time of occurrence with recognition of blood coloration, pulsatile flow, ultrasound visualization, or pressure measurements. If a needle puncture has occurred, it can typically be addressed with application of pressure. If the artery is cannulated, symptoms are reported in 30% of patients. In this subset, mortality reaches a rate of 20–40% [5]. Arterial catheter removal with direct pressure is associated with major complications in 47% of patients [31]. When removed by a surgical specialist or intervention radiologist under direct visualization with immediate surgical or endovascular intervention a 0% complication rate is reported [31]. This disparity in outcomes prompted the recommendation that if arterial cannulation is suspected, leave the catheter in place and seek immediate surgical consultation [25, 29, 31].

Arterial cannulation can lead to hemorrhage/hematoma, neurologic deficits, pseudoaneurysm, and AV fistula formation. Neurologic deficits are the result of either cerebral vascular ischemia or hematoma with nerve compression [5, 25, 31, 32]. Cerebral vascular ischemia from arterial CVC occurs when the inadvertent cannulation is not recognized and vasopressors are administered [5, 31]. Pseudoaneurysm and AV fistula formation can be an acute or delayed complication of arterial injury and discovery is reported years after catheterization [5]. The estimated incidence of AV fistula formation is 0.2% for IJ and 0.6% for SC catheterization attempts and can lead to symptomatic intracranial hypertension [5, 26]. Pseudoaneurysms are a recognized complication associated with arterial cannulation or rupture of a mediastinal vein during CVC placement [4, 33, 34]. The incidence of this rare complication is not defined in the literature. When a pseudoaneurysm does occur, treatment via endovascular stenting and open repair are described [4, 33]. Pseudoaneurysms can also occur with embolization following fracture of a catheter and in one case report resulted in a  $5 \times 4$  cm pulmonary artery pseudoaneurysm which required surgical excision via lobectomy [33]. Both of these conditions require intervention. Various methods are described in the literature with coils, thrombin injections, manual compression, stenting, and open surgical approach utilized for repair [5, 26]. Once identified, the management of these complications should be undertaken with the aid of a vascular surgeon.



Localized hematomas with nerve compression of the brachial plexus or the sympathetic trunk (causing Horner syndrome) occurs in 4.7% of all CVC. It is caused by either arterial or venous hemorrhage [5, 26]. Other complications which can arise from hematomas include vocal cord paralysis, phrenic nerve injury, respiratory distress and airway obstruction [5, 26]. Venous hematomas can arise from multiple punctures, venous laceration, and attempted access at an inappropriate site. The utilization of ultrasound or fluoroscopy is advocated for prevention of these complications [1, 6, 25].

Catastrophic hemorrhage is a surgical emergency which requires prompt recognition and action. It occurs in the acute setting from puncture or perforation into regions of large potential space including the thoracic, abdominal, and retroperitoneal cavities [5, 28, 35, 36]. Unlike the mediastinum or neck which has relatively limited space, these cavities can accommodate a large amount of blood without clinical signs until hemodynamic instability is reached. Similar to arterial cannulation, if this occurs or is suspected, the catheter should be left in place and a vascular or cardiothoracic consultation immediately obtained. In this case, the catheter is partially occluding the tract and removal of the catheter blindly can lead to increased hemorrhage and death. If circumstances allow, imaging studies to define the path of the catheter are obtained to aid in planning for its safe removal [5, 25, 36].

### 3.2.2. *Central line-associated bloodstream infections (CLABSI)*

Infective sequela of CVC has become an area of interest in recent years, particularly as the Centers for Medicare and Medicaid Services (CMS) withdrew reimbursement for the treatment of hospital-acquired infections (HAI) including central line-associated bloodstream infections (CLABSI) [37]. The cause of CLABSI in non-tunneled CVC is attributed mainly to the migration of skin organisms at the insertion site through the cutaneous catheter tract and into the bloodstream with colonization of the external surface of the catheter. This modality of contamination is part of the rationale for tunneled CVC. Both non-tunneled and tunneled CVC contamination can occur via the catheter hub with intraluminal colonization of the catheters. Rarely, CVC can become seeded from other hematogenous infections [20, 38]. The infective organism encountered most frequently is *Staphylococcus* (37%), followed by *Enterococcus* [20, 22, 26, 38, 39]. The overall incidence of CLABSI is reported at 5.3 per 1000 catheter days with a CDC estimated cost per infection of \$16,550 and an attributed mortality of 18% [5, 26].

Higher rates of infection are noted based on entry site, emergent status of insertion, increased number of lumens, and type of CVC. With regards to location, PICC have the lowest infection rates of non-tunneled CVC at 1–2 per 1000 catheter days [20, 26, 38]. These are followed by SC (4 per 1000 catheter days) then IJ (8.6 per 1000 catheter days) and finally the femoral vein (15.3 per 1000 catheter days) [5, 20, 22, 26, 38]. In the case of elective non-tunneled CVC, infection incidence is reported at 1.1–3.35 per 1000 catheter days, significantly lower than the reported overall infection rates [5, 20, 38]. The rate for tunnelled CVC is 1.3 per 1000 catheter days and for implanted ports is 0–1 per 1000 catheter days [20, 26].

In recent years, a number of guidelines emerged to aid in the safe insertion and utilization of CVC. These were prompted by the Michigan Keystone project published in 2006 by Pronovost

et al. which demonstrated significant reduction in CLABSI by implementing simple infection-control practices [40]. These measures included maximum sterile barrier precautions, aseptic insertion technique, chlorhexidine skin preparation, transparent dressings, and removal of the catheter as soon as clinically possible [40–42]. It was also determined that the routine exchange of catheters for infection prevention was not necessary and may cause contamination [40, 42]. The increased interest and financial considerations have also led to device innovations for infection reduction. These include alcohol impregnated caps for the covering of hubs, and the development of antimicrobial-impregnated CVC with both internal and external surface impregnation [41, 42].

### 3.2.3. Cardiac arrhythmias and ectopy

Cardiac arrhythmias and ectopy are a recognized phenomenon during the placement of central venous devices and are frequently observed with incidence reaching 75% when the guidewire is advanced 25–32 cm from the IJ entry site [5]. Occurrence rates during insertion of CVC in adult patients are 41% for atrial arrhythmias, and 25% for ventricular ectopy [43]. A slightly lower rate is reported for pediatric patients with a 30% overall incidence of arrhythmias [44]. While complications from these are rarely reported in the literature, malignant/fatal arrhythmias have been described including complete heart block and sudden death. Typically these coincide with preexisting conduction abnormalities. In one such case report, a patient with a left bundle branch block was converted into a complete heart block during guidewire insertion [3]. The suggested mechanism was the superficial location of the right bundle branch making it vulnerable to guidewire trauma [3].

Continuous cardiac monitoring should be utilized throughout CVC placement. If any ectopy or arrhythmia is identified, the guidewire should be withdrawn until it resolves completely. It is imperative that the provider is aware of the guidewire length. Guidewire insertion for the placement of a CVC should never exceed 18 cm and insertion of 14 cm should be adequate for all insertion sites [23, 24]. Late onset of arrhythmia is also reported with an incidence of 0.9% in indwelling tunneled or implanted port CVC [5]. These are typically responsive to removal or replacement of CVC. Another cause of delayed arrhythmia which must be considered is mediastinal or cardiovascular perforation which is the result of catheter malposition [6].

### 3.2.4. Catheter malposition and thrombosis

Catheter malposition occurs in 3.3% of CVC insertions with the highest incidence with right SC entry (9.1%) and least frequently with right IJ (1.4%) [45]. Catheter malposition into the innominate, left internal mammary, azygous, hemiazygos, lateral thoracic, inferior thyroid, intercostal, and thymic veins have occurred [46, 47]. Incorrect position can result in inaccurate hemodynamic monitoring, thrombosis, and arrhythmias [6, 45–47]. While a rare event, perforation is possible. CVC perforation without tamponade occurs at a rate of 0.4–1% with an associated mortality of 12%; the rate of perforation with subsequent tamponade is 0.2% with a mortality of 81–90% [5, 6]. These perforations are attributed to catheter malposition [5, 6]. The exact definition of catheter malposition has evolved over the years but today is accepted as placement within the heart, an angle of incidence (the angle between the CVC tip and the wall of the vein)  $>40^\circ$ , and placement into vessel other than the SVC or IVC [5].

The ideal catheter position for SC and IJ is with the tip in the SVC just above the right atrial junction. The accepted corresponding surface landmarks are the angle of Louis (the junction between the manubrium and sternum) or the right sternal border of the third intercostal space [1, 12, 15]. These can be used to estimate the appropriate length of catheter for insertion but final positioning should always be confirmed with a chest X-ray or fluoroscopy. The most reliable radiography landmark for placement verification is the CVC tip at the right tracheobronchial angle which ensures it lays  $\geq 3$  cm above the pericardial reflection [5]. This is accurate even when patient positioning gives the appearance of the CVC within the cardiac silhouette.

CVC thrombotic events are site, catheter, and patient dependent. In the case of non-tunneled CVC, site appears to be the major determining factor with the highest incidence occurring at the femoral site (21.5–29%) and lowest at the SC site (1.9%) [1, 6]. Catheter-related thrombosis in tunneled and indwelling port CVC has a reported incidence of 33–59% with a SVC obstruction rate of 0.1% [5]. Patients with malignancies are at particularly high risk for thrombus formation with an incidence of 41%; 15–30% of these patients will be symptomatic and 11% will experience an associated pulmonary embolism [5]. Anticoagulation and thromboprophylaxis was studied in this subset of patients without evidence of prevention or benefit [5]. Efforts to reduce the thrombogenicity of the catheter materials have been ongoing for >30 years [48–50]. This led to the refinement of materials with recognition that polyethylene catheters have a higher incidence of thrombus while silicone and polyurethane exhibit improved biocompatibility [49, 51]. Newer efforts have investigated the application of an athrombogenic layer, impregnation of catheter with medications including heparin and nitric oxide, as well as improved composition of catheter materials [51–53]. Due to the interaction between the catheter surface and hematogenous components, thrombus formation can occur at any point along the device. Morbidity from thrombus formation includes embolic events (particularly if the thrombus is associated with the tip of the catheter or >3 cm), infected thrombus, SVC occlusion, and ipsilateral edema [6, 54–57]. If a thrombus is identified and is <3 cm, the CVC can be safely removed without evidence of adverse events. However, if >3 cm there is an increased risk of embolic event upon line removal; anticoagulation or thrombolytic therapy is utilized to reduce the thrombus size but surgical removal is sometimes necessary [26]. In the event of thrombus identification, therapy should include symptomatic management, determination of the continued need to catheterize, monitoring for propagation and anticoagulation or thrombolytic therapy if indicated.

### 3.2.5. Mechanical failure

The mechanical failure of equipment is a potential complication of any device. Immediate mechanical failure is generally related to guidewire issues including retention from looping, entrapment, wedging within the catheter and fracture during insertion [9–11]. Cases of wire and catheter entrapment within inferior vena cava (IVC) filters, knotting with existing CVC, and incorporation with cardiac sutures are reported [26]. These have been managed with fluoroscopic endovascular procedures but at times require surgical intervention [11, 26]. When identified, immediate correction is preferred in stable patients. Known complications include catheter fragmentation with distal embolization and access site injury [26, 58]. The available literature on these cases is limited.

During insertion, guidewire fracture risk can be minimized by careful attention to associated resistance. If resistance is encountered, it may be from extraluminal placement, kinking, entrapment, or

intraluminal stenosis [8, 25, 47, 58, 59]. When this occurs, remove the needle and guide wire en bloc (together), inspect immediately to verify complete removal, obtain new equipment and reinitiate procedure [12, 15, 16]. In this way, wire fracture and embolization is avoided. If you continue to encounter resistance, an alternative insertion site or fluoroscopic guidance should be considered.

Delayed mechanical failure is more commonly encountered with catheter fracture and embolization occurring in 0.5–3% of indwelling CVC with a morbidity rate of 71% and mortality of 30–38% [5]. Arrhythmia, cardiac arrest, pulmonary embolism with hemoptysis, perforation, and thrombosis are reported. Causes of delayed failure include breakage during catheter removal, entrapment, material properties of the catheter, and long-term mechanical fatigue [60, 61]. Material analysis from fractured catheters has shown an increased fracture risk with silicone catheters compared to polyurethane [60, 61]. Additionally, fatigue is particularly prevalent in SC catheters where mechanical shearing between the clavicle and first rib can occur [2, 5, 62]. This is referred to as pinch-off syndrome and is characterized by functional occlusion with postural changes. It will be reported by patients and staff as an inability to aspirate and difficulty flushing the catheter which is improved when the arm is raised. When pinch-off syndrome occurs, the repeated shear stress on the catheter will eventually cause fracture and embolization [2, 5, 62]. It is estimated that pinch-off syndrome is responsible for 41% of catheter embolic events and should be addressed immediately upon identification [2].

### 3.3. Foreign body retrieval

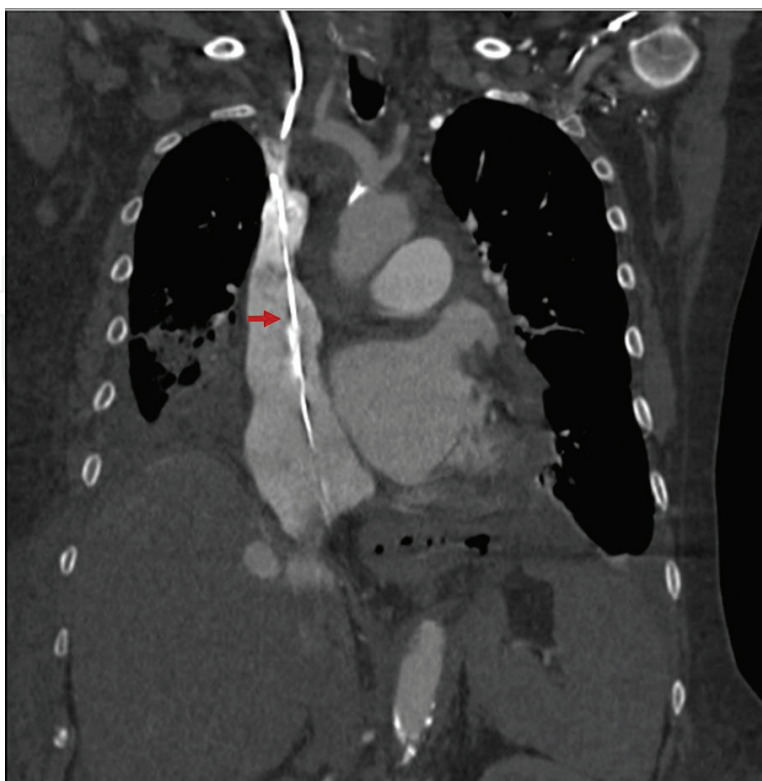
Retained intravascular foreign bodies can occur during a variety of procedures. With the rapidly expanding scope of endovascular interventions, this complication will continue to be of clinical significance. In the case of CVC, guidewire retention during insertion is estimated at a rate of 0.03–0.1%, catheter retention during removal is estimated at 1.5%, and the overall incidence of retained foreign body due to CVC is reported between 0.3 and 1.5% [63–65]. Reports of CVC retention and recovery are presented in case reports, case series and retrospective reviews. These often pool the identification and recovery of all intravascular foreign objects. Embolization is common with identification in the venous system (46%), right heart (35%), and pulmonary arterial system (19%). The reported cases occur both immediately following procedures and with indwelling devices. In the case of procedure related retention, delayed identification of the foreign body is reported in 54% of cases, with the longest time to identification reported at 6 weeks [10]. Since post-procedure imaging often fails to demonstrate a retained object, the true incidence may be higher than reported. When an intravascular foreign object is identified, they are symptomatic in 5.6% of cases and an incidental finding on unrelated imaging in 37% of cases [64]. When identified, endovascular retrieval is the preferred method of recovery due to its minimally invasive approach [5, 9–11, 64, 66].

Endovascular retrieval methods have substantially improved since first reported by Thomas et al in 1964 [67]. Approaches for endovascular retrieval include fluoroscopic, CT, ultrasound, and rarely MRI guided retrieval [9]. Retrieval devices include a variety of loop snares, intravascular retrieval forceps, and retrieval baskets [9, 11, 64, 66]. A recovery rate of 86.6–94% is reported [64, 66]. One case series noted that two thirds of the non-retrieved items were related to CVC [64]. Interestingly, the rate of failed retrieval in case reports is 14.4% while only 3.7% in case series, suggesting publication bias is likely prevalent [66]. Proposed relative contraindications

to recovery include small fragment size, difficult to access location, predicted potential for subsequent complication, patient's clinical status, and associated symptoms [64, 66].

Complication rates associated with retained intravascular foreign bodies vary substantially. In the pediatric literature, Chan et al described no complications in a case series of four retained CVC in pediatric patients with a median follow up of 7.5 months (range 1–53 months). Within the international literature, they noted an overall retention rate of 48.6% with no major complications reported [63]. When retention and embolism occurs in the adult literature, the rate of major complication is 71%. Major complications include persistent infection with sepsis, thrombosis, vascular occlusion, and migration into surrounding structures [63, 64, 66, 68–70]. Bacterial contamination is noted in 28% of these patients. Overall mortality associated with all intravascular foreign bodies ranges between 24 and 60% whereas the mortality rate specific to CVC related events is estimated to be much lower at 1.8% [64, 66, 71].

Attempts to identify complication risk factors and implement appropriate preventive measures prompted a recent study of intravenous retained surgical items (ivRSI) spanning 6 years [10]. In this multicenter study, 13 ivRSI were identified. Risk factors associated with ivRSI were unexpected procedural factors and equipment failure. Unexpected procedural factors were defined as blood loss >500 mL, technically difficult procedure, lack of familiarity with equipment, and difficult/emergent setting. Equipment failure included any documented malfunction/breakage of instrument, hardware, wire, or catheter during the procedure. While this study was specific to endovascular procedures, similar risk factors can be anticipated in bedside procedures (**Figure 2**).



**Figure 2.** CT-chest revealing a retained guidewire within right atrium (arrow). This was removed under local anesthetic with fluoroscopic guidance via an 8 Fr. right IJ sheath with a 2.5 cm loop snare and guiding catheter.

## 4. Conclusion

Central venous catheters represent an important clinical adjunct. Their utilization for the delivery of life saving therapies continues to expand. The complications discussed represent the most frequently reported and potentially devastating complications. With more than 15 million central venous catheter days yearly in the US, it is likely that providers will encounter complications [26]. Identified risk factors include number of unsuccessful needle passes, inexperience of provider, body mass index >30 or <20, hypovolemia, large catheter size and previously failed catheterization attempts [1, 5, 25, 26]. As a provider it is necessary to have a basic knowledge of complication management. Prompt action reduces the morbidity and mortality. In the case of a retained guide wire or embolized fragment, immediate retrieval is indicated.

## Author details

Maureen E. Cheung<sup>1\*</sup>, Logan T. Mellert<sup>1</sup> and Michael S. Firstenberg<sup>2</sup>

\*Address all correspondence to: [cheungme@gmail.com](mailto:cheungme@gmail.com)

1 Department of Surgery, Western Reserve Hospital, Cuyahoga Falls, OH, United States

2 Department of Cardiovascular Surgery, Summa Health System, Akron, OH, United States

## References

- [1] McGee DC, Gould MK. Preventing complications of central venous catheterization. *The New England Journal of Medicine*. 2003;**348**(12):1123-1133. DOI: 10.1056/NEJMra011883
- [2] Bannon M, Heller SF, Rivera M. Anatomic considerations for central venous cannulation. *Risk Management and Healthcare Policy*. April 2011;**4**:27-39. DOI: 10.2147/RMHP.S10383
- [3] Chhabra L, Spodick DH. Complete heart block—An underappreciated serious complication of central venous catheter placement. *Journal of Electrocardiology*. 2012;**45**(6):790-792. DOI: 10.1016/j.jelectrocard.2012.06.005
- [4] Yoon DY, Annambhotla S, Resnick SA, Eskandari MK, Rodriguez HE. Inadvertent arterial placement of central venous catheters: Diagnostic and therapeutic strategies. *Annals of Vascular Surgery*. 2015;**29**(8):1567-1574. DOI: 10.1016/j.avsg.2015.05.030
- [5] Kusminsky RE. Complications of central venous catheterization. *Journal of the American College of Surgeons*. 2007;**204**(4):681-696. DOI: 10.1016/j.jamcollsurg.2007.01.039
- [6] Schroeder B, Barbeito A, Bar-Yosef S, Mark J. Cardiovascular monitoring. In: Miller RD, editor. *Miller's Anesthesia*. 10th ed. Philadelphia, PA: Elsevier/Saunders; 2015
- [7] Omar HR, Sprenker C, Karlinski R, Mangar D, Miller J, Camporesi EM. The incidence of retained guidewires after central venous catheterization in a tertiary care center. *The American Journal of Emergency Medicine*. 2013;**31**(10):1528-1530. DOI: 10.1016/j.ajem.2013.07.009

- [8] Vannucci A, Jeffcoat A, Ifune C, Salinas C, Duncan JR, Wall M. Retained guidewires after intraoperative placement of central venous catheters. *Anesthesia and Analgesia*. 2013;**117**(1):102-108. DOI: 10.1213/ANE.0b013e3182599179
- [9] Floridi C, Nocchi-Cardim L, De Chiara M, Ierardi AM, Carrafiello G. Intravascular foreign bodies: What the radiologist needs to know. *Seminars in Ultrasound, CT, and MRI*. 2015;**36**(1):73-79. DOI: 10.1053/j.sult.2014.11.001
- [10] Moffatt-Bruce SD, Ellison EC, Anderson HL, et al. Intravascular retained surgical items: A multicenter study of risk factors. *The Journal of Surgical Research*. 2012;**178**(1):519-523. DOI: 10.1016/j.jss.2012.02.053
- [11] Nayeemuddin M, Pherwani AD, Asquith JR. Imaging and management of complications of central venous catheters. *Clinical Radiology*. 2013;**68**(5):529-544. DOI: 10.1016/j.crad.2012.10.013
- [12] Brown P and Mitchell D. Central venous and dialysis access. In: Beard JD, Gaines PA, Loftus I, editors. *Vascular & Endovascular Surgery*. Edinburgh: Saunders Elsevier, 2014 5th ed.; 2013
- [13] Seldinger SI. Catheter replacement of the needle in percutaneous arteriography; a new technique. *Acta Radiologica*. 1953;**39**(5):368-376
- [14] Graham AS, Ozment C, Tegtmeyer K, Lai S, Braner DAV. Central venous catheterization. *The New England Journal of Medicine*. 2007;**356**(21):e21. DOI: 10.1056/NEJMc055053
- [15] Rhodes A, Grounds R, Bennett ED. Central venous catheter placement. In: Velasco JM. *Essential Surgical Procedures*; 2016
- [16] Parks RW. Practical procedures and patient investigation. In: Garden OJ. *Principles & Practice of Surgery*. Edinburgh: Churchill Livingstone/Elsevier; 2014
- [17] Zhong L, Wang H-L, Xu B, et al. Normal saline versus heparin for patency of central venous catheters in adult patients—A systematic review and meta-analysis. *Critical Care*. 2017;**21**(5):1-9. DOI: 10.1186/s13054-016-1585-x
- [18] Pronovost PJ. Ensuring that guidelines help reduce patient harm. *Journal of Oncology Practice/American Society of Clinical Oncology*. 2013;**9**(4):e172-e173. DOI: 10.1200/JOP.2012.000780
- [19] Schiffer CA, Mangu PB, Wade JC, et al. Central venous catheter care for the patient with cancer: American Society of Clinical Oncology clinical practice guideline. *Journal of Clinical Oncology*. 2013;**31**(10):1357-1370. DOI: 10.1200/JCO.2012.45.5733
- [20] Hughes JA, Cantwell CP, Waybill PN. Peripherally inserted central catheters and non-tunneled central venous catheters. In: Mauro M, Murphy K, Thomson K, editors. *Image-Guided Interventions: With Expert Consult; Expert Radiology Series*. 2E ed. Edinburgh: Saunders Elsevier, 2014; Chapter 118, 861-868.

- [21] Coady K, Ali M, Sidloff D, Kenningham RR, Ahmed S. A comparison of infections and complications in central venous catheters in adults with solid tumours. *The Journal of Vascular Access*. 2015;**16**(1):38-41. DOI: 10.5301/jva.5000300
- [22] Beekmann SE and Henderson DK. Infections caused by percutaneous intravascular devices. In: Bennett JE, Dolin R, Blaser MJ, Mandell GL, Douglas RG. *Mandell, Douglas, and Bennett's Principles and Practice of Infectious Diseases*; 2015
- [23] Andrews RT, Bova DA, Venbrux AC. How much guidewire is too much? Direct measurement of the distance from subclavian and internal jugular vein access sites to the superior vena cava-atrial junction during central venous catheter placement. *Critical Care Medicine*. 2000;**28**(1):138-142
- [24] Kim WY, Lee CW, Sohn CH, et al. Optimal insertion depth of central venous catheters—Is a formula required? A prospective cohort study. *Injury*. 2012;**43**(1):38-41. DOI: 10.1016/j.injury.2011.02.007
- [25] Bowdle A. Vascular complications of central venous catheter placement: Evidence-based methods for prevention and treatment. *Journal of Cardiothoracic and Vascular Anesthesia*. 2014;**28**(2):358-368. DOI: 10.1053/j.jvca.2013.02.027
- [26] Kornbau C, Lee KC, Hughes GD, Firstenberg MS. Central line complications. *International Journal of Critical Illness and Injury Science*. 2015;**5**(3):170-178. DOI: 10.4103/2229-5151.164940
- [27] Rajinikanth J, Stephen E, Agarwal S. Complication of central venous cannulation. *Canadian Journal of Surgery. Journal Canadien de Chirurgie*. 2008;**51**(5):E113-E114
- [28] Robinson JF, Robinson WA, Cohn A, Garg K, Armstrong JD. Perforation of the great vessels during central venous line placement. *Archives of Internal Medicine*. 1995;**155**(11):1225-1228
- [29] Vats HS. Complications of catheters: Tunneled and nontunneled. *Advances in Chronic Kidney Disease*. 2012;**19**(3):188-194. DOI: 10.1053/j.ackd.2012.04.004
- [30] Siordia JA, Ayers GR, Garlish A, Subramanian S. Innominate vein repair after iatrogenic perforation with central venous catheter via mini-sternotomy—Case report. *International Journal of Surgery Case Reports*. 2015;**11**:98-100. DOI: 10.1016/j.ijscr.2015.03.025
- [31] Guilbert M-C, Elkouri S, Bracco D, et al. Arterial trauma during central venous catheter insertion: Case series, review and proposed algorithm. *Journal of Vascular Surgery*. 2008;**48**(4):918-925; discussion 925. DOI: 10.1016/j.jvs.2008.04.046
- [32] Ahmadi SH, Shirzad M, Zeraatian S, Salehiomran A, Abbasi SH, Ghiasi A. Central venous line and acute neurological deficit: A case series. *The Journal of Tehran Heart Center*. 2014;**9**(4):186-190
- [33] Oz K, Demirhan R, Onan B, Sancakli I. Pulmonary artery pseudoaneurysm after a vascular access port catheter implantation. *The Annals of Thoracic Surgery*. 2009;**87**(1):295-297. DOI: 10.1016/j.athoracsur.2008.05.061



- [34] Hathi R, Patel S, Wilson P. An unusual case of pseudoaneurysm of the left brachiocephalic vein secondary to rupture during central venous catheterization treated with self-expanding, uncovered stent and coils. *Clinical Radiology*. 2011;**66**(1):89-92. DOI: 10.1016/j.crad.2010.07.009
- [35] Wallin D, Privette AR, Campbell AR, Tang JF. A case of unrecognized intrathoracic placement of a subclavian central venous catheter in a patient with large traumatic hemothorax. *Case Reports in Emergency Medicine*. 2015;**2015**:1-2. DOI: 10.1155/2015/382624
- [36] Kuzniec S, Natal SRB, Werebe E de C, Wolosker N. Videothoroscopic-guided management of a central vein perforation during hemodialysis catheter placement. *Journal of Vascular Surgery*. 2010;**52**(5):1354-1356. DOI: 10.1016/j.jvs.2010.05.109
- [37] Peasah S, McKay N, Harman J, Al-Amin M, Cook R. Medicare non-payment of hospital-acquired infections: Infection rates three years post implementation. *Medicare & Medicaid Research Review*. 2013;**3**(3):E1-E16. DOI: 10.5600/mmrr.003.03.a08
- [38] Hughes CJ, Ramsey-Stewart G, Storey DW. Percutaneous infraclavicular insertion of long-term central venous Hickman catheters. *The Australian and New Zealand Journal of Surgery*. 1989;**59**(11):889-893
- [39] Miller LM, Clark E, Dipchand C, et al. Hemodialysis tunneled catheter-related infections. *Canadian Journal of Kidney Health and Disease*. 2016;**3**:1-11. DOI: 10.1177/2054358116669129
- [40] Pronovost P, Needham D, Berenholtz S, et al. An intervention to decrease catheter-related bloodstream infections in the ICU. *The New England Journal of Medicine*. 2006;**355**(26):2725-2732. DOI: 10.1056/NEJMoa061115
- [41] Lorente L, Lecuona M, Jiménez A, et al. Chlorhexidine-silver sulfadiazine-impregnated venous catheters are efficient even at subclavian sites without tracheostomy. *American Journal of Infection Control*. 2016;**44**(12):1526-1529. DOI: 10.1016/j.ajic.2016.04.236
- [42] Patel PA, Boehm S, Zhou Y, et al. Prospective observational study on central line-associated bloodstream infections and central venous catheter occlusions using a negative displacement connector with an alcohol disinfecting cap. *American Journal of Infection Control*. 2017;**45**(2):115-120. DOI: 10.1016/j.ajic.2016.06.013
- [43] Stuart R, Shikora S, Akerman P, et al. Incidence of arrhythmia with central venous catheter insertion and exchange. *Journal of Parenteral and Enteral Nutrition*. 1990;**14**(2):152-155. DOI: 10.1177/0148607190014002152
- [44] da Silva PSL, Waisberg J. Induction of life-threatening supraventricular tachycardia during central venous catheter placement: An unusual complication. *Journal of Pediatric Surgery*. 2010;**45**(8):e13-e16. DOI: 10.1016/j.jpedsurg.2010.05.013
- [45] Pikwer A, Bååth L, Davidson B, Perstoft I, Akesson J. The incidence and risk of central venous catheter malpositioning: A prospective cohort study in 1619 patients. *Anaesthesia and Intensive Care*. 2008;**36**(1):30-37

- [46] Kumar USD, Shivananda S, Wali M. Malpositioned central venous catheters: A diagnostic dilemma. *The Journal of the Association for Vascular Access*. 2016;**21**(1):35-38. DOI: 10.1016/j.java.2015.11.002
- [47] Vahid B, Kotiah S, Marik P. Malposition of central venous catheter in left superior intercostal vein in a patient with superior vena cava syndrome. *Radiography*. 2007;**13**(4):307-309. DOI: 10.1016/j.radi.2006.03.006
- [48] Linder LE, Curelaru I, Gustavsson B, Hansson HA, Stenqvist O, Wojciechowski J. Material thrombogenicity in central venous catheterization: A comparison between soft, antebrachial catheters of silicone elastomer and polyurethane. *Journal of Parenteral and Enteral Nutrition*. 1984;**8**(4):399-406
- [49] Pottecher T, Forrler M, Picardat P, Krause D, Bellocq JP, Otteni JC. Thrombogenicity of central venous catheters: Prospective study of polyethylene, silicone and polyurethane catheters with phlebography or post-mortem examination. *European Journal of Anaesthesiology*. 1984;**1**(4):361-365
- [50] Borow M, Crowley JG. Evaluation of central venous catheter thrombogenicity. *Acta Anaesthesiologica Scandinavica. Supplementum*. 1985;**81**:59-64
- [51] Hitz F, Klingbiel D, Omlin A, Riniker S, Zerz A, Cerny T. Athrombogenic coating of long-term venous catheter for cancer patients: A prospective, randomised, double-blind trial. *Annals of Hematology*. 2012;**91**(4):613-620. DOI: 10.1007/s00277-011-1343-8
- [52] Wildgruber M, Lueg C, Borgmeyer S, et al. Polyurethane versus silicone catheters for central venous port devices implanted at the forearm. *European Journal of Cancer (Oxford, England: 1990)*. 2016;**59**:113-124. DOI: 10.1016/j.ejca.2016.02.011
- [53] Brisbois EJ, Major TC, Goudie MJ, Meyerhoff ME, Bartlett RH, Handa H. Attenuation of thrombosis and bacterial infection using dual function nitric oxide releasing central venous catheters in a 9day rabbit model. *Acta Biomaterialia*. 2016;**44**:304-312. DOI: 10.1016/j.actbio.2016.08.009
- [54] Petridis C, Nitschke M, Lehne W, et al. Tip design of hemodialysis catheters influences thrombotic events and replacement rate. *European Journal of Vascular and Endovascular Surgery*. 2017;**53**(2):262-267. DOI: 10.1016/j.ejvs.2016.10.015
- [55] Roguin A. Right atrial mass related to indwelling central venous catheters in patients undergoing dialysis. *European Journal of Echocardiography*. 2000;**1**(3):222-223. DOI: 10.1053/euje.2000.0017
- [56] Dreyer G, Bingham C. Right atrial thrombus as a complication of a temporary haemodialysis catheter—A potentially avoidable complication. *Nephrology, Dialysis, Transplantation*. 2005;**20**(2):474-475. DOI: 10.1093/ndt/gfh626
- [57] Barbeito A, Bar-Yosef S, Lowe JE, Atkins BZ, Mark JB. Unusual cause of superior vena cava syndrome diagnosed with transesophageal echocardiography. *Canadian Journal of Anaesthesia (Journal canadien d'anesthésie)*. 2008;**55**(11):774-778. DOI: 10.1007/BF03016351

- [58] Hamad M, Rajan R, Kosai N, Sutton P, Das S, Harunarashid H. Retained fractured fragment of a central venous catheter: A minimally invasive approach to safe retrieval. *Ethiopian Journal of Health Sciences*. 2016;**26**(1):85-88
- [59] Park K-H, Son J-W, Park W-J, et al. Characterization of the left atrial vortex flow by two-dimensional transesophageal contrast echocardiography using particle image velocimetry. *Ultrasound in Medicine & Biology*. 2013;**39**(1):62-71. DOI: 10.1016/j.ultrasmedbio.2012.08.013
- [60] Kojima S, Hiraki T, Gobara H, et al. Fracture of totally implanted central venous access devices: A propensity-score-matched comparison of risks for Groshong silicone versus polyurethane catheters. *The Journal of Vascular Access*. 2016;**17**(6):535-541. DOI: 10.5301/jva.5000606
- [61] Braun U, Lorenz E, Weimann C, et al. Mechanic and surface properties of central-venous port catheters after removal: A comparison of polyurethane and silicon rubber materials. *Journal of the Mechanical Behavior of Biomedical Materials*. 2016;**64**:281-291. DOI: 10.1016/j.jmbbm.2016.08.002
- [62] Viviani E, Giribono AM, Ferrara D, et al. Chest pain due to Pinch-off syndrome: Radiological findings and endovascular rescue. *La Clinica Terapeutica*. 2016;**167**(1):13-15
- [63] Chan BKY, Rupasinghe SN, Hennessey I, Peart I, Baillie CT. Retained central venous lines (CVLs) after attempted removal: An 11-year series and literature review. *Journal of Pediatric Surgery*. 2013;**48**(9):1887-1891. DOI: 10.1016/j.jpedsurg.2013.01.050
- [64] Wolf F, Schernthaner RE, Dirisamer A, et al. Endovascular management of lost or misplaced intravascular objects: Experiences of 12 years. *Cardiovascular and Interventional Radiology*. 2008;**31**(3):563-568. DOI: 10.1007/s00270-007-9201-8
- [65] Song Y, Messerlian AK, Matevosian R. A potentially hazardous complication during central venous catheterization: Lost guidewire retained in the patient. *Journal of Clinical Anesthesia*. 2012;**24**(3):221-226. DOI: 10.1016/j.jclinane.2011.07.003
- [66] Schechter MA, O'Brien PJ, Cox MW. Retrieval of iatrogenic intravascular foreign bodies. *Journal of Vascular Surgery*. 2013;**57**(1):276-281. DOI: 10.1016/j.jvs.2012.09.002
- [67] Thomas J, Sinclair-Smith B, Bloomfield D, Davachi A. Non-surgical retrieval of a broken segment of steel spring guide from the right atrium and inferior vena cava. *Circulation*. 1964;**30**:106-108
- [68] Hassan A, Khalifa M, Al-Akraa M, Lord R, Davenport A. Six cases of retained central venous haemodialysis access catheters. *Nephrology, Dialysis, Transplantation: Official Publication of the European Dialysis and Transplant Association—European Renal Association*. 2006;**21**(7):2005-2008. DOI: 10.1093/ndt/gfl123
- [69] Jafferbhoy SF, Asquith JR, Jeeji R, Levine A, Menon M, Pherwani AD. A stuck haemodialysis central venous catheter: Not quite open and shut!. *Journal of Surgical Case Reports*. 2015;**2015**(4):rjv032-rjv032. DOI: 10.1093/jscr/rjv032

- [70] Reddy A, Stangl A, Radbill B. Retained catheter fragment from a fractured tunneled catheter—A rare and potentially lethal complication: Retained fractured catheter fragment. *Seminars in Dialysis*. 2010;**23**(5):536-539. DOI: 10.1111/j.1525-139X.2010.00756.x
- [71] Tazzioli G, Gargaglia E, Vecchioni I, Papi S, Di Blasio P, Rossi R. Retained embolized fragment of totally implantable central venous catheter in right ventricle: It is really necessary to remove?. *The Journal of Vascular Access*. 2015;**16**(5):431-433. DOI: 10.5301/jva.5000430

IntechOpen

