

We are IntechOpen, the world's leading publisher of Open Access books Built by scientists, for scientists

4,800

Open access books available

122,000

International authors and editors

135M

Downloads

Our authors are among the

154

Countries delivered to

TOP 1%

most cited scientists

12.2%

Contributors from top 500 universities



WEB OF SCIENCE™

Selection of our books indexed in the Book Citation Index
in Web of Science™ Core Collection (BKCI)

Interested in publishing with us?
Contact book.department@intechopen.com

Numbers displayed above are based on latest data collected.
For more information visit www.intechopen.com



Emergent or Early Flap Resurfacing Is Required for Bone-Exposing Wounds of Gustilo-Anderson IIIB and IIC Fractures

Masaki Fujioka

Additional information is available at the end of the chapter

<http://dx.doi.org/10.5772/intechopen.70147>

Abstract

Background: The wound treatment has progressed owing to the development of new medicine, instruments. Following these trends, can the bone-exposing wounds of severe open fractures be resurfaced without using flaps but only skin grafting? We evaluated a new medicine and instrument, for the resurfacing of bone-exposing complex wounds of Gustilo-Anderson IIIB and C fractures. **Patients and methods:** Patients with Gustilo-Anderson IIIB (five cases) and C (two cases) open fractures who underwent open reduction and external fixation were evaluated. Bone-exposing wounds were resurfaced with artificial dermis, and basic fibroblast growth factor was sprayed. We investigated the course and outcome. **Result:** In all of seven cases, abundant granulation tissue did not develop on the bone-exposing wound surface during 2–5 weeks, and 4 patients developed osteomyelitis. Subsequently, all cases required flap surgery to resurface the wound. All patients could walk; however, required a longer period for the complete union of bones. **Conclusion:** This study showed that it was impossible to prepare a favorable wound bed on the bone when the fracture was severe. Thus, early flap surgery was a recommendable resurfacing option. Furthermore, emergent bone resurfacing with flap, while performing rigid bone fixation with an internal fixation plate, was an ideal procedure.

Keywords: emergent reconstruction, free flow-through flap, anterolateral thigh flap, Gustilo-Anderson IIIB and C fractures, vascular repair

1. Introduction

Gustilo-Anderson type III fracture is defined as an open fracture with extensive soft-tissue laceration, damage, or loss or an open segmental fracture, and type IIIB as a severe that open

fracture with extensive soft-tissue loss. The severest open fracture is called type IIIC; it is associated with an arterial injury requiring immediate repair [1]. The resurfacing of bone-exposing complex wounds of this type of fracture remains challenging. Previous conventional wound management involved leaving wounds open after debridement; this might have been because antibiotics and surgical debridement did not prevail, and soft-tissue reconstructive techniques had not been developed [2–5].

Recent technological advances of wound management have made the healing of complex chronic wounds earlier and easier [6, 7]. The development of new medicines, instruments, and techniques, including artificial dermis, angiogenic cytokines, and negative pressure wound treatment device, has allowed bone-exposing wounds to heal more quickly [8, 9]. Among these, artificial dermis is beneficial for the resurfacing of wounds with exposed tendons or bone. Its unique granular regeneration promoting characteristic even on bare bone may allow resurfacing with a free skin graft. Thus, it may replace flap surgery for the treatment of several bone-exposing wounds including deep burns, postabrasion of neoplasms, and skin defects due to trauma (**Figures 1–3**) [10, 11].

It is generally felt difficult to prepare a favorable wound bed on the bone when the open fracture is too severe and complex, such as those classified as Gustilo-Anderson IIIB and C. This work is divided into three sections. In the first section, we present and discuss the outcome of resurfacing Gustilo-Anderson IIIB and C bone-exposing wounds, subjected to late treatment using artificial dermis. In the second section, we describe and discuss cases of successful

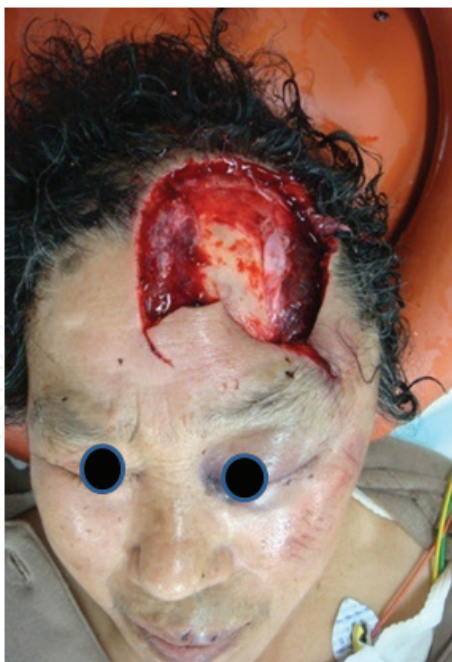

Figure 1. Case 1. This picture shows a forehead injury with a skin defect exposing frontal bone. Artificial dermis was applied to the wound.

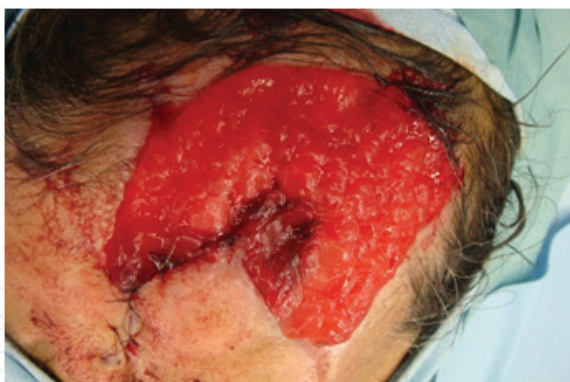

Figure 2. The wound was covered with granulation tissue 4 weeks after injury; thus, a full-thickness skin graft could be performed.

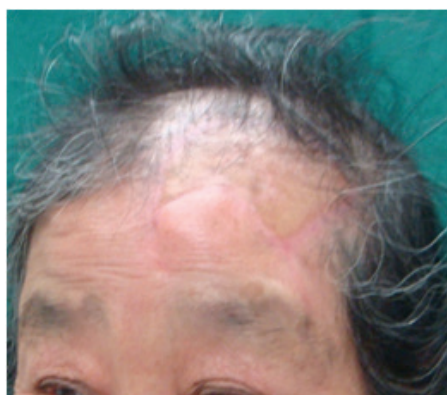

Figure 3. Photograph at 3 months postinjury showing the resurfacing of all of the bone-exposing wound.

salvage and reconstruction of Gustilo-Anderson IIIC extremity fractures, highlighting the advantage of emergent free flow-through flap resurfacing. In the third section, we introduce and discuss the “fix and flap” concept, a new radical concept for the treatment of severe open fractures.

2. Disadvantages of conventional late resurfacing for Gustilo-Anderson IIIB and C bone-exposing wounds

Conventional options to treat Gustilo-Anderson IIIB and C bone-exposing injuries are primary surgery including debridement and cleansing, vascular repair, bone reduction/external fixation, and secondary wound resurfacing surgery by skin graft and pedicle or free flap transfer (**Figures 4–8**) [12–14]. Ideally, all procedure should be performed immediately; however, the resurfacing of wound tends to be performed late, because of concerns over the development of wound infection or shortage of surgical staff for emergent surgery. In these cases,

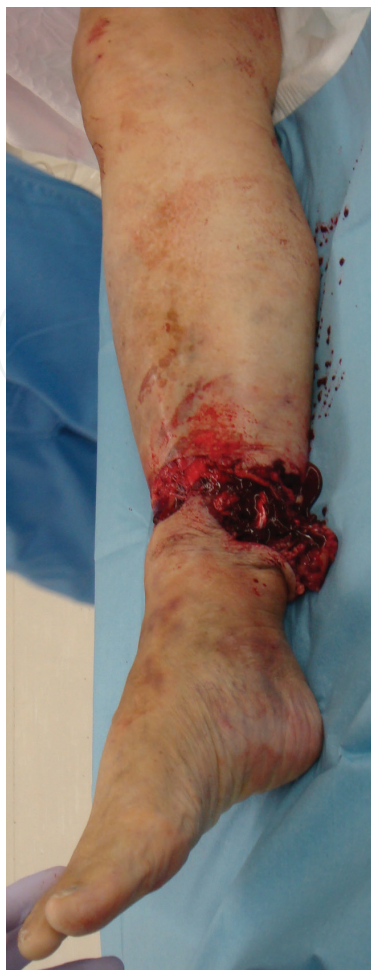

Figure 4. Case 2. Conventional treatment of Gustilo-Anderson III C fracture. The patient sustained an open fracture to the right leg.

pending secondary surgery, the wound is dressed temporarily with wet gauze, several wound dressing materials, or artificial dermis. Our practice has been to apply artificial dermis on the bone, expecting granulation. In this section, we present the outcome of resurfacing Gustilo-Anderson IIIB and C wounds, which had been treated with artificial dermis.

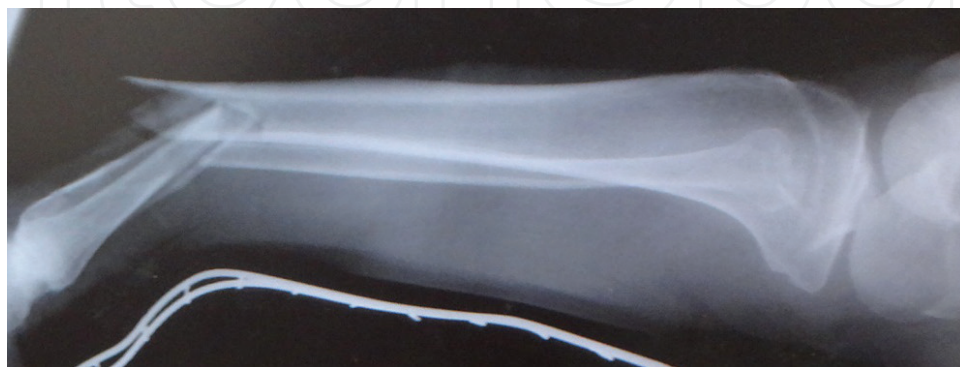


Figure 5. The X-ray image shows both tibia and fibula fractures.

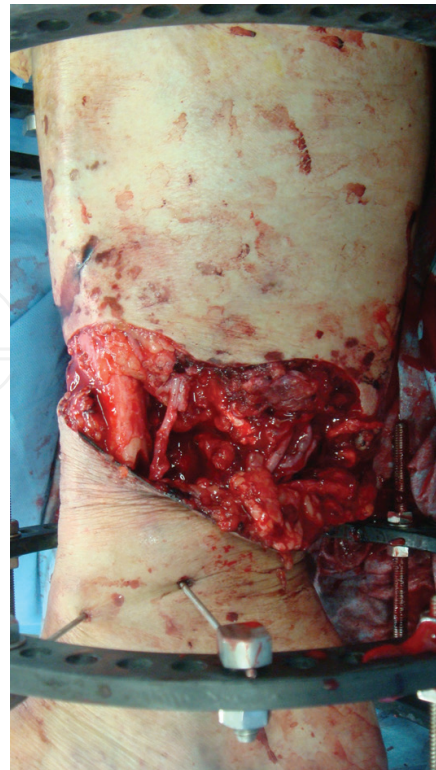


Figure 6. After reduction and external fixation, the posterior tibial artery was repaired with an interposition of vein graft. The wound was covered temporarily with artificial dermis.

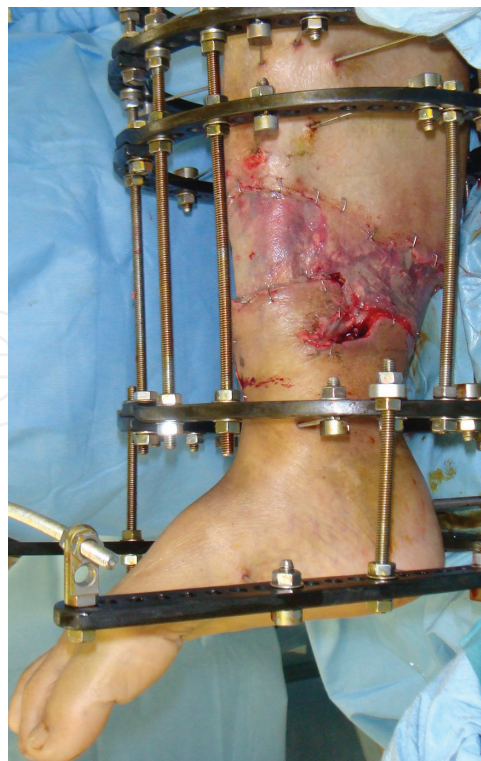

Figure 7. Three weeks later, the wound was resurfaced by local skin flap and free skin graft.




Figure 8. The X-ray image months later shows favorable bone union.

3. Patients and method

A total of seven patients with Gustilo-Anderson III B (five cases) and C (two cases) open fracture were treated in the National Organization Nagasaki Medical Center in 2011 and 2012 (**Table 1**). All patients underwent open reduction and Ilizarov external fixation. Artificial dermis (TerudermisR, Orimpas-Terumo Co., Ltd., Tokyo, Japan) and ointment-impregnated gauze were applied to the wounds.

	Age sex	Site of open fracture	Gustilo-Anderson classification	Complication	Surgical resurfacing (postinjury period, week)	Additional surgery	Prognosis/external fixation period
1	74 M	Rt. tibia and fibula	IIIC (PTA reconstruction)	–	Local flap (5 W)	–	Walk/4 months
2	58 M	Rt. tibia and fibula	IIIB	–	Local flap (3 W)	–	Walk/6 months
3	32 M	Rt. tibia and fibula	IIIB	Osteomyelitis	Sequestration (2 W), local flap (5 W)	Sequestrectomy	Walk/13 months
4	68 M	Rt. tibia and fibula	IIIB	Osteomyelitis	Local flap (W)	Bone grafting	Walk/11 months
5	44 M	Rt. tibia and fibula	IIIB	Osteomyelitis	Sequestration, local flap (2 W)	Sequestrectomy	Walk/18 months
6	56 M	Rt. tibia	IIIC (PTA reconstruction)	Osteomyelitis	Local flap (4 W)	–	Walk/11 months
7	74 M	Rt. tibia and fibula	IIIB	–	Local flap (W)	–	Walk/10 months

PTA: Posterior tibial artery, FSG: Free skin grafting

Table 1. Cases of patients with Gustilo-Anderson IIIB and C open fracture who were treated with artificial dermis.

4. Results

In all of the seven cases, abundant granulation tissue did not develop on the bone-exposing wound surface during 2–5 weeks after applying the artificial dermis to the bone. Four patients developed osteomyelitis and required continuous irrigation. Among them, two underwent sequestrectomy (**Figures 9–12**). Subsequently, all cases required local flap transfer to resurface the bone-exposing wound (**Figures 13–16**). One patient developed malunion and required bone grafting. Patients suffering from complications required a longer period for the complete union of bones, a fact which prolonged the fixation period (11–18 months). Finally, all patients could walk after removal of the external fixation (**Figures 17 and 18**).

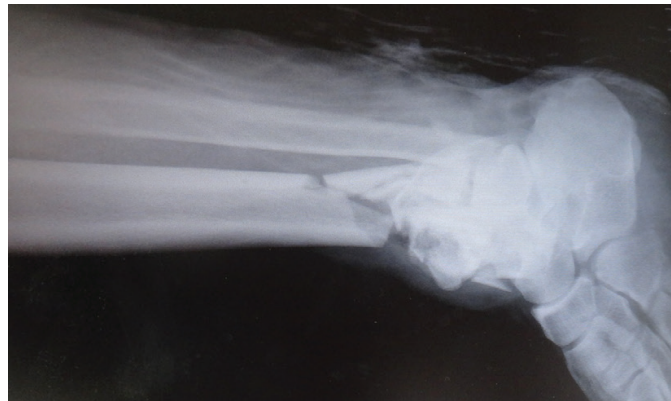


Figure 9. Case 3. The unpleasant course of Gustilo-Anderson III B fracture treated with conventional late wound resurfacing. The patient sustained an open fracture to the right leg.

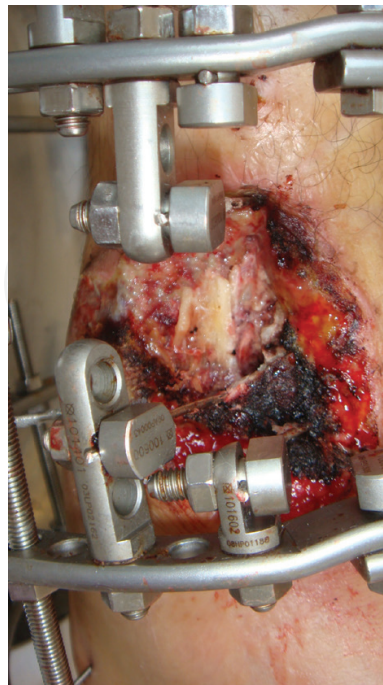

Figure 10. After reduction and external fixation, the wound was covered temporarily with artificial dermis. The picture shows osteomyelitis 2 weeks later.

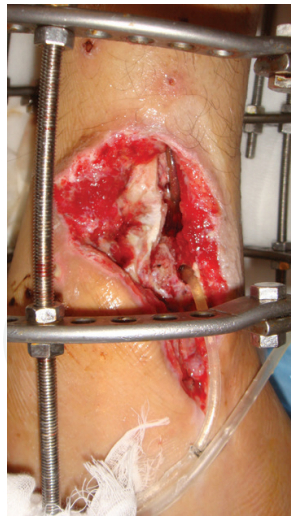


Figure 11. After sequestrectomy and continuous wound irrigation, the wound was cleansed. Next, the wound was resurfaced by local skin flap and free skin graft 3 weeks later.

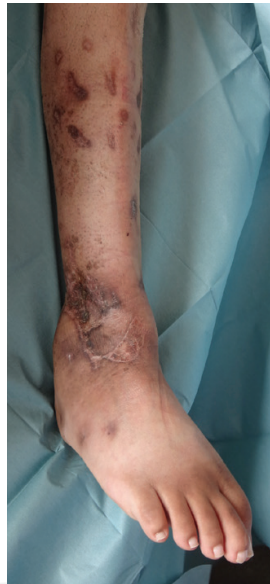

Figure 12. The picture shows the appearance of the injured leg. The patient took 6 months to walk.

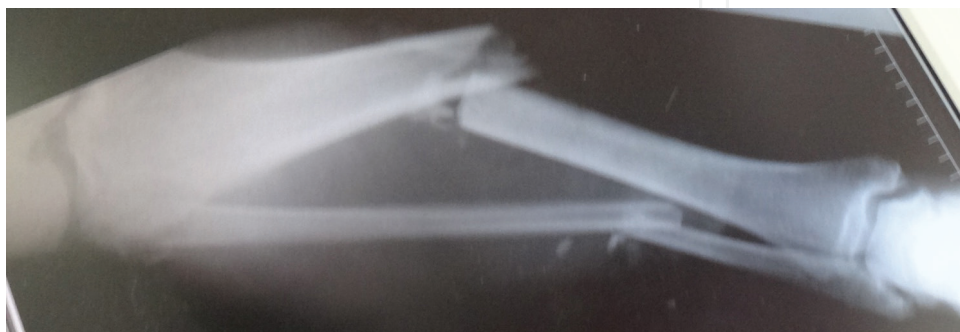

Figure 13. Case 4. The patient sustained a Gustilo-Anderson IIIB open fracture to both tibia and fibula.

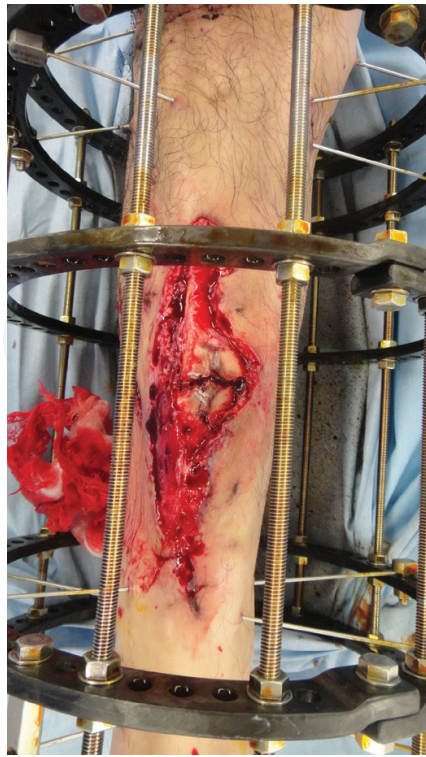


Figure 14. The wound was covered temporarily with artificial dermis. The picture shows absence of granulation growth on the bone 3 weeks later.

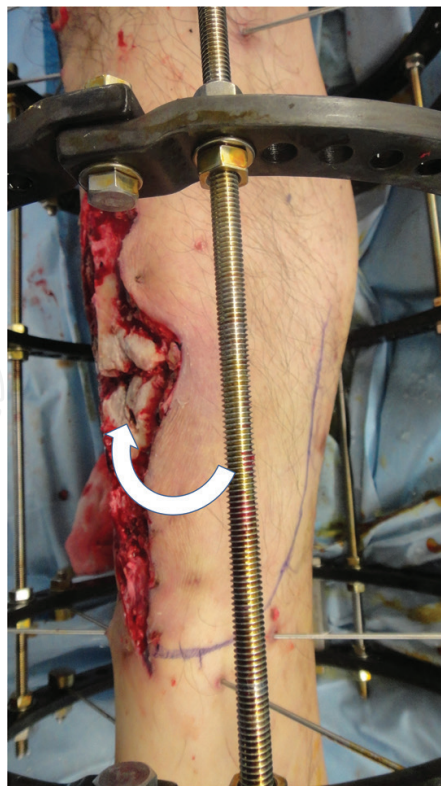

Figure 15. A local skin flap and a free skin were planned to resurface the wound. The picture shows the design of the flap.

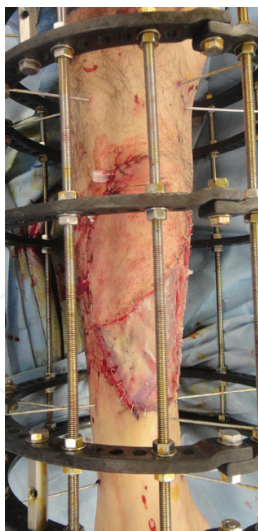

Figure 16. The picture shows a postoperative view. The bone-exposed wound was covered with flap, the remaining wound received a free skin graft.

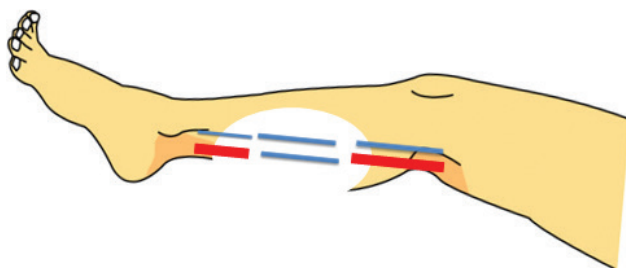


Figure 17. Schematic representation of the conventional procedure of vascular repair for Gustilo-Anderson IIIC fracture. This method requires additional flap surgery for wound coverage.

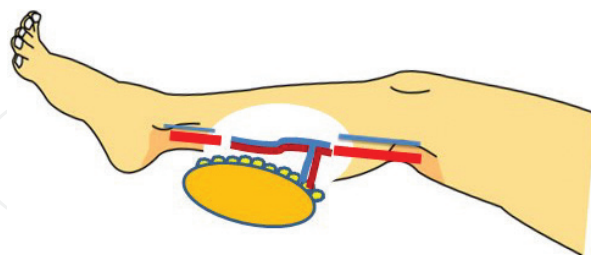


Figure 18. Schematic representation of the flow-through free flap procedure of vascular repair for Gustilo-Anderson IIIC fracture. This method makes both vascular repair and immediate wound resurfacing possible.

5. Discussion and conclusion

It is widely known that artificial dermis is used for the reconstruction of wounds with exposed tendons or bone, because it promotes early infiltration of mononuclear cells and

fibroblasts and better growth of connective tissue strands and epithelium [10]. However, bone-exposing wounds in our patients with Gustilo-Anderson IIIB and C fractures had not improved with this treatment, and required conventional flap surgery. The main problem might have been the total absence or extreme deficiency of blood flow to bone fragment or fractured stumps, which had led to sequestration and osteomyelitis, prolonging the period of external fixation. Although the wounds might not have developed infection, a favorable wound bed could not have developed with poor vascularity. We conclude that, at the present stage of its development, artificial dermis is not a recommendable resurfacing option for patients with Gustilo-Anderson IIIB and C fractures, because it does not help improve poor bone circulation, a fact which may result in osteomyelitis. Thus, immediate primary skin closure is desired for patients with Gustilo-Anderson IIIB and C fractures [15].

6. Application of free flow-through anterolateral thigh (ALT) flap for Gustilo-Anderson IIIB and C bone-exposing wounds

6.1. Advantage of flow-through type flaps

The vascular injury associated with extremity trauma primarily requires open vascular repair immediate after injury, such as direct anastomosis, an interposition vein graft, or a bypass graft, to restore blood flow to distal area of injured extremities [13] (**Figure 17**). Since the development of concept of the flow-through flap, in which both the proximal and distal ends of the vascular pedicle of a free flap are anastomosed to restore blood flow to distal tissues, many investigators have described the application of flow-through flaps for reconstruction of the extremities [16–19] (**Figure 18**). Instead of conventional interposing vein graft to replace the injured artery, microsurgical free flow-through type flaps use has the added benefit of restoring blood flow to the distal extremities normally, whilst simultaneously immediately reconstructing soft-tissue defects in soft-tissue-deficient wounds. Furthermore, exploring the recipient vasculature for purpose of anastomosing the flap vessels is usually straightforward when reconstructive surgery is performed immediately after injury [20].

These special flaps require a T-shaped branching system of the pedicle vessel with proper diameters. Surgeon can choose several kinds of flow-through type flaps, including latissimus dorsi musculocutaneous, rectus abdominis musculocutaneous, fibula osteomyocutaneous, and anterolateral thigh (ALT) flaps [20–22]. Among all of the above, the ALT flap can provide a large skin paddle and long and suitable pedicle; thus, it is ideal for extremity reconstruction with minimal donor site morbidity [23]. In this article, we present cases of successful salvage and reconstruction of the extremities using free flow-through ALT flaps.

6.2. Case presentations of Gustilo-Anderson IIIB and C limb fractures reconstructed with free ALT flow-through type flaps

Case 7. Having been caught in a harvester, a 62-year-old man sustained a Gustilo-Anderson type IIIC ulnar fracture to the left elbow with wide abrasion of the skin and flexor muscles (**Figure 19**)

defect in the ulna, with subsequent opening of the elbow joint cavity (**Figure 20**). The circulation of the left forearm had ceased due to interruption of the brachial artery (**Figure 21**). Immediate reconstruction using a free ALT flow-through type flap was performed. After debridement and external fixation of the elbow joint, the T portion of the descending branch of the lateral circumflex femoral

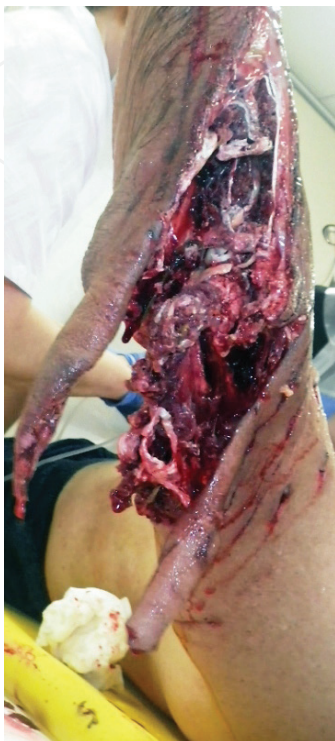

Figure 19. Case 5. The picture shows Gustilo-Anderson III C fracture to the left elbow with abrasion of the skin and flexor muscles.

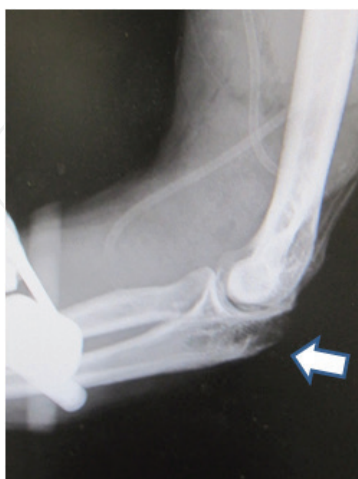

Figure 20. An X-ray photograph shows bone defect of ulna, which caused opening of elbow joint cavity.

artery was interposed within the defect of the brachial artery. Two veins were connected to the cutaneous veins by end-to-end anastomosis (Figures 22 and 23). The defect of elbow joint capsule was reconstructed with the fascia of the ALT flap, and the bone- and joint-exposing wound was

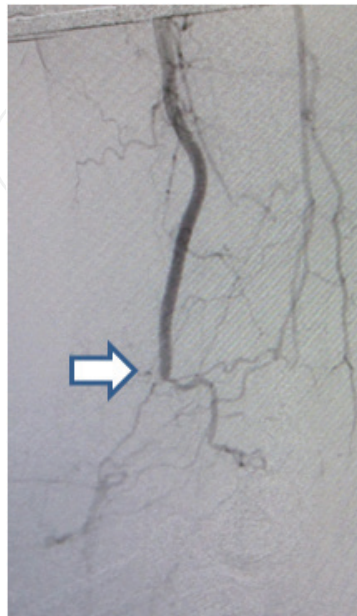


Figure 21. Contrast-enhanced computed tomography showed that circulation of the left forearm had ceased due to interruption of brachial artery.

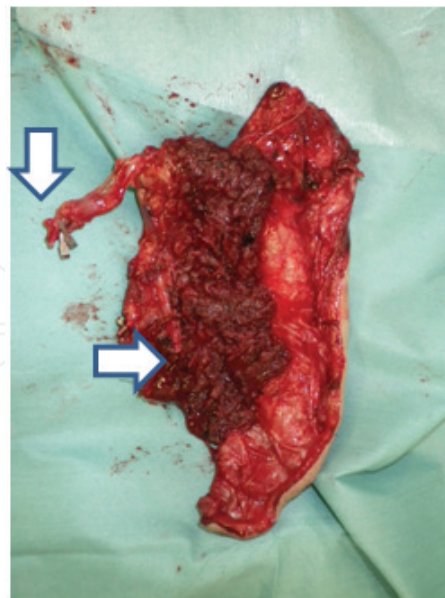


Figure 22. The picture shows a harvested flow-through ALT flap. Arrows indicate the distal and proximal ends of the descending branch.

resurfaced with the vastus lateralis overlying skin island. The blood flow to the hand and forearm through the interposed descending branch was restored, while that to the flap was also favorable (**Figure 24**). The patient could flex his elbow 3 months after surgery (**Figures 25**).

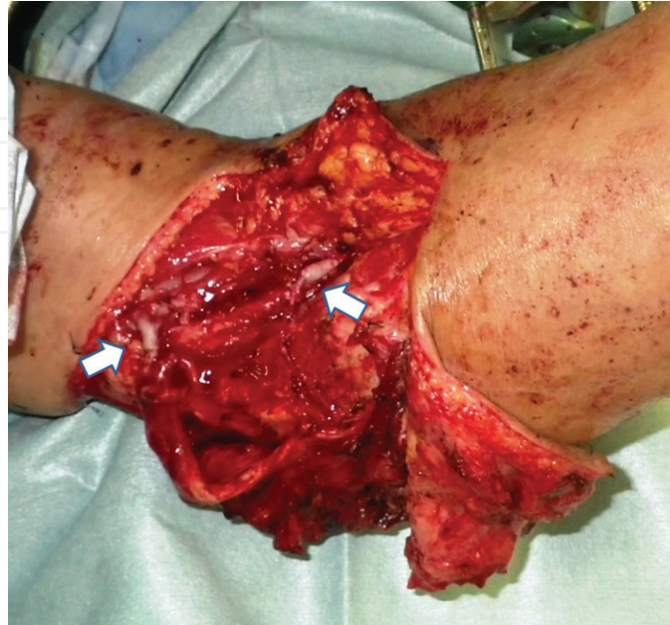

Figure 23. The intraoperative photograph shows the descending branch interposed within the interrupted brachial artery. Arrows indicate the areas of anastomosis.

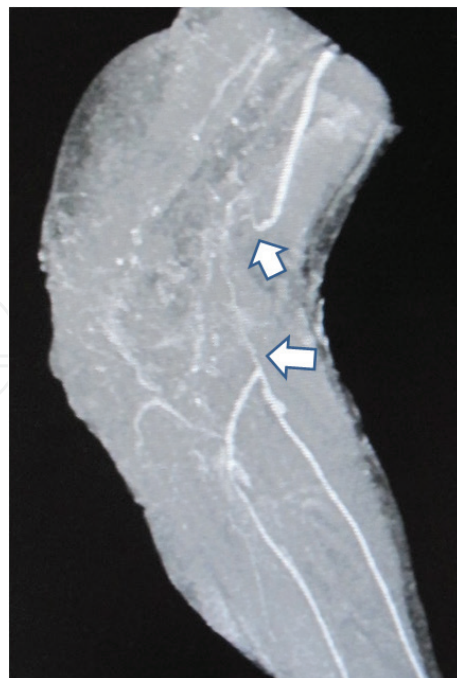

Figure 24. Contrast-enhanced computed tomography 2 weeks after surgery showing reestablishment of circulation to the hand and forearm through the interposed descending branch, and blood flow to the flap. The arrows indicated the points of anastomosis.

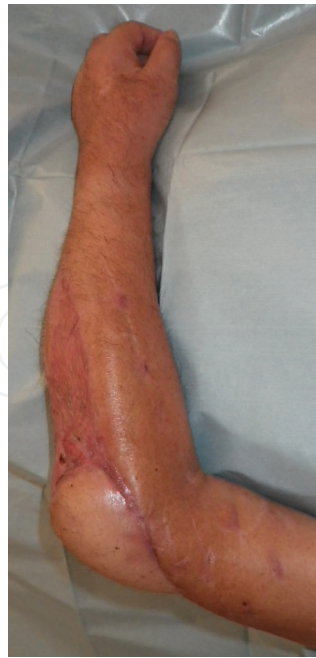

Figure 25. View of the reconstructed forearm 3 month after surgery showing favorable resurfacing and successful functional outcome.

Case 8: Due to a traffic accident, a 32-year-old man sustained a Gustilo-Anderson IIIC type bone-exposing fracture to the left fibula and tibia with severe abrasion of the skin and anterior tibial muscles (**Figure 26**). Circulation of the left foot had ceased because three main arteries

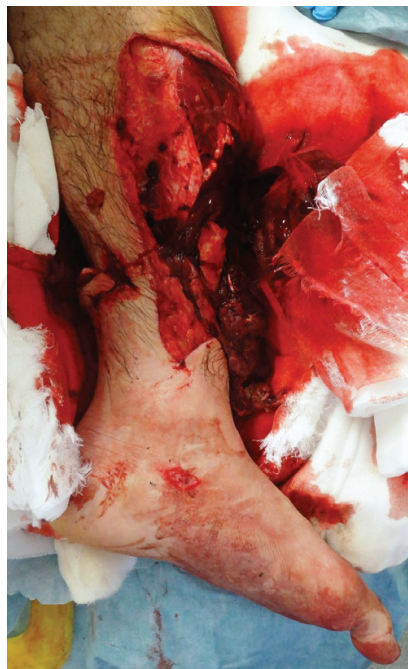

Figure 26. Case 6. This photograph shows a Gustilo-Anderson IIIC fracture to the left fibula and tibia with severe abrasion of the skin and anterior tibial muscles.

in the leg (peroneal, posterior tibial, and anterior tibial arteries) had ruptured, and flow had been interrupted. After the crushed bones had been reconstructed and fixed externally, the bone-exposing wound was repaired with a free flow-through ALT flap (**Figures 27 and 28**). The T portion of the descending branch of the ALT flap was interposed to the defect of the anterior tibia artery, and two veins were connected to the cutaneous veins by end-to-end anastomosis. The interrupted anterior tibia artery resumed normal blood flow (**Figure 29**). The viability of the flap was favorable without infection and necrosis. The patient could walk without canes 1 year after surgery (**Figures 30 and 31**).

6.3. Discussion and conclusion

A flow-through flap is utilized when the flap inflow arterial system not only provides perfusion to the transported flap but also provides a vascular link between the obliterated arteries [24, 25]. Especially, this flap is useful for patients suffering from Gustilo-Anderson IIIC complex injuries, which present with both large soft-tissue defects and main artery defects with compromised circulation of a distal extremities. The flow-through flap transfer can be superior to conventional flaps for achieving the resurfacing of a large tissue defect and vascular repair immediately, a process which reduces infection, induces bony healing, and optimizes limb salvage [23].

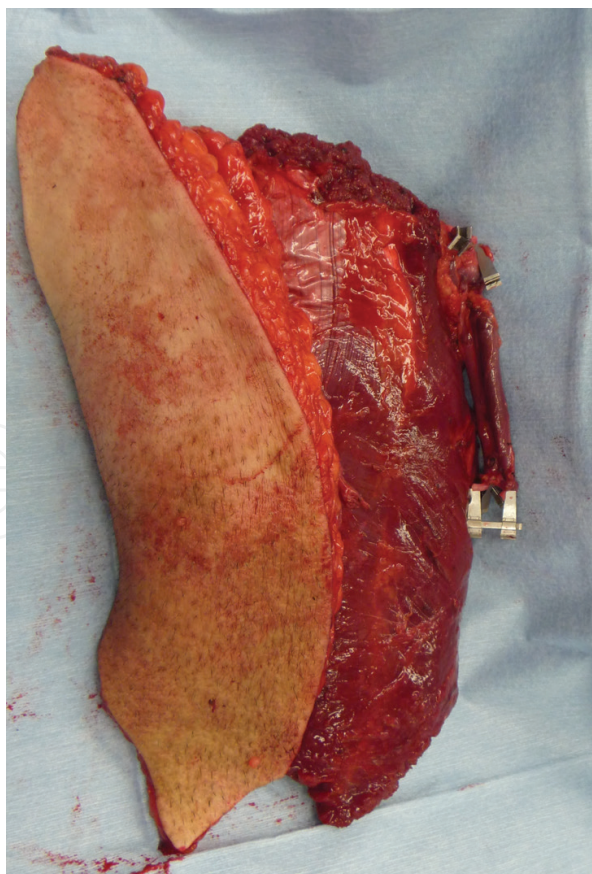

Figure 27. This picture shows a harvested flow-through ALT flap.

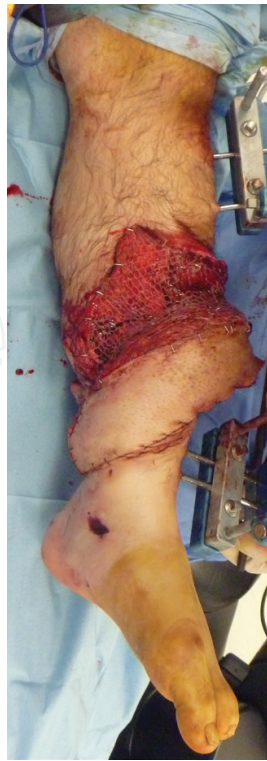

Figure 28. A The postoperative photograph showing resurfacing with flap and skin graft; circulation of the foot resumed immediately.

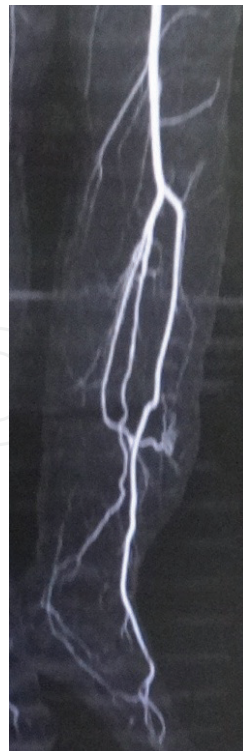

Figure 29. Computed tomography angiography reveals that the descending branch of the ALT flap was interposed into the defect of the anterior tibia artery, which supplied blood flow to the foot.

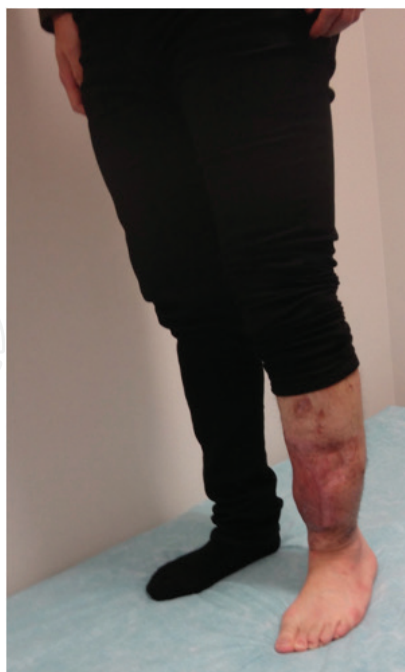

Figure 30. The patient could walk without canes 1 year after surgery.

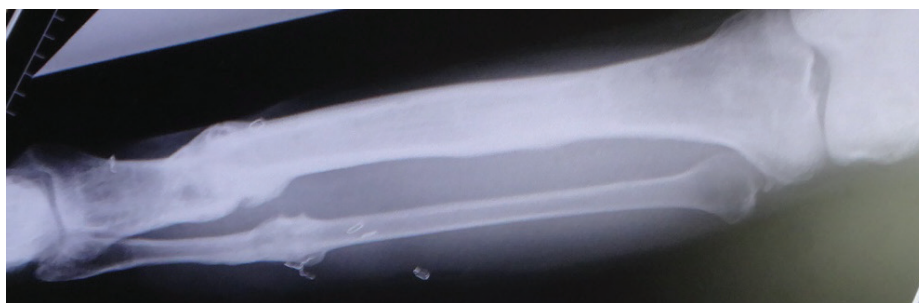


Figure 31. An X-ray photograph shows favorable bone union.

7. “Fix and flap,” a new radical concept for the treatment of severe open fractures

7.1. Concept of “fix and flap” procedure for open fracture

Wound closure of severe open fractures has been delayed with the aim to minimize the risk of infection. However, development of systemic antibiotics, advanced debridement methods, and improvement of surgical techniques have reduced surgical infection. As recent studies have reported that infections after treatment of open fractures are not caused by initial contamination but often are acquired later, emergent or early wound resurfacing for open fractures has been recommended [26–29]. On the other hand, a new radical concept for the treatment of severe open fractures so-called “fix and flap” is recommended as this method also reduces infection [30–32].

7.2. Case presentation of fix and flap procedure for Gustilo-Anderson IIIB fracture

A 32-year-old man sustained Gustilo-Anderson IIIB type both tibia and fibula fractures to the right leg with abrasion of the skin and hamstring muscles (**Figures 32** and **33**). After immediate cleansing, reduction, and temporary external fixation, the secondary “fix and

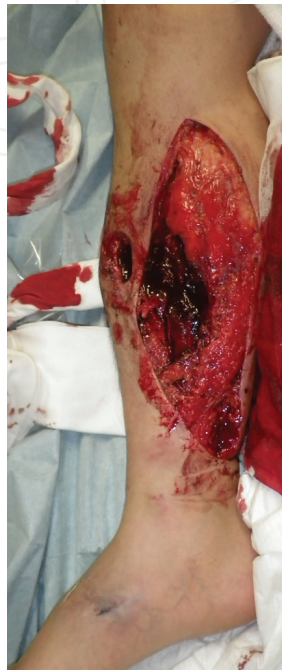

Figure 32. Case 7. This photograph shows a Gustilo-Anderson IIIB type bone-exposing fracture to the right leg with abrasion of the skin and hamstring muscles.

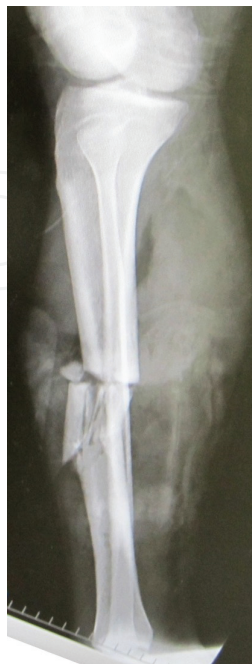

Figure 33. An X-ray photograph shows both tibia and fibula fractures.

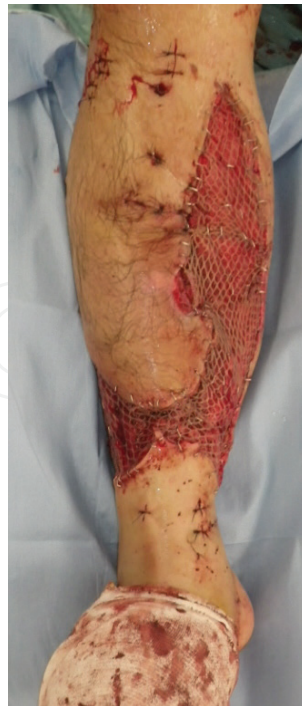

Figure 34. Late “fix and flap” surgery including internal bone fixation, local flap transfer; a free skin graft was performed 5 days later.

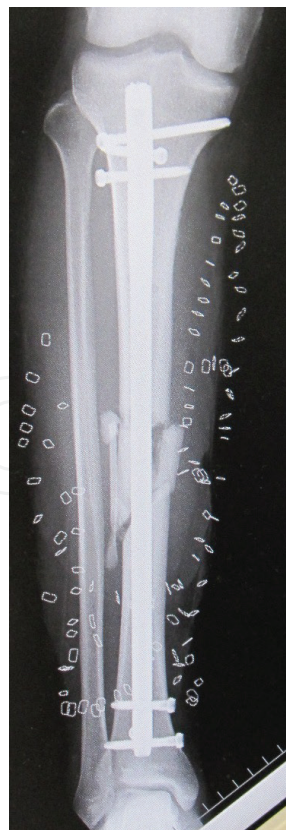


Figure 35. An X-ray photograph showing ridged fixation of the broken tibia using intramedullary fixation system.

flap” surgery including internal bone fixation, fasciocutaneous flap transfer, and free skin graft was performed 5 days later (**Figure 34**). The wound was healed 10 days later, the patient could walk 1 month after secondary surgery without cane because rigid intramedullary fixation system conferred steady stability to the broken leg (**Figures 35 and 36**).

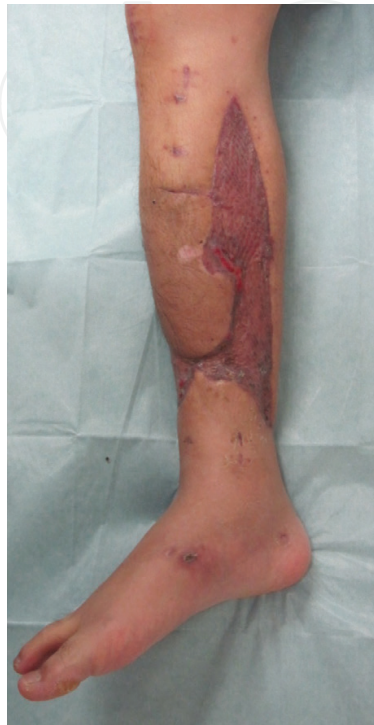

Figure 36. View of the reconstructed leg 1 month after surgery, showing favorable resurfacing.

8. Conclusion

Surgeons are recommended to perform early closure of the wound after rigid bone fixation. These “fix and flap” procedures improve postsurgical problems such as infection, and accelerate the rehabilitation, a process which speeds up patients’ recovery and improve their quality of life [30–32].

Author details

Masaki Fujioka

Address all correspondence to: mfujioka@nagasaki-mc.com

Department of Plastic and Reconstructive Surgery, Clinical Research Center, National Hospital Organization Nagasaki Medical Center, Nagasaki, Japan

References

- [1] Gustilo RB, Anderson JT. Prevention of infection in the treatment of one thousand and twenty-five open fractures of long bones: Retrospective and prospective analyses. *The Journal of Bone and Joint Surgery American*. 1976;**58**:453-458
- [2] Clancey GJ, Hansen Jr ST. Open fractures of the tibia: A review of one hundred and two cases. *The Journal of Bone and Joint Surgery American*. 1978;**60-A**:118-122
- [3] Russell GG, Henderson R, Arnett G. Primary or delayed closure for open tibial fractures. *Journal of Bone and Joint Surgery, British*. 1990;**72-B**:125-128
- [4] Goldner JL, Hardaker Jr WT, Mabrey JD. Open fractures of the extremities: The case for open treatment. *Postgraduate Medical*. 1985;**78**:199-214
- [5] Trueta J. Reflections on the past and present treatment of war wounds and fractures. *Military Medicine*. 1976;**141**:255-258
- [6] Chen X, Chen H, Zhang G. Management of wounds with exposed bone structures using an artificial dermis and skin grafting technique. *Journal of Plastic, Reconstructive & Aesthetic Surgery*. 2010;**63**(6):e512-518
- [7] Fujioka M. Artificial dermis: A new material for wound treatment. *Journal of Wound Technology*. 2009;**4**:13-19
- [8] Fujioka M. Combination treatment with basic fibroblast growth factor and artificial dermis improves complex wounds caused by collagen diseases with steroid use. *Dermatologic Surgery*. 2009;**35**(9):1422-1425
- [9] Daniel RS, Adam GH, Lawrence XW. Negative pressure wound therapy in grade IIIB tibial fractures: Fewer infections and fewer flap procedures? *Clinical Orthopaedics and Related Research*. 2015;**473**(5):1802-1811. DOI: 10.1007/s11999-015-4140-1
- [10] Hom DB, Manivel JC. Promoting healing with recombinant human platelet-derived growth factor-BB in a previously irradiated problem wound. *Laryngoscope*. 2003;**113**:1566-1571
- [11] Fujioka M, Fujii T. Maxillary growth following atelocollagen implantation on mucoperiosteal denudation of the palatal process in young rabbits: Implications for clinical cleft palate repair. *The Cleft Palate-Craniofacial Journal*. 1997;**34**:297-308
- [12] Soni A, Tzafetta K, Knight S, Giannoudis PV. Gustilo IIIC fractures in the lower limb: Our 15-year experience. *Journal of Bone and Joint Surgery, British*. 2012;**94**:698-703
- [13] Halvorson JJ, Anz A, Langfitt M, Deonanan JK, Scott A, Teasdall RD, Carroll EA, Carroll EA. Vascular injury associated with extremity trauma: Initial diagnosis and management. *Journal of the American Academy of Orthopaedic Surgeons*. 2011;**19**:495-504
- [14] Fujioka M, Hayashida K, Murakami C. Artificial dermis is not effective for resurfacing the bone-exposing wounds of Gustilo-Anderson III fracture. *Journal of Plastic, Reconstructive & Aesthetic Surgery*. 2013;**66**:e119-e121

- [15] Rajasekaran S, Dheenadhayalan J, Babu JN, Sundararajan SR, Venkatramani H, Sabapathy SR. Immediate primary skin closure in type-III A and B open fractures: Results after a minimum of five years. *Journal of Bone and Joint Surgery, British*. 2009;**91**(2):217-224. DOI: 10.1302/0301-620X.91B2.21228
- [16] Soutar DS, Scheker LR, Tanner NS, McGregor IA. The radial forearm flap: A versatile method for intra-oral reconstruction. *British Journal of Plastic Surgery*. 1983;**36**(1):1-8
- [17] Koshima I, Fujitsu M, Ushio S, Sugiyama N, Yamashita S. Flow-through anterior thigh flaps with a short pedicle for reconstruction of lower leg and foot defects. *Plastic and Reconstructive Surgery*. 2005;**115**(1):155-162
- [18] Miyamoto S, Kayano S, Umezawa H, Fujiki M, Sakuraba M. Flow-through fibula flap using soleus branch as distal runoff: A case report. *Microsurgery*. 2013;**33**(1):60-62
- [19] Garvey PB, Clemens MW, Rhines LD, Sacks JM. Vertical rectus abdominis musculocutaneous flow-through flap to a free fibula flap for total sacrectomy reconstruction. *Microsurgery*. 2013;**33**(1):32-38
- [20] Kim JT, Kim CY, Kim YH. T-anastomosis in microsurgical free flap reconstruction: an overview of clinical applications. *Journal of Plastic, Reconstructive & Aesthetic Surgery*. 2008;**61**(10):1157-1163
- [21] Rowsell AR, Davies DM, Eisenberg N, Taylor GI. The anatomy of the subscapular-thoracodorsal arterial system: study of 100 cadaver dissections. *British Journal of Plastic Surgery*. 1984;**37**(4):574-576
- [22] Xu DC, Zhong SZ, Kong JM, et al. Applied anatomy of the anterolateral femoral flap. *Plastic and Reconstructive Surgery*. 1988;**82**(2):305-310
- [23] Fujioka M, Hayashida K, Murakami C. Emergent free flow-through anterolateral thigh flaps for Gustilo-Anderson III fracture of the upper extremity. *Journal of Emergencies, Trauma and Shock*. 2014;**7**(1):53-55. DOI: 10.4103/0974-2700.125642
- [24] Hidalgo DA. Aesthetic improvements in free-flap mandible reconstruction. *Plastic and Reconstructive Surgery*. 1991;**88**:574-585
- [25] Saint-Cyr M, Langstein HN. Reconstruction of the hand and upper extremity after tumor resection. *Journal of Surgical Oncology*. 2006;**94**:490-503
- [26] Weitz-Marshall AD, Bosse MJ. Timing of closure of open fractures. *Journal of the American Academy of Orthopaedic Surgeons*. 2002;**10**:379-384
- [27] Moola F, Jacks D, Reindl R, Berry G, Harvey EJ. Safety of primary closure of soft tissue wounds in open fractures. *Journal of Bone and Joint Surgery, British*. 2008;**90-B**(Suppl 1):94
- [28] Hohmann E, Tetsworth K, Radziejowski MJ, Wiesniewski TF. Comparison of delayed and primary wound closure in the treatment of open tibial fractures. *Archives of Orthopaedic and Trauma Surgery*. 2007;**127**:131-136

- [29] Siwach R, Singh R, Arya S, Gupta R. Treatment of 78 type II and type IIIa open fractures by primary closure on suction drain: A prospective study. *Journal of Orthopaedic Trauma*. 2007;**8**:173-176
- [30] DeLong Jr WG, Born CT, Wei SY, et al. Aggressive treatment of 119 open fracture wounds. *The Journal of Trauma* 1999;**46**:1049-1054.
- [31] Gopal S, Majumder S, Batchelor AG, et al. Fix and flap: The radical orthopaedic and plastic treatment of severe open fractures of the tibia. *Journal of Bone and Joint Surgery, British*. 2000;**82-B**:959-966
- [32] Hertel R, Lambert SM, Muller S, Ballmer FT, Ganz R. On the timing of soft tissue reconstruction for open fractures of the lower leg. *Archives of Orthopaedic and Trauma Surgery*. 1999;**119**:7-12