

# We are IntechOpen, the world's leading publisher of Open Access books Built by scientists, for scientists

**4,800**

Open access books available

**122,000**

International authors and editors

**135M**

Downloads

Our authors are among the

**154**

Countries delivered to

**TOP 1%**

most cited scientists

**12.2%**

Contributors from top 500 universities



**WEB OF SCIENCE™**

Selection of our books indexed in the Book Citation Index  
in Web of Science™ Core Collection (BKCI)

Interested in publishing with us?  
Contact [book.department@intechopen.com](mailto:book.department@intechopen.com)

Numbers displayed above are based on latest data collected.

For more information visit [www.intechopen.com](http://www.intechopen.com)



---

# **Integral Management in Painful Shoulder Treatment: Anesthesiologist's Point of View**

---

José Miguel Esparza Miñana

Additional information is available at the end of the chapter

<http://dx.doi.org/10.5772/intechopen.69914>

---

## **Abstract**

Shoulder pain is a common complaint in clinical practice. The usual form of treatment is based on nonsteroidal anti-inflammatory drugs (NSAIDs), rest, rehabilitation and, as an alternative, a local injection into the joint. Due to the lack of oral medication and the lack of evidence, it is necessary to use different nonsurgical therapeutic alternatives. Pulsed radiofrequency produces a temporary nondestructive blockage being the most common technique in the management of shoulder pain. The application of pulsed radiofrequency on the suprascapular nerve has proven to be an effective method in the treatment of shoulder pain, with a decrease in pain that allows the rehabilitation of patients. The axillary or circumflex nerve provides motor innervation mainly to deltoids with branches to the teres minor, provides sensitive innervation to the lower, lateral, and anterior articular capsule, and innervates the humeral head and upper humeral neck. It has a cutaneous branch, which contributes sensitivity of the skin on the deltoids. Combined pulsed radiofrequency on the suprascapular nerve and on the circumflex nerve has been scarcely studied with very few references in the literature. The joint treatment by pulsed radiofrequency technique on suprascapular nerve and circumflex nerve can provide a complete and lasting relief of this pathology.

**Keywords:** shoulder, suprascapular nerve, circumflex nerve, radiofrequency, chronic pain

---

## **1. Introduction**

Shoulder pain is a common problem with an estimated prevalence of 4–26%. It has been estimated that 20% of the general population will suffer shoulder pain throughout their life with a prevalence that can reach up to 50% [1]. This entity is responsible for approximately 16% of all musculoskeletal conditions only behind patients with low back pain.

The painful shoulder is the third most frequent reason for consultation of osteoarticular pathology, after low back pain and neck pain. Between 70 and 85% of the consultations are due to pathology of the rotator cuff [2]. In recent years, these conditions are increasing being a reason for increasing consultation in specialized services in the locomotor system. Although the rotator cuff and subacromial structures make up the majority of the presentations of painful pathology of the shoulder, we cannot forget other less frequent but not less important pain locations [3].

“Painful shoulder syndrome” is a frequent and debilitating disease of diverse etiologies and complex diagnosis, being more common in the female population, and especially after the 5th decade of life [4], in an age range between 45 and 65 years, although it can manifest itself in other age groups [5]. The prevalence increases with age, some professions, and certain sports activities.

Although most chronic shoulder problems can be treated conservatively with activity modification, oral medications, physical therapy, and possible injections of corticosteroids, there are cases where surgical intervention is required. Patients with continuous instability or disabling pain not responding to initial conservative measures may require prior surgical referral. Surgical or specialty referral should also be considered when the diagnosis is unknown [6].

Post-operative pain after shoulder surgery is severe in many patients. For many years, interscalene brachial plexus block has been the gold standard for controlling this pain. However, this is a blockage of the proximal brachial plexus, and therefore, is associated with extensive nerve block, resulting in significant side effects and possible complications.

## 2. Anatomy and biomechanics of the shoulder

The shoulder or shoulder girdle is the anatomical structure with greater mobility of the body, in turn is the most complex structure. The shoulder complex allows an arch of maximum mobility due to the multitude of structures involved in its stabilization: joints, ligaments, and muscles.

The articular complex of the shoulder is an enarthrosis, which confers an ample capacity of movement in the three axes and planes of the space, and this is due to the simultaneous and synchronous functioning of three joints: glenohumeral, acromioclavicular, and sternum-clavicular, in two sliding planes: scapulothoracic and subacromial deltoid. These joints intervene differently in the shoulder movements: in the first 90° of the abduction, the glenohumeral participates, between the 30 and the 135° the scapulator is added, and from the 90° the acromioclavicular and the sternoclavicular are mobilized.

The glenohumeral joint consists of the head of the humerus and the glenoid cavity, has a large lax capsule, and is lined with a synovium, in which two muscles–tendinous systems of stabilization and fixation are joined. The humeral articular surface closes an ellipse, while the glenoid cavity offers a practically flat articular surface. The consequence of such mobility is the great instability of this joint, the joint being more frequently dislocated.

To compensate this instability, there are passive and active stabilizers. Within the passives is the joint capsule with anterior and posterior reinforcements that become independent in the upper and lower ligaments and the labrum. The labrum is a structure that surrounds the margin of the glenoid cavity conferring a greater congruence with respect to the humeral head. Among the active stabilizers, the most important elements are the components of the so-called rotator cuff.

The rotator cuff consists of the subscapularis muscle anteriorly, the supraspinatus and the long portion of the biceps above, and the infraespinatus and teres minor behind. Each of these muscles has its own rotating function (**Table 1**), but its joint action is the one that coacts the head of the humerus against the glenoid cavity and allows the elevation of the limb by the action of the deltoid [7].

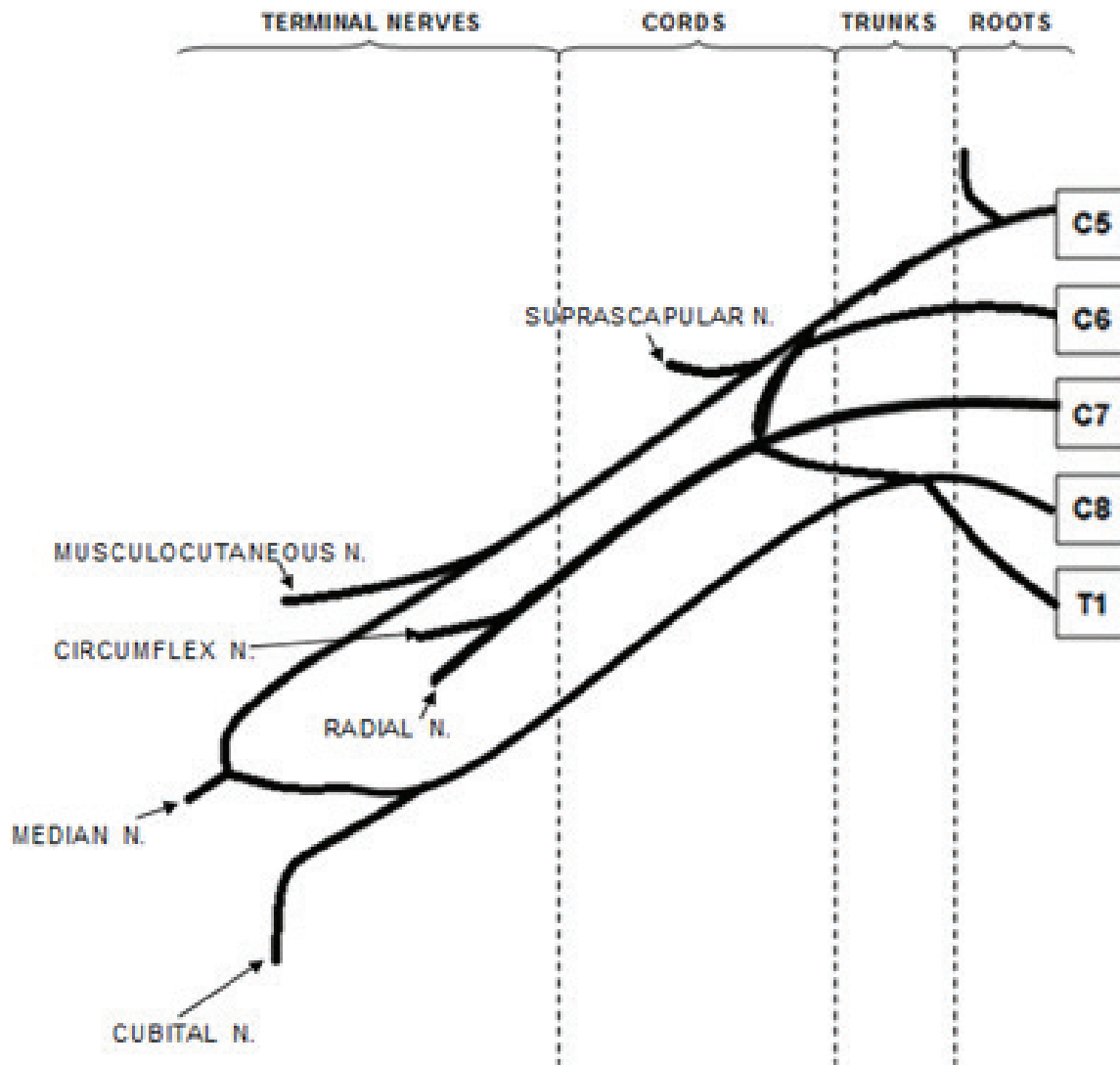
	Muscle tendon	Movements
Upper region	Supraspinatus	Abduction
Posterior region	Infraspinatus, teres minor	External rotation
Anterior region	Subscapularis	Internal rotation
	Bicipital	Elbow flexion-supination

**Table 1.** Muscles and function.

### 3. Innervation of the joint

Sensory innervation of the shoulder joint is complex and involves contributions of the axillary, suprascapular, subscapular, musculocutaneous, and lateral pectoral nerves. Of these, the axillary and suprascapular nerves are considered the most important. However, variations and communications between the nerves are common.

It is important to have an exhaustive knowledge of the brachial plexus (**Figure 1**), since before considering a regional technique it is necessary to know well the innervation of the shoulder. The brachial plexus is formed by the anterior or ventral branches of the last four cervical spinal nerves: C5–C8 and the first thoracic: T1. These spinal nerves join together to form the primary trunks: upper (C5–C6), middle (C7), and lower (C8–T1). Just below the clavicle, the six divisions of the trunks will be formed, since each trunk is divided into anterior and posterior branches. From this moment, they are called secondary trunks or cords, which descend to the armpit. The axilla are denominated according to their relation with the axillary artery: anteroexternal (formed by the union of the upper and middle trunks), anterointernal (formed by the anterior branch of the inferior trunk), and posterior, formed by the posterior divisions of the primary trunks. Finally, each secondary trunk will give origin to the different terminal nerves: the posterior cord originates the axillary and radial nerves, the medial cord the ulnar nerve, and the lateral cord will give rise to the musculocutaneous nerve.



**Figure 1.** Division of the brachial plexus into its terminal branches.

The axillary plexus is responsible for both internal and cutaneous innervation of the shoulder, except for the upper part of the shoulder, which is innervated by the supraclavicular nerve originated in the lower part of the superficial cervical plexus (C3–C4). The articular innervation and the structures that surround it are mainly in charge of the axillary nerve or circumflex and the suprascapular nerve. To a lesser extent, they can be innervated by the musculocutaneous and subscapular nerve.

The suprascapular nerve is a mixed, motor and sensory nerve, formed by the direct union of the upper primary trunk of C5 and C6, with occasional contributions of C4 in some variants. It occurs laterally below the trapezius and omohyoid, and enters the suprascapular fossa. The transverse scapular ligament closes the fossa on the nerve. In the suprascapular fossa, the nerve sends motor branches to the supraspinatus and infraspinatus muscles and some to the teres minor. It provides sensitive branches to the posterior glenohumeral capsule, acromioclavicular joint, and the coracohumeral ligament. In 15% of patients, the suprascapular nerve receives cutaneous sensory fibers from the upper side of the arm (deltoid) [8].

The axillary or circumflex nerve is a branch of the posterior secondary trunk (C5–C6). It forms on the lateral border of the subscapularis muscle, and is directed toward the posterior part of the surgical neck of the humerus. It runs below the shoulder joint about 2–3 mm below the lower capsule. Along with the posterior humeral circumflex artery, the nerve passes through a quadrilateral space forming a small aperture delimited by teres minor, teres major below, long head of medial biceps, and proximal humerus laterally. It provides motor innervation mainly to deltoids with branches to the teres minor, provides sensitive innervation to the lower, lateral, and anterior joint capsule, and innervates the humeral head and upper humeral neck. It has a cutaneous branch, which contributes sensitivity of the skin on the deltoids.

#### 4. Intraoperative analgesic techniques

Multiple advantages present loco-regional anesthesia:

1. They allow a better control of the pain, decreasing the need for opiates, both intra- and post-operatively.
2. Decreases the incidence of nausea and vomiting, which increases patient satisfaction and decreases the average stay.
3. It provides an adequate muscular relaxation for the correct position of the patient.
4. Reduces intraoperative bleeding and promotes hemodynamic stability.

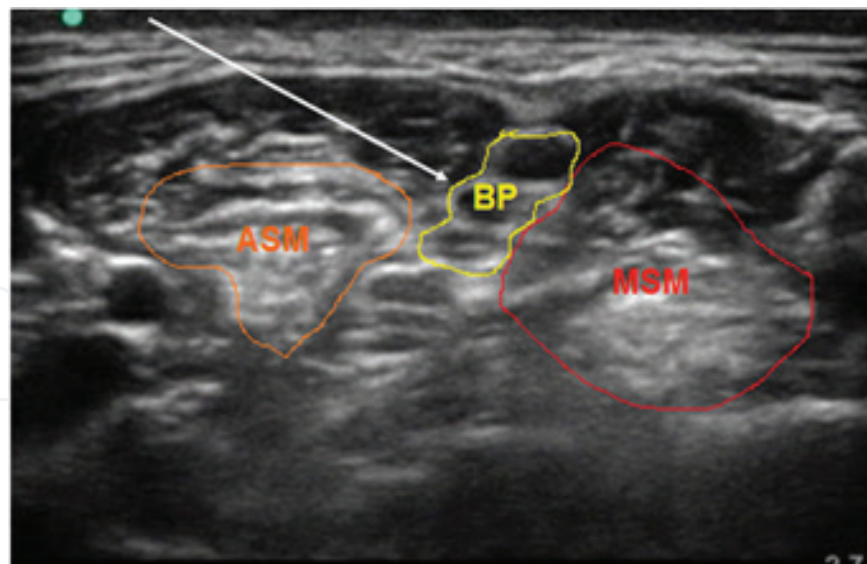
The reference technique for intraoperative analgesia is brachial plexus block at interscalene level [9]. Multiple approaches have been described: Winnie, Pippa, and Meier are the best known. Until not many years ago, the use of the neurostimulator for the accomplishment of the blockade was the gold standard technique. It was recommended to obtain a good response of the triceps (C5–C6) rather than a response of the biceps (C4–C5), ensuring a better distribution of the anesthetic.

With the development of ultrasound techniques and their progressive introduction into anesthesiology services, the use of neurostimulation for nerve localization in analgesic or anesthetic blocks has become obsolete. At the moment, the realization of a blockade that is not guided by ultrasound is not conceived.

The use of this technology brings a number of advantages. One of the most important is to be able to confirm the distribution of the local anesthetic around the nerve by direct vision. The use of ultrasound also improves safety, since we observe at all times the trajectory of the needle and its relation with neighboring structures (vascular, pleura, and solid organs). Another notable advantage is that the volume of local anesthetic is considerably lower. The correct extension of the anesthetic around the nerve allows a shortening of the latency of the blockade and a longer duration of the effect.

Brachial plexus block at interscalene level has been well described and widely used (**Figure 2**). The lack of impact of suprascapular nerve block on respiratory function makes it a good





**Figure 2.** Ultrasound view of brachial plexus block at interscalene level. ASM, anterior scalene muscle; MSM, medium scalene muscle; BP, brachial plexus.

alternative in certain groups. To date, there have been no extensive trials comparing the efficacy and safety of the two, which could cause some reluctance to adopt suprascapular blockade as the regional technique of choice for shoulder surgery [10].

Good studies have recently appeared in this line. Dhir et al. [11] carried out a study with 60 patients in which they analyzed the combined blockade of the suprascapular and axillary nerves, comparing it with the interscalene brachial plexus block. They observed that the combined block provides nonequivalent analgesia compared to interscalene block in arthroscopic shoulder surgery. They conclude that while combined blockade provides better quality pain relief at rest and fewer adverse effects at 24 hours, interscalene block provides better postoperative analgesia. Therefore, for arthroscopic shoulder surgery, combined blockade may be a clinically acceptable analgesic option with a different analgesic profile compared to interscalene blockade.

However, Wiegel et al. [12] in a very recent study with 329 patients comparing the combined blockade of the suprascapular and axillary nerve with the interscalene blockade as analgesic techniques in arthroscopic shoulder surgery concluded that for outpatients subjected to arthroscopic surgery under general anesthesia, combined blockade seems preferable to interscalene. It provides excellent postoperative analgesia without exposing patients to alterations in mobility and the risks of interscalene blockade.

## 5. Postoperative analgesic techniques

In the immediate postoperative period, the patients present a very intense pain during the first hours. It is necessary to apply analgesic guidelines to control it, such as the combination of nonsteroidal anti-inflammatory drugs and intravenous opioids.

The use of catheters with continuous perfusion of local anesthetics accompanied by the possibility of self-administered boluses in shoulder surgery reduces the total dose of local anesthetic and the risk of side effects, and improves overall patient satisfaction. The use of an interscalene catheter is indicated mainly in patients who are going to undergo aggressive surgery with painful postoperative in the first 6 hours and in those patients who present the need for early and energetic rehabilitation. According to the type of surgery and patient characteristics, the catheter will be used between 3 and 5 days.

## 6. Analgesic techniques in treatment of chronic pain

The term "painful shoulder" encompasses all processes that determine pain in the anatomical region of the shoulder. "Painful shoulder syndrome" is a frequent and incapacitating pathology of diverse etiology and complex diagnosis. The causes of painful shoulder are multiple (Table 2). We should always ask if we are facing a disease of the shoulder or if it is a pain referred from another location.

---

### Periarticular

- Rotator cuff tendinitis
- Rupture of the rotator cuff tendon
- Bicipital tendinitis
- Long biceps tendon rupture

### Articular

- Frozen shoulder (adhesive capsulitis)
- Inflammatory arthritis
- Microcrystalline arthritis
- Dislocation, subluxation

### Extrinsic causes

- Vascular or somatic origin
    - Pancoast tumor, pneumothorax
    - Aortic dissection, ischemic heart disease
    - Atherosclerosis, vasculitis, aneurysms
  - Neurological origin
    - Spinal cord injury, peripheral nerve entrapment
    - Fibromyalgia
    - Complex regional pain syndrome
- 

**Table 2.** Etiology of painful shoulder.



The most common symptom in the shoulder is pain. The patient's age, nature, and evolution of pain often lead to diagnosis. It is important to observe its onset, periodicity, location, character, irradiation, concomitant symptoms, and factors that aggravate or alleviate it. The radicular pain that radiates from the cervical region of the shoulder is almost always lacerating; on the other hand, the pain of tendinitis is diffuse, deaf, and continuous.

Subacromial syndrome (SAS), associated or not with rotator cuff tears, is a common cause of shoulder pain, especially in manual workers and athletes involving throwing. The most frequent clinical manifestation of this pathology is through a painful arch pattern between 90 and 120° of abduction. However, SAS can also be presented by a capsular pattern, appearing as a rigid shoulder, or with a pseudoparalytic pattern, in which the main manifestation is impotence for shoulder elevation. This pattern indicates a massive lesion of the rotator cuff with alteration of the kinematic pattern of the shoulder. Finally, a mixed pattern may appear in which several forms of presentation are manifested associated with each other [13].

There is a wide range of painful shoulder treatments beginning with conservative treatment, physical therapies with rest, thermal, physiotherapeutic exercises, drug treatment with nonsteroidal anti-inflammatory drugs (NSAIDs) or analgesics, and joint blockages. Radiofrequency techniques are proposed as a therapeutic alternative in cases refractory to the treatments described.

We have several therapeutic options. Conservative treatment is the first step among the different nonpharmacological alternatives. Modifying daily activity is a simple treatment to decrease shoulder pain. Specific recommendations based on avoiding or decreasing painful activity are the basis of treatment in rotator cuff pathology, glenohumeral joint arthritis, and adhesive capsulitis. Avoiding movement above the head eludes the painful arch between 60 and 120° [6]. There are therapeutic modalities designed to relieve pain directly: cold and heat, ultrasound, iontophoresis, as well as stretching and strengthening [14] exercises that aim to improve overall shoulder function.

In a systematic review, Camarinos et al. concluded that the benefit of nonpharmacological interventions is based on improving mobility, although improvement in function and quality of life is questionable. Fortunately, we also have a broad pharmacological array, although few medications are specifically approved for the treatment of chronic shoulder pain. Most of these are indicated only for bursitis [15]. Nonsteroidal anti-inflammatory drugs (NSAIDs) may be effective in 50–67% of patients, but have only been evaluated in short periods of time. There are no randomized studies comparing the effectiveness of NSAIDs with other analgesics or with a more conservative approach.

Due to the lack of oral medication and the lack of existing evidence, it is necessary to use different nonsurgical therapeutic alternatives [16]. Among the invasive techniques, intra-articular infiltration is a relatively simple technique that can provide adequate pain control. Intra-articular injection of corticosteroids provides better pain relief than oral NSAIDs in the short term.

A recent Cochrane [15] review comparing intra-articular injection with other nonphysiotherapeutic treatment interventions and including a multiple outcome study evaluated at many time points shows that intra-articular corticosteroid injection is significantly more beneficial

than a combined physiotherapeutic approach (mobilization, exercise, and electrotherapy) in improving the main complaint at 3, 7, and 13 weeks, but not later. This benefit was maintained when combined with a second study that evaluated short-term pain and did not demonstrate significant differences between groups.

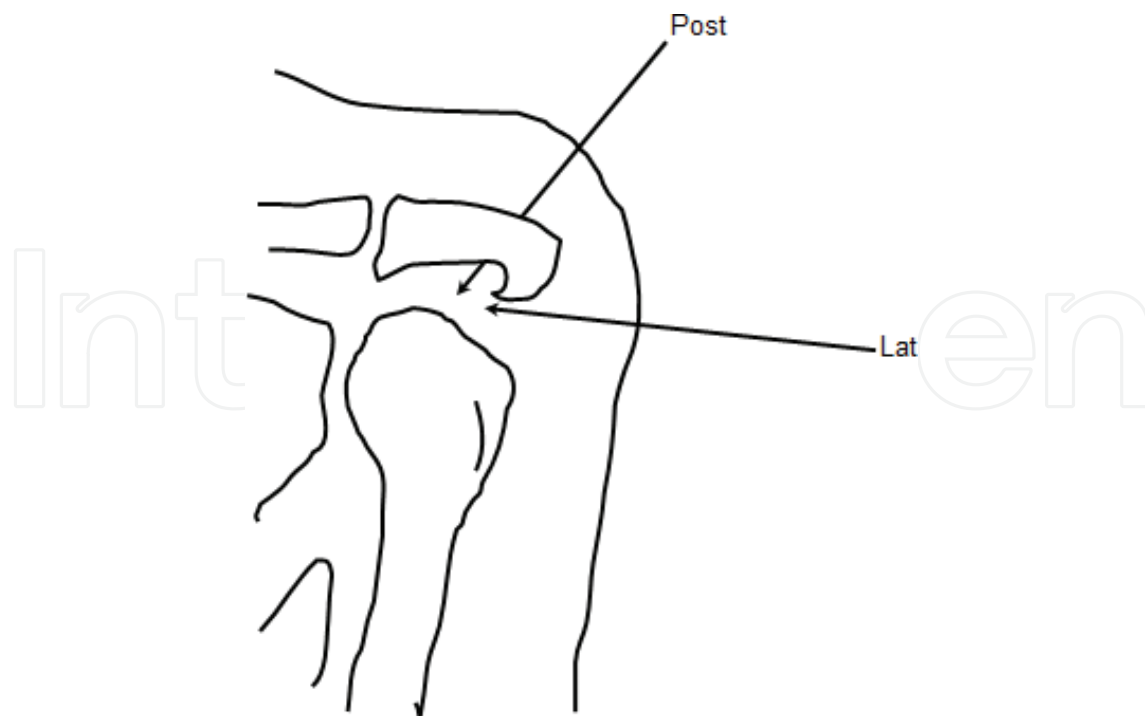
Several studies have evaluated the use of hyaluronic acid in the treatment of shoulder pain. The study by Abellán et al. [13] compared the treatment with subacromial infiltrations with hyaluronic acid and those of corticosteroids, considered as the gold standard, in the treatment of conservative treatment resistant shoulder pain. The results show that subacromial infiltration of hyaluronic acid decreases pain and improves joint function in the same way as corticosteroids. Corticosteroids improve the patients faster, while with hyaluronic acid the improvement is progressive, presenting the same results at 6 months.

Infiltrations would be indicated in the case of poor recovery 4–8 weeks after conservative treatment and in patients with severe pain limiting rehabilitation treatment. The following are the most frequent infiltration techniques:

### 6.1. Intra-articular infiltration

With corticosteroids, local anesthetic, NSAIDs or combined, it is not recommended to make more than three infiltrations.

1. Infiltration of the acromioclavicular joint: with the patient seated and the upper limbs resting on their thighs, the physician should be placed in front, in an anterior position and lateral to the shoulder to infiltrate. To identify the joint, it is useful to palpate the lateral epiphysis of the clavicle in the medial-lateral direction to locate a small depression usually painful under pressure. Injection can be done by superior or anterior approach.
2. Infiltration of the glenohumeral joint: it can be approached by posterior or anterior route, in the latter the anatomical relations are more important. With the patient seated and the upper limbs resting on their thighs we will position laterally to the shoulder to infiltrate, and placed in a plane anterior or posterior to the shoulder according to the way of approach. The posterior route is the safest route and the least technical complication.
3. Infiltration of the subacromial space: it is an efficient and economic technique, which has a double function, on the one hand, clinical confirmation of the diagnosis in the pathology of the rotator cuff and the subacromial syndrome and, on the other hand, its symptomatic treatment in both processes. There are several introduction windows in the subacromial space, but the most recommended and used in the clinic are the following two (**Figure 3**):
  - a. *Lateral path*: The puncture window is located in the space between the acromion and the humeral head, on the lateral side of the shoulder. The patient is placed with the shoulder in neutral position, with the elbow in 90° flexion and the hand on the thigh of the same side.
  - b. *Posterior path*: The puncture window is located just below the acromion on the posterior side of the shoulder. With the patient in the same anterior position, we placed behind this and located the posterolateral edge of the acromion, marking the point of infiltration just below it.



**Figure 3.** Infiltration of the subacromial space.

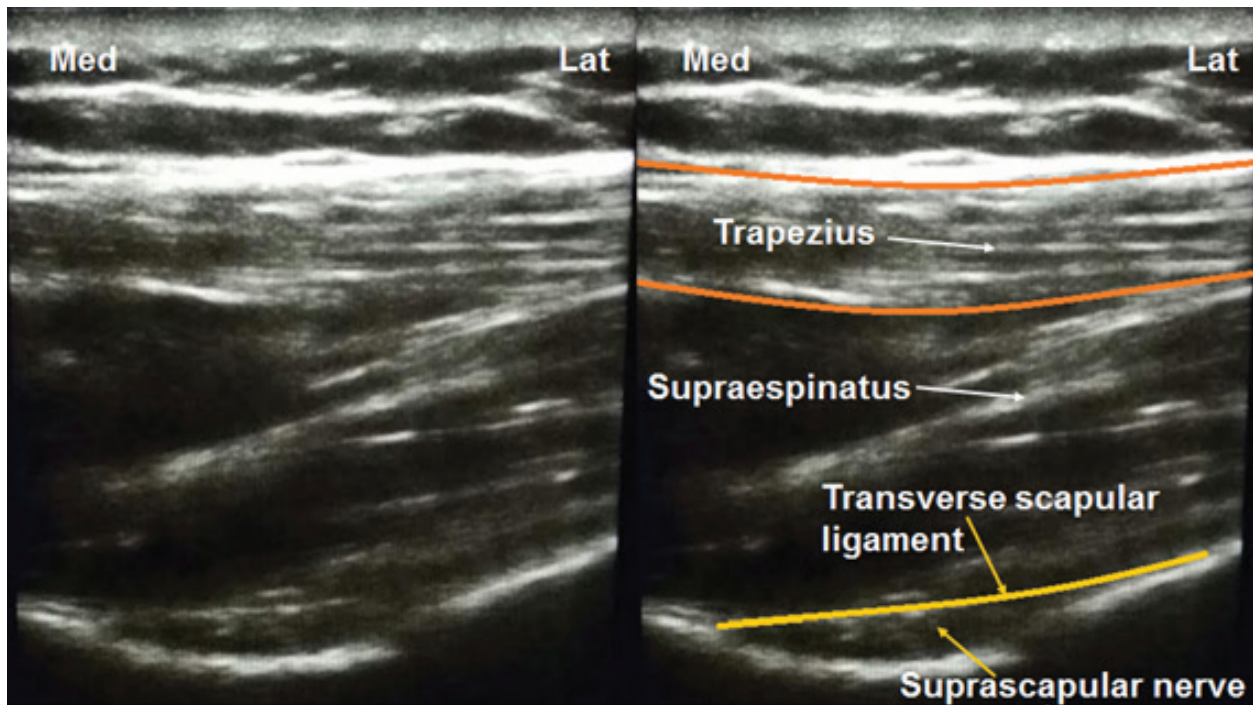
## 6.2. Suprascapular nerve block

Suprascapular nerve block appears to be effective in the treatment of chronic shoulder pain secondary to degenerative diseases and inflammatory diseases using injections of local anesthetic and corticosteroids. It also allows an early rehabilitation with adequate range of movements after reconstruction of shoulder or joint prosthesis. The development of ultrasound and the availability of echographs in the pain units have made it possible to use this technology to perform the blockade in a quick, simple, and practically free of complications.

In order to perform this ultrasound-guided block, we place the patient in a sitting or lateral position with the affected shoulder above. We will use a linear high frequency transducer (6–13 MHz). We performed an initial scan in sagittal orientation at the medial border of the scapula to identify the pleura. Later, we scan laterally with this orientation and move the transducer to visualize the spine of the scapula. If we move it cephalically, we will find the suprascapular fossa. If we move the transducer laterally, maintaining a transverse orientation, to identify the supraspinatus muscle and the suprascapular fossa, we will find the nerve as a round, hyperechoic image below the transverse scapular ligament in the scapular notch (**Figure 4**).

## 6.3. Axillary nerve block

As we have discussed at the beginning of the chapter, this nerve provides motor innervation mainly to deltoids and teres minor, provides sensitive innervation to the lower, lateral, and



**Figure 4.** Ultrasound view suprascapular nerve.

anterior joint capsule, and innervates the humeral head and upper humeral neck. It has a cutaneous branch, which contributes sensitivity of the skin on the deltoids. To achieve more complete analgesic control of the shoulder joint, including the anterior region, we can perform a combined treatment of the suprascapular nerve and the axillary nerve. Therefore, axillary nerve block is performed as a complement to suprascapular nerve block to improve analgesic quality.

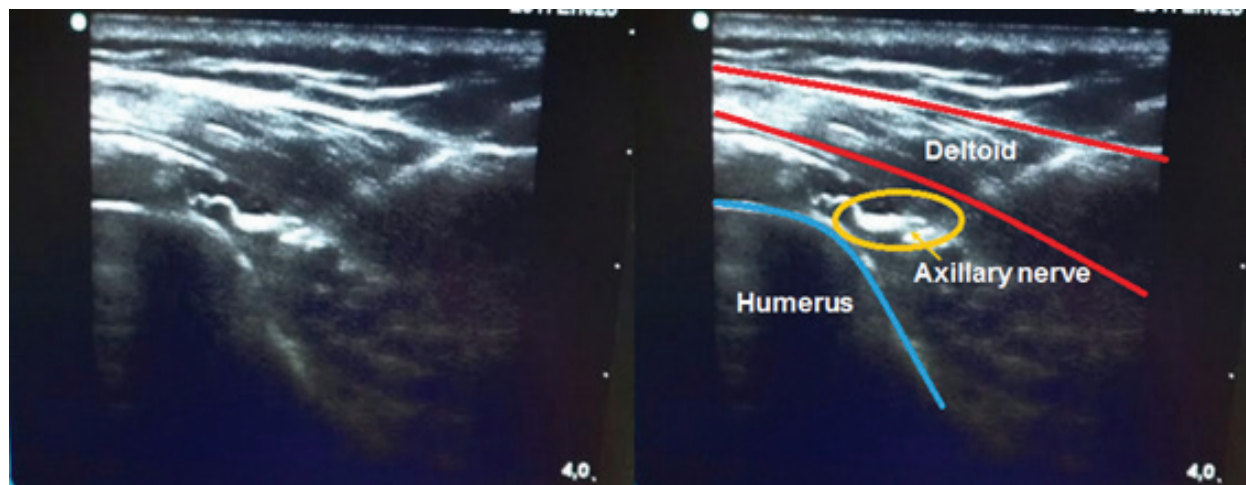
In order to perform this ultrasound-guided block, we place the patient in a sitting or lateral position with the affected shoulder above. We will use a linear high frequency transducer (6–13 MHz). We performed an initial scan at the posterior border of the arm at the deltoid level and identified the humeral head and the deltoid muscle. Between both the axillary nerves appear as a rounded and hyperechoic image (**Figure 5**).

#### **6.4. Radiofrequency techniques**

Radiofrequency was first used in the early 1950s. Cosman and Cosman [17, 18] described the use of high frequency currents (in the radiofrequency range) to produce lesions. A few years later, Sweet and Wepsic [19] made a second breakthrough in this field when he developed the first temperature-controlled radiofrequency system to produce lesions for the treatment of trigeminal neuralgia.

Currently, the use of electric currents by radiofrequency is a widely used clinical technique in the field of chronic pain treatment. It is a minimally invasive, percutaneous access technique in most cases, consisting of the application of a radiofrequency electric field (around 500 kHz)





**Figure 5.** Ultrasound view axillary nerve.

around a tissue, through an applicator, that produces a modification in the treated target tissue, and consequently an alteration in the transmission of the painful stimulus.

The pulsed radiofrequency method (RFp) was initially used by Sluijter et al. [20]. To date, it has been used for the treatment of peripheral nerves and the dorsal root ganglion. It has been commonly applied for the treatment of low back pain, neck pain, and neuropathies with very good results. An advantage of RFp over conventional radiofrequency (RF) is that it generates very little discomfort and can be performed with very little or no pain on the patient while the technique is being performed.

The application of pulsed radiofrequency on the suprascapular nerve has proven to be an effective method in the treatment of shoulder pain, with a decrease in pain that allows the rehabilitation of patients [21]. On the other hand, it prevents repetitive infiltrations with local anesthetics and corticosteroids, which are not without undesirable effects [8, 22]. In order to achieve more complete analgesic control of the shoulder joint, including the anterior region, we can perform a combined treatment of the suprascapular nerve and the circumflex nerve.

In an observational study involving 16 patients with painful shoulder (13 patients with rheumatoid arthritis and 3 with osteoarthritis) and limited active movement of the joint, a combined block of the suprascapular nerve and the articular branches of the circumflex were performed. A mean reduction in pain intensity of 69% was observed with an improvement in ranges of motion (abduction, adduction, and flexion) that increased from 36 to 67% over a 13-week follow-up period [23].

The combined pulsed radiofrequency on the suprascapular nerve and on the axillary or circumflex nerve has been scarcely studied with very few references in the literature. Since the innervation of the shoulder joint is largely collected by these two nerves, the treatment by pulsed radiofrequency technique on suprascapular nerve and axillary or circumflex nerve can provide a complete and lasting relief of this pathology. In any case, more well-designed studies are needed to define the role of the combined technique in the treatment of the painful shoulder.

## Author details

José Miguel Esparza Miñana

Address all correspondence to: [miespmi@gmail.com](mailto:miespmi@gmail.com)

Escuela de Doctorado, Universidad Católica de Valencia San Vicente Mártir, Hospital de Manises, Valencia, Spain

## References

- [1] Esparza Miñana JM, Londoño Parra M, Villanueva Pérez VL, De Andrés Ibáñez J. Nuevas alternativas en el tratamiento del síndrome de hombro Doloroso. *Semergen*. 2012;**38**(1):40-43
- [2] Dias D, Matos M, Daltro C, Guimarães A. Clinical and functional profile of patients with the painful shoulder syndrome (PSS). *Ortopedia Traumatologia Rehabilitaça*. 2008;**10**:547-553
- [3] Benítez Pareja D, Trinidad Martín-Arroyo JM, Benítez Pareja P, Torres Morera LM. Estudio e intervencionismo ecoguiado de la articulación del hombro. *Revista de la Sociedad Española del Dolor*. 2012;**19**(5):264-272
- [4] Camarinos J, Marinko L. Effectiveness of manual physical therapy for painful shoulder conditions: A systematic review. *Journal of Manual and Manipulative Therapy*. 2009;**17**:206-215
- [5] Van der Windt DA, Koes BW, De Jong BA, Bouter LM. Shoulder disorders in general practice: Incidence, patient characteristics, and management. *Annals of Rheumatic Diseases*. 1995;**5**(4):959-964
- [6] Burbank KM, Stevenson JH, Czarnecki GR, Forfman J. Chronic shoulder pain: Part II. Treatment. *American Family Physician*. 2008;**77**:493-497
- [7] Basora M, Colomina MJ. Anestesia en Cirugía Ortopédica y en Traumatología. Capítulo: Hombro. *Médica Panamericana*; 2011. pp. 141-149
- [8] Van Zundert J, de Louw A, Joosten E, Kesseles AG, Honig W, Federen PJ, et al. Pulsed and continuous radiofrequency current adjacent to the cervical dorsal root ganglion of the rat induces late cellular activity in the dorsal horn. *Anaesthesiology*. 2005;**102**:125-131
- [9] Singelyn FJ, Lhotel L, Fabre B. Pain relief after arthroscopy shoulder surgery: A comparison of intraarticular analgesia, suprascapular nerve block and interscalene brachial plexus bloc. *Anesthesia and Analgesia*. 2004;**99**:589-592
- [10] Heron M, Dattani R, Smith R. Interscalene vs suprascapular nerve block for shoulder surgery. *British Journal of Hospital Medicine*. August 2016;**77**(8):494-494



- [11] Dhir S, Sondekoppam RV, Sharma R, Ganapathy S, Athwal GS. A comparison of combined suprascapular and axillary nerve blocks to interscalene nerve block for analgesia in arthroscopic shoulder surgery: An equivalence study. *Regional Anesthesia and Pain Medicine*. 2016 Sep–Oct;**41**(5):564-571. DOI: 10.1097/AAP.0000000000000436
- [12] Wiegel M, Moriggl B, Schwarzkopf P, Petroff D, Reske AW. Anterior suprascapular nerve block versus interscalene brachial plexus block for shoulder surgery in the outpatient setting: A randomized controlled patient- and assessor-blinded trial. *Regional Anesthesia and Pain Medicine*. 2016 Sep–Oct;**41**(5):564-571. DOI: 10.1097/AAP.0000000000000436
- [13] Abellán JF, Gimenez D, Melendreras E, Ruiz Merino G, Moreno MA. Treatment of persistent shoulder pain with subacromial sodium hyaluronate injection. *Archivos de Medicina del Deporte*. 2010;**XXVII**(140):449-456
- [14] Vaquer L, Blasco L, Gozávez E, Bayona MJ, Villanueva V, Asensio J, et al. Iontoforesis en el abordaje del paciente con dolor crónico. *Revista de la Sociedad Española del Dolor*. 2009;**16**:2758
- [15] Green S, Buchbinder R, Hetrick S. Intervenciones fisioterapéuticas para el dolor del hombro. *The Cochrane Library*. 2008;Tomo **1**(2):65-75
- [16] Andrews JR. Diagnosis and treatment of chronic painful shoulder: Review of non-surgical interventions. *Arthroscopy: Journal of Arthroscopic and Related Surgery*. 2005;**21**:333-347
- [17] Cosman BJ, Cosman EC. *Guide to Radiofrequency Lesion Generation in Neurosurgery*. Radionics Procedure Technique Series Monographs. Burlington, MA: Radionics; 1974
- [18] Cosman ER, Cosman BJ. Methods of making nervous system lesions. In: Wilkins RH, Ren-gachary SS, editors. *Neurosurgery*. Vol. 1. New York: McGraw-Hill; 1984. pp. 2490-2498
- [19] Sweet WH, Wepsic JG. Controlled thermocoagulation of trigeminal ganglion and rootlets for differential destruction of pain fibers: I. Trigeminal neuralgia. *Journal of Neurosurgery*. 1974;**39**:143-156
- [20] Sluijter ME, Cosman ER, Rittman WJ, Kleef M. The effects of pulsed radiofrequency fields applied to the dorsal root ganglion—A preliminary report. *Pain Clinic*. 1998;**11**(2):109-118
- [21] Po-Chou, Kang L, Cheng-Loong. Pulsed radiofrequency lesioning of the suprascapular nerve for chronic shoulder pain: A preliminary report. *Pain Medicine*. 2009;**10**(1):70-75
- [22] Haguichi Y, Nashold BS, Sluijter M, Cosman E, Pearlstein RD. Exposure of the dorsal root ganglion in rats to pulsed radiofrequency currents activates dorsal horn lamina I and II neurons. *Neurosurgery*. 2002;**50**:850-855
- [23] Lewis RN. The use of combined suprascapular and circumflex (articular branches) nerve blocks in the management of chronic arthritis of the shoulder joint. *European Journal of Anaesthesiology*. 1999;**16**:37-41