

We are IntechOpen, the world's leading publisher of Open Access books Built by scientists, for scientists

4,800

Open access books available

122,000

International authors and editors

135M

Downloads

Our authors are among the

154

Countries delivered to

TOP 1%

most cited scientists

12.2%

Contributors from top 500 universities



WEB OF SCIENCE™

Selection of our books indexed in the Book Citation Index
in Web of Science™ Core Collection (BKCI)

Interested in publishing with us?
Contact book.department@intechopen.com

Numbers displayed above are based on latest data collected.
For more information visit www.intechopen.com



Inguinal Hernia in Infancy and Children

Ahmed Abdelghaffar Helal

Additional information is available at the end of the chapter

<http://dx.doi.org/10.5772/intechopen.69378>

Abstract

Congenital inguinal hernia is a very important subject for both general and pediatric surgeons, and many issues related to the inguinal hernia in infants and children are still confusing. Herein, the subject of congenital inguinal hernia, including the relevant embryology, related anatomy, the symptoms and signs essential for diagnosis, and the needed examination tests and investigations, is presented in a systematic manner. Also, the updated treatment options were discussed including both open and laparoscopic approaches with spotlight on the very recent single incision laparoscopic inguinal hernia repair in children. Finally, at the end of the chapter, there are many valuable references for more details.

Keywords: congenital inguinal hernia, inguinal canal, infants, children, laparoscopic hernia repair

1. Introduction

Congenital inguinal hernia in infants and children is a common surgical problem. Numerous issues, including the rational and timing of the repair, the need to explore the contralateral side, the use of laparoscopy, and anesthetic precautions, remain unsettled. Moreover, inguinal hernias in both full-term and preterm infants are commonly repaired shortly after diagnosis to avoid incarceration of the hernia, may be due to the lack of definitive data regarding optimal timing for repair of inguinal hernias in infants. In this chapter, the reader will be able to know and understand:

- the embryology and anatomy of pediatric inguinal hernia,
 - the different clinical presentations of pediatric inguinal hernia,
-

- the differential diagnosis of inguinal hernia in infants and children,
- the treatment options for pediatric inguinal hernia, and
- the common open and laparoscopic approaches to pediatric inguinal hernias.

2. Embryology

Inguinal hernia in children represents arrest of development rather than acquired weakness. It is directly related to the descent of the developing gonads. The testes are preceded in their descent to the scrotum by a “finger” of peritoneum, the processus vaginalis (PV), which is first seen around the 12th week of gestation, and it is usually closed between the 36th and 40th weeks of gestation, except for the part that becomes the tunica vaginalis. In many newborns, this process is incomplete, leaving a patent processus vaginalis (PPV). Usually, the closure of PV is completed at birth; however, it may be delayed to postnatal period. Approximately 40% of PPV will close during the first months of life and an additional 20% close by 1 year of age. The closure of the PV on the left side precedes closure on the right; therefore, it is not surprising that 60% of congenital inguinal hernia occurs on the right side. The assumption that PPV is the same as an inguinal hernia is not true. The presence of PPV is necessary but not sufficient to develop a congenital inguinal hernia. In other words, all congenital inguinal hernias are preceded by PPV, but not all PPV go on to become inguinal hernia. About 12–14% of boys with PPV will develop inguinal hernia in their life time. The exact cause of the obliteration of the PPV is unknown. When PPV fails to close, a sac is present through which abdominal contents can be herniated via the inguinal canal. However, sometimes the entrance may be adequately covered by the internal oblique and transverses abdominal muscles, preventing escape of abdominal contents for many years, or allowing only fluid to pass through it forming a communicating hydrocele. If closure occurs proximally while fluid is trapped within the tunica distally, a non-communicating hydrocele is the result [1, 2].

3. Anatomy

3.1. Open anatomy

The inguinal canal is an oblique inter-muscular passage that extends from the deep to superficial inguinal rings and transmits the spermatic cord in males and round ligament in females. Most of the canal consists of the aponeurosis of the external oblique muscle as it curves inward to form the inguinal ligament. The roof of the canal is formed of the lower arched fibers of internal oblique and transverses abdominis muscles. The posterior wall of the canal consists of the transversalis fascia along its whole length. The inferior border of the canal is formed by the rolled fibers of inguinal ligament medially, and then the pectineus fascia and the insertion of the lacunar ligament (**Figure 1**). In neonates and infants, the inguinal canal is not well developed, and it was very short with both external and internal inguinal rings overlapping. Therefore, during open herniotomy before 1 year of age, there is no need to open the external oblique muscle [3, 4].

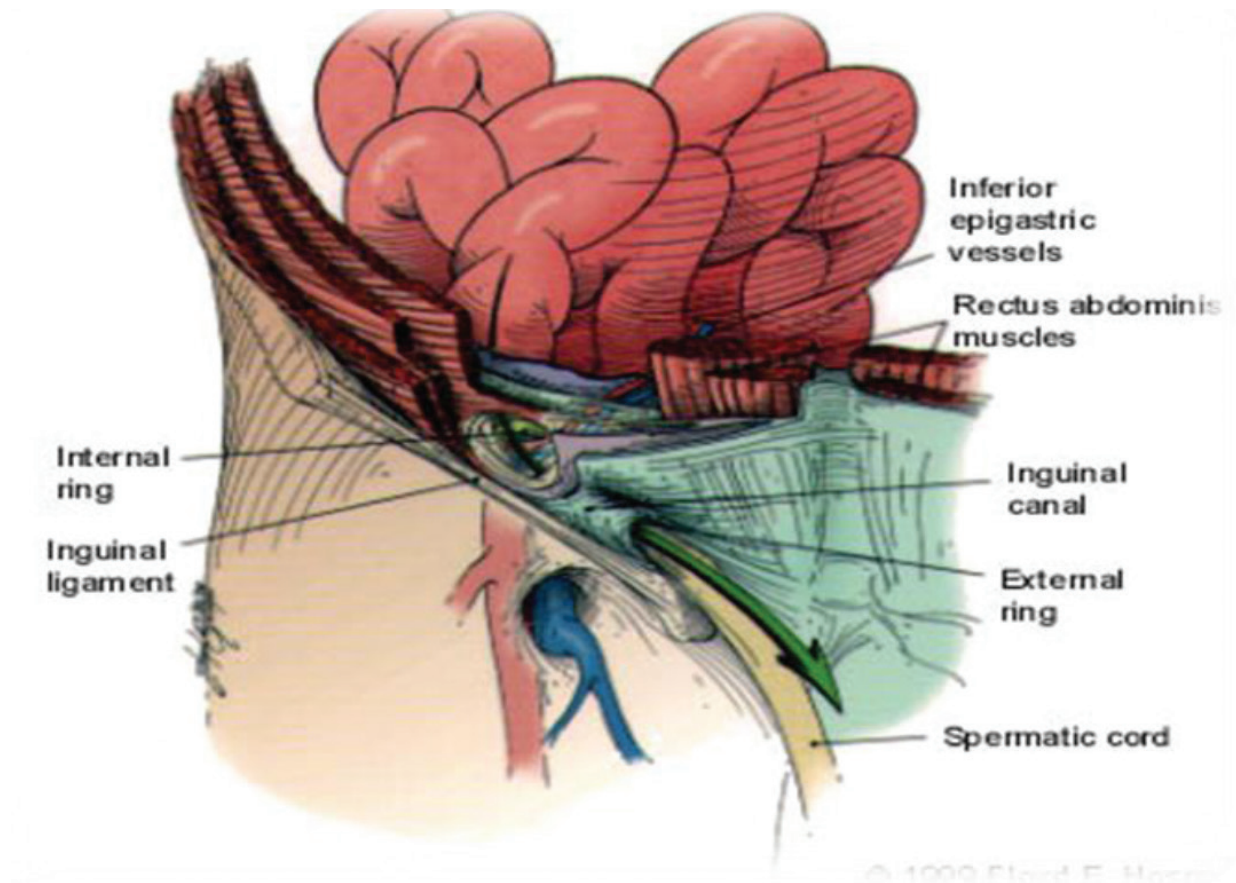


Figure 1. The open anatomy inguinal canal.

3.2. Laparoscopic anatomy

In 1945, Lytle wrote “The surgeon knows little about the anatomy of the posterior wall of the inguinal canal, as it is hidden from his view.” During laparoscopic hernia repair, the hernia is no longer viewed as a protrusion from the abdominal wall, but rather as an extrusion of a viscous from the peritoneal cavity. So, the layers of the inguinal region and the abdominal wall are viewed in a reversed order or practically it is seen from an opposite view point. Therefore, during laparoscopic hernia repair, the following changes must be considered: the inguinal anatomy is visualized from inside with an optimal panoramic view of the posterior surface of the abdominal wall. Moreover, the inguinal anatomy is visualized with a paralyzed and expanded abdominal wall muscles. The pneumoperitoneum itself distorts normal anatomy, stretches ligaments, tenses parietal peritoneum, and inflates hernia sac. This laparoscopic change modifies the tension, texture, and handling characteristics of the peritoneum and the abdominal wall muscles when compared with its normal characteristics found during laparotomy (Figure 2) [5, 6].

Laparoscopically, the abdominal wall below the umbilicus shows five peritoneal folds, with three convergent fibrous cords in the center and two vascular bundles peripherally. In the mid-line is the median umbilical ligament, which represents the obliterated remnant of the embryonic urachus and extends from the fundus of the bladder to the umbilicus. The medial umbilical ligament consists of a peritoneal fold covering the obliterated distal portion of the

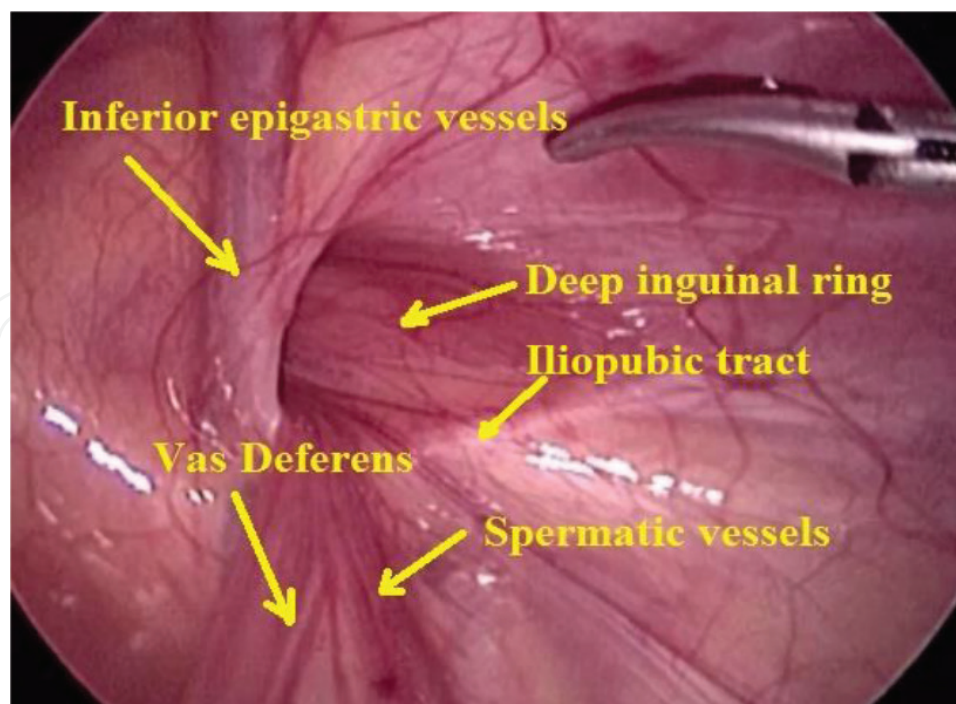


Figure 2. The laparoscopic view of inguinal anatomy.

umbilical artery. The lateral umbilical ligament consists of a fold of peritoneum around the inferior epigastric vessels together with a variable amount of fatty tissue [7, 8].

The pre-peritoneal space is important for the laparoscopic surgeon. It contains a variable amount of connective tissue, the residual of the umbilical artery, and the inferior epigastric vessels. The external iliac vessels and the inferior epigastric vessels lie free in this space and have no intimate anatomic relationship with the fascia transversalis, a fact that is important during laparoscopic hernia repair. The obturator artery originating from the inferior epigastric or external iliac vessel has been observed in approximately 30% of the patients. Damage to this artery during inguinal hernia repair may cause serious hemorrhage into the pre-peritoneal space. Finally, the laparoscopic pediatric surgeon must become familiar with the pre-peritoneal space anatomy and its vascular contents, as vascular injury during laparoscopic hernia repair is easy and usually leads to severe hematoma formation [9–11].

The vas deferens ascends from the side wall of the pelvis, curving upward around the obliterated umbilical artery, below the level of the transverse vesical fold as it passes from medial to lateral across the external iliac vessels. Then, it disappears from view as it meets with the testicular vessels immediately lateral to the base of the epigastric artery. The round ligament alone enters the deep inguinal ring. The artery to the vas or round ligament accompanies each structure, with several minor veins, often visible through the thin peritoneal covering. While the vas forms just a ridge beneath the peritoneum, the round ligament tends to lie deeper at an intra-peritoneal level. The testicular vessels usually not seen through the peritoneum disappear from laparoscopic view as they meet with the vas on its lateral aspect, and they enter together the deep ring on its posteromedial edge (**Figure 3**) [12, 13].

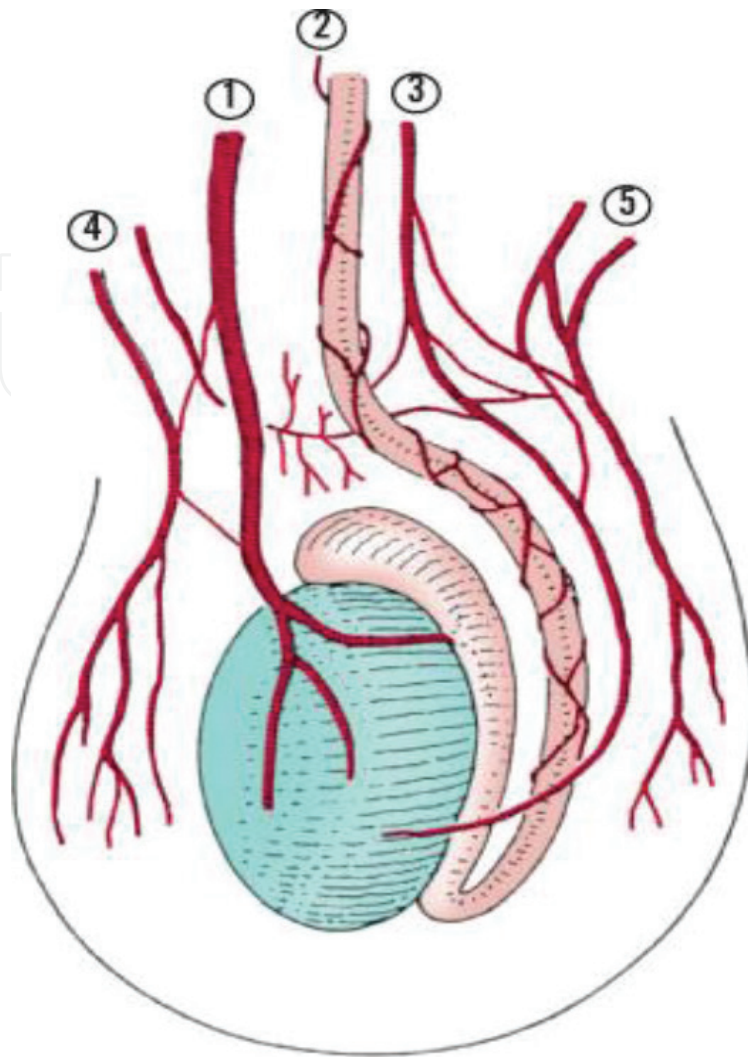


Figure 3. Arterial supply of testis and epididymis. (1) Testicular artery. (2) Deferential artery. (3) Cremasteric artery. (4) Posterior scrotal artery. (5) Anterior scrotal artery.

4. Clinical presentations

The incidence of congenital inguinal hernia in infants and children ranges from 1 to 5%. With 60% occurring on the right side, premature infants are at higher risk. The male-to-female ratio is estimated to be 6:1. Inguinal bulge with straining or crying is the most common presentation described by the parents or observed during physical examination. Classically, the diagnosis is established by history taking and clinical examination.

4.1. History taking

The parents usually described a visible, intermittent swelling or bulge in the inguino-scrotal region in boys or inguino-labial region in girls appears with crying or straining, and usually it disappeared during night while the baby is sleeping. The swelling is usually not associated

with pain or discomfort. But, sometimes, the parents may perceive the bulge as being painful, which is not true as it in fact causes no discomfort to the baby except if complicated. The presence of a painful bulge should alert the pediatric surgeon to the presence of an incarcerated inguinal hernia. Most pediatric surgeons diagnose and operate child with congenital inguinal hernia depending on a classic history description by parents or a referring physician, others still insist on seeing the hernia themselves and may return the child for a second examination after 2–3 weeks [14, 15].

4.2. Clinical examination

Local examination is essential to confirm the diagnosis of congenital inguinal hernia, and it usually starts with inspection of the inguinoscrotal region to see the inguinal bulge, and if it is not obvious by inspection, holding baby legs and arms gently against the examination table will result in crying with increased intra-abdominal pressure and appearance of the inguinal bulge. For older children, blowing bubbles, or having them blow up balloons or examination gloves will increase intra-abdominal pressure and inguinal bulge may appear. The “silk purse” or “silk glove” sign is an important local physical sign. It is elicited by gently rolling the cord structures across the pubic tubercle. The feeling of a sac moving on itself is considered a positive finding. Published reports showed a wide variation in diagnostic accuracy of the silk purse sign, with a sensitivity of 91% and specificity of 97.3%. Currently, the most reasonable approach is to consider the silk purse sign as supporting but not conclusive evidence to confirm the diagnosis. It is essential to palpate both testicles, to rule out an undescended or retractile testicle, which can be associated with an inguinal hernia. In girls, feeling the ovary in the hernia sac is not uncommon and may be mistaken for a lymph node [16, 17].

Direct hernias through the floor of the inguinal canal due to muscular weakness are extremely rare in children. It classically presents medial to the inferior epigastric vessels. Due to the rarity of the direct hernia in children and the fact that direct hernia in children will never reach the scrotum, the pediatric surgeon can easily diagnose that an inguinal hernia in a child is of the indirect type. Femoral hernia in children can be very difficult to differentiate from an indirect inguinal hernia. It is located below the inguinal canal, through the femoral canal. The only possible differentiation is during the operative repair as the anatomy and relationship to the inguinal ligament are clearly visualized. The clinical presentations of femoral hernias in children are essentially the same as indirect inguinal hernias. In a case of incarcerated inguinal hernia, there will be a tender firm mass in the inguinal region or scrotum, and the child may be fussy, unwilling to feed, and crying inconsolably. The overlying skin may be edematous, erythematous, and discolored. On the other hand, the hernia may be huge enough to be easily diagnosed as seen in (Figure 4) [18, 19].

The differentiation between congenital inguinal hernia and hydrocele in young children is not always straightforward. The well-known trans-illumination test is essential for distinguishing between the presence of a sac filled with fluid in the scrotum and the presence of bowel in the scrotal sac. However, in cases of incarcerated inguinal hernia, the trans-illumination test may be equivocal, as distended viscera with fluid in the scrotum of a young infant will trans-illuminate. Finally, the use of inguinal ultrasound may be needed to differentiate between PPV

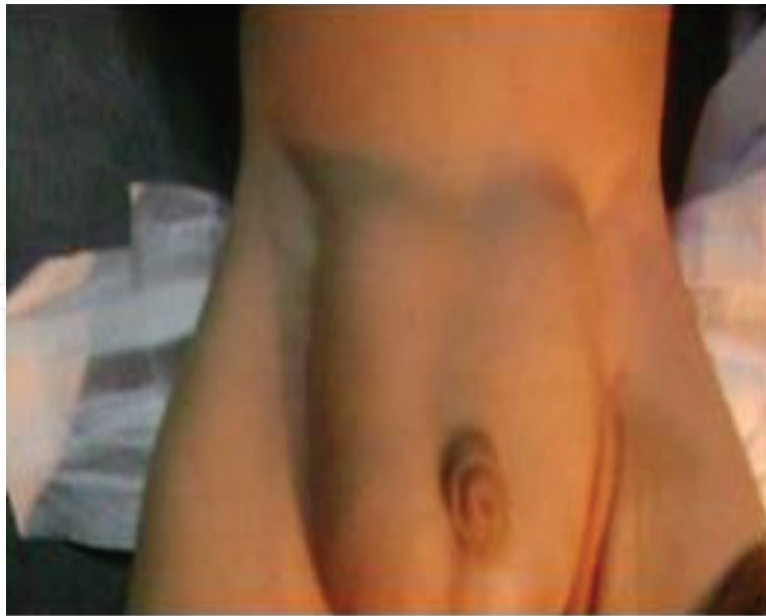

Figure 4. Bilateral huge congenital inguinal hernia.

and inguinal hernia. It can differentiate between hydrocele, incarcerated hernia, and testicular torsion. In most cases, inguinal ultrasound was used to increase the diagnostic accuracy of inguinal hernia in children from 84% on physical examination alone to 97.9% and that hypoechoic structure in the inguinal canal measuring 4–6 mm was a PPV, and greater than 6 mm was a hernia [20, 21].

5. Treatment

Congenital inguinal hernia repair is one of the most common operations performed by pediatric surgeons, and consultations for inguinal hernia are among the most frequent reasons for pediatric surgical referral. In infants and young children, the risk of incarceration of the unrepaired inguinal hernia is as high as 31% (usually in the first few months of life), posing a significant risk to the bowel and testicle. Accordingly, surgical repair of a symptomatic inguinal hernia is recommended soon after diagnosis. Parents are instructed to do gentle pressure on the inguinal bulge to prevent incarceration of the contents until the elective surgery is performed. On the other hand, in neonates, the surgical treatment of hydrocele is delayed for 12–18 months because in such case the PPV opening is very small and may have already closed or be in the process of closing. If the hydrocele persists after this observation period, operative repair is usually indicated [22, 23].

5.1. Open repair

Open hernia repair in children is usually an outpatient procedure. Surgery should be postponed in the presence of upper respiratory tract, otitis media, or significant napkin dermatitis. The basic principle of the repair includes high ligation and excision of the hernia sac with or

without narrowing of the internal inguinal ring. The classical open herniotomy is performed as follows: a lower abdominal skin crease incision is made, and then both Scarp's fascia and the external oblique are opened. The cremasteric fibers are bluntly dissected until the sac can be seen. The sac is then gently separated from the cord structures, dissected to the level of the internal inguinal ring, ligated, and divided at this level. In patients with a wide internal ring, narrowing of the internal ring can be added with repair of the inguinal floor. The distal sac is either split anteriorly or excised. The excision versus splitting of the distal hernia sac continues to be controversial issue; however, it was founded that there is no difference in recurrence or hydrocele formation, suggesting that simply opening the anterior wall is sufficient in children and neonates. On the other hand, complete excision of the distal sac may increase the risk of injury to the cord structures and the testis and may cause hematoma. It is important to ensure that the testis is in the scrotum at the end of the operation to avoid iatrogenic cryptorchidism. If undescended testis is discovered during herniotomy, it must be fixed in the scrotum, even if the infant is younger than 12 months old. This avoids the possible risk of incarceration, strangulation, and testicular infarction [24, 25, 26].

Contralateral exploration for PPV in children with unilateral hernia is still debatable. Contralateral PPV was present in about 30–40% of children presenting with unilateral hernia. The introduction of the telescope through the sac of the hernia to visualize the contralateral PPV is used to avoid contralateral exploration, and recently, during laparoscopic hernia repair, contralateral PPV is easily diagnosed [27, 28].

5.2. Laparoscopic repair

Laparoscopic hernia repair recently challenged the conventional open herniotomy, with reported results that comparable to open herniotomy with nearly similar recurrence rate and superior cosmetic results. The basic principle for laparoscopic inguinal hernia repair (LIHR) in children is a high ligation of the hernia sac from inside either in continuity using complete purse string suture or after complete dissection of the peritoneum around internal inguinal ring (IIR) to separate the distal hernia sac (like open herniotomy). The most widely used techniques for laparoscopic hernia repair are as follows: (1) Insertion of a complete purse-string suture around the internal inguinal ring with intra-corporeal knotting using either two laparoscopic instruments, or recently using only single laparoscopic instrument technique. (2) Complete separation of the peritoneum around the IIR to disconnect the distal hernia sac (dissection technique). (3) Percutaneous extra-corporeal ligation of the IIR under laparoscopic guidance [29, 30].

5.2.1. Intra-corporeal techniques

The first laparoscopic technique described for repair of inguinal hernia in children use three ports for the repair, two intra-peritoneal working instruments to make a complete purse string suture around the opened IIR, and a camera port. The technique started with insertion of the umbilical camera port by the open Hasson's technique. Then pneumoperitoneum was established to a pressure of 8–12 mm Hg according to age. Laparoscopic exploration of the pelvis and both internal inguinal rings were done. Then two 3-mm ports for the working

instruments (two laparoscopic needle holders) were inserted at the lateral borders of the rectus muscles at the level of the umbilicus. Non-absorbable 3-0 Prolene suture was used to make a complete purse suture around the opened internal inguinal ring, with intra-corporeal knot tying. The sutures include only the peritoneum with no underlying tissues. The contralateral IIR was closed if its diameter is more than 2 mm. This technique is not cosmetically superior in children, when compared to open herniotomy, which was performed through a small lower abdominal crease incision. Recently, in 2015, Helal modified this traditional laparoscopic hernia repair technique and introduced a novel technique for laparoscopic hernia repair using only single laparoscopic instrument (laparoscopic needle holder). The principle of his repair is the closure of the IIR with complete purse string suture using single laparoscopic needle holder instrument, with intra-corporeal knotting using single instrument tie. He reported that his novel technique is feasible, simple, secure, and more cosmetic. It permits extension of benefits of minimal access surgery. Also, he reported that it reduces operative time especially in bilateral cases and allows for quick return to normal activity of children (**Figure 5**) [18, 31, 32].

5.2.2. Percutaneous extra-corporeal technique

This technique entails percutaneous insertion of complete purse string suture using non-absorbable sutures around the IIR under laparoscopic guidance and the suture was tightened

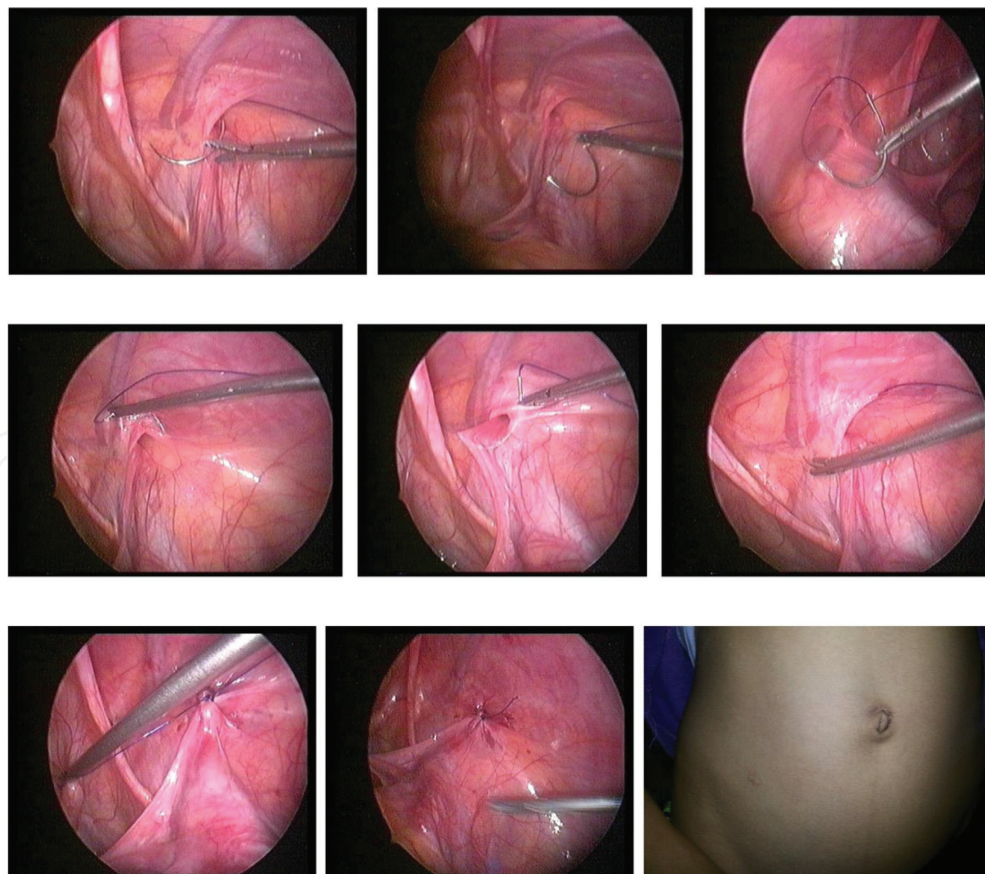


Figure 5. Steps of laparoscopic single instrument repair of inguinal hernia (Helal technique).

extra-corporeally and burred subcutaneously. The suture crosses over the spermatic duct or the gonadal vessels to avoid their injury. In girls, the round ligaments were not dissected, and it is included with the closure of the hernia sac. It is safe, effective, and reliable technique, with short operative time. It is suitable for laparoscopic surgeons that don't have a good experience in intra-corporeal laparoscopic suturing and tying techniques. However, the main concerns about this technique are the presence of the suture subcutaneously which may cause stitch granuloma or sinus formation. Also, the inclusion of the abdominal wall muscles with the suture may cause later losing of the suture or the suture may cut through the muscle which may increase the risk of hernia recurrence. The subcutaneous endoscopic assisted ligation (SEAL) technique entails percutaneous insertion of complete purse string suture around the IIR without any intra-peritoneal laparoscopic instrument. The technique was described by Ozgediz et al., and its main principles include passing a curved needle threaded with a 2/0 non-absorbable suture through the anterior abdominal wall under direct vision to surround the IIR peri-peritoneally in a U-shaped manner. The tip of the needle is grasped in a needle driver, and the heel of the needle is backed through the subcutaneous tissue to come out through the original stab incision. The suture is then secured and ligated subcutaneously. The needle may jump over the vas and vessels, and a peritoneal gap may be left untouched. This skip area is the cause of recurrence of hernia. However, if the size of the defect is extraordinarily wide, an additional instrument to assist guidance of the needle or conversion to open herniotomy is necessary. The steps of the technique are showed in **Figure 6**. The SEAL technique is then modified by injecting saline in the pre-peritoneal space for hydro-dissection to separate the peritoneum over the vas and the vessels [33, 34].

5.2.3. Single incision laparoscopic hernia repair

Recently, single incision laparoscopic surgery is advancing significantly, and nowadays, many laparoscopic surgeons prefer to perform most laparoscopic operations through several tiny incisions rather than one large incision, to improve the cosmetic outcome. At the

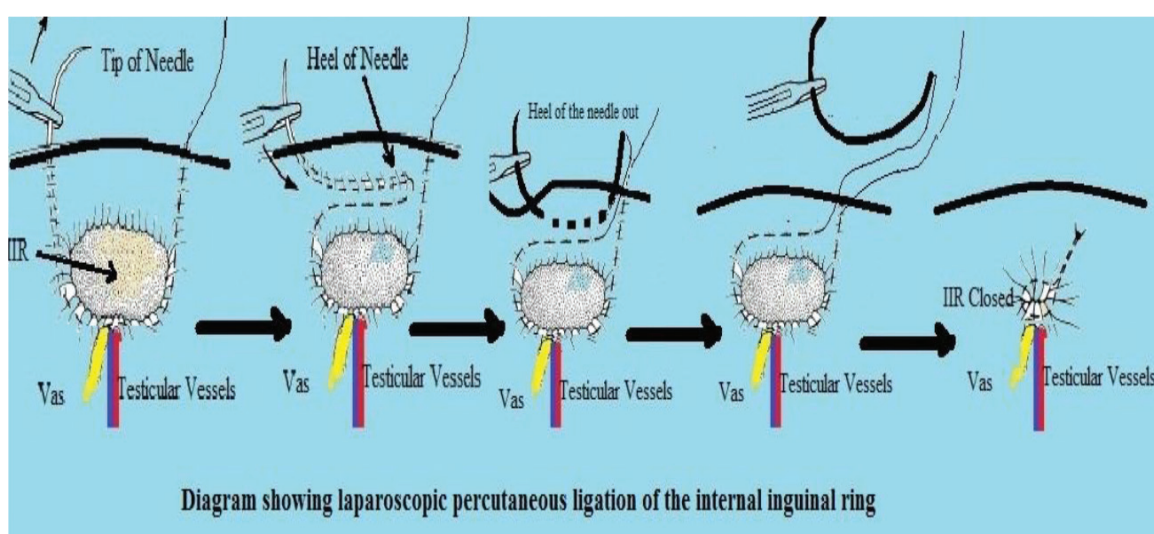


Figure 6. The steps of the subcutaneous endoscopic assisted ligation technique.

moment, single incision laparoscopic hernia repair (SILHR) has been well reported in the literature with many studies describing its feasibility and safety in children. SILHR is a newly developed technique for minimizing the post-operative pain, reducing the invasiveness of traditional laparoscopy, and reducing hospital stay with nearly scar less surgery. It is a new paradigm in minimally invasive surgery world. In our hospital, we perform laparoscopic inguinal hernia repair in children using the needlescopic assisted SILHR by using epidural needle gauge 18 to make complete purse string suture around the IIR, and we tied the suture extra-corporally using the self-sliding clinch knot (as shown in **Figure 7**) with an outstanding cosmetic results making great parent satisfaction. We think that there would be no reason to perform multiple incisions in laparoscopic hernia repair in children as SILHR is a safe and secure technique with excellent cosmetic results because it results in single umbilical wound which is already scar area in the body, the scar is hidden in the fold of the umbilicus, and the puncture wounds from the epidural needle are practically unnoticeable. Finally, SILHR in children is safe, perhaps even less technically demanded than open herniotomy [35–37].

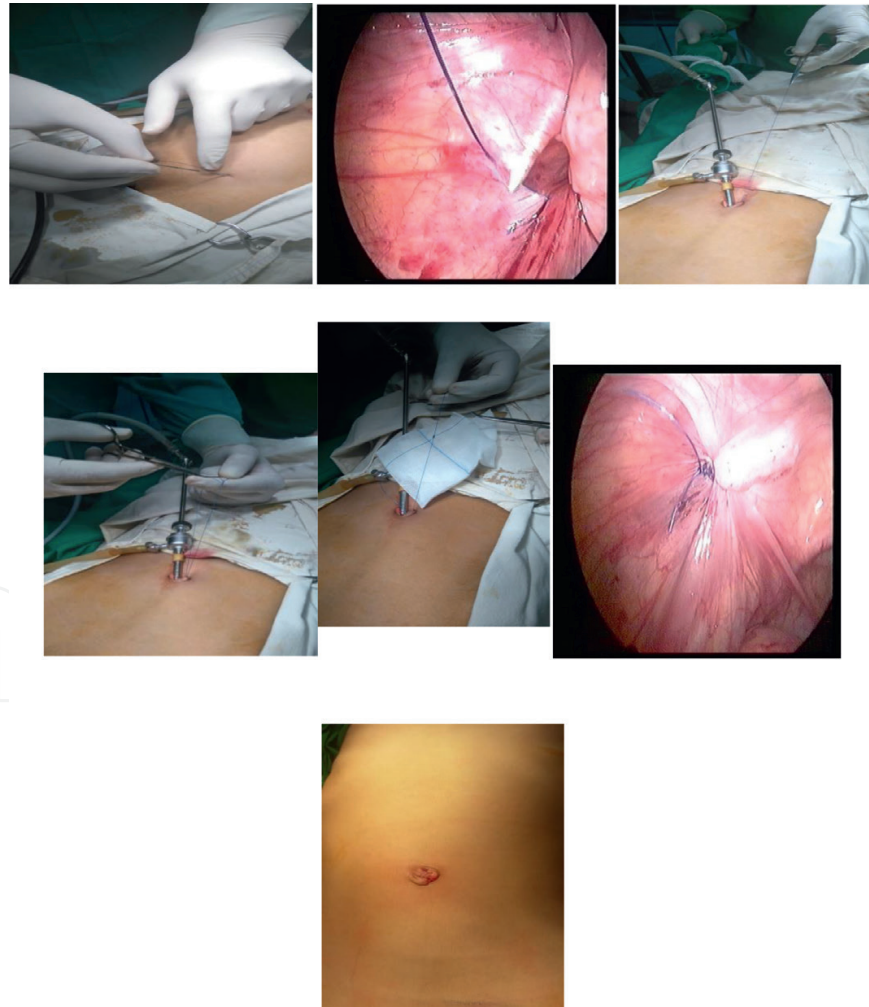

Figure 7. Single incision laparoscopic hernia repair in children with intra-corporeal knotting and finally the umbilical scar is practically unnoticeable.

6. Post-operative care

Most patients are discharged home on the same day after open or laparoscopic inguinal hernia repair. Small premature babies may need overnight observation and monitoring due to the risk of post-operative apnea. Post-operative follow-up after inguinal hernia repair requires only one clinic visit. Post-operative scrotal swelling and bruising for 1–2 weeks are very common, and they represent normal post-operative changes rather than a complication. Post-operative hydrocele (non-communicating) is not uncommon, and it usually reabsorbed spontaneously in 95% of the cases. Only major physical activity should be avoided after open or laparoscopic inguinal hernia repair in children for 1–3 weeks. Post-operatively, most children do well with acetaminophen alone, although the addition of non-steroidal anti-inflammatory drugs may be necessary for some children. The most common complications of herniotomy include injury to the vas deferens, iatrogenic cryptorchidism, and testicular atrophy. Iatrogenic cryptorchidism occurs in 0.6–2.9 % of patients. Injury to the vas deferens has been reported to occur in as many as 1.6% of patients. Testicular atrophy occurs in 1–2% and decreased testicular size in 2.7–13% of patients. Increased incidence of complications may present with inexperienced surgeons. Very rarely infertility may result from injury to both Fallopian tubes in girls subjected to bilateral herniotomy during childhood. Factors that may contribute to recurrence after congenital inguinal hernia repair include failure to ligate the sac high enough, tear in the sac or missing the posterior wall of the sac, leaving wide internal ring, and the presence of comorbid conditions (e.g., collagen disorders, severe malnutrition) [38].

7. Summary

Inguinal hernia in children can be a simple problem or a major catastrophe. True direct hernia is extremely rare in children. Recurrence of inguinal hernia in a child should be investigated for a general cause rather than a pure local reason. There is a difference between the hernia “sac” and the hernia “defect” which is actually a normal hiatus that allows passage of the cord structures or round ligament and should therefore not require repair *per se*. In fact, narrowing of a normal internal inguinal ring may cause entrapment of the cord structures. Instead, simple ligation and division of the hernia sac should allow the hiatus to close down to a normal functional size.

The open herniotomy through a lower skin crease incision is still the gold standard for inguinal hernia repair in children. It is very safe, well-tolerated, with low recurrence rate, leaving early invisible scar. On the other hand, at the moment the great advancement in laparoscopic techniques for inguinal hernia repair challenged this traditional operation, because of short operative time after learning curve, the untouched cord structure with increased fertility later on also allows it to rule out a contralateral PPV, finally the outstanding cosmetic results especially in female children, with great parent’s satisfaction. I hope to someday be proven that laparoscopic hernia repair in children will be a gold standard like laparoscopic cholecystectomy.

Incarcerated inguinal hernia is defined as obstruction to the blood supply of the hernia contents, and if not corrected within reasonable time (from 4 to 6 hours), gangrene will occur. Therefore, repair of inguinal hernia in children should be undertaken as soon as possible after diagnosis.

In case of incarcerated hernia if a trial of manual reduction is to be performed, the following precautions must be considered, the use of sedation is mandatory even anesthetic consultation may be needed in very irritable child, gradually increasing pressure for 2–3 min with short periods of rest for 1 min in between. Don't forget that during reduction of the incarcerated hernia, two edematous surfaces are being rubbed together (similar to that of two pickles). Tense hydrocele may be confused with an incarcerated hernia, and in such situation, urgent surgical exploration is mandatory without losing time in doing diagnostic investigations.

Laparoscopic hernia repair needs a learning curve especially in doing intra-corporeal suturing and knot tying which is the basic step in conventional laparoscopic approach; however, extra-corporeal self-sliding knot becomes a suitable solution for replacing traditional intra-corporeal suturing and knotting during laparoscopic hernia repair. It is very important for junior pediatric surgeons not to be in hurry to perform laparoscopic repair of inguinal hernia without mastering the open herniotomy and dealing with its different complications. Laparoscopic complete purse string suture around the internal inguinal ring is very sufficient for repair of inguinal hernia in children. However, laparoscopic dissection of the hernia sac is mandatory in recurrent cases and in the presence of very wide internal ring which needs repair of the muscular defect. Injection of saline will elevate the peritoneum over the vas and vessels and make a plane for the needle to pass safely. The needle sign is very important during laparoscopic repair of inguinal hernia in which the needle and the thread are clearly seen under the peritoneum. Inclusion of tissue with the suture around internal inguinal ring will cause later losing of the suture with increased recurrence rate.

Home message

- Congenital inguinal hernia is a common surgical problem in infants and children.
 - More than 98% of inguinal hernias in children are indirect hernias.
 - Incarcerated hernia if not managed within a reasonable time will lead to bowel necrosis and testicular atrophy.
 - History is very important aspect in diagnosis of inguinal hernia in children.
 - Hernias in children are usually painless, except if complicated.
-

Author details

Ahmed Abdelghaffar Helal

Address all correspondence to: helalhmada@yahoo.com

Department of Pediatric Surgery, Faculty of Medicine, Al-Azhar University, Cairo, Egypt

References

- [1] Becmeur F, Philippe P, Lemandat SA, et al. A continuous series of 96 laparoscopic inguinal hernia repairs in children by a new technique. *Surgical Endoscopy*. 2004;**18**:1738-1741

- [2] Bharathi RS, Arora M, Baskaran V. How we “SEAL” internal ring in pediatric inguinal hernias. *Surgical Laparoscopy Endoscopy & Percutaneous Techniques*. 2008;**18**:192-194
- [3] Bharathi RS, Arora M, Baskaran V. Minimal access surgery of pediatric inguinal hernias. A review. *Surgical Endoscopy*. 2008;**22**:1751-1762
- [4] Canes D, et al. Transumbilical single-port surgery: Evolution and current status. *European Urology*. 2008;**54**:1020-1029
- [5] Chang YT, Wang JY, Lee JY. A simple single-port laparoscopic assisted technique for completely enclosing inguinal hernia in children. *The American Journal of Surgery*. 2009;**198**:13-16
- [6] Chang YT. Technical refinements in single-port laparoscopic surgery of inguinal hernia in infants and children. *Diagnostic and Therapeutic Endoscopy*. 2010;1-6
- [7] Chen K, Xiang G, Wang H, Xiao F. Towards a near-zero recurrence rate in laparoscopic inguinal hernia repair for pediatric patients. *Journal of Laparoendoscopic & Advanced Surgical Techniques. Part A*. 2011;16
- [8] Chinnaswamy P, Malladi V, Jani KV, et al. Laparoscopic inguinal hernia repair in children. *Journal of Second Language Studies*. 2005;**9**:393-398
- [9] Chow A, Purkayastha S, Paraskeva P. Appendicectomy and cholecystectomy using single-incision laparoscopic surgery (SILS): The first UK experience. *Surgical Innovation*. 2009;**16**:211-217.
- [10] de Armas IA, Garcia I, Pimpalwar A. Laparoscopic single port surgery in children using Triport: Our early experience. *Pediatric Surgery International*. 2011;**27**:985-989
- [11] Dorsey JH, Sharp HT, Chovan JD, et al. Laparoscopic knot strength: A comparison with conventional knots. *Obstetrics & Gynecology*. 1995;**86**:536-540
- [12] Ein SH, Njere I, Ein A. Six thousand three hundred sixty-one pediatric inguinal hernias. A 35-year review. *Journal of Pediatric Surgery*. 2006;**41**:980-986
- [13] El-Gohary MA. Laparoscopic ligation of inguinal of inguinal hernia in girls. *Pediatric Endosurgery & Innovative Techniques*. 1997;**1**:185-187
- [14] Endo M, Watanabe T, Nakano M, et al. Laparoscopic completely extraperitoneal repair of inguinal hernia in children. A single-institute experience with 1257 repairs compared with cut-down herniorrhaphy. *Surgical Endoscopy*. 2009;**23**:1706-1712
- [15] Erez I, Rathause V, Vacian I, et al. Preoperative ultrasound and intraoperative findings of inguinal hernia in children: A prospective study of 642 children. *Journal of Pediatric Surgery*. 2002;**37**:865-868
- [16] George EK, Qudesluys MAM, Madern GC, et al. Inguinal hernia containing the uterus, fallopian tube and ovary in premature female infants. *Journal of Paediatric*. 2000;**136**:696-703

- [17] Giseke S, Glass M, Priyanka TP, et al. True laparoscopic herniotomy in children evaluation of long-term outcome. *Journal of Laparoendoscopic & Advanced Surgical Techniques Part A*. 2010;**20**:191-194
- [18] Helal AA. Laparoscopic single instrument closure of inguinal hernia in female children: A novel technique. *Journal of Pediatric Surgery*. 2015;**50**(9):1613-1616
- [19] Koivusalo AI, Korpela R, Wirtavuori K, et al. A single-blinded, randomized comparison of laparoscopic versus open hernia repair in children. *Pediatrics*. 2009;**123**:332-337
- [20] Kumar A, Ramakrishnan TS. Single port laparoscopic repair of pediatric inguinal hernias: Our experience at a secondary care centre. *Journal of Minimal Access Surgery*. 2013;**9**:7-12
- [21] Lee DY, Baik YH, Kwak BS, et al. A purse-string suture at the level of internal inguinal ring, taking only the peritoneum leaving the distal sac: Is it enough for inguinal hernia in pediatric patients? *Hernia*. 2015;1348-1347
- [22] Lukong CS. Surgical techniques of laparoscopic inguinal hernia repair in childhood: Critical appraisal. *Journal of Surgical Technique and Case Report*. 2012;**4**:1-5
- [23] Luo CC, Chao HC. Prevention of unnecessary contralateral exploration using the silk glove sign (SGS) in pediatric patients with unilateral inguinal hernia. *European Journal of Pediatrics*. 2007;**166**:667-669
- [24] McClain L, Streck C, Leshar A. Laparoscopic needle assisted inguinal hernia repair in 495 children. *Surgical Endoscopy*. 2014;**29**:781-786
- [25] Cam C, Celik C, Sancak A, et al. Inguinal herniorrhaphy in childhood may result intubal damage and future infertility. *Archives of Gynecology and Obstetrics*. 2009;**279**:175-176
- [26] Schier F. Laparoscopic inguinal hernia repair—a prospective personal series of 542 children. *Journal of Pediatric Surgery*. 2006;**41**:1081-1084
- [27] Parelkar SV, Oak S, Gupta R, et al. Laparoscopicinguinal hernia repair in the pediatric age group; Experience with 437 children. *Journal of Pediatric Surgery*. 2010;**45**:789-792
- [28] Patkowski D, Czernik J, Chrzan R. Percutaneous internal ring suturing: A simple minimally invasive technique for inguinal hernia repair in children. *Journal of Laparoendoscopic & Advanced Surgical Techniques Part A*. 2006;**16**:513-517
- [29] Ponsky TA, Diluciano J, Chwals W, et al. Early experience with single-port laparoscopic surgery in children. *Journal of Laparoendoscopic & Advanced Surgical Techniques Part A*. 2009;**19**:551-553
- [30] Rothenberg SS, Shipman K, Yoder S. Experience with modified single-port laparoscopic procedures in children. *Journal of Laparoendoscopic & Advanced Surgical Techniques Part A*. 2009;**19**:695-698
- [31] SarangaBharathi R, Arora M, Baskaran V. Pediatric inguinal hernia: Laparoscopic versus open surgery. *Journal of Second Language Studies*. 2008;**12**:277-281

- [32] Schier F. Laparoscopic herniorrhaphy in girls. *Journal of Pediatric Surgery*. 1998;**33**:1495-1497
- [33] Ozgediz D, Roayaie K, Lee H, et al. Subcutaneous endoscopically assisted ligation (SEAL) of the internal ring for repair of inguinal hernias in children. Report of a new technique and early results. *Surgical Endoscopy*. 2007;**21**:1327-1331
- [34] Tural S, Enders J, Krause K, Schier F. Laparoscopic inguinal herniorrhaphy in babies weighing 5 kg or less. *Surgical Endoscopy*. 2011;**25**:72-78
- [35] Uchida H, Kawashima H, Goto C. Inguinal hernia repair in children using single-incision laparoscopic-assisted percutaneous extraperitoneal closure. *Journal of Pediatric Surgery*. 2010;**45**:2386-2389
- [36] Yang C, Zhang H, Pu J, et al. Laparoscopic vs open herniorrhaphy in the management of pediatric inguinal hernia: A systemic review and meta-analysis. *Journal of Pediatric Surgery*. 2011;**46**:1824-1834
- [37] Helal AA. Single incision laparoscopic closure of inguinal hernia in female children: a simplified technique. *Mini-invasive Surg* 2017 May 23.
- [38] Zallen G, Glick PL. Laparoscopic inversion and ligation inguinal hernia repair in girls. *Journal of Laparoendoscopic & Advanced Surgical Techniques*. 2007;**17**:143-145