

We are IntechOpen, the world's leading publisher of Open Access books Built by scientists, for scientists

4,800

Open access books available

122,000

International authors and editors

135M

Downloads

Our authors are among the

154

Countries delivered to

TOP 1%

most cited scientists

12.2%

Contributors from top 500 universities



WEB OF SCIENCE™

Selection of our books indexed in the Book Citation Index
in Web of Science™ Core Collection (BKCI)

Interested in publishing with us?
Contact book.department@intechopen.com

Numbers displayed above are based on latest data collected.
For more information visit www.intechopen.com



Minimally Invasive Esophagectomy

Rafael Cholvi Calduch, Isabel Mora Oliver,
Fernando Lopez Mozos and Roberto Martí Obiol

Additional information is available at the end of the chapter

<http://dx.doi.org/10.5772/intechopen.69584>

Abstract

Minimally Invasive Surgery (MIS) for esophageal carcinoma has improved the outcome of patients. This approach has been shown to decrease the rate of respiratory complications, the intensive care unit (ICU) stay, and to allow a faster recovery of patients. Also, an improvement in perioperative care has contributed to better outcomes compared to the open approach. MIS has been shown to be as safe as open surgery in terms of resectability, harvested lymph nodes, and overall survival.

Keywords: esophageal carcinoma, anesthesia, minimally invasive esophagectomy, thoracoscopic esophagectomy, laparoscopic esophagectomy, surgical technique, prone position, postoperative care, postoperative prognosis

1. Introduction

Neoplasm of the esophagus is one of the most aggressive diseases with poor survival rate despite of the improvements in staging procedures, multimodality treatments, supportive care, and surgical techniques. It is the eighth most common cause of cancer and the sixth leading cause of cancer death worldwide [1]. Patients often are diagnosed at an advanced stage with metastatic disease in more than 50% at the time of presentation. Surgery is the gold standard for treatment both for early stage disease and for advanced disease after chemoradiotherapy neoadjuvant treatment. Surgery of esophageal cancer is probably one of the most demanding and challenging procedure for the surgeon and the patient alike—with a significant morbidity and mortality, particularly in inappropriately selected patients. Surgical treatment must consist on a radical R0 en-bloc esophagectomy associated with a two-field lymphadenectomy [2].

Traditionally, open approaches have been used to resect esophageal cancer, performed by transhiatal, transthoracic, or combined approach. Esophagectomy is a complex challenge for the surgeon, dealing with wide areas of the neck, mediastinum, and abdomen. Open esophagectomy is considered to be one of the most traumatic oncologic procedures performed in gastrointestinal surgery because of the extent of resection and dissection required [3]. It entails a significant risk of morbidity (at least a half of patients develop complications) and mortality, that ranges from 6–7% in high-volume centers to 20–28% in low-volume centers.

Orringer et al. [4] reported a large series of 1085 patients who underwent open esophagectomy by transhiatal approach, which has served as a standard to compare postoperative outcomes: hospital mortality rate of 4%; 53% of patients were discharged by 10th postoperative day; and an anastomotic leak rate of 13%. The most frequently reported complications of open approach have been pneumonia (21%), respiratory failure (16%), prolonged ventilatory support more than 48 h (22%), according to the report published by Bailey et al. [5].

In an attempt to avoid extensive tissue aggression and reduce the high morbidity and mortality, the minimal invasive approach has been introduced in the field of gastroesophageal surgery [6]. Cuschieri et al. [7] and DePaula et al. [8] were the first to apply a laparoscopic approach to patients with esophageal cancer. Cuschieri et al. performed six subtotal endoscopic esophagectomies through a right thoracoscopic approach with a mean duration of stay in the ICU of 19 h (range 16–26 h) and a median hospital stay of 11 days (8–18 days). DePaula et al. reported a small series of 12 patients who underwent transhiatal esophagectomy conducted by videolaparoscopy with no mortality and minimal blood loss.

Thanks to the improvements in technology and instrumentation, as well as the surgeons' training in advanced minimally invasive procedures, the practice of this technique has been extended since the 1990s. There are several single institution series reports [7–10] (retrospective and prospective) comparing Minimally Invasive Esophagectomy (MIE) versus open surgery [11, 12], and recent meta-analyses [13, 14] that have confirmed the safety and feasibility of the procedure and the advantages of minimally invasive surgery. These reports show that MIE can reduce the mortality and morbidity of open operations as well as allow a faster recovery. All these findings have been confirmed at the only available level I evidence study, the TIME-trial [15].

2. Patient selection

Tumor staging is essential for planning surgical treatment, and surgery should not be performed for patients without a chance of cure, such as those with distant metastases, or in those unable to survive the physiologic insult of the operation. The main objective of surgery must be to achieve a R0 resection. Nowadays, neoadjuvant chemoradiation plays a key role because it downstages the tumor and allows an adequate micro and macroscopic tumoral resection. From a surgical perspective, the drawback is that it may further complicate the procedure by distorting the peri-esophageal microanatomy and by causing a significant postradiation fibrosis. Tissue plane may be unclear and surgery will not be easy in this situation.

The difficult dissection as a result of neoadjuvant therapy and surgeons' fear to use a minimally invasive approach in advanced tumors, especially during their learning curve, cause an important discussion about MIE effectiveness in these situations. In a multicenter, open-label, randomized controlled trial published in 2012 by Biere et al. [15] that compares open surgery with MIE in advanced tumors, both with a similar number of patients, did not show significant differences between both in terms of margins resection. Thus, the minimally invasive approach would not be a contraindication in advanced stages. However, a previous history of abdominal or thoracic surgeries due to a significant underlying adhesion process could represent a real hindrance for minimally invasive technique.

3. Evaluation of physiological reserve

Predicting which patients are going to develop complications is not easy. Even so, we must know which indicators can increase postoperative morbidity and mortality. Many risk factors have been identified: Karnofsky score less than 80, liver cirrhosis, chronic obstructive pulmonary disease (COPD), ischemic heart disease, advanced age, locally advanced tumor, active smoking, alcoholism, and malnutrition [16–19] are some of them. Evaluating individual risk is important for patient selection and a proper preoperative management, regardless of the surgical approach to be performed (MIE or open surgery). However, there are physiological conditions of patients that cannot be improved.

The risk factors suggestive of preoperative optimization are the following:

- In cases of COPD, the use of long-acting β -agonists, combined with inhaled steroids [20, 21] and preoperative inspiratory muscle training, may reduce postoperative pulmonary complications [22].
- If significant coronary ischemia is discovered in perioperative time, coronary revascularization with angioplasty and stenting could be performed, although antiplatelet agents prescribed after this technique could delay esophagectomy.
- Alcoholism and smoking—The UK National Institute for Health and Clinical Excellence (NICE) recommends the use of nicotine as a replacement therapy for smokers to help stop smoking, because smoking is associated with higher risk of 30-day mortality and serious postoperative complications [23].
- Malnutrition is considered an independent risk factor that influences the development of postoperative infections, mortality, length of stay, and hospital costs in patients undergoing surgery [24]. We must bear in mind that most patients with esophageal neoplasia have difficulties for an adequate intake, which generates poor nutritional status and immunosuppression. Therefore, patients with nutritional risk screening (NRS) score ≥ 3 should have an optimized nutritional support that includes both enteral nutrition to maintain the intestinal barrier function and parenteral nutrition to avoid malnutrition and infection due to long-term insufficient feeding. These measures will help to improve clinical outcomes in these patients [25, 26].

- Patients who have a Forced Expiratory Volume in one second (FEV 1) < 70% of the predicted normal in the pulmonary function tests with normal arterial gas blood measurements are considered of moderate risk and those with FEV 1 < 50% or if the arterial gas blood analysis show hypoxemia or carbon dioxide retention must be considered of high risk.
- Patients with Child C stage cirrhosis must not be eligible for surgery.

4. Anesthetic challenges of MIE

The anesthetic challenges of MIE include prolonged surgery, difficulties of lung isolation, and one lung ventilation (OLV) when patient is positioned right up and complications related to extraperitoneal CO₂. Pain relief has been described as a protective factor to avoid postoperative respiratory complications, so it is highly recommended to use regional techniques for reducing postoperative pain. Also, the amount of fluids administered perioperatively can lead to the development of pulmonary complications and should be adequately evaluated to avoid fluid overload.

4.1. Prolonged surgery

MIE is a long procedure and may extend at least 5–6 h, depending on the experience of the surgeon. Such prolonged surgery increases the risk of hypothermia which can lead to reduce oxygen delivery and increase myocardial work, stress response, and postoperative infection. Our main objective is to maintain normothermia. If at the end of the surgery the patient is normothermic, extubation will be possible and postoperative ventilation will not be necessary [27].

Balanced anesthesia, by an inhalation approach (sevoflurane and desflurane) or by propofol target-controlled infusion with remifentanyl, may help promote early recovery after MIE. There is evidence that both sevoflurane and desflurane, when compared with propofol, produce a beneficial local immunomodulatory effect in patients undergoing OLV for thoracic surgery, significantly reducing inflammatory mediators, adverse postoperative events, and improving clinical outcomes [28, 29].

4.2. One lung ventilation

MIE with a patient in right up position requires a period of one lung ventilation during the mobilization of thoracic esophagus. Inadequately managed lung isolation contributes to mortality and morbidity [30].

When surgery is performed thoroscopically, retraction of an inadequately collapsed lung or lobe results more difficult than in open surgery, and this is important when choosing the method used to achieve lung isolation. The options described to reach an adequate lung isolation are a left or right double lumen tube or a single lumen tracheal tube and a bronchial blocker. A retrospective study has not found differences in intraoperative hypoxemia, hypercapnia, and high airway pressures whether a left- or right-sided tube was placed for OLV [31].

As a consequence most MIE techniques involve access to the right thorax; a left double-lumen tube perhaps would be preferable, especially when the thoracic approach is done in lateral decubitus. If we used the prone position (PP), a single-lumen endotraqueal tube is a valid alternative. Whichever method of lung isolation is selected, a fiberoptic bronchoscope should be used to check correct positioning both after intubation and after moving the patient before surgery [32].

The combination of OLV and esophageal surgery results in an inflammatory response that will increase alveolar injury, leading to the development of acute lung injury (ALI) [33]. During and after OLV, the alveolar concentrations of IL-6 and IL-8 are increased. The lung protective ventilatory strategy can reduce airway pressure and airway resistance. It can decrease the release of IL-6 and IL-8 and inhibit lung inflammatory response during OLV and postoperatively [34]. Some of the consequences that may cause ventilator-induced lung injury are volutrauma (high tidal volume), barotrauma (excessive transpulmonary pressure), atelectrauma (repeated opening and closing of alveoli resulting), and biotrauma (caused by inflammatory mediators) [35].

Thus, it is essential for the implementation of protective ventilatory strategies to reduce the severity of lung injuries during mechanical ventilation. These strategies include restrict tidal volume to 5–6 ml/kg during OLV, optimizing positive expiratory end pressure (PEEP), and limiting plateau and peak inspiratory pressures to less than 25 cm H₂O and less than 35 cm H₂O, respectively [36]. In addition to reduce lung injury, these actions promote early extubation [37].

4.3. Complications of extra-peritoneal carbon dioxide

MIE may require a large period of capnoperitoneum, while laparoscopic dissection and mobilization of the stomach are being performed. As a consequence of surgical communication between the chest and abdomen, carbon dioxide may pass into the right chest, where drain tube has been placed in thoracic step, and this gas can be vented by this drain. In this situation, laparoscopic abdominal dissection could be difficult. Moreover, carbon dioxide may diffuse into the mediastinum (capnomediastinum), into the left chest, and it can cause subcutaneous emphysema around the chest, axilla, and neck. We can realize that gas is spreading to these spaces if we object a rapid increase in end-tidal CO₂. If CO₂ is accumulated inside thorax cavity, an increase of airway pressures and lung compression might occur, leading to oxygen desaturation. This fact could negatively affect cardiac output.

We can solve all these problems by reducing the pressure at which the capnoperitoneum is maintained, and this will reduce the diffusion of gas to thoracic cavity without impairing abdominal dissection. Anyway, if extra-abdominal CO₂ compromises cardiac or respiratory function, the capnoperitoneum should be evacuated. We should not extubate patients with significant emphysema until we achieve normocarbia [27].

4.4. Fluid management—goal directed therapy (GDT)

Maintaining adequate fluid balance is essential in both open surgery and MIE. While excessive fluid administration may be associated with increased postoperative pulmonary complication,

tissue edema, and compromised perfusion, an inadequate intravascular volume can predispose to ischemia, end-organ dysfunction, and risk of anastomotic failure and leak.

In esophagectomy patients, an accurate fluid balance is essential to achieve adequate perfusion pressure and oxygen delivery to vital organs. The form of fluid replacement therapy, which is currently recommended, seems to be based on the principles of goal-directed therapy (GDT) with the aim to increase cardiac output in high-risk surgical patients. Various studies have found that GDT-based fluid administration improves intraoperative hemodynamic stability and reduces intensive care unit admissions, the incidence of complications, and mortality [38].

Some authors have suggested that restrictive fluid therapy is preferable to fluid overload because it leads to improved gastrointestinal recovery time, reduced overall morbidity [39], improved respiratory parameters, decreased incidence of postoperative pulmonary complications and shorter recovery periods [40]. On the other hand, fluid overload causes lung injury and has negatively impact to intestinal anastomoses [41].

4.5. Thoracic epidural analgesia (TEA) versus paravertebral analgesia

Even with reduction in trauma access, MIE may still result in an important postoperative pain, and optimal multimodal analgesia is required. Effective analgesia accelerates extubation, recovery, and early mobilization. Despite the importance of regular postoperative simple analgesia, a regional technique is essential.

Thoracic epidural analgesia (TEA) offers many benefits in esophagectomy, reducing respiratory complications, such as pneumonia [42–44] and postoperative pain. TEA has also been associated with decreased incidence of anastomotic leakage [37], possibly as a consequence of improving microcirculation in the gastric conduit [45]. Moreover, epidural analgesia also decreases the risk of prolonged ventilation or reintubation and improves some lung function parameters and blood oxygenation [46]. However, TEA also has some disadvantages: the incidence of failure may reach 12%, there are risks in the application technique, and it does not only promote urinary retention but also cause hypotension which makes necessary additional fluid administration [47–49]. Contraindications to an epidural access include sepsis or bacteraemia, infection at the insertion site, hypovolemia or shock, coagulopathy or thrombocytopenia and increased intracranial pressure [50].

Paravertebral blockade has recently been shown to provide analgesia comparable with TEA after thoracic step of esophagectomy. It is associated with less incidence of failed block and reduces hypotension and urinary retention when it is compared with TEA. Several recent reviews and meta-analyses defend its benefits [51–53], and it is a standard practice in some UK hospitals for minimally invasive esophagectomy. Local data also show shorter stays in the intensive therapy unit comparing with TEA.

4.6. Conclusion

MIE supposes many anesthetic challenges, some of them unique for this type of procedure and requires an accurate knowledge of the different surgical steps performed. Moreover, it is

essential to know and treat complications of one lung anesthesia and extra-peritoneal spread of CO₂. Paravertebral blockade might have more benefits than TEA to improve postoperative pain in patients undergoing for MIE.

5. Operative technique

Minimally invasive esophageal resection for cancer involves a three-stage operation that includes a thoracoscopy and laparoscopy, either with a cervical or intrathoracic anastomosis. It has been described as different combinations of laparotomy, thoracotomy, thoracoscopy, and laparoscopy approaches called hybrid techniques. These techniques have 1 step of the procedure completed via an open approach.

5.1. Thoracoscopy phase

The operation starts with thoracoscopic mobilization of the esophagus and thoracic lymphadenectomy. The thoracic phase can be performed through a lateral right thoracic approach by blocking the right tracheal bronchus, or in prone position without selecting any blocking.

In the first case, the patient is positioned in the left lateral decubitus position (LDP) and a right lung blocking is achieved employing a double-lumen tube. The surgeon stands on the left side of the patient and the assistant on the right. Three to four thoracoscopic ports are used in this approach and placed as follows:

- 10-mm camera port is placed at the 7th to 8th intercostal space, just anterior to the midaxillary line.
- A 5-mm port is placed at the 8th or 9th intercostal space, posterior to the posterior axillary line.
- A 10-mm port is placed at the 4th intercostal space in the anterior axillary line.
- The last 5-mm port is placed just posterior to the scapula tip.

When thoracoscopy is performed in a prone position (**Figure 1**), the mobilization of the esophagus takes place with a right prone posterior approach. Patients are intubated with a single-lumen endotracheal tube and the right lung remains partially collapsed because of the positive pressure of pneumothorax created and due to the gravity. The right upper limb is abducted 80–100°. The surgeon stands on the right side of the patient, the first assistant (camera) to the left of the surgeon, and the second assistant stands on the left side of the patient. Three ports are used and placed as follow:

- 10-mm camera port is placed at the 7th intercostal space below the inferior angle of the scapula.
- 5–10 mm port for right-hand working is placed at the 5th intercostal space right lateral from the spinous process.
- 5 mm for left-hand working is placed at the 9th intercostal space right lateral from the spinous process.

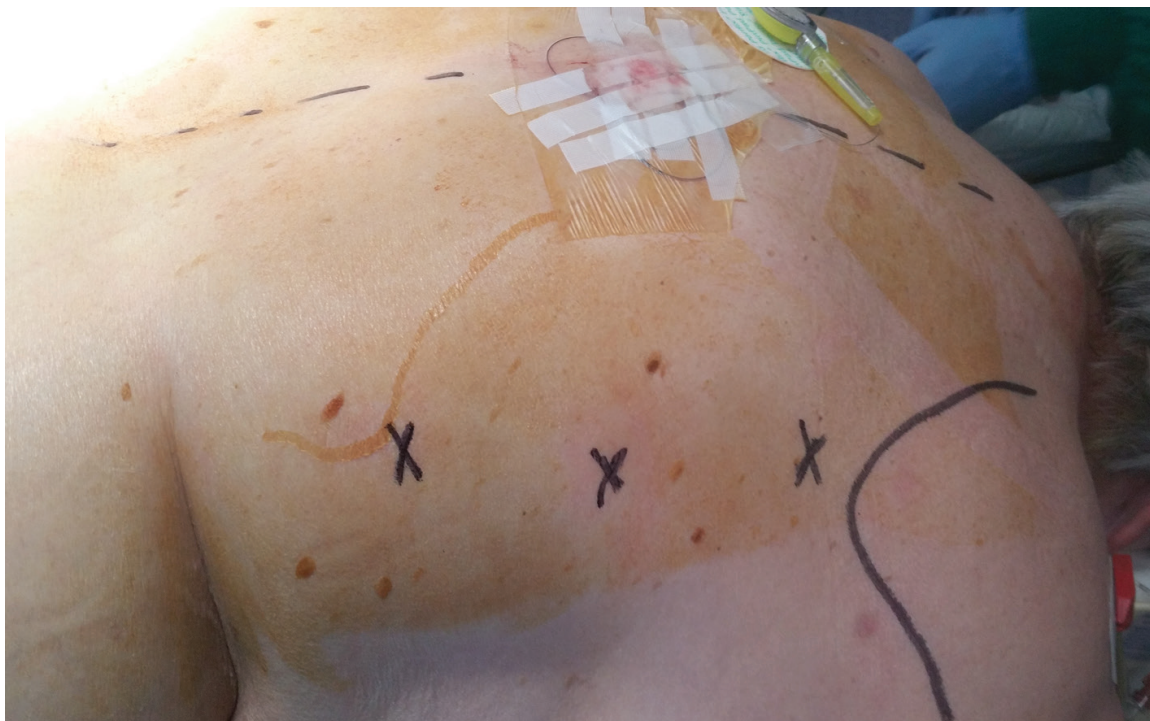

Figure 1. Thoracic trocar position on the right chest for thoracoscopic esophagectomy.

Pneumothorax is created and the insufflation pressure must be maintained at 6–8 mmHg. A single retracting suture in the diaphragm could be used to provide downward traction allowing good exposure of the distal esophagus, although in most occasions this is not necessary.

After a general survey of the tumor area and pleura, the inferior pulmonary ligament and the mediastinal pleura over the esophagus are divided up to the level of the azygos vein (**Figure 2**), which is sectioned with an endoscopic vascular stapler. The proximal esophagus is exposed and dissected circumferentially up to the level of 1–2 cm above the carina, using 5-mm harmonic shears, from the pericardium, chest wall, descending thoracic aorta, and superior cava vein, including all surrounding lymph nodes (**Figure 3**), periesophageal tissue, and fat. A tape is used for retraction of the esophagus to facilitate the dissection around it. Any aorto-esophageal vessel and any lymphatic branches must be clipped. The thoracic duct has to be protected. The vagal trunks are identified and divided.

The dissection should be performed near the esophagus to avoid trauma to the posterior membranous trachea and the recurrent laryngeal nerves, which is the most difficult step. Laterally, dissection is carried down to the left pleura and continues to the thoracic inlet. A careful lymph nodal clearance must be achieved in the supracarinal space. Mobilization of the distal esophagus poses no problem, and it is important to limit it in order to avoid difficulty in maintaining pneumoperitoneum during the abdominal phase.

After the placement of a chest tube, the right lung is allowed to expand fully (or inflated in left lateral decubitus approach). Some surgeons infiltrate intercostal spaces with local anesthetic. Trocars are removed, and ports are closed.

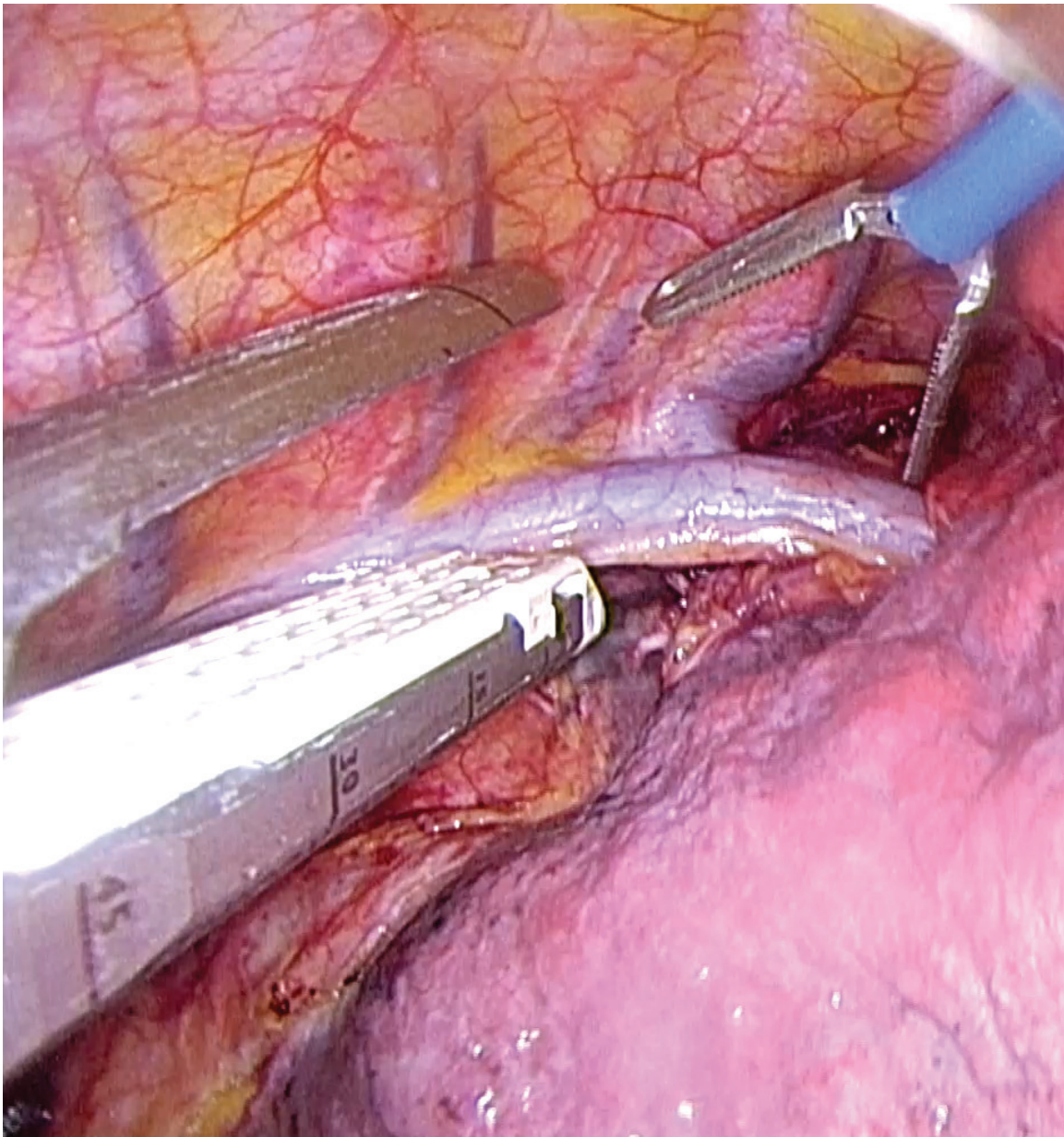


Figure 2. Division of the azygos vein using a stapler.

5.2. Laparoscopy and cervical phase

The second stage starts turning the patient to a modified Lloyd-Davis position with reverse Trendelenburg and neck exposing the left cervical area. The surgeon remains between the legs of the patient. The first and second assistants stand to the right and to the left of the patient, respectively. Five abdominal ports are used for the dissection: 10-mm supraumbilical port for camera; 5 mm epigastric port for retraction of left lobe of the liver, 5–10 mm right midclavicular port for left-hand working; 5–10 mm left midclavicular port for right-hand working; and 5–10 mm left anterior axillary port for gastric retraction. It is advisable to use trocars of a diameter of 10 mm for the possibility of using staplers from any port.

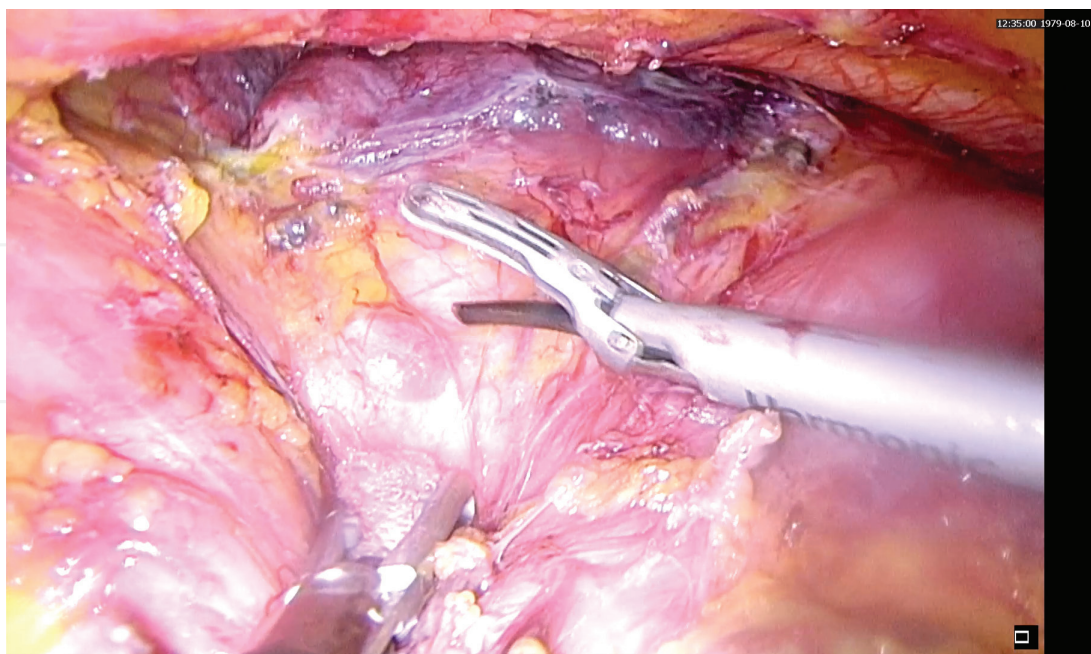


Figure 3. Mediastinal periesophageal lymph node.

After placement of the ports, an abdominal general survey must be performed. The gastrohepatic omentum is divided; the right and left crura of the diaphragm are dissected to allow easy passage of the gastric tube through the hiatus (preventing later gastric outlet obstruction). Left gastric artery and vein are dissected and divided using an endoscopic stapler with vascular load and a careful lymph node clearance over the left gastric pedicle, celiac axis, common hepatic, and splenic artery must be achieved. The stomach is mobilized by dividing the short gastric vessels in the gastrocolic omentum, using ultrasonic coagulating shears taking care of preserving the right gastroepiploic arcade. The fundus is dissected from the superior pole of the spleen and the pancreaticogastric ligaments are divided. Authors do not recommend pyloroplasty since it has been widely demonstrated that this does not improve gastric emptying.

Then the gastric tube is constructed with the stapler by dividing the stomach starting at the lesser curve. The construction of the gastric tube may vary depending on the characteristics of the tumor (if the tumor is located in the gastroesophageal junction or it has gastric extension, it may be necessary to resect some of the proximal stomach and to make an intrathoracic anastomosis). It is preferably a gastric tube with 5–6 cm in diameter. Most of the groups place a feeding jejunostomy laparoscopically. Authors prefer to leave a nasojejunal feeding tube to avoid complications derived from a jejunostomy.

The phrenoesophageal membrane is dissected, and gastric conduit is pulled through posterior mediastinum and brought up to the neck. Torsion is avoided by ensuring that the greater curvature always lies toward the left crus.

The last stage consists of a careful dissection of the cervical esophagus. A 4–6 cm left skin crease cervical incision is made. The tape looped around the esophagus left during the thoracic

dissection allows the surgeon to pull it out through the neck to facilitate the dissection. The esophagogastric specimen is pulled out of the neck incision and the esophagus is transected 2–3 cm distal to the upper esophageal sphincter. A very high anastomosis is performed between the cervical esophagus and gastric tube in an end-to-end manner using an End-to-end anastomosis stapler (EEA stapler) or something similar. Some groups suture the gastric conduit to the prevertebral fascia. Neck wound is closed and a cervical drain could be placed. To prevent hiatal herniation, laparoscopic tacking sutures between the gastric tube and the diaphragm should be placed. If the anastomosis is performed intrathoracically, cervical stage is not performed.

Some groups pull out the specimen through a minilaparotomy incision incorporating camera port, and they construct the gastric tube in an extracorporeal way. This is recommended in cases of bulky tumors because it facilitates extraction of the specimen and allows to achieve a longer gastroplasty in case of performing the anastomosis in the neck.

One tube-drain is placed close to the hiatus. Trocars are removed, and ports are closed.

6. Minimally invasive surgery versus open approaches

Minimally invasive esophagectomy emerges as an attempt to reduce the significant morbidity and mortality of classic open techniques and allows a faster recovery of the patient.

Different groups have reported their experience in implementation of minimally invasive surgery in esophageal cancer in order to assess the potential advantages and disadvantages. One of the largest series was published by Luketich et al. [9]. They showed their outcomes in 222 patients after MIE: 30-day operative mortality of 1.4%, median intensive care unit stay of 1 day (range 1–3), hospital stay of 7 days (range 3–75), lower incidence of pneumonia, and adult respiratory distress syndrome (ARDS) (7.6 and 5%, respectively); anastomotic leak rate of 11.7%; and excellent health-related quality of life (HRQL) scores at a mean follow-up of 19 months, showing that MIE is a safety procedure and have potential advantages over open approach. Palanivelu et al. [10] reported their experience in 130 patients who underwent MIE with prone thoracoscopy: median ICU stay of 1 day (range 1–32 days), median hospital stay of 8 days (range 4–68 days), postoperative morbidity of 20.76%, perioperative mortality of 1.54%, anastomotic leak rate of 2.31%, lower incidence of pneumonia, and ARDS (1.54 and 0.77%, respectively), minimum blood loss. Both series showed a stage-specific survival similar to an open approach.

These findings have been confirmed in a recent meta-analysis [13] of 57 studies containing 15,790 patients with resectable esophageal cancer. Less intraoperative blood loss, short hospital stay, reduction of the incidence of total and pulmonary complications (OR: 0.700, 95% CI 0.626–0.781 and OR: 0.527, 95% CI: 0.431–0.645, $p < 0.05$, respectively), and high operative time than Open esophagectomy were found. However, ICU stay, the number of harvested lymph nodes, and anastomotic leak had no significant differences.

As we have mentioned previously in this chapter, traditional open esophagectomy carries a significant risk of postoperative complications that involves a profound detrimental impact on

patient's quality of life. Quality of life typically returns to baseline after 1 year [54]. Minimally invasive techniques avoid thoracoabdominal incisions and reduce the levels of tissue trauma. The recovery rate after minimally invasive esophagectomy seems to be faster than after open approach. Parameswaran et al. [11] assessed this question in a prospective longitudinal non-randomized study in 62 patients, measuring health-related quality of life (HRQL) after MIE. Their study noticed that although patients reported marked deterioration in most aspects of HRQL 6 weeks after the operation, they started to recover by 3 months and returned to baseline levels by 6 months, except reflux and diarrhea.

There is concern about if oncologic outcomes are equivalent to that of the open approach. When minimally invasive surgery was introduced in the management of colorectal cancer, there was also a concern about safety and oncological quality of resections. However, several randomized prospective trials demonstrated that the laparoscopic approach was not only safe but also oncologically sound [12].

While the advantages over short-term postoperative outcomes have been widely published by different institutions, there is a lack on the available data about oncologic efficacy and survival after MIE compared with the open approach. Different groups have tried to demonstrate that the adequacy of surgical margins and lymphadenectomy can be maintained or even improved with a MIE approach [55]. Berger and colleagues [12] found in their retrospective review that there were no differences between the groups in the R0 resection rates and a significant increase in nodal harvest in the MIE group (median 20 versus 9; $p < 0.0001$). Because of the known impact of neoadjuvant treatments on lymph node yields, they also examined lymph node harvest by the presence or absence of neoadjuvant chemoradiation, and they did not find differences in both groups. However, patients in the open group had a more advanced stage disease, and most of them had received neoadjuvant treatments.

The same group published a later work, Palazzo et al. [56], that compares survival of patients undergoing MIE and open or hybrid esophagectomy (OHE) in a retrospective analysis. They found on Kaplan-Meier univariate analysis, a significantly improved 5-year survival with MIE (MIE 64%, OHE 35%, $p < 0.001$) and after adjusting for potential confounding factors (lymph nodes harvested, neoadjuvant treatments, stage, etc.) in a multivariate analysis demonstrated that patients undergoing OHE had a significantly worse survival. They made the same selection bias as in their previous study.

Nevertheless, these results are based on nonrandomized small series with heterogeneous data and could be affected by patient selection bias (frequently MIE group include a higher number of patients who have early disease stages and thus, less patients who received neoadjuvant chemoradioterapy). Advanced tumors and the use of neoadjuvant therapy have been considered to be contraindications to MIE by many surgeons and limited its use, especially in patients with advanced disease.

All these studies have culminated in TIME-trial published in *The Lancet* in 2012 by Biere et al. [15, 57]. It is the first randomized trial to investigate the potential advantages of minimally invasive esophagectomy. They undertook a multicenter, open-label, randomized controlled trial at five study centers in three different countries. They compared open with minimally

invasive esophagectomy with a right thoracoscopy in the prone position in a total of 115 patients with resectable esophageal cancer, excluding cervical allocation. The results showed that significantly fewer patients had postoperative pulmonary infections, shorter hospital stay, and less blood loss in the minimally invasive group than in the open group. No difference was found in ICU stay. Also, short-term postoperative quality of life measured by SF 36, EORTC C30, and esophageal-specific OES18 questionnaire were significantly better for patients in the minimally invasive group, and they had less pain according to the Visual Analogue Scale (VAS) pain score. However, pathological parameters of the resected specimen and 30-day and in-hospital mortality did not differ between groups. They concluded that patients undergoing the minimally invasive approach have short-term benefits in pulmonary infections, hospital stay, and quality of life outcomes with no compromise in the quality of the resected specimen.

More randomized clinical trials are needed in order to assess the long-term advantages of minimally invasive surgery.

7. Prone position versus lateral decubitus position for thoracic step

To minimize morbidity and mortality after an esophagectomy, a thoracoscopic approach was introduced as a minimally invasive option [58, 59]. This procedure is most commonly performed with the patient in the left lateral decubitus position, but prone position is a valid alternative. Cuschieri et al. [60] first explained the prone position (PP) for thoracoscopic esophageal mobilization in 1994. They described this technique in 6 patients and compared the results with those of left lateral position in 20 patients. They suggested that PP had technical advantages and reduced postoperative complications. However, this technique was not widely used at that time, and more than 10 years have passed by to find publications that talk about PP again. In 2006, Palanivelu et al. [10] reported their experience with 130 patients treated by thoracoscopic esophagectomy in PP raising new interest in this procedure. Many reports about that have been published so far.

The primary benefit of the PP is derived from the anatomical exposure: the lung falls away as a consequence of gravity and the esophagus is better visualized. This permits performance of the operation without the need for collapsing the right lung using a double-lumen endotracheal tube. If we use a single-lumen endotracheal tube, the partial or intermittent ventilation of the right lung reduces the venous shunt effect and results in opening up a great percentage of the alveoli helping in prevention atelectasis. Moreover, this type of ventilation does not make difficult the surgical procedure or prolong its duration. In a prone position, we have better functional residual capacity than in a supine position. Furthermore, ventilation perfusion ratio is well maintained, and hypoxia and hypercarbia are avoided. All of this, aided by gravity, reduces lung injury. All that was mentioned previously could explain why Cuschieri et al. [60] described a decrease in respiratory complications in PP. Luketich group [9] performed the thoracoscopic surgery in LDP and reported the incidence of pneumonia in 7.6% and adult respiratory distress syndrome (ARDS) in 5% of the patients. Palanivelu et al. [10] talks about pneumonia in 1.54% of the patients and ARDS in 0.77% with PP approach.

As we have described already, gravity and artificial pneumothorax may improve mediastinal organs and structures exposure without any help of an assistant: this is another benefit of the PP. It makes possible the use of only three trocars, while four of them are needed in lateral decubitus approach. Prone position also promotes blood and other fluids from accumulating in the right anterior thorax, instead of posterior mediastinum that takes part of operative field. Thus, intermittent suction of accumulated fluids is not required during surgery. In the lateral position, the esophagus is in a dependent place and any pooling of blood obscures the surgical field.

Recently, Javed et al. [61] have published a comparative study between MIE in prone versus lateral decubitus position (LDP). They described the surgery in LDP using an additional trocar (four in total) for the assistant to retract the lung and to suction out the blood, whereas they only need three for PP technique. In this study, authors report low blood loss intraoperative, which was significantly less in PP group. Kubo et al. [62] also describe significantly lower blood loss with this approach. This fact could be explained due to a better exposure in PP that allows a more meticulous dissection avoiding damage to vessels and other thoracic structures and decreasing bleeding.

Noshiro et al. [63] have published a study to describe whether lymphadenectomy along the left recurrent laryngeal nerve is facilitated in the PP. Lymph nodes along this nerve are frequently involved by carcinoma cells, and their complete dissection is required [58]. They conclude that when PP is compared with LDP, lower blood loss and better exposure of the surgical field around the left recurrent laryngeal nerve occurs in first group. Although they describe slightly higher number of the resected lymph nodes in the PP, they do not find significant differences. On the other hand, Javed et al. [61] show a significantly higher lymph node yield in PP and the number of patients with affected lymph nodes is also significantly higher.

Most of the reports [10, 61] describe a shorter operative time for a thoracoscopic esophagectomy in PP than in LDP. As we have said before, the best exposure of the surgical field allows for faster and better quality surgery.

Fabian et al. [64] suggested that the learning curve for the prone position approach appears to be relatively short, within the first five cases. This author also says that prone approach may result in better dissection into the neck explained by pneumatic dissection from the thoracic cavity cranially along the esophagus. This maneuver simplifies the neck surgery that could lead to less morbidity in cervical step.

The incidence of complications, such as anastomosis leak, gastric tip necrosis, chylothorax, tracheal, or vocal cord injury is comparable between PP and LDP according to many reports. Other clinical outcomes seem to be similar between both: median length of stay, discharged within 10 days, and in-hospital mortality [63, 64]. As we have commented at the beginning, it might be possible to reduce respiratory morbidity using PP approach.

In addition, in PP the surgeon's wrist and shoulder joints are in a neutral position in relation to the forearms and upper arms, minimizing fatigue and maximizing ergonomic function. The view of the monitor stands parallel to operative field and ergonomic position of the surgeon makes easier hand-eye coordination. In contrast in LDP, the surgeon's view of the monitor

must be turned upside down to avoid the counterimage when two monitors are set on each side. In this situation, hand-eye coordination cannot be obtained smoothly if a scope-holding assistant does not work correctly.

One disadvantage with the prone technique could be the need for conversion to open required electively when many adhesions preclude a minimally invasive approach or emergently as a consequence of uncontrollable bleeding. Although a posterior thoracotomy can be performed in this position, it is a less familiar approach that hinders dissection. Moreover, if we have performed the thoracic step without the use of a double-lumen endotracheal tube, we have to know that if a conversion is required, isolated lung ventilation would be invaluable. Thus, there are authors that continue using double-lumen intubation in the prone approach [64].

In conclusion, the PP may be performed with comparable outcomes to the LDP. The technique improves exposure of the operative field and reduces surgical times without compromising patient's safety or oncological results. Moreover, PP brings on an ergonomic position for the surgeon that makes easy the dissection.

8. Fast-track surgery (FTS) protocol on patient undergoing MIE

The concept of fast-track surgery (FTS) was first introduced by Kehlet and Mogensen [65], and the objective of his study was to show less postoperative stress, reduce morbidity associated with complications, accelerate recovery, and reduce postoperative cost in patients submitted for colon surgery after a rehabilitation programme [66]. It is essentially a multidisciplinary team to perform a fast-track approach during perioperative period for reaching an optimal outcome [67]. To date, the fast-track protocol has been applied in many surgical fields such as colon, rectum, or liver, but there is limited literature talking about the safety of using this protocol in esophageal surgery, especially in those cases where a minimally invasive technique is going to be performed.

Patients must receive health instructions and adequate information about FTS in the preoperative period. As we have explained previously, it is essential to optimize nutritional support with enteral and parenteral nutrition in those patients with long-term insufficient feeding and nutritional deficiencies. Recall that this measure has not been carried out in conventional care [68].

Many anesthesiologists have always been wary of allowing an esophageal cancer patient to ingest liquids 3 h before induction of anesthesia, defending the risk of aspiration pneumonia with this maneuver. But National and European Anesthesia Societies now recommend intake of clear fluids until 2 h before the induction of anesthesia as well as a 6 h fast for solid food [69]. Following these guidelines, Pan and his group, who have recently published a FTS protocol for MIE [70], instructed patients to drink fluid meals until 6 h before surgery and a carbohydrate drink until 3 h before surgery. They do not notice more pulmonary complications in FTS group than in conventional management group.

The use of the nasogastric tube (NGT) during the postoperative period is still controversial, although data describes disturbance of water, electrolyte, and acid base, and more digestive

fluid reflux using nasogastric tube, which can increase pulmonary morbidity [71]. Some studies also show that NGT can delay normal gastrointestinal function [72]. Removal of NGT in the immediate postoperative period promotes early oral diet introduction that has some physiological advantages: decreases bacterial translocation, ensures function of intestinal mucosal cells, activates digestive secretory system, reduces postoperative infection, and accelerates organ recovery [73]. Oral feeding can be initiated during the first 48 h, following a stepwise programme from water to fluid meals, and finally to semifluid meals and normal food. Pan et al. [70] do not report gastroenterological complications, including anastomosis leak, without using NGT in postoperative period, and they suggest that an early oral diet in patients with MIE is safe and feasible. Enteral nutrition through jejunostomy may be initiated on the first postoperative day, even before oral intake. Both, oral and enteral nutrition, promote faster recovery of gastrointestinal function. Lewis et al. [74] concluded in their meta-analysis that early enteral nutrition can reduce anastomosis leakage and mortality. Jejunostomy can be removed when patients are able to ingest normal food.

The evidence about restrictive fluid administration intraoperatively and postoperatively, as we have reported in section called “anesthetic challenges of MIE,” show less cardiopulmonary complications with this therapy. Earlier oral and enteral nutrition promotes that postoperative intravenous fluids can be reduced to as little as possible and removed during the first 24–48 h.

Abdominal and chest tube are also points of discussion in the FTS programme:

- Abdominal cavity drainage allows monitoring active bleeding and anastomosis leak, but it also can lead to abdominal infection and intestinal obstruction. While conventional care prefers to maintain drainage a few days, supporters of the fast-track protocol suggest that we should not leave drainage if there is no evidence of intraoperative complications. Jesus et al. [75] do not report more mortality or morbidity without using abdominal drainage.
- Chest tube causes pain and limits patient's mobility, so it has to be removed as soon as possible. A recent study has showed that it is safe to remove thoracic drainage when its volume is between 250 and 450, and there is no air leak.

The fast-track protocol also includes early perambulation after surgery for preventing venous thromboembolism that can be facilitated if patients are not carrying any type of drainage. Adequate analgesia can also accelerate perambulation and promote the recovery of intestinal function. Moreover, chest physiotherapy and incentive spirometry should be instituted. In their study, Pan et al. [70] reported that hospital stay and the days until intestinal activity are significantly shortened in the FTS group without an increase in morbidity and mortality. Patients undergoing MIE and fast-track protocol can be discharged earlier, even in the first week.

In summary, FTS program can be used safely in patients undergoing MIE because it promotes early recovery without increasing morbidity and mortality. We must offer the patient adequate preoperative information about the fast-track protocol to facilitate its implementation in the immediate postoperative period.

9. Conclusion

The minimally invasive approach to esophageal cancer is a safe and feasible procedure with favorable outcomes when compared to open esophagectomy. The data available reported by the different studies describe fewer respiratory complications, a reduction of hospital stay and faster patient recovery without compromising the oncologic efficacy related with harvested lymph nodes and R0 margin resection. The thoracoscopic approach in prone position is an alternative that offers more benefits than the lateral decubitus technique. Moreover, the implementation of a fast-track protocol allows an early recovery without increasing morbidity and mortality.

Acknowledgements

Thanks to Mrs. Noelia Tomás Marín-Baldo for her contribution in correcting English.

Author details

Rafael Cholvi Calduch, Isabel Mora Oliver, Fernando Lopez Mozos* and Roberto Martí Obiol

*Address all correspondence to: ferlomo@gmail.com

Division of Oesophageal and Upper Gastrointestinal Surgery, Department of Surgery, Hospital Clínico Universitario de Valencia, Valencia, Spain

References

- [1] Zhang Y. Epidemiology of esophageal cancer. *World Journal of Gastroenterology*. 2013; **19**(34):5598-5606
- [2] Griffin SM, Raimes SA. *Oesophagogastric Surgery: A companion to Specialist Surgical Practice*. 4th ed. Philadelphia: Saunders, Elsevier, 2009
- [3] D'Journo XB, Thomas PA. Current management of esophageal cancer. *Journal of Thoracic Disease*. 2014;**6**(S2):S253-S264
- [4] Orringer MB, Marshall B, Lannettoni MD. Transhiatal esophagectomy: Clinical experience and refinements. *Annals of Surgery*. 1999;**230**:392-403
- [5] Bailey SH, Bull DA, Harpole DH, et al. Outcomes after esophagectomy: A ten-year prospective cohort. *Annals of Thoracic Surgery*. 2003;**75**(1):217-222
- [6] T. Kim, S. N. Hochwald, G. A. Sarosi, A. et al. Review of Minimally Invasive Esophagectomy and Current Controversies. *Gastroenterology Research and Practice*, vol. 2012, Article ID 683213, 7 pages, 2012.

- [7] Cuschieri A, Shimi S, Banting S. Endoscopic oesophagectomy through a right thoracoscopic approach. *Journal of the Royal College of Surgeons of Edinburgh*. 1992;**37**(1):7-11
- [8] DePaula AL, Hashiba K, Ferreira EA, et al. Laparoscopic transhiatal esophagectomy with esophagogastroplasty. *Surgical Laparoscopy and Endoscopy*. 1995;**5**(1):1-5
- [9] Luketich JD, Alvelo-Rivera M, Percival O, et al. Minimally invasive esophagectomy. Outcomes in 222 patients. *Annals of Thoracic Surgery*. 2003;**238**:486-495
- [10] Palanivelu C, Prakash A, Senthilkumar R, et al. Minimally invasive esophagectomy: thoracoscopic mobilization of the esophagus and mediastinal lymphadenectomy in prone position experience of 130 patients. *Journal of American College of Surgeons*. 2006;**203**:7-16
- [11] Parameswaran E, Blazeby JM, Hughes R, et al. Health-related quality of life after minimally invasive oesophagectomy. *British Journal of Surgery*. 2010;**97**:525-531
- [12] Berger AC, Bloomenthal A, Weksler B, et al. Oncologic efficacy is not compromised and may be improved with minimally invasive esophagectomy. *J Am Coll Surg*. 2011;**212**:560-566 (discussion 566-568)
- [13] Yibulayin W, Abulizi S, Hongbo LV, et al. Minimally invasive oesophagectomy versus open esophagectomy for resectable esophageal cancer: A meta-analysis. *World Journal of Surgical Oncology*. 2016;**14**:304
- [14] Lv L, Hu W, Ren Y, et al. Minimally invasive esophagectomy versus open esophagectomy for esophageal cancer: A meta-analysis. *OncoTargets and Therapy*. 2016;**9**:6751-6762
- [15] Biere SS, Berge Henegouwen MI, Maas KW, et al. Minimally invasive versus open oesophagectomy for patients with oesophageal cancer: A multicentre, open-label, randomised controlled trial. *The Lancet*. 2012;**379**:1887-1892
- [16] Bartels H, Stein HJ, Siewert JR. Preoperative risk analysis and postoperative mortality of oesophagectomy for resectable oesophageal cancer. *British Journal of Surgery*. 1998;**85**:840-844
- [17] Fekete FBJ. *Nutrition Factors and Oesophageal Resection*. Edinburgh: Churchill Livingstone; 1988
- [18] Law S, Wong KH, Kwok KF, et al. Predictive factors for postoperative pulmonary complications and mortality after esophagectomy for cancer. *Annals of Surgery*. 2004;**240**:791-800
- [19] Bollschweiler E, Schroder W, Holscher AH, et al. Preoperative risk analysis in patients with adenocarcinoma or squamous cell carcinoma of the oesophagus. *British Journal of Surgery*. 2000;**87**:1106-1110
- [20] Ueda K, Tanaka T, Hayashi M, et al. Role of inhaled tiotropium on the perioperative outcomes of patients with lung cancer and chronic obstructive pulmonary disease. *Journal of Thoracic and Cardiovascular Surgery*. 2010;**58**:38-42

- [21] Bolukbas S, Eberlein M, Eckhoff J, et al. Short-term effects of inhalative tiotropium/formoterol/budesonide versus tiotropium/formoterol in patients with newly diagnosed chronic obstructive pulmonary disease requiring surgery for lung cancer: A prospective randomized trial. *European Journal of Cardio-Thoracic Surgery*. 2011;**39**:995-1000
- [22] Hulzebos EH, Helders PJ, Favié NJ, et al. Preoperative intensive inspiratory muscle training to prevent postoperative pulmonary complications in high-risk patients undergoing CABG surgery: A randomized clinical trial. *JAMA*. 2006;**296**:1851-1857
- [23] Turan A, Mascha EJ, Roberman D, et al. Smoking and perioperative outcomes. *Anesthesiology*. 2011;**114**:837-846
- [24] Correia MI, Caiaffa WT, Da Silva AL, et al. Risk factors for malnutrition in patients undergoing gastroenterological and hernia surgery: an analysis of 374 patients. *Nutrición Hospitalaria*. 2001;**16**:59-64
- [25] Jie B, Jiang ZM, Nolan MT, et al. Impact of preoperative nutritional support on clinical outcome in abdominal surgical patients at nutritional risk. *Nutrition*. 2012;**8**:1022-1027
- [26] Kuppinger D, Hartl WH, Bertok M, et al. Nutritional screening for risk prediction in patients scheduled for extra-abdominal surgery. *Nutrition*. 2013;**29**:399-404
- [27] Rucklige M, Sanders D, Alastair M. Anaesthesia for minimally invasive oesophagectomy. *Continuing Education in Anaesthesia, Critical Care & Pain*. 2010;**10**:43-47
- [28] De Conno E, Steurer MP, Wittlinger M, et al. Anaesthetic-induced improvement of the inflammatory response to one-lung ventilation. *Anesthesiology*. 2009;**110**:1316-1326
- [29] Schilling T, Kozian A, Kretzschmar M, et al. Effects of propofol and desflurane anaesthesia on the alveolar inflammatory response to one-lung ventilation. *British Journal of Anaesthesia*. 2007;**99**:368-375
- [30] Sherry K. Management of patients undergoing oesophagectomy. In: Gray AJG, Hoile RW, Ingram GS, Sherry KM, editors. *The Report of the National Confidential Enquiry into Perioperative Deaths 1996/1997*. London: NCEPOD; 1998. pp. 57-61
- [31] Ehrenfeld JM, Walsh JL, Sandberg WS. Right and left-sided Mallinckrodt double-lumen tubes have identical clinical performance. *Anesthesia and Analgesia*. 2008;**106**:1847-1852
- [32] Pennefather SH, Russel GN. Placement of double lumen tubes — Time to shed light on an old problem. *British Journal of Anaesthesia*. 2000;**84**:308-310
- [33] Kooguchi K, Kobayashi A, Kitamura Y, et al. Elevated expression of inducible nitric oxide synthase and inflammatory cytokines in the alveolar macrophages after esophagectomy. *Critical Care Medicine*. 2002;**30**:71-76
- [34] Lin WQ, Lu XY, Cao LH, et al. Effects of the lung protective ventilatory strategy on pro-inflammatory cytokine release during one-lung ventilation. *Ai Zheng*. 2008;**27**:870-873
- [35] Badenes R, Belda FJ, Aguilar G. Mechanical ventilation in cardiac surgery. *Current Anaesthesia & Critical Care*. 2010;**21**:250-254

- [36] Slinger P. Pro: Low tidal volume is indicated during one-lung ventilation. *Anesthesia and Analgesia*. 2006;**103**:268-270
- [37] Michelet P, D'Journo XB, Roch A, et al. Protective ventilation influences systemic inflammation after esophagectomy: A randomized controlled study. *Anesthesiology*. 2006;**105**:911-919
- [38] Mayer J, Boldt J, Mengistu AM, et al. Goal-directed intraoperative therapy based on autocalibrated arterial pressure waveform analysis reduces hospital stay in high-risk surgical patients: A randomized, controlled trial. *Critical Care*. 2010;**14**:R18
- [39] Nisanevich V, Felsenstein I, Almogy G, et al. Effect of intraoperative fluid management on outcome after intra-abdominal surgery. *Anesthesiology*. 2005;**103**:25-32
- [40] Kita T, Mammoto T, Kishi Y. Fluid management and postoperative respiratory disturbances in patients with transthoracic esophagectomy for carcinoma. *Journal of Clinical Anesthesia*. 2002;**144**:252-256
- [41] Licker M, de Perrot M, Spiliopoulos A, et al. Risk factors for acute lung injury after thoracic surgery for lung cancer. *Anesthesia and Analgesia*. 2003;**97**:1558-1565
- [42] Ballantyne JC, Carr DB, deFerranti S, et al. The comparative effects of postoperative analgesic therapies on pulmonary outcome: cumulative meta-analyses of randomized, controlled trials. *Anesthesia and Analgesia*. 1998;**86**:598-612
- [43] Watson A, Allen PR. Influence of thoracic epidural analgesia on outcome after resection for esophageal cancer. *Surgery*. 1994;**115**:429-432
- [44] Whooley BP, Law S, Murthy SC, et al. Analysis of reduced death and complication rates after esophageal resection. *Annals of Surgery*. 2001;**233**:338-344
- [45] Lázár G, Kaszaki J, Abraham S, et al. Thoracic epidural anesthesia improves the gastric microcirculation during experimental gastric tube formation. *Surgery*. 2003;**134**:799-805
- [46] Cense HA, Lagarde SM, de Jong K, et al. Association of no epidural analgesia with postoperative morbidity and mortality after transthoracic esophageal cancer resection. *Journal of American College of Surgeons*. 2006;**202**:395-400
- [47] Pathak D, Pennefather SH, Russell GN, et al. Phenylephrine infusion improves blood flow to the stomach during oesophagectomy in the presence of a thoracic epidural analgesia. *European Journal of Cardio-Thoracic Surgery*. 2013;**44**:130-133
- [48] Al-Rawi OY, Pennefather SH, Page RD, et al. The effect of thoracic epidural bupivacaine and an intravenous adrenaline infusion on gastric tube blood flow during esophagectomy. *Anesthesia and Analgesia*. 2008;**106**:884-887
- [49] Richards ER, Kabir SI, McNaught CE, et al. Effect of thoracic epidural anaesthesia on splanchnic blood flow. *British Journal of Surgery*. 2013;**100**:316-321
- [50] Joshi GP, Bonnet F, Shah R, et al. A systematic review of randomized trials evaluating regional techniques for postthoracotomy analgesia. *Anesthesia and Analgesia*. 2008;**107**:1026-1040

- [51] Davies RG, Myles PS, Graham JM. A comparison of the analgesic efficacy and side-effects of paravertebral vs. epidural blockade for thoracotomy—A systematic review and meta-analysis of randomized trials. *British Journal of Anaesthesia*. 2006;**96**:418-426
- [52] Baidya DK, Khanna P, Maitra S. Analgesic efficacy and safety of thoracic para-vertebral and epidural analgesia for thoracic surgery: A systematic review and meta-analysis. *Interactive Cardiovascular and Thoracic Surgery*. 2014;**18**:626-635
- [53] Ding X, Jin S, Niu X, et al. A comparison of the analgesia efficacy and side effects of para-vertebral compared with epidural blockade for thoracotomy: An updated meta-analysis. *PLoS One*. 2014;**9**:e96233
- [54] Zieren HU, Jacobi CA, Zieren J, et al. Quality of life following resection of oesophageal carcinoma. *British Journal of Surgery*. 1996;**83**:1772-1775
- [55] Burdall OC, Boddy AP, Fullick J, et al. A comparative study of survival after minimally invasive and open oesophagectomy. *Surgical Endoscopy*. 2015;**29**:431-437
- [56] Palazzo F, Rosato EL, Chaudhary A, et al. Minimally invasive esophagectomy provides significant survival advantage compared with open or hybrid esophagectomy for patients with cancer of the esophagus and gastroesophageal junction. *Journal of American College of Surgeons*. 2014
- [57] Biere SS, Maas KW, Bonavina L, et al. Traditional invasive vs. minimally invasive esophagectomy: A multi-center, randomized trial (TIME-trial). *Study Protocol*. *BMC Surgery*. 2011;**11**:2
- [58] Akiyama H, Tsurumaru M, Udagawa H, et al. Radical lymph node dissection for cancer of the thoracic esophagus. *Annals of Surgery*. 1994;**220**(3):364-372
- [59] Fujita H, Kakegawa T, Yamana H, et al. Mortality and morbidity rates, postoperative course, quality of life, and prognosis after extended radical lymphadenectomy for esophageal cancer. Comparison of three-field lymphadenectomy with two-field lymphadenectomy. *Annals of Surgery*. 1995;**222**(5):654-662
- [60] Cuschieri A. Thoracoscopic subtotal oesophagectomy. *Endoscopic Surgery and Allied Technologies*. 1994;**2**(1):21-25
- [61] Javed A, Manipadam JM, Jain A, et al. Minimally invasive oesophagectomy in prone position versus lateral decubitus position: A comparative study. *Journal of Minimal Access Surgery*. 2016;**12**(1):10-15
- [62] Kubo N, Ohira M, Yamashita Y, Sakurai K, Lee T, Tokokawa T, et al. Thoracoscopic esophagectomy in the prone position versus in the lateral position for patients with esophageal cancer: A comparison of short-term surgical results. *Surgical Laparoscopy, Endoscopy & Percutaneous Techniques*. 2014;**24**:158-163
- [63] Noshiro H, Iwasaki H, Kabayashi K, et al. Lymphadenectomy along the left recurrent laryngeal nerve by minimally invasive esophagectomy in the prone position for thoracic esophageal cancer. *Surgical Endoscopy*. 2010;**24**:2965-2973

- [64] Fabian T, Martin J, Katigbak M, et al. Thoracoscopic esophageal mobilization during minimally invasive esophagectomy: A head-to-head comparison of prone versus decubitus positions. *Surgical Endoscopy*. 2008;**22**(11):2485-2491
- [65] Kehlet H, Mogensen T. Hospital stay of 2 days after open sigmoidectomy with a multimodal rehabilitation programme. *British Journal of Surgery*. 1999;**86**:227-230
- [66] Kehlet H. Multimodal approach to control postoperative pathophysiology and rehabilitation. *British Journal of Anaesthesia*. 1997;**78**:606-617
- [67] Hubner M, Muller S, Bonnard L, et al. Fast track surgery. *Revue Médicale Suisse*. 2008;**4**:2001-2004
- [68] Jin-Yi W, Xuan H, Guo-Han C, et al. Clinical application of the fast track surgery model based on preoperative nutritional risk screening in patients with esophageal cancer. *Asia Pacific Journal of Clinical Nutrition*. 2015;**24**:206-211
- [69] Cerfolio RJ, Bryant AS, Bass CS, Alexander JR, Bartolucci AA. Fast tracking after Ivor Lewis esophagogastrectomy. *Chest*. 2004;**126**:1187-1194
- [70] Pan H, Hu X, Yu Z, et al. Use of a fast-track surgery protocol on patients undergoing minimally invasive oesophagectomy: Preliminary results. *Interactive Cardiovascular and Thoracic Surgery*. 2014;**19**:441-447
- [71] Nguyen NT, Slone J, Wooldridge J, et al. Minimally invasive esophagectomy without the use of postoperative nasogastric tube decompression. *American Surgeon*. 2009;**75**:929-931
- [72] Koukouras D, Mastronikolis NS, Tzoracoleftherakis E, et al. The role of nasogastric tube after elective abdominal surgery. *Clinical Therapeutics*. 2001;**152**:241-244
- [73] Henriksen MG, Jensen MB, Hansen HV, et al. Enforced mobilization, early oral feeding, and balanced analgesia improve convalescence after colorectal surgery. *Nutrition*. 2002;**18**:147-152
- [74] Lewis SJ, Andersen HK, Thomas S. Early enteral nutrition within 24 h of intestinal surgery versus later commencement of feeding: A systematic review and meta-analysis. *Journal of Gastrointestinal Surgery*. 2009;**13**:569-755
- [75] Jesus EC, Karliczek A, Matos D, et al. Prophylactic anastomotic drainage for colorectal surgery. *Cochrane Database of Systematic Reviews*. 2004;CD002100.