

# We are IntechOpen, the world's leading publisher of Open Access books Built by scientists, for scientists

4,800

Open access books available

122,000

International authors and editors

135M

Downloads

Our authors are among the

154

Countries delivered to

TOP 1%

most cited scientists

12.2%

Contributors from top 500 universities



WEB OF SCIENCE™

Selection of our books indexed in the Book Citation Index  
in Web of Science™ Core Collection (BKCI)

Interested in publishing with us?  
Contact [book.department@intechopen.com](mailto:book.department@intechopen.com)

Numbers displayed above are based on latest data collected.  
For more information visit [www.intechopen.com](http://www.intechopen.com)



---

# Osteonecrosis of the Jaws. Prevalence, Risk Factors and Role of Microbiota and Inflammation in a Population of Spain

---

Mario Pérez-Sayáns, Carmen Vidal-Real,  
José M. Suárez-Peñaranda and Abel García-García

Additional information is available at the end of the chapter

<http://dx.doi.org/10.5772/intechopen.69315>

---

## Abstract

**Introduction:** The purpose of this article is to determine the prevalence of ONJ in patients who have undergone intravenous bisphosphonate therapy, and relate the risk factors described (including Actinomycetes); indeed, to establish a protocol to reduce the risk of developing ONJ and to evaluate the evolution of the patient according to the sample's antibiogram.

**Results:** The prevalence of ONJ was 12.9%. Most of the non-diabetic patients did not develop ONJ (92.3%) ( $p = 0.048$ ). In regards to the periodontal state, 94.3% of patients without periodontal problems did not develop ONJ ( $p = 0.001$ ). Almost 50% of the necrosis were unifocal and located on the mandible ( $p < 0.001$ ). The number of affected patients and the aggressiveness of the disease increased significantly three years after starting treatment ( $p < 0.001$ ). 87.5% of biopsies showed the presence of Actinomyces. The inflammatory response was very variable, ranging from absent to intense but it increased with age ( $p = 0.005$ ). The combination of amoxicillin with clavulanic acid showed good sensitivity in the majority of patients (82.6%).

**Conclusions:** As the etiology of ONJ remains unknown, it is essential to prioritize prevention while assessing the risk factors.

**Keywords:** osteonecrosis, bisphosphonates, prevalence, risk factors, microbiota, inflammation, actinomyces

## 1. Osteonecrosis of the jaws

### 1.1. History

The term osteonecrosis dates back to the 1950s, when a series of cancer patients who underwent radiotherapy developed bone lesions on the jaws following the treatment [1–3]. This treatment, which is currently resulting in many complications on an oral level, makes it very hard to cure infections that are sometimes inevitable for these patients, since ischemia takes place on the jaws.

Some years later, the first article appeared citing a periapical lesion following arsenic infiltration for canal treatment. Arsenic was used as a therapeutic agent and as poison in Ancient Greek and Roman times [4]. It was also used as an agent during dental history for pulp devitalization, when anesthetics did not exist. Due to its ability to destroy cells in surrounding tissues, the use of arsenic trioxide in vital pulpectomy has been dropped progressively [5]. Dumlu's article (2007) described a case of jaw necrosis in a young patient following tooth extraction of a first failed molar after arsenic treatment of the canals [6]. Toxavit, another devitalizing agent, has also been related to bone necrosis. In any case, both agents are currently obsolete for these dental treatments [7, 8].

Another one of the causes mentioned in the history of osteonecrosis is the untreated intracapsular fracture, after several months, the described clinical symptoms were pain in the temporal-jaw articulation in the affected side and the limitation in opening the jaw. On a radiographic level, the condylar head is usually eroded and irregular [9].

Back in 1982, the first cases of osteonecrosis of the jaw in toothless patients by chemotherapy treatment were published. Specifically, the article considered the origin was a lesion on the mucosa due to a trauma caused by removable prosthesis.

The cases of aseptic osteonecrosis after jaw osteotomy following orthognathic surgeries have also been described in the literature; they have been related mostly to a complication following a surgical error [10].

In 2002, a clinical case of osteonecrosis of the jaws due to chemotherapy in a patient with myelogenous leukemia was published [11]; and, a year later, the current term bisphosphonates-related osteonecrosis of the jaws was branded (BRONJ) [12].

Despite the osteonecrosis of the jaws was exclusively related to the mouth, some rare cases in the external ear, the hip, the tibia and the femur have been documented [13, 14].

### 1.2. Definition

The concept of osteonecrosis of the jaws was introduced in 2003 when a series of 36 bone lesions in the mandible and the maxilla were described in patients undergoing treatment with pamidronate or zoledronate [12].

Then in 2007, the American Association of Oral and Maxillofacial Surgeons (AAOMS) described osteonecrosis of the jaws like persistent bone exposure in the mouth for over 8 weeks in patients with a history of use of bisphosphonates, without local evidence of malignancy or radiotherapeutic treatment of the affected region [15].

Despite that the term osteonecrosis has been used in numerous contexts and even in different locations (not only for the jaws); it is currently related exclusively to the chronic use of bisphosphonates. The condition is called bisphosphonate-related osteonecrosis of the jaw (BRONJ) [16], which was changed by the AAOMS in 2014 for the term medication-related osteonecrosis of the jaw (MRONJ), since this complication has also been described in relation to other antiresorptive drugs (denosumab) and antiangiogenic therapies [17].

### *1.2.1. Prevalence and incidence*

The prevalence of osteonecrosis of the jaws is variable according to the consulted authors, reaching approximately 7–12%, although in more recent articles it tends to be even higher (18.6%) [18].

In regards to IV bisphosphonates, the bibliography of a series of cases, case studies and controls and cohorts, the estimations of the accumulated incidence of MRONJ ranges from 0.8 to 12% [19].

In regards to oral bisphosphonates, clinical effectiveness has been proven, which is shown in over 190 million prescriptions of these drugs around the globe [20]. Despite that osteonecrosis cases have been described, these patients have a considerably lower risk of MRONJ than cancer patients who have been treated with monthly IV bisphosphonates.

According to the database of the alendronate manufacturer (Merk), the incidence of MRONJ was calculated as 0.7/100.000 people/years of exposure [21]. This derives from the number of (non-confirmed) reports of the cases that were considered as MRONJ, divided between the number of alendronate pills prescribed since the approval of the drug. Although this is the best information available to date, there could be a bias in the collection and validity of the data.

In Australia, MRONJ incidence in patients receiving weekly alendronate treatment ranges between 0.01 and 0.04% [22]

Felsenberg registered a prevalence of MRONJ among patients who underwent bisphosphonates therapy for osteoporosis of 0.00038%, based on the reports of three cases in the German Central Register for Jaw Necrosis [23].

## **1.3. Risk factors**

### *1.3.1. Local factors*

#### **A. Dentoalveolar surgery**

- Extractions

- Dental implants
- Periapical surgery
- Periodontal surgery

Cancer patients treated with IV bisphosphonates and who underwent dentoalveolar procedures had 5–21 times more risk of MRONJ than cancer patients who were treated with IV bisphosphonates and who did not undergo dentoalveolar procedures [19].

## B. Local anatomy

### B1. Mandibular

- Lingual torus
- Mylohyoid line

### B2. Maxilla

- Palatine Torus

The lesions are located with a higher frequency on the mandible than on the superior maxilla (2:1) and more frequently in areas with thin mucosa that cover bone protrusions, such as the torus, bone exostosis and the mylohyoid edge [24–26].

**C. Concomitant oral diseases:** Dental or periodontal abscesses [27].

### 1.3.2. Systemic and demographic factors

- Age:** Advanced age is related to a higher prevalence of MRONJ.
- Sex:** This factor has not been statistically related to a higher risk of osteonecrosis.
- Race:** Caucasians have a higher risk of MRONJ compared to the Negro race [28].
- Cancer diagnosis,** with or without osteoporosis: The type of malignancy is not statistically related to a higher risk of MRONJ, although the presence of bone metastasis presents a correlation, according to Wessel's article ( $P = 0.051$ ) [29]. It is related with a higher risk of osteonecrosis in the coadjuvant treatments in these patients, such as chemotherapeutic agents (cyclophosphamide), erythropoietin and steroids [30, 31].
- Tobacco and alcohol:** There is a possible correlation with smoking but not with drinking, according to the study published by Wessel et al. [29].
- Genetic factors:** It has been proven that polymorphism in the farnesyl pyrophosphate synthase or the cytochrome of gen P450 CYP2C8 increase the risk of MRONJ in patients treated with IV bisphosphonates [32–34].
- Others:** Dialysis, low hemoglobin, obesity and diabetes are variables related to MRONJ [29, 31, 35].

### 1.3.3. Drug-related factors

- a. **Bisphosphonate potency:** IV bisphosphonates present higher power than oral ones [19].
- b. **Duration of the treatment:** The longer the duration of the treatment, higher the risk of MRONJ [19].

### 1.4. Diagnosis

Patients diagnosed with MRONJ are defined by the following characteristics [17]:

1. Prior treatment with antiresorptive and antiangiogenic drugs.
2. Presence of bone exposure or intra- or extraoral fistula for over 8 weeks, without remission.
3. Patients who have not been treated with radiotherapy nor have metastasizing diseases in the jaws.

With the intention of standardizing all the signs and symptoms present in the patients affected by osteonecrosis of the jaws, a protocol for MRONJ diagnosis was proposed in 2010 [36].

#### 1.4.1. Clinical diagnosis

##### a. Greater clinical signs [37]

- Exposed necrotic bone in the oral cavity

##### b. Minor clinical signs and symptoms

- Abscess
- Displacement of jaw fragments
- Intra-extra oral fistula
- Jaw deformation
- Lip hypaesthesia/paraesthesia
- Gum or mucous fistula
- Nasal level excretions
- Unhealed post-extraction alveoli
- Pus excretion
- Spontaneous expulsion of bone sequestration

- Dental mobility
- Local inflammation
- Bone and dental pain
- Trismus

#### 1.4.2. Radiographic/tomographic diagnosis

##### a. Initial signs [38]

- Cortical fracture
- Sclerosis of the focal bone marrow
- Presence of post-extraction alveoli
- Trabecular engrossment

##### b. Late signs

- Diffuse sclerosis
- Oro-antral fistula
- Osteolysis extended to the sinus floor
- Osteosclerosis of adjacent bones (zygoma and hard palate)
- Pathological fracture
- Prominence of the lower dental nerve canal
- Sinusitis

#### 1.4.3. Diagnosis through complementary testing

The histopathologic study and microbiological culture are also tests developed on the supuration area. Developing an antibiogram is very helpful since these patients will be treated with antibiotics during long periods of time and it is convenient to know the existing bacterial spectrum and the sensitivity of these microorganisms to different antibiotics.

### 1.5. MRONJ staging

The stages initially described by Ruggiero et al. [24] have been modified and adapted to classify patients with greater precision [17, 19, 39] (**Figure 1**).

**Risk patient:** Without apparent necrotic lesions in asymptomatic patients undergoing treatments with oral or IV bisphosphonates.

**Stage 0:** Patients without clinical evidence of bone necrosis, but with unspecific systems or clinical or radiographic findings.

**a. Symptoms**

- Odontalgia without odontogenic cause.
- Pain at the jaw level that may irradiate to the temporomandibular joint.
- Sinus pain, which may be related to inflammation or engrossment of the maxillary sinus wall.
- Alteration of the neurosensory function

**b. Clinical findings**

- Dental loss without periodontal cause
- Periapical or periodontal fistula that is not related to a pulpal necrosis by cavities.

**c. Radiographic findings**

- Bone resorption that is not attributable to chronic periodontal disease.
- Changes to the trabeculate and bone density and resistance to healing of the post-extraction alveoli.
- Widening/darkening of the periodontal ligament.
- Narrowing of the lower dental nerve canal.

These unspecific findings that are characteristic of State 0 can take place in patients with a prior history of more advanced phases in whom the disease has been cured and have no clinical evidence of exposed bone.

**Stage 1:** Asymptomatic bone exposure without clinical signs of inflammation or infection.

**Stage 2:** Bone exposure with infection and pain, erythema or inflammation of the mucosa, with or without suppuration.

**Stage 3:** Bone exposure associated to pain, inflammation and infection with one or more of the following complications:

- Exposed necrotic bone beyond the alveolar region, as the lower border of the mandibular branch, maxillary sinus or zygoma.
- Pathological fracture.
- Oro-antral and oro-nasal communication.
- Extra-oral fistula.



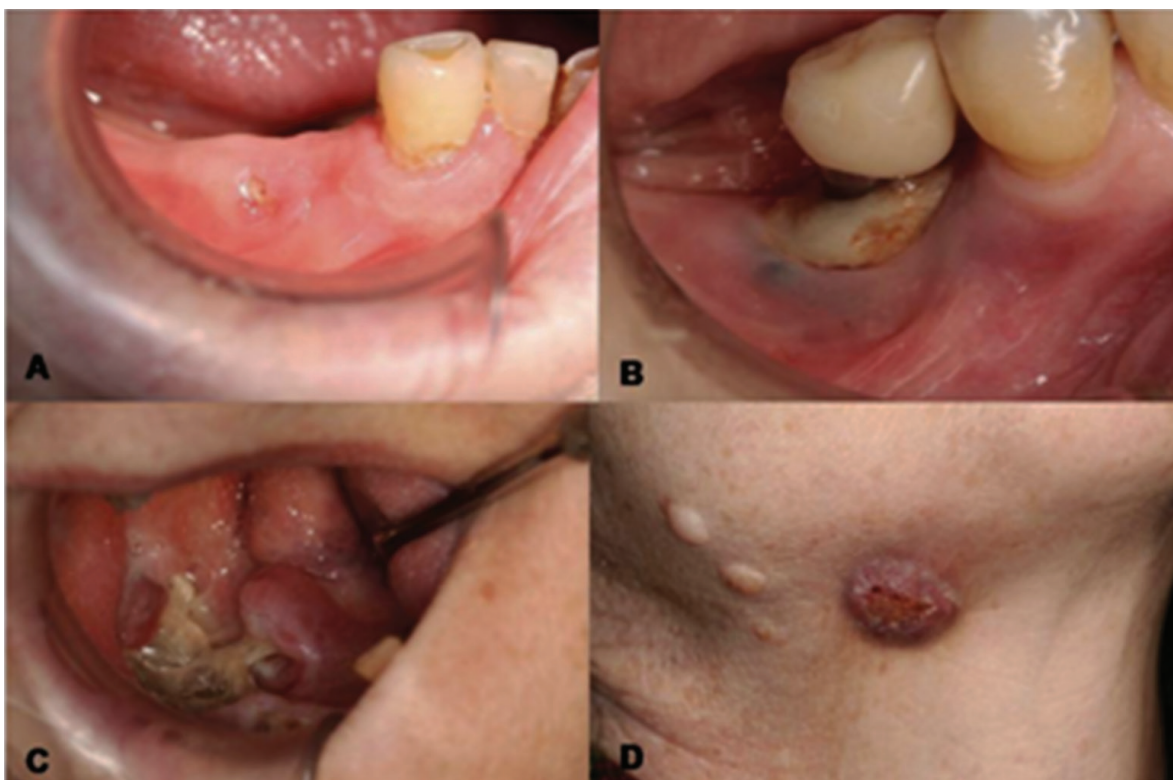

Figure 1. TNM Staging. (A) Stage 1; (B) Stage 2; (C) and (D) Stage 3.

### 1.6. Treatment

To focus on the treatment to be developed regarding this complication, it is essential to know the pathophysiology of MRONJ, only by this way we can draft an appropriate treatment plan.

To date, the source has not been adequately documented, describing a multi factor source. Suppression of bone remodeling can contribute to the development of osteonecrosis by an inadequate activity of osteoclasts that do not allow the post-extraction alveoli to heal. The presence of microflora in the mouth have also been related as an osteonecrosis-promoting factor, since numerous biopsy studies and bone sequestrations revealed the presence of *Fusobacterium*, *Eikenella*, *Bacillus*, *Actinomyces*, *Staphylococcus* and *Streptococcus* [40]. Bacterial infection produces local cytokines that promote local osteolysis that contribute to the stimulation of bone resorption and, therefore, subsequent necrosis [41–43].

Additionally, recent articles relate the presence of *Actinomyces* in MRONJ, although these are small studies on a series of cases having a very small impact in establishing a specific treatment strategy [28, 44–46].

*Actinomyces* are Gram-positive anaerobic facultative bacteria that do not form spores and are commonly filamentous. They are frequent commensals of the mucosa in the oropharynx,

intestinal tract and the female genital tract, once the mucosa barrier is broken due to trauma, surgical interventions or foreign objects, they can invade deep tissue structures and compromise treatment response. Progressive chronic disease is called actinomycosis, and the treatment of this pathology is based on a prolonged antimicrobial therapy for 2–6 months in combination with surgery [47, 48].

#### 1.6.1. Conservative treatment

- a. **Oral hygiene:** Teach the patient good brushing techniques and a good daily control of dental plaque.
- b. **Periodical dental exam:** Periodical visits to control the new pathology that could receive conservative treatment.
- c. **Antimicrobial rinses:** The mouthwash par excellence is chlorhexidine at 0.12%.
- d. **Antibiotic treatment:** Multiple antibiotic standards have been described, but it is obvious that there is an increasing bacterial resistance to penicillins. Running an antibiogram is always advisable to assess the sensitivity and drug resistance to provide the most appropriate treatment.
  - Amoxicillin with or without clavulanic acid (500 mg/1 g)
  - Clindamycin (300 mg)
  - Azithromycin (500 mg)
  - Metronidazole with betalactamic antibiotics
- e. **Ozone therapy:** Ozone is a natural gas produced by the atmosphere that has antimicrobial and healing properties. Its role as a treatment for the osteonecrosis of the jaws has been discussed in clinical and pre-clinical studies, since it was believe that this gas induced tissue repair and, therefore, healing of the mucosa [49].

Numerous studies have used this therapy as an adjuvant in antibiotic treatments with good results, although further standardized studies are needed to accurately determine their effectiveness [50].

- f. **Hyperbaric oxygen therapy:** Hyperbaric oxygen therapy (HBOT) is very controversial in the literature. It is believed that it stimulates tissue healing, reducing edema and inflammation, stimulates cell proliferation and moderates the suppression of bone remodeling produced by the use of bisphosphonates [51–53].
- g. **Soft LASER:** This innovative and effective medical method has a pain-reducing effect, improving circulation in the lesion and helping nerve regeneration. At an oral level, it improves re-epithelialization following periodontal or third molar surgery [52, 54].

Most conservative treatments on their own do not show accurate results on their effectiveness, especially in more advanced stages. Authors use them in combination with antibiotics and observe that these can help heal the patient, especially in terms of tissue regeneration; but it is always reinforced with an appropriate antibiotic treatment (**Table 1**) [55].

### 1.6.2. Surgical treatment

For patients in advanced stages and resistant-clinical-cases:

- a. **Conservative surgery:** Includes the removal of the necrotic bone (sequestration) and/or superficial unbinding associated to antibiotic therapy and chlorhexidine rinses.
- b. **Resective surgery:** Destined to patients in whom previous treatments have not been effective or have very advanced stages. This process has been questioned since it is difficult to guarantee complete resection of the necrosed bone sectioned at the healthy bone [56, 57].

Numerous studies show high improvement rates in patients who underwent surgical treatment both in conservative and resective procedures (**Table 2**) [55].

### 1.6.3. Other treatments

The use of stem cells [58, 59], platelet-rich plasma [60], the administration of parathyroid hormone [61] or the use of leukocyte- and platelet-rich fibrin [62] are also promising proposals, but they require further clinical studies that attest to their effectiveness.

### 1.6.4. Protocol for the treatment of MRONJ

**Risk Patients:** They do not require treatment, but must be informed of the risks of developing MRONJ, as well as the signs and symptoms of this disease [19, 24].

Type of treatment	Author/Year	No. patients healed/No. patients treated (%)
Antibiotic treatment	Melea et al. (2014)	23/38 (60%)
	Van den Wyngaert et al. (2009)	16/33 (53%)
	Scoletta et al. (2010)	18/30 (62%)
	Nicolatou-Galitis et al. (2011)	7/47 (14.9%)
T Antibiotic treatment + hyperbaric oxygen	Freiberger et al. (2012)	13/25 (52%)
Antibiotic treatment + ozone therapy	Ripamonti et al. (2011)	10/10 (100%)
Pentoxifylline + $\alpha$ -tocopherol	Magremanne et al. (2014)	1/1 (100%)

**Table 1.** Summary of studies with a conservative focus for the management of ONJ-related osteonecrosis [55].

Type of treatment	Author/Year	No. patients healed/No. patients treated (%)
Conservative surgery	Rugani et al. 2014	15/17 (88.2%)
	Vescovi et al. (2012)	11/17 (65%)
	Thumbigere-Math et al. (2009)	3/19 (15%)
	Williamson et al. (2010)	40/40 (100%)
	Vescovi et al. (2014)	25/27 (92.6%)
	Graziani et al. (2012)	227 (54%)
	Wutzl et al. (2008)	24/41 (519%)
Conservative surgery + ozone therapy	Agrillo et al.	57/94 (60%)
Conservative surgery + L-PRF	Kim et al.	26/34 (77%)
Resective surgery	Graziani et al. (2012)	87/120 (72.5%)
	Carlson and Basile (2009)	87/95 (92%)
	Bedogni et al. (2011)	27/30 (90%)
	Voss et al. (2012)	20/21 (95%)
	Schubert et al. (2012)	47/54 (87%)

Note: L-PRF (leukocyte- and platelet-rich fibrin).

**Table 2.** Summary of studies with a surgical focus for the treatment of MRONJ.

**Stage 0:** Symptomatic treatment and control of local factors, such as cavities and periodontal disease.

**Stage 1:** Daily rinses with antimicrobial agents (chlorhexidine at 0.12%) and regular control visits.

**Stage 2:** Oral antimicrobial rinses (chlorhexidine at 0.12%) in combination with antibiotic therapy.

**Stage 3:** Combination of different protocols:

- Surgical debridement of the necrotic bone
- Antibiotic therapy (oral or IV)
- Analgesics
- Daily rinses with antimicrobial agents (chlorhexidine at 0.12%)

Regardless of the state of the patient, mobile bone sequestration segments must be retrieved. Extraction of affected teeth with symptoms within the exposed necrotic bone must be considered, since it is improbable that the extraction exacerbates the established necrotic process.

### 1.7. Prevention

Despite all the treatments proposed above, the latest articles agree that none of these are completely effective for all cases, therefore, the main goal in these patients is prevention of this complication.

Back in 2009, AAOMS [16] determined that prevention was the main goal in the management of these patients, recommending that patients are evaluated and treated before initiating bisphosphonate therapy.

There are several studies that document that preventative dental treatment decreases the risk of MRONJ among patients with malignant tumors treated with IV bisphosphonates [63, 64]. These findings suggest that, although MRONJ is not eliminated, evaluations and dental treatment prior to beginning bisphosphonate therapy in cancer patients reduces the risk of MRONJ.

Furthermore, they advise revising the doses prescribed to the patients, since it has been proven that [65] the accumulative doses can increase the risk of suffering complications.

The risk of developing MRONJ due to oral bisphosphonate treatment is minimal, but it seems to increase when the duration of the treatment is more than 3 years. This period of time can be reduced in the presence of certain concomitant diseases, such as the chronic use of corticosteroids. Systemic conditions permitting the clinician should consider interrupting oral bisphosphonate treatments for a 3-month period before and another 3 months after elective invasive dental surgery with the purpose of reducing the risk of MRONJ. The justification of this focus is based on extrapolated data that show fluctuations depending on osteoclasts, which is related to the treatment with bisphosphonates, and recent studies show that there is a better result in the treatment of MRONJ after eliminating the drug [66]. In the long term, prospective studies will be necessary to establish the efficacy of suppression period of these drugs to reduce the risk of MRONJ in patients undergoing oral bisphosphonate treatments.

#### 1.7.1. Patients about to begin bisphosphonate treatment

The goal is to reduce the risk of developing MRONJ to the minimum despite that a small percentage of patients who receive IV bisphosphonate therapy can develop osteonecrosis spontaneously [19]. Thus, if the medical conditions of the patient allow, the start of the treatment must be delayed until their dental health is optimal [63, 64]. This decision must be made by the doctor, together with the dentist and other specialists involved in the patient's care.

Untreatable teeth and those with bad prognosis must be extracted. Additionally, other necessary dentoalveolar surgeries should also be performed at this time. The start of the treatment with bisphosphonates, if possible, should be delayed until complete healing of the mucosa (14–21 days) or until there is an appropriate bone healing.

Dental prophylaxis, cavity control and restorative-conservative odontology are essential to maintain dental health. This level of attention should be maintained indefinitely. The patients with complete or partial prosthesis should be examined to avoid the trauma areas of the mucosa, especially in the border of the tongue. It is essential that patients are trained in regards to the importance of oral hygiene and regular dental evaluations, and instructed specifically to report any pain, swelling or exposed bone area.

#### *1.7.2. Asymptomatic patients who receive IV bisphosphonates*

Procedures that imply direct bone lesion should be avoided, therefore, unrestorable teeth should be treated by eliminating the crown and the endodontic treatment of root fragments [21]. The placement of dental implants must be avoided in cancer patients exposed to higher potency bisphosphonates (zoledronic acid and pamidronate) with a frequent dose program (4–12 times/year).

#### *1.7.3. Asymptomatic patients who receive oral bisphosphonate treatments*

In general terms, these patients seem to have less severe manifestations of necrosis and respond promptly to the described treatments [67, 68]. Elective alveolodental surgery does not seem to be contraindicated in this group, although it is advisable that the patients are appropriately informed on the small risk of complications in bone healing. The use of levels in the bone exchange markers and a drug break in the treatment have been documented as additional tools that guide in making treatment decisions in patients exposed to oral bisphosphonates [68]. Currently, the effectiveness of the systemic markers of bone exchange to assess the risk of developing jaw necrosis in risk patients is being questioned, which requires more research before considering it as a valid risk evaluation tool. In the long term, prospective studies will be necessary to establish the efficacy of suppression period of these drugs (drug holidays) to reduce the risk of MRONJ in these patients.

The risk of MRONJ seems to be more associated to the duration of the treatment ( $\geq 3$  years) than the dosage, since there has not been any information indicating that the monthly dosage of bisphosphonates is related, with a high or reduced risk of MRONJ when it is compared with the weekly dose program.

There are no solid recommendations based on clinical research for patients who take oral bisphosphonates. The Task Force strategies described above have remained essentially unchanged and are based on the clinical experience of the physicians (expert opinions) who participate in the care of these patients [24, 64, 68–70].

##### *1.7.3.1. Patients who have taken oral bisphosphonates for less than 3 years and have no clinical risk factors, alterations and have the possibility of programmed surgery*

Includes all the common procedures for oral and maxillofacial surgeons, periodontists and specialists.

If dental implants are placed, an informed consent must be presented in regards to possible implant failure and the possible osteonecrosis of the jaws, if the patient continues the oral

bisphosphonate treatment. It is also advisable to contact the doctor who initially prescribed the oral bisphosphonate to suggest monitoring of these patients and consider a possible alternative dose to the bisphosphonate, temporary suppression of the drug or an alternative to the medication.

*1.7.3.2. Patients who have been administered oral bisphosphonates for less than 3 years associated with corticosteroids*

If systemic conditions allow, the physician must be contacted to consider the interruption of the oral treatment for at least 3 months prior to the oral surgery. Reinstatement of bisphosphonate therapy should not take place until complete bone healing. These strategies are based on the opinion of experts with significant clinical experience and the hypothesis that concomitant treatment with corticosteroids can increase the risk of developing MRONJ.

*1.7.3.3. Patients who have been administered oral bisphosphonates for less than 3 years, with or without corticosteroids*

If systemic conditions allow, the physician must be contacted to consider the interruption of the oral treatment for at least 3 months prior to the oral surgery and, similarly, bisphosphonate therapy should not be reinstated until complete bone healing.

*1.7.4. CTXs (C-terminal telopeptide in serum)*

This bone resorption biomarker has been used for years as a predictive factor for the development of bisphosphonate-related osteonecrosis when deciding on the dental treatments for this type of patients [71]. In a study by Marx et al. (2007), they observed CTXs in fasting samples to correlate the values and the period of use of oral bisphosphonates and to demonstrate if the increase in value could indicate a recovery in bone remodeling when suspending oral bisphosphonate treatment. Risk stratification was determined according to the obtained values, CTX under 100 pg/ml represented high risk, CTX between 100 pg/ml and 150 pg/ml represented moderate risk, while CTX above 150 pg/ml represented minimal risk. CTX values increased between 25.9 and 26.4 pg/ml for each drug holiday month from the bisphosphonates, which indicated a recovery of the bone remodeling and a directive in terms of when the oral surgical procedures could be developed at a lower risk. Additionally, it was observed that in terms of the drug suppression periods associated to CTX values, the latter rose above the threshold of 150 pg/ml, which coincides with spontaneous bone healing or a better response to complete healing after debridement. [68].

After years of research, a meta-analysis of nine controlled studies did not reveal significant differences in the mean values of CTXs among patients with MRONJ and controls (mean difference, -31.417; 95% confidence interval [CI], -91.560 to 28.726;  $P = 0.306$ ). Additionally, a second meta-analysis of four studies did not show significant differences in the risk of osteonecrosis with CTX values below 150 pg/ml for patients with MRONJ in comparison with the controls (risk ratio, 1.892; 95% CI, 0.636–5.626;  $P = 0.251$ ) [71].

The term “**Drug Holiday**” has appeared recently as a preventative measure when certain risk odontological treatment must be performed or to improve healing after the appearance of osteonecrosis. There are several proposals but there is no clear consensus regarding bisphosphonate suppression periods (**Table 3**) [72].

Cancer patients benefit mainly from the therapeutic effects of bisphosphonates, such as the control of bone pain and the incidence of pathological fractures. An interruption of IV bisphosphonate therapy does not offer short-term benefits. However, if systemic conditions allow, long-term suspension can be beneficial in the stabilization of the areas affected by MRONJ, which reduces the risk of necrosis in other locations and minimizes clinical symptoms [63, 64]. The oncologist’s role is very important to assess the risks and benefits of suppressing the treatment.

Regarding the interruption of oral bisphosphonate treatment in patients with MRONJ, a gradual improvement of the disease has been proven [68]. The interruption of oral bisphosphonates for 6–12 months may favor healing, after the removal of a bone sequestration or after

Guideline	Bisphosphonate exposure history by route of administration	
	Oral	Intravenous
ASBMR <sup>56</sup>	No specific guidelines given	No guidelines given
AAOMS <sup>57</sup>	Less than 3 year duration: No change to dosing Less than 3 year duration and corticosteroids: Cease: 3 months prior Recommence: Osseous healing has occurred <sup>†</sup> More than 3 year duration: Cease: 3 months prior Recommence: Osseous healing has occurred <sup>†</sup>	No guidelines given
CCPG <sup>60</sup>	No specific guidelines given	Cease: 3–6 months prior Recommence: Full healing <sup>†</sup>
Mayo Clinic <sup>62</sup>	No guidelines given	Cease: 1 month prior Recommence: Full healing
MFA <sup>64</sup>	No guidelines given	Low/intermediate risk of SRE: Cease: 2–3 months prior Recommence: 2–3 months after or full healing

<sup>†</sup>If systemic condition permits.

**Table 3.** Proposals in the bisphosphonates suppression rate [72].



debridement. The decision to suppress the drug must be assessed by the physician and the patient, as long as the systemic conditions allow.

## 2. Bisphosphonates

### 2.1. Definition

Bisphosphonates are non-metabolizable pyrophosphate analogues that are deposited on the bones and prevent or improve bone complications of the patients with bone alterations. Different bisphosphonates differ depending on the alterations of the R-2 lateral chain structure. These R-2 lateral chains determine the efficiency and the cellular effects of the inhibition of bone resorption [73]. The bisphosphonates are internalized by osteoclasts, causing the interruption of bone resorption. They also have antiangiogenic properties, since they reduce the circulating levels of vascular endothelial growth factor (VEGF) [74–78] and antineoplastic effects [79]. It has very little intestinal absorption and is excreted without being metabolized by the kidneys.

Until 2001, pamidronate (Aredia®) was the only drug approved in the USA for the treatment of bone metastasis. In 2002, the US Food and Drug Administration (FDA) [80] approved zoledronic acid (Zometa®) as a treatment for these patients. Currently, the annual transfusion of zoledronate (Reclast®) and the parenteral formulation of ibandronate (Bonviva®) administered every 3 months has been approved by the FDA for the treatment of osteoporosis [81].

In 2003, using the articles by Marx [12] and Ruggiero et al. [25], they observed and reported on the cases of unhealed bone exposure in the maxillofacial region in patients treated with IV bisphosphonates and, after multiple further publications, in September 2004, Novartis the manufacturer of pamidronate (Aredia®) and zoledronic acid (Zometa), added the complications deriving from this treatment to the labeling of these drugs, with the purpose of warning the health care professionals of the possibility of developing osteonecrosis of the jaws [82].

### 2.2. Types of bisphosphonates

According to their chemical structure, these are divided into two groups.

**Non-nitrogenous:** These are very similar to natural pyrophosphate, such as etidronate or clodronate that contain CH<sub>3</sub> and Cl groups instead of the R<sub>2</sub> chain and a nitrogen-free ring, such as tiludronate. They are metabolized by macrophages in toxic analogues of adenosine triphosphate (ATP) [83].

**Nitrogenous:** They present higher power, such as zoledronate and pamidronate, with a primary atom of basic nitrogen with an alkyl chain. They have a power 10–100 times higher than non-nitrogenous. Mevalonate inhibits the cholesterol route through the farnesyl diphosphate synthase enzyme [83].

There is a great variety of bisphosphonates approved for clinical use in the USA (**Table 4**).

Generic name	Commercial name	Laboratory	RP	FDA-a
Pamidronate	Aredia, IV	Novartis	100	1991
Tiludronate	Skelid, O	Sanofi	10	1997
Alendronate	Fosamax, O	Merck	1000	1997
Etidronate	Didronel, O	Proctor & Gamble	1	1997
Risedronate	Actonel, O	Proctor & Gamble	5000	1998
Zoledronic acid	Zometa, IV	Novartis	100,000	2001
Ibandronate	Bonviva, O	Roche	10,000	2005

Note: O: oral; IV: intravenous.

**Table 4.** Drugs approved in EEUU.

### 2.2.1. IV bisphosphonates

It is estimated that over 2.8 million cancer patients from around the world have received treatment with IV bisphosphonates since their introduction [84].

- **Pamidronate** (Aredia): a second-generation bisphosphonates that are administered every 3–4 weeks at a dosage of 90 mg.
- **Zoledronic acid** (Zometa): a third-generation bisphosphonates, administered every 3–4 weeks, at a dosage of 4 mg.

It is a heterocyclic imidazole and, to date, the most powerful bisphosphonate to be administered to humans. In a test on in-vitro bone resorption using mouse cranium, zoledronate was at least 100 times more powerful than pamidronate. Additionally, the in-vivo animal model of calcitriol-induced hypercalcemia in thyroparathyroidectomized rats was 850 times more active than pamidronate and over 4 times more powerful than clodronate. Of all the bisphosphonates under clinical evaluation, this is the one having a higher therapeutic relationship between the desired inhibition of bone resorption and the undesired inhibition of bone mineralization, furthermore, several toxicology studies proved that the compound is safe [85].

### 2.2.2. Oral bisphosphonates

Due to the proven clinical effectiveness, it is considered a first line therapy in the treatment of osteoporosis and they are the most prescribed antiresorptive agents.

- **Alendronate** (Fosamax): 70 mg once a week during the osteoporosis treatment or less, if it has been prescribed for the prevention of osteoporosis.

It has been proven to prevent approximately 50% of cases in the prevention of the bone loss in the spine or hips in menopausal women and the reduction of bone fractures [86, 87].

- **Risedronate** (Actonel): 35 mg once a week.

In a prospective study with a large sample, risedronate produced a reduction of 30% in hip fractures [88, 89].

- **Ibandronate** (Boniva): is the latest drug to be approved by the FDA (March, 2005) for the treatment of osteoporosis and it is administered monthly.
- **Etidronate** (Didronel): prescribed for the Paget disease with a dose of 300–750 mg/day for 6 months.
- **Tiludronate** (Skelid): prescribed for Paget disease with a dose of 400 mg/day for 3 months.

### 2.3. Metabolism

Bisphosphonates have an average life between 30 min and 2 h and are deposited in the locations with higher bone metabolism, and can remain at the bone level for approximately 10 years. The highest concentration is located in urine and saliva, and the most frequent adverse effects are renal insufficiency and osteonecrosis [90–92]. The accumulative doses described by Maerevoet, is of 72 mg for 18 months [90, 93].

In the case of IV bisphosphonates, such as zoledronic acid, 40% is eliminated unaltered through urine after 24 h [94] and the remaining 60% are united at bone level due to the great affinity of hydroxyapatite. This phenomenon takes place in areas of bone remodeling, in which the periodical exchange produces unaltered kidney excretion after a long elimination phase [95]. The mean life of this second elimination phase may last months or years, depending on the duration of the bisphosphonate treatment [96].

Excretion of oral bisphosphonates has also been studied, for example, in a rat study, in which they administered risedronate orally, and determined that 80% of the drug was excreted through the kidneys 12 h after the administration of the drug. Additionally, the study concluded that taking oral bisphosphonates with mineral water that contains high calcium and magnesium levels reduced the effect of the drug; therefore it is advisable to take it as soon as the patient wakes up and in a vertical position [97]. These authors previously described the effect of water in combination with taking alendronate [98].

### 2.4. Detection of bisphosphonates

The concentration of bisphosphonates in a specific bone location depends on the speed of bone remodeling and blood circulation [99]. It is important to know the concentration of accumulated bisphosphonate in the bone to understand the long-term drug effect and its toxicity. Today, numerous authors have been able to quantify these drugs in plasma and urine through mass spectrometry (MS), which requires a previous derivation process that allows to transform the bisphosphonates into more hydrophobic substances so they can be studied [100, 101].

The development of analysis methods for the detection of bisphosphonates in biological matrices, it is hard due to the chemical properties of these compounds. The detection of bisphosphonates in human biological matrices comes with certain difficulties and therefore a

broad range of analytic techniques have been described, such as gas chromatography [102], ion chromatography [103], capillary electrophoresis, ionization mass spectrometry by electro-spray [104] and chromatography of fluids [105].

#### 2.4.1. Mass spectrometry (MS)

A method for the extraction and detection of zoledronic acid in urine and blood plasma or even accumulated in the bone (in a mouse model) through the combination of chromatography and mass spectrometry (MS) [100, 106].

In these studies, a higher accumulation of bisphosphonates in bone extracts of the mandible was detected, compared to other types of bones [106]. On the other hand, human urine and blood plasma detected a maximum concentration peak of the drug of 77  $\mu\text{M}$  (5 h after the administration) and 1.5  $\mu\text{M}$  (after 1 h), respectively [100]. This methodology achieves high sensitivity and specificity in the detection, however, it requires a pretty complex and arduous treatment of the sample requiring phases with chemical reactions to derive the complex. The complexity of the treatment of the sample can be a limiting factor when the number of samples to be analyzed is high, as in the case of the follow-up of the pharmacokinetics and the bioavailability of zoledronic acid since its administration. For this reason, it would be desirable to have a more efficient alternative method to detect this drug.

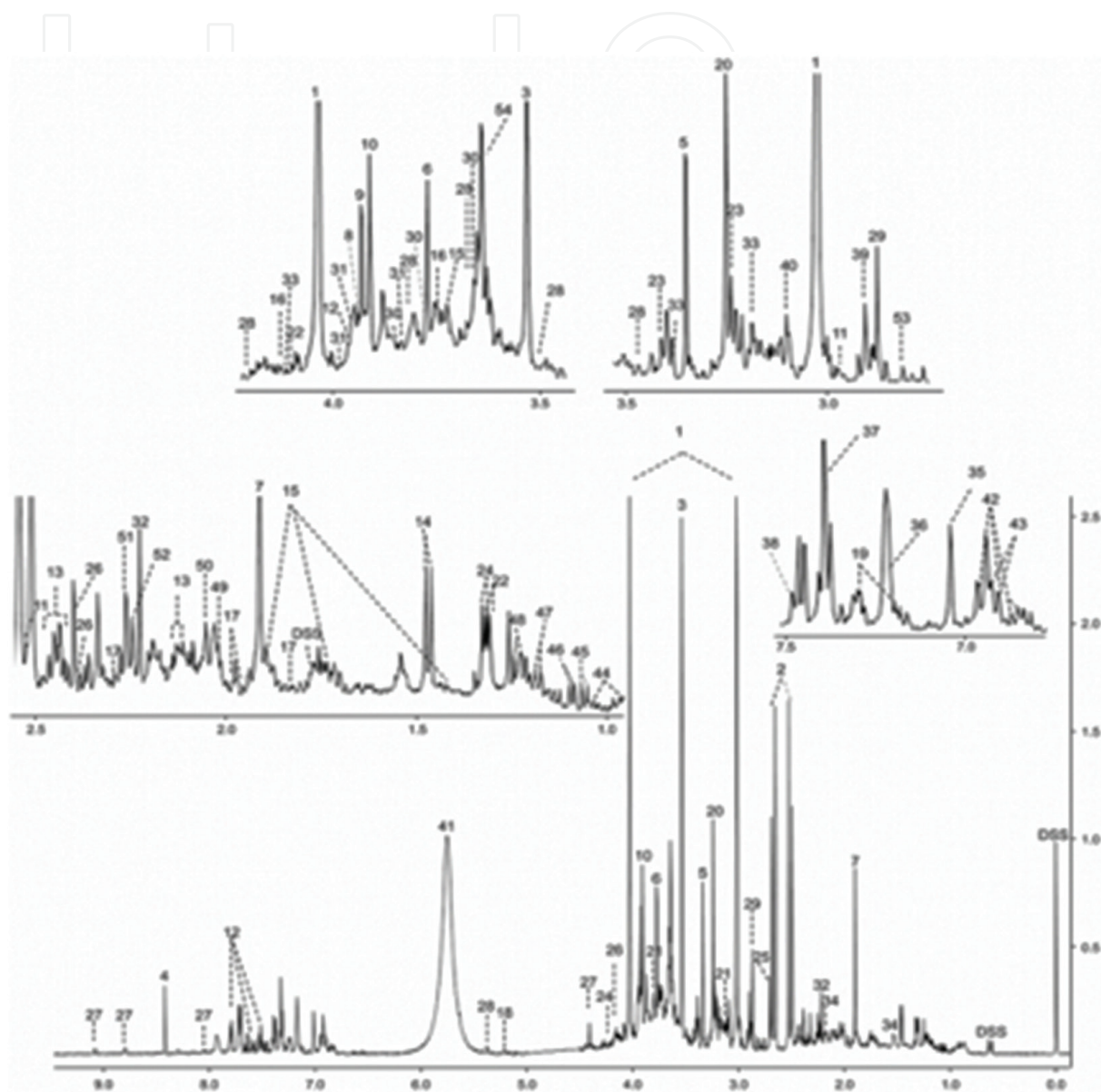
#### 2.4.2. Nuclear magnetic resonance spectroscopy (NMR)

Nuclear magnetic resonance (NMR) spectroscopy is a useful technique in chemometrics that can be used for the characterization of simple or complex mixes of different sources and provide quantitative results. There is a great variety of “omics” applications for NMR, such as *metabonomics*, *metabolomics*, *proteomics*, *transcriptomics*, *fluxomics*, *foodomics*, *lipidomics*, *fermentanomics*, *isotopomics*, etc. One of the areas with greater impact in biomedicine is metabolomics by NMR for the study of metabolites in different types of samples, such as biofluids (urine, saliva, blood plasma, blood serum, sweat, etc.), tissue extracts, cerebrospinal fluid, cells, etc. Metabolomics by NMR can be used to find biomarkers for the study, diagnosis and prognosis of diseases. Similarly, it can help many traditional analysis at a clinical level, since the cost per sample is or can be competitive if large lots of samples are managed, in terms of the time for the analysis (measurement) and the generation of results (automated). There are a number of pathologies for which the study of biofluids or tissues by NMR has found useful biomarkers [107, 108]. A relevant case of application of NMR in this area is the quantification of lipoprotein in blood serum/plasma. NMR offers details on the relative abundance of different subclasses of lipoproteins that are not accessible to traditional analysis methods [109, 110].

It is a quantitative technique that allows determination of the absolute concentration of diluted substances in general, including biofluids. It is based on the fact that the intensity of a signal in the NMR spectrum is proportionate to the concentration of the molecule (or metabolite) generating the said signal. As an approximate value, to assess the sensitivity of this technique, in a current spectrometer with a 11.7 T magnet, the minimum concentration required to detect a molecule in a monodimensional spectrum (1D) of  $^1\text{H}$  (proton spectrum,

as it is commonly known in our jargon) must amount to a minimum of 10  $\mu\text{m}$ , for a measurement period of 15 min.

For the case of urine samples, under these same measurement conditions, 50–60 metabolites can be identified and quantified in their proton spectrum (**Figure 2**).



**Figure 2.** Typical spectrum of  $^1\text{H}$  NMR of a human urine sample. The numbers indicate the following metabolites: 1: creatinine, 2: citric acid, 3: glycine, 4: formic acid, 5: methanol, 6: guanidinoacetic acid, 7: acetic acid, 8: L-cysteine, 9: glycolic acid, 10: creatine, 11: Isocitric acid, 12: hippuric acid, 13: L-glutamine, 14: L-alanine, 15: L-Lysine, 16: gluconic acid, 17: 2-hydroxylglutaric acid, 18: D-glucose, 19: indoxyl sulfate, 20: trimethyl-N-oxide, 21: ethanolamine, 22: L-lactic acid, 23: taurine, 24: L-threonine, 25: dimethylamine, 26: pyroglutamic acid, 27: trigonelline, 28: sucrose, 29: trimethylamine, 30: mannitol, 31: L-serine, 32: acetone, 33: L-cystine, 34: adipic acid, 35: L-histidine, 36: L-tyrosine, 37: imidazole, 38: mandelic acid, 39: dimethylglycine, 40: cis-aconitic acid, 41: urea, 42: 3-(3-Hydroxyphenyl)-3-hydroxypropanoic (HPHPA), 43: phenol, 45: isobutyric acid, 46: methylsuccinic acid, 47: 3-Aminoisobutiric acid, 48: L-fucose, 49: N-acetylaspartic acid, 50: N-acetylneuraminic, 51: acetoacetic acid, 52: Alpha-aminoadipic acid, 53: methylguanidine, 54: phenylacetylglutamine [111].

When a series of NMR spectra need to be compared, such as urine, it is important to consider some details regarding post-processing of the spectra and the process to obtain their quantitative values, in such a way that no errors are introduced in this phase and the quantitative results that are obtained are the most precise and repeatable as possible. Although with slight variations regarding some details, the general method for the treatment of spectral information for the metabolomic studies by NMR is the one described below.

#### *2.4.2.1. Preparation of a biofluid sample*

A series of protocols have been established for the preparation of biofluid samples and their subsequent preservation until the NMR measuring [112, 113]. Similarly, there are experimental parameters to be used for the measurement of the NMR spectrum for each type of biofluid [112, 113]. These protocols standardize the measurements, thus allowing the comparison of the spectra obtained and the NMR spectrum (e.g. the Human Metabolome Database: [www.hmdb.ca](http://www.hmdb.ca)) and/or with bibliographic results. These sample preparation protocols tend to be simple and do not require special laboratory equipment.

##### *2.4.2.1.1. Generation of a signal intensity data matrix (integrals) on regions of interest (ROIs) of the NMR spectrum*

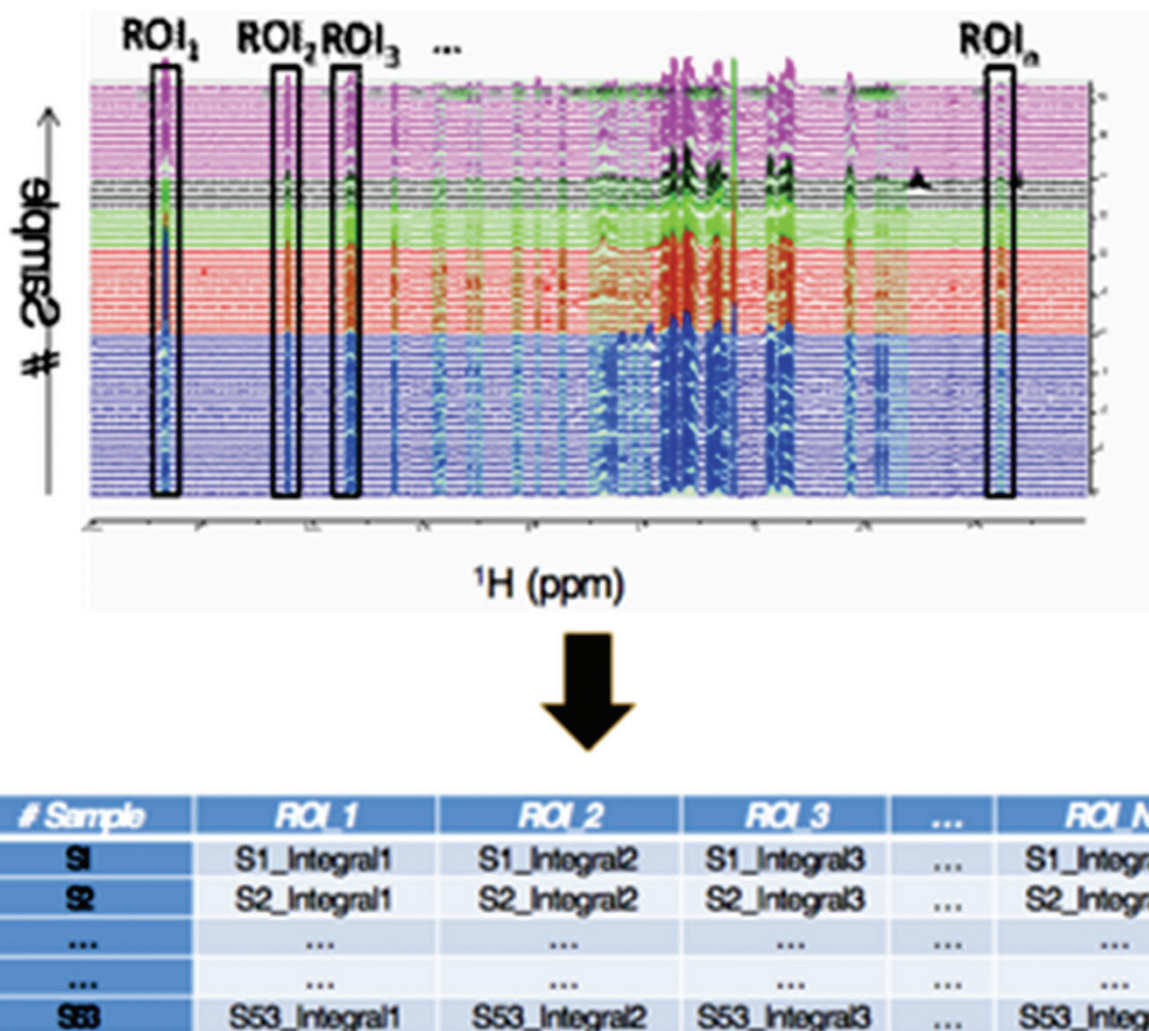
The raw data provided by the spectrometer when measuring the  $^1\text{H}$  NMR spectrum is called free induction decay (FID). The data must be post-processed by applying a series of operations to generate a final spectrum with a scale of frequencies (expressed by standardized ppm units) and with the best quality possible [114]. Once the post-processing has been completed for each of the spectra to be studied, the following phase consists of comparing analogue regions of the spectrum with the target to find, if possible, a certain region that could serve as a biomarker, in other words, a region in which the signal's intensity pattern is significantly different in the samples of the control group and the experiment group, while being similar within their own group.

Instead of manually selecting one or several regions for comparison, the usual and practical procedure is to perform a systematic analysis, dividing the entire spectrum automatically, from right to left, through a series of small segmental regions (e.g. with an established width) in which the area of the signal is integrated individually. Each of these regions is called buckets or regions of interest (ROIs). This way, a complete spectrum is represented as a data vector formed by the integrals of the selected ROIs, with as many integral values as segments of the spectrum have been created.

Lastly, a table is created with the data, placing the vectors of each of the analyzed samples in different lines (**Figure 3**). There are software tools that automate these operations to generate the data table, as well as the phase before the post-processing.

##### *2.4.2.2. Standardization of the data of the ROIs Matrix*

Of the ROI matrix integral values, the negative values are initially purged since they only contain noise (a ROI must have at least an integral value or a signal area that equals zero).



**Figure 3.** Scheme for the construction of a NMR ROI data matrix from 53 NMR spectra. Above: 53  $^1\text{H}$  spectra in which we have selected certain ROIs for the integration of the signal. The vertical piling scale identifies each of the samples (# sample). The same color has been used to identify samples that should be, a priori, of the same type. Below: NMR ROIs data matrix obtained through the integration of each of the ROIs.

The ROIs data standardization process seeks to take all the analyzed samples to a “virtual” constant that eliminates all the differences in global concentration in the ROI integral samples, which could simply respond to the urine having a higher or lower concentration of  $\text{H}_2\text{O}$ . When the dilution effect is eliminated, the differences between values of the same ROI in a pair of samples directly reflect variations in the relative concentration of the studied metabolite.

#### 2.4.2.2.1. Standardization method of each ROI line at a standard addition

A first standardization method consists of standardizing the total addition of the ROIs. This method considers that the total addition of all the ROIs of the same spectrum has a constant value, and that this is the same for all the samples. This type of standardization by matrix lines consists of dividing each ROI value by the total addition of ROIs of its same line. As a result, the standardized ROIs of a sample add up to the unit.

#### 2.4.2.2.2. Probabilistic quotient standardization method

This method consists of using the data of the ROIs of a certain sample of the study (a line of the matrix) and dividing the ROIs between those of another sample that is used as reference. This allows us to deduce the most probable multiplication factor so that the ROIs of the first sample are as close as possible to the reference sample. The most probable multiplication factor is calculated for each sample (for each line of the matrix). As a result of applying each factor on the ROIs of the relevant samples, their ROIs will be standardized as if the sample would have been prepared in the same concentration as the reference sample [115].

#### 2.4.2.3. Statistical analysis of the NMR ROIs Matrix

The Matrix of standardized ROIs is analyzed by multivariate statistic methods to identify the ROIs that contain similar or different patterns of the integral in samples of the same or different group and their potential biomarkers. To do this, algorithms, such as the Principal Components Analysis (PCA), Discriminant Analysis (DA) and Orthogonal Projections to Latent Structures-Discriminant Analysis (OPLS-DA) are used. These algorithms have been implemented in several general statistical software packages, for example, R, SPSS or XLSTAT, among others.

In favorable cases, one or more ROIs with potential biomarkers related to the property under investigation are identified, for example, the effect of certain medical treatments, a type of diet, a disease, etc. Additional objectives can then be included in the study, such as the identification of what specific biomarkers (metabolites) were altered compared to the control group, to try to discover through which metabolic pathway they underwent this change. Some of the biomarkers that are identified as different from the control group may not correspond to any of those that are typically found in the relevant type of biofluid, but they may proceed from the metabolism of a drug or a special diet that has been prescribed. In this case, once its NMR signal has been identified, we could consider performing a longitudinal follow-up on its appearance in the biofluid since its administration.

### 2.5. Medication-related osteonecrosis of the jaw (MRONJ)

Currently, two types of drugs, aside from bisphosphonates, have been proven to cause necrosis of the jaws.

#### 2.5.1. Antireabsorptives: denosumab

It is a RANKL monoclonal antibody that is currently still undergoing clinical trials for the treatment of osteoporosis, primary and metastatic bone cancer, giant cell tumor and rheumatoid arthritis [116, 117]. RANKL is necessary for the activation and function of mature osteoclasts [118, 119], which together with osteoprotegerin (OPG), maintains the balance of bone resorption in a healthy state. When an imbalance occurs in the RANKL/OPG ratio, resorption is favored in bone diseases [120, 121].

Denosumab has a high specificity due to human IgG2 that binds specifically to human RAN, and not other members of the TNF superfamily [116, 122, 123]. In clinical trials, this drug



causes rapid and prolonged decreases in bone exchange markers without any change in bone formation, which gives it antireabsorptives characteristics [124]. It has also shown better clinical results compared to bisphosphonates in the treatment of osteoporosis and cancer with a higher increase in bone density and suppression of bone remodeling markers, with a proven efficacy even in patients who had been previously resistant to bisphosphonates [117, 125, 126].

These drugs also produce osteonecrosis of the jaws with a prevalence of 0.7–19% [127, 128], which is very similar to the osteonecrosis from bisphosphonate treatments [117]. Since the first case of maxillary osteonecrosis due to this drug published in 2010 [129], several studies have been published but only one of them describes histopathologic characteristics [130]. The fragments of necrotic bone showed empty osteocytic lacuna and absence of osteocytes, osteoblasts and osteoclasts. The authors suggest that these characteristics are very similar to bisphosphonate-related osteonecrosis [131]

### 2.5.2. Antiangiogenics

These drugs hinder the development of new blood vessels and block the cascade of angiogenesis [132].

**Bevacizumab:** Monoclonal antibodies that stop the growth factor.

**Sunitinib and Sorafenib:** Tyrosine kinase inhibitors.

## 3. Results of our experience

### 3.1. Regarding the risk factors

All the patients of this study visited the Master of Oral Medicine, Surgery and Implantology of the Faculty of Dentistry of the University of Santiago de Compostela. The patients were derived from the Unit of Oncology of the Complejo Hospitalario Universitario de Santiago de Compostela (CHUS) for a dental examination prior to treatment with intravenous bisphosphonates. The study was approved by the Clinical Research Ethics Committee of Galicia, in addition to the gaining informed consent from the patients.

Patients treated with zoledronic acid for a period of 7 years (2006–2013) and patients with a history of treatment of head and neck radiotherapy were excluded.

**Local risk factors:** Only those patients who underwent exodontics during bisphosphonate treatment had a statistically significant risk ( $P > 0.001$ ), as well as a direct relationship according to the periodontal status of the patient, since no patient with periodontal health developed MRONJ ( $P = 0.001$ ). As previously described in the literature, research showed that the mandible is more affected than the upper maxilla and is also statistically significant ( $P < 0.001$ )

**Systemic risk factors:** There were no significant differences in terms of gender ( $P = 0.063$ ). Age did not show significant differences but there were more cases of osteonecrosis in elderly patients, probably because these patients are more compromised at the systemic level; in fact,

86.6% of them were polymedicated. The type of cancer, arterial hypertension and treatment with chemotherapy or corticosteroids did not show statistically significant differences, although the literature describes them as obvious risk factors. We could only conclude that patients without diabetes did not develop MRONJ ( $P = 0.048$ ). In our study we did not factor in their race, since 100% of the patients were Caucasian and from a specific population. As described by Wessel et al. [29] in their study, 100% of our patients had bone metastases, which justified the use of intravenous bisphosphonates and, therefore, also implied an increased risk of complications.

**Drug-related factors:** Regarding potency, all patients were treated with the same bisphosphonate (zoledronic acid, 4 mg). The cumulative dose showed that patients with more than three years of treatment had a higher risk of developing MRONJ, which was statistically significant ( $P < 0.001$ ) (Table 5).

### 3.2. Bacterial role in osteonecrosis of the jaws

We selected 28 patients (16 men and 12 women) with a mean age of 71.96 years, all of whom were treated in the Oncology Department of the Complejo Hospitalario Universitario de Santiago de Compostela (CHUS). They were referred to the Unit of Oral Surgery and Implantology of the Faculty of Medicine and Dentistry of Santiago de Compostela for a prior dental examination and for the follow-up of possible complications after treatment.

All patients treated with both oral and intravenous bisphosphonates and those undergoing head and neck radiotherapy within an 8-year period were included (2006–2014). The diagnostic criteria followed were those determined by the AAOMS [15] for patients treated with bisphosphonates, while in the case of those undergoing radiotherapy, we included those who had bone exposure for more than 8 weeks.

Samples of exudates from bone exposure were sent to the Department of Microbiology to be processed under Gram staining and seeded in liquid medium (thioglycolate broth) and in solids (agar-blood and agar-chocolate for the growth of aerobic bacteria, Sabouraud agar for yeast growth and Schaedler agar for anaerobic growth). The seeded plates were incubated for 48 h at 37°C in a CO<sub>2</sub> atmosphere and 72 h in anaerobic chambers. Identification of microorganisms was done using the Vitek 2 system (Bio-Merieux, Marcy l'Etoile, France) and Microscam (Siemens, Erlangen, Germany) in the case of aerobes; and API-ANA (Biomeriex) in the case of anaerobes. Antimicrobial susceptibility testing was performed by the e-test method (AB biodisk) and the Clinical Laboratory Standards Institute (CLSI) interpretation criteria were followed.

Biopsies of bone sequestration were sent to the Pathological Anatomy Service where they were fixed in 10% buffered formaldehyde and embedded in paraffin following standard processing. For evaluation, they were stained with hematoxylin/eosin, PAS and methenamine silver to visualize the colonies of Actinomyces. Their presence was evaluated semi-quantitatively and divided into scarce, moderately abundant or very abundant. In addition, the presence of acute inflammation (when polymorphonuclear neutrophil cells were observed), which was also quantified in three degrees: mild, moderate and intense, and the presence of chronic inflammation (indicated by the presence of lymphocytes and plasma cells).

Characteristics	Total patients with ONJ (%)	Total patients without ONJ (%)	P
<b>Gender</b>			0.063
Men	14 (7.2)	125 (64.4)	
Women	11 (5.7)	44 (22.7)	
<b>Systemic Risk Factor</b>			0.214
Cancer	12 (6.2)	95 (49)	
Prostate	9 (4.6)	34 (17.5)	
Breast	4 (2)	11 (5.7)	
Myeloma	0 (0)	18 (9.3)	
Lung	0 (0)	2 (1)	
Bladder	0 (0)	5 (2.6)	
Colon	0 (0)	3 (1.5)	
Kidney	18 (9.3)	176 (90.7)	
Diabetes	168 (86.6)	26 (13.4)	0.048
Polymedicated.	94 (48.5)	100 (51.5)	0.139
HTA	42 (21.6)	152 (78.4)	0.704
Cortisone	65 (33.5)	129 (66.5)	0.234
QTP	11 (5.7)	54 (27.8)	0.462
<b>Local Risk Factor</b>			
Extraction Before	8 (4.1)	86 (44.3)	0.078
Extraction during	5 (2.6)	1 (0.5)	<0.001
Extraction after	4 (2)	7 (3.6)	0.017
Prosthesis	5 (2.6)	33 (17)	0.936
periodontal state	19 (9.8)	70 (36)	0.001
<b>Toxic factors</b>			0.998
Tobacco	2 (1)	13 (6.7)	
Alcohol	3 (1.5)	19 (9.8)	
<b>Location</b>			
Unifocal mandible	13 (6.7)	–	<0.001
Unifocal maxilla	5 (2.6)	–	
Multifocal mandible	3 (1.5)	–	
Maxilla and mandible	4 (2)	–	

**Table 5.** Risk factors in the occurrence of ONJ.

The collected data were analyzed with the SPSS statistical system, version 20.0 for Windows. The discontinuous quantitative or discreet variables were analyzed through descriptive statistics, expressing the results in mean, deviation and standard. The frequency tables and percentages were used for qualitative variables. For the study of the association of variables we employed the chi-squared test, the T-Student test or the ANOVA factor test, depending on the application conditions. Values in which  $P \leq 0.05$  were considered statistically significant.

### 3.2.1. Clinical results

Of the 28 patients, 16 were men (57.1%) and 12 women (48.8%) with a mean age of 71.96 years (SD 8.94). According to the risk factors analyzed, 8 patients (28.5%) were diabetic, 15 (53.6%) were undergoing chemotherapy, 4 were smokers (14.3%), 14 was hypertensive (50%) and 9 (32.1%) were taking corticosteroids. The reason for treatment with bisphosphonates was oral cancer (14.3%), breast cancer (25%), prostate cancer (39.2%), multiple myeloma (10.7%) and osteoporosis (10.7%).

The most affected region of the mouth was the mandible (67.8%) followed by the upper jaw (21.4%) or both (10.7%).

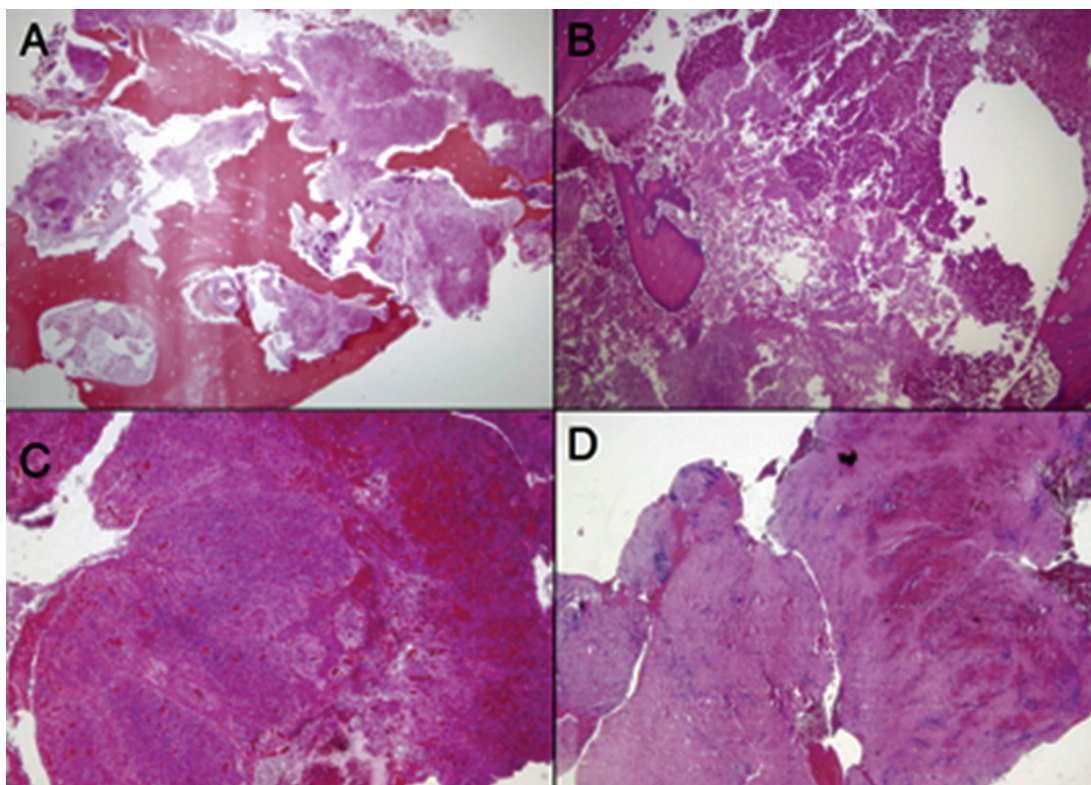
The degree of affectation was variable depending on the type of treatment. Patients on intravenous bisphosphonates had all stages of ONJ, whereas patients undergoing the oral treatment had only stage II ONJ and patients treated with radiotherapy showed both stage II (5%) and stage III (75%).

### 3.2.2. Histological results

A total of 24 of 28 patients underwent a histological study with a biopsy of a bone sequestration lesion. Of these, in 21 patients (87.5%) we proved the presence of Actinomyces within the 3 degrees of osteonecrosis of the jaws. The amount of Actinomyces present was quantified semi-quantitatively by the pathologist. The pathogen count was very abundant in degrees I and II, while in degree III the patients had lower amounts of Actinomyces (**Figure 4**).

The degree of acute and/or chronic inflammation was also evaluated. In 54.2% of the patients, the presence of Actinomyces was not accompanied by any sign of inflammation; while in the rest of the patients, it was observed that as age increased, the intensity of the inflammation also increased; therefore a lower mean age accounted for the absence of inflammation (65.31; SD: 7.91) contrasting with abundant inflammation (81.00; SD: 2.83). Such differences were statistically significant ( $F = 5.270$ ,  $P = 0.005$ ). There was acute inflammation in 37.5% of the patients being quantified as mild inflammation (two patients), moderate (five patients) and severe (two patients); the latter two were present in patients with grade II osteonecrosis, exclusively. There were only two chronic inflammation cases, one patient with grade II and another with grade III ONJ.

The relationship between the amount of Actinomyces present in the histological sections and the degree of inflammation observed in bone sequestration was evaluated. Despite not having statistically significant data, it was observed that the high amount of Actinomyces could trigger either null or an abundant inflammatory response (**Table 6**).



**Figure 4.** Histological image of bone sequestration. Histopathologic examination revealed different combinations of Actinomyces and the inflammatory response. Some cases showed abundant colonies of Actinomyces, but lacked any inflammatory infiltration (A); while in other examples this microorganism was identified along with a dense PMN infiltrate (B). PMNs were also seen in some cases, in the absence of Actinomyces (C). Last of all, in some patients, the only change consisted of fibrosis and the scarce inflammatory response was composed mainly of lymphocytes (D).

### 3.2.3. Microbiological results

Regarding the isolation of bacteria obtained through suppuration of the necrosed area, all the bacteria described by the microbiologist were recorded, which were later classified according to their aerobic or anaerobic metabolism. Aerobic bacteria were mostly found (85%) in patients with grade I and II of ONJ, being statistically significant ( $P = 0.002$ ). However, anaerobic bacteria were present in 56% of the patients in the three stages of ONJ. Although all the cases of grade III presented anaerobic bacteria, this data were not statistically significant.

Actinomyces	Inflammation				
	Null	Mild	Moderate	Abundant	Chronic
Null	0	0	1	0	0
Scarce	1	0	1	0	1
Moderate	8	1	1	0	1
Abundant	4	1	2	2	0

**Table 6.** Relationship of the amount of Actinomyces and the inflammatory response.

There was practically no significance in the families of bacterial species specific to the different degrees of osteonecrosis, except *Streptococcus* sp. which was very abundant in grade II of ONJ. Only three bacteria showed statistically significant differences in relation to the ONJ stages (Table 7, Figure 5).

Antibiograms were also performed for each of the species found, in order to guide the antibiotic pattern of these patients. We studied the six most common antibiotics, as well as the specific ones for the pathology described in the literature, we observed a variable bacterial behavior among the patients with osteonecrosis of the jaws.

Penicillin G did not show complete sensitivity in any patient against all the bacteria isolated in the cultures, in addition, there was much variability among patients regarding the response to this antibiotic (Figure 6).

The combination of amoxicillin and clavulanic acid showed good sensitivity in most patients (82.6%) although this was not statistically significant (Figure 7).

Clindamycin was effective in 40% of patients and resistant in 14.5%, while 28% of the patients showed variability in the response to this antibiotic. Azithromycin was effective in a few patients (38%) and the response was highly variable, without showing complete sensitivity to isolated bacteria (Figure 8).

Levofloxacin was effective in 42.8% of the patients, which showed good sensitivity in most cases (88.8%). Last of all, gentamicin, another antibiotic which is less frequent in our daily practice, showed good sensitivity although it was effective in few patients (38%).

	Grade I	Grade II	Grade III	P value
<i>Staphylococcus</i> sp.	0	1	1	0.372
<i>Capnocytophaga</i> sp.	2	1	0	0.008
<i>Morganella morganii</i>	0	1	0	0.817
<i>Enterobacter cloacae</i>	0	1	2	0.037
<i>Streptococcus</i> sp.	3	12	1	0.112
<i>Eikenella corrodens</i>	0	3	1	0.664
<i>Neisseria</i> sp.	3	3	0	0.004
<i>Proteus</i> sp.	0	1	0	0.074
<i>Actinomyces</i> sp.	2	3	0	0.003
<i>Veionella parvula</i>	0	0	2	0.817
<i>Peptostreptococcus</i> sp.	0	3	0	0.515
<i>Fusobacterium</i> sp.	0	1	1	0.372
<i>Prevotella</i> sp.	0	4	1	0.648
<i>Bacteroides</i> sp.	0	2	0	0.655

**Table 7.** Relationship between the isolated type of bacteria and the degree of ONJ.

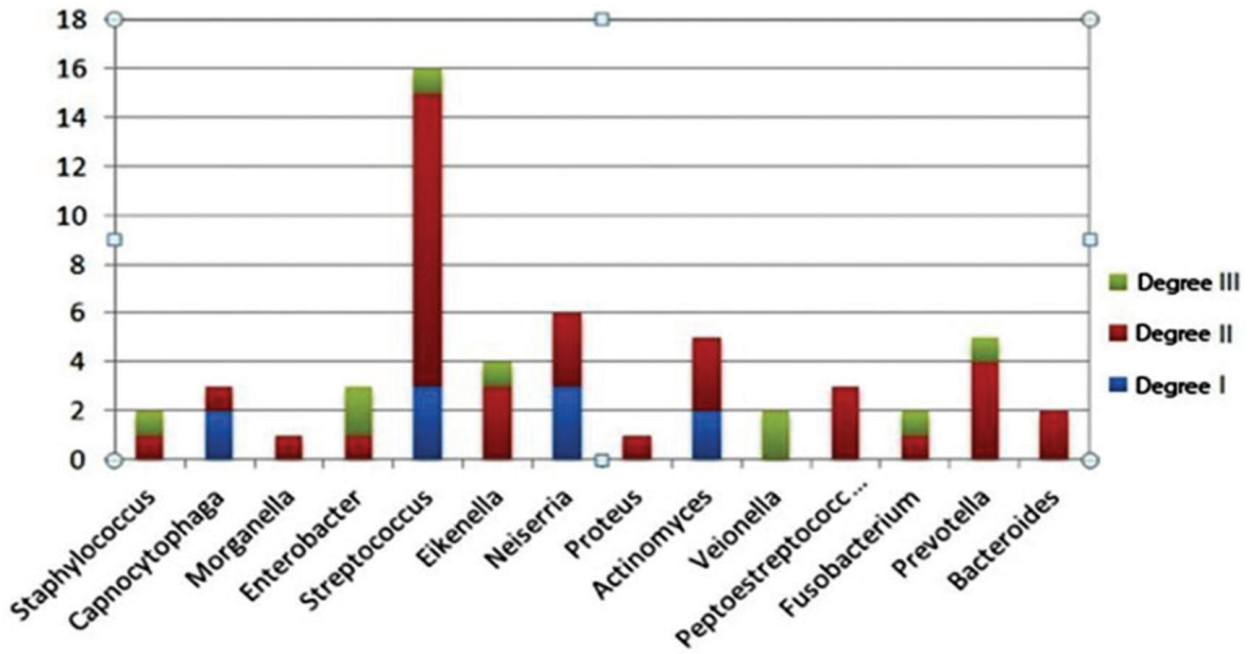


Figure 5. Relationship between the isolated type of bacteria and the degree of ONJ.

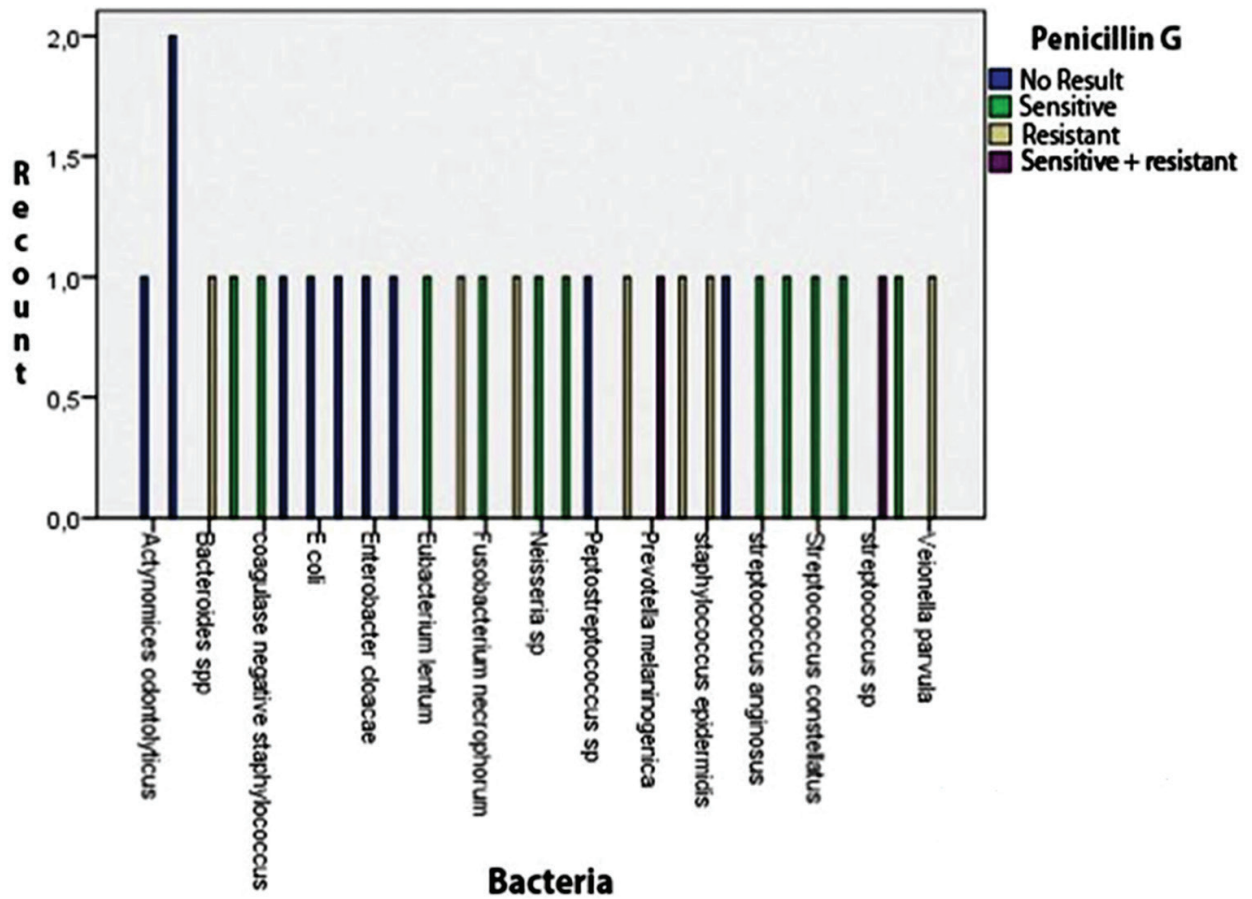


Figure 6. Antibiogram of Penicillin G.

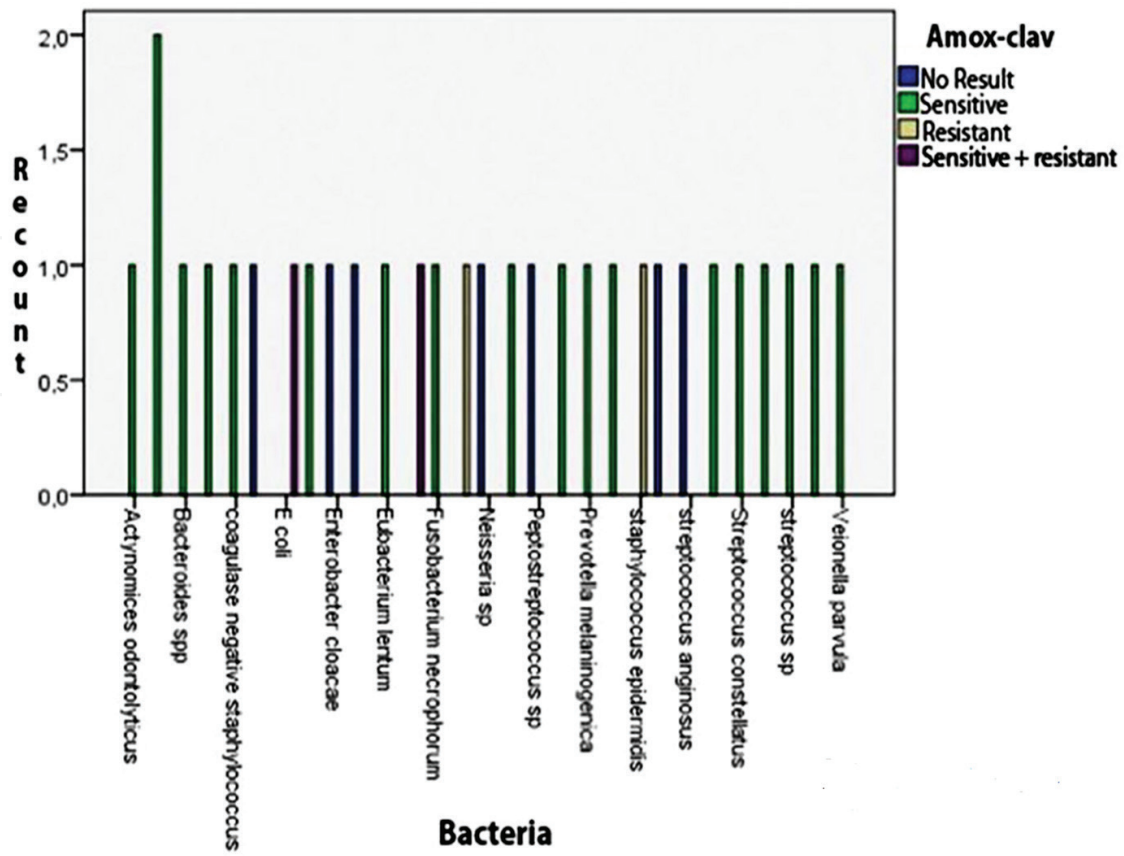


Figure 7. Antibiogram of the association of amoxicillin with clavulanic acid.

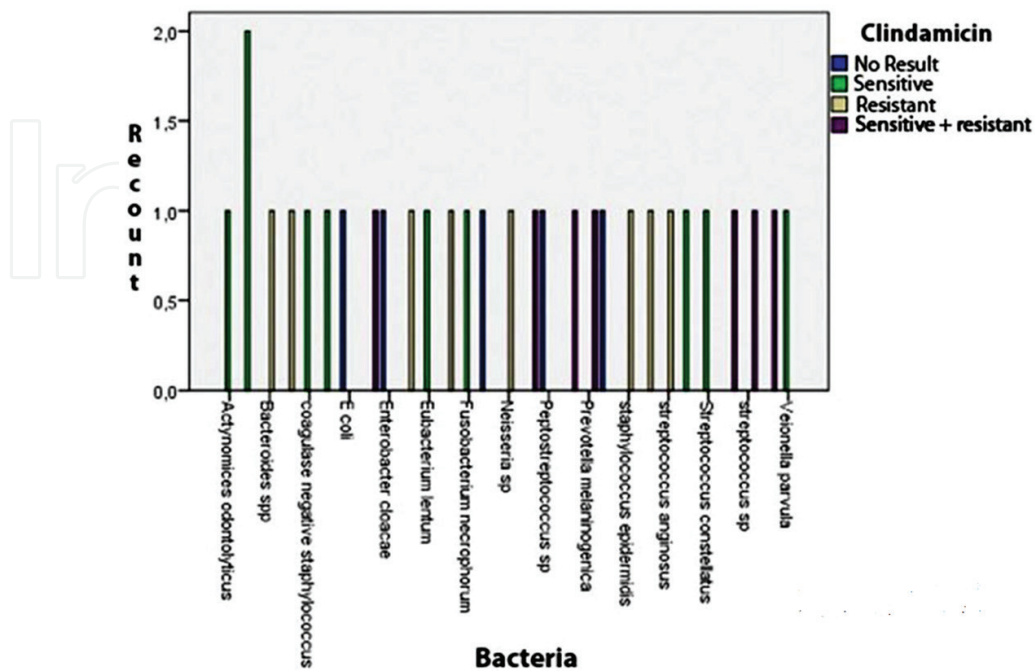


Figure 8. Clindamycin antibiogram.



## Acknowledgement

I would like to thank to Aram Ríos for his invaluable cooperation in graphic design of the book chapter.

## Author details

Mario Pérez-Sayáns<sup>1\*</sup>, Carmen Vidal-Real<sup>1</sup>, José M. Suárez-Peñaranda<sup>2</sup> and Abel García-García<sup>1</sup>

\*Address all correspondence to: perezsayans@gmail.com

1 Oral Medicine, Oral Surgery and Implantology Unit, Faculty of Medicine and Dentistry, Instituto de Investigación Sanitaria de Santiago (IDIS), Santiago de Compostela, Spain

2 Servicio de Anatomía Patológica, Hospital Clínica Universitario de Santiago, Spain

## References

- [1] Lapidus FI. Cancer and osteonecrosis of the lower jaw following irradiation. *Stomatologia (Mosk)*. 1950;**2**:34-36
- [2] Gowgiel JM. Experimental radio-osteonecrosis of the jaws. *Journal of Dental Research*. 1960 Jan-Feb;**39**:176-197
- [3] Lawrence EA. Osteoradionecrosis of the mandible. *The American Journal of Roentgenology and Radium Therapy*. 1946 Jun;**55**:733-742
- [4] Gallagher RE. Arsenic—new life for an old potion. *New England Journal of Medicine*. 1998;**339**(19):1389-1391
- [5] Cruse WP, Bellizzi R. A historic review of endodontics, 1689-1963, part 1. *Journal of Endodontics*. 1980;**6**(3):495-499
- [6] Dumlu A, Yalcinkaya S, Olgac V, Güvercin M. Osteomyelitis due to arsenic trioxide use for tooth devitalization. *International Endodontic Journal*. 2007;**40**(4):317-322
- [7] Tal M, Kaufman A, Buchner A. Bone necrosis and dentine resorption caused by Toxavit: A case report. *International Endodontic Journal*. 1978;**11**(2):77-79
- [8] Bataineh A, Al-Omari M, Owais A. Arsenical necrosis of the jaws. *International Endodontic Journal*. 1997;**30**(4):283-287
- [9] Sanders B, McKelvy B, Adams D. Aseptic osteomyelitis and necrosis of the mandibular condylar head after intracapsular fracture. *Oral Surgery, Oral Medicine, and Oral Pathology*. 1977;**43**(5):665-670

- [10] Lanigan DT, West RA. Aseptic necrosis of the mandible: Report of two cases. *Journal of Oral and Maxillofacial Surgery*. 1990;**48**(3):296-300
- [11] Sung EC, Chan SM, Sakurai K, Chung E. Osteonecrosis of the maxilla as a complication to chemotherapy: A case report. *Special Care in Dentistry*. 2002;**22**(4):142-146
- [12] Marx RE. Pamidronate (Aredia) and zoledronate (Zometa) induced avascular necrosis of the jaws: A growing epidemic. *Journal of Oral and Maxillofacial Surgery*. 2003 Sep;**61**(9):1115-1117
- [13] Gupta S, Jain P, Kumar P, Parikh PM. Zoledronic acid induced osteonecrosis of tibia and femur. *Indian Journal of Cancer*. 2009 Jul-Sep;**46**(3):249-250
- [14] Polizzotto MN, Cousins V, Schwarer AP. Bisphosphonate-associated osteonecrosis of the auditory canal. *British Journal of Haematology*. 2006;**132**(1):114-114
- [15] Advisory Task Force on Bisphosphonate-Related Osteonecrosis of the Jaws, American Association of Oral and Maxillofacial Surgeons. American Association of Oral and Maxillofacial Surgeons position paper on bisphosphonate-related osteonecrosis of the jaws. *Journal of Oral and Maxillofacial Surgery*. 2007 Mar;**65**(3):369-376
- [16] Ruggiero SL, Dodson TB, Assael LA, Landesberg R, Marx RE, Mehrotra B, et al. American Association of Oral and Maxillofacial Surgeons position paper on bisphosphonate-related osteonecrosis of the jaw - 2009 update. *Australian Endodontic Journal*. 2009 Dec;**35**(3):119-130
- [17] Ruggiero SL, Dodson TB, Fantasia J, Goodday R, Aghaloo T, Mehrotra B, et al. American Association of Oral and Maxillofacial Surgeons position paper on medication-related osteonecrosis of the jaw—2014 update. *Journal of Oral and Maxillofacial Surgery*. 2014;**72**(10):1938-1956
- [18] Khan A, Morrison A, Cheung A, Hashem W, Compston J. Osteonecrosis of the jaw (ONJ): Diagnosis and management in 2015. *Osteoporosis International*. 2016;**27**(3):853-859
- [19] Ruggiero SL, Dodson TB, Assael LA, Landesberg R, Marx RE, Mehrotra B. American Association of Oral and Maxillofacial Surgeons position paper on bisphosphonate-related osteonecrosis of the jaws—2009 update. *Journal of Oral and Maxillofacial Surgery*. 2009;**67**(5):2-12
- [20] IMS HEALTH. NPA Plus™; May 2006
- [21] American Dental Association. Report of the Council of Scientific Affairs. Expert Panel Recommendations: Dental Management of Patients on Oral Bisphosphonate Therapy. June 2006. [Cited 29 Jun 2006.] Available from URL: <http://www.ada.org/prof/resources/topics/osteonecrosis.asp>
- [22] Mavrokokki T, Cheng A, Stein B, Goss A. Nature and frequency of bisphosphonate-associated osteonecrosis of the jaws in Australia. *Journal of Oral and Maxillofacial Surgery*. 2007;**65**(3):415-423

- [23] Ault A. Jaw necrosis affects 1 in 1,700 on oral bisphosphonates. *Internal Medicine News*. 2008;**41**(15):23-23
- [24] Ruggiero SL, Fantasia J, Carlson E. Bisphosphonate-related osteonecrosis of the jaw: Background and guidelines for diagnosis, staging and management. *Oral Surgery, Oral Medicine, Oral Pathology, Oral Radiology, and Endodontics*. 2006;**102**(4):433-441
- [25] Ruggiero SL, Mehrotra B, Rosenberg TJ, Engroff SL. Osteonecrosis of the jaws associated with the use of bisphosphonates: A review of 63 cases. *Journal of Oral and Maxillofacial Surgery*. 2004 May;**62**(5):527-534
- [26] Marx RE, Sawatari Y, Fortin M, Broumand V. Bisphosphonate-induced exposed bone (osteonecrosis/osteopetrosis) of the jaws: Risk factors, recognition, prevention, and treatment. *Journal of Oral and Maxillofacial Surgery*. 2005 Nov;**63**(11):1567-1575
- [27] Hoff, AO, Toth, BB, Altundag, K, Guarneri, V, Adamus, A, Nooka, AK, Sayegh GG, Johnson MM, Gagel RF & Hortobagyi GN. Osteonecrosis of the jaw in patients receiving intravenous bisphosphonate therapy. *Journal of Clinical Oncology*. 2006;**24**(90180):8528-8528
- [28] Badros A, Weikel D, Salama A, Goloubeva O, Schneider A, Rapoport A, et al. Osteonecrosis of the jaw in multiple myeloma patients: Clinical features and risk factors. *Journal of Clinical Oncology*. 2006 Feb 20;**24**(6):945-952
- [29] Wessel JH, Dodson TB, Zavras AI. Zoledronate, smoking, and obesity are strong risk factors for osteonecrosis of the jaw: A case-control study. *Journal of Oral and Maxillofacial Surgery*. 2008;**66**(4):625-631
- [30] Zervas K, Verrou E, Teleioudis Z, Vahtsevanos K, Banti A, Mihou D, et al. Incidence, risk factors and management of osteonecrosis of the jaw in patients with multiple myeloma: A single-centre experience in 303 patients. *British Journal of Haematology*. 2006;**134**(6):620-623
- [31] Jadu F, Lee L, Pharoah M, Reece D, Wang L. A retrospective study assessing the incidence, risk factors and comorbidities of pamidronate-related necrosis of the jaws in multiple myeloma patients. *Annals of Oncology*. 2007 Dec;**18**(12):2015-2019
- [32] Hoefert S, Schmitz I, Tannapfel A, Eufinger H. Importance of microcracks in etiology of bisphosphonate-related osteonecrosis of the jaw: A possible pathogenetic model of symptomatic and non-symptomatic osteonecrosis of the jaw based on scanning electron microscopy findings. *Clinical Oral Investigations*. 2010;**14**(3):271-284
- [33] English BC, Baum CE, Adelberg DE, Sissung TM, Kluetz PG, Dahut WL, et al. A SNP in CYP2C8 is not associated with the development of bisphosphonate-related osteonecrosis of the jaw in men with castrate-resistant prostate cancer. *Therapeutics and Clinical Risk Management*. 2010 Nov 19;**6**:579-583
- [34] Sarasquete ME, Garcia-Sanz R, Marin L, Alcoceba M, Chillon MC, Balanzategui A, et al. Bisphosphonate-related osteonecrosis of the jaw is associated with polymorphisms of the cytochrome P450 CYP2C8 in multiple myeloma: A genome-wide single nucleotide polymorphism analysis. *Blood*. 2008 Oct 1;**112**(7):2709-2712.

- [35] Khamaisi M, Regev E, Yarom N, Avni B, Leitersdorf E, Raz I, et al. Possible association between diabetes and bisphosphonate-related jaw osteonecrosis. *The Journal of Clinical Endocrinology & Metabolism*. 2007;**92**(3):1172-1175
- [36] Bedogni A, Fusco V, Agrillo A, Campisi G. Learning from experience. Proposal of a refined definition and staging system for bisphosphonate-related osteonecrosis of the jaw (BRONJ). *Oral Diseases*. 2012;**18**(6):621-623
- [37] Fedele S, Porter SR, D'Aiuto F, Aljohani S, Vescovi P, Manfredi M, et al. Nonexposed variant of bisphosphonate-associated osteonecrosis of the jaw: A case series. *American Journal of Medicine*. 2010;**123**(11):1060-1064
- [38] Arce K, Assael LA, Weissman JL, Markiewicz MR. Imaging findings in bisphosphonate-related osteonecrosis of jaws. *Journal of Oral and Maxillofacial Surgery*. 2009;**67**(5):75-84
- [39] Ruggiero SL. Guidelines for the diagnosis of bisphosphonate-related osteonecrosis of the jaw (BRONJ). *Clinical Cases in Mineral and Bone Metabolism*. 2007;**4**(1):37
- [40] Mawardi H, Giro G, Kajiya M, Ohta K, Almazrooa S, Alshwaimi E, et al. A role of oral bacteria in bisphosphonate-induced osteonecrosis of the jaw. *Journal of Dental Research*. 2011 Nov;**90**(11):1339-1345
- [41] Katsarelis H, Shah NP, Dhariwal DK, Pazianas M. Infection and medication-related osteonecrosis of the jaw. *Journal of Dental Research*. 2015 Apr;**94**(4):534-539
- [42] Wimalawansa SJ. Insight into bisphosphonate-associated osteomyelitis of the jaw: Pathophysiology, mechanisms and clinical management. *Expert Opinion on Drug Safety*. 2008;**7**(4):491-512
- [43] Allen MR, Burr DB. The pathogenesis of bisphosphonate-related osteonecrosis of the jaw: So many hypotheses, so few data. *Journal of Oral and Maxillofacial Surgery*. 2009 May;**67**(5 Suppl):61-70
- [44] Lee CY, Pien FD, Suzuki JB. Identification and treatment of bisphosphonate-associated actinomycotic osteonecrosis of the jaws. *Implant Dentistry*. 2011 Oct;**20**(5):331-336
- [45] Schipmann S, Metzler P, Rossle M, Zemann W, von Jackowski J, Obwegeser JA, et al. Osteopathology associated with bone resorption inhibitors - which role does *Actinomyces* play? A presentation of 51 cases with systematic review of the literature. *Journal of Oral Pathology and Medicine*. 2013 Sep;**42**(8):587-593
- [46] De Ceulaer J, Tacconelli E, Vandecasteele S. *Actinomyces* osteomyelitis in bisphosphonate-related osteonecrosis of the jaw (BRONJ): The missing link?. *European Journal of Clinical Microbiology & Infectious Diseases*. 2014;**33**(11):1873-1880
- [47] Moghimi M, Salentijn E, Debets Ossenkop Y, Karagozoglu KH, & Forouzanfar T. Treatment of cervicofacial actinomycosis: A report of 19 cases and review of literature. *Medicina Oral, Patología Oral y Cirugía Bucal*. 2013 Jul 1;**18**(4):e627-e632
- [48] Steininger C, Willinger B. Resistance patterns in clinical isolates of pathogenic *Actinomyces* species. *Journal of Antimicrobial Chemotherapy*. 2016 Feb;**71**(2):422-427

- [49] Bocci V. Ozone as Janus: This controversial gas can be either toxic or medically useful. *Mediators of Inflammation*. 2004 Feb;**13**(1):3-11
- [50] Ripamonti CI, Cislighi E, Mariani L, Maniezzo M. Efficacy and safety of medical ozone (O<sub>3</sub>) delivered in oil suspension applications for the treatment of osteonecrosis of the jaw in patients with bone metastases treated with bisphosphonates: Preliminary results of a phase I–II study. *Oral Oncology*. 2011;**47**(3):185-190
- [51] Vescovi P, Manfredi M, Merigo E, Meleti M, Fornaini C, Rocca J, et al. Surgical approach with Er: YAG laser on osteonecrosis of the jaws (ONJ) in patients under bisphosphonate therapy (BPT). *Lasers in Medical Science*. 2010;**25**(1):101-113
- [52] Vescovi P, Merigo E, Meleti M, Manfredi M, Fornaini C, Nammour S, et al. Conservative surgical management of stage I bisphosphonate-related osteonecrosis of the jaw. *International Journal of Dentistry*. 2014;**2014**:107690
- [53] Freiburger JJ, Padilla-Burgos R, McGraw T, Suliman HB, Kraft KH, Stolp BW, et al. What is the role of hyperbaric oxygen in the management of bisphosphonate-related osteonecrosis of the jaw: A randomized controlled trial of hyperbaric oxygen as an adjunct to surgery and antibiotics. *Journal of Oral and Maxillofacial Surgery*. 2012;**70**(7):1573-1583
- [54] Atalay B, Yalcin S, Emes Y, Aktas I, Aybar B, Issever H, et al. Bisphosphonate-related osteonecrosis: Laser-assisted surgical treatment or conventional surgery?. *Lasers in Medical Science*. 2011;**26**(6):815-823
- [55] Rodriguez-Lozano, FJ, & Oñate-Sánchez, RE. Treatment of osteonecrosis of the jaw related to bisphosphonates and other antiresorptive agents. *Medicina Oral, Patología Oral y Cirugía Bucal*. 2016;**21**(5):e595
- [56] Bedogni A, Saia G, Bettini G, Tronchet A, Totola A, Bedogni G, et al. Long-term outcomes of surgical resection of the jaws in cancer patients with bisphosphonate-related osteonecrosis. *Oral Oncology*. 2011;**47**(5):420-424
- [57] Schubert M, Klätte I, Linek W, Müller B, Döring K, Eckelt U, et al. The Saxon Bisphosphonate Register—Therapy and prevention of bisphosphonate-related osteonecrosis of the jaws. *Oral Oncology*. 2012;**48**(4):349-354
- [58] Cella L, Oppici A, Arbasi M, Moretto M, Piepoli M, Vallisa D, et al. Autologous bone marrow stem cell intralesional transplantation repairing bisphosphonate related osteonecrosis of the jaw. *Head & Face Medicine*. 2011;**7**(1):1
- [59] Gonzalez-Garcia M, Rodriguez-Lozano FJ, Villanueva V, Segarra-Fenoll D, Rodriguez-Gonzalez MA, Onate-Sanchez R, et al. Cell therapy in bisphosphonate-related osteonecrosis of the jaw. *The Journal of Craniofacial Surgery*. 2013 May;**24**(3):e226–e228
- [60] Curi MM, Cossolin GSI, Koga DH, Zardetto C, Christianini S, Feher O, et al. Bisphosphonate-related osteonecrosis of the jaws—an initial case series report of treatment combining partial bone resection and autologous platelet-rich plasma. *Journal of Oral and Maxillofacial Surgery*. 2011;**69**(9):2465-2472

- [61] Cheung A, Seeman E. Teriparatide therapy for alendronate-associated osteonecrosis of the jaw. *New England Journal of Medicine*. 2010;**363**(25):2473-2474
- [62] Kim J, Kim S, Kim M. Leucocyte-rich and platelet-rich fibrin for the treatment of bisphosphonate-related osteonecrosis of the jaw: A prospective feasibility study. *British Journal of Oral and Maxillofacial Surgery*. 2014;**52**(9):854-859
- [63] Dimopoulos MA, Kastritis E, Bamia C, Melakopoulos I, Gika D, Roussou M, et al. Reduction of osteonecrosis of the jaw (ONJ) after implementation of preventive measures in patients with multiple myeloma treated with zoledronic acid. *Annals of Oncology*. 2009 Jan;**20**(1):117-120
- [64] Mehrotra, B., Fantasia, J, & Ruggiero, SL. Outcomes of bisphosphonate-related osteonecrosis of the jaw – Importance of staging and management guidelines: A large single institutional update. *Journal of Clinical Oncology*. 2008;**26**(90150):20526-20526
- [65] Corso A, Varettoni M, Zappasodi P, Klersy C, Mangiacavalli S, Pica G, et al. A different schedule of zoledronic acid can reduce the risk of the osteonecrosis of the jaw in patients with multiple myeloma. *Leukemia*. 2007;**21**(7):1545-1548
- [66] Rosen H, Moses A, Garber J, Iloputaife I, Ross D, Lee S, et al. Serum CTX: A new marker of bone resorption that shows treatment effect more often than other markers because of low coefficient of variability and large changes with bisphosphonate therapy. *Calcified Tissue International*. 2000;**66**(2):100-103
- [67] Carlson ER, Basile JD. The role of surgical resection in the management of bisphosphonate-related osteonecrosis of the jaws. *Journal of Oral and Maxillofacial Surgery*. 2009;**67**(5):85-95
- [68] Marx RE, Cillo Jr JE, Ulloa JJ. Oral bisphosphonate-induced osteonecrosis: Risk factors, prediction of risk using serum CTX testing, prevention, and treatment. *Journal of Oral and Maxillofacial Surgery*. 2007;**65**(12):2397-2410
- [69] Migliorati CA, Siegel MA, Elting LS. Bisphosphonate-associated osteonecrosis: A long-term complication of bisphosphonate treatment. *The Lancet Oncology*. 2006;**7**(6):508-514
- [70] American Association of Endodontists Position Statement. Endodontic Implications of Bisphosphonate-Associated Osteonecrosis of the Jaws. [Cited 14 Aug 2006.] RL: <http://www.aae.org/dentalpro/guidelines.htm>
- [71] Enciso R, Keaton J, Saleh N, Ahmadiéh A, Clark GT, & Sedghizadeh PP Assessing the utility of serum C-telopeptide cross-link of type 1 collagen as a predictor of bisphosphonate-related osteonecrosis of the jaw: A systematic review and meta-analysis. *The Journal of the American Dental Association*. 2016;**147**(7):551-560
- [72] Borromeo G, Tsao C, Darby I, Ebeling P. A review of the clinical implications of bisphosphonates in dentistry. *Australian Dental Journal*. 2011;**56**(1):2-9
- [73] Rodan GA, Fleisch HA. Bisphosphonates: Mechanisms of action. *Journal of Clinical Investigation*. 1996 Jun 15;**97**(12):2692-2696

- [74] Wood J, Bonjean K, Ruetz S, Bellahcene A, Devy L, Foidart JM, et al. Novel antiangiogenic effects of the bisphosphonate compound zoledronic acid. *Journal of Pharmacology and Experimental Therapeutics*. 2002 Sep;**302**(3):1055-1061
- [75] Santini D, Vincenzi B, Avvisati G, Dicuonzo G, Battistoni F, Gavasci M, et al. Pamidronate induces modifications of circulating angiogenetic factors in cancer patients. *Clinical Cancer Research*. 2002 May;**8**(5):1080-1084
- [76] Kapitola J, Zak J, Lacinova Z, Justova V. Effect of growth hormone and pamidronate on bone blood flow, bone mineral and IGF-I levels in the rat. *Physiological Research*. 2000;**49**:S101-S106
- [77] Kapitola J, Zak J. Effect of pamidronate on bone blood flow in oophorectomized rats. *Physiological Research*. 1998;**47**:237-240
- [78] Fournier P, Boissier S, Filleur S, Guglielmi J, Cabon F, Colombel M, et al. Bisphosphonates inhibit angiogenesis in vitro and testosterone-stimulated vascular regrowth in the ventral prostate in castrated rats. *Cancer Research*. 2002 Nov 15;**62**(22):6538-6544
- [79] Corso A, Ferretti E, Lunghi M, Zappasodi P, Mangiacavalli S, De Amici M, et al. Zoledronic acid down-regulates adhesion molecules of bone marrow stromal cells in multiple myeloma. *Cancer*. 2005;**104**(1):118-125
- [80] Berenson JR, Hillner BE, Kyle RA, Anderson K, Lipton A, Yee GC, et al. American Society of Clinical Oncology clinical practice guidelines: The role of bisphosphonates in multiple myeloma. *Journal of Clinical Oncology*. 2002 Sep 1;**20**(17):3719-3736
- [81] Physicians' Desk Reference. 57th ed. Montvale, NJ: Medical Economics; 2003
- [82] Hohnacker JA. Novartis 'Dear Doctor' Precautions Added to Label of Aredia and Zometa. Novartis Pharmaceuticals Corporation East Hanover USA. September 24, 2004.
- [83] Almojaly, S. The Effect of the Bisphosphonate, Alendronate, on Primary Human Alveolar Bone Cells. State University of New York at Buffalo, ProQuest Dissertations Publishing; Paris, France. 2008. 1453398
- [84] <http://www.fda.gov/ohms/dockets/ac/05/briefing/2005-4095b1.htm>
- [85] Green JR, Müller K, Jaeggi KA. Preclinical pharmacology of CGP 42' 446, a new, potent, heterocyclic bisphosphonate compound. *Journal of Bone and Mineral Research*. 1994;**9**(5): 745-751
- [86] Black DM, Cummings SR, Karpf DB, Cauley JA, Thompson DE, Nevitt MC, et al. Randomised trial of effect of alendronate on risk of fracture in women with existing vertebral fractures. *The Lancet*. 1996;**348**(9041):1535-1541
- [87] Ravn P, Bidstrup M, Wasnich RD, Davis JW, McClung MR, Balske A, et al. Alendronate and estrogen-progestin in the long-term prevention of bone loss: Four-year results from the early postmenopausal intervention cohort study: A randomized, controlled trial. *Annals of Internal Medicine*. 1999;**131**(12):935-942

- [88] McClung MR, Geusens P, Miller PD, Zippel H, Bensen WG, Roux C, et al. Effect of risedronate on the risk of hip fracture in elderly women. *New England Journal of Medicine*. 2001;**344**(5):333-340
- [89] Miller P, Roux C, McClung M, Adami S, Eastell R, Pack S, et al. Risedronate reduces hip fractures in patients with low femoral neck bone mineral density. *Arthritis and Rheumatism*. 1999;**42**(S1):S287
- [90] Wierna A, Ansonnaud A, Soria de González A, González Mac Donald M, Zamudio H. Osteonecrosis maxilar postextracción dentaria en pacientes bajo tratamiento con bifosfonatos: Presentación de 2 casos clínicos. *Revista Círculo Argentino de Odontología*. 2009;**66**(207):14-18
- [91] Bisdas S, Pinho NC, Smolarz A, Sader R, Vogl T, Mack M. Bisphosphonate-induced osteonecrosis of the jaws: CT and MRI spectrum of findings in 32 patients. *Clinical Radiology*. 2008;**63**(1):71-77
- [92] Font RG, García MM, Martínez JO. Osteochemonecrosis of the jaws due to bisphosphonate treatments. Update. *Medicina Oral, Patología Oral y Cirugía Bucal*. 2008;**13**(5):318-324
- [93] Anguita T, Agurto J, Roa I, Laissle G. Osteonecrosis asociada al uso de bifosfonatos: A propósito de un caso clínico. *Revista Médica de Chile*. 2006;**134**(9):1161-1165
- [94] Dicuonzo G, Vincenzi B, Santini D, Avvisati G, Rocci L, Battistoni F, et al. Fever after zoledronic acid administration is due to increase in TNF- $\alpha$  and IL-6. *Journal of Interferon & Cytokine Research*. 2003;**23**(11):649-654
- [95] Khan SA, Kanis JA, Vasikaran S, Kline W, Matuszewski B, McCloskey EV, et al. Elimination and biochemical responses to intravenous alendronate in postmenopausal osteoporosis. *Journal of Bone and Mineral Research*. 1997;**12**(10):1700-1707
- [96] Stepsky D, Kleinberg L, Hoffman A. Bone as an effect compartment. *Clinical Pharmacokinetics*. 2003;**42**(10):863-881
- [97] Itoh A, Akagi Y, Shimomura H, Aoyama T. Interaction between bisphosphonates and mineral water: Study of oral risedronate absorption in rats. *Biological and Pharmaceutical Bulletin*. 2016;**39**(3):323-328
- [98] Akagi Y, Sakaue T, Yoneyama E, Aoyama T. Influence of mineral water on absorption of oral alendronate in rats. *Yakugaku Zasshi*. 2011;**131**(5):801-807
- [99] Masarachia P, Weinreb M, Balena R, Rodan G. Comparison of the distribution of 3 H-alendronate and 3 H-etidronate in rat and mouse bones. *Bone*. 1996;**19**(3):281-290
- [100] Veldboer K, Vielhaber T, Ahrens H, Harges J, Streitbürger A, Karst U. Determination of zoledronic acid in human urine and blood plasma using liquid chromatography/electrospray mass spectrometry. *Journal of Chromatography B*. 2011;**879**(22):2073-2080
- [101] Allen MR. Skeletal accumulation of bisphosphonates: Implications for osteoporosis treatment. *Expert Opinion on Drug Metabolism & Toxicology*. 2008;**4**(11):1371-1378



- [102] Muntoni E, Canaparo R, Della Pepa C, Serpe L, Casale F, Barbera S, et al. Determination of disodium clodronate in human plasma and urine using gas-chromatography–nitrogen-phosphorous detections: Validation and application in pharmacokinetic study. *Journal of Chromatography B*. 2004;**799**(1):133-139
- [103] Han YR, Qin X. Determination of alendronate sodium by ion chromatography with refractive index detection. *Journal of Chromatography A*. 1996;**719**(2):345-352
- [104] Huikko K, Kostianen R. Analysis of bisphosphonates by capillary electrophoresis–electrospray ionization mass spectrometry. *Journal of Chromatography A*. 2000;**872**(1):289-298
- [105] Xie Z, Jiang Y, Zhang D. Simple analysis of four bisphosphonates simultaneously by reverse phase liquid chromatography using n-amylamine as volatile ion-pairing agent. *Journal of Chromatography A*. 2006;**1104**(1):173-178
- [106] Raccor BS, Sun J, Lawrence RF, Li L, Zhang H, Somerman MJ, et al. Quantitation of zoledronic acid in murine bone by liquid chromatography coupled with tandem mass spectrometry. *Journal of Chromatography B*. 2013;**935**:54-60
- [107] Leo GC, Darrow AL. NMR-based metabolomics of urine for the atherosclerotic mouse model using apolipoprotein-E deficient mice. *Magnetic Resonance in Chemistry*. 2009;**47**(S1):S20–S25
- [108] Zhang J, Bowers J, Liu L, Wei S, Gowda GN, Hammoud Z, et al. Esophageal cancer metabolite biomarkers detected by LC-MS and NMR methods. *PLoS One*. 2012;**7**(1):e30181
- [109] Mallol R, Rodriguez MA, Brezmes J, Masana L, Correig X. Human serum/plasma lipoprotein analysis by NMR: Application to the study of diabetic dyslipidemia. *Progress in Nuclear Magnetic Resonance Spectroscopy*. 2013;**70**:1-24
- [110] Kostara CE, Papathanasiou A, Psychogios N, Cung MT, Elisaf MS, Goudevenos J, et al. NMR-based lipidomic analysis of blood lipoproteins differentiates the progression of coronary heart disease. *Journal of Proteome Research*. 2014;**13**(5):2585-2598
- [111] Bouatra S, Aziat F, Mandal R, Guo AC, Wilson MR, Knox C, et al. The human urine metabolome. *PLoS One*. 2013;**8**(9):e73076
- [112] Beckonert O, Keun HC, Ebbels TM, Bundy J, Holmes E, Lindon JC, et al. Metabolic profiling, metabolomic and metabonomic procedures for NMR spectroscopy of urine, plasma, serum and tissue extracts. *Nature Protocols*. 2007;**2**(11):2692-2703
- [113] Dona AC, Jiménez B, Schäfer H, Humpfer E, Spraul M, Lewis MR, et al. Precision high-throughput proton NMR spectroscopy of human urine, serum, and plasma for large-scale metabolic phenotyping. *Analytical Chemistry*. 2014;**86**(19):9887-9894
- [114] Richards SA, & Hollerton JC. *Essential Practical NMR for Organic Chemistry*. John Wiley & Sons; 2010
- [115] Dieterle F, Ross A, Schlotterbeck G, Senn H. Probabilistic quotient normalization as robust method to account for dilution of complex biological mixtures. Application in <sup>1</sup>H NMR metabonomics. *Analytical Chemistry*. 2006;**78**(13):4281-4290

- [116] Geusens P. Emerging treatments for postmenopausal osteoporosis - focus on denosumab. *Clinical Interventions in Aging*. 2009;4:241-250
- [117] Fizazi K, Lipton A, Mariette X, Body JJ, Rahim Y, Gralow JR, et al. Randomized phase II trial of denosumab in patients with bone metastases from prostate cancer, breast cancer, or other neoplasms after intravenous bisphosphonates. *Journal of Clinical Oncology*. 2009 Apr 1;27(10):1564-1571
- [118] Boyle WJ, Simonet WS, Lacey DL. Osteoclast differentiation and activation. *Nature*. 2003;423(6937):337-342.
- [119] Baud'Huin M, Lamoureux F, Duplomb L, Rédini F, Heymann D. RANKL, RANK, osteoprotegerin: Key partners of osteoimmunology and vascular diseases. *Cellular and Molecular Life Sciences*. 2007;64(18):2334-2350
- [120] Teitelbaum SL. Osteoclasts: What do they do and how do they do it? *The American Journal of Pathology*. 2007;170(2):427-435
- [121] Hofbauer LC, Heufelder AE. Role of receptor activator of nuclear factor- $\kappa$ B ligand and osteoprotegerin in bone cell biology. *Journal of Molecular Medicine*. 2001;79(5-6):243-253
- [122] Reddy GK, Mughal TI, Roodman GD. Novel approaches in the management of myeloma-related skeletal complications. *Supportive Cancer Therapy*. 2006;4(1):15-18
- [123] Romas E. Clinical applications of RANK-ligand inhibition. *Internal Medicine Journal*. 2009;39(2):110-116
- [124] Bekker PJ, Holloway DL, Rasmussen AS, Murphy R, Martin SW, Leese PT, et al. A single-dose placebo-controlled study of AMG 162, a fully human monoclonal antibody to RANKL, in postmenopausal women. *Journal of Bone and Mineral Research*. 2004;19(7):1059-1066
- [125] Brown JP, Prince RL, Deal C, Recker RR, Kiel DP, de Gregorio LH, et al. Comparison of the effect of denosumab and alendronate on BMD and biochemical markers of bone turnover in postmenopausal women with low bone mass: A randomized, blinded, phase 3 trial. *Journal of Bone and Mineral Research*. 2009;24(1):153-161
- [126] Lipton A, Steger GG, Figueroa J, Alvarado C, Solal-Celigny P, Body JJ, et al. Extended efficacy and safety of denosumab in breast cancer patients with bone metastases not receiving prior bisphosphonate therapy. *Clinical Cancer Research*. 2008 Oct 15;14(20): 6690-6696
- [127] Qi W, Tang L, He A, Yao Y, Shen Z. Risk of osteonecrosis of the jaw in cancer patients receiving denosumab: A meta-analysis of seven randomized controlled trials. *International Journal of Clinical Oncology*. 2014;19(2):403-410
- [128] Scagliotti GV, Hirsh V, Siena S, Henry DH, Woll PJ, Manegold C, et al. Overall survival improvement in patients with lung cancer and bone metastases treated with denosumab versus zoledronic acid: Subgroup analysis from a randomized phase 3 study. *Journal of Thoracic Oncology*. 2012;7(12):1823-1829
- [129] Taylor K, Middlefell L, Mizen K. Osteonecrosis of the jaws induced by anti-RANK ligand therapy. *British Journal of Oral and Maxillofacial Surgery*. 2010;48(3):221-223

- [130] Aghaloo TL, Dry SM, Mallya S, Tetradis S. Stage 0 osteonecrosis of the jaw in a patient on denosumab. *Journal of Oral and Maxillofacial Surgery*. 2014;**72**(4):702-716
- [131] Matsushita Y, Hayashida S, Morishita K, Sakamoto H, Naruse T, Sakamoto Y, et al. Denosumab-associated osteonecrosis of the jaw affects osteoclast formation and differentiation: Pathological features of two cases. *Molecular and Clinical Oncology*. 2016;**4**(2):191-194
- [132] Tenore G, Palaia G, Gaimari G, Brugnoletti O, Bove L, Lo Giudice R, et al. Medication-related osteonecrosis of the jaws (MRONJ): Etiological update. *Senses and Sciences*. 2014;**1**(10):147-152