

We are IntechOpen, the world's leading publisher of Open Access books Built by scientists, for scientists

4,800

Open access books available

122,000

International authors and editors

135M

Downloads

Our authors are among the

154

Countries delivered to

TOP 1%

most cited scientists

12.2%

Contributors from top 500 universities



WEB OF SCIENCE™

Selection of our books indexed in the Book Citation Index
in Web of Science™ Core Collection (BKCI)

Interested in publishing with us?
Contact book.department@intechopen.com

Numbers displayed above are based on latest data collected.
For more information visit www.intechopen.com



Fusionless Correction of Moderate Adolescent Idiopathic Scoliosis with a New Minimally Invasive Dynamic Implant (ApiFix®) and Postoperative Schroth Scoliosis Specific Exercises-Case Series

Yizhar Floman and Michael A. Millgram

Additional information is available at the end of the chapter

<http://dx.doi.org/10.5772/intechopen.69457>

Abstract

The standard surgical management of AIS is spinal fusion. Nonfusion solutions for addressing moderate AIS curves are desirable. ApiFix® is a new posterior dynamic device consisting of an expandable ratcheting rod anchored by two pedicle screws to the concave side of the scoliotic spine. It was designed to address single, moderate Lenke type 1 or 5 curves. Surgery is performed without the addition of spine fusion of the instrumented segments. The surgical procedure is short with negligible blood loss and rapid recovery. Deformity correction is achieved by distraction leading to rod elongation. Curve correction is achieved not only during surgery but also after the surgical procedure by performing scoliosis specific exercises. These exercises activate the ratchet with further rod expansion and curve reduction. The reported cases demonstrate the efficacy of the combined approach of surgery and exercises in controlling moderate AIS. This clinical experience with the ratchet device shows consistent curve improvement and stabilization. It lends support to the concept that surgery with this new posterior dynamic device may be a viable alternative to fusion and or as an internal brace in non-compliant brace users for managing moderate AIS curves.

Keywords: moderate AIS, Lenke 1 and Lenke 5 curves, non-fusion surgery combined with Schroth SSE

1. Introduction

Adolescent idiopathic scoliosis (AIS) is a condition that affects 1–3% of children aged 10–16 years [1]. A structural lateral curvature of the spine with a rotational component develops in

otherwise healthy teenagers during puberty. Mild or moderate curves pose no health threats but may be associated with cosmetic concerns. Teenagers with mild deformities are placed under clinical surveillance and are encouraged to exercise, those with larger curves (more than 25°) are braced, while skeletally immature patients with thoracic curves exceeding 45° are candidates for surgical intervention [2]. Patients with thoracolumbar or lumbar curves usually undergo surgery with a lower than the traditional 45° Cobb angle threshold [3]. The standard surgical procedure for AIS is a spinal fusion of 8–10 vertebrae. Although surgical fusion is a successful solution for progressive spinal deformity, fusion leads to loss of spine mobility and may cause painful disc degeneration at the junctions of the mobile spine with the fused segments.

Non-fusion surgical solutions addressing moderate AIS curves may, therefore, be desirable alternatives to the traditional standard care of fusion. To this end, growth-modulating nonfusion procedures have been developed such as convex vertebral body stapling and/or convex vertebral body tethering as a surgical alternative for idiopathic scoliosis [4–6]. Stapling or tethering necessitate an anterior surgical approach to the spine and are both relatively extensive procedures. An intermediate posterior fusionless and less complex surgical approach for moderate AIS may be helpful. The ApiFix® system was developed to fill this missing gap [7].

ApiFix® is a new posterior dynamic device consisting of an expandable ratcheting rod anchored by two pedicle screws to the concave side of the scoliotic spine. Surgery is performed without the addition of spine fusion of the instrumented segments. Deformity correction is achieved by distraction leading to rod elongation. Curve correction is achieved not only during surgery but also after the surgical procedure by performing scoliosis specific exercises. These exercises activate the ratchet with further rod expansion and curve reduction. Early experience with the ApiFix® device showed it to be a viable alternative to fusion in reducing and maintaining correction of moderate AIS curves [7].

2. Indications, implant design, surgical technique, postoperative exercises

2.1. Indications

The implant is designed to be used in patients with AIS, aged 10–17 years, with a single major curve, either Lenke type 1 or Lenke type 5 curves, with a Risser sign between 0 and 4. The magnitude of the major curve should be between 30° and 60° and adequate flexibility on supine side bending views showing curve diminution to 35° or less. The device may be also used in individuals with smaller curves as an internal brace, especially in non-compliant external brace users.

2.2. Implant design

The device has a mini-ratchet mechanism that allows unidirectional elongation of an expandable rod. It is made out of titanium alloy with an Amorphous Diamond-Like Ceramic coating

(**Figure 1**). The expandable rod with polyaxial rings (eye joint) at its' extremities is anchored to the spine with two pedicle screws that are implanted around the apex of the main curve (**Figure 1**). The rod screw connection has a 50° freedom of motion. The rod can expand by 40 mm, depending on the pre-distraction rod length. Rod expansion is incremental and gradual, making the deformity correction safer. The implant has a control pin that can abort the ratchet mechanism and put the device in a neutral mode or in a locked position to create a fusion-like rod (**Figure 1**).

The implant has a CE mark.

2.3. Surgical technique

The concave side of the spine is exposed through a 10–12 cm incision usually from end to end vertebrae. The convex side of the spine is left undisturbed. Two pedicle screws are inserted into the end vertebrae and connected by the eye joints to the expandable ApiFix® device. The construct usually spans five to six disc spaces around the curve apex.

The distraction of the ratchet mechanism during surgery allows immediate correction of the deformity. No fusion is performed. The surgical procedure takes about 1 h, and blood loss is negligible. Intra-operative neuro-monitoring is utilized during surgery. Hospitalization is very short, i.e., 1–2 days. Patients are immediately mobilized without external support.




Figure 1. (A) The ApiFix® device, the expandable rod, and the control pin and (B) close-up of the ratchet and the control pin.

2.4. Postoperative exercises

Postoperative exercises were designed to activate the ratchet mechanism and to further elongate the distance between the pedicle screws. Two to three weeks after surgery, patients are directed to perform five basic Schroth-like exercises that enabled gradual elongation of the ratchet mechanism, leading to further curve reduction (**Figure 2**). The patients bend towards the corrective direction, and the device maintains the designated correction after the patients' return to the neutral position. There are five basic exercises:

(1) Hanging from an open door or bar; the exercise begins with both hands holding the door top with the hips and knees bent at 90°, while the knees and toes lean on the door. By extending the

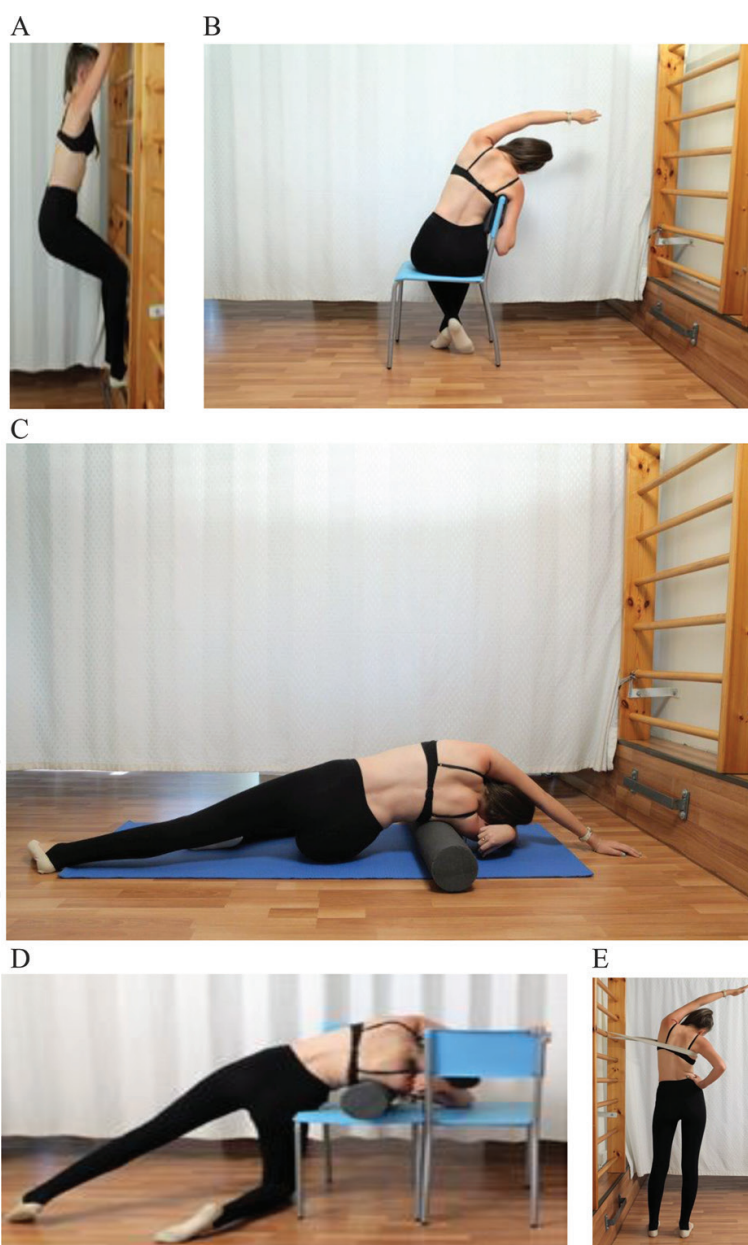


Figure 2. (A) Hanging from a door or bar, (B) chair bends, (C) bending on a roll, (D) lying on two chairs, and (E) bending over the band.

hips and knees, a traction force along the instrumented spine is exerted elongating the device. The maneuver is repeated five times. (2) Sitting on a chair with the backrest against the right rib cage (in Lenke type 1 curves). The right-hand leans on the backrest and the left one is placed over the head. The torso is leaned toward the backrest and right hand. The exercise is repeated 10–15 times. (3) Side bending on a rigid cylinder or roll placing the roll under the right rib cage. The right hand is bent under the head and the left one is placed over the head. The left arm is stretched above the head. (4) Lying on two chairs and a roll. A bolster is placed on the chair closer to the exercising individual. The patient lies on the bolster over the right side. The left hand is stretched over the head toward the second chair. (5) Standing tilts with a band. The band is placed on the right rib cage creating a fulcrum over which the torso is bent to the corrective side.

For Lenke type 5 curves, exercises are slightly modified by applying the band or bolster to the lower ribs or even to the waist usually on the left side of the body.

The patients are instructed to perform the exercises for 30 min daily, for 3–6 months after surgery. No braces are used and no restrictions on physical activity are imposed on the adolescents.

3. Illustrative case reports

Case 1: 15-year-old male presented with a Lenke type 1 curve of 48°, Risser sign was 3 (**Figure 3A**). The curve was considered too big to be controlled by bracing. He was subjected to surgery with ApiFix®. The procedure lasted about an hour, and blood loss was negligible. Hospitalization was 2 days. Initially, the curve was reduced to 26° (**Figure 3B**). After 3 months of performing the designated exercises, the curve was reduced to 18° (**Figure 3C**).

The patient is pain-free and satisfied with his cosmetic appearance.

Case 2: An 11-year-old female presented with a Lenke type 5 curve T8–L2 of 20° Risser 0. Family history revealed that her elder sister who also had AIS underwent posterior spine fusion from T4–L1. A TLSO was prescribed but the curve progressed to 43° during a period of 2 years (**Figure 4A**). At age 13, she underwent surgery with ApiFix® between T8–L1 (**Figure 4B**). The surgery lasted 50 min, and blood loss was insignificant. The immediate postoperative Cobb angle was 24°. She began exercises and the rod had elongated considerably with the exercises. At 9 months, the curve measured 20° (**Figure 4C**). Angle trunk rotation as measured by the Scoliometer was reduced from 7° preoperatively to 2° after surgery (**Figure 4D1 and D2**).

4. Discussion

The current communication describes a unique approach to moderate AIS curve correction. The new approach combines operative curve correction followed by additional correction with exercises performed after the surgery. The designated scoliosis specific exercises become an integral part of the treatment protocol with the ratchet device. This differs dramatically from scoliosis correction by spinal fusion. By avoiding spinal fusion, natural spinal motion

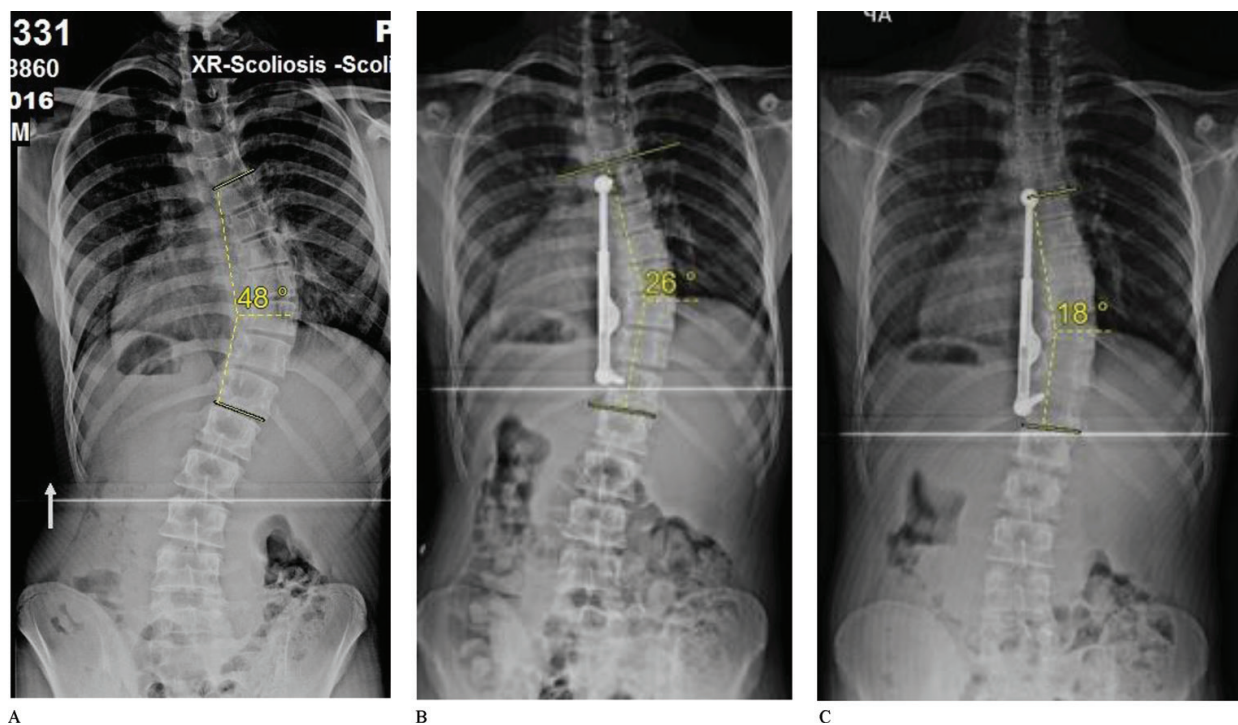


Figure 3. Case 1: (A) Preoperative standing AP X-ray, (B) postoperative standing AP X-ray, and (C) after 3 months of exercises. The expandable rod has elongated with further curve reduction.

is preserved by in large and allows further curve correction by exercising. The novel ratchet spinal implant may be looked upon as an internal brace. It is, therefore, logical to combine the internal brace with scoliosis specific exercises. Schreiber et al. in a randomized controlled study on nonoperative management of AIS reported that a combination of standard of care of AIS including bracing with Schroth scoliosis specific exercises gave a better curve correction than care without exercises [8]. Our novel concept and method also combine a brace, although internal, and exercises in the management protocol. The postoperative quasi Schroth corrective exercises help in reducing the final Cobb angle. Schreiber suggested that Schroth exercises should be considered as an add-on to the standard of care of AIS. Likewise, the correcting exercises after ApiFix® implantation should also be viewed as an add-on to surgical treatment. Theoretically, the combination of exercises with ApiFix® surgery may be more efficient than external bracing and Schroth maneuvers as the ratchet mechanism captures the correction gained during exercises.

The biomechanical properties of the ApiFix® ratchet device were investigated by Holewijn et al. [9]. They performed a biomechanical study on cadaveric thoracic spines in which they compared spinal motion with the ApiFix® device or with rigid pedicle screw fixation. The ratchet device caused a 40% decrease in range of motion in flexion/extension and about 18% in lateral bending, while the range of motion in axial rotation remained unaffected. In comparison, rigid instrumentation caused a significantly ($p < 0.05$) larger decrease in range of motion in flexion/extension (-80.9%), lateral bending (-75.0%), and axial rotation (-71.3%). The study of Holewijn et al. [9] showed that spinal range of motion was significantly less constrained by the ratcheted device as compared to rigid pedicle screw-rod instrumentation. Therefore, it can

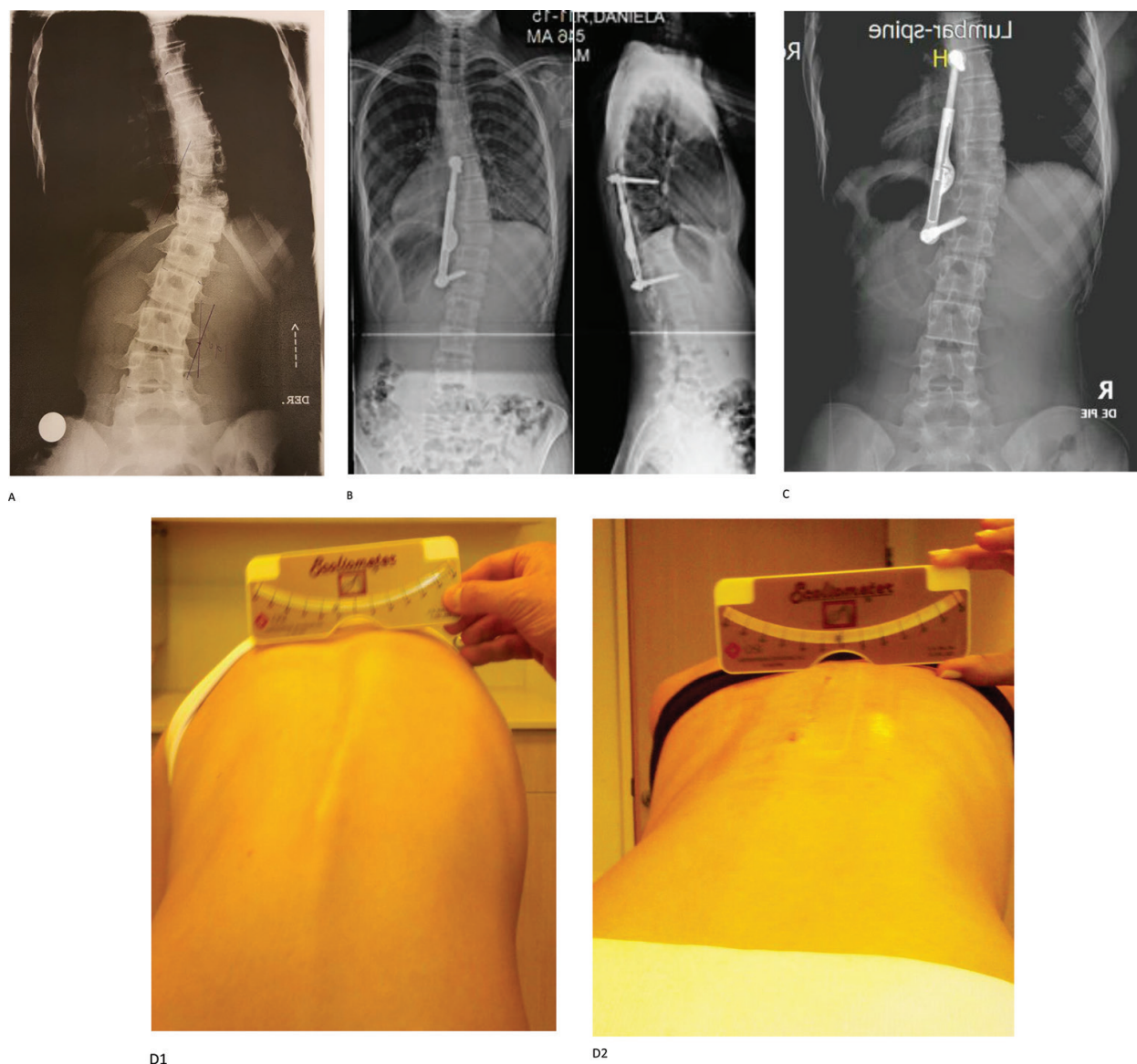


Figure 4. Case 2: (A) Preoperative standing AP X-ray and (B) postoperative standing AP & lateral X rays, and (C) after 9 months of exercises. The expandable rod has elongated with further curve reduction. D1: Scoliometer measurement before surgery 7. D2: Scoliometer measurement after surgery 2.

be assumed that the concave ratchet device enables scoliosis correction with preservation of a more physiological spinal motion. Holewijn et al. [9] also found that adjacent segment biomechanics were not significantly altered. These beneficial biomechanical characteristics can be attributed to the polyaxial connectors between the implant and screws. Therefore the risk of implant failure is deemed low as implant loads in the absence of spinal fusion are expected to be minimal.

At the time of writing, the new dynamic device was utilized in over 100 cases in Europe and Israel. The clinical outcome observed in those cases documented that curve correction and stabilization of moderate AIS without concomitant fusion were both efficient and durable (unpublished results). Although there were few failures, analysis of the failed cases revealed

that each failure was related to operation on curves bigger than 60° , rigid curves or to improper pedicle screw placement. In properly selected candidates for instrumentation with ApiFix®, no implant failures or loosening were observed. The clinical experience gained lends support to the view that the ratchet device is a valid alternative to traditional standard surgery with long instrumentation and fusion. The main curves (Lenke 1 or Lenke 5) were reduced, and curve reduction was maintained during the follow-up period. Although the ApiFix® device operates in a distraction mode that may produce kyphosis, there was no clinically significant change in the sagittal curves of the spine in the operated patients. Long term, 2–4 years follow-up, of a cohort of operated patients showed no curve progression, adding on, or implant failure.

Curve correction without fusion in the management of AIS is not a new concept. Fusionless scoliosis surgery has the benefit of curve correction without limiting spinal motion. Betz et al. [5] and Samdani et al. [6] reported growth-modulating convex vertebral body stapling and/or convex vertebral body tethering as a nonfusion surgical alternative for idiopathic scoliosis that occurs before the onset of the adolescent growth spurt. The published clinical results of that technique are promising [4–6]. The indications chosen for the use of ApiFix® in managing moderate AIS are almost identical to the indications of vertebral body tethering, although the surgical approach (posterior vs. anterior) and the age of the patients are different [6]. Some of the shortcomings of vertebral body tethering/stapling include the inability to predict the amount of curve correction and whether overcorrection will occur. In contrast, the final curve correction with ApiFix® can be predicted to closely match the magnitude seen on the preoperative bending views, and there is no possibility of overcorrection.

In addition to the loss of natural spinal motion, standard fusion surgery has additional disadvantages, including considerable blood loss, requiring blood transfusions [10, 11], a 12% prevalence of non-neurologic complications [11, 12], late infections, and pseudoarthrosis. Almost all complications can be avoided by the use of ApiFix®: specifically, there is minimal blood loss and no need for blood transfusion, the prevalence of non-neurologic complications is negligible, neurological complications can be expected to be significantly reduced by the use of only two pedicle screws and the gradual nature of the deformity correction, and there is no risk of pseudoarthrosis since fusion is not attempted. The ultra-short operative time and hospital stay are also significant advantages.

In conclusion, our experience with this novel dynamic device demonstrated consistent curve improvement and stabilization. It lends support to the concept that surgery with this new posterior dynamic device combined with postoperative scoliosis specific exercises may be a viable alternative to fusion and non-compliant brace users for managing moderate AIS curves.

Author details

Yizhar Floman* and Michael A. Millgram

*Address all correspondence to: yizharfloman@gmail.com

Israel Spine Center, Assuta Hospital Tel Aviv, Israel

References

- [1] Weinstein SL, Dolan LA, Cheng JCY, Danielson A, Morcuende JA. Adolescent idiopathic scoliosis. *Lancet* 2008;**371**:1527-1537
- [2] de Kleuver M, Lewis SJ, Gerscheid NM. et al. Optimal surgical care for adolescent idiopathic scoliosis: An international consensus. *European Spine Journal*. 2014;**23**:2603-2618
- [3] Souder C, Newton PO, Shah SA, Lonner BS, Bastrom TP, Yaszay B. Factors in surgical decision making for thoracolumbar/lumbar AIS: It's about more than just the curve magnitude. *Journal of Pediatric Orthopaedics*. 2016; 3 Mar. DOI: 10.1097/BPO.0000000000000746. [Epub ahead of print]
- [4] Betz RR, Kim J, D'Andrea LP. et al. An innovative technique of vertebral body stapling for the treatment of patients with adolescent idiopathic scoliosis: A feasibility, safety, and utility study. *Spine*. 2003;**28**:S255-S265
- [5] Betz RR, Ranade A, Samdani AF. et al. Vertebral body stapling: A fusionless treatment option for a growing child with moderate idiopathic scoliosis. *Spine*. 2010;**35**:169-176
- [6] Samdani AF, Ames RJ, Kimball JS. et al. Anterior vertebral body tethering for idiopathic scoliosis: Two-year results. *Spine*. 2014;**39**:1688-1693
- [7] Floman Y, Burnei G, Gavrilu S. et al. Surgical management of moderate adolescent idiopathic scoliosis with ApiFix®: A short peri-apical fixation followed by post-operative curve reduction with exercises. *Scoliosis*. 2015;**10**:4
- [8] Schreiber S, Parent EC, Moez EK. et al. Schroth physiotherapeutic scoliosis-specific exercises added to the standard of care lead to better Cobb angle outcomes in adolescents with idiopathic scoliosis-an assessor and statistician blinded randomized controlled trial. *PLoS One*. DOI: 10.1371/journal.pone.0168746. 29 December 2016
- [9] Holewijn RM, de Kleuver M, van der Veen AJ. et al. A novel spinal implant for fusionless scoliosis correction: A biomechanical analysis of the motion preserving properties of a posterior peri-apical concave distraction device. *Global Spine Journal*; First Published April 7, 2017. DOI: 10.1177/2192568217699377. In press
- [10] Shapiro F, Sethna N. Blood loss in pediatric spine surgery. *European Spine Journal*. 2004;**13**(Suppl 1):S6-S17
- [11] Newton PO, Marks MC, Bastrom TP. et al. Surgical treatment of Lenke 1 main thoracic idiopathic scoliosis. *Spine*. 2013;**38**:328-338
- [12] Reames DL, Smith JS, Fu KM. et al. Complications in the surgical treatment of 19360 cases of pediatric scoliosis. A review of the scoliosis research society morbidity and mortality data base. *Spine*. 2011;**36**:1484-1489

