

We are IntechOpen, the world's leading publisher of Open Access books Built by scientists, for scientists

4,800

Open access books available

122,000

International authors and editors

135M

Downloads

Our authors are among the

154

Countries delivered to

TOP 1%

most cited scientists

12.2%

Contributors from top 500 universities



WEB OF SCIENCE™

Selection of our books indexed in the Book Citation Index
in Web of Science™ Core Collection (BKCI)

Interested in publishing with us?
Contact book.department@intechopen.com

Numbers displayed above are based on latest data collected.
For more information visit www.intechopen.com



Diagnosis of Tuberculosis among Children and Adolescents

Clemax Couto Sant'Anna,
Maria de Fátima B. Pombo March and
Rafaela Baroni Aurílio

Additional information is available at the end of the chapter

<http://dx.doi.org/10.5772/intechopen.69227>

Abstract

The authors discuss the challenging aspects of the diagnosis of tuberculosis in children and adolescents, since there is no gold standard for its diagnosis. The different clinical and radiological presentations and the low bacteriological positivity of tuberculosis in childhood are grounds for confrontation to the present. Immunological tests called interferon gamma release assays (IGRAs) failed to overcome the tuberculin skin test in practice. Advances with nucleic acid amplification tests, on the other hand, have contributed to the diagnosis of tuberculosis among adolescents. Standardized systems for diagnosis can be useful as tools for screening or for decision-making in childhood tuberculosis.

Keywords: tuberculosis, diagnosis, child, adolescents

1. Introduction

It is estimated that one-third of the world population is infected by *Mycobacterium tuberculosis* and that each year about nine million people develop the disease, out of which 11% are children. This percentage can be higher in countries with high burden of tuberculosis (TB). At least one million children are sick with TB every year. In 2015, as many as 210,000 children died from TB, out of which 40,000 were patients coinfecting with HIV [1, 2].

It is believed that genetic predisposition influences the resistance of certain individuals who, even in contact with patients with baciliferous TB, are not infected with *M. tuberculosis* [3].

In childhood, the distinction between infection and disease is often difficult. Some authors avoid the term latent TB (or latent TB infection) in children, preferring to use the term TB

infection. The progression of infection to disease can be subtle and go unnoticed. This difficulty becomes more remarkable, often in extrapulmonary TB [2, 3].

From a practical point of view, the diagnosis of TB infection occurs when the child is asymptomatic with normal chest radiography and a reactive TB skin test (TST) or interferon gamma release assays (IGRA). On the other hand, the diagnosis of TB disease or active TB is a challenge. It occurs when the child is symptomatic (with symptoms consistent with TB) and chest or other X-ray is abnormal, compatible with TB. TST or IGRA can be reactive or not.

2. Differences between pulmonary tuberculosis in children and adolescents

The WHO has adopted standards for TB management in childhood that emphasize the importance of clinical, radiological, and epidemiological data consistent with TB and bacteriological confirmation, where possible, to diagnose the disease. Anti-HIV serology is also useful, especially in endemic areas of both diseases [4]. Even today these elements are essential for the diagnosis, since bacteriological confirmation is difficult in general, in children. Children mostly develop primary TB and are non-bacilliferous or paucibacillary (in 80% of cases the diagnosis is made without bacteriological confirmation). Up to 7 or 8 years of age, children do not know how to expectorate properly to take samples for examination and, in addition, TB in this age group is usually paucibacillary, that is, with sputum smear negative. Recently, the incorporation of molecular diagnosis of TB allowed positive results in a higher percentage than those observed with the smear. Yet TB in children differs fundamentally from the disease in adults, as in childhood forms of negative TB prevail [4].

It is important to divide TB in childhood into two aspects. TB in children up to 10 years of age (TB in children) and from 10 years of age (TB in adolescents). In the first case, most of the forms are *primary TB*. In adolescents, most are *adult-type TB*. That is, it is similar in clinical and radiological presentation to the pattern seen in adults. Adolescents are often bacilliferous and may transmit TB, develop excavated pulmonary forms, and, moreover, are able to cough and eliminate bacilli, similar to what occurs in adults [5, 6]. To collect specimens for bacteriological examination of children is only possible, most of the times, with the use of gastric lavage and induced sputum, since children under 5 or 6 years of age are almost unable to expectorate. The sputum smear or other specimen is processed by the traditional Ziehl-Neelsen method. The culture can be performed by Loewstein-Jensen method or liquid media—Ogawa or Middlebrook. More recently, molecular methods of nucleic acid amplification (NAATs) have been advocated. Among these methods, the *Gene-Xpert MTB/RIF* method (Cepheid, California) was recommended by the WHO in 2013 to diagnose TB in childhood [5, 7, 8].

Note that in childhood, compared to a case with high clinical suspicion, although the bacteriological and molecular tests are negative, the diagnosis of TB can and should be done.

Serological diagnosis of childhood TB was insistently sought, as it does not depend on the bacterial burden in the lesions. This is an advantage in patients whose disease progresses with

small number of bacilli. However, a study with commercially available serum tests in 2011 supported the WHO position of not recommending them for routine use. Thus, serological methods are no longer used as a diagnostic tool in children [3].

In adolescents, the diagnosis of TB may be bacteriologically proven in most cases. Patients from this age group with suspected TB are, most of the times, able to expectorate and are bacilliferous [5, 6, 9]. Soon, sputum smear microscopy can be a useful method, associated with clinical and radiological findings.

Table 1 shows differences in pulmonary TB in children and adolescents.

Children (primary TB)	Adolescents (≥10 years old) (adult-type TB)
Signs and symptoms: persistent fever, weight loss, interruption or loss in height and weight percentile, cough > 2 weeks, fatigue, night sweats	Signs and symptoms: persistent fever, cough >2 weeks, night sweats, weight loss, blood spitting
Contact with adult with TB	There may be no history of contact with people with TB
Radiography: enlarged mediastinal lymph nodes, miliary pattern, pneumonia with no response to antibiotics	Radiography: infiltration in the upper third, excavations, pneumonia
Slow evolution pneumonia	Slow evolution pneumonia
Reactive tuberculin skin test	Reactive tuberculin skin test
Negative bacteriological tests	Positive bacteriological tests (AFB and culture)
Positive Xpert* in a few cases (~10%)	Positive Xpert in most cases

*Gene-Xpert MTB/RIF.

Table 1. Differences in pulmonary tuberculosis in children and adolescents.

3. Basis for the clinico-radiological diagnosis

Some risk factors for active TB in childhood continue to be valued for the diagnosis of active TB [4]:

- Intradomiciliary contact with a bacilliferous case recently diagnosed
- Under 3 years of age
- HIV infection
- Severe malnutrition

The clinical manifestations of TB, especially in young children, are subtle and may go unnoticed. Discrete changes such as weight loss or lack of weight gain, fatigue, and decreased interest in playing and decreased physical activity can be frequent and sometimes are not noticed by the family. Unexplained fever, irritability, or nystagmus can be subtle findings in the early forms of meningoencephalitis caused by TB, for example. TB meningitis is a case of

clear cerebrospinal fluid (CSF), the laboratory test of which shows a predominance of monocytes in the early stages and lymphocyte stage, in evolution, lower glucose blood sugar, and high levels of protein [4].

Pulmonary TB is taken into account in some situations, such as slow evolution pneumonia. Cases where the child is being treated with antibiotics for acute pneumonia and shows no good performance should be valued as suggestive of TB. Most relevant clinical data such as evening fever, weight loss, profuse night sweats, and coughing or combinations of these signs and symptoms may facilitate suspected diagnoses of TB, especially if it has remained for over two weeks.

Some aspects remain as challenges for the diagnosis of TB in children. Young infants may present a subtle case of TB, with signs and symptoms that are confused with other infectious and noninfectious diseases. In such cases the diagnosis may be delayed by a longer or shorter time, depending on the diagnostic suspicion capacity of the health team, and its consequences can be disastrous. TB externalized as severe and acute pneumonia (patients admitted to ICU on ventilatory failure) is rare and difficult to diagnose. The suspected clinical appearance of TB in HIV-infected patients or with severe malnutrition or the discovery of HIV in patients with TB almost always confuses doctors who are attending such patients. An extensive differential diagnosis of diseases related to HIV immunosuppression, which are confused with TB is necessary. It is no less difficult to diagnose multidrug-resistant TB (MDR-TB) in children. In general, contact with adults with MDR-TB is the key to establish such a diagnostic suspicion [2, 10]. The performance of susceptibility testing of patient specimens with suspected MDR-TB is of limited use in childhood, because most cases are negative (no bacillus). When bacteriological examinations of the child cannot be done, but information is available on the sensitivity to adult drugs with which the child comes into contact, it can be assumed that his/her treatment is done with the same regimen of adult MDR-TB. When the child's clinical specimen is available and it is possible to perform Xpert, rifampicin resistance may be a proxy resistance to isoniazid. That is, there is high probability of being a case of MDR-TB. More recently, *Line-probe assays* have become available, which can simultaneously detect resistance to rifampicin and isoniazid. Another promising method is *MTBDR-sl*, which detects resistance to fluoroquinolones, aminoglycosides, and ethambutol simultaneously. These latest tests are rarely used in childhood (Heemskerk, Guidance).

Although there is more radiological and clinical data suggestive of TB than others, the epidemiological context and the clinical picture have to be taken into account to achieve the diagnosis of TB. Since there is no gold standard for the diagnosis of TB in childhood, it is necessary to consider the epidemiological reality of the region where the work is being done. Is it an endemic area for TB? Is the patient followed up in a basic health unit? Or in a reference center? Has the child with suspected TB had contact with an adult with TB or suspected TB? Was this a sporadic or lasting contact? Has the child suspected of intrathoracic TB been treated with antibiotics for common germs recently, with no successful result? All these questions may help contextualize the highest probability or not of diagnosing the disease in the child.

The possible contact of the child with an adult (especially if bacilliferous) is of great interest especially in young children. Infants and preschool children tend to have closer contact with adults than children of school age and adolescents. Thus, the history of contact with a person with TB can be epidemiologically valuable data on suspected TB diagnosis in childhood.

Household contact is more important than an external or sporadic one. However, in certain locations, the difference between household and external contact is subtle. In poor communities, it is common for people to live together in neighboring houses; children are cared for by people in these communities and sleep in their relatives' houses. So it is worth asking if the child has contact with other people supposedly with TB (cough > 3 weeks) in or out of his/her home. In nurseries or schools of endemic regions of TB, cases are sometimes discovered where employees or teachers with TB who were diagnosed late and may have infected children who interacted with them. A situation of extreme gravity is the occurrence of TB cases in pediatric intensive care units (PICU) or nurseries. Newborns in condition of extreme vulnerability can be infected by *M. tuberculosis* and can develop the disease, the diagnosis of which is often difficult.

It is known that the period of greatest risk of developing TB is the first 2 years following the primary infection by *M. tuberculosis*. This interval of 2 years is the most appropriate time to initiate preventive measures such as treatment of latent TB infection (isoniazid preventive therapy, IPT) [10].

4. Radiological diagnosis

The most common radiological patterns of pulmonary TB in children are hilar lymphadenopathy identified on front X-ray and more visible in profile incidence (**Figure 1a** and **1b**); miliary

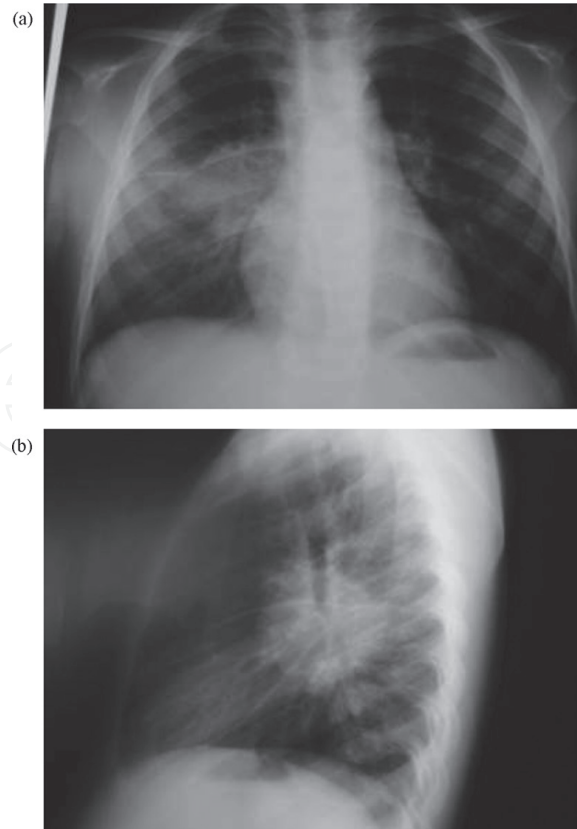


Figure 1. (a and b) Enlarged hilar lymph glands: front and profile incidences (Primary TB).

aspect—diffuse micronodular pattern in both hemithoraces, corresponding to hematogenous spread of TB (**Figure 2**) and appearance of alveolar pneumonia, that is, pattern of bacterial pneumonia caused by common germs, like pneumococcus, which may only be a case of TB when it becomes a case of slow evolution, not responsive to antibiotics (**Figure 3**) [4, 10]. It is often emphasized that many times we observe clinical and radiological dissociation in TB in children. The clinical evaluation of the child is disproportionately favorable in relation to the extent of radiation injury. That is, the radiological image suggests a serious pneumonia but the patient does not show signs of severity that would be expected in a pneumonia caused by common germs.

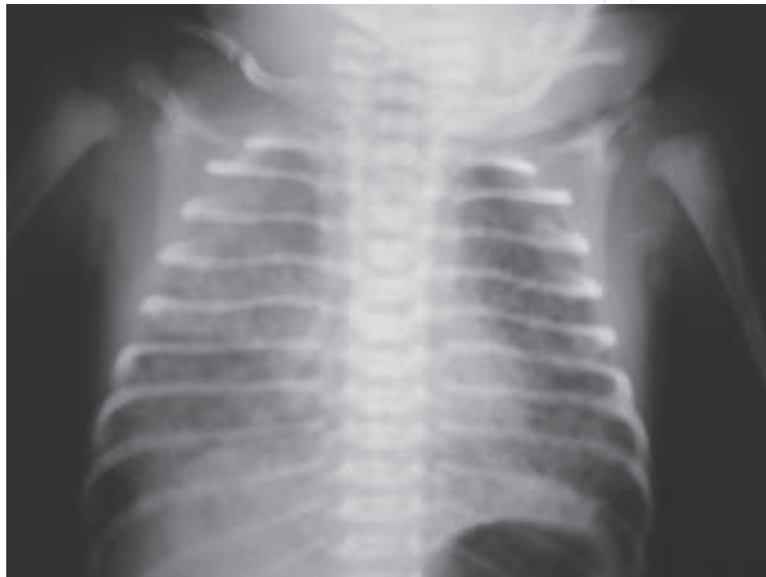

Figure 2. Micronodules in both lungs; miliary TB.

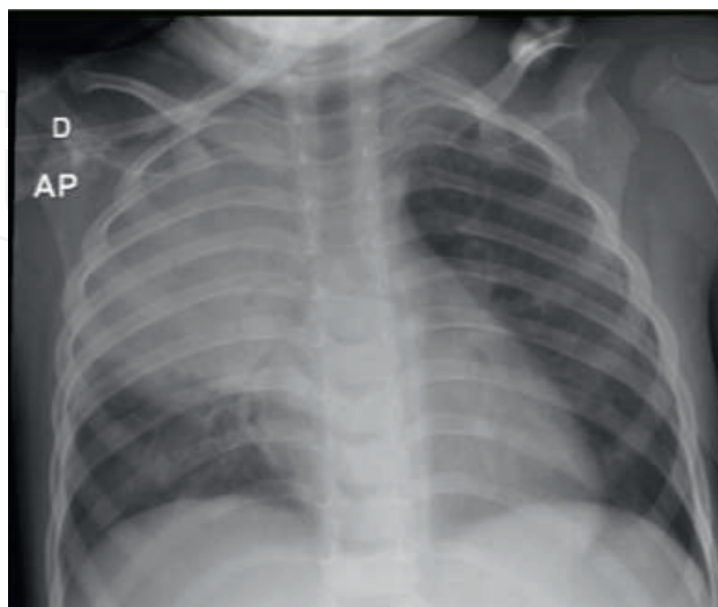


Figure 3. Slow evolution pneumonia; radiological aspect of a Pneumococcus pneumonia. Infiltrate on the left lung.

Some of these radiological findings in suspected cases of TB in children always require some differential diagnoses. Thus, the miliary pattern may appear on acute histoplasmosis or lung metastases of neoplasm (**Figure 4**); the unilateral or bilateral adenomegalies may arise in the course of Hodgkin's disease or sarcoidosis, and slow progression of pneumonia may also occur in atypical pneumonia (for *Mycoplasma*, for example), pneumonia caused by common germs, actinomycosis, nocardiosis, and other noninfectious agents in immunocompromised patients. In adolescents, radiological aspects are identical to the pattern seen in adults: adult-type TB (**Figure 5**).

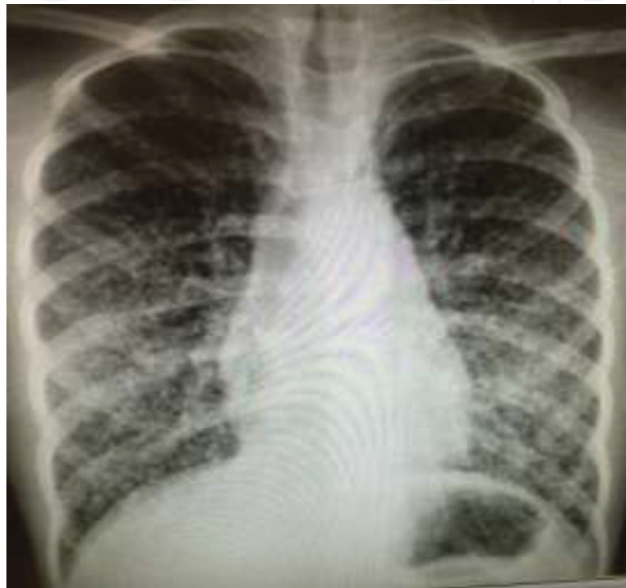

Figure 4. Micronodules in both lungs. Aspect of miliary TB. In fact, it was a thyroid carcinoma with metastases.

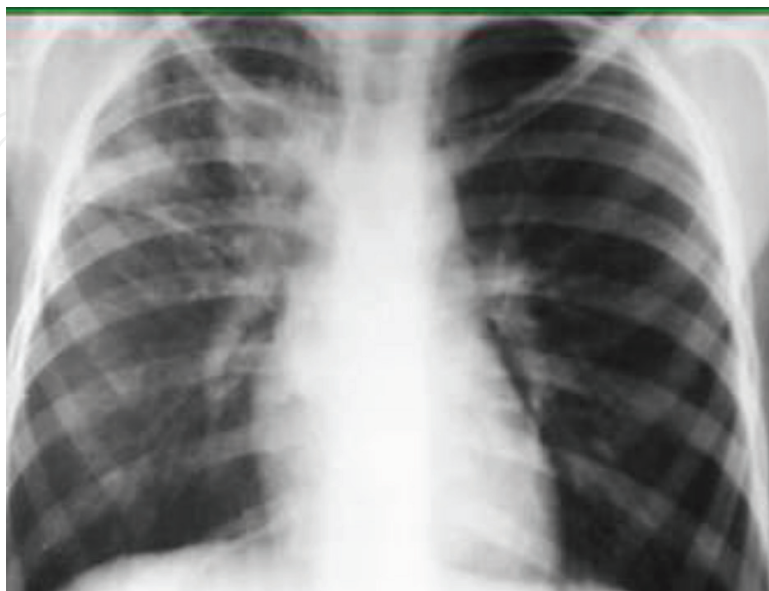

Figure 5. Pulmonary infiltrate in upper zone of the right lung. Aspect of TB *adult type*.

5. Immunological diagnosis

The main methods of immunological diagnosis of TB are the tuberculin skin test (TST) and *interferon gamma release assay* or IGRA.

The TST with PPD, conducted by the Mantoux technique, introduced in 1907, is the intradermal injection of 5 tuberculin units (TU) of purified protein derivative PPD-S (PPD) or 2 TU PPD RT23 (are equivalent). In the event of cellular immunity to such tuberculin antigens, a delayed hypersensitivity reaction will occur within 48–72 h [11].

The reaction will cause skin induration at the injection site, and its transverse diameter must be measured (induration mm) by a trained individual and interpreted using stratified cutoffs: 0–4 mm = no reaction; 5 mm or more = reaction.

Immunity measured by TST may also reflect exposure to other environmental mycobacteria, vaccination by BCG (*Bacillus Calmette–Guérin–Mycobacterium bovis*), or a previous TB infection. This type of reactivity can lead to false-positive results. On the other hand, false negative results may occur especially in immunosuppressed people, for example, with advanced HIV infection or using immunosuppressive medication [3].

The IGRA is an *in vitro* test which detects the production of IFN- γ in peripheral blood by T cells of the host infected by *M. tuberculosis*. The identification of immunogenic proteins of the mycobacteria, antigens ESAT-6, CFP-10, and TB 7, which are specifically expressed by pathogenic strains of *M. tuberculosis* complex, allowed the development of IGRA. These antigens are encoded in the region of difference 1 (RD1) of the genome of *M. tuberculosis*. RD1 contains genes encoding the secretive system of the bacillus, known as ESX-1. Such antigens are very specific of *M. tuberculosis* although there is some evidence of cross-reactivity with *Mycobacterium leprae*, not yet proven; positive results in individuals infected with *Mycobacterium marinum* and *Mycobacterium kansasii* have also been evidenced [3, 11].

There are two types of IGRA. The test conducted by QuantiFERON TB Gold methodology allows the measurement of *in vitro* level of IFN- γ produced by T cells that have been stimulated by the said antigens. The result is reported as number of IFN- γ in international units (IU) per milliliter. An individual is considered positive if the amount of IFN- γ is above the cutoff point of the test (considering the negative control). Another method may be used: T-SPOT.TB. It is an immunosorbent assay (ELISPOT) performed in separate and counted mononuclear cells from peripheral blood which are incubated with ESAT-6 and CFP-10 antigens. The result is reported as the number of T-cells producing IFN- γ (spot-forming cells). An individual is considered positive if the points count in the antigens exceeds the negative control points. Indeterminate IGRA results may occur due to a low IFN- γ response of the positive control (mitogen) or a high IFN- γ response of the negative control. Further studies are needed on this test in children [7, 11].

6. IGRA and TST in tuberculosis diagnosis in children

The purpose of carrying out the TST or IGRA in children is to determine whether there is or not *M. tuberculosis* infection while other factors such as contact history and clinical and

radiological picture will allow diagnosis. Thus, the negative result of these tests does not exclude TB disease, nor does its positive result confirm it. Both tests have limitations inherent in specific methodologies and rationales. In addition, IGRAs are still poorly studied in children living in regions with high TB prevalence or HIV-infected children [7]. Some studies suggest that in children above 5 years of age vaccinated with BCG, IGRAs may be preferred to the TST, whereas in children who have not been vaccinated with BCG, the IGRAs and TST are equally indicated. In Brazil, to consider a child to be infected with TB, the cutoff point of the TST ≥ 5 mm was adopted in children vaccinated more than 2 years or in immunosuppressed children; in children vaccinated with BCG less than 2 years, the cutoff point is ≥ 10 mm. These cutoff points were decided as above, since during the 2 years after the application of BCG vaccine, the TST reaction will gradually decline [6].

IGRAs and TST alone do not allow the diagnosis of TB disease; its role is to indicate TB infection. Both tests have a similar sensitivity for detecting infection by *M. tuberculosis*. More studies are needed in children, because IGRAs still yield indeterminate results, which are justified by the low capacity of producing immunoglobulins in children in early childhood. In patients infected with HIV, the sensitivity of IGRAs is low, similar to what occurs with the TST [11].

The cost of IGRAs is much higher and is also technically more complex than the TST. Furthermore, it involves collecting blood, which is a limitation in the case of children. On the other hand, the TST requires two visits to the clinic in order to get the result within 48–72 h. The trend of international standards is to keep the TST as a standard for identifying cases of TB infection, at the expense of IGRAs, due to the advantages of the TST in terms of cost, more reliable results in small children, and lack of need for laboratory resources [4].

Table 2 lists the main differences between IGRAs and TST.

Characteristic	TST	IGRA
Antigens used	Many, PPD	3 (QFT) or 2 (T-SPOT)
Sample	Intradermal injection	Blood draw
Patient visits required	2	1
Distinguish between Latent TB and TB disease	No	No
Cross-reactivity with BCG	Yes	No
Cross-reactivity with non-TB mycobacteria	Yes	Only rare species *
Differing positive values by risk	Yes (5-10-15)	No
Causes boosting	Yes	No
Subject to boosting by previous TST	Yes	Possible
Durability over time (stays positive with or without treatment)	Yes	Unknown
Difficulties with test reproducibility	Yes	Yes
Relative cost	Lower	Higher
Location of need for trained staff	“Bedside”	Laboratory

Characteristic	TST	IGRA
Estimated specificity in BCG-unvaccinated children	95–100%	90–95%
Estimated specificity in BCG-vaccinated children	49–65%	89–100%
Estimated sensitivity (confirmed TB disease)	75–85%	80–85%
Estimated sensitivity (clinical TB disease)	50–70%	60–80%

**M. marinum*, *M. kansasii*, *Mycobacterium szugai*, *Mycobacterium flavescens*.

Source: Ref. [11].

Table 2. Comparison of the TST and IGRA.

7. Molecular diagnosis

The Xpert MTB-Rif system (Xpert) is a test based on nucleic acid amplification used to detect *M. tuberculosis* and for the screening of drug-resistant strains. It uses real-time polymerase chain reaction (PCR) technique, on the Gene Xpert platform, which allows to integrate three processes: purification, concentration, and amplification of nucleic acids by polymerase chain reaction (PCR) and detection of nucleic acid sequences in the genome of *M. tuberculosis*, specifically in *rpoβ* gene. This technique does not require mycobacterial DNA manipulation after amplification and thus reduces the complexity and risk of cross reactivity by DNA product amplification [12].

Not only does it allow, in a period of 2 h in the laboratory, to identify *M. tuberculosis* but also to detect bacterial resistance to rifampicin (RIF) by amplification, using PCR, of five overlapping probes which are supplemental to the region determining RIF resistance, consisting of 81 base pairs of *rpoβ* gene in *M. tuberculosis*. Then, this region is examined in order to identify mutations associated with resistance [3].

It is a quick, highly automated test and does not depend upon the machine operator. The only manual step involves adding the correct dose of the reagent into the specimen under analysis, and it is subsequently homogenized for 15 min and transferred to the Xpert cartridge.

The system consists of a Gene Xpert instrument, a computer, a barcode reader, and a pre-installed software to perform tests on samples taken and to view the results generated on the screen and to report as negative or positive *M. tuberculosis*, as well as to report whether sensitive or not to RIF. However, a positive result does not necessarily indicate the presence of viable bacilli, since the method can identify the DNA of live or dead microorganisms [7, 12].

Various specimens (organic liquids, aspirated peripheral ganglia) can be processed, but its main application is in sputum samples, and its wider applicability is in adults with suspected pulmonary tuberculosis [7]. Its use in extrapulmonary samples still has a variation between different studies, in terms of sensitivity and specificity according to the analyzed material, as well as considerations related to cost-effectiveness in these samples [13].

The following samples should not be processed: those composed exclusively of saliva; containing food particles; consisting solely of pus (no mucus and greenish); consisting exclusively of blood; with quantity less than 1 ml in the case of pulmonary and extrapulmonary samples, except cerebrospinal fluid (CSF); CSF samples amounting to less than 0.1 ml.

The sensitivity and specificity values for a single Xpert in adult sputum approach 88% (95% CI: 83–92) and 98% (95% CI: 97–99), respectively. Among those with positive sputum smear, the sensitivity is around 98% (95% CI: 97–99) and among those with negative sputum smears, it is around 68% (95% CI: 59–75) [14].

Xpert has still limited use in childhood, since its excellent performance is seen in bacteriologically confirmed TB, which is the minority of cases in children [7]. It has been shown that, by using culture as the gold standard, the sensitivity of Xpert on a single test in children under 15 years of age is from 42.9 to 90%, both in sputum and in induced sputum [13, 15, 16]. For the gastric lavage samples, sensitivity is 68.8% [15] and for nasopharyngeal aspirate it is 48% [17]. Specificity is similar to the adult (over 98%). A second test in children with negative sputum smears may increase the sensitivity of Xpert in 27.8% [13].

The prospect of broadening the diagnosis of TB in children with the use of Xpert was the subject of some studies carried out in South Africa and other African countries. There was higher positivity of Xpert in cases of PT in relation to culture for *M. tuberculosis* on specimens, such as gastric lavage, nasopharyngeal aspirate, and sputum induction. It became clear that Xpert contributes to increased diagnostic capacity of pulmonary TB in microbiologically confirmed TB [12, 17].

In Detjen and colleagues meta-analysis with studies using Xpert for the diagnosis of pulmonary TB in children and adolescents, the pooled sensitivities and specificities of Xpert for TB detection, when compared to culture: 62% (IC 95%: 51–73) and 98% (IC95%: 97–99) in sputum and induced sputum, respectively, and for samples from gastric lavage: 62% (95% CI: 51–73) and 98% (95% CI: 96–99), respectively. When compared with microscopy, the Xpert sensitivity was better [18].

In New Delhi, India, in a study investigating suspected cases of pediatric TB in public services, it was observed that Xpert was able to detect twice as many cases of pulmonary TB compared to smear and to increase the capacity to detect resistance to RIF, which is a quick and promising test for pediatric patients [19].

8. The role of clinical examination

The clinical examination does not always contribute significantly to the diagnosis of TB in children. It is recommended to evaluate the child's weight and development and to identify possible growth retardation attributable to the chronic nature of TB. In adolescents the clinical examination can be more informative: weight loss, poor general condition and presence of cough, and sometimes, blood spitting, call the doctor's attention to the possibility of the disease. Physical examination changes in the respiratory tract, such as bronchial or *cavernous breath*, have been reported for decades in patients with excavation (caverns) in the lungs, but they are currently little researched or recognized. Occasionally, wheezing in the chest can be

located by auscultation, due to extrinsic compression of the bronchi by mediastinal lymphadenopathy [10].

Extrapulmonary manifestations of TB may be evident on clinical examination, such as peripheral lymphadenopathy. Peripheral lymph node TB can present with cervical lymphadenopathy with progressive worsening, sometimes fistulated (scrofuloderma). Osteoarticular tuberculosis affecting the column (Pott disease) can present, insidiously, with back pain and night crying, deformity in the column, and difficulty in walking. Meningoencephalitis in the early stages evolves with discrete findings such as conjugate deviation of the eyes, irritability, vomiting, and behavioral changes, reaching to severe cases of neck stiffness. Pleural TB, most common in children and adolescents, may manifest as a pleural syndrome without apparent cause, with afebrile patient, or low fever and with no difficulty breathing even in cases of large spills. Cutaneous TB in general is difficult to diagnose by multiple lesions that it can determine. An experienced dermatologist in general needs to be contacted.

The manifestation of skin that most commonly can relate to TB is erythema nodosum. This transient injury, usually in the anterior tibial crest, may arise in TB primary infection. However, causes such as streptococcal infections, drug reactions, and leprosy, among others, should always be considered in these cases [4, 8].

Remember that extrapulmonary manifestations associated with pulmonary TB can be seen with some frequency. Thus, when one is investigating a suspected case of extrapulmonary TB, such as meningoencephalitis, bone, or other location, chest X-ray is recommended concurrently. Although the patient is asymptomatic for lung, pulmonary radiological damage may occur silently, which will ultimately assist in the diagnosis of TB.

Cases of pulmonary TB with severe course, resulting in ventilatory insufficiency, are uncommon but require the experience of an intensive care team to reach the diagnosis. Severe acute pneumonia of rapid course, similar to those caused by common germs, was described in infants and children with HIV. Clinical findings such as oral candidiasis, parotid hypertrophy, and digital clubbing can be seen in HIV-infected patients, in which TB-HIV coinfection can be considered. Lymphocytic interstitial pneumonia, currently uncommon, is a chronic process associated with the HIV virus that mimics the miliary TB. It is pneumonia with diffuse micronodular interstitial pattern, similar to *Pneumocystis jirovecii*, which can affect patients with HIV/AIDS and whose differential diagnosis of TB is a challenge [10].

The diagnosis of TB should also be sought in child living with an adult with TB, even if it is asymptomatic. This is the case of asymptomatic contacts. The contact control is one of the most valued preventive measures of TB in childhood, because it allows diagnosing TB cases at an early stage and taking preventive measures, such as the IPT, provided that the existence of active TB can be ruled out. Asymptomatic contact should preferably be submitted to chest radiography and TST or IGRA. If the X-ray is abnormal, compatible with TB, regardless of the result of the TST/IGRA, the child must be considered as a case of TB and justifies starting treatment of the disease. If the X-ray is normal and the TST/IGRA is reactive, IPT is indicated [4, 10].

9. Clinical classification of intrathoracic tuberculosis in children

The international consensus proposed in 2015 aimed at clinical standardization of intrathoracic TB cases in childhood called for, among others, the following clinical findings suggestive of TB: persistent cough for ≥ 2 weeks, growth arrest in the last 3 months (documented), and fatigue [20].

Standardizing sought to establish parameters for research in TB area, so that the terms used are easy to understand and even among researchers. It also facilitates the clinical approach and can be used in routine care.

Based on the clinical, radiological, and epidemiological findings, in immunological confirmation of *M. tuberculosis* infection and bacteriological confirmation, the following rating for intrathoracic TB in childhood was proposed [20]:

1. **TB confirmed**—Finding of *M. tuberculosis* (Culture or Xpert MTB/RIF) in at least one respiratory specimen.
2. **TB not confirmed**—No bacteriological confirmation and at least 2 of the following findings: signs and symptoms suggestive of TB; chest radiograph compatible with TB; close contact or evidence of immune infection by *M. tuberculosis*; Positive response to treatment.

Infected by *M. tuberculosis*—immunological evidence of infection by *M. tuberculosis* (positive TST or IGRA).

Not infected by *M. tuberculosis*—with no immunological evidence of infection.

3. **TB unlikely**—No bacteriological confirmation of TB; no criteria of unconfirmed TB, and no evidence of infection by *M. tuberculosis*.

10. Algorithms and scoring systems for diagnosis

For more than four decades, algorithms and scoring system have been published for diagnosis of TB in childhood. Some were validated and others were not. In Brazil, a scoring system is used for the diagnosis of pulmonary TB (intrathoracic) since 2002, which has been validated in HIV-infected and HIV-uninfected children [9, 21] and already tested in other countries [22, 23]. In HIV-infected patients, the system scored better sensitivity than specificity, becoming therefore more suitable as a screening test [24].

In HIV-uninfected children, the system provided sensitivity and specificity values greater than 86%. One of the advantages of this system is that it requires no bacteriological confirmation, which is admittedly useful in small children unable to expectorate (**Table 3**).

Characteristic	Points
Clinical manifestations	
Fever or cough, lost energy, sputum, weight loss, or night sweats for >2 weeks	+15
No symptoms or symptoms for <2 weeks	+0
Respiratory infection improving with or without antibiotic treatment for common bacteria	-10
Thoracic X-ray	
Hilar adenomegaly or miliary pattern	+15
Exudate or patch shadow (with or without cavitation) unaltered/worsening after > 2 weeks with antibiotic treatment for common bacteria	+15
Exudate or patch shadow (with or without cavitation) <2 weeks	+5
Normal	-5
Adult TB contact	
Regular contact	+10
None or occasional contact	0
BCG vaccination and TST	
BCG ≥ 2 years ago or no BCG, TST >5 mm	+15
BCG <2 years ago, TST >10 mm	+15
TST ≤ 5 mm, regardless of BCG	0
Nutritional status	
Severe malnutrition (grade III)	+5
Eutrophic or non-severe malnutrition	0

Table 3. Guide for Brazilian ministry of health diagnostic system.

11. Conclusion

The diagnosis of TB in children is based on clinical and radiological features adding other data as epidemiological and immunological (TST or IGRAs) information. In children (<10 years old) the bacteriological confirmation is difficult because in these individuals the TB is negative. There are few cases in which we can establish the disease confirmation due to the etiopathogenesis of primary TB. Primary TB means a disease of a small quantity of bacillus (*M. tuberculosis*). However, in adolescents (>10 years old) the TB assumes other characteristics: it is an adult type TB. In this form of TB the majority of the patients are bacilliferous (positive), so the bacteriological confirmation is possible. So, the molecular diagnosis using *Gene-Xpert MTB/RIF* test is adopted in several endemic countries with good results.

12. Projections and applications

As the diagnosis of pediatric TB is a challenge, we consider that the professional capacitating is necessary for enhancing the despistage of cases in childhood. Till today, the only diagnostic tool for childhood TB is the *Gene Xpert TB* test. However, this test is almost only useful in adolescents who have a bacteriological disease. The majority of cases in children depend on the health professional capacity of interpreting clinico-radiological and epidemiological aspects aiming to establish the correct diagnosis of TB.

Author details

Clemax Couto Sant'Anna^{1*}, Maria de Fátima B. Pombo March² and Rafaela Baroni Aurílio¹

*Address all correspondence to: clemax01@yahoo.com

1 Federal University of Rio de Janeiro (UFRJ), Rio de Janeiro, RJ, Brazil

2 Federal University of Rio de Janeiro (UFRJ) and Fluminense Federal University, Rio de Janeiro, RJ, Brazil

References

- [1] WHO. Global Tuberculosis Report [Internet]. 2016. Available from: http://www.who.int/tb/publications/global_report/en/ [Accessed: 28-01-2017]
- [2] WHO. Report of the Annual Meeting of the Childhood TB Subgroup, 26 October 2016, Liverpool, UK: World Health Organization; 2016. Licence: CC BY-NC-SA 3.0 IGO
- [3] Pai M, Behr MA, Dowdy D, Dheda K, Divagahi M, Boehme CC, et al. Tuberculosis. *Nature Reviews Disease Primers*. 2016;**2**:16076. DOI: 10.1038/nrdp.2016.76
- [4] WHO. Guidance for National Tuberculosis Programmes on the Management of Tuberculosis in Children. 2nd ed. World Health Organization, Geneva; 2014
- [5] Sant'Anna CC, Schmidt CM, March MFBP, Pereira SM, Barreto ML. Tuberculose em adolescentes em duas capitais brasileiras (Port) [Tuberculosis among adolescents in Brazilian capitals]. *Cadernos de Saúde Pública*. 2013;**29**(1):111-116. DOI: 10.1590/S0102-311X2013000100013
- [6] Brazil. Ministry of Health. Manual de recomendações para o controle da tuberculose no Brasil [Internet]. Available from: http://bvsmis.saude.gov.br/bvs/publicacoes/manual_recomendacoes_controle_tuberculose_brasil.pdf [Accessed: 25-01-2017]
- [7] WHO. Automated Real-time Nucleic Acid Amplification Technology for Rapid and Simultaneous Detection of Tuberculosis and Rifampicin Resistance: Xpert MTB/RIF

- System for the Diagnosis of Pulmonary and Extrapulmonary TB in Adults and Children. Policy Update [Internet]. Geneva: World Health Organization; 2011. Available from: http://whqlibdoc.who.int/publications/2011/9789241501545_eng.pdf [Accessed: 25-01-2017]
- [8] Heemskerk D, Caws M, Marais B, Farrar J. Tuberculosis in Adults and Children. New York: Springer; 2015. p. 66. DOI: 10.1007/978-3-319-19132-4
- [9] Pedrozo C, Sant'Anna C, de Fatima March M, Lucena S. Clinical scoring system for paediatric tuberculosis in HIV-infected and non-infected children in Rio de Janeiro. *International Journal of Tuberculosis and Lung Disease*. 2009;**13**:413-415
- [10] Grahon S, et al. The Union's Desk Guide for Diagnosis and Management of Tuberculosis in Children. 3rd ed. Paris: IUATLD; 2016
- [11] Starke JR, Committee on Infectious Diseases. Interferon-gamma release assays for diagnosis of tuberculosis infection and disease in children. *Pediatrics*. 2014;**134**(6):e1763-e1773. DOI: 10.1542/peds.2014-2983
- [12] Nicol MP, Whitelaw A, Stevens W. Using Xpert MTB/RIF. *Current Respiratory Medicine Reviews*. 2013;**9**:187-192. DOI: 10.1164/rccm.201101-0056OC
- [13] Nicol MP, Woekman L, Isaacs W, Munro J, Black F, Eley B, et al. Accuracy of the Xpert MTB/RIF test for the diagnosis of pulmonary tuberculosis in children admitted to hospital in Cape Town, South of Africa: A descriptive study. *Lancet Infectious Diseases*. 2011;**11**:819-824. DOI: 10.1016/S2214-109X(13)70036-6
- [14] Steingart KR, Schiller I, Horne DJ, Pai M, Boehme CC, Dendukuri N. Xpert® MTB/RIF assay for pulmonary tuberculosis and rifampicin resistance in adults. *Cochrane Database of Systematic Reviews* 2014;(1). Art. No.: CD009593. DOI: 10.1002/14651858.CD009593.pub3
- [15] Bates M, Grady JO, Mauerer M, Tembo J, Chilukutu L, Chabala C, et al. Assessment of the Xpert MTB/RIF assay for diagnosis of tuberculosis with gastric lavage aspirates in children in sub-Saharan Africa: A prospective descriptive study. *Lancet*. 2013;**13**:36-42. DOI: 10.1016/S1473-3099(12)70245-1
- [16] Togun TO, Egere U, Sillah AK, Ayorinde A, Mendy F, Tientvheu L, et al. Contribution of Xpert MTB/RIF to the diagnosis of pulmonary tuberculosis among TB-exposed children in the Gambia. *International Journal of Tuberculosis and Lung Disease*. 2015;**19**(9):1091-1097. DOI: 10.5588/ijtld.15.0228
- [17] Zar HJ, Workman L, Isaacs W, Munro J, Black F, Eley B, et al. Rapid molecular diagnosis of pulmonary tuberculosis in children using nasopharyngeal specimens. *Clinical Infectious Diseases*. 2012;**5**(8):1088-1095. DOI: 10.1093/cid/cis598
- [18] Detjen AK, DiNardo AR, Leyden J, Steingart KR, Menzies D, Schiller I, et al. Xpert MTB/RIF assay for the diagnosis of pulmonary tuberculosis in children: A systematic review and meta-analysis. *Lancet Respiratory Medicine*. 2015;**3**:451-461. DOI: 10.1016/S2213-2600(15)00095-8

- [19] Raizada N, Sachdev KS, Nair SA, Kulsange S, Gupta RS, Thakur R, Parmar M, et al. Enhancing TB case detection: Experience in offering upfront Xpert MTB/RIF testing to pediatric presumptive TB and DR TB cases or early rapid diagnosis of drug sensitive and drug resistant TB. *PloS One*. 2014;**9**(8):e105346. DOI: 10.1371/journal.pone.0105346
- [20] Graham SM, Cuevas LE, Jean-Philippe P, Browning R, Casenghi M, Detjen AK, et al. Clinical case definitions for classification of intrathoracic tuberculosis in children: An update. *Clinical Infectious Diseases*. 2015;**61**(Suppl. 3):S179–S187. DOI: 10.1093/cid/civ581
- [21] Sant'Anna C, Orfaliais C, de March MFP, Conde M. Evaluation of a proposed diagnostic scoring system for pulmonary tuberculosis in Brazilian children. *International Journal of Tuberculosis and Lung Disease*. 2006;**10**:463-465
- [22] Edwards D, Kitetele F, Van Rie A. Agreement between clinical scoring systems used for the diagnosis of pediatric tuberculosis in the HIV era. *International Journal of Tuberculosis and Lung Disease*. 2007;**11**:263-269
- [23] Pearce EC, Woodward JF, Nyandiko WM, Vreeman RC, Ayaya SO. A systematic review of clinical diagnostic systems used in the diagnosis of tuberculosis in children. *AIDS Research and Treatment*. 2012;**2012**:401896. DOI: 10.1155/2012/401896
- [24] David SG, Lovero KL, March MFBP, Abreu TF, Ruffino-Netto, Kritski A et al. A comparison of tuberculosis diagnostic systems in a retrospective cohort of HIV-infected children in Rio de Janeiro, Brazil. *International Journal of Infectious Diseases*. 2017, <http://dx.doi.org/10.1016/j.ijid.2017.01.038>

