

We are IntechOpen, the world's leading publisher of Open Access books Built by scientists, for scientists

4,800

Open access books available

122,000

International authors and editors

135M

Downloads

Our authors are among the

154

Countries delivered to

TOP 1%

most cited scientists

12.2%

Contributors from top 500 universities



WEB OF SCIENCE™

Selection of our books indexed in the Book Citation Index
in Web of Science™ Core Collection (BKCI)

Interested in publishing with us?
Contact book.department@intechopen.com

Numbers displayed above are based on latest data collected.
For more information visit www.intechopen.com



Noninvasive Diagnostic and Prognostic Assessment Tools for Liver Fibrosis and Cirrhosis in Patients with Chronic Liver Disease

Ju-Seop Kang and Min-Ho Lee

Additional information is available at the end of the chapter

<http://dx.doi.org/10.5772/intechopen.68317>

Abstract

Liver fibrosis, that is, excessive accumulation of extracellular matrix protein, occurs and is the wound-healing response and common final pathway of various chronic liver diseases. Advanced hepatic fibrosis caused by chronic liver inflammation eventually progresses to cirrhosis, and prognosis and management of chronic liver diseases depend on the fibrotic severities. Therefore, the early and precise evaluation of severity and status of liver fibrosis provides useful information for diagnosis as well as treatment planning and treatment efficacy and prognosis. Although invasive liver biopsy is the gold standard to assess the nature and severity of hepatic fibrosis, it has several recognized limitations including sampling error and inter-observer variability in interpretation and staging. Furthermore, the dynamic process of fibrosis resulting from progression and regression is difficult to capture with biopsy alone. Therefore, alternative, simple, reliable, and noninvasive direct and indirect serum markers able to predict the presence of significant fibrosis or cirrhosis in patients with chronic liver disease with considerable accuracy were needed. The hepatology experts are actively researching noninvasive methods of fibrosis quantification. The aims of this chapter were to review the nature and limitations of the several noninvasive methods for the assessment of presence and severity of liver fibrosis in patients with chronic liver disease.

Keywords: noninvasive method, biomarker, stage of liver fibrosis, cirrhosis, chronic liver disease

1. Introduction

Liver fibrosis and cirrhosis are an important and growing global health problem. Patients with non-cirrhotic chronic liver disease may have an increased mortality rate compared to controls [1]. However, mortality and morbidity rates increase exponentially once cirrhosis

develops. Prognosis and management of chronic liver diseases greatly depend on the amount and progression of liver fibrosis. Therefore, the ability to reliably rule out cirrhosis may be considered an important characteristic of any test designed to assess liver fibrosis [2]. The diagnosis of cirrhosis also portends an increased risk of liver-related morbidity [3] as well as mortality [4]. Liver-related mortality and decompensation are expected to continue to increase over the next decade, due to the projected increase in the number of patients with advanced liver fibrosis in the population [5]. Therefore, the accurate and timely evaluation of liver fibrosis is a key step to manage a chronic liver disease and to assess its prognosis and in need of close monitoring, management of complications, and underlying liver disease in patients with advanced stages [6]. For many years, liver biopsy has been considered the “gold standard” for evaluation of liver fibrosis [7]. Pathologists have proposed robust scoring system for staging liver fibrosis such as the semi-quantitative Metavir score (*F0*: no fibrosis, *F1*: portal fibrosis, *F2*: bridging fibrosis, *F3*: bridging fibrosis, and marked, *F4*: cirrhosis) [8] and the modified Ishak score, an expansion of Metavir score [9]. In addition, computer-aided morphometric measurement of collagen-proportional area, a partly automated technique, provides an accurate and linear evaluation of the amount of fibrosis [10]. However, liver biopsy is an invasive procedure with rare but potentially life-threatening complications and prone to sampling errors. Also, liver biopsy gives a snapshot and not an insight into the dynamic changes during the process of fibrogenesis (progression, atatic, or regression). Therefore, liver biopsy has some limitations as follows. First, biopsy is an invasive technique, which has associated morbidity; pain occurs in 20% of patients and major complications such as bleeding or hemobilia in 0.5% [11]. The bleeding rate (0.5%) has not changed significantly in recent years, according to a large multicenter study [12]. The primary factor that appeared to contribute to bleeding risk was platelet count rather than qualitative factors such as operator experience, needle size, or the use of ultrasound to localize the site. Second, the small size of the biopsy makes it prone to sampling variability [13]. Third, the interpretation of the histologic changes can be problematic with inter- and intra-observer variation [14]. These limitations as well as the availability of powerful viral diagnostic tools and new antiviral drugs have rapidly decreased the use of liver biopsy in viral hepatitis and led to the development of noninvasive techniques for the assessment of liver fibrosis. On the other hand, at least some correlation between biopsy stage and outcomes has begun to emerge. In the NIH-HALT C cohort, a correlation was found between the Ishak fibrosis stage and clinical outcomes, the need of liver transplantation, and liver-related deaths in patients with chronic HCV. However, even in this study, up to 25% of the liver biopsy samples were fragmented, which significantly diminished the ability to draw correlations between biopsy findings and clinical outcomes [15]. While some of these methodologies are now generally applied in patients for a top priority of evaluation, biopsy exists within the clinical technique of hepatologists for estimating the causes of complicated diseases or when there are unconformities between clinical characteristics and extents of fibrosis evaluated by noninvasive methodologies [16]. The dynamic process of fibrosis should be best measured as a continuous variable and classical histological staging systems do not permit this [17]. Since liver biopsy is an invasive procedure, cost-intensive, mostly uncomfortable for the patients, and sometimes prone to complication, alternative, simple noninvasive tests have been developed to reliably assess the stage of liver fibrosis. Ongoing efforts include serum markers and imaging based on ultrasound, computed

tomography (CT), and magnetic resonance imaging (MRI). The goal is to develop tests with high specificity and sensitivity to estimate liver fibrosis and predict outcomes [18]. Ideally, noninvasive methodologies of liver fibrosis should be liver specific, easy to perform, reliable, and inexpensive. In addition, it should be accurate not only for the staging of fibrosis but also for the monitoring of disease progression and antiviral therapy efficacy [19]. Scientific attention is currently focused on new antifibrotic therapies, aiming at fibrosis reversibility and cirrhosis regression [20]. It is therefore important, now more than ever, to ensure accurate and prompt assessment of hepatic fibrosis in therapeutic trials of chronic liver disease. Consequently, the demand for noninvasive method substitutes to estimate hepatic fibrosis is a main trial that has provoked research and induced the improvement of noninvasive serological markers of hepatic fibrosis. Several noninvasive serological markers have been described to forecast the existence of significant fibrosis or cirrhosis in patients with chronic hepatic disease with good accuracy. However, most of these markers require complicated calculations, and manipulation in various clinical situations is difficult and inconvenient [21]. Recently, transient elastography (TE, FibroScan) has been introduced as a novel, rapid, noninvasive, and reproducible method to measure liver stiffness [22]. In several studies [22, 23], liver stiffness measurement (LSM) using M probe of FibroScan accurately predicted hepatic fibrosis and cirrhosis in patients with chronic liver disease.

This chapter focuses and provides comparison of invasive and noninvasive methods for assessing the severity of liver fibrosis and aims to provide update on noninvasive diagnostic and prognostic assessment tools for liver fibrosis and cirrhosis in patients with chronic liver disease.

2. Mechanism of liver fibrosis

Liver fibrosis is the result of the continuous wound-healing process of the liver to repeated damage [24]. After acute liver injury (e.g., viral hepatitis), parenchymal cells regenerate and replace the necrotic or apoptotic cells. The process is associated with a hepatic inflammatory response and a limited deposition of extracellular matrix (ECM) in the hepatic parenchyma. If the liver injury persists, then eventually the liver regeneration fails, and hepatocytes are substituted with abundant ECM, including fibrillar collagen [25]. This process results in cirrhosis, which can have a bad outcome and high mortality. Progression to this end stage is typically variable but slow, developing over 20–40 years in patients with chronic liver damage; the speed is dependent on both genetic and environmental factors [26]. Liver fibrosis is a common pathological consequence of a variety of chronic stimuli, including viral, alcohol, and autoimmune, drug-induced, cholestatic and metabolic diseases [18, 26–28]. Deposition of excess ECM is rich in fibril-forming collagens [29], which change the normal structure of the liver resulting in pathophysiologic damage to the organ [30]. Liver fibrosis is beneficial at first because it can encapsulate the injury and is considered a reversible process at this stage [31]. In normal liver, ECM is highly dynamic substratum with a precisely regulated balance between synthesis and degradation. Normally, the hepatic ECM comprises less than 3% of the relative area on a liver tissue section and approximately 0.5% of the total wet weight of liver [32]. It is

also a component of Glisson's capsule, portal tracts, central veins, and the subendothelial space of Disse. The most important structural ECM components in liver are collagen, proteoglycans, laminin, fibronectin, and matricellular proteins. The hepatic parenchyma is composed of hepatocytes, endothelial cells, and other resident cells, including hepatic stellate cell (HSCs) and Kupffer cells (KCs). The sinusoid is the hepatic microvascular unit that has an endothelial lining distinguished by fenestration of pores and is separated from the hepatocytes by the space of Disse, where HSCs reside. This space contains a low-density basal membrane-like matrix that is essential for maintaining the differentiated function of parenchymal cell yet is sufficiently porous to enable metabolic exchange between the bloodstream and hepatocytes [26]. During chronic liver injury, however, ECM production exceeds ECM degradation, and liver fibrosis develops as results of the progressive thickening of fibrotic septae and chemical cross-linking of collagen. Moreover, these changes in ECM composition directly stimulate fibrogenesis (**Figure 1**) [33]. After liver injury, disruption of this matrix and replacement by fibrillar collagens I and III and fibronectin have occurred [34, 35]. Fibrosis is characterized histologically and biochemically by a several-fold elevation in the total ECM content of the liver [25].

Accumulation of ECM in the space of Disse leads to loss of the normal fenestrating structures that are characteristic of the endothelial lining, which causes the impairment of the normal bidirectional metabolic exchange between portal blood and hepatocytes. This process is sinusoidal remodeling, termed capillarization of the sinusoid [38]. All major constituents of normal ECM are represented, to some extent, in the newly formed matrix during the fibrogenic process. As in normal ECM, collagen (especially types I and III) and elastin are most abundant proteins, but glycoproteins (fibronectin and laminin) and pure carbohydrates are also present. When compared to normal matrix, scar tissue produced in liver fibrosis has a significantly higher percentage of type I collagen [39]. ECM deposition occurs as a result of an imbalance between excessive ECM production and less degradation. In the normal liver, matrix metalloproteinases (MMPs) have a well-described ECM-degrading function. The activity of MMPs, however, is suppressed in the setting of liver injury as a result of overexpression of tissue inhibitor of metalloproteinase (TIMPs) by the activated HSCs [25]. TIMPs are key regulators of MMPs, by blocking their collagenolytic activity. In addition, TIMP-1 is anti-apoptotic toward HSCs, in part through the induction of Bcl-2, thus promoting the survival of fibrogenic cells [40]. This balance between MMPs and TIMPs is crucial for ECM homeostasis [41]. In human liver, the degree of TIMP-1 expression correlates with the extent of liver fibrosis [42]. In order to preserve matrix homeostasis, ECM also contains MMPs, MMP-1, MMP-8, and MMP-13 that degrade the fibrillary collagen types I and III predominating in fibrosis, while MMP-2 and MMP-9 degrade collagen types IV as well as denatured fibrillary collagens. HSCs are the key source of both MMPs in liver. Although the increase of MMP production should control the excessive increase of the ECM, it can also promote injury. Early increases in MMP, particularly MMP-2, degrade normal matrix and recruit cells that amplify fibrosis [43, 44]. In addition, there is also enhanced secretion of TIMP-1 and -2 by HSCs during progressive tissue injury and cellular activation. Different populations of cells play roles in fibrogenesis, but the activation of HSCs is an essential factor in fibrinogenesis [45]. The mechanism of liver fibrosis is thought to be associated with the hepatic damage of various etiologic

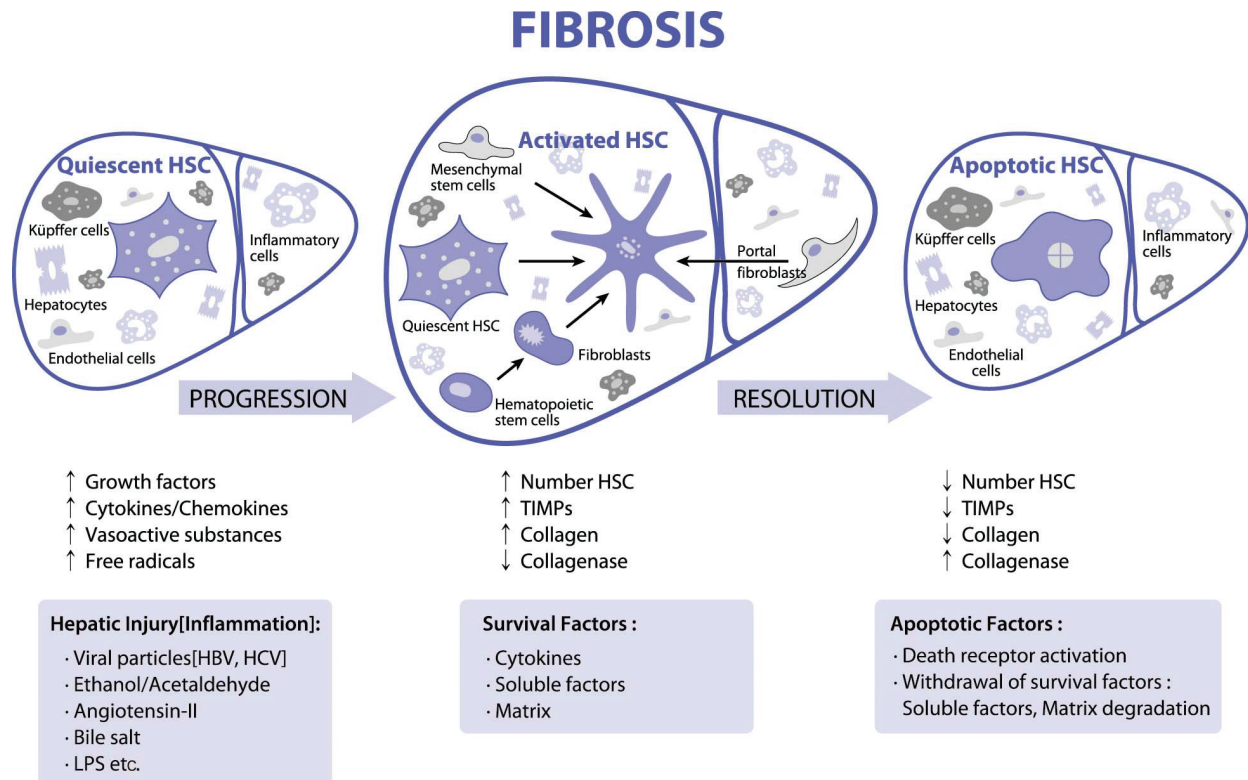


Figure 1. Schematic illustration of fibrosis progression and regression (modified from Refs. [18, 36, 37]).

factors followed by the activation of HSCs within the liver that develop into liver myofibroblasts (LMFs) [46]. LMFs include a heterogeneous population of highly proliferative cells that accumulate at injury sites and promote ECM accumulation [47]. The pool of LMF originates mainly from liver mesenchymal cells, namely HSCs [48]. Although HSCs are the primary source of LMFs in liver fibrosis, extrahepatic precursors such as bone marrow-derived mesenchymal cells and portal fibroblasts contribute in ECM production [49, 50]. HSCs are resident peri-sinusoidal cells in the subendothelial space of Disse between hepatocytes and sinusoidal endothelial cells. The main cells affected by liver fibrosis are the HSCs and fibroblasts, which are activated by soluble mediators produced by activated KCs or inflammatory cells in the course of chronic liver disease [51]. ECM may thereby regulate cellular activity and availability of growth factors. For instance, decorin and biglycan, two ECM components, bind transforming growth factor- β (TGF- β), fibronectin and laminin bind tumor necrosis factor- α (TNF- α), and collagen binds platelet-derived growth factor (PDGF), hepatocyte growth factor (HGF), and interleukin-2 (IL-2). The binding of survival factors to the ECM may prevent apoptosis of hepatocyte in the pathologic condition and also prevent growth factor degradation [33]. In liver tissues, HSCs store retinoids such as vitamin A and produce glial fibrillary acidic protein (GFAP), the so-called fat-storing cells or vitamin A-rich cells [52]. Following liver injury, HSCs become activated, which leads to the conversion of a quiescent to activated HSCs that has lost vitamin A droplets, leading to increased proliferation and contraction and the release of proinflammatory, profibrogenic, and promitogenic cytokines. These activated HSCs are capable of enhanced migration and deposition of ECM components [46, 53]. The activation of HSCs can be divided into two stages: initiation and perpetuation [46]. In the first or initiation

phase, HSCs undergo the initial changes toward a myofibroblast-like cell differentiation and become more responsive to proliferative and fibrogenic cytokines by up-regulation of membrane receptors [54]. This stage also called a “pre-inflammatory” stage refers to early changes in gene expression that result primarily from paracrine stimuli derived from damaged resident liver cells (sinusoidal endothelial cells, KCs, and hepatocytes) and platelets. KCs engagement drives release cytokines (especially TGF- β) and ROS signaling [55]. Endothelial cells participate in the conversion of latent TGF- β into active form and produce fibronectin, which also provokes early HSC activation. In addition, PDGF, TGF- β , and endothelial growth factor (EGF) which is potent activators of HSCs [56]. Persistence of these stimuli accompanying sustained injury leads to a perpetuation stage regulated by autocrine and paracrine stimuli. Perpetuation stage involves at least seven distinct changes in HSC behavior, including proliferation, chemotaxis, fibrogenesis, contractility, altered matrix degradation, retinoid loss, and inflammatory signaling [57]. Therefore, a critical event in liver fibrogenesis is that the ECM is a dynamic structure, and even advanced fibrosis may be reversible [58, 59]. Multiple interactions between the ECM, HSCs, endothelial cells, and immune cells have been identified. The central event in liver fibrogenesis appears to be the activation of HSCs, which is a complex process [59]. Different patterns of fibrosis progression have been described on the basis of their etiology, region of injury (e.g., portal or central), the source of fibrogenic cells involved, and the predominant fibrogenic mechanisms [60]. For example, chronic viral hepatitis B and C are major causes of bridging fibrosis, resulting in the formation of portal-central fibrotic septa. Perisinusoidal or pericellular fibrosis is typically found in alcohol-related disorders and nonalcoholic fatty liver disease (NAFLD). Progression of hepatic pathology with sustained fibrogenesis leads to cirrhosis, which is not merely the end-stage accumulation of scar, but rather is characterized by a destruction of the hepatic parenchyma and vascular architecture. The main pathological characteristic of cirrhosis is the formation of nodules of regenerative parenchyma enclosed by fibrotic septa, which may contain terminal hepatic venules and portal tracts when the nodules are especially large (i.e., macronodular cirrhosis). Portosystemic shunts and venous occlusion often occur, leading to impairment in liver function and the development of portal hypertension. The formation of vascularized fibrous septa that link portal tracts and central veins is stimulated by angiogenesis and contributes to portosystemic shunting that bypasses the liver parenchyma [61].

3. Liver biopsy: pros and cons, and limitations

Liver biopsy is usually known as the most specific test to evaluate the feature and severity of liver pathology and can be useful in monitoring the efficacy of various treatments. There are currently several techniques available for obtaining liver tissue and each of these has pros and cons [7]. The size of the biopsy specimen, which varies between 10 and 30 mm in length and between 1.2 and 2 mm in diameter, represents only 1:50,000 of the total mass of liver [62]. Therefore, in disease affecting the liver in a diverse way, the histologic findings of biopsy specimen may not be representative of the pathologic process. However, most cases of chronic liver disease causing fibrosis, such as viral and autoimmune hepatitis, as well as nonalcoholic steatohepatitis (NASH), affect the liver in a relatively uniform pattern [63]. Then the extent, to

which the biopsy will be representative, will depend greatly on the size of the specimen obtained. The number of portal triads present in the specimen is important; most hepatopathologists are satisfied with a biopsy specimen containing at least 6–8 portal triads. The indications of liver biopsy are outlined in **Table 1** [7].

-
- ◆ Diagnosis, grading, and staging of chronic hepatitis C or chronic hepatitis B.
 - ◆ Diagnosis, grading, and staging of alcoholic liver disease, nonalcoholic steatohepatitis (NASH), or autoimmune hepatitis
 - ◆ Diagnosis of heavy metal storage disorders (e.g., hemochromatosis, Wilson’s disease)
 - ◆ Evaluation of the cholestatic liver disease, primary biliary cirrhosis, and primary sclerosing cholangitis
 - ◆ Evaluation of abnormal results of biochemical tests of the liver in association with serological workup that is negative or inconclusive
 - ◆ Use of hepatotoxic regimens (e.g., methotrexate therapy for psoriasis): monitoring
 - ◆ Diagnosis of liver mass (e.g., cancer or unexplained lesions)
 - ◆ Liver donor status before transplantation
 - ◆ Evaluation of systemic illness (e.g., fever of unknown origin, inflammatory or granulomatous disorders)
 - ◆ Hepatosplenomegaly of unknown cause: diagnosis
-

Table 1. Indication for liver biopsy (modified from Ref. [7]).

Even for patients where serological tests point to a specific liver disease, a liver biopsy can provide valuable information regarding staging, prognosis, and management. There are bad interrelationships between clinical characteristics or status of serum liver enzymes and hepatic histopathologic findings, but also patients with healthy status of liver enzymes may be diagnosed to have clinically advanced fibrosis or cirrhosis on histopathologic findings [64]. If the patient has minor-state illness and is infected with genotype 1a or 1b of the hepatitis C virus, a medical judgment may be made to delay treatment. If the patients have the above degree of moderate disease, treatment will be commonly suggested. If the patients have a virological reaction and acceptable adverse reactions with treatment, continued therapy would be firmly encouraged. The cirrhotic findings on hepatic histopathology will indicate the need for extra tests, such as upper endoscopic procedure to rule out esophageal varices and monitoring for hepatoma with continuing assessment of serum α -fetoprotein and hepatic sonography [7]. In alcoholic liver disease (ALD), the grade of the clinical symptoms and the severity of serum liver enzymes elevation correlate poorly with the degree of liver pathology, particularly in patients who continue to consume alcohol. The long-term prognosis depends upon the extent of liver damage [65]. In patients with ALD as well as NASH, liver biopsy may demonstrate hepatic fatty infiltration, ballooning degeneration of hepatocyte, Mallory’s bodies, and hepatonecrosis, regardless of clinically severe fibrosis or cirrhosis [7]. In primary biliary cirrhosis (PBC), sequential liver biopsies may assist one to investigate the natural history, track the responses of therapy, or identify a recurrence of the disease after liver transplantation [66, 67]. Liver biopsy allows a precise evaluation in approximately 90% of patients with obscure disorders revealed on liver function tests [68]. The explanation of diverse courses that appear in a transplanted liver including immune reaction, systemic or infectious complications, drug

toxic reaction, and the recurrence of primary disease necessitates a liver histological examination [69]. Liver biopsy can also provide the diagnosis of systemic diseases that can influence the liver, such as sarcoidosis, lymphoma, acquired immune deficiency syndrome (AIDS), and amyloidosis. The histopathological examination of the biopsy material is a subjective process; therefore, diagnostic reproducibility at the 100% level is practically impossible. Intra-observer and inter-observer agreement studies suggest that biopsy specimen size and observer experience (specialization, duration of practice, and academic practice) are important factors in reducing the variation of assessment [8, 70]. Most studies of specimen adequacy have focused on chronic hepatitis because it represents the most common indication for liver biopsy [71]. At present, the most common suggestions for the precise assessment of the degree of fibrosis in chronic hepatic diseases are that the size of biopsy tissue materials must be at a minimum of 20 mm in size and 1.4 mm in radius and must be retained at a minimum of 11 intact portal tracts [72]. In addition, the type of biopsy needle is important, as suction needles tend to miss the fibrous tissue of the septa, as opposed to cutting needles, thus providing the wrong impression regarding the degree of fibrosis and the presence or absence of cirrhosis [73]. Finally, it should be kept in mind that biopsy specimens obtained from subcapsular locations generally contain more fibrous tissue than deeper specimens taken perpendicular to the hepatic surface. For many years, liver biopsy has been considered the gold standard for the staging liver fibrosis [7]. For instance, in patients with chronic HCV, precise definition of the liver fibrosis stage is the important parameter to assess the risk of disease progression and to decide the need for immediate antiviral therapy [74]. Several standardized semi-quantitative scoring systems have been proposed for the staging histological activity index (HAI) proposed in 1981 by Knodell [75] and, more recently, the Ishak score [9] and the Metavir system [76] (**Table 2**). All of these scoring systems have some limitations, being not linear and prone to intra- and inter-observer variation and to sampling variability [77].

The Knodell score is a composite score that is based on histological assessment of periportal and/or bridging necrosis, intralobular degeneration and focal necrosis, portal inflammation, and fibrosis. The score ranges from 0 to 22, with higher scores representing more advanced disease [75]. Knodell score is frequently used in trials of treatments for chronic hepatitis, particularly HCV. The score is used to assure that baseline histologic features in treatment groups are equally matched and to assess histologic changes after therapy. A limitation of the Knodell score is that it combines inflammation and fibrosis to arrive at one composite score, so it is relatively insensitive to changes in fibrosis. This is important because it is fibrosis, and not inflammation per se, that leads to many of the sequelae of chronic liver disease. In addition, patients may have the same Knodell score despite having markedly different degree of fibrosis. Also, the Knodell score is associated with high inter- and intra-observer variability. The Metavir system is a semi-quantitative classification that consists of four intensity degrees of an activity score (A0–A3) and a five-point scale of fibrosis (F0–F4) [8, 76]. In contrast to the Knodell score, the Metavir system was specifically designed and validated for patients with HCV [76]. The inter- and intra-observer reliabilities of the activity and fibrosis scores of the Metavir system are similar to the Knodell score. The Ishak score is a modification of the Knodell score that includes six stages of fibrosis [9]. This permits documentation of small changes in fibrosis compared with the standard Knodell score, which has only four stages.

Fibrosis stage	Knodell	Ishak	Metavir	Scheuer	Batt-Ludwig	Laennec
No fibrosis	0	0	0	0	0	0
Fibrosis of some portal areas without septa	1	1	1	1	1	1
Fibrosis of most portal areas without septa	1	2	1	1	1	2
Portal fibrosis with few septa	3	3	2	2	2	3
Septal fibrosis without cirrhosis	3	4	3	2	2	3
Incomplete cirrhosis	4	5	4	3	4	4A
Cirrhosis	4	6	4	4	4	4B-4C

Table 2. Comparison between three scoring systems for liver fibrosis in chronic viral hepatitis (modified from Refs. [19, 78–80]).

This staging system has become widely used in clinical trials because of its ability to detect mild changes in fibrosis [81]. The Scheuer system is a simple scoring system that separates necrotic inflammation from fibrosis [78]. Histologic findings of portal inflammation, interface hepatitis, and lobular inflammation are each assigned a score of 0–4. A separate score (0–4) is assigned to the stage of fibrosis. Batts-Ludwig system is also known as the modified Scheuer system [79]. This system is applicable to both chronic viral hepatitis and autoimmune hepatitis and is more useful for assessing an individual patient’s liver biopsy for clinical care than therapeutic trials. In addition, disease-specific scoring systems are also available, including scoring systems for nonalcoholic fatty liver disease (NAFLD), ALD, primary biliary cirrhosis (PBC), and primary sclerosing cholangitis (PSC). However, it is not common to encounter two or more concurrent diseases in a liver biopsy specimen, no scoring systems are available that specifically address these situations [81]. Absolute contraindication to liver biopsy includes patient’s inability to remain still and to maintain brief expiration for the procedure, suspected vascular lesion (e.g., hemangioma), bleeding tendency (e.g., INR >1.2 despite receiving vitamin K, bleeding time >10 min), and severe thrombocytopenia (<50,000/mL). Relative contraindications include profound anemia, peritonitis, marked ascites, high-grade biliary obstruction, and a subphrenic or right pleural infection or effusion. Nonetheless, percutaneous liver biopsy is sufficiently safe to be performed on an outpatient setting [82]. Despite liver biopsy being the standard test for an appropriate assessment of patients with chronic liver diseases, there are several limitations of this including variable quality of liver biopsy specimens of <20 mm in length which may be difficult to interpret. Therefore, larger caliber needles may yield better than fine-needle biopsies [71]. Because of fluctuating disease activity, histologic changes obtained at a single point in time may not reflect overall disease activity, which may vary. On the other hand, one would often want to be aware of the progression of liver disease in order to assess therapy response. Limitations entailed by repeat liver biopsy as regards potential patient’s risks demand the development of new methods for liver fibrosis evaluation. The features and limitations of liver biopsy are summarized in **Table 3**. On all these grounds, noninvasive diagnostic tests (serum markers and imaging modalities) have been developed of late mainly to assess liver fibrosis severity. The following pages attempt to describe available information on the better-known serum markers as well as imaging techniques.

	Liver biopsy	Noninvasive methods
Pros	<ul style="list-style-type: none"> • Gold standard to assess fibrosis • Direct observation and quantitative assessment of fibrosis, inflammation, and steatosis • Different stage by different scoring systems • Diagnosing different forms of liver disease • Accurately assessing progression of liver disease or the effect of therapy 	<ul style="list-style-type: none"> • Noninvasive • No complications and no contraindications • Inter-laboratory reproducibility • High applicability and wide availability for repeated assays • Reasonable cost • Accurate assessment of cirrhosis and minimal/no fibrosis
Cons	<ul style="list-style-type: none"> • Invasive • Sampling variability/evaluation of a tiny part of the whole organ (1:50,000) • Intra- and inter-observer variability • Unsuitable for repeated assays • Risk of complications, rare major complications, morbidity and mortality • High cost 	<ul style="list-style-type: none"> • Less accurate for intermediate fibrosis stages • False-positive values • Scores may change in different disease stages • Unsuitable for diagnosing liver disease • Not quantitative • "Grey zone" (intermediate results in 14–33% of cases)

Table 3. Pros and cons of liver biopsy and noninvasive methods for the evaluation of liver fibrosis in chronic liver disease (modified from Refs. [83, 84]).

4. Noninvasive assessment of liver fibrosis in patients with chronic liver disease

Liver biopsy remains the "gold standard" of assessing hepatic fibrosis. However, it has limitations, such as high cost, invasiveness, associated risk for complications, and sampling or observer variability. Therefore, liver biopsy has recently been challenged by the development of novel noninvasive modalities, including serum direct and/or indirect markers of hepatic fibrosis, noninvasive modalities of predicting fibrosis and imaging techniques, including TE (FibroScan), ultrasonography (US), computed tomography (CT), magnetic resonance imaging (MRI), and thallium 201 per rectal scintigraphy (TI-201 test). As well as TE [85, 86], TI-201 test is a relatively new technique for assessment of liver fibrosis or cirrhosis [87–91]. However, the cost of the equipment may limit the use of TE in some institutions with limited resources. In the past decade, several noninvasive methods for assessing hepatic fibrosis have been published, resulting in more noninvasive tests than histologic scoring systems. The noninvasive tests were introduced to estimate the likelihood of advanced liver fibrosis in patients with chronic viral liver disease at presentation, and on follow-up to assess fibrosis regression in post-treatment period [92]. These tests were later applied in ALD [93, 94] and NAFLD [95, 96]. Our previous studies on the clinical value of the TI-201 test in chronic liver disease may be useful in differentiating chronic hepatitis from cirrhosis and prediction of its prognosis for the management of disease [90, 91, 97, 98]. The first important clinical topic in the assessment of new diagnostic methodologies for evaluation of liver fibrosis is its validation against the present clinical gold standard, liver biopsy, to calculate sensitivity, specificity, and negative- (NPV) and positive-predictive values (PPV). The standard statement of the efficiency of modalities is to examine the area under the receiver operator characteristic curve (AUROC), which plots the sensitivity over 1-specificity using liver biopsy as the reference [17]. The AUROC

-
- ◆ Liver specific
 - ◆ Levels not influenced by alterations in liver, renal, or reticuloendothelial function
 - ◆ Measurement of one or more of the following processes: Stage of fibrosis, imbalance of activity of ECM (fibrogenesis vs. degradation)
 - ◆ Easy to perform
-

Table 4. Features of an ideal marker of liver fibrosis (modified from Ref. [108]).

indicates the probability that a test will correctly rank two randomized patient groups, one with a liver biopsy considered “normal group” and the other “diseased group” [99, 100]. Because liver biopsy itself is not a perfect gold standard, a perfect test will never reach maximal value (1.0) [17]. According to a range of accuracies of the biopsy and a range of prevalence of significant disease (that influence the AUROC), an AUROC of >0.90 in the most favorable scenario cannot be achieved when assessing the so-called “significant fibrosis” even for a perfect marker [99, 101]. This is important for several reasons. First, studies have already shown that these maximal AUROC values have been reached for surrogate markers, especially when assessing cirrhosis versus non-cirrhosis, suggesting that these surrogate markers may be at least as good as liver biopsy in the diagnosis of cirrhosis [102]. Second, some reports suggest that a definitive method for assessing the performance of surrogate markers would employ a clinical end point rather than biopsy as gold standard [101]. The AUROC values may also depend on the biopsy tissue size and fragmentation [103] as well as the incidence of each stage of fibrosis within the studied population (e.g., the spectrum bias) [104]. Indeed, if extreme stages of fibrosis (F_0 and F_4) are overestimated in a population, the sensitivity and specificity achieved will automatically be higher than in a population that included only patients with near stages of fibrosis (F_1 and F_2). Several strategies of prohibiting the “spectrum bias” have been suggested including the realignment of AUROC by the DANA method that define advanced (F_2 – F_4) and non-advanced fibrosis (F_0 – F_1) [104] or the Obuchowski measure that is multinomial version of the AUROC [105, 106]. Today, noninvasive methods are widely available. Their most advantages are the absence of contraindication and dangerous complications for the patients, and their reproducibility [107]. In contrast to liver biopsy, many noninvasive methods can effectively evaluate the extent of fibrosis in the whole organ and not only in a part of it. Their potential ability to identify and differentiate between advanced fibrosis stages, the high specificity and sensitivity to diagnose cirrhosis, and their easy application makes them a useful tool in daily clinical practice. Many liver fibrosis experts would therefore consider noninvasive fibrosis tests with an AUROC of 0.85–0.90 to be as good as liver biopsy for diagnosis and staging for liver fibrosis [108]. The role of noninvasive diagnostic tests becomes more significant because their diagnostic accuracy can be increased if they are combined, that is, a serological panel may be used in conjunction with an imaging technique [90, 99, 109]. Features of ideal noninvasive markers of liver fibrosis are summarized in **Table 4**.

4.1. Serological markers of liver fibrosis

The clinical need for good noninvasive markers of fibrosis is underlined by the marked increase in the number of reports in this area in recent years. A large number of the serological markers of liver fibrosis have been assessed for the noninvasive evaluation of liver fibrosis and

are broadly categorized into two groups (direct and indirect) [107]. First, we will refer to direct markers of fibrosis that are thought to directly reflect ECM turnover. Fields in which these methods may have clinical or investigational values involve both the noninvasive method for staging of liver fibrosis but they may also be useful for monitoring the behavior of fibrogenesis and ECM metabolism. Therefore, such assays may be valuable in forecasting fibrotic disease deterioration as well as the efficiency of treatment. Second, there are those that reflect changes in hepatic function but do not directly reflect ECM turnover, for instance, platelet count, coagulation studies, and evaluation of liver enzymes, the so-called indirect markers of liver fibrosis. Researches and developments of these markers have largely focused on the diagnosis of cirrhosis, but more recent researches have emphasized the availability of these markers to assess patients with more advanced fibrosis and hence may be valuable in guiding treatment decisions and prediction of complications of liver cirrhosis [90, 108].

4.1.1. Direct markers of liver fibrosis

Direct markers of liver fibrosis include serum markers, which have been shown to be, or are thought to be, directly involved in the deposition or degradation of ECM. The best-validated marker is hyaluronic acid (HA), a glycosaminoglycan synthesized by HSCs [110]. HA levels correlate with fibrosis in ALD [111] and chronic viral hepatitis [112, 113] and a highly negative score may be used in clinical practice as a reliable index for exclusion of liver fibrosis. Amino-terminal propeptide of type III collagen is a marker associated with collagen deposition and its level is increased in acute and chronic hepatic diseases [114]. TIMPs (TIMP-1 and -2), on the other hand, are associated with the procedure of collagen degradation, which is progressive to fibrosis consequence [114]. The direct markers include several cytokines and markers of matrix turnover (**Table 5**). The circulating retention times of these molecules are short, so levels may reflect the behavior of ECM turnover. Since ECM turnover is related to both new ECM accumulation and degradation and rebuilding of formed ECM, circulating levels probably exhibit both the activity of the fibrogenesis and the total amount of ECM rebuilding [108]. This phenomenon is identified by at least three properties. First, circulating amounts of these markers are often most increased in situations with rapidly processing fibrosis (e.g., advanced ALD or more active viral hepatitis) and may be high ahead of the significant accumulation of ECM [113, 115]. Second, circulating ECM levels tend toward a decrease in reaction to therapy of the underlying illness, often before any perceptible decrease in the stage of fibrosis [116]. Third, in chronic liver diseases, elevations of several, but not all of these markers associate independently with the stage of fibrosis, rather than with either serological or histopathological findings of inflammatory reaction [112, 117, 118]. In some studies, however, levels of these markers correlated more strongly with the degree of histopathological inflammation or serum liver enzymes [119]. The observation that markers of ECM metabolism are increased in parallel with markers of liver inflammation and necrosis may reflect the importance of these processes in up-regulating fibrogenesis. Direct markers of fibrosis can also be categorized according to their molecular structures. These include (a) collagens: procollagen I and III, propeptides released into the circulation during matrix accumulation and rebuilding. Type IV collagen, which is secreted during interstitial filament metabolism, reflects matrix depletion and rebuilding; (b) glycoproteins and polysaccharides including HA [120], laminin [121], tenascin, and

Markers of deposition	Markers of degradation	Unknown roles
◆ Procollagen I C-terminal	◆ Procollagen IV C peptide	◆ Hyaluronic acid(HA)
◆ Procollagen III N-terminal	◆ Procollagen IV N peptide (7-S collagen)	◆ Laminin
◆ Tenascin	◆ Collagen IV	◆ YKL-40 (Chondrex)
◆ TIMPs	◆ Undulin	
◆ TGF-β	◆ MMPs	

Table 5. Direct markers of ECM turnover (deposition vs. degradation) (modified from Ref. [108]).

YKL-40 [122]; and (c) collagenase and their inhibitors, include the MMPs and TIMPs, and cytokines involved in liver fibrosis, the best studies of these is TGF-β. Others, including PDGFs and the antifibrotic cytokine IL-10, have been less well evaluated [108]. The greatest clinical utility of HA may be its ability to exclude patients with significant fibrosis and cirrhosis [112].

4.1.2. Indirect marker and combined panels of liver fibrosis

Indirect markers of fibrosis are simple routine blood tests reflecting alterations in liver function but not directly representing ECM homeostasis. These biomarkers include indices related to portal hypertension (platelet count and spleen size), liver synthetic parameters (i.e., albumin), liver enzymes such as aspartate aminotransferase (AST) and alanine aminotransferase (ALT) [123], AST/ALT ratio [124, 125], bilirubin, prothrombin index (PT) [126], γ-glutamyl transferase (γ-GT), and apolipoprotein A₁(apo-A₁). They can be used in combination to produce sophisticated serological panels such as PGA index (prothrombin time, γ-GT, and apo-A₁) [127–129] and APRI (AST to platelet ratio index) [130, 131]. PGA is one of the first biological indexes used for the noninvasive detection of cirrhosis in ALD patients [127]. APRI is based on serum AST level and platelet [131]. It is calculated as (AST/upper limit of normal*) × 100/platelet count and has been extensively studied in patients with HCV or ALD (*adjusted according to the reference values of each laboratory) [107, 132]. PGA index was subsequently modified to the PGAA index by the addition of α₂-macroglobulin which resulted in some improvement in its performance (PGAA) [128]. Analysis of studies of indirect markers of fibrosis reveals several features, which are applicable to routine clinical practice. First, in viral and NAFLD, an AST/ALT ratio of greater than 1 is frequently associated with progressive liver fibrosis or cirrhosis [133–135]. Second, both components of the PGA index such as γ-GT and thrombin index are markers of advanced liver fibrosis and can be used to discern patients with more advanced liver fibrosis. Indeed, the prothrombin index has been carried out alike or better than specific other markers of liver fibrosis [117, 136]. It should be emphasized that these markers represent liver dysfunction or structure rather than the disturbance of normal ECM metabolism (**Table 6**) [108].

4.1.3. Indices/algorithms combining indirect and direct markers of liver fibrosis

The limitations of each marker to assess liver fibrosis have led to the development of more sophisticated algorithms or indices combining the results of panels of markers that substantially improved diagnostic accuracy in noninvasive evaluation of liver fibrosis (**Table 7**).

Direct serum markers	Indirect serum markers/combined panels
◆ HA	◆ Liver enzymes (ALT, AST)
◆ Laminin	◆ AST/ALT
◆ YKL-40	◆ γ -GT
◆ Procollagen type III	◆ Platelet count
◆ PIIINP	◆ Albumin
◆ MMP-1 and -2	◆ Bilirubin
◆ TIPMs	◆ PGA
◆ TGF- β	◆ APRI

Abbreviation: TIMP, tissue inhibitors of metalloproteinases; MMP, matrix metalloproteinase; ALT, alanine aminotransferase; HA, hyaluronic acid; APRI, aspartate aminotransferase/platelet ratio index; PIIINP, Procollagen III amino terminal; γ -GT, γ -glutamyl transpeptidase.

Table 6. Serum noninvasive marker of liver fibrosis (modified from Refs. [19, 84]).

Scores/algorithms	Description
FibroTest [137]	<ul style="list-style-type: none"> • Most validated algorithm and consider patient age and gender • Five parameters: apo-A₁, α₂-macroglobulin, γ-GT, total bilirubin, haptoglobin.
Hepascore [147]	<ul style="list-style-type: none"> • Four parameters: bilirubin, γ-GT, HA, TIMP-1, α₂-macroglobulin, age, and gender. • Prediction with AUROC 0.81 in significant fibrosis and 0.88 for cirrhosis
Fibrospect [148]	<ul style="list-style-type: none"> • 3 parameters: serum HA, TIMP-1, α₂-macroglobulin • Moderate or severe fibrosis versus no fibrosis
Fibrometer [149]	<ul style="list-style-type: none"> • Six parameters: platelet count, prothrombin time, AST, α₂-macroglobulin, HA, BUN • Prediction of severe fibrosis in chronic viral hepatitis
ViraHep C model [150]	<ul style="list-style-type: none"> • Probability = $1/(\exp[-y] + 1)$, $y = -5.17 + 0.2x_{\text{race}} + \text{age}(\text{years}) + 1.19 \times \ln(\text{AST, IU/L}) - 1.76 \times \ln(\text{platelet, } 10^3/\text{mL}) + 1.38 \times \ln(\text{AP, IU/L})$ for severe fibrosis in chronic hepatitis C • Dependent on race (AA, African American = 0, CA, Caucasian American = 1)
Glycocirrhostat [151]	<ul style="list-style-type: none"> • Detection of compensated cirrhosis with 100% specificity and 75% sensitivity. • Follow-up of chronic liver diseases patients without repeated biopsy
Fibrosis Probability Index (FPI) [152]	<ul style="list-style-type: none"> • Multivariate logistic regression analysis identified age, AST, total cholesterol level, insulin resistance (by homeostasis model), and past alcohol intake as independent predictors of significant fibrosis. • 96% sensitivity and NPV 93% at a score of ≥ 0.2 versus 94% specificity and PPV 87% at a score of ≥ 0.8. • Probability of significant liver fibrosis in patients with chronic HCV infection and useful guide to make decision for need of biopsy.
Goteborg University Cirrhosis Index (GUCI) [153]	<ul style="list-style-type: none"> • Multivariate logistic regression analysis between fibrosis stage (ref. as Ishak stage) • GUCI formula: normalized AST \times prothrombin-INR \times 100/platelet count ($\times 10^9/\text{L}$) • 80% sensitivity and 78% specificity for cirrhosis with NPV 97% and PPV 31%
Forns score [154]	<ul style="list-style-type: none"> • $7.811 - 3.131 \times \ln(\text{PT}) + 0.781 \times \ln(\gamma\text{-GT}) + 3.467 \times \ln(\text{age}) - 0.014 \times (\text{cholesterol})$ • Validation in patients with CHC as well as nonviral chronic hepatitis

Scores/algorithms	Description
ELF score [155]	<ul style="list-style-type: none"> • Combination of HA, TIMP-1, amino-terminal propeptide of collagen III collagen. • Useful tool in various chronic liver diseases (e.g. ALD, NAFLD)
APRI+Fibrotest [140]	<ul style="list-style-type: none"> • Improvement of diagnostic accuracy of Fibrotest for detection of significant fibrosis (≥ 2 by Metavir) and cirrhosis (F4) in CHC patients. • Accuracy of SAFE biopsy for significant fibrosis and/or cirrhosis: above 90%
BAAT score [156]	<ul style="list-style-type: none"> • Index for NAFLD fibrosis (BMI, age, ALT, TG levels) • 4 features, assigning 1 point for each of the following: BMI ≥ 28 kg/m², age ≥ 50 years, ALT \geq twice the normal values, and TG ≥ 1.7 mmol/L. • A score of 0 or 1 excludes significant fibrosis with NPV of 100%
BARD score [157]	<ul style="list-style-type: none"> • Combination of three variables (AST/ALT ratio, BMI, Type 2 DM) • (BMI $\geq 28 = 1$, AST/ALT ratio $\geq 0.8 = 2$, diabetes = 1, score ≥ 2, odds ratio for advanced fibrosis = 17) • The variables such as obesity, diabetes, and age influence the score, resulting in a very low PPV and validated in a cohort of NAFLD
NAFLD fibrosis score [158, 159]	<ul style="list-style-type: none"> • Logistic formula: $-1.675 + 0.037 \times \text{age}(\text{years}) + 0.094 \times \text{BMI}(\text{kg}/\text{m}^2) + 1.13 \times \text{impaired fasting glucose/diabetes}(\text{yes} = 1, \text{no} = 0) + 0.99 \times \text{AST}/\text{ALT ratio} - 0.013 \times \text{platelet count}(\times 10^9/\text{L}) - 0.66 \times \text{albumin}(\text{g}/\text{dL})$ • Values ≤ 1.455: no advanced fibrosis vs. ≥ 0.676: advanced fibrosis
FIB-4 score [160]	<ul style="list-style-type: none"> • 90% NPV in excluding and a satisfying 80% PPV in diagnosing fibrosis. • Calculating formula: $(\text{age} \times \text{AST}) / (\text{platelet count}(\times 10^9/\text{L}) \times \sqrt{\text{ALT}})$ • NAFLD score and FIB-4: determination of necessity of liver biopsy in NAFLD
P-value [98]	<ul style="list-style-type: none"> • 3 parameters: ALT/AST ratio, prothrombin time, H/L ratio • $P\text{-value} = \exp[y] / (\exp[y] + 1)$, $y = 3.3431 - 0.8160 \times \text{ALT}/\text{AST} - 0.343 \times \text{PT} + 2.693 \times \text{H}/\text{L ratio}$ • $P < 7.0$: non-cirrhotic patients (96.2%)

Abbreviation: AP, alkaline phosphatase; NPV, negative-predictive value; PPV, positive-predictive value, CHC, BMI, body mass index; H/L ratio, heart/liver uptake ratio; γ -GT, γ -glutamyl transpeptidase.

Table 7. Combined scores/algorithms for evaluation of liver fibrosis.

In most studies, indices have been validated against the current clinical gold standard, liver biopsy, using as expression of their effectiveness the AUROC with optimal value being as close as possible [99]. The first proposed index was based on a parented mathematical formula combining five variables (total bilirubin, γ -GT, haptoglobin, $\alpha 2$ -macroglobulin, and apo-A₁) [137] and the results of this test were ranged from 0 to 1.0, using Fibrotest as a reference. In the initial report, a very low score (< 0.1) allowed the exclusion of significant fibrosis with a 100% negative-predictive value (NPV), whereas a moderate high score (> 0.6) allowed the diagnosis of significant fibrosis with a 90% positive-predictive value (PPV), using liver biopsy as a reference. Overall, liver biopsy could have been avoided in 46% of the patients from that study. Fibrotest has been primarily used for patients with chronic viral hepatitis and is now extensively evaluated in the patients with chronic hepatitis C [109, 138, 139] but also in other cases, such as hepatitis B [140, 141], HCV and HIV coinfection [142], NAFLD [143], ALD [93], and renal-transplanted patients with chronic HCV [144]. The recent meta-analysis that pooled 7985 subjects (with analysis of individual data in 3282) with both Fibrotest and biopsy (HCV, 4600; HBV, 1580; NAFLD, 267; ALD, 524; mixed form, 1014) and the mean standardized AUROC for

diagnosing significant fibrosis was 0.84 (95% confidence interval: 0.83–0.89), without differences between causes of liver disease. Therefore, Fibrotest have been used as an alternative to liver biopsy for the first-line assessment of fibrosis and common chronic liver diseases, namely HCV, HBV, NAFLD, and ALD [145]. One of the important issues of these algorithms is that in individual patients they cannot reliably differentiate the intermediate stages of fibrosis. Finally, in patients with chronic HCV, the application of these algorithms or indices can confirm or exclude fibrosis in less than 40% of patients [146].

4.1.4. Combination of indices and algorithms for assessment of liver fibrosis

In order to increase diagnostic accuracy, new approaches using stepwise algorithms combining continually different indices have been proposed in patients with chronic hepatitis C [161] and B [140]. For instance, one group was able to identify significant fibrosis with high diagnostic outcome above 94% diagnostic accuracy by APRI as screening procedure, followed by Fibrotest in APRI non-classified cases and prohibiting liver biopsy to patients classified *F0–F1* by noninvasive procedures. Cirrhosis could also have been recognized with 95% diagnostic accuracy applying a similar algorithm by the combination of APRI and Fibrotest (**Figure 2**). On the whole, liver biopsy could have been prevented in approximately 50 and 80% of patients for the diagnosis of severe fibrosis and cirrhosis in patients with chronic hepatitis C, respectively. Other groups have proposed alternative algorithms combining Fibrotest and APRI either with [162] or without Forns index [146]. Otherwise, high diagnostic accuracy for the evaluation of significant fibrosis and cirrhosis has been reported for the combination of Fibrotest with Fibroscan that is based on the assessment of hepatic stiffness by TE [22, 109]. However, this method requires the availability of complex equipment, with limited access and costs that most likely exceed those of their more simple and accessible algorithms [161].

Several noninvasive markers of liver fibrosis have been represented but their application in substitute for liver biopsy may still remain controversy and is not generally acceptable due to still insufficient diagnostic performance. In fact, some of these methodologies such as APRI and Forns index remain in many cases unclassified group and all of them are not over 80–85% diagnostic performance [131, 139, 163, 164]. As a consequence, many patients still need to have a liver biopsy taken, and in those classified without liver biopsy, misdiagnosis is expected to occur in at least 15–20%, a figure that is considered inadequate by many clinicians [165, 166]. Most of them, such as APRI and Forns index, are not able to identify individual stages of fibrosis. APRI cannot be completely standardized due to the variability of measurement and normal ranges of AST in different laboratories [167]. Since the diagnostic performance of described noninvasive markers is variable depending on the stage of fibrosis and other patients' characteristics, they can be used to reduce rather than completely substitute the need for liver biopsy. Even though many studies have been shown that Fibrotest had the best performance when compared to other noninvasive methods, none of the investigated noninvasive markers of liver fibrosis has adequate accuracy for universal use instead of liver biopsy [140]. And, one of the major critical points of the clinical application of serum markers and indices of liver fibrosis is that they are not regularly useful in most clinical situation. Another clinical point of these markers is that they are liver nonspecific and may be influenced by changes of their level; for example, HA levels increase after the meal [168] or in senile

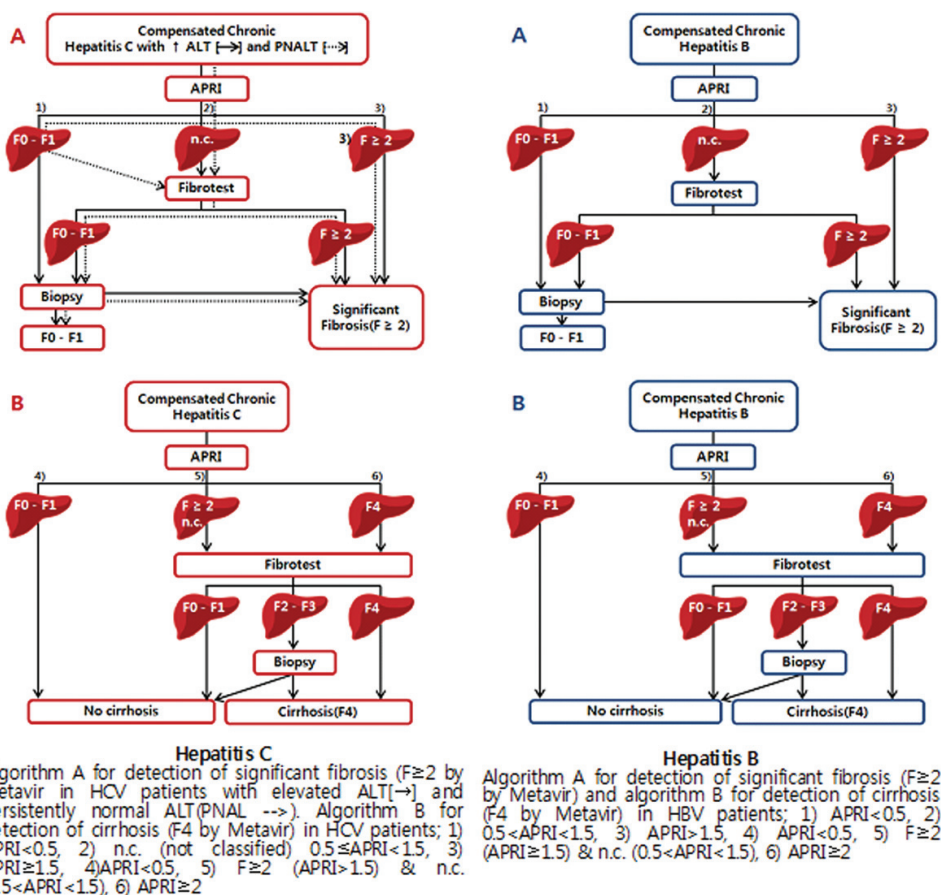


Figure 2. Proposed best algorithm for the detection of significant fibrosis and cirrhosis using APRI and Fibrotect in patients with chronic hepatitis C and B with diagnostic accuracy (modified from Refs. [90, 159]).

patients with chronic inflammatory states such as rheumatoid arthritis [169]. Also, the repeatability of assessments of several biomarkers included in direct serum markers, such as AST levels or platelet count, is doubtful [170]. The effect of serum lipid levels caused by anticholesteremic agents on the Forns index was taken into consideration. Finally, when applying Fibrotect in clinical situation, the evaluation should consider each of the five markers individually in order to escape false-positive outcomes related to hemolysis (low hepatoglobin level), Gilbert syndrome (high bilirubin level), or false-negative outcomes related to inflammatory reactions [171]. However, a panel that combines proteins and proteinases of the ECM has been proposed and the results are promising [155]. The combined use of some of these markers with the aim of reducing rather than completely abolishing liver biopsy may represent a rational and more convincing approach [172]. In a large-scale multicenter study, the diagnostic accuracy of a stepwise combination of two well-studied noninvasive markers of fibrosis (APRI and Fibrotect) was followed by liver biopsy in only a subset of cases [171]. This approach, called SAFE (sequential algorithm for fibrosis evaluation) biopsy, has been built up with double goal of detecting both severe fibrosis and cirrhosis and has here been confirmed to assure $>90\%$ diagnostic accuracy in comparison with respect to liver biopsy as the gold standard with $<2\%$ underestimation of the stage of liver disease as derived from NPV. The

SAFE biopsy may be particularly useful for screening HCV-infected patients in whom an immediate approach with liver biopsy is particularly problematic or questionable [173]. Using two algorithms (Fibrotest and APRI), liver biopsy could be avoided in 50% of cases for the diagnosis of significant fibrosis and in 70% of cases for the identification of cirrhosis [174].

4.2. Imaging modalities and combinations with other markers for the diagnosis of liver fibrosis

4.2.1. Transient elastography (TE)

Liver fibrosis can be staged using one-dimensional ultrasound TE (Fibroscan) [22], which is the most widely used imaging method for noninvasive and rapid measurement of hepatic tissue stiffness. Many studies have evaluated the diagnostic accuracy of TE for diagnosing cirrhosis with specificity and sensitivity approaching 90%. The accuracy for liver fibrosis detection is lower, with sensitivity and specificity approaching 70–80% [102, 175, 176]. Because both adipose tissue and the presence of fluid may influence the velocity of shear wave [107], obesity, ascites, acute inflammation, liver congestion, and elevated portal vein pressure may reduce TE accuracy. Furthermore, a falsely increased liver stiffness, due to postprandial increase in portal vein pressure, has been observed [177, 178]. Comparison of TE with biopsy results has provided that cut-off values can be demonstrated to differentiate mild and moderate fibrosis from advanced fibrosis and cirrhosis, with validation tests showing variable performance and with greatest statistical significance being ensured in the distinction of cirrhosis from mild fibrosis (AUROC $F = 4$ (0.94), sensitivity $F \geq 2$ (85%), specificity $F \geq 2$ (91%)) [179, 180]. Investigations have applied various best stiffness cut-off values, making comparison between researches. Generally, advanced fibrosis is more likely with higher cut-off values (**Table 8**) [181, 182]. The optimal cut-off value is 14.6 kPa for the detection of cirrhosis, but a cut-off value of 10.0 and 14.1 kPa was adequate to achieve 95% sensitivity and specificity in their HCV patients with cirrhosis [183]. Otherwise, the performance of TE was low for discriminating mild from significant liver fibrosis [184] and Spearman's correlation coefficient between the elasticity scores using real-time TE and histopathological fibrosis stage was low at 0.48 [185]. However, TE was more useful for the identification of advanced fibrosis and their necroinflammatory activity influences TE measurements in patients without cirrhosis [186] and might be overestimated liver fibrosis when ALT is elevated [187]. Some reports were shown that good correlation between TE and fibrosis exists, but data on TE in an Asian cohort show only 8% of patients having limited HCV [188]. Liver stiffness measurement (LSM) by TE is a reliable predictor of liver fibrosis in Indian patients with chronic hepatitis C and B. LSM is superior to APRI for noninvasive diagnosis of hepatic fibrosis and cirrhosis, and high bilirubin (10.5 mg/dL) and Ishak HAI grade (>11) were independent predictors of discordance between liver biopsy and LSM [189]. Liver stiffness has also been revealed to have good correlation with steatosis, necrotic inflammatory activity and hepatic iron accumulation as well as fibrosis [190]. TE is restrictive, however, by its impossibility to perform in patients with ascites and patients with narrow intercostal spaces or morbid obesity. Advantages of TE include a short procedure time (<5 min), immediate results, and the ability to perform the test at the bedside or in an outpatient clinic.

Etiologies	Patients (n)	Metavir score		Cut-offs (kPa)	AUROC	SE (%)	SP (%)	CC (%)
		F ≥ 2 (%)	F 4 (%)					
HCV [109]	183	74		7.1	0.83	67	89	73
			25	12.5	0.95	87	91	90
HCV [181]	251	65		8.6	0.79	56	91	68
			19	14.6	0.87	86	96	94
HCV [186]	150	56		7.8	0.91	83	82	83
			19	14.8	0.98	94	92	92
HCV [190]	324	65		7.4	0.86	76	84	79
			21	11.9	0.94	87	91	90
HBV(CV)[179]	228	62		8.3	0.93	90	32	57
			50	14.0	0.96	78	98	88
HBV [192]	173	50		7.2	0.81	70	83	76
			8	11.0	0.93	93	87	94
HBV [193]	284	42		5.2	0.78	89	38	59
			10	12.9	0.85	52	93	89

Abbreviations: AUROC, area under the receiver operator characteristic curve; CC, correctly classified: true positive and negative; HBV, chronic hepatitis B; HCV, chronic hepatitis C; SE, sensitivity; SP, specificity.

Table 8. Diagnostic performance of TE for significant fibrosis ($F \geq 2$) and cirrhosis ($F4$) in patients with Hepatitis B or C (modified from Refs. [191]).

4.2.2. Magnetic resonance elastography (MRE)

MRE is a noninvasive method of measuring the viscoelastic properties of the liver and evaluate liver stiffness by measuring the propagation of mechanical waves [194]. MRE indicated that patients with hepatic fibrosis have higher LSM than normal volunteers [195] and that those with mild fibrosis were able to be distinguished from those with moderate or advanced fibrosis, with a mean hepatic shear elasticity being 2.24, 2.56, and 4.68 kPa in patients with $F0-F1$, $F2-F3$, and $F4$ fibrosis, respectively [196]. MRE is superior to TE because of its ability to scan the whole organ and its application in patients with ascites or obesity. MRE was accurate in liver fibrosis staging and superior to biochemical testing with APRIs in patients with chronic HBV and HCV infection [197, 198]. These findings suggest that noninvasive MRE potentially has a role in determining the treatment and the prognosis of patients with chronic liver disease because it enables substantial and advanced fibrosis to be readily diagnosed. More particularly, MRE might be useful in the selection of patients with liver fibrosis who should either be treated (score of $\geq F2$) or undergo surveillance for portal hypertension and hepatocellular carcinoma (score of $\geq F3$) [197]. Antiviral treatment should be considered in patients with liver stiffness values of ≥ 2.8 kPa [199]. The main drawbacks are the high cost and complexity of the method that is too procrastinating for daily clinical

practice. MRE values may be affected by the increased portal vein pressure following a meal similar to TE [200].

4.2.3. Acoustic radiation force impulses (ARFI)

ARFI use conventional hepatic ultrasonography to assess liver stiffness [199, 201]. ARFI uses short duration of acoustic pulses that produce mechanical excitation. The speed of the produced waves correlates directly with the extent of liver fibrosis and results are expressed in m/s. For fibrosis quantification, the “Virtual Touch (VT) tissue quantification” application was used, allowing for the measurement of SWV (shear wave velocity, m/s) within the interest area chosen by the examiner, according to principles. The higher the tissue stiffness shows, the higher the SWV produces [202]. The theoretical advantage of ARFI as compared to TE is its implementation on an ultrasound device, via additional software imaging control and detection algorithms, thus allowing the visualization of B-mode, color Doppler mode, and ARFI images with same equipment [201]. Advantages of this technology include the ability to select the area to be assessed, avoiding large vessels or ribs [107] and the fact that steatosis does not influence the accuracy of the procedure. Otherwise, ARFI and TE are influenced by high ALT levels. In European patients with chronic hepatitis B and C, ALT values between 1.1x and 5xULN had only limited influence on ARFI values. The best cut-off values for predicting significant fibrosis and cirrhosis were similar in patients with moderately elevated ALT levels [203].

4.2.4. Real-time sonography-based elastography (RTE)

RTE is a new method for the measurement of tissue elasticity different from TE. The echo signals are captured in the real time, while the probe slightly compresses or relaxes the body through freehand operation. Many clinical researches indicated that RTE could allow a high accuracy on the differential diagnosis of superficial focal pathological lesion such as mammary gland tumors, thyroid tumors, and prostate tumors [204, 205]. This method estimates the velocity of a shear wave through the liver using US and results are expressed in kPa. The diagnostic accuracies expressed as AUROC were 0.75 for the diagnosis of significant fibrosis ($F \geq 2$), 0.73 for severe fibrosis ($F \geq 3$), and 0.69 for cirrhosis. For a combined elasticity-laboratory scores (platelet count and γ -GT), AUROCs were 0.93, 0.95, and 0.91, respectively. Therefore, RTE is a new and promising sonography-based noninvasive method for the assessment of liver fibrosis in patients with chronic viral hepatitis [185].

4.2.5. 2D-Shear wave elastography (2D-SWE)

2D-SWE combines ultrasound images with radiation force induced into the liver. 2D-SWE can measure shear waves propagation in real time [16]. Advantages of 2D-SWE (m/s or kPa) include good applicability and adjustable region of interest depending on the operator [84]. Its failure rate is significantly lower than that of TE [206–208], particularly in patients with ascites [207, 208], but not in obese patients when the XL probe is used for TE (10.4 vs. 2.6%, respectively) [209]. In a pilot study in 121 patients with chronic hepatitis C (Metavir, 41% F0/F1, 27% F2, 12% F3, and 20% F4), AUROCs of 2D-AWE for the diagnosis of significant fibrosis

and cirrhosis were 0.92 and 0.98, respectively [206]. Sensitivities and specificities were 85 and 92% for the diagnosis of significant fibrosis using a cut-off of 7.1 kPa, and 97 and 93% for the diagnosis of liver cirrhosis using a cut-off of 10.1 kPa. Therefore, 2D-SWE is a promising technique that is currently under investigation. It seems to be at least equivalent to TE and pSWE/ARFI for noninvasive staging of liver fibrosis in viral hepatitis [16].

4.2.6. Sonography-based imaging

US imaging has been used to noninvasively evaluate the severity of liver fibrosis in patients with chronic HCV. Results vary with some studies showing associations between US score and diagnosis of cirrhosis with various sensitivities (87.5–100%) and specificities (81.5–93.5%) [210, 211]. The application of US to assess liver fibrosis was used by calculating a fibrosis extraction ratio (FER) (fiber volume/total volume), which was able to distinguish F0/F1 from \geq F2 fibrosis with a sensitivity of 55% in the HCV cohort [212]. In sonography, contrast-enhanced sonography is based on intravenous injection of specifically sized microbubbles, transferred with a shell of protein or biopolymers that facilitate their sonographic imaging [213]. Some report studied the hepatic vein transit time (HVTT) for grading liver disease using a microsound microbubble contrast agent as a tracer. This study also applied Doppler sonography to make a decision for several indices to assess portal vein congestive index, but found that there was no significance. HVTT was significantly shorter in cirrhotic patients than in non-cirrhotic patients ($p < 0.001$) and distinguished between these patients with high accuracy [214]. Therefore, unenhanced Doppler ultrasound is not reliable in the discrimination of varying degrees of fibrosis, but that results can be improved with additional measurement such as heart pulsation at the liver surface and portal venous flow measurements. Color Doppler is a noninvasive method for assessing portal hemodynamics. In the study for portal hemodynamics by color Doppler and gastric mucosal blood flow (GMBF) by laser Doppler velocimetry in patients with cirrhosis, portal venous blood flow (PVBF), portal flow velocity (PFV), and GMBF were all significantly slower in cirrhotic patients and PVBF and PFV were lower in Child's class B/C than in class A [215]. A statistically significant difference has been shown in all US markers between patients with and without cirrhosis, but sensitivity and specificity were significantly increased when evaluation of the transmission of heart pulses on the liver surface area included as part of the US test a sensitivity of 85 versus 55% and a specificity of 93 versus 86%, respectively [216].

4.2.7. Per rectum TI-201 scintigraphy (TI-201 test)

A complete understanding of the hepatic disease requires the evaluation of portal circulation, which allows for more appropriate treatment and follow-up of patients. During the last six decades or more, several clinical reports have investigated portal circulation by radioactive tracers [87, 88]. These reports have been established that TI-201 test allows us to understand the portal circulation, and a new method using TI-201 distribution patterns seems to be useful in evaluating the portosystemic shunt (heart/liver uptake ratio, H/L ratio), which can develop to varying extents in liver cirrhosis and positive correlation to portal pressure in patients with chronic hepatitis [87–89, 217]. Our previous studies on the clinical value of H/L ratio in chronic liver disease may be useful in differentiating chronic hepatitis from cirrhosis and the prediction

of its prognosis for the management of disease [97]. Noninvasive test such as maximal removal rate of indocyanine green and H/L ratio, as well as ALT/AST ratio, prothrombin time, and platelet count, may be used to evaluate the progression of chronic liver disease without liver biopsy [98] as well as progression of variceal bleeding without an endoscopy in biopsy-proven patients with cirrhosis [218]. However, because most serum markers except H/L ratio may be changeable by medical treatment of chronic liver disease, serum markers are not suitable for monitoring long-term outcomes of patients with cirrhosis. On assessing the predictive values of H/L ratio for decompensation during the follow-up period of 45.5 months in 107 patients [90], the last visiting value of H/L ratio provided a strongly reliable predictor of decompensation with an odds ratio estimate of 14.4, an AUROC of 0.825, a cut-off of 0.4, a sensitivity of 73.1%, and a specificity of 71.6% (Figure 3).

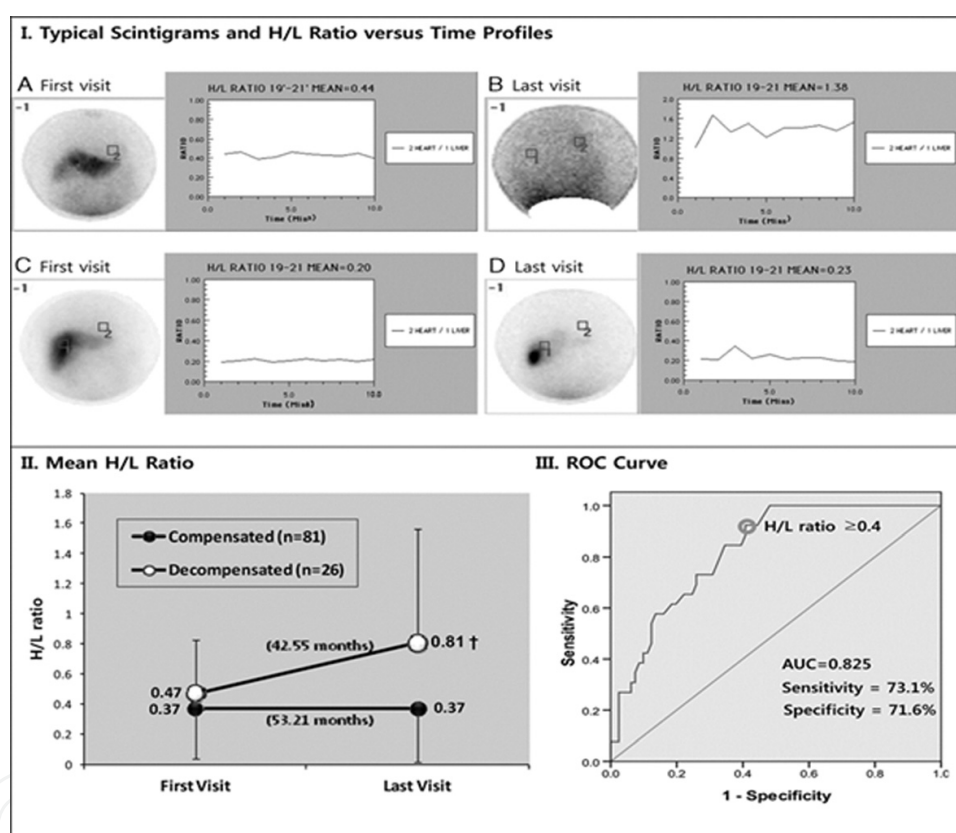


Figure 3. I. Typical scintigrams after administration per rectum of 18.5 MBq ^{201}Tl and H/L ratio versus time profiles in a decompensated patient (A, B) and compensated patient (C, D) at the first and last visits. On the left I (AYD) are scintigrams after administration per rectum of 18.5 MBq ^{201}Tl in each patient (ROI g1, liver area vs. ROI g2, heart area) and on the right I (AYD) are time-activity curves for the H/L ratio in each patient. ROI, regions of interest. II. Mean H/L ratio of the first visit when the patient is diagnosed with cirrhosis and the last visit before the development of decompensation in patients with liver cirrhosis. III. ROC curve and cut-off point of last visit H/L ratio (0.4) (permission from Ref. [90]).

5. Conclusion and perspectives

There is an urgent need to pursue the development of noninvasive tests in addition to a liver biopsy for the staging of fibrosis. The area of liver fibrosis and cirrhosis has been extensively

studied during the few decades. As a result of growing understanding of liver injury and fibrosis, a number of noninvasive tests for fibrosis that are accurate and replace liver biopsy are being used to develop, commercialized, and are being used more and more in practices. The current serum tests are a start and may have utility in identifying patients with minimal fibrosis who do not require a liver biopsy. Because of the conditional relationship with biopsy, the development of serum markers will always have obvious limitations. The use of noninvasive tools varies widely depending on practice setting and the individual physician's management style. However, as with many new diagnostic methodologies, such tests are being adopted and marketed while the evidence of their general usefulness in various clinical settings remains incomplete. For instance, there is no solid evidence that the currently available tests for liver fibrosis have the precision necessary for tracing disease progression in real time or patient's response to therapy. Before such tests are accepted, their superiority to routine laboratory studies should be demonstrated. Although invasive liver biopsy is still the gold standard to assess the nature and severity of hepatic fibrosis, it has several recognized limitations including sampling error and inter-observer variability in interpretation and staging. Furthermore, the dynamic process of fibrosis resulting from progression and regression is difficult to capture with biopsy alone. Therefore, alternative, simple, reliable, and noninvasive direct and indirect serum markers able to predict the presence of significant fibrosis or cirrhosis in patients with chronic liver disease with considerable accuracy were needed. The hepatology experts are actively researching noninvasive methods of fibrosis quantification. This chapter reviewed the nature and limitations of the several noninvasive methods for the assessment of the presence and severity of liver fibrosis in patients with chronic liver disease.

Author details

Ju-Seop Kang^{1*} and Min-Ho Lee²

*Address all correspondence to: jskang@hanyang.ac.kr

1 Department of Pharmacology, College of Medicine, Hanyang University, Seoul, South Korea

2 Department of Internal Medicine, College of Medicine, Ministry of Food and Drug Safety, Hanyang University, Seoul, South Korea

References

- [1] Adams LA, Lymp JF, St Sauver J, Sanderson SO, Lindor KD, Feldstein A, et al. The natural history of nonalcoholic fatty liver disease: A population-based cohort study. *Gastroenterology*. 2005;**129**:113–121
- [2] Sharma S, Khalili K, Nguyen GC. Non-invasive diagnosis of advanced fibrosis and cirrhosis. *World Journal of Gastroenterology*. 2014;**20**:16820–16830. DOI: 10.3748/wjg.v20.i45.16820

- [3] Gines P, Quintero E, Arroyo V, Teres J, Bruguera M, Rimola A, et al. Compensated cirrhosis: Natural history and prognostic factors. *Hepatology (Baltimore, Md)*. 1987;**7**:122–128
- [4] D'Amico G, Garcia-Tsao G, Pagliaro L. Natural history and prognostic indicators of survival in cirrhosis: A systematic review of 118 studies. *Journal of Hepatology*. 2006;**44**:217–231. DOI: 10.1016/j.jhep.2005.10.013
- [5] Poynard T, Bedossa P, Opolon P. Natural history of liver fibrosis progression in patients with chronic hepatitis C. The OBSVIRC, METAVIR, CLINIVIR, and DOSVIRC groups. *Lancet (London, England)*. 1997;**349**:825–832
- [6] Vergniol J, Foucher J, Terrebonne E, Bernard PH, le Bail B, Merrouche W, et al. Noninvasive tests for fibrosis and liver stiffness predict 5-year outcomes of patients with chronic hepatitis C. *Gastroenterology*. 2011;**140**:1970–1979, 9.e1-3. DOI: 10.1053/j.gastro.2011.02.058
- [7] Bravo AA, Sheth SG, Chopra S. Liver biopsy. *The New England Journal of Medicine*. 2001;**344**:495–500. DOI: 10.1056/nejm2001021534440706
- [8] Bedossa P, Poynard T. An algorithm for the grading of activity in chronic hepatitis C. The METAVIR Cooperative Study Group. *Hepatology (Baltimore, Md)*. 1996;**24**:289–293. DOI: 10.1002/hep.510240201
- [9] Ishak K, Baptista A, Bianchi L, Callea F, De Groote J, Gudat F, et al. Histological grading and staging of chronic hepatitis. *Journal of Hepatology*. 1995;**22**:696–699
- [10] Tsochatzis E, Bruno S, Isgro G, Hall A, Theocharidou E, Manousou P, et al. Collagen proportionate area is superior to other histological methods for sub-classifying cirrhosis and determining prognosis. *Journal of Hepatology*. 2014;**60**:948–954. DOI: 10.1016/j.jhep.2013.12.023
- [11] Cadranel JF, Rufat P, Degos F. Practices of liver biopsy in France: Results of a prospective nationwide survey. For the Group of Epidemiology of the French Association for the Study of the Liver (AFEF). *Hepatology (Baltimore, Md)*. 2000;**32**:477–481. DOI: 10.1053/jhep.2000.16602
- [12] Seeff LB, Everson GT, Morgan TR, Curto TM, Lee WM, Ghany MG, et al. Complication rate of percutaneous liver biopsies among persons with advanced chronic liver disease in the HALT-C trial. *Clinical Gastroenterology and Hepatology: The Official Clinical Practice Journal of the American Gastroenterological Association*. 2010;**8**:877–883. DOI: 10.1016/j.cgh.2010.03.025
- [13] Bedossa P, Dargere D, Paradis V. Sampling variability of liver fibrosis in chronic hepatitis C. *Hepatology (Baltimore, Md)*. 2003;**38**:1449–1457. DOI: 10.1016/j.jhep.2003.09.022
- [14] Regev A, Berho M, Jeffers LJ, Milikowski C, Molina EG, Pylsopoulos NT, et al. Sampling error and intraobserver variation in liver biopsy in patients with chronic HCV infection.

The American Journal of Gastroenterology. 2002;**97**:2614–2618. DOI: 10.1111/j.1572-0241.2002.06038.x

- [15] Everhart JE, Wright EC, Goodman ZD, Dienstag JL, Hoefs JC, Kleiner DE, et al. Prognostic value of Ishak fibrosis stage: Findings from the hepatitis C antiviral long-term treatment against cirrhosis trial. *Hepatology* (Baltimore, Md). 2010;**51**:585–594. DOI: 10.1002/hep.23315
- [16] European Association for the Study of the Liver Association Latinoamericana para el Estudio del H. EASL-ALEH Clinical Practice Guidelines: Non-invasive tests for evaluation of liver disease severity and prognosis. *Journal of Hepatology*. 2015;**63**:237–264. DOI: <http://dx.doi.org/10.1016/j.jhep.2015.04.006>
- [17] Bedossa P, Carrat F. Liver biopsy: The best, not the gold standard. *Journal of Hepatology*. 2009;**50**:1–3. DOI: 10.1016/j.jhep.2008.10.014
- [18] Cohen-Naftaly M, Friedman SL. Current status of novel antifibrotic therapies in patients with chronic liver disease. *Therapeutic Advances in Gastroenterology*. 2011;**4**:391–417. DOI: 10.1177/1756283x11413002
- [19] Castera L. Assessing liver fibrosis. *Expert Review of Gastroenterology & Hepatology*. 2008;**2**:541–552. DOI: 10.1586/17474124.2.4.541
- [20] Calvaruso V, Craxì A. Regression of fibrosis after HBV antiviral therapy. Is cirrhosis reversible? *Liver International*. 2014;**34**:85–90
- [21] Grigorescu M. Noninvasive biochemical markers of liver fibrosis. *Journal of Gastrointestinal and Liver Diseases: JGLD*. 2006;**15**:149–159
- [22] Sandrin L, Fourquet B, Hasquenoph JM, Yon S, Fournier C, Mal F, et al. Transient elastography: A new noninvasive method for assessment of hepatic fibrosis. *Ultrasound in Medicine & Biology*. 2003;**29**:1705–1713
- [23] de Ledinghen V, Vergniol J. Transient elastography for the diagnosis of liver fibrosis. *Expert Review of Medical Devices*. 2010;**7**:811–823. DOI: 10.1586/erd.10.46
- [24] Friedman SL. Liver fibrosis—From bench to bedside. *Journal of Hepatology*. 2003;**38**(**Suppl 1**):S38–S53
- [25] Bataller R, Brenner DA. Liver fibrosis. *The Journal of Clinical Investigation*. 2005;**115**:209–218. DOI: 10.1172/jci24282
- [26] Hernandez-Gea V, Friedman SL. Pathogenesis of liver fibrosis. *Annual Review of Pathology*. 2011;**6**:425–456. DOI: 10.1146/annurev-pathol-011110-130246
- [27] Puche JE, Saiman Y, Friedman SL. Hepatic stellate cells and liver fibrosis. *Comprehensive Physiology*. 2013;**3**:1473–1492. DOI: 10.1002/cphy.c120035
- [28] Iredale JP. Models of liver fibrosis: Exploring the dynamic nature of inflammation and repair in a solid organ. *The Journal of Clinical Investigation*. 2007;**117**:539–548. DOI: 10.1172/jci30542

- [29] Germani G, Hytioglou P, Fotiadu A, Burroughs AK, Dhillon AP. Assessment of fibrosis and cirrhosis in liver biopsies: An update. *Seminars in Liver Disease*. 2011;**31**:82–90. DOI: 10.1055/s-0031-1272836
- [30] Suk KT, Kim DJ. Staging of liver fibrosis or cirrhosis: The role of hepatic venous pressure gradient measurement. *World Journal of Hepatology*. 2015;**7**:607–615. DOI: 10.4254/wjh.v7.i3.607
- [31] Falize L, Guillygomarc'h A, Perrin M, Laine F, Guyader D, Brissot P, et al. Reversibility of hepatic fibrosis in treated genetic hemochromatosis: A study of 36 cases. *Hepatology (Baltimore, Md)*. 2006;**44**:472–477. DOI: 10.1002/hep.21260
- [32] Geerts A. History, heterogeneity, developmental biology, and functions of quiescent hepatic stellate cells. *Seminars in Liver Disease*. 2001;**21**:311–335. DOI: 10.1055/s-2001-17550
- [33] Schuppan D, Ruehl M, Somasundaram R, Hahn EG. Matrix as a modulator of hepatic fibrogenesis. *Seminars in Liver Disease*. 2001;**21**:351–372. DOI: 10.1055/s-2001-17556
- [34] Gressner AM. Cytokines and cellular crosstalk involved in the activation of fat-storing cells. *Journal of Hepatology*. 1995;**22**:28–36
- [35] Olaso E, Ikeda K, Eng FJ, Xu L, Wang LH, Lin HC, et al. DDR2 receptor promotes MMP-2-mediated proliferation and invasion by hepatic stellate cells. *The Journal of Clinical Investigation*. 2001;**108**:1369–1378. DOI: 10.1172/jci12373
- [36] Bataller R, Brenner DA, editors. *Hepatic stellate cells as a target for the treatment of liver fibrosis*. *Seminars in Liver Disease*. NY, USA: Thieme Medical Publishers, Inc.; 2001
- [37] Iredale JP, editor. *Hepatic stellate cell behavior during resolution of liver injury*. *Seminars in Liver Disease*. NY, USA: Thieme Medical Publishers, Inc.; 2001
- [38] Schaffner F, Poper H. Capillarization of hepatic sinusoids in man. *Gastroenterology*. 1963;**44**:239–242
- [39] Gressner A, Weiskirchen R. Modern pathogenetic concepts of liver fibrosis suggest stellate cells and TGF- β as major players and therapeutic targets. *Journal of Cellular and Molecular Medicine*. 2006;**10**:76–99
- [40] Yoshiji H, Kuriyama S, Miyamoto Y, Thorgeirsson UP, Gomez DE, Kawata M, et al. Tissue inhibitor of metalloproteinases-1 promotes liver fibrosis development in a transgenic mouse model. *Hepatology (Baltimore, Md)*. 2000;**32**:1248–1254. DOI: 10.1053/jhep.2000.20521
- [41] Ebrahimi H, Naderian M, Sohrabpour AA. New concepts on pathogenesis and diagnosis of liver fibrosis; A review article. *Middle East Journal of Digestive Diseases*. 2016;**8**:166
- [42] Benyon RC, Iredale JP, Goddard S, Winwood PJ, Arthur MJ. Expression of tissue inhibitor of metalloproteinases 1 and 2 is increased in fibrotic human liver. *Gastroenterology*. 1996;**110**:821–831

- [43] Takahara T, Furui K, Yata Y, Jin B, Zhang LP, Nambu S, et al. Dual expression of matrix metalloproteinase-2 and membrane-type 1-matrix metalloproteinase in fibrotic human livers. *Hepatology (Baltimore, Md)*. 1997;**26**:1521–1529. DOI: 10.1002/hep.510260620
- [44] Arthur MJ. Fibrogenesis II. Metalloproteinases and their inhibitors in liver fibrosis. *American Journal of Physiology Gastrointestinal and Liver Physiology*. 2000;**279**:G245–G249
- [45] Wells RG, Schwabe RF. Origin and function of myofibroblasts in the liver. *Seminars in Liver Disease*. 2015;**35**:97–106. DOI: 10.1055/s-0035-1550061
- [46] Friedman SL. Mechanisms of hepatic fibrogenesis. *Gastroenterology*. 2008;**134**:1655–1669. DOI: 10.1053/j.gastro.2008.03.003
- [47] Parola M, Marra F, Pinzani M. Myofibroblast-like cells and liver fibrogenesis: Emerging concepts in a rapidly moving scenario. *Molecular Aspects of Medicine*. 2008;**29**:58–66. DOI: 10.1016/j.mam.2007.09.002
- [48] Iwaisako K, Jiang C, Zhang M, Cong M, Moore-Morris TJ, Park TJ, et al. Origin of myofibroblasts in the fibrotic liver in mice. *Proceedings of the National Academy of Sciences of the United States of America*. 2014;**111**:E3297–E3305. DOI: 10.1073/pnas.1400062111
- [49] Dranoff JA, Wells RG. Portal fibroblasts: Underappreciated mediators of biliary fibrosis. *Hepatology (Baltimore, Md)*. 2010;**51**:1438–1444. DOI: 10.1002/hep.23405
- [50] Lemoine S, Cadoret A, Rautou PE, El Mourabit H, Ratzu V, Corpechot C, et al. Portal myofibroblasts promote vascular remodeling underlying cirrhosis formation through the release of microparticles. *Hepatology (Baltimore, Md)*. 2015;**61**:1041–1055. DOI: 10.1002/hep.27318
- [51] Brenner DA. Molecular pathogenesis of liver fibrosis. *Transactions of the American Clinical and Climatological Association*. 2009;**120**:361–368
- [52] Carotti S, Morini S, Corradini SG, Burza MA, Molinaro A, Carpino G, et al. Glial fibrillary acidic protein as an early marker of hepatic stellate cell activation in chronic and posttransplant recurrent hepatitis C. *Liver Transplantation: Official Publication of the American Association for the Study of Liver Diseases and the International Liver Transplantation Society*. 2008;**14**:806–814. DOI: 10.1002/lt.21436
- [53] Kalluri R, Zeisberg M. Fibroblasts in cancer. *Nature Reviews Cancer*. 2006;**6**:392–401. DOI: 10.1038/nrc1877
- [54] Moreira RK. Hepatic stellate cells and liver fibrosis. *Archives of Pathology & Laboratory Medicine*. 2007;**131**:1728–1734. DOI: 10.1043/1543-2165(2007)131[1728:hscalf]2.0.co;2
- [55] Bilzer M, Roggel F, Gerbes AL. Role of Kupffer cells in host defense and liver disease. *Liver International: Official Journal of the International Association for the Study of the Liver*. 2006;**26**:1175–1186. DOI: 10.1111/j.1478-3231.2006.01342.x

- [56] Bachem MG, Melchior R, Gressner AM. The role of thrombocytes in liver fibrogenesis: Effects of platelet lysate and thrombocyte-derived growth factors on the mitogenic activity and glycosaminoglycan synthesis of cultured rat liver fat storing cells. *Journal of Clinical Chemistry and Clinical Biochemistry Zeitschrift fur Klinische Chemie und Klinische Biochemie*. 1989;**27**:555–565
- [57] Ghiassi-Nejad Z, Friedman SL. Advances in antifibrotic therapy. *Expert Review of Gastroenterology & Hepatology*. 2008;**2**:803–816. DOI: 10.1586/17474124.2.6.803
- [58] Ramachandran P, Iredale JP. Reversibility of liver fibrosis. *Annals of Hepatology*. 2009;**8**:283–291
- [59] Elpek GO. Cellular and molecular mechanisms in the pathogenesis of liver fibrosis: An update. *World Journal of Gastroenterology*. 2014;**20**:7260–7276. DOI: 10.3748/wjg.v20.i23.7260
- [60] Cassiman D, Libbrecht L, Desmet V, Denef C, Roskams T. Hepatic stellate cell/myofibroblast subpopulations in fibrotic human and rat livers. *Journal of Hepatology*. 2002;**36**:200–209
- [61] Fernandez M, Semela D, Bruix J, Colle I, Pinzani M, Bosch J. Angiogenesis in liver disease. *Journal of Hepatology*. 2009;**50**:604–620. DOI: 10.1016/j.jhep.2008.12.011
- [62] Lee RG. *Diagnostic Liver Pathology*. Mosby Inc.; 1994.
- [63] Germani G, Burroughs AK, Dhillon AP. The relationship between liver disease stage and liver fibrosis: A tangled web. *Histopathology*. 2010;**57**:773–784. DOI: 10.1111/j.1365-2559.2010.03609.x
- [64] Stanley AJ, Haydon GH, Piris J, Jarvis LM, Hayes PC. Assessment of liver histology in patients with hepatitis C and normal transaminase levels. *European Journal of Gastroenterology & Hepatology*. 1996;**8**:869–872
- [65] Diehl AM. Alcoholic liver disease. *The Medical Clinics of North America*. 1989;**73**:815–830
- [66] Locke GR, 3rd, Therneau TM, Ludwig J, Dickson ER, Lindor KD. Time course of histological progression in primary biliary cirrhosis. *Hepatology (Baltimore, Md)*. 1996;**23**:52–56. DOI: 10.1002/hep.510230108
- [67] Bach N, Thung SN, Schaffner F. The histologic effects of low-dose methotrexate therapy for primary biliary cirrhosis. *Archives of Pathology & Laboratory Medicine*. 1998;**122**:342
- [68] Hultcrantz R, Gabrielsson N. Patients with persistent elevation of aminotransferases: Investigation with ultrasonography, radionuclide imaging and liver biopsy. *Journal of Internal Medicine*. 1993;**233**:7–12
- [69] Brown KE, Janney C, Brunt EM. Liver biopsy: Indications, technique, complications, and interpretation. In: Bacon BR, Di Bisceglie AM Churchill Livingstone, editors. *Liver Disease: Diagnosis and Management*. New York, NY; 2000

- [70] Rousselet MC, Michalak S, Dupre F, Croue A, Bedossa P, Saint-Andre JP, et al. Sources of variability in histological scoring of chronic viral hepatitis. *Hepatology (Baltimore, Md)*. 2005;**41**:257–264. DOI: 10.1002/hep.20535
- [71] Colloredo G, Guido M, Sonzogni A, Leandro G. Impact of liver biopsy size on histological evaluation of chronic viral hepatitis: The smaller the sample, the milder the disease. *Journal of Hepatology*. 2003;**39**:239–244
- [72] Standish RA, Cholongitas E, Dhillon A, Burroughs AK, Dhillon AP. An appraisal of the histopathological assessment of liver fibrosis. *Gut*. 2006;**55**:569–578. DOI: 10.1136/gut.2005.084475
- [73] Colombo M, Del Ninno E, de Franchis R, De Fazio C, Festorazzi S, Ronchi G, et al. Ultrasound-assisted percutaneous liver biopsy: Superiority of the Tru-Cut over the Menghini needle for diagnosis of cirrhosis. *Gastroenterology*. 1988;**95**:487–489
- [74] EASL International Consensus Conference on Hepatitis C. Paris, 26–27 February 1999. Consensus statement. *Journal of Hepatology*. 1999;**31(Supp 1 1)**:3–8
- [75] Knodell RG, Ishak KG, Black WC, Chen TS, Craig R, Kaplowitz N, et al. Formulation and application of a numerical scoring system for assessing histological activity in asymptomatic chronic active hepatitis. *Hepatology (Baltimore, Md)*. 1981;**1**:431–435
- [76] Group TFMC. Intraobserver and interobserver variations in liver biopsy interpretation in patients with chronic hepatitis C. The French METAVIR Cooperative Study Group. *Hepatology (Baltimore, Md)*. 1994;**20**:15–20
- [77] Hubscher SG. Histological grading and staging in chronic hepatitis: Clinical applications and problems. *Journal of Hepatology*. 1998;**29**:1015–1022
- [78] Scheuer PJ. Classification of chronic viral hepatitis: A need for reassessment. *Journal of Hepatology*. 1991;**13**:372–374
- [79] Batts KP, Ludwig J. Chronic hepatitis. An update on terminology and reporting. *The American Journal of Surgical Pathology*. 1995;**19**:1409–1417
- [80] Wanless IR, Sweeney G, Dhillon AP, Guido M, Piga A, Galanello R, et al. Lack of progressive hepatic fibrosis during long-term therapy with deferiprone in subjects with transfusion-dependent beta-thalassemia. *Blood*. 2002;**100**:1566–1569. DOI: 10.1182/blood-2002-01-0306
- [81] Fiel MI. Histologic scoring systems for chronic liver disease. UpToDate com. 2016:1–70. Available from: <https://www.uptodate.com/contents/histologic-scoring-systems-for-chronic-liver-disease>. [Accessed: 23 January, 2017]
- [82] The Merck Manual Wolters Kluwer; 19th ed. Elsevier; 2011
- [83] Zeng DW, Dong J, Liu YR, Jiang JJ, Zhu YY, Shaffer EA. Testing for hepatic and biliary disorders. Noninvasive models for assessment of liver fibrosis in patients with chronic hepatitis B virus infection. *World Journal of Gastroenterology*. 2016;**22**:6663–6672. DOI: 10.3748/wjg.v22.i29.6663

- [84] Almpanis Z, Demonakou M, Tiniakos D. Evaluation of liver fibrosis: "Something old, something new...". *Annals of Gastroenterology: Quarterly Publication of the Hellenic Society of Gastroenterology*. 2016;**29**:445–453. DOI: 10.20524/aog.2016.0046
- [85] Sarin SK, Kumar M, Lau GK, Abbas Z, Chan HL, Chen CJ, et al. Asian-Pacific clinical practice guidelines on the management of hepatitis B: A 2015 update. *Hepatology International*. 2016;**10**:1–98. DOI: 10.1007/s12072-015-9675-4
- [86] EASL-ALEH Clinical Practice Guidelines: Non-invasive tests for evaluation of liver disease severity and prognosis. *Journal of Hepatology*. 2015;**63**:237–264. DOI: 10.1016/j.jhep.2015.04.006
- [87] Tonami N, Nakajima K, Hisada K, Tanaka N, Kobayashi K. A noninvasive method for evaluating portal circulation by administration of Ti-201 per rectum. *Journal of Nuclear Medicine: Official Publication, Society of Nuclear Medicine*. 1982;**23**:965–972
- [88] Bradley-Moore PR, Lebowitz E, Greene MW, Atkins HL, Ansari AN. Thallium-201 for medical use. II: Biologic behavior. *Journal of Nuclear Medicine: Official Publication, Society of Nuclear Medicine*. 1975;**16**:156–160
- [89] Urbain D, Muls V, Makhoul E, Ham HR. Prognostic value of thallium-201 per rectum scintigraphy in alcoholic cirrhosis. *Journal of Nuclear Medicine: Official Publication, Society of Nuclear Medicine*. 1994;**35**:832–834
- [90] Lee MH, Tae HJ, Jun DW, Ryu SE, Choi YY, Kwak MJ, et al. 201Tl heart-liver radioactivity uptake ratio and prediction of decompensation in patients with cirrhosis. *Clinical Nuclear Medicine*. 2013;**38**:169–174. DOI: 10.1097/RLU.0b013e31827087e3
- [91] Park MS, Lee MH, Park YS, Kim SH, Kwak MJ, Kang JS. Abnormal gas diffusing capacity and portosystemic shunt in patients with chronic liver disease. *Gastroenterology Research*. 2012;**5**:182–189. DOI: 10.4021/gr475e
- [92] Sebastiani G, Castera L, Halfon P, Pol S, Mangia A, Di Marco V, et al. The impact of liver disease aetiology and the stages of hepatic fibrosis on the performance of non-invasive fibrosis biomarkers: An international study of 2411 cases. *Alimentary Pharmacology & Therapeutics*. 2011;**34**:1202–1216. DOI: 10.1111/j.1365-2036.2011.04861.x
- [93] Naveau S, Raynard B, Ratziau V, Abella A, Imbert-Bismut F, Messous D, et al. Biomarkers for the prediction of liver fibrosis in patients with chronic alcoholic liver disease. *Clinical Gastroenterology and Hepatology: The Official Clinical Practice Journal of the American Gastroenterological Association*. 2005;**3**:167–174
- [94] Naveau S, Gaude G, Asnacios A, Agostini H, Abella A, Barri-Ova N, et al. Diagnostic and prognostic values of noninvasive biomarkers of fibrosis in patients with alcoholic liver disease. *Hepatology (Baltimore, Md)*. 2009;**49**:97–105. DOI: 10.1002/hep.22576
- [95] Adams LA, George J, Bugianesi E, Rossi E, De Boer WB, van der Poorten D, et al. Complex non-invasive fibrosis models are more accurate than simple models in non-

- alcoholic fatty liver disease. *Journal of Gastroenterology and Hepatology*. 2011;**26**:1536–1543. DOI: 10.1111/j.1440-1746.2011.06774.x
- [96] Guha IN, Parkes J, Roderick PR, Harris S, Rosenberg WM. Non-invasive markers associated with liver fibrosis in non-alcoholic fatty liver disease. *Gut*. 2006;**55**:1650–1660. DOI: 10.1136/gut.2006.091454
- [97] Lee KS, Hwang SH, Hahm JS, Rhee JC, Kee CS, Park KN, et al. Clinical significance of ICG–Rmax and thallium–201 test per rectum in chronic liver disease. *Korean Journal of Medicine (구대한내과학회지)*. 1994;**46**:19–26
- [98] Park GT, Jeon DW, Yoo YJ, Choi CS, Jung JW, Kim JB, et al. Correlation analysis and clinical significance of various noninvasive examinations to determine the progression of chronic liver disease. *The Korean Journal of Gastroenterology*. 1999;**33**:799–807
- [99] Castera L. Invasive and non-invasive methods for the assessment of fibrosis and disease progression in chronic liver disease. *Best Practice & Research Clinical Gastroenterology*. 2011;**25**:291–303. DOI: 10.1016/j.bpg.2011.02.003
- [100] Song SW. Using the receiver operating characteristic (ROC) curve to measure sensitivity and specificity. *Korean Journal of Family Medicine*. 2009;**30**:841–842
- [101] Mehta SH, Lau B, Afdhal NH, Thomas DL. Exceeding the limits of liver histology markers. *Journal of Hepatology*. 2009;**50**:36–41. DOI: 10.1016/j.jhep.2008.07.039
- [102] Friedrich-Rust M, Ong MF, Martens S, Sarrazin C, Bojunga J, Zeuzem S, et al. Performance of transient elastography for the staging of liver fibrosis: A meta-analysis. *Gastroenterology*. 2008;**134**:960–974. DOI: 10.1053/j.gastro.2008.01.034
- [103] Poynard T, Halfon P, Castera L, Charlotte F, Le Bail B, Munteanu M, et al. Variability of the area under the receiver operating characteristic curves in the diagnostic evaluation of liver fibrosis markers: Impact of biopsy length and fragmentation. *Alimentary Pharmacology & Therapeutics*. 2007;**25**:733–739. DOI: 10.1111/j.1365-2036.2007.03252.x
- [104] Poynard T, Halfon P, Castera L, Munteanu M, Imbert-Bismut F, Ratziu V, et al. Standardization of ROC curve areas for diagnostic evaluation of liver fibrosis markers based on prevalences of fibrosis stages. *Clinical Chemistry*. 2007;**53**:1615–1622. DOI: 10.1373/clinchem.2007.085795
- [105] Lambert J, Halfon P, Penaranda G, Bedossa P, Cacoub P, Carrat F. How to measure the diagnostic accuracy of noninvasive liver fibrosis indices: The area under the ROC curve revisited. *Clinical Chemistry*. 2008;**54**:1372–1378. DOI: 10.1373/clinchem.2007.097923
- [106] Obuchowski NA. An ROC-type measure of diagnostic accuracy when the gold standard is continuous-scale. *Statistics in Medicine*. 2006;**25**:481–493. DOI: 10.1002/sim.2228
- [107] Papastergiou V, Tsochatzis E, Burroughs AK. Non-invasive assessment of liver fibrosis. *Annals of Gastroenterology: Quarterly Publication of the Hellenic Society of Gastroenterology*. 2012;**25**:218–231

- [108] Afdhal NH, Nunes D. Evaluation of liver fibrosis: A concise review. *The American Journal of Gastroenterology*. 2004;**99**:1160–1174. DOI: 10.1111/j.1572-0241.2004.30110.x
- [109] Castera L, Vergniol J, Foucher J, Le Bail B, Chanteloup E, Haaser M, et al. Prospective comparison of transient elastography, Fibrotest, APRI, and liver biopsy for the assessment of fibrosis in chronic hepatitis C. *Gastroenterology*. 2005;**128**:343–350
- [110] McGary CT, Raja RH, Weigel PH. Endocytosis of hyaluronic acid by rat liver endothelial cells. Evidence for receptor recycling. *The Biochemical Journal*. 1989;**257**:875–884
- [111] Gibson PR, Fraser JR, Brown TJ, Finch CF, Jones PA, Colman JC, et al. Hemodynamic and liver function predictors of serum hyaluronan in alcoholic liver disease. *Hepatology (Baltimore, Md)*. 1992;**15**:1054–1059
- [112] McHutchison JG, Blatt LM, de Medina M, Craig JR, Conrad A, Schiff ER, et al. Measurement of serum hyaluronic acid in patients with chronic hepatitis C and its relationship to liver histology. Consensus Interferon Study Group. *Journal of Gastroenterology and Hepatology*. 2000;**15**:945–951
- [113] Pares A, Deulofeu R, Gimenez A, Caballeria L, Bruguera M, Caballeria J, et al. Serum hyaluronate reflects hepatic fibrogenesis in alcoholic liver disease and is useful as a marker of fibrosis. *Hepatology (Baltimore, Md)*. 1996;**24**:1399–1403
- [114] Curry M, Nezam H. Noninvasive assessment of hepatic fibrosis: Overview of serologic and radiographic tests. UpToDate com. 2016. Available from: <https://www.uptodate.com/contents/noninvasive-assessment-of-hepatic-fibrosis-overview-of-serologic-and-radiographic-tests>. [Accessed: 23 January, 2017]
- [115] Ramadori G, Zohrens G, Manns M, Rieder H, Dienes HP, Hess G, et al. Serum hyaluronate and type III procollagen aminoterminal propeptide concentration in chronic liver disease. Relationship to cirrhosis and disease activity. *European Journal of Clinical Investigation*. 1991;**21**:323–330
- [116] Niemela O, Risteli J, Blake JE, Risteli L, Compton KV, Orrego H. Markers of fibrogenesis and basement membrane formation in alcoholic liver disease. Relation to severity, presence of hepatitis, and alcohol intake. *Gastroenterology*. 1990;**98**:1612–1619
- [117] Pilette C, Rousselet MC, Bedossa P, Chappard D, Oberti F, Rifflet H, et al. Histopathological evaluation of liver fibrosis: Quantitative image analysis vs semi-quantitative scores. Comparison with serum markers. *Journal of Hepatology*. 1998;**28**:439–446
- [118] Leroy V, De Traversay C, Barnoud R, Hartmann JD, Baud M, Ouzan D, et al. Changes in histological lesions and serum fibrogenesis markers in chronic hepatitis C patients non-responders to interferon alpha. *Journal of Hepatology*. 2001;**35**:120–126
- [119] Giustina G, Fattovich G, De Paoli M, Guido M, Favarato S, Rugge M, et al. Serum procollagen type III peptide in chronic hepatitis B. Relationship to disease activity and response to interferon-alpha therapy. *International Journal of Clinical & Laboratory Research*. 1996;**26**:33–36

- [120] Yamada M, Fukuda Y, Nakano I, Katano Y, Takamatsu J, Hayakawa T. Serum hyaluronan as a marker of liver fibrosis in hemophiliacs with hepatitis C virus-associated chronic liver disease. *Acta Haematologica*. 1998;**99**:212–216. DOI: 40841
- [121] Korner T, Kropf J, Gressner AM. Serum laminin and hyaluronan in liver cirrhosis: markers of progression with high prognostic value. *Journal of Hepatology*. 1996;**25**:684–688
- [122] Nojgaard C, Johansen JS, Christensen E, Skovgaard LT, Price PA, Becker U. Serum levels of YKL-40 and PIIINP as prognostic markers in patients with alcoholic liver disease. *Journal of Hepatology*. 2003;**39**:179–186
- [123] Anderson FH, Zeng L, Rock NR, Yoshida EM. An assessment of the clinical utility of serum ALT and AST in chronic hepatitis C. *Hepatology Research: The Official Journal of the Japan Society of Hepatology*. 2000;**18**:63–71
- [124] Imperiale TF, Said AT, Cummings OW, Born LJ. Need for validation of clinical decision aids: use of the AST/ALT ratio in predicting cirrhosis in chronic hepatitis C. *The American Journal of Gastroenterology*. 2000;**95**:2328–2332. DOI: 10.1111/j.1572-0241.2000.02322.x
- [125] Sheth SG, Flamm SL, Gordon FD, Chopra S. AST/ALT ratio predicts cirrhosis in patients with chronic hepatitis C virus infection. *The American Journal of Gastroenterology*. 1998;**93**:44–48. DOI: 10.1111/j.1572-0241.1998.044_c.x
- [126] Croquet V, Vuillemin E, Ternisien C, Pilette C, Oberti F, Gallois Y, et al. Prothrombin index is an indirect marker of severe liver fibrosis. *European Journal of Gastroenterology & Hepatology*. 2002;**14**:1133–1141
- [127] Poynard T, Aubert A, Bedossa P, Abella A, Naveau S, Paraf F, et al. A simple biological index for detection of alcoholic liver disease in drinkers. *Gastroenterology*. 1991;**100**:1397–1402
- [128] Naveau S, Poynard T, Benattar C, Bedossa P, Chaput JC. Alpha-2-macroglobulin and hepatic fibrosis. Diagnostic interest. *Digestive Diseases and Sciences*. 1994;**39**:2426–2432
- [129] Teare JP, Sherman D, Greenfield SM, Simpson J, Bray G, Catterall AP, et al. Comparison of serum procollagen III peptide concentrations and PGA index for assessment of hepatic fibrosis. *Lancet (London, England)*. 1993;**342**:895–898
- [130] Takyar V, Surana P, Kleiner DE, Wilkins K, Hoofnagle JH, Liang TJ, et al. Noninvasive markers for staging fibrosis in chronic delta hepatitis. *Alimentary Pharmacology & Therapeutics*. 2017;**45**:127–138. DOI: 10.1111/apt.13834
- [131] Wai CT, Greenson JK, Fontana RJ, Kalbfleisch JD, Marrero JA, Conjeevaram HS, et al. A simple noninvasive index can predict both significant fibrosis and cirrhosis in patients with chronic hepatitis C. *Hepatology (Baltimore, Md)*. 2003;**38**:518–526. DOI: 10.1053/jhep.2003.50346

- [132] Loeza-del-Castillo A, Paz-Pineda F, Oviedo-Cardenas E, Sanchez-Avila F, Vargas-Vorackova F. AST to platelet ratio index (APRI) for the noninvasive evaluation of liver fibrosis. *Annals of Hepatology*. 2008;**7**:350–357
- [133] Park GJ, Lin BP, Ngu MC, Jones DB, Katelaris PH. Aspartate aminotransferase: Alanine aminotransferase ratio in chronic hepatitis C infection: Is it a useful predictor of cirrhosis? *Journal of Gastroenterology and Hepatology*. 2000;**15**:386–390
- [134] Angulo P, Keach JC, Batts KP, Lindor KD. Independent predictors of liver fibrosis in patients with nonalcoholic steatohepatitis. *Hepatology (Baltimore, Md)*. 1999;**30**:1356–1362. DOI: 10.1002/hep.510300604
- [135] Pohl A, Behling C, Oliver D, Kilani M, Monson P, Hassanein T. Serum aminotransferase levels and platelet counts as predictors of degree of fibrosis in chronic hepatitis C virus infection. *The American Journal of Gastroenterology*. 2001;**96**:3142–3146. DOI: 10.1111/j.1572-0241.2001.05268.x
- [136] Oberti F, Valsesia E, Pilette C, Rousselet MC, Bedossa P, Aube C, et al. Noninvasive diagnosis of hepatic fibrosis or cirrhosis. *Gastroenterology*. 1997;**113**:1609–1616
- [137] Imbert-Bismut F, Ratziu V, Pieroni L, Charlotte F, Benhamou Y, Poynard T. Biochemical markers of liver fibrosis in patients with hepatitis C virus infection: A prospective study. *Lancet (London, England)*. 2001;**357**:1069–1075. DOI: 10.1016/s0140-6736(00)04258-6
- [138] Poynard T, Imbert-Bismut F, Munteanu M, Messous D, Myers RP, Thabut D, et al. Overview of the diagnostic value of biochemical markers of liver fibrosis (FibroTest, HCV FibroSure) and necrosis (ActiTest) in patients with chronic hepatitis C. *Comparative Hepatology*. 2004;**3**:8. DOI: 10.1186/1476-5926-3-8
- [139] Rossi E, Adams L, Prins A, Bulsara M, de Boer B, Garas G, et al. Validation of the FibroTest biochemical markers score in assessing liver fibrosis in hepatitis C patients. *Clinical Chemistry*. 2003;**49**:450–454
- [140] Sebastiani G, Vario A, Guido M, Alberti A. Sequential algorithms combining non-invasive markers and biopsy for the assessment of liver fibrosis in chronic hepatitis B. *World Journal of Gastroenterology*. 2007;**13**:525–531
- [141] Poynard T, Zoulim F, Ratziu V, Degos F, Imbert-Bismut F, Deny P, et al. Longitudinal assessment of histology surrogate markers (FibroTest-ActiTest) during lamivudine therapy in patients with chronic hepatitis B infection. *The American Journal of Gastroenterology*. 2005;**100**:1970–1980. DOI: 10.1111/j.1572-0241.2005.41957.x
- [142] Myers RP, Benhamou Y, Imbert-Bismut F, Thibault V, Bochet M, Charlotte F, et al. Serum biochemical markers accurately predict liver fibrosis in HIV and hepatitis C virus co-infected patients. *AIDS (London, England)*. 2003;**17**:721–725. DOI: 10.1097/01.aids.0000050827.06065.16
- [143] Ratziu V, Massard J, Charlotte F, Messous D, Imbert-Bismut F, Bonyhay L, et al. Diagnostic value of biochemical markers (FibroTest-FibroSURE) for the prediction of liver

- fibrosis in patients with non-alcoholic fatty liver disease. *BMC Gastroenterology*. 2006;**6**:6. DOI: 10.1186/1471-230x-6-6
- [144] Varaut A, Fontaine H, Serpaggi J, Verkarre V, Vallet-Pichard A, Nalpas B, et al. Diagnostic accuracy of the fibrotest in hemodialysis and renal transplant patients with chronic hepatitis C virus. *Transplantation*. 2005;**80**:1550–1555
- [145] Poynard T, Morra R, Ingiliz P, Imbert-Bismut F, Thabut D, Messous D, et al. Assessment of liver fibrosis: Noninvasive means. *Saudi Journal of Gastroenterology: Official Journal of the Saudi Gastroenterology Association*. 2008;**14**:163–173. DOI: 10.4103/1319-3767.43273
- [146] Leroy V, Hilleret MN, Sturm N, Trocme C, Renversez JC, Faure P, et al. Prospective comparison of six non-invasive scores for the diagnosis of liver fibrosis in chronic hepatitis C. *Journal of Hepatology*. 2007;**46**:775–782. DOI: 10.1016/j.jhep.2006.12.013
- [147] Adams LA, Bulsara M, Rossi E, DeBoer B, Speers D, George J, et al. Hepascore: An accurate validated predictor of liver fibrosis in chronic hepatitis C infection. *Clinical Chemistry*. 2005;**51**:1867–1873. DOI: 10.1373/clinchem.2005.048389
- [148] Patel K, Gordon SC, Jacobson I, Hezode C, Oh E, Smith KM, et al. Evaluation of a panel of non-invasive serum markers to differentiate mild from moderate-to-advanced liver fibrosis in chronic hepatitis C patients. *Journal of Hepatology*. 2004;**41**:935–942. DOI: 10.1016/j.jhep.2004.08.008
- [149] Cales P, Oberti F, Michalak S, Hubert-Fouchard I, Rousselet MC, Konate A, et al. A novel panel of blood markers to assess the degree of liver fibrosis. *Hepatology (Baltimore, Md)*. 2005;**42**:1373–1381. DOI: 10.1002/hep.20935
- [150] Fontana RJ, Kleiner DE, Bilonick R, Terrault N, Afdhal N, Belle SH, et al. Modeling hepatic fibrosis in African American and Caucasian American patients with chronic hepatitis C virus infection. *Hepatology (Baltimore, Md)*. 2006;**44**:925–935. DOI: 10.1002/hep.21335
- [151] Callewaert N, Van Vlierberghe H, Van Hecke A, Laroy W, Delanghe J, Contreras R. Noninvasive diagnosis of liver cirrhosis using DNA sequencer-based total serum protein glycomics. *Nature Medicine*. 2004;**10**:429–434
- [152] Sud A, Hui JM, Farrell GC, Bandara P, Kench JG, Fung C, et al. Improved prediction of fibrosis in chronic hepatitis C using measures of insulin resistance in a probability index. *Hepatology (Baltimore, Md)*. 2004;**39**:1239–1247. DOI: 10.1002/hep.20207
- [153] Islam S, Antonsson L, Westin J, Lagging M. Cirrhosis in hepatitis C virus-infected patients can be excluded using an index of standard biochemical serum markers. *Scandinavian Journal of Gastroenterology*. 2005;**40**:867–872. DOI: 10.1080/00365520510015674
- [154] Forns X, Ampurdanes S, Llovet JM, Aponte J, Quinto L, Martinez-Bauer E, et al. Identification of chronic hepatitis C patients without hepatic fibrosis by a simple predictive model. *Hepatology (Baltimore, Md)*. 2002;**36**:986–992. DOI: 10.1053/jhep.2002.36128

- [155] Rosenberg WM, Voelker M, Thiel R, Becka M, Burt A, Schuppan D, et al. Serum markers detect the presence of liver fibrosis: A cohort study. *Gastroenterology*. 2004;**127**:1704–1713
- [156] Ratziu V, Giral P, Charlotte F, Bruckert E, Thibault V, Theodorou I, et al. Liver fibrosis in overweight patients. *Gastroenterology*. 2000;**118**:1117–1123
- [157] Harrison SA, Oliver D, Arnold HL, Gogia S, Neuschwander-Tetri BA. Development and validation of a simple NAFLD clinical scoring system for identifying patients without advanced disease. *Gut*. 2008;**57**:1441–1447. DOI: 10.1136/gut.2007.146019
- [158] Angulo P, Hui JM, Marchesini G, Bugianesi E, George J, Farrell GC, et al. The NAFLD fibrosis score: A noninvasive system that identifies liver fibrosis in patients with NAFLD. *Hepatology (Baltimore, Md)*. 2007;**45**:846–854. DOI: 10.1002/hep.21496
- [159] Shah AG, Lydecker A, Murray K, Tetri BN, Contos MJ, Sanyal AJ. Comparison of noninvasive markers of fibrosis in patients with nonalcoholic fatty liver disease. *Clinical Gastroenterology and Hepatology: The Official Clinical Practice Journal of the American Gastroenterological Association*. 2009;**7**:1104–1112. DOI: 10.1016/j.cgh.2009.05.033
- [160] Dyson JK, McPherson S, Anstee QM. Non-alcoholic fatty liver disease: Non-invasive investigation and risk stratification. *Journal of Clinical Pathology*. 2013;**66**:1033–1045. DOI: 10.1136/jclinpath-2013-201620
- [161] Sebastiani G, Vario A, Guido M, Noventa F, Plebani M, Pistis R, et al. Stepwise combination algorithms of non-invasive markers to diagnose significant fibrosis in chronic hepatitis C. *Journal of Hepatology*. 2006;**44**:686–693. DOI: 10.1016/j.jhep.2006.01.007
- [162] Bourliere M, Penaranda G, Renou C, Botta-Fridlund D, Tran A, Portal I, et al. Validation and comparison of indexes for fibrosis and cirrhosis prediction in chronic hepatitis C patients: Proposal for a pragmatic approach classification without liver biopsies. *Journal of Viral Hepatitis*. 2006;**13**:659–670. DOI: 10.1111/j.1365-2893.2006.00736.x
- [163] Thabut D, Simon M, Myers RP, Messous D, Thibault V, Imbert-Bismut F, et al. Noninvasive prediction of fibrosis in patients with chronic hepatitis C. *Hepatology (Baltimore, Md)*. 2003;**37**:1220–1221; author reply 1. DOI: 10.1053/jhep.2003.50109
- [164] Poniachik J, Bernstein DE, Reddy KR, Jeffers LJ, Coelho-Little ME, Civantos F, et al. The role of laparoscopy in the diagnosis of cirrhosis. *Gastrointestinal Endoscopy*. 1996;**43**:568–571
- [165] Gebo KA, Herlong HF, Torbenson MS, Jenckes MW, Chander G, Ghanem KG, et al. Role of liver biopsy in management of chronic hepatitis C: A systematic review. *Hepatology (Baltimore, Md)*. 2002;**36**
- [166] Lackner C, Struber G, Liegl B, Leibl S, Ofner P, Bankuti C, et al. Comparison and validation of simple noninvasive tests for prediction of fibrosis in chronic hepatitis C. *Hepatology (Baltimore, Md)*. 2005;**41**:1376–1382. DOI: 10.1002/hep.20717

- [167] Le Calvez S, Thabut D, Messous D, Munteanu M, Ratziu V, Imbert-Bismut F, et al. The predictive value of Fibrotest vs. APRI for the diagnosis of fibrosis in chronic hepatitis C. *Hepatology* (Baltimore, Md). 2004;**39**:862–863; author reply 3. DOI: 10.1002/hep.20099
- [168] Fraser JR, Gibson PR. Mechanisms by which food intake elevates circulating levels of hyaluronan in humans. *Journal of Internal Medicine*. 2005;**258**:460–466. DOI: 10.1111/j.1365-2796.2005.01564.x
- [169] Yamada N, Uzuki M, Rikimaru A, Sakurai M, Sawai T. Increased levels of circulating hyaluronate in the sera of patients with rheumatoid arthritis with special reference to joint destruction. *Ryumachi [Rheumatism]*. 1994;**34**:752–760
- [170] Piton A, Poynard T, Imbert-Bismut F, Khalil L, Delattre J, Pelissier E, et al. Factors associated with serum alanine transaminase activity in healthy subjects: Consequences for the definition of normal values, for selection of blood donors, and for patients with chronic hepatitis C. MULTIVIRC Group. *Hepatology* (Baltimore, Md). 1998;**27**:1213–1219. DOI: 10.1002/hep.510270505
- [171] Poynard T, Munteanu M, Imbert-Bismut F, Charlotte F, Thabut D, Le Calvez S, et al. Prospective analysis of discordant results between biochemical markers and biopsy in patients with chronic hepatitis C. *Clinical Chemistry*. 2004;**50**:1344–1355. DOI: 10.1373/clinchem.2004.032227
- [172] Sebastiani G, Alberti A. Non invasive fibrosis biomarkers reduce but not substitute the need for liver biopsy. *World Journal of Gastroenterology*. 2006;**12**:3682–3694
- [173] Sebastiani G, Halfon P, Castera L, Pol S, Thomas DL, Mangia A, et al. SAFE biopsy: A validated method for large-scale staging of liver fibrosis in chronic hepatitis C. *Hepatology* (Baltimore, Md). 2009;**49**:1821–1827. DOI: 10.1002/hep.22859
- [174] Castera L, Sebastiani G, Le Bail B, de Ledinghen V, Couzigou P, Alberti A. Prospective comparison of two algorithms combining non-invasive methods for staging liver fibrosis in chronic hepatitis C. *Journal of Hepatology*. 2010;**52**:191–198. DOI: 10.1016/j.jhep.2009.11.008
- [175] Tsochatzis EA, Gurusamy KS, Ntaoula S, Cholongitas E, Davidson BR, Burroughs AK. Elastography for the diagnosis of severity of fibrosis in chronic liver disease: A meta-analysis of diagnostic accuracy. *Journal of Hepatology*. 2011;**54**:650–659. DOI: 10.1016/j.jhep.2010.07.033
- [176] Talwalkar JA, Kurtz DM, Schoenleber SJ, West CP, Montori VM. Ultrasound-based transient elastography for the detection of hepatic fibrosis: Systematic review and meta-analysis. *Clinical Gastroenterology and Hepatology: The Official Clinical Practice Journal of the American Gastroenterological Association*. 2007;**5**:1214–1220. DOI: 10.1016/j.cgh.2007.07.020
- [177] Chin JL, Farrelly A, Chan G, Norris S, McCormick PA. Liver stiffness changes during meal times. *Hepatology* (Baltimore, Md). 2014;**60**:432. DOI: 10.1002/hep.26922

- [178] Tsochatzis EA, Burroughs AK. Liver stiffness measurements increase after meal ingestion—An important step towards standardization. *Annals of Hepatology*. 2013;**12**:839–840
- [179] Coco B, Oliveri F, Maina AM, Ciccorossi P, Sacco R, Colombatto P, et al. Transient elastography: A new surrogate marker of liver fibrosis influenced by major changes of transaminases. *Journal of Viral Hepatitis*. 2007;**14**:360–369. DOI: 10.1111/j.1365-2893.2006.00811.x
- [180] Gomez-Dominguez E, Mendoza J, Rubio S, Moreno-Monteaagudo JA, Garcia-Buey L, Moreno-Otero R. Transient elastography: A valid alternative to biopsy in patients with chronic liver disease. *Alimentary Pharmacology & Therapeutics*. 2006;**24**:513–518. DOI: 10.1111/j.1365-2036.2006.02999.x
- [181] Ziol M, Handra-Luca A, Kettaneh A, Christidis C, Mal F, Kazemi F, et al. Noninvasive assessment of liver fibrosis by measurement of stiffness in patients with chronic hepatitis C. *Hepatology (Baltimore, Md)*. 2005;**41**:48–54. DOI: 10.1002/hep.20506
- [182] Takeda T, Yasuda T, Nakayama Y, Nakaya M, Kimura M, Yamashita M, et al. Usefulness of noninvasive transient elastography for assessment of liver fibrosis stage in chronic hepatitis C. *World Journal of Gastroenterology*. 2006;**12**:7768–7773
- [183] Ganne-Carrie N, Ziol M, de Ledinghen V, Douvin C, Marcellin P, Castera L, et al. Accuracy of liver stiffness measurement for the diagnosis of cirrhosis in patients with chronic liver diseases. *Hepatology (Baltimore, Md)*. 2006;**44**:1511–1517. DOI: 10.1002/hep.21420
- [184] Vergara S, Macias J, Rivero A, Gutierrez-Valencia A, Gonzalez-Serrano M, Merino D, et al. The use of transient elastometry for assessing liver fibrosis in patients with HIV and hepatitis C virus coinfection. *Clinical Infectious Diseases: An Official Publication of the Infectious Diseases Society of America*. 2007;**45**:969–974. DOI: 10.1086/521857
- [185] Friedrich-Rust M, Ong MF, Herrmann E, Dries V, Samaras P, Zeuzem S, et al. Real-time elastography for noninvasive assessment of liver fibrosis in chronic viral hepatitis. *American Journal of Roentgenology*. 2007;**188**:758–764. DOI: 10.2214/ajr.06.0322
- [186] Arena U, Vizzutti F, Abraldes JG, Corti G, Stasi C, Moscarella S, et al. Reliability of transient elastography for the diagnosis of advanced fibrosis in chronic hepatitis C. *Gut*. 2008;**57**:1288–1293. DOI: 10.1136/gut.2008.149708
- [187] Wong GL, Wong VW, Choi PC, Chan AW, Chum RH, Chan HK, et al. Assessment of fibrosis by transient elastography compared with liver biopsy and morphometry in chronic liver diseases. *Clinical Gastroenterology and Hepatology: The Official Clinical Practice Journal of the American Gastroenterological Association*. 2008;**6**:1027–1035. DOI: 10.1016/j.cgh.2008.02.038
- [188] Chang PE, Lui HF, Chau YP, Lim KH, Yap WM, Tan CK, et al. Prospective evaluation of transient elastography for the diagnosis of hepatic fibrosis in Asians: Comparison with

- liver biopsy and aspartate transaminase platelet ratio index. *Alimentary Pharmacology & Therapeutics*. 2008;**28**:51–61. DOI: 10.1111/j.1365-2036.2008.03711.x
- [189] Sharma P, Dhawan S, Bansal R, Tyagi P, Bansal N, Singla V, et al. Usefulness of transient elastography by FibroScan for the evaluation of liver fibrosis. *Indian journal of Gastroenterology: Official Journal of the Indian Society of Gastroenterology*. 2014;**33**:445-51. DOI: 10.1007/s12664-014-0491-x
- [190] Lupsor M, Badea R, Stefanescu H, Grigorescu M, Sparchez Z, Serban A, et al. Analysis of histopathological changes that influence liver stiffness in chronic hepatitis C. Results from a cohort of 324 patients. *Journal of Gastrointestinal and Liver Diseases*. 2008;**17**:155–163
- [191] Castera L. Noninvasive methods to assess liver disease in patients with hepatitis B or C. *Gastroenterology*. 2012;**142**:1293–1302. e4
- [192] Marcellin P, Ziol M, Bedossa P, Douvin C, Poupon R, de Ledinghen V, et al. Non-invasive assessment of liver fibrosis by stiffness measurement in patients with chronic hepatitis B. *Liver International: Official Journal of the International Association for the Study of the Liver*. 2009;**29**:242–247. DOI: 10.1111/j.1478-3231.2008.01802.x
- [193] Degos F, Perez P, Roche B, Mahmoudi A, Asselineau J, Voitot H, et al. Diagnostic accuracy of FibroScan and comparison to liver fibrosis biomarkers in chronic viral hepatitis: A multicenter prospective study (the FIBROSTIC study). *Journal of Hepatology*. 2010;**53**:1013–1021. DOI: 10.1016/j.jhep.2010.05.035
- [194] Huwart L, Sempoux C, Vicaut E, Salameh N, Annet L, Danse E, et al. Magnetic resonance elastography for the noninvasive staging of liver fibrosis. *Gastroenterology*. 2008;**135**:32–40. DOI: 10.1053/j.gastro.2008.03.076
- [195] Rouviere O, Yin M, Dresner MA, Rossman PJ, Burgart LJ, Fidler JL, et al. MR elastography of the liver: Preliminary results. *Radiology*. 2006;**240**:440–448. DOI: 10.1148/radiol.2402050606
- [196] Huwart L, Peeters F, Sinkus R, Annet L, Salameh N, ter Beek LC, et al. Liver fibrosis: Non-invasive assessment with MR elastography. *NMR in Biomedicine*. 2006;**19**:173–179. DOI: 10.1002/nbm.1030
- [197] Huwart L, Sempoux C, Salameh N, Jamart J, Annet L, Sinkus R, et al. Liver fibrosis: noninvasive assessment with MR elastography versus aspartate aminotransferase-to-platelet ratio index. *Radiology*. 2007;**245**:458–66. DOI: 10.1148/radiol.2452061673
- [198] Shi Y, Guo Q, Xia F, Dzyubak B, Glaser KJ, Li Q, et al. MR elastography for the assessment of hepatic fibrosis in patients with chronic hepatitis B infection: Does histologic necroinflammation influence the measurement of hepatic stiffness? *Radiology*. 2014;**273**:88–98. DOI: 10.1148/radiol.14132592
- [199] Wu W-P, Chou C-T, Chen R-C, Lee C-W, Lee K-W, Wu H-K. Non-invasive evaluation of hepatic fibrosis: The diagnostic performance of magnetic resonance elastography in patients with viral hepatitis B or C. *PLoS One*. 2015;**10**:e0140068

- [200] Yin M, Talwalkar JA, Glaser KJ, Venkatesh SK, Chen J, Manduca A, et al. Dynamic postprandial hepatic stiffness augmentation assessed with MR elastography in patients with chronic liver disease. *American Journal of Roentgenology*. 2011;**197**:64–70. DOI: 10.2214/ajr.10.5989
- [201] Lupsor M, Badea R, Stefanescu H, Sparchez Z, Branda H, Serban A, et al. Performance of a new elastographic method (ARFI technology) compared to unidimensional transient elastography in the noninvasive assessment of chronic hepatitis C. Preliminary results. *Journal of Gastrointestinal and Liver Diseases: JGLD*. 2009;**18**:303–310
- [202] Zhai L, Palmeri ML, Bouchard RR, Nightingale RW, Nightingale KR. An integrated indenter-ARFI imaging system for tissue stiffness quantification. *Ultrasonic Imaging*. 2008;**30**:95–111
- [203] Wong G. Transient elastography: Kill two birds with one stone. *World Journal of Hepatology*. 2013;**5**:264–274
- [204] Giuseppetti GM, Martegani A, Di Cioccio B, Baldassarre S. Elastasonography in the diagnosis of the nodular breast lesions: Preliminary report. *La Radiologia Medica*. 2005;**110**:69–76
- [205] Konig K, Scheipers U, Pesavento A, Lorenz A, Ermert H, Senge T. Initial experiences with real-time elastography guided biopsies of the prostate. *The Journal of Urology*. 2005;**174**:115–117. DOI: 10.1097/01.ju.0000162043.72294.4a
- [206] Leung VY, Shen J, Wong VW, Abrigo J, Wong GL, Chim AM, et al. Quantitative elastography of liver fibrosis and spleen stiffness in chronic hepatitis B carriers: Comparison of shear-wave elastography and transient elastography with liver biopsy correlation. *Radiology*. 2013;**269**:910–918. DOI: 10.1148/radiol.13130128
- [207] Poynard T, Munteanu M, Luckina E, Perazzo H, Ngo Y, Royer L, et al. Liver fibrosis evaluation using real-time shear wave elastography: Applicability and diagnostic performance using methods without a gold standard. *Journal of Hepatology*. 2013;**58**:928–935. DOI: 10.1016/j.jhep.2012.12.021
- [208] Elkrief L, Rautou P-E, Ronot M, Lambert S, Dioguardi Burgio M, Francoz C, et al. Prospective comparison of spleen and liver stiffness by using shear-wave and transient elastography for detection of portal hypertension in cirrhosis. *Radiology*. 2014;**275**:589–598
- [209] Cassinotto C, Lapuyade B, Mouries A, Hiriart JB, Vergniol J, Gaye D, et al. Non-invasive assessment of liver fibrosis with impulse elastography: Comparison of Supersonic Shear Imaging with ARFI and FibroScan(R). *Journal of Hepatology*. 2014;**61**:550–557. DOI: 10.1016/j.jhep.2014.04.044
- [210] Ferral H, Male R, Cardiel M, Munoz L, Quiroz y Ferrari F. Cirrhosis: Diagnosis by liver surface analysis with high-frequency ultrasound. *Gastrointestinal Radiology*. 1992;**17**: 74–78. DOI: 10.1007/bf01888512

- [211] Simonovsky V. The diagnosis of cirrhosis by high resolution ultrasound of the liver surface. *The British Journal of Radiology*. 1999;**72**:29–34. DOI: 10.1259/bjr.72.853.10341686
- [212] Yamada H, Ebara M, Yamaguchi T, Okabe S, Fukuda H, Yoshikawa M, et al. A pilot approach for quantitative assessment of liver fibrosis using ultrasound: Preliminary results in 79 cases. *Journal of Hepatology*. 2006;**44**:68–75. DOI: 10.1016/j.jhep.2005.08.009
- [213] Quaia E. Microbubble ultrasound contrast agents: An update. *European Radiology*. 2007;**17**:1995–2008. DOI: 10.1007/s00330-007-0623-0
- [214] Abbattista T, Ridolfi F, Ciabattoni E, Marini F, Bendia E, Brunelli E, et al. Diagnosis of liver cirrhosis by transit-time analysis at contrast-enhanced ultrasonography. *La Radiologia Medica*. 2008;**113**:860–874. DOI: 10.1007/s11547-008-0292-3
- [215] Vyas K, Gala B, Sawant P, Das HS, Kulhalli PM, Mahajan SS. Assessment of portal hemodynamics by ultrasound color Doppler and laser Doppler velocimetry in liver cirrhosis. *Indian Journal of Gastroenterology: Official Journal of the Indian Society of Gastroenterology*. 2002;**21**:176–178
- [216] Weickert U, Buttman A, Jakobs R, Schilling D, Eickhoff A, Riemann JF. Diagnosis of liver cirrhosis: A comparison of modified ultrasound and laparoscopy in 100 consecutive patients. *Journal of Clinical Gastroenterology*. 2005;**39**:529–532
- [217] D'Arienzo A, Celentano L, Scuotto A, Di Siervi P, Lombardi V, Squame G, et al. Thallium-201 per rectum for the diagnosis of cirrhosis in patients with asymptomatic chronic hepatitis. *Hepatology (Baltimore, Md)*. 1988;**8**:785–787
- [218] Kim J-M, Lee M-H, Yun Y-S, Bae J-H, Moon W, Jun D-W, et al. Predictive factors of development and progression of esophageal varices in patients with liver cirrhosis. *Korean Journal of Medicine*. 2006;**70**:378–385

IntechOpen

