

# We are IntechOpen, the world's leading publisher of Open Access books Built by scientists, for scientists

4,800

Open access books available

122,000

International authors and editors

135M

Downloads

Our authors are among the

154

Countries delivered to

TOP 1%

most cited scientists

12.2%

Contributors from top 500 universities



WEB OF SCIENCE™

Selection of our books indexed in the Book Citation Index  
in Web of Science™ Core Collection (BKCI)

Interested in publishing with us?  
Contact [book.department@intechopen.com](mailto:book.department@intechopen.com)

Numbers displayed above are based on latest data collected.  
For more information visit [www.intechopen.com](http://www.intechopen.com)



---

# Surgical Treatment of Brachial Plexus Injury

---

Pavel Haninec and Libor Mencil

Additional information is available at the end of the chapter

<http://dx.doi.org/10.5772/intechopen.68442>

---

## Abstract

In recent years, brachial plexus injury has been attracting increasing attention, partly because of an increasing incidence arising out of higher survival rates for patients after polytrauma. Brachial plexus injury is one of the hardest and most mutilating injuries. Owing to advances in microsurgical techniques, we can achieve success in restoring motor function for these patients. The purpose of this chapter is to introduce the reader with various microsurgical techniques, including nerve fascicle transfers and end-to-side neurorrhaphy (ETSN), which can be used for brachial plexus reconstruction based on personal experience with 1130 nerve reconstructions performed by the first author (PH) between 1993 and 2017. Another goal of brachial plexus surgery is the resolution of severe intractable pain which can develop in up to 20% of cases. Dorsal root entry zone (DREZ) thermocoagulation is a very effective method for treatment of severe neuropathic pain.

**Keywords:** brachial plexus surgery, neurotization, fascicular transfer, end-to-side neurorrhaphy, obstetrical brachial plexus palsy, root avulsion, DREZ thermocoagulation

---

## 1. Introduction

Recently, brachial plexus injury has been attracting increasing attention, partly because of an increasing incidence arising from higher survival rates in patients after polytrauma. The purpose of this chapter is to introduce the reader with various microsurgical techniques which can be used for brachial plexus reconstruction based on personal experience with over than 990 nerve reconstructions performed by the first author (PH) between 1993 and 2017.

Being one of the hardest and most mutilating injuries, the main goals of brachial plexus injury surgeries are the restoration of movement in the affected segments of the upper extremity and the resolution of pain. Owing to advances in microsurgical techniques, we can achieve success

---

in restoring motor function in 60–80% patients [1, 2]. There is an absence of publications dealing with the epidemiology of brachial plexus injury. Midha described 54 cases of brachial plexus injury in 4538 patients after polytrauma (1.2%), while the total number of brachial plexus injuries in patients after winter sports injuries and motorcycle collisions was much higher, 4.8 and 4.2%, respectively [3]. The majority of injuries are upper brachial plexus palsies (72%), followed by complete lesions (26%). Lower plexus palsies were present only in 2% of the cases [4].

There are two main types and mechanisms of brachial plexus injury. The first is the traction injury, which results in the avulsion of cervical roots and the other is direct injury to the trunks, cords, and nerves of the brachial plexus [5]. The timing of surgery remains controversial mainly because of a lack of large randomized clinical trials of this specific surgical procedure. In cases of open injury, immediate neurosurgical revision is recommended within 72 h. Neurosurgical revision of closed brachial plexus injury in 3–6 months is acceptable, if there is no useful spontaneous reinnervation [1]. Treatment of patients with avulsion of cervical roots is especially difficult, since direct reconstruction is impossible and the results of reimplantation of avulsed roots are thoroughly controversial and have been presented in only a small number of cases [6].

## 2. Preoperative examination

Precise assessment of preoperative neurological status is highly recommended. Muscle strength in each our patient was graded, using the Medical Research Council scale: grade 0, no contraction; grade 1, flicker or trace contraction; grade 2, active movement with gravity eliminated; grade 3, active movement against gravity; grade 4, active movement against resistance; and grade 5, normal strength [7]. Sensory function was evaluated in the distribution area of the roots and peripheral nerves. Attention was paid to the presence of Tinel's sign or Horner's syndrome and detailed evaluation of pain. Clinical assessment was extended by radiological and electrophysiological examination. All the patients had undergone preoperative electromyography examination by means of needle concentric electrode and nerve conduction examinations. In addition to performing electromyography assessment of muscles innervated by the nerves of the brachial plexus, we focused on evaluation of muscles innervated by possible donors for the neurotization procedures [8]. The donors can be divided into two groups. The group of extraplexal donors which are not part of the brachial plexus: the accessory nerve (upper part of the trapezius) and motor branches of the C-4 spinal nerve (levator scapulae). And the group of intraplexal donors, direct branches of the brachial plexus: the thoracodorsal nerve (latissimus dorsi), the long thoracic nerve (serratus anterior), and the pectoral nerves (pectoralis major). Somatosensory evoked potentials were recorded in order to help distinguish the different levels of brachial plexus injury. Computed tomography myelography was considered to be the technique of choice for diagnostic root avulsions with a reported overall diagnostic accuracy of 85% [9]. This is an invasive, yet safe procedure, completed without any serious complications in all our patients. This examination is able to detect not only the presence of pseudocysts but also partial root avulsion in the absence of a rupture of the enveloping meninges [10]. RTG retinoscopy or ultrasonography is routinely used for evaluation of diaphragm function.

### 3. Operative techniques

#### 3.1. Direct repair procedures

Surgery is performed under general anesthesia without the use of muscle-blocking agents. Once the plexus is exposed through anterior supraclavicular, infraclavicular, or combined approach, a visual assessment of the presence, location, and extent of the neuroma takes place. Further operation technique is selected based on preoperative knowledge of the presence of avulsions and selective electrical stimulation of all involved nerve portions. The nerve action potential recording is carried out with the aim of demonstrating the presence or the absence of regenerating myelinated fibers through the site of the lesion. Direct bipolar electrical stimulation and visual evaluation of the muscle contraction is performed as well. In cases in which visual evidence of contraction was in doubt, intraoperative electromyography evaluation of motor response was carried out using concentric needle electrodes. If a sufficient muscle response after intraoperative electrical stimulation proximal to the neuroma is present, then only neurolysis is performed. If there is no useful response to electrical stimulation, the neuroma tissue is resected in a stepwise manner. The preferred option is direct coaptation between available proximal and distal nerve stumps. If this is not possible, nerve grafts are harvested and used across the gap. In most cases sural nerves are harvested from one or both legs and then used as grafts. Removal of these nerves does not produce any severe deficits in the legs. After the nerves have been harvested, there can be a slight loss of sensation in the lateral part of the foot, which tends to diminish progressively with time. Another option is to use medial or less frequently lateral antebrachial cutaneous nerve or free vascularized non-critical injured nerve as a graft [11]. The overall success rate of direct repair was 79% in our previously presented study, with the average period leading to the first signs of reinnervation measured by EMG evaluation being 12 months [1].

#### 3.2. Nerve transfers

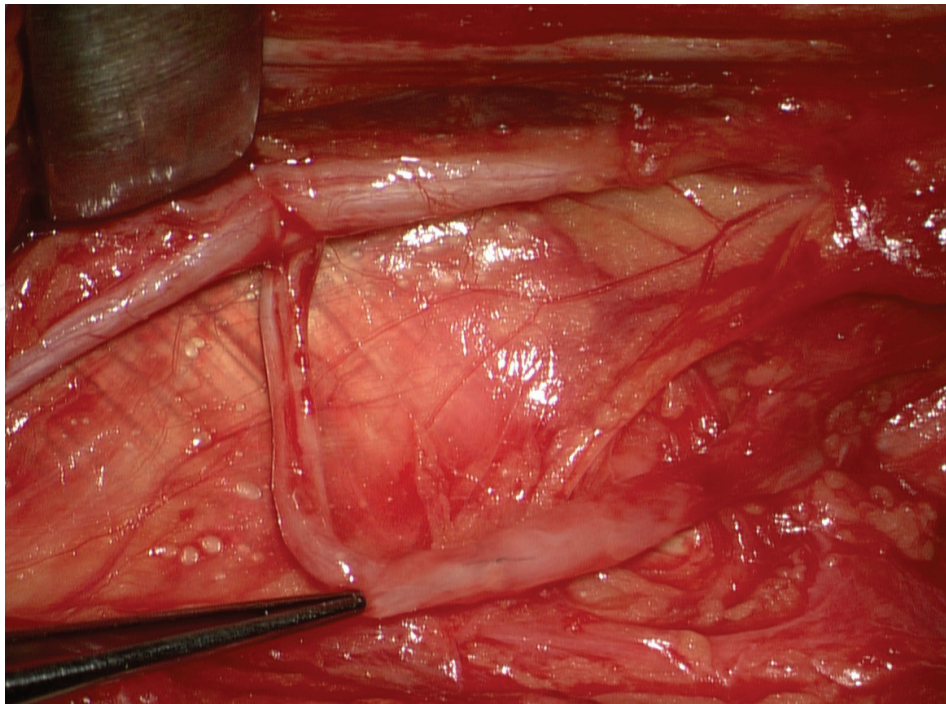
Nerve transfer (neurotization) is a method using the transfer of a functional but less important donor nerve to a nonfunctional, more important recipient nerve in cases of cervical root avulsions or intractable proximal brachial plexus injury. The choice of donor nerves for neurotization remains a controversial topic in peripheral nerve surgery mainly because of a lack of large randomized clinical trials of this specific surgical procedure [12]. In general, there are two categories of donor nerves for neurotization. The use of extraplexal nerves such as an accessory nerve, motor branches of the cervical plexus, intercostal nerves, or the phrenic nerve, is the only option for patients with complete avulsion of cervical roots forming a brachial plexus. The use of intraplexal nerves as donors of motor fibers, such as the thoracodorsal nerve, the long thoracic nerve, and the pectoral nerves leads to more favorable results than the use of extraplexal donors [1]. The time interval between injury and surgery can influence surgical outcome [13]. The suprascapular nerve, the crucial nerve in shoulder abduction and external rotation, arises from the C-5 and C-6 roots and rarely from C-4 [14]. The incidence of C-4 nerve participation in the brachial plexus, as well as of the suprascapular nerve, differs between 18 and 62.8% among studies. In such cases, shoulder abduction may be stronger,

especially at the beginning of the motion [15]. The suprascapular nerve is reconstructed from one of the roots or separately with the spinal accessory nerve as donor. We preserved the proximal branches to the trapezius muscle in all cases. The success rate of this procedure is 80–90%, and it is generally accepted that simultaneous neurotization of the suprascapular and axillary nerves offers better overall shoulder function [16]. In axillary nerve reconstruction, good results have been obtained using the: (1) thoracodorsal nerves (86%), (2) intercostal nerves (33–67%), (3) phrenic nerve (66%), (4) spinal accessory nerve (60%), (5) C-5 and/or C-6 root via nerve grafts (67%), or (6) the contralateral C-7 root (52%) as the donor of motor nerve fibers. [1, 2, 16–19]. Best results can be achieved in cases with a preserved proximal stump of the axillary nerve that can be reconstructed via end-to-end suturing using a short nerve graft [16]. When other donor nerves were not available, especially in total brachial plexus palsies, recently we have been using the long thoracic nerve (from C-4 to C-7). The disadvantage of this method rests with the risk of scapular instability [16]. The method of choice in axillary nerve reconstruction is, in our opinion, neurotization by using the thoracodorsal nerve, which has an 86% success rate [1]. The thoracodorsal nerve arises from C5–7 and is often available in injuries of the upper plexus [14]. So far, numerous methods of musculocutaneous nerve neurotization have been defined. Successful reinnervation with this technique has been obtained using: (1) the medial pectoral nerve (84–91%), (2) the intercostal nerves (44–70%), (3) phrenic nerve (66%), and (4) spinal accessory nerve (50–88%) as donor nerves [1, 20]. The intercostal nerves may be destructed in patients with rib fractures. In such cases, the intercostal nerves cannot be used for neurotization. We do not use the phrenic nerve as a donor because its use may result in poor outcomes and increased risk of diaphragmatic impairment [1]. Methods of successful reinnervation of radial nerve have been described using: (1) branch of the median nerve 91.7%, (2) from the dorsal cord (93–100%) [1, 11]. The least successful results were achieved after the reconstructions of the ulnar and median nerves. A long distance to the motor point of the reinnervated muscle and a long reinnervation time are the reasons for poor results [1, 21].

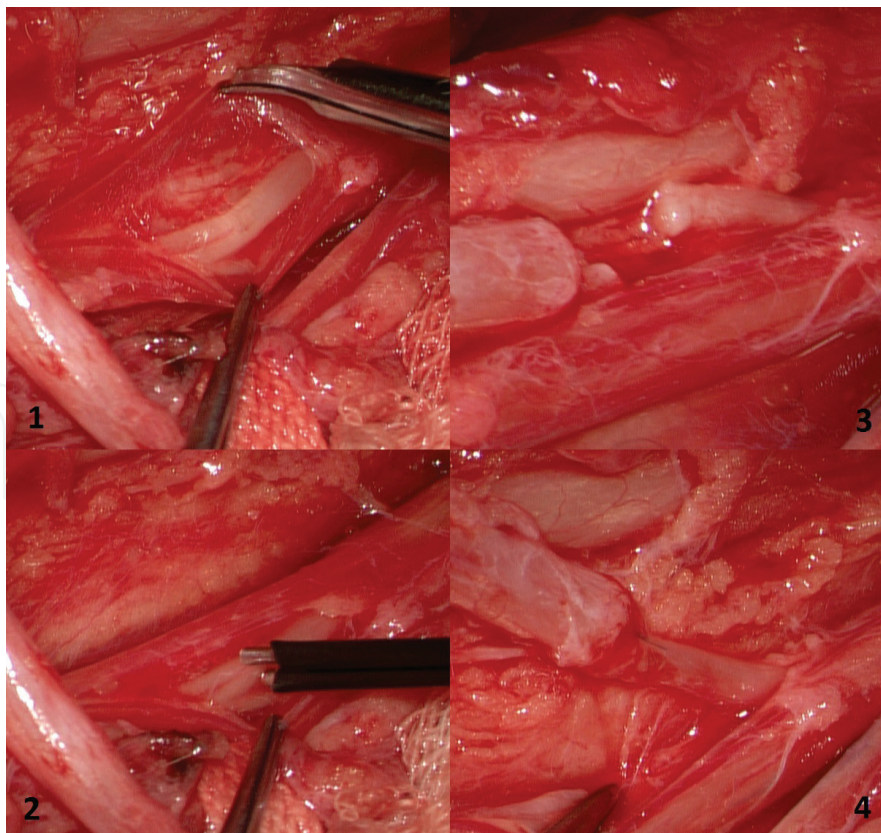
### 3.3. Fascicular transfer

Recently, new promising ways of neurotization using only a part of the donor nerve have been published. Transfer of the triceps motor branches of the radial nerve to the axillary nerve was performed to restore deltoid muscle function and appears to be safe and effective (**Figure 1**). The functional loss relative to the triceps, with a single nerve transferred, is negligible because of compensation by the remaining heads [22]. Oberlin introduced a neurotization technique in which an ulnar nerve fascicle is transferred to the branch of the musculocutaneous nerve for biceps muscle, thus reanimating flexion of elbow in patients with upper brachial plexus injuries without significant motor or sensory deficits of the donor nerve [23]. This technique can only be performed in patients in whom the lower brachial plexus is intact, as the ulnar nerve is formed from the C-8 and T-1 roots [14]. The Oberlin technique is now routinely used to reinnervate the biceps muscle and restore elbow flexion in cases of upper brachial plexus palsy (**Figure 2**). In 2001, Songcharoen described an alternative technique using a median nerve fascicle to repair the musculocutaneous nerve and restore biceps muscle function [18]. Based on these findings, we performed this neurotization technique on a group of 17 patients with median age 34 years (SD = 12.7, range 17–58), the median time between trauma and





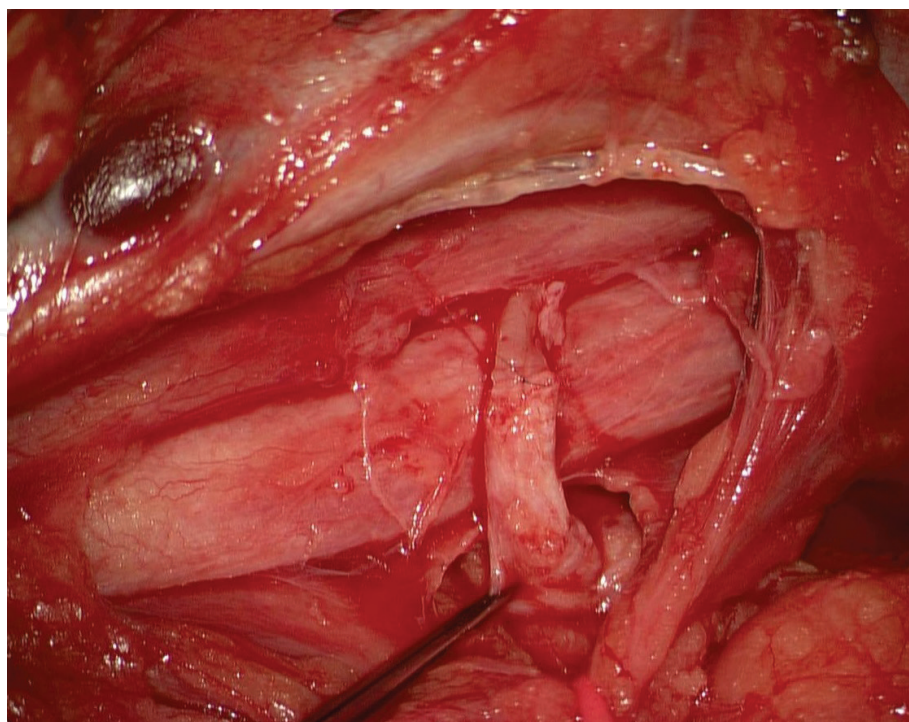
**Figure 1.** Transfer of the triceps motor branches of the radial nerve to the axillary nerve.



**Figure 2.** Fascicular transfer to the musculocutaneous nerve. (1) Epineurotomy of ulnar nerve; (2) detection of fascicle with direct bipolar electrical stimulation; (3) preparation; (4) direct coaptation.

surgery was 6 months (SD = 2.7, range 2–13). This method produces outstanding results, with success rates between 90 and 100% when the donor is the ulnar nerve and 64–80% when the donor is the median nerve. The major benefit of this technique is the option to create a distal suture close to the target muscle [18, 24, 25]. However, we do not use this particular method in musculocutaneous nerve reconstruction because we have had very positive experiences using the pectoral nerves for neurotization of this nerve [20].

In 2007, Haninec published the effectiveness of motor fascicle transfer in axillary nerve reconstruction using one or two fascicles from the ulnar or median nerve [12]. Between 2007 and 2017, the first author performed this operation in a subset of 24 patients. The median age of these patients was 29 years (SD = 13.4, range 18–61). The median time between trauma and reconstructive surgery was 5 months (SD = 2.4, range 2–13). The axillary nerve was divided 3 cm above the foramen of Velpeau and dorsal to the subscapular vessels. The fascicle of the ulnar nerve for flexor carpi ulnaris muscle was carefully selected using electrical stimulation of the proximal part of the arm. The localization of this fascicle was verified after epineurotomy through observation of the reaction of the corresponding muscle to direct bipolar electrical stimulation. In the case of the absence of muscle activity in the flexor carpi ulnaris muscle, the fascicle of the median nerve for the flexor carpi radialis muscle can be used same way. The distal portion of the axillary nerve was transferred ventrally from the subscapular vessels and medially from the radial nerve and sutured to prepared fascicle of the ulnar or median nerve (**Figure 3**). The success rate for the whole group of patients was 78.6% [12]. None of the patients lost motor function in the hand. Only two of the patients evaluated in the present study had



**Figure 3.** Ulnar fascicle transfer to the axillary nerve. The axillary nerve was transected 3 cm cranial to foramen of Velpeau and dorsal to the subscapular vessels.



a partial short-term sensory loss following the surgery. This is in concordance with the previously reported data [18, 24, 25]. The advantages of the fascicular transfer techniques include reduced regeneration distance, faster reinnervation because the nerve repair can be performed much closer to the neuromuscular junction, and also lower level of invasiveness and the fact that the nerve transfer is performed on nontraumatized tissue distal to the site of injury [12].

### 3.4. End-to-side neurorrhaphy

In cases when commonly used donor nerves are not available or when there is a high risk of transection of the donor nerve fascicle, end-to-side neurorrhaphy (ETSN) could be used for nerve repair in brachial plexus reconstructive surgery. This situation is expected in patients with combined supra- and infraclavicular brachial plexus injuries resulting in impaired hand functions. Advantage of ETSN over end-to-end neurotization is that with ETSN there is no need to sacrifice the surrounding nerves or their fascicles [20]. End-to-side neurorrhaphy was rediscovered in the early 1990s [26]. This technique is based on the regeneration of an injured recipient nerve through collateral sprouting of axons, one of the most important manifestations of neuroplasticity of an intact donor nerve and has been the subject of many theoretical and experimental studies [27–29]. Haninec et al. evaluated results of ETSN on a group of patients with an upper brachial injury for axillary or musculocutaneous nerve reconstruction [20]. The patients cohort consisted of 23 patients, the median age of the patients was 25 years (SD = 14.0, range 12–63), and the median time between trauma and surgery was 5 months (SD = 2.0, range 2–9). Twelve patients had cervical roots C5–6 avulsed, 11 patients had cervical roots C5–7 avulsed. The ETSN was performed through a perineurial suture of the axillary or musculocutaneous nerve onto the side of the ulnar, median, or radial nerve after the creation of a perineurial window. The success of the ETSN was achieved in 10 out of the 23 patients, corresponding to an overall rate of success of 43.5%. The choice of donor nerve (ulnar or median) did not affect the success rate. The precise site on the donor nerve where ETSN is to be performed is chosen by direct bipolar electrical stimulation and registration in the corresponding muscle. It can be found on the surface of the donor nerve from which the maximum amplitude of motor response is evoked [20]. A perineurial suture is performed after the creation of a perineurial window. This method is our standard technique because studies with experimental models have indicated that the success rate of such sutures is high [30]. In experimental models, there were no signs of denervation of the donor nerve after creation of a perineurial window [30, 31]. Similarly, none of the patients in our series had any sensory or motor loss in the innervation zone of the donor nerve. The existence of collateral sprouting of axons is well documented. Some authors' experimental studies have demonstrated that the terminolateral nerve repair can be used without a surgical incision into the donor nerve's perineurium or epineurium [32]. These methods do not seem applicable in brachial plexus surgery because only a few collateral branches grow from the mixed donor nerve with a rather thick perineurium into the mixed recipient nerve and these collateral branches are very thin. In our previous study, we observed that a perineurial suture is the only possible way to achieve effective reinnervation in nerves with large diameters such as those found in the brachial plexus [28]. Successful ETSN takes place via collateral sprouting of intact axons and also through direct growth of some injured axons into the recipient nerve. Without the contribution of the



injured axons, the outcome of ESTN would be very poor, since only about 1.4% of motor neurons with intact axons can send out collateral branches. In addition, only a limited number of motor neurons have the capacity to send out collateral sprouts from intact axons [31]. Several experimental studies have suggested that sensory reinnervation is superior to motor reinnervation after ETSN. The explanation for better sensory reinnervation after ETSN may lie in the higher total number of sensory fibers than the number of motor fibers contributing to the reinnervation [32]. However, our previous results showed that motor and sensory neurons have a similar ability to send out collateral sprouts from their axons in rats with a perineurial window [28]. On the basis of our results, we recommend the use of ETSN only in cases when commonly used donor nerves are not available. Advantage of ETSN over end-to-end neurotization is that with ETSN there is no need to sacrifice the surrounding nerves or their fascicles. One possible method of getting better results in the future may be the use of neurotrophics to strengthen the reinnervation process [31].

#### 4. Obstetrical brachial plexus injury

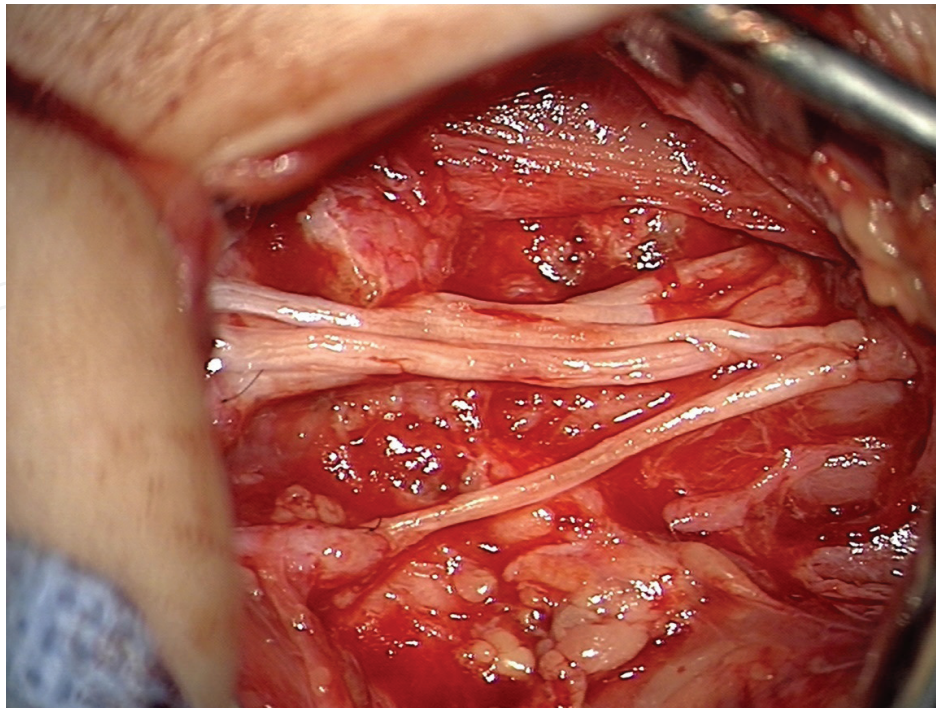
Obstetrical brachial plexus injury (OBPI) is caused by excessive lateral traction to the infants' head during delivery, although cases of OBPI injury after nontraumatic caesarean sections have also been described, and so perinatal brachial plexus injury would be an alternative nomenclature. Obstetrical brachial plexus palsy displays a stable incidence of 0.15–3 per 1000 live births [33]. Shoulder dystocia, macrosomia, and instrument delivery, forceps or vacuum extraction, present the greatest risk for brachial plexus injury. Caesarean section and having a twin or multiple birth mates seem to offer some protection against injury [33, 34]. Most children show good spontaneous recovery, but a recent literature review showed that a residual deficit remains in 20–30% of children [35]. The final nerve injury may vary from neurapraxia, axonotmesis, neurotmesis to cervical root avulsion from the spinal cord. Axonotmetic injuries with intact basal lamina tubes allow for axons to grow from the lesion site down into the basal lamina tube to the target muscle. Complete recovery will usually occur within the weeks or months. A more severe traction lesion results in a neurotmetic injury with a rupture of the basal lamina tubes; outgrowth of axons is blocked and does not end in appropriate endoneurial tube. The consequence is formation of neuroma in continuity, a mass of outgrowing axons and scar tissue. However, even in the most severe cases, some axons will pass through and reach some tubes distal to the injury site [36]. Axons that successfully pass the neuroma in continuity are likely to end up in a different basal lamina tube from the original. This process is called misrouting and may cause the phenomenon of cocontraction [37]. Root avulsion, the most severe type of lesion, is a total disconnection between peripheral nervous system and the spinal cord. When roots are avulsed, the outgrowth of axons, neuroma formation or misrouting cannot take place. Most often, brachial plexus injuries are associated with the upper trunk, when the limb is typically held in internal rotation and pronation, with the elbow extended (roots C5–C6 ± C7, 73–86%) or complete plexus injury (roots C5–Th1, 15–20%). Isolated lower brachial plexus injury also known as Klumpke's paralysis, involving the roots of C8–Th1, does occur, but is very rare, with a frequency of only 0.16%. It is suggested that these injuries originate from complete

plexus palsy with recovery of the upper part of brachial plexus [36, 38, 39]. Although we perform electromyography and imaging studies, the final decision of operation relies heavily on the clinical examination. Muscle strength testing system (MRC) although reliable for examination of motor power in adults is not suited for use with non-cooperative infants. All patients involved in our study were evaluated using the Active Movement Scale (AMS), which grades 15 upper extremity movements from 0 to 7, and greatly increases the ability to detect partial movements [40]. The results of neurophysiological investigations in older patients are mostly accurate, indicating the severity, location and extent of the lesions. In contrast, the findings of EMG and nerve-conduction studies in obstetrical brachial plexus palsy mostly suggest a falsely optimistic prognosis [41].

Between 2000 and 2016, 185 patients with obstetrical brachial plexus injury were examined at our department, and 47 underwent nerve surgery. The patient cohort consisted of 27 males and 20 females, with the right side was involved in 28 cases (59.6%). The delivery was aided with forceps or a vacuum extractor in seven cases. One case after Caesarean section was present. The patients were divided into two groups for better analysis. Group 1 involved 23 patients with upper brachial plexus birth injuries. The limb was typically held in internal rotation and pronation, with the elbow extended. An additional lack of elbow, wrist and finger extension was present in the case of root C7 involved. The median birth weight was 3840 g (range 2240–4600 g), AMS score 65 (range 15–94), clavicle fractures were present in 13% and the median Apgar score was 7–8–9. Group 2 consisted of 24 patients with complete paralysis; the upper limb was flailing, without any tonus and without hand function. The median birth weight was 4080 g (range 2550–5200 g), AMS score 3.5 (range 0–30), clavicle fractures were present in 29% and the median Apgar score was 5–8–9. Computed tomography myelography was performed for diagnostic root avulsions. Seventy-one roots were found to be avulsed (C5, 8.5%; C6, 21.1%; C7, 23.9%; C8, 25.4%; T1, 21.1%). In most cases, the lower roots were affected; avulsion of all five roots was not seen.

Although the indication and timing of surgery remains controversial among authors [38, 42, 43], we recommend surgery in cases of total palsy with impaired hand function within the first 3 months. In cases of upper brachial plexus injuries, surgery is acceptable within the first 4 months if there is no useful elbow flexion. Operation strategy is based on preoperative knowledge of the presence of avulsions and selective intraoperative electrical stimulation of all involved nerve portions. A supraclavicular incision is sufficient for access to all roots and trunks of the brachial plexus in most cases. Infraclavicular or combined approaches are used in the case of distal nerve transfer. Neuroma resection and nerve grafting was the most frequently used technique. Nerve transfer or fascicular transfer was performed in standard manner. When the number of proximal stumps was limited in the case of root avulsion, a reconstruction of the entire brachial plexus from a single root stump was performed (**Figure 4**) [44].

The surgical objective in cases of upper OBPI is functional restoration of shoulder abduction with external rotation and biceps function. Our series reached the overall success rate 80% for shoulder abduction, 50% for external rotation and 81.8% for elbow flexion with median follow-ups of 36 months. The results of global shoulder recovery and elbow flexion [36, 38, 44, 45]. In contrast, the results with regard to external rotation are poor [46]. No difference in



**Figure 4.** Neurotization following neuroma resection performed from C5 and C6 root stumps to suprascapular nerve and superior, medius, and inferior trunk with sural nerves used as grafts. C7-Th1 roots avulsed.

final external rotation was found between patients who underwent nerve grafting from the proximal stump of C5 and patients who underwent spinal accessory nerve transfer [47]. In cases of conducting neuroma, Lin et al. documented the superiority of long-term functional results following excision and grafting compared to neurolysis [48]. Reanimation of the shoulder and elbow can also be performed with nerve transfers. The use of pectoral nerve to musculocutaneous nerve neurotization and fascicular transfer using median or ulnar nerve has been described with excellent results [36, 44]. The transfer of triceps motor branches of the radial nerve to the axillary nerve appears to be effective and safe. The functional loss relative to the triceps muscle, with a one branch transferred, is meaningless because of compensation by the remaining heads of triceps muscle [49]. The surgical objective in cases with complete OBPI is recovery of hand function and establishing the ability to use the affected hand in bimanual activities [36, 42]. Bimanual execution of daily activities requires strong finger flexion in combination with good elbow flexion [50]. Reanimation of the hand is crucial; otherwise, the maximal function attained for the affected upper extremity is as a hook [36]. Recovery of the hand is dependent on the time of surgery—the younger the patient's age, the better the outcome [51]. We achieved useful hand reanimation in 87% of cases. Shoulder abduction was successful in 87%, external rotation in 25%, elbow flexion in 75%, and supination in 25% of cases. Elbow extension was successful in 87%, wrist extension in 50% and finger, thumb extension in 37% of cases with median follow-ups of 46 months (**Figure 5**) [44]. Hand function outcomes in published reports are difficult to interpret, given the variety of evaluation scales used for assessment, thus the overall success is ranging from 69 to 93% [38]. Emphasis must be placed on reconstructing the median nerve (mainly controlled by the C8 root) for innervating extrinsic





**Figure 5.** Result 36 months after brachial plexus reconstruction presented in Figure 4 with successful reanimation of hand.

flexor muscles of the fingers and opposition of thumb rather than the ulnar nerve innervating intrinsic muscles (mainly controlled by the Th1 root). In addition, because of the long reinnervation trajectory, severe muscle atrophy can occur [36]. The use of the end-to-side technique has been abandoned by most surgeons due to insufficient results. We described two cases with surprisingly good results, which can be attributed exclusively to the ETSN technique. In both patients we decided for a perineural suture after making a perineural window [20, 44]. This result, although with only two cases presented, may be explained by the superior nerve regeneration capacity in infants compared with adults. Laboratory reports showed better results after ETSN in young rats than in older animals [52]. In cases of late obstetrical brachial plexus injury, nerve reconstruction will be ineffective, and thus secondary surgery is called for to improve the shoulder, elbow, forearm, and hand function and to stop muscle contractures and bone shortening. The procedure includes tendon transfers, free-muscle transplantation, surgical release of muscle contractures and osteotomies. Surgery should be carried out after the age of 4 years when the child is able to cooperate with rehabilitation and on condition that severe contractures are absent [44]. Our results demonstrate that improved hand function can be obtained in infants with obstetrical brachial plexus injury with early surgical reconstruction.



## 5. Painful consequences of brachial plexus injury

Pain is an early symptom in up to 70% of patients with brachial plexus injury. In up to 20% of cases, severe intractable pain develops. Pain does not appear at the time of injury, but typically several days after. Typical is persistent pain with sporadic acral irritations described by patients as cutting or burning [53]. Pathophysiology of the formation is not fully explained, but it initiates after the loss of sensory impulses from the periphery which leads to the creation of pathologic pain generator in the dorsal horn of the spinal cord, in Rexed's lamina I [54]. In 90%, the pain corresponds to the avulsion of one of the lower roots. Pharmacotherapy may give satisfactory relief. However, if conservative treatment is inadequate and pain progresses, it indicates that a central component is present. The only causal therapy in these situations is dorsal root entry zone (DREZ) thermocoagulation [55]. This technique was first described by Nashold [56]. Procedure is generally performed in semisitting position with the head fixed in three-point fixation. An incision is made vertically from external occipital protuberance to the vertebra prominens. Multilevel hemilaminectomies are performed to expose the spinal cord at the level of the nerve root avulsion. The lesions are made in dorsal root entry zone in a 2-mm depth using a radiofrequency electrode. The tip of the electrode is strictly perpendicular to the surface of the spinal cord surface. Lesioning time is 15 s and lesioning temperature 75°C [55]. The risk of this procedure involves potentially serious neurological complications. The close location of thermocoagulation site from the corticospinal tract laterally and lemniscal tract dorsomedially creates a risk of motor or sensitivity failure from the point of damage. Anatomical and functional localization of DREZ is therefore essential. Problems tend to occur in cases with the dural scarring and the presence of pseudomeningocele [57]. They can cause changes in spinal anatomical arrangement of the surface. A very useful technique in guiding the placement of the thermocoagulation lesions is a localization of the dorsal root entry zone by evoked potentials. A bipolar registration of evoked response and using very low intensity of stimulus (0.1–0.2 mA), even in spinal cord extensively encased in scar, allows obtaining a well-differentiated response without movement artifacts. The strip electrode with two active members (5 mm distance, 1 mm in diameter) is slipped under the dura at the rostral end of exposed spinal cord. Responses are amplified at a gain setting of 100 with the high frequency filter set at 5 kHz and the low frequency filter set at 20 Hz. Responses are not averaged. The stimulating electrode is a bipolar stimulating electrode with constant distance between tips of 1 mm. A 200- $\mu$ s square-wave impulse and a stimulation rate of three stimuli per second are used. Initially, the stimulating electrode is placed over the dorsal column and the intensity of the stimulus is gradually increased until an evoked potential with amplitude of approximately 30–50  $\mu$ V is elicited. The stimulus intensity is not changed during the rest of the procedure and varies from 0.1 to 0.2 mA. Dorsolateral surface of spinal cord is gradually stimulated at a constant distance from the registration electrode, in approximately 2 mm steps. Sites where the stimulation electrode failed to evoke a response are considered as a dorsal root entry zone and thermocoagulation lesion is made at that site. The stimulating technique is repeated along the axis of the spinal cord at 1 cm intervals [58]. Surgical procedures were performed by the first author between 1993 and 2016 on 61 patients. The patient cohort consisted of 56 men and 5 women with a median age of 38 years (SD = 11.4, range 20–70). Median number of

performed thermo-lesions were 29 (SD = 9.2, range 13–50). A decrease in preoperative pain intensity of more than 75% was considered a definite success. Based on our long-term follow-up (median follow-up 61 months, range 15–180), this goal was achieved in 68.4% of patients. Another 22.8% reported decrease of pain intensity between 75 and 50% and reported some pain persistence, usually in the form of dull pain or paresthesias of the affected upper limb. Overall satisfaction with the surgery was achieved in 91.2% of patients. An operative painkilling surgery is generally required in 10–15% of patients with spinal cord root avulsion [59, 60]. The incidence of complications is different for different authors, ranging from 0 to 60% [57]. Haninec et al. found in a group of 48 patients that frequency of complications was 15.4%, sensory deficits occurred in five cases (1× hemihypoesthesia of the trunk and lower limb, 4× hypoesthesia of ipsilateral lower extremity), motor leg weakness occurred in two patients and one case had a combined disability [55]. The best results have been achieved in sporadic irritations while persistent dull pain had a worse prognosis and higher tendency to recur [53, 61]. Paroxysmal pain is successfully eliminated in 91.6% while severe dull pain was treatable in 70.8% cases [55]. It has been stated that there is no correlation between the number of roots avulsed or the extent of the DREZ T procedure performed and the degree of pain reduction [60]. DREZ thermocoagulation is a very effective method for treatment of severe neuropathic pain that can develop in some patients with supraganglion brachial plexus injury. Needless to say, such delicate procedures require masterful execution.

## 6. Conclusions

Brachial plexus injury is one the hardest and most mutilating injuries. Owing to advances in microsurgical techniques, we can achieve success in restoring motor function for these patients. Direct repair and neurotization has become the mainstay for the brachial plexus surgery. The presence and following choice of donor nerves for neurotization is most important. Using only a part of the donor nerve for neurotization is a new promising technique. The advantages of the fascicular transfer include reduced regeneration distance, faster reinnervation, and lower level of invasiveness. The timing of surgery remains controversial mainly because of a lack of large randomized clinical trials of this specific surgical procedure. The use of end-to-side neurorrhaphy is recommended only in cases when commonly used donor nerves are not available. In cases of obstetrical brachial plexus injury, shoulder dystocia, macrosomia, and instrument delivery present the greatest risk. Our results demonstrate that improved hand function can be obtained in infants with early surgical reconstruction. One possible method of getting better results in the future may be the use of neurotrophics to strengthen the reinnervation process. Dealing with painful consequences of brachial plexus injury, DREZ thermocoagulation is a very effective method for the treatment of severe neuropathic pain.

## Acknowledgements

This study was supported by Charles University in Prague, Progress Q35.

## Author details

Pavel Haninec\* and Libor Mencl

\*Address all correspondence to: haninec@fnkv.cz

Department of Neurosurgery, 3rd Faculty of Medicine, Charles University, Prague, Czech Republic

## References

- [1] Haninec P, et al. Direct repair (nerve grafting), neurotization, and end-to-side neurorrhaphy in the treatment of brachial plexus injury. *Journal of Neurosurgery*. 2007;**106**(3):391–399
- [2] Kim DH, et al. Outcomes of surgery in 1019 brachial plexus lesions treated at Louisiana State University Health Sciences Center. *Journal of Neurosurgery*. 2003; **98**(5):1005–1016
- [3] Midha R. Epidemiology of brachial plexus injuries in a multitrauma population. *Neurosurgery*. 1997;**40**(6):1182–1189
- [4] Kaiser R, Mencl L, Haninec P. Injuries associated with serious brachial plexus involvement in polytrauma among patients requiring surgical repair. *Injury*. 2014; **45**(1):223–226
- [5] Kline DG, Hudson AR. *Nerve Injuries: Operative Results For Major Nerve Injuries, Entrapments, and Tumors*. Philadelphia: Saunders; 1995
- [6] Carlstedt T, et al. Spinal nerve root repair and reimplantation of avulsed ventral roots into the spinal cord after brachial plexus injury. *Journal of Neurosurgery: Spine*. 2000;**93**(2):237–247
- [7] Seddon H. *Peripheral nerve injuries*. Medical Research Council Special Report Series No. 282. London: Her Majesty's Stationary Office; 1954. pp. 1–7
- [8] Kline DG, Hackett ER, May PR. Evaluation of nerve injuries by evoked potentials and electromyography. *Journal of Neurosurgery*. 1969;**31**(2):128–136
- [9] Carvalho GA, et al. Diagnosis of root avulsions in traumatic brachial plexus injuries: Value of computerized tomography myelography and magnetic resonance imaging. *Journal of Neurosurgery*. 1997;**86**(1):69–76
- [10] Steens SC, et al. Obstetric brachial plexus lesions: CT myelography. *Radiology*. 2011;**259**(2):508–515
- [11] Davidge KM, et al. Median to radial nerve transfers for restoration of wrist, finger, and thumb extension. *The Journal of Hand Surgery*. 2013;**38**(9):1812–1827
- [12] Haninec P, Kaiser R. Axillary nerve repair by fascicle transfer from the ulnar or median nerve in upper brachial plexus palsy: Clinical article. *Journal of Neurosurgery*. 2012;**117**(3):610–614

- [13] Samii A, Carvalho GA, Samii M. Brachial plexus injury: Factors affecting functional outcome in spinal accessory nerve transfer for the restoration of elbow flexion. *Journal of Neurosurgery*. 2003;**98**(2):307–312
- [14] Bonnel F. Microscopic anatomy of the adult human brachial plexus: An anatomical and histological basis for microsurgery. *Microsurgery*. 1984;**5**(3):107–118
- [15] Shin C, et al. Spinal root origins and innervations of the suprascapular nerve. *Surgical and Radiologic Anatomy*. 2010;**32**(3):235–238
- [16] Vekris MD, et al. Shoulder reanimation in posttraumatic brachial plexus paralysis. *Injury*. 2010;**41**(3):312–318
- [17] Samardzic M, et al. Results of nerve transfers to the musculocutaneous and axillary nerves. *Neurosurgery*. 2000;**46**(1):93–103
- [18] Songcharoen P. Management of brachial plexus injury in adults. *Scandinavian Journal of Surgery*. 2008;**97**(4):317–323
- [19] Terzis JK, Kokkalis ZT. Selective contralateral C7 transfer in posttraumatic brachial plexus injuries: A report of 56 cases. *Plastic and Reconstructive Surgery*. 2009;**123**(3):927–938
- [20] Haninec P, Mencl L, Kaiser R. End-to-side neurorrhaphy in brachial plexus reconstruction: Clinical article. *Journal of Neurosurgery*. 2013;**119**(3):689–694
- [21] Spinner RJ, Kline DG. Surgery for peripheral nerve and brachial plexus injuries or other nerve lesions. *Muscle & Nerve*, 2000;**23**(5):680–695
- [22] Leechavengvongs S, et al. Nerve transfer to deltoid muscle using the nerve to the long head of the triceps, part II: A report of 7 cases. *The Journal of Hand Surgery*. 2003;**28**(4):633–638
- [23] Oberlin C, et al. Nerve transfer to biceps muscle using a part of ulnar nerve for C5–C6 avulsion of the brachial plexus: Anatomical study and report of four cases. *The Journal of Hand Surgery*. 1994;**19**(2):232–237
- [24] Nath RK, Lyons AB, Bietz G. Physiological and clinical advantages of median nerve fascicle transfer to the musculocutaneous nerve following brachial plexus root avulsion injury. *Journal of Neurosurgery*. 2006;**105**(6):830–834
- [25] Tung TH, Novak CB, Mackinnon SE. Nerve transfers to the biceps and brachialis branches to improve elbow flexion strength after brachial plexus injuries. *Journal of Neurosurgery*. 2003;**98**(2):313–318
- [26] Viterbo F, et al. End-to-side neurorrhaphy with removal of the epineurial sheath: An experimental study in rats. *Plastic and Reconstructive Surgery*. 1994;**94**(7):1038–1047
- [27] Bajrović F, et al. Interneuronal signalling is involved in induction of collateral sprouting of nociceptive axons. *Neuroscience*. 2002;**111**(3):587–596
- [28] Haninec P, Kaiser R, Dubový P. A comparison of collateral sprouting of sensory and motor axons after end-to-side neurorrhaphy with and without the perineurial window. *Plastic and Reconstructive Surgery*. 2012;**130**(3):609–614



- [29] Haninec P, et al. Enhancement of musculocutaneous nerve reinnervation after vascular endothelial growth factor (VEGF) gene therapy. *BMC Neuroscience*. 2012; **13**(1):57
- [30] Geuna S, Papalia I, Tos P. End-to-side (terminolateral) nerve regeneration: A challenge for neuroscientists coming from an intriguing nerve repair concept. *Brain Research Reviews*. 2006; **52**(2):381–388
- [31] Dubový P, et al. Ciliary neurotrophic factor promotes motor reinnervation of the musculocutaneous nerve in an experimental model of end-to-side neurorrhaphy. *BMC Neuroscience*. 2011; **12**(1):58
- [32] Pannucci C, et al. End-to-side nerve repair: Review of the literature. *Restorative Neurology and Neuroscience*. 2007; **25**(1):45–63
- [33] Foad SL, Mehlman CT, Ying J. The epidemiology of neonatal brachial plexus palsy in the United States. *Journal of Bone and Joint Surgery America*. 2008; **90**(6):1258–1264
- [34] Gilbert WM, Nesbitt TS, Danielsen B. Associated factors in 1611 cases of brachial plexus injury. *Obstetrics & Gynecology*. 1999; **93**(4):536–540
- [35] Pondaag W, et al. Natural history of obstetric brachial plexus palsy: A systematic review. *Developmental Medicine & Child Neurology*. 2004; **46**(2):138–144
- [36] Malessy MJ, Pondaag W. Nerve surgery for neonatal brachial plexus palsy. *Journal of Pediatric Rehabilitation Medicine*. 2011; **4**(2):141–148
- [37] Anguelova GV, et al. A cross-sectional study of hand sensation in adults with conservatively treated obstetric brachial plexus lesion. *Developmental Medicine & Child Neurology*. 2013; **55**(3):257–263
- [38] Gilbert A, Pivato G, Kheiralla T. Long-term results of primary repair of brachial plexus lesions in children. *Microsurgery*. 2006; **26**(4):334–342
- [39] Al-Qattan M, Clarke H, Curtis C. Klumpke's birth palsy: Does it really exist? *The Journal of Hand Surgery: British & European Volume*. 1995; **20**(1):19–23
- [40] Clarke HM, Curtis CG. An approach to obstetrical brachial plexus injuries. *Hand Clinics*. 1995; **11**(4):563–580
- [41] VAN D, et al. Needle electromyography at 1 month predicts paralysis of elbow flexion at 3 months in obstetric brachial plexus lesions. *Developmental Medicine & Child Neurology*. 2012; **54**(8):753–758
- [42] Vekris MD, et al. Management of obstetrical brachial plexus palsy with early plexus microreconstruction and late muscle transfers. *Microsurgery*. 2008; **28**(4):252–261
- [43] El-gammal TA, et al. Total obstetric brachial plexus palsy: results and strategy of microsurgical reconstruction. *Microsurgery*. 2010; **30**(3):169–178
- [44] Mencl L, Waldauf P, Haninec P. Results of nerve reconstructions in treatment of obstetrical brachial plexus injuries. *Acta Neurochirurgica*. 2015; **157**(4):673–680

- [45] Birch R, et al. Repair of obstetric brachial plexus palsy. *Bone & Joint Journal*. 2005;**87**(8): 1089–1095
- [46] Pondaag W, et al. External rotation as a result of suprascapular nerve neurotization in obstetric brachial plexus lesions. *Neurosurgery*. 2005;**57**(3):530–537
- [47] Tse R, et al. Suprascapular nerve reconstruction in obstetrical brachial plexus palsy: Spinal accessory nerve transfer versus C5 root grafting. *Plastic and Reconstructive Surgery*. 2011;**127**(6):2391–2396
- [48] Lin JC, et al. Final results of grafting versus neurolysis in obstetrical brachial plexus palsy. *Plastic and Reconstructive Surgery*. 2009;**123**(3):939–948
- [49] McRae MC, Borschel GH. Transfer of triceps motor branches of the radial nerve to the axillary nerve with or without other nerve transfers provides antigavity shoulder abduction in pediatric brachial plexus injury. *Hand*. 2012;**7**(2):186–190
- [50] Krumlinde-Sundholm L, et al. The assisting hand assessment: Current evidence of validity, reliability, and responsiveness to change. *Developmental Medicine & Child Neurology*. 2007;**49**(4):259–264
- [51] Terzis JK, Kokkalis ZT. Outcomes of hand reconstruction in obstetric brachial plexus palsy. *Plastic and Reconstructive Surgery*. 2008;**122**(2):516–526
- [52] Hess JR, et al. Influence of aging on regeneration in end-to-side neurorrhaphy. *Annals of Plastic Surgery*. 2006;**57**(2):217–222
- [53] Aichaoui F, Mertens P, Sindou M. Dorsal root entry zone lesioning for pain after brachial plexus avulsion: Results with special emphasis on differential effects on the paroxysmal versus the continuous components. A prospective study in a 29-patient consecutive series. *PAIN®*. 2011;**152**(8):1923–1930
- [54] Bertelli JA, Ghizoni MF. Concepts of nerve regeneration and repair applied to brachial plexus reconstruction. *Microsurgery*. 2006;**26**(4):230–244
- [55] Haninec P, et al. Usefulness of screening tools in the evaluation of long-term effectiveness of DREZ lesioning in the treatment of neuropathic pain after brachial plexus injury. *BMC Neurology*. 2014;**14**(1):225
- [56] Nashold Jr BS, Ostdahl RH. Dorsal root entry zone lesions for pain relief. *Journal of Neurosurgery*. 1979;**51**(1):59–69
- [57] Sindou MP, et al. Microsurgical lesioning in the dorsal root entry zone for pain due to brachial plexus avulsion: A prospective series of 55 patients. *Journal of Neurosurgery*. 2005;**102**(6):1018–1028
- [58] Tomás R, Haninec P. Dorsal root entry zone (DREZ) localization using direct spinal cord stimulation can improve results of the DREZ thermocoagulation procedure for intractable pain relief. *Pain*. 2005;**116**(1–2):159–163

- [59] Chen H, Tu Y. Long term follow-up results of dorsal root entry zone lesions for intractable pain after brachial plexus avulsion injuries. *Acta Neurochir Suppl.* 2006;**99**:73–75.
- [60] Samii M, et al. Treatment of refractory pain after brachial plexus avulsion with dorsal root entry zone lesions. *Neurosurgery.* 2001;**48**(6):1269–1277
- [61] Aly MM, et al. Importance of distinction between paroxysmal and continuous patterns of pain during evaluation of pain after brachial plexus injury. *Acta Neurochirurgica.* 2011;**153**(2):437–438

IntechOpen