

We are IntechOpen, the world's leading publisher of Open Access books Built by scientists, for scientists

4,800

Open access books available

122,000

International authors and editors

135M

Downloads

Our authors are among the

154

Countries delivered to

TOP 1%

most cited scientists

12.2%

Contributors from top 500 universities



WEB OF SCIENCE™

Selection of our books indexed in the Book Citation Index
in Web of Science™ Core Collection (BKCI)

Interested in publishing with us?
Contact book.department@intechopen.com

Numbers displayed above are based on latest data collected.
For more information visit www.intechopen.com



Usefulness of Cone Beam Computed Tomography for the Diagnosis and Treatment of Oral and Maxillofacial Pathology

Márcio Diniz-Freitas, Javier Fernández-Feijoo,
Lucía García-Caballero, Maite Abeleira,
Mercedes Outumuro, Jacobo Limeres-Pose and
Pedro Diz-Dios

Additional information is available at the end of the chapter

<http://dx.doi.org/10.5772/intechopen.68313>

Abstract

Three-dimensional (3D) evaluation of oral and maxillofacial pathology, in comparison with two-dimensional (2D) radiological studies, offers many advantages that can assist in the diagnostic and in the preoperative evaluation of certain lesions and conditions of the jaws, reducing the risk of intraoperative and postoperative complications. The introduction of cone beam computed tomography (CBCT) represents an important technological advance in the context of oral and maxillofacial radiology as it permits the acquisition of high-quality 3D images and dynamic navigation over an area of interest in real time, with a short scan time and lower dose of radiation than conventional computed tomography (CT). The initial indications for CBCT have been extended by the progressive addition of new ones such as evaluation of the extent of osteonecrotic lesions of the jaw due to bisphosphonates, preoperative staging of oral cancer, and planning reconstructive surgery. As a consequence, this radiological technique represents an interesting complement to conventional radiology in those clinical situations in which 3D imaging can facilitate diagnosis and/or treatment.

Keywords: cone beam computed tomography, oral maxillofacial radiology, oral maxillofacial pathology

1. Introduction

Radiological evaluation of the size of a lesion, its density, thickness of the adjacent bone, and distance from anatomically nearby structures can assist in the diagnostic and in the preoperative evaluation of certain lesions and conditions of the jaws, reduce the risk of intraoperative and postoperative complications, and reduce surgical stress on the surgeon [1]. However, although two-dimensional (2D) radiological studies provide relevant information, in many situations they have limitations, such as indicating the location and size of a lesion in the buccolingual plane, showing characteristics of the surface (smooth or rough), and demonstrating changes that develop over time in order to evaluate progression of the lesion. As a consequence, three-dimensional (3D) studies are valuable in order to improve the diagnosis and treatment of these lesions.

Cone beam computed tomography (CBCT), also known as digital volumetric tomography (DVT) [2], volumetric computed tomography (VCT), or cone beam three-dimensional imaging (CB3D) [3], is a relatively new technology in the field of oral and maxillofacial radiology, but it is rapidly becoming established as the radiological technique of choice in numerous clinical situations [4]. CBCT enables a large quantity of data to be acquired with a short scan time and low dose of radiation compared with conventional computed tomography (CT). CBCT uses a conical X-ray beam (in contrast to the fan beam of conventional CT) and a special detector that, depending on the technology developed by the manufacturers, may be an image intensifier tube or an amorphous silicon flat-panel detector [4]. The X-ray source and reciprocal detector rotate synchronously around the head of the patient, in a single scan. Single projection images, known as “basis” images, are acquired at predetermined degree intervals. Software programs incorporating back-filtered projection are applied to the series of base images to generate a 3D volumetric data set, creating a spherical or a cylindrical volume called the “field of view” (FOV), which can be used to provide primary reconstruction images in three orthogonal planes (axial, sagittal, and coronal) [5].

The objective of this chapter is to provide a brief review of this new technology, its advantages and disadvantages, and its possible applications in the area of oral and maxillofacial pathology.

2. Clinical applications in dentistry

One of the main indications for CBCT is to determine bone availability for implant surgery [6]. However, the usefulness of CBCT imaging of the oral and maxillofacial region is continually increasing. Particularly useful indications include the diagnosis of bone disease (including maxillofacial fractures and deformities), preoperative evaluation of dental impaction, study of the temporomandibular joint, 3D cephalometric analysis in orthodontic practice, and diagnosis and surgical simulation in orthognathic surgery and in patients with cleft palate [7].

There now follows a summary of the most important studies on the use of CBCT in oral and maxillofacial pathology.

2.1. Disorders of tooth eruption

An important clinical application of CBCT is the diagnosis and planning of treatment for tooth eruption alterations. In this field, CBCT provides multiplanar visualization of the position of the tooth and its relationship with neighboring anatomical structures, as well as the presence of associated conditions, such as cystic degeneration of the dental follicle and root reabsorption of adjacent teeth, all of which are important factors in the therapeutic decision-taking process.

2.1.1. Dental inclusions

The extraction of impacted third molars is a common procedure in dental practice. In the majority of cases, it is a simple procedure with a minimal risk of damage to adjacent structures; however, in some cases, there is an intimate relationship between the roots of the mandibular third molars and the mandibular canal or the lingual cortical plate of the mandible, making it important to evaluate the topographical relationship between the third molar and these structures (**Figure 1**). Other characteristics that must be evaluated preoperatively are

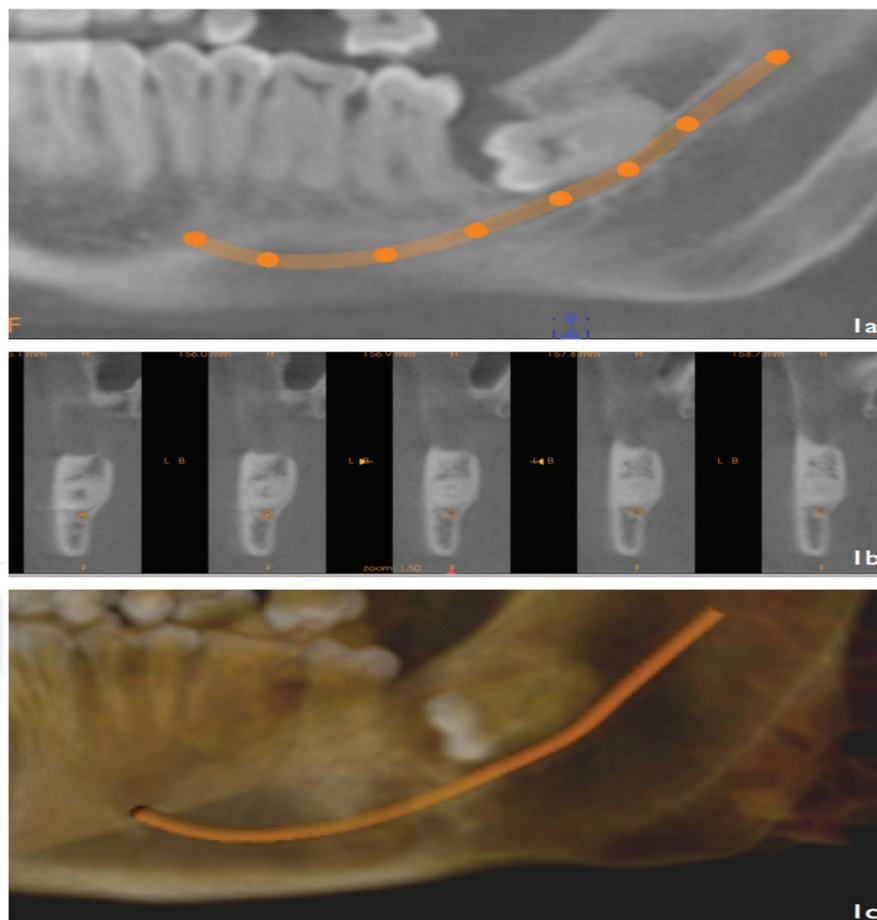


Figure 1. Inferior left third molar inclusion. (a) Detail of the panoramic reconstruction on CBCT in which the close relationship with the inferior alveolar nerve (IAN) canal (continuous line) is observed. (b) Cross-sectional images showing the three-dimensional location of the unerupted tooth and its relationship with the IAN (dark point). (c) Preoperative planning of surgical exodontia based on three-dimensional reconstruction (CS3D Imaging, CareStream, Rochester, NY).

angulation with respect to the sagittal plane, buccolingual inclination, size and shape of the crown, and the presence of local lesions. With respect to the roots of the tooth, the most important characteristic is their relationship with the mandibular canal, though it is also important to determine factors such as the number and shape of the roots and their stage of development in order to predict surgical difficulty [8, 9]. Oral and maxillofacial surgeons tend to use panoramic radiographs for evaluation of the morphology of impacted third molars and their relationship with the mandibular canal [10]. A number of radiological criteria suggestive of an intimate relationship between these two structures have been described in the literature. Sedaghatfar et al. [11] found that darkening of the root, interruption of the radiopaque lines that represent the roof and floor of the mandibular canal, divergence of the mandibular canal, and narrowing of the root on the panoramic radiograph were significantly associated with exposure of the inferior alveolar nerve after extraction of the mandibular third molars. Tantanapornkul et al. [12] found that these four criteria used independently were able to predict exposure of the nerve packet after third molars extraction, but in the multivariate analysis only interruption of the wall of the canal predicted nerve exposure. When the findings on the panoramic radiograph suggest an intimate relationship between the impacted tooth and the mandibular canal, some authors recommend complementary studies with CT or CBCT [13]. Using CBCT, Tantanapornkul et al. [12] found a sensitivity of 93% and a specificity of 77% for the prediction of inferior alveolar nerve exposure after third molar extraction, improving on the results obtained with panoramic radiographs. Exposure of the nerve correlated significantly with the presence of altered sensitivity in the postoperative follow-up. Recent studies based on images obtained by CBCT have shown that darkening of the root observed on the panoramic radiograph is more closely related with a reduction in the thickness or perforation of the lingual cortical plate than with the presence of an intimate relationship between the third molar and the mandibular canal. Thinning or perforation of the lingual cortical plate was confirmed on CBCT in 80% of cases in which darkening of the root was observed on panoramic radiograph [14]. When compared to a combination of 2D radiographs (panoramic radiography and cephalometric radiography), CBCT showed a higher detection quality of the relationship between the mandibular canal and the root tips of the third molars [15]. In addition, it has also been shown that CBCT is able to identify accessory roots and apical anomalies/curvatures not visible in the panoramic radiography [16].

Although two-dimensional imaging (panoramic and periapical radiography) is sufficient in most cases prior to the extraction of the lower third molars, CBCT may be indicated in cases where the two-dimensional image suggests one or more signs of close contact relationship between the third molar and the IDN, and if it is believed that the CBCT will change the treatment plan or the patient's prognosis [17].

With respect to the maxillary third molars, CBCT can be used to evaluate the relationship between the roots and the floor of the maxillary sinus [18] (**Figure 2**). Another advantage of CBCT in the preoperative evaluation of third molar surgery is the possibility of significantly decreasing the surgeon's level of stress in complex cases and reducing the duration of surgery.

The second most common dental impaction after the third molars is the maxillary canine, with a prevalence that varies between 1 and 2.5% [19]. Due to their functional and esthetic

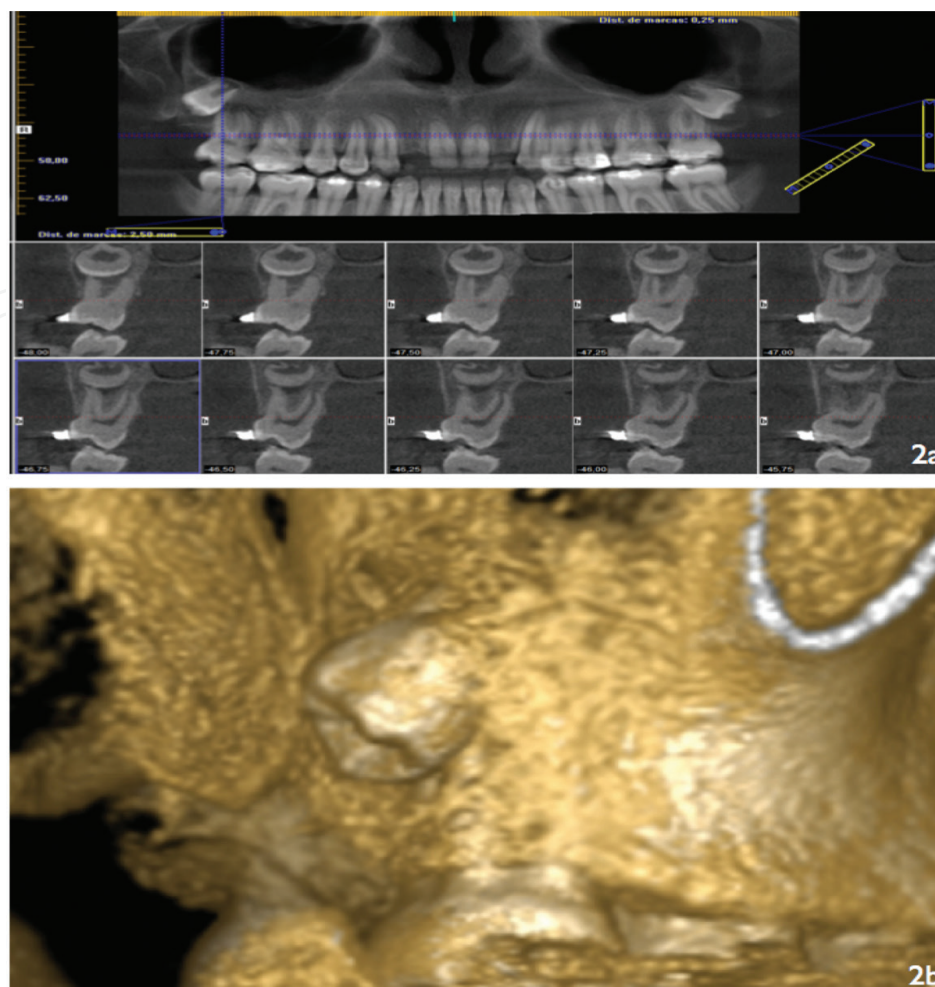


Figure 2. Third upper left molar inclusion. (a) View of the panoramic reconstruction and the cross-sectional images where an intimate relationship is observed with the roots of the second molar. (b) Preoperative planning of surgical exodontia based on three-dimensional reconstruction (I-CAT Vision, Imaging Sciences International, Hatfield, PA, USA).

relevance, the main objective in the treatment of impacted canines is their repositioning in the dental arch. Their 3D localization (**Figure 3**) is therefore important both for diagnosis and for the surgical-orthodontic management; this localization can be particularly difficult to explore with conventional radiological methods due to overlying anatomical structures [20]. CBCT can provide additional data not available with conventional 2D studies, such as the size of the follicle, the degree of inclination of the long axis of the tooth, facial-palatal position, the quantity of bone covering the tooth, the proximity and reabsorption of adjacent roots, and the stage of development of the tooth [21]. There are reports of the use of CBCT in the management of both maxillary- and mandibular-impacted canines [22]. Liu et al. [23] used CBCT to study the position and angulation of 210 impacted maxillary canines, the presence of reabsorption of the adjacent incisors, and the thickness of the dental follicle. These authors recommended complementary radiographic study using CBCT in those patients with impacted canines with marked displacement, possible reabsorption of adjacent incisors, or cystic degeneration of the dental follicle. Recently, How Kau et al. [24] proposed a new classification system—the KPG

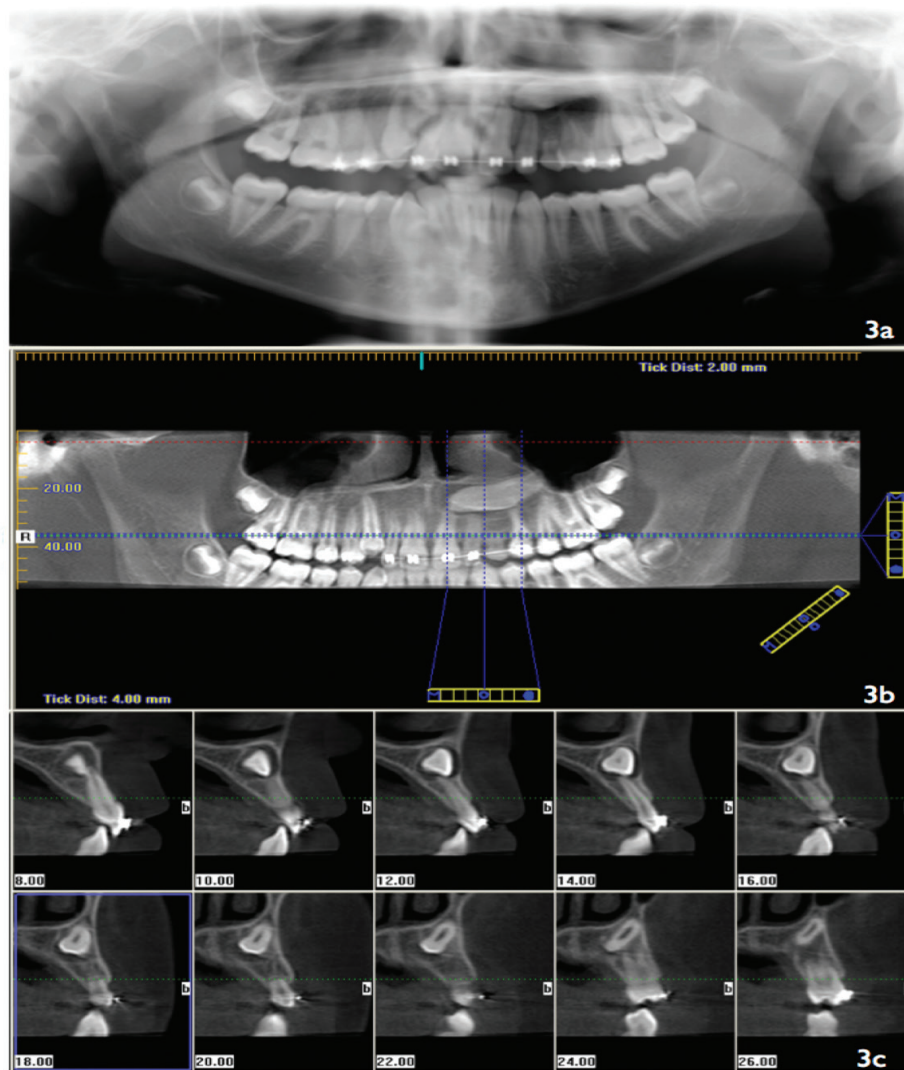


Figure 3. Left maxillary impacted canine. (a) Panoramic radiography; (b) cone beam computed tomography (CBCT) reconstruction obtained with I-CAT system (Imaging Sciences International, Hatfield, PA, USA); (c) cross-sectional images obtained with I-CAT system showing the three-dimensional location of the unerupted tooth and its relationship with adjacent anatomic structures.

index—based on the tridimensional localization of impacted canines provided by CBCT to predict the difficulty of treatment. However, this new classification system needs to be validated by prospective longitudinal studies. A recent systematic review concluded that CBCT is more accurate than conventional radiographs in localizing maxillary-impacted canine [25].

2.1.2. Supernumerary teeth

Supernumerary teeth are usually asymptomatic and are identified during routine radiological evaluation. Radiological study is useful to determine their position. Traditionally, such studies have used periapical, occlusal, and lateral skull radiographs. Periapical radiographs provide a detailed view of the anatomy of the tooth and, through the Clark's rule [26], can be used to establish the buccolingual and the palatal position of the tooth. However, these

radiographs frequently do not enable a 3D evaluation to be made of the supernumerary tooth with respect to adjacent teeth and neighboring anatomical structures (**Figure 4**); this information can be important to determine the treatment plan. Liu et al. [27] used CBCT to study 487 patients with a total of 626 supernumerary teeth; in addition, panoramic and lateral skull radiographs had been performed previously in 50 of these patients with supernumerary teeth in the anterior region, allowing comparison of the visualization of the teeth and the adjacent bone structures with the three techniques. CBCT provided visualization qualified as “excellent” in practically all cases (there were only six cases in which visualization of the apices of the incisors was qualified as “reasonable”). CBCT was superior to panoramic and lateral skull radiographs for all radiological criteria evaluated. Based on these results, the authors recommended that the evaluation of supernumerary teeth should routinely be performed by CBCT, particularly in those cases with multiple supernumerary teeth, malocclusions, or a high intramaxillary position. When extraction of supernumerary teeth is indicated, 3D localization by CBCT can help the surgeon in the choice of surgical access and identification of the tooth to be extracted, reducing trauma to the adjacent soft and hard tissues (**Figure 5**).

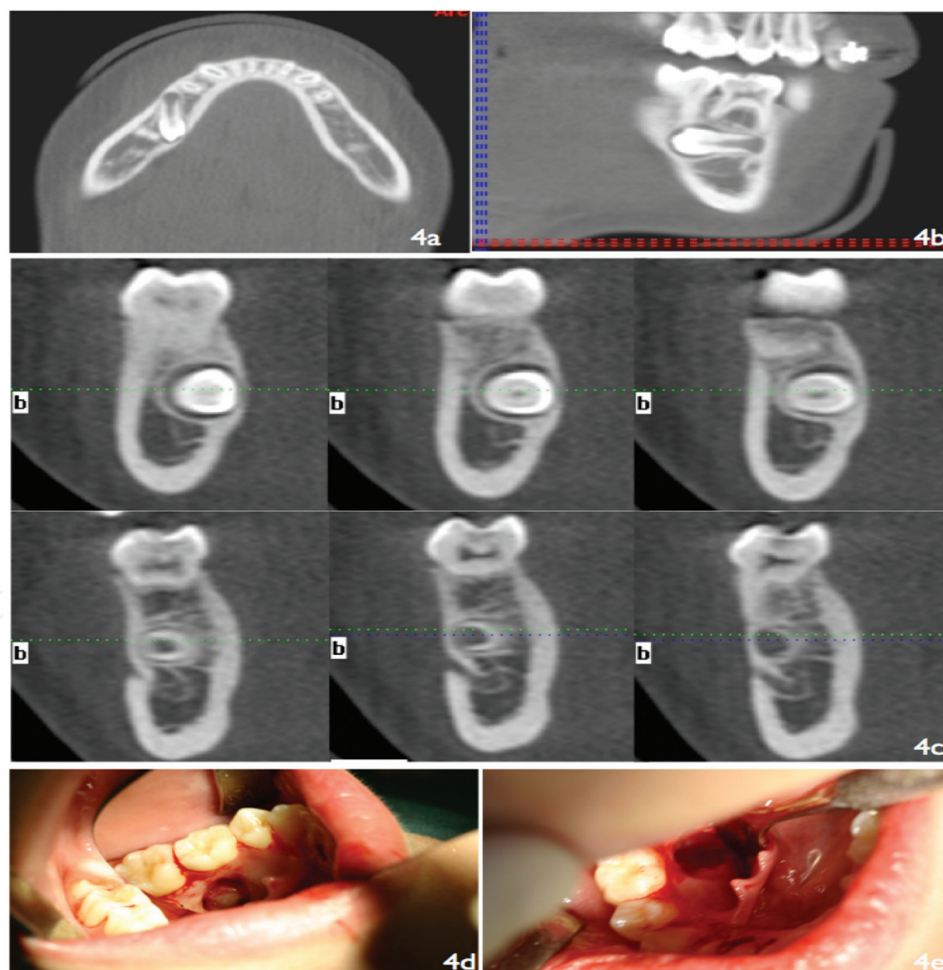


Figure 4. Supernumerary teeth in the posterior zone of the right inferior jaw. (a–c) Buccolingual localization and relationship with the mental foramen based on the multiplanar (MPR) reconstruction and cross-sectional images (I-Cat Vision). (d, e) Surgical removal of the supernumerary tooth.

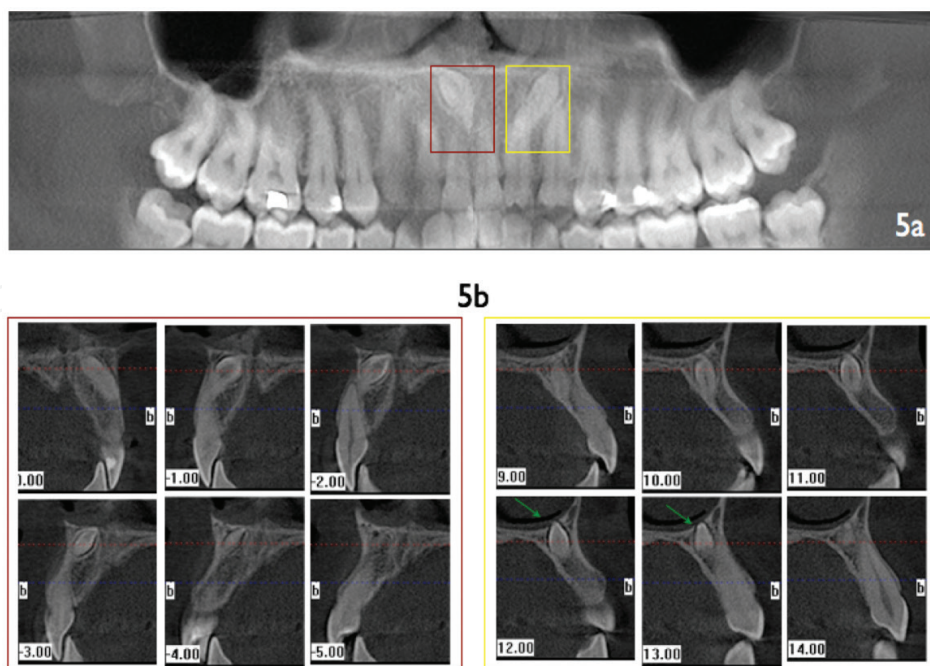


Figure 5. Supernumerary teeth in the anterior portion of the upper jaw. (a) Cone beam computed tomography (CBCT) reconstruction obtained with I-CAT system (Imaging Sciences International, Hatfield, PA, USA); (b) cross-sectional view of the supernumerary teeth and their relationship with adjacent anatomic structures. Notice a crown erupting in the nasal floor (arrows).

2.2. Periapical disease

Conventional radiographic techniques provide limited information about the origin, size, and situation of periapical lesions [28]. Superposition of adjacent anatomical and dental structures makes it necessary to perform a number of images from different angles [29]. It should be noted that the effective dose of radiation of two periapical radiographs in the area of the molars is of between 0.01 and 0.02 μSv [30], whereas the dose with limited CBCT is between 0.006 and 0.012 μSv [31].

Experimental studies have shown that CBCT is superior to digital or conventional intraoral radiography for the detection of chemically [32] or mechanically [33] induced periapical lesions. Lofthag-Hansen et al. [29] demonstrated the utility of limited CBCT for the detection of periapical pathosis not identified by conventional intraoral radiography. With CBCT, these authors found a larger number of teeth and roots involved and a larger number of lesions extending toward the maxillary sinus than on periapical radiographs. In 70% of the cases studied, the examiners considered that CBCT provided relevant additional diagnostic information in comparison with intraoral radiographs. The authors recommend the use of CBCT when there is a clinical suspicion of periapical disease and no pathology is detected on conventional radiographic techniques, as well as to plan periapical surgery for multi-rooted teeth. On the same subject, Estrela et al. [34] demonstrated that panoramic and periapical radiographs underestimated both the number and size of periapical lesions in comparison with CBCT. Estrela et al. [35] compared CBCT and intraoral radiographs for the diagnosis of periapical pathology in 596 patients with one or more endodontically treated teeth. Periapical pathology was detected in

60.9% of cases with CBCT and in 39.5% with intraoral radiographs. Based on these results, the authors proposed a new classification—the periapical index—for periapical pathosis based on the diameter of the lesion and on the expansion or destruction of cortical bone.

CBCT can also be used as a noninvasive diagnostic technique in periapical pathosis. Simon et al. [36] compared the diagnosis of large periapical lesions (granulomas vs. cysts) using CBCT and biopsy. These authors examined 17 lesions with a size equal to or greater than 1 cm × 1 cm, making a preoperative diagnosis based on the density of the lesions measured by CBCT. There was concordance between the preoperative diagnosis based on CBCT and the histological study in 13 of 17 cases. In four of the 17 lesions, the preoperative diagnosis by CBCT was of a cyst whereas the histological result was of chronic periapical granuloma. These results suggest that CBCT could be a rapid diagnostic method without invasive surgery and/or prolonged periods of observation to see if a nonsurgical therapy is effective.

Knowledge of the regional anatomy, such as, for example, root divergence and position in relation to the maxillary sinus or inferior alveolar nerve, and erosion of the vestibular and/or palatine/lingual cortical plate, can determine the surgical approach when planning periapical surgical treatment (**Figures 6** and **7**). After performing a descriptive study using CBCT to visualize the regional anatomy of the area of the upper first molars, Rigolone et al. [37] suggested the possibility of using a small vestibular access for apicoectomy of the palatal root of the maxillary first molars.

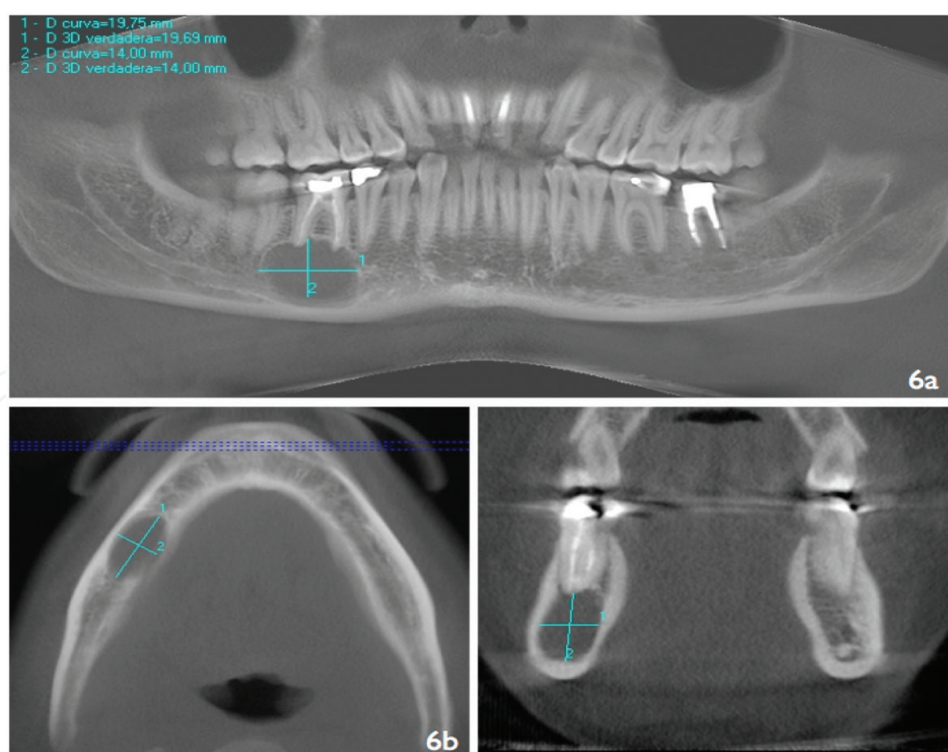


Figure 6. Well-defined radiolucent lesion at the apex of the lower right first molar. (a) Panoramic reconstruction of the CBCT. Two-dimensional measurement of lesion size (blue lines). (b, c) Measurement of the lesion in the axial and coronal sections.

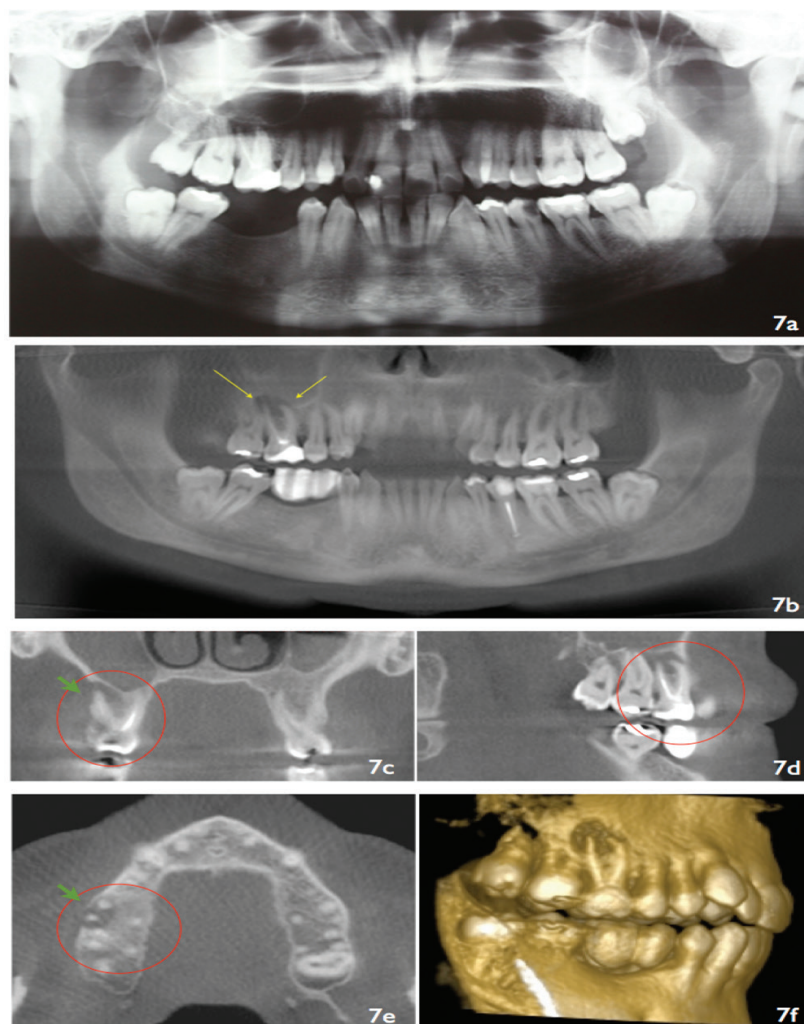


Figure 7. Preoperative evaluation of the lower right quadrant for dental implants treatment. (a) Panoramic radiography. (b) Panoramic reconstruction from cone beam computed tomography (CBCT) obtained with I-CAT system (Imaging Sciences International, Hatfield, PA, USA). Notice a periapical radiolucency in the first upper right molar poorly seen in the panoramic radiography and better identified in the CBCT (arrows). (c–e) Multiplanar reconstruction showing the limits of the periapical lesion (circle) and buccal alveolar plate destruction (arrow). (f) Three-dimensional-rendered model for case illustration.

In any case, there appears to be a degree of agreement by authors that CBCT should be reserved for those cases in which conventional radiological techniques are insufficient for providing diagnostic information about periapical pathosis.

2.3. Medication-related osteonecrosis of the jaws (MRONJs)

Medication-related osteonecrosis of the jaw (MRONJ) due to bisphosphonates was described by Marx in 2003 [38] and is characterized by exposure of the bone in the maxillofacial area (which can occur spontaneously or after a dental intervention) occurring in patients treated with antiresorptives or antiangiogenics and that does not heal after 8 weeks. The diagnosis of MRONJ is based on clinical and/or radiological findings. The differential diagnosis includes lesions secondary to radiotherapy of the head and neck and malignant diseases of the jaw.

Radiological evaluation is used to confirm the diagnosis and determine the extent of the lesions. The radiological study must include orthopantomography (OPG) as first-line test, reserving magnetic resonance imaging (MRI), CT, and CBCT for those cases that require complementary tests to resolve the differential diagnosis [39]. A number of radiological signs suggestive of ONJ have been described, including an absence of bone healing and osteosclerosis at the cortical margins of dental sockets after tooth extraction, broadening of the periodontal ligament, osteolysis, altered medullary bone structure with increased density, and the formation of sequestra [40, 41] (**Figure 8**).

CBCT, as an alternative to CT, has become more widely accepted as a diagnostic technique for 3D imaging in jaw lesions [42, 43]. Although soft-tissue definition can be limited due to a poor contrast resolution, CBCT can provide detailed information about cortical thickness, medullary involvement, irregularities after tooth extraction, and density of the medullary bone; its use has been described in the diagnosis, follow-up, and treatment of patients with

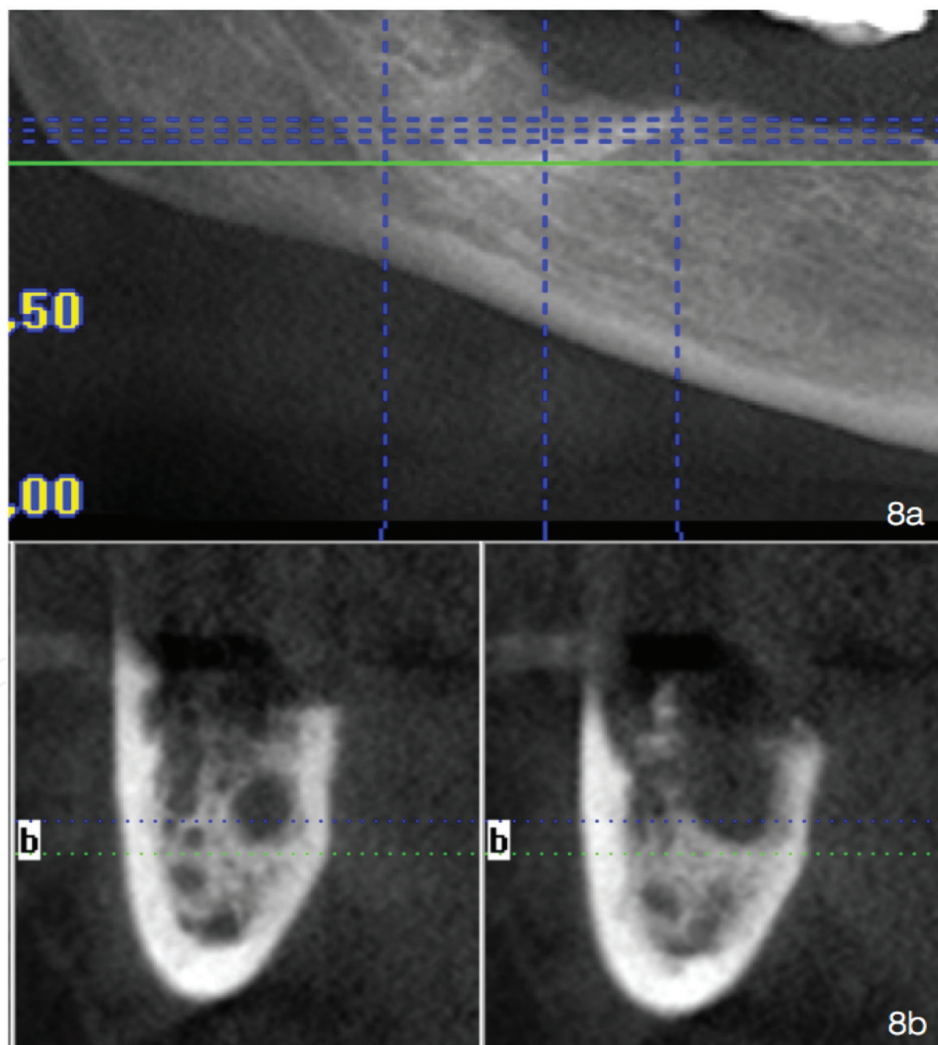


Figure 8. Medication-associated osteonecrosis of the jaws (MROJ). (a) Amplification of the zone of interest in the panoramic reconstruction. (b) Sectional views of the CBCT where the presence of osteolytic lesion is observed with small bone sequestra formation (I-CAT Vision, Imaging Sciences International, Hatfield, PA, USA).

MRONJ [44, 45]. Fullmer et al. [46] described the radiological findings of chronic suppurative osteomyelitis of the mandible on CBCT, including two cases with a history of bisphosphonate use. The authors suggested that the information provided by CBCT was not only of diagnostic utility but also that it was useful for preoperative evaluation of the true extent of the medullary bone involvement, and this information was easily transferred to 3D models that served as topographical references for the surgical treatment.

Flisher et al. [45] and Pautke et al. [41] used CBCT to locate areas of osteolysis and bone sequestra for their subsequent analysis with fluorescent lamps (Wood's lamp) to direct tetracycline absorption-guided surgical debridement. MRONJ is usually diagnosed in advanced stages, when it starts to become symptomatic [47], and CBCT can therefore facilitate early diagnosis and the identification of sequestra that could be undetectable clinically or on panoramic radiographs. According to these authors, CBCT is a useful screening technique for ONJ in patients on treatment with bisphosphonates and with additional risk factors.

Barragan-Adjemian et al. [48] analyzed 26 cancer patients treated with intravenous bisphosphonates, 18 of them presenting exposure of necrotic bone. CBCT revealed sclerotic and radiolucent bone lesions, and it was possible to measure them. The authors suggested that CBCT examination can be useful for evaluation of the extent of the lesions and for patient follow-up. Treister et al. [49] compared clinical and radiographic features of a series of seven subjects with MRONJ who were evaluated by both CBCT and panoramic radiography. Radiographic findings included sclerosis, cortical irregularity, lucency, mottling, fragmentation/sequestra formation, sinus communication, and persistent sockets. CBCT demonstrated a greater extent and quality of changes compared with panoramic radiography in nearly all cases. Other authors suggested that staging of osteonecrosis of the jaw requires computed tomography for accurate definition of the extent of bony disease [50]. Kämmerer et al. [51] have shown significant advantage of CBCT over panoramic radiography for surgeons with regard to therapeutic planning for MRONJ.

2.4. Oral cancer

The preoperative study of patients with oral cancer usually includes physical examination, blood tests, panendoscopy, and radiological examination. The radiological studies of choice are OPG, CT, and MRI. The technique of choice for visualization of tumor size in the soft tissues and for evaluation of cervical lymph node involvement is MRI, while CT is the technique of choice for evaluation of the presence and extent of bone invasion. The introduction of CBCT represents an alternative for the preoperative study of patients with oral cancer to evaluate the extent of jaw bone invasion.

Closmann and Schmidt [52] described the use of CBCT as a complementary examination for the preoperative evaluation of three patients with malignant lesions of the oral cavity (two squamous cell carcinomas and one osteosarcoma). Examination by CBCT was superior to that of OPG and MRI for evaluation of mandibular invasion and the extent of the lesion in the hard tissues, with the added advantage of lower cost and lower radiation dose than CT. The authors concluded that CBCT could be useful for the preoperative staging of oral cancer and for determining the extent of surgical resection necessary, as well as for planning reconstruction techniques.

In a study of 197 patients diagnosed with oral cancer, Linz et al. [53] have found that CBCT and bone scintigraphy (BS) showed the highest accuracy for the detection of bone invasion and showed better performance than panoramic radiography and CT/MRI. The authors concluded that for the evaluation of bone invasion, CBCT and BS might be the modalities of choice. However, CT and/or MRI remain essential for lymph node staging and for the detection of soft-tissue involvement.

3. Conclusions

The introduction of CBCT represents a great technological advance in the context of oral and maxillofacial radiology as it permits the acquisition of high-quality 3D images and dynamic navigation over an area of interest in real time, with a short scan time and lower dose of radiation than conventional CT. The initial indications of CBCT have been extended by the progressive addition of new ones such as evaluation of the extent of osteonecrotic lesions of the jaw due to bisphosphonates, preoperative staging of oral cancer, and planning reconstructive surgery. As a consequence, this radiological technique represents an interesting complement to conventional radiology in those clinical situations in which 3D imaging can facilitate diagnosis and/or treatment.

Author details

Márcio Diniz-Freitas*, Javier Fernández-Feijoo, Lucía García-Caballero, Maite Abeleira, Mercedes Outumuro, Jacobo Limeres-Pose and Pedro Diz-Dios

*Address all correspondence to: marcio.diniz@usc.es

Special Needs Unit and OMEQUI Research Group, School of Medicine and Dentistry, Santiago de Compostela University, Santiago de Compostela, Galicia, Spain

References

- [1] Nakagawa Y, Kobayashi K, Ishii H, Mishima A, Ishii H, Asada K, Ishibashi K. Preoperative application of limited cone beam computerized tomography as an assessment tool before minor oral surgery. *International Journal of Oral and Maxillofacial Surgery*. 2002;**31**:322-327
- [2] Patel S. New dimensions in endodontic imaging: Part 2. Cone beam computed tomography. *International Journal of Endodontics*. 2009;**42**:463-475
- [3] Molteni R. The so-called cone beam computed tomography technology (orCB3D, rather!). *Dentomaxillofacial Radiology*. 2008;**37**:477-478

- [4] Whaites E. *Essentials of Dental Radiography and Radiology*. 3rd ed. Churchill Livingstone, Edinburgh; 2002
- [5] Scarfe WC, Farman AG, Sukovic P. Clinical applications of CBCT in dental practice. *JCDA*. 2006;**72**(1):75
- [6] . Guerrero ME, Jacobs R, Loubele M, Schtyser F, Suetens P, van Steenberghe D. State-of-art on cone beam CT imaging for preoperative planning of implant placement. *Clinical Oral Investigations*. 2006;**10**:1-7
- [7] Quereshy FA, Savell TA, Palomo JM. Applications of cone beam computed tomography in the practice of oral and maxillofacial surgery. *Journal of Oral and Maxillofacial Surgery*. 2008;**66**:791-796
- [8] Flyagare L, Öhman A. Preoperative imaging procedures for lower wisdom teeth removal. *Clinical Oral Investigations*. 2008;**12**:291-392
- [9] Danforth RA, Peck J, Hall P. Cone beam volume tomography: An imaging option for diagnosis of complex mandibular third molar anatomical relationships. *CDA Journal*. 2003;**31**:847-852
- [10] Koong B, Pharoah MJ, Bulsara M, Tenannant M. Methods of determining the relationship of the mandibular canal and third molars. A survey of Australian oral and maxillofacial surgeons. *Australian Dental Journal* 2006;**51**:164-168
- [11] Sedaghatfar M, August MA, Dodson TB. Panoramic radiographic findings as predictors of the inferior alveolar nerve exposure following third molar extraction. *Journal of Oral and Maxillofacial Surgery*. 2005;**63**:3-7
- [12] Tantanapornkul W, Okouchi K, Fujiwara Y, Yamashiro M, Maruoka Y, Ohbayashi N, Kurabayashi T. A comparative study of cone-beam computed tomography and conventional panoramic radiography in assessing the topographic relationship between the mandibular canal and impacted third molars. *Oral Surgery, Oral Medicine, Oral Pathology, Oral Radiology and Endodontology*. 2007;**103**:253-259
- [13] Friedland B, Donoff B, Dodson TB. The use of 3-dimensional reconstructions to evaluate the anatomic relationship of the mandibular canal and impacted mandibular third molars. *Journal of Oral and Maxillofacial Surgery*. 2008;**66**:1678-1685
- [14] Tantanapornkul W, Okouchi K, Bhakdinaronk A, Ohbayashi N, Kurabayashi. Correlation of darkening of impacted mandibular third molar root on digital panoramic images with cone beam computed tomography findings. *Dentomaxillofacial Radiology*. 2009;**38**:11-16
- [15] Neugebauer J, Shirani R, Mischkowski RA, Ritter L, Scheer M, Keeve E, Zöllner JE. Comparison of cone-beam volumetric imaging and combined plain radiographs for localization of the mandibular canal before removal of impacted lower third molars. *Oral Surgery, Oral Medicine, Oral Pathology, Oral Radiology and Endodontology*. 2008;**105**:633-642

- [16] Pippi R, Santoro M, D'Ambrosio F. Accuracy of cone-beam computed tomography in defining spatial relationships between third molar roots and inferior alveolar nerve. *European Journal of Dentistry*. 2016 Oct–Dec;**10**(4):454-458
- [17] Matzen LH, Wenzel A. Efficacy of CBCT for assessment of impacted mandibular third molars: A review-based on a hierarchical model of evidence. *Dentomaxillofacial Radiology*. 2015;**44**(1):20140189
- [18] Lopes LJ, Gamba TO, Bertinato JV, Freitas DQ. Comparison of panoramic radiography and CBCT to identify maxillary posterior roots invading the maxillary sinus. *Dentomaxillofacial Radiology*. 2016;**45**(6):20160043
- [19] Cooke J, Wang HL. Canine impactions: Incidence and management. *International Journal of Periodontics and Restorative Dentistry*. 2006;**26**:483-491
- [20] Maverna R, Gracco A. Different diagnostic tools for the localization of impacted maxillary canines: Clinical considerations. *Progress in Orthodontics*. 2007;**8**:28-44
- [21] Walker L, Enciso R, Mah J. Three-dimensional localization of maxillary canines with cone-beam computed tomography *American Journal of Orthodontics and Dentofacial Orthopedics*. 2005;**128**:418-423
- [22] Mah J, Enciso R, Jorgensen M. Management of impacted cuspids using 3-D volumetric imaging. *Journal of the California Dental Association*. 2003;**31**:835-841
- [23] Liu DG, Zhang WL, Zhang ZY, Wu YT, Ma XC. Localization of impacted maxillary canines and observation of adjacent incisor resorption with cone-beam computed tomography. *Oral Surgery, Oral Medicine, Oral Pathology, Oral Radiology and Endodontology*. 2008;**105**:91-98
- [24] How Kau C, Pan P, Gallerano RL, English JD. A novel 3D classification system for canine impactions—the KPG index. *International Journal of Medical Robotics*. 2009;**5**:291-6 (In press)
- [25] Eslami E, Barkhordar H, Abramovitch K, Kim J, Masoud MI. Cone-beam computed tomography vs conventional radiography in visualization of maxillary impacted-canine localization: A systematic review of comparative studies. *American Journal of Orthodontics and Dentofacial Orthopedics*. 2017 Feb;**151**(2):248-258
- [26] Clark CA. A method of ascertaining the relative position of unerupted teeth by means of film radiographs. *Proceedings of the Royal Society of Medical Odontology Section*. 1910;**3**:87-90
- [27] Liu DG, Zhang WL, Zhang ZY, Wu YT, Ma XC. Three-dimensional evaluations of supernumerary teeth using cone-beam computed tomography for 487 cases. *Oral Surgery, Oral Pathology, Oral Medicine, Oral Radiology and Endodontology*. 2007;**103**:403-411
- [28] Shoha RR, Downson J, Richards AG. Radiographic interpretation of experimentally produced bony lesions. *Oral Surgery, Oral Pathology, Oral Medicine, Oral Radiology and Endodontology*. 1974;**38**:294-303

- [29] Lofthag-Hansen S, Huumonen S, Gröndahl HG. Limited cone beam CT and intraoral radiography for the diagnosis of periapical pathology. *Oral Surgery, Oral Pathology, Oral Medicine, Oral Radiology and Endodontology*. 2007;**103**:114-119
- [30] Ekestube A, Thilander-Klang A, Lith A, Gröndahl HG. Effective and organ doses from scanography and zonography: A comparison with periapical radiography. *Dentomaxillofacial Radiology*. 2004;**33**:87-92
- [31] Iwai K, Arai Y, Hashimoto K, Nishizawa K. Estimation of effective dose from limited cone beam X-ray CT examination. *Japanese Dental Radiology*. 2000;**40**:251-259
- [32] Özen T, Kamburoglu K, Cebeci ALI, Yüskel SP, Paksoy CS. Interpretation of chemically created periapical lesions using 2 different dental cone-beam computerized tomography units, an intraoral digital sensor, and conventional film. *Oral Surgery, Oral Medicine, Oral Pathology, Oral Radiology and Endodontology*. 2009;**107**:426-432
- [33] Stravropoulos A, Wenzel A. Accuracy of cone beam dental CT, intraoral digital and conventional film radiography for the detection of periapical lesions. An ex vivo study in pig jaws. *Clinical Oral Investigations*. 2007;**11**:101-116
- [34] Estrela C, Bueno MR, Leles CR, Azevedo B, Azevedo JR. Accuracy of cone beam computed tomography and panoramic and periapical radiography for detection of apical periodontitis. *Journal of Endodontology*. 2008;**34**:273-279
- [35] Estrela C, Bueno MR, Azevedo BC, Azevedo JR, Pécora JD. A new periapical index based on cone beam computed tomography. *Journal of Endodontology*. 2008;**34**:1325-1331
- [36] Simon JHS, Enciso R, Malfaz JM, Rogers R, Bailey-Perry M, Patel A. Differential diagnosis of large periapical lesions using cone-beam computed tomography measurements and biopsy. *Journal of Endodontology*. 2006;**32**:833-837
- [37] Rigolone M, Pasqualini D, Bianchi L, Berutti E, Bianchi SD. Vestibular surgical access to the palatine root of the superior first molar: "Low-dose cone-beam" CT analysis of the pathway and its anatomic variations. *Journal of Endodontology*. 2003;**29**:773-775
- [38] Marx RE. Pamidronate (Aredia) and zoledronate (Zometa) induced avascular necrosis of the jaws: A growing epidemic. *Journal of Oral and Maxillofacial Surgery*. 2003;**61**:1115-1117
- [39] Rizzoli R, Burlet N, Cahall D, Delmas PD, Eriksen EF, Felsenberg D, Grbic J, Jontell M, Landesberg R, Laslop A, Wollenhaupt M, Papapoulos S, Sezer O, Sprafka M, Reginster JY. Osteonecrosis of the jaw and bisphosphonate treatment for osteoporosis. *Bone*. 2008;**42**:841-847
- [40] Groetz K, Al-Nawas B. Persisting alveolar sockets—A radiologic symptom of BP-ONJ. *Journal of Oral and Maxillofacial Surgery*. 2006;**64**:1571-1572
- [41] Pautke C, Bauer F, Tischer T, Kreutzer K, Weitz J, Kesting M, Hölze F, Kolk A, Stüezenbaum SR, Wolf KD. Fluorescence-guided bone resection in bisphosphonate associated osteonecrosis of the jaws. *Journal of Oral and Maxillofacial Surgery*. 2009;**67**:471-476

- [42] Sukovic P. Cone beam computed tomography in craneofacial imaging. *Orthodontics & Craniofacial Research*. 2003;**6**:31-36s; discussion 179-82s
- [43] Hashimoto K, Arai Y, Iwai K, Araki M, Kawashima S, Terakado M. A comparison of a new limited cone beam computed tomography machine for dental use with a multidetector row helicoidal CT machine. *Oral Surgery, Oral Medicine, Oral Pathology, Oral Radiology and Endodontology*. 2003;**95**:371-377
- [44] Kumar V, Pass B, Guttenberg SA, Ludlow J, Emery RW, Tyndall DA, Padilla RJ. Bisphosphonate-related osteonecrosis of the jaws: A report of three cases demonstrating variability in outcomes and morbidity. *JADA*. 2007;**138**:602-609
- [45] Flisher K, Phelan J, Norman RG, Glickman RS. Tetracycline-guided debridement and cone beam computed tomography for the treatment of bisphosphonate-related osteonecrosis of the jaw: A technical note. *Journal of Oral and Maxillofacial Surgery*. 2008;**66**:2646-2653
- [46] Fullmer JM, Scarfe WC, Kushner GM, Alpert B, Farman AG. Cone beam computed tomographic findings in refractory chronic suppurative osteomyelitis of the mandible. *British Journal of Oral and Maxillofacial Surgery*. 2007;**45**:364-371
- [47] Chiandussi S, Biassoto M, Dore F, Rinaldi A, Rizzardi C, Cavalli F, Cova MA, Di Lenarda R. Clinical and diagnostic imaging of bisphosphonate-associated osteonecrosis of the jaws. *Dentomaxillofacial Radiology*. 2006;**35**:236-243
- [48] Barragan-Adjemian C, Lausten L, Ang DB, Johnson M, Katz J, Bonewald LF. Bisphosphonates-related osteonecrosis of the jaw: Model and diagnosis with cone beam computerized tomography. *Cells Tissue Organ*. 2009;**189**:284-288
- [49] Treister NS, Friedland B, Woo SB. Use of cone-beam computerized tomography for evaluation of bisphosphonate-associated osteonecrosis of the jaws. *Oral Surgery, Oral Medicine, Oral Pathology, Oral Radiology and Endodontology*. 2010;**109**:753-784
- [50] Bedogni A, Fedele S, Bedogni G, Scoletta M, Favia G, Colella G, et al. Staging of osteonecrosis of the jaw requires computed tomography for accurate definition of the extent of bony disease. *British Journal of Oral and Maxillofacial Surgery*. 2014 Sep;**52**(7):603-608
- [51] Kämmerer PW, Thiem D, Eisenbeiß C, Dau M, Schulze RK, Al-Nawas B, Draenert FG. Surgical evaluation of panoramic radiography and cone beam computed tomography for therapy planning of bisphosphonate-related osteonecrosis of the jaws. *Oral Surgery, Oral Medicine, Oral Pathology, Oral Radiology*. 2016 Apr;**121**(4):419-424
- [52] Closmann JJ, Schmidt BL. The use of cone beam computed tomography as an aid in evaluating and treatment planning for mandibular cancer. *Journal of Oral and Maxillofacial Surgery*. 2007;**65**:766-771
- [53] Linz C, Müller-Richter UD, Buck AK, Mottok A, Ritter C, Schneider P, et al. Performance of cone beam computed tomography in comparison to conventional imaging techniques for the detection of bone invasion in oral cancer. *International Journal of Oral and Maxillofacial Surgery*. 2015 Jan;**44**(1):8-15

