

We are IntechOpen, the world's leading publisher of Open Access books Built by scientists, for scientists

4,800

Open access books available

122,000

International authors and editors

135M

Downloads

Our authors are among the

154

Countries delivered to

TOP 1%

most cited scientists

12.2%

Contributors from top 500 universities



WEB OF SCIENCE™

Selection of our books indexed in the Book Citation Index
in Web of Science™ Core Collection (BKCI)

Interested in publishing with us?
Contact book.department@intechopen.com

Numbers displayed above are based on latest data collected.
For more information visit www.intechopen.com



Chronic Total Occlusions

Gregor Leibundgut and Mathias Kaspar

Additional information is available at the end of the chapter

<http://dx.doi.org/10.5772/68067>

Abstract

The following chapter provides a brief overview on the prevalence, clinical features, and histological findings in chronically occluded coronary arteries. The role of coronary collaterals and myocardial viability as well as left ventricular function for the evaluation of treatment strategies of chronic total occlusions (CTO) will be discussed. Imaging modalities such as computed tomography and intracoronary imaging are discussed for their significance in CTO assessment and intervention. Finally, important clinical and procedural aspects, latest interventional strategies and techniques, the armamentarium of dedicated tools for CTO interventions, as well as evidence from published trials and clinical research in the field will be presented.

Keywords: chronic total occlusions, coronary artery disease, percutaneous intervention

1. Introduction

A chronic total occlusion (CTO) of a coronary artery is defined as complete closure of the vessel lumen for at least 3 months (**Figure 1**). The true prevalence of CTOs in the general population is unknown and assumed to be around 15–20% [1–3] but varies widely (30–50%) in patients with significant coronary artery disease (CAD) [1–5].

Percutaneous coronary intervention (PCI) of CTOs is considered to be the most challenging procedure in interventional cardiology and is associated with higher periprocedural failure and complication rates. At this, the presence of a CTO influences treatment recommendations and is a strong predictor against PCI as a treatment strategy [5].

CTO PCI in specialized centers is currently performed with success rates greater than 80% and decreasing complication rates, suggesting a favorable risk/benefit ratio supporting its

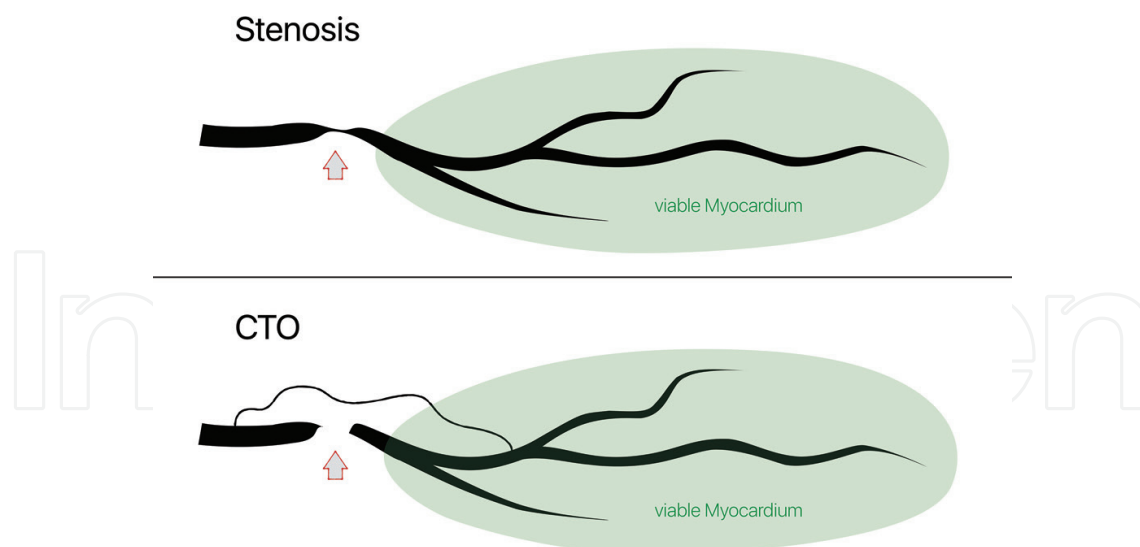


Figure 1. Stenosis versus chronic total occlusion.

increasing selection as a treatment option [6]. However, discrepant CTO PCI quantity and success rates exist among catheterization laboratories [1] and may be explained by individual skills among operators, lesion assessment, and the absence of consensual treatment strategies. Recently, CTO PCI has become more predictable as a consequence of dedicated tools, standardized procedural techniques, and continuous educational programs.

Contemporary PCI strategies with dedicated devices significantly improved procedural success, and the introduction of drug-eluting stents (DES) led to better long-term patency with preservation of left ventricular (LV) function. Still, there is little systematic evidence that post-procedural outcomes have relevantly changed, although much retrospective data suggest CTO PCI as favorable.

2. Basics of chronic total occlusions

2.1. Definition

A “true” total occlusion is defined as a coronary lesion with thrombolysis in myocardial infarction (TIMI) flow grade 0. In order to be classified as “chronic,” the occlusion needs to be present for at least 3 months. It is difficult in clinical practice to determine the period of time for which a total occlusion has been present. The age of the occlusion is usually specified by detailed assessment of medical history and cardiovascular symptoms over the past 3 months [7–9]. Despite using contemporary criteria for CTO, Fefer et al. reported determined CTO duration in only 46% of cases, whereas another recent survey showed a known occlusion duration in 61% of CTO cases, with the undetermined duration of CTO as a predictor of procedural failure and major adverse cardiac events (MACE) [1, 10].

2.2. Prevalence and clinical features

In a recent report from the Canadian multicenter CTO registry, about 15% of patients without previous coronary artery bypass graft (CABG) surgery or known CAD and about 18% of patients with clinically significant CAD show at least one CTO on coronary angiogram [9]. In these registries, only 40% had a prior history of myocardial infarction (twice as high as without CTO), and more than 50% of CTO patients showed normal LV ejection fraction [11]. Furthermore, 64% of these patients underwent medical therapy, 26% were referred to CABG (with 88% successfully bypassing CTO), and only 10% underwent PCI of the CTO [1, 9]. In this study, only 5% of patients with a CTO were asymptomatic and it was in general difficult to attribute symptoms to the CTO in symptomatic multi-vessel disease (MVD) cases. Interestingly, recanalization of an occluded left anterior descending artery (LAD) rather than PCI of an occluded right coronary artery (RCA) results in greater increase of left ventricular function and more beneficial autonomic nervous system parameters with a potential antiarrhythmic effect [12].

Patients with CAD and CTO are mostly men, tend to be older, and usually have a higher cardiac risk profile. Interestingly, peripheral artery disease was found to be the strongest clinical predictor for the presence of a CTO [5]. In comparison to men, females with CTO tend to have less vessel disease, are usually older, have a higher frequency of hypertension and diabetes, and smoke less, but overall sex has no influence on CTO PCI failure [9, 13].

2.3. Spatial distribution of CTO

Few prospective surveys and a report from the National Heart, Lung, and Blood Institute (NHLBI) Dynamic Registry show CTO located in the RCA in over 50% of the cases [1, 14]. These figures are consistent with the Canadian multicenter CTO registry report, where, in most of the cases, CTO was found in the RCA (47%), 20% in the LAD, 16% in the left circumflex (LCX), and 17% in multiple locations [1, 9]. In a recent post-mortem analysis in CTO with and without CABG, CTO was most frequently located in the RCA (57.9%), followed by the LAD (22.1%) and LCX (20.0%), mainly located in the proximal segment (68.4%) of the vessel [15].

Garcia et al. examined the clinical and angiographic characteristics as well as clinical outcomes of >1300 consecutive CTO PCIs prospectively and retrospectively in multiple centers in the US. The study showed that proximal lesions were more common, and these patients had a higher prevalence of adverse comorbidities, mostly heart failure with reduced left ventricular ejection fraction (LVEF). Furthermore, proximal lesions had more adverse angiographic features (including proximal cap ambiguity, side branch at proximal cap, blunt or no stump, and moderate or severe calcification) but had more interventional collaterals and showed a higher angiographic complexity, resulting in longer and more complex procedures. The retrograde approach was used in half of the cases involving proximal CTO lesions and was successful in one-third of these cases. Surprisingly, procedural success and complication rates were similar to mid- and distal lesions [16].

3. Histopathology

Wang et al. demonstrated that acute coronary occlusions leading to segment elevation myocardial infarction (STEMI) seem to predominately occur in predictable spots within the proximal third of the coronary arteries and that for each 10 mm increase in distance from the ostium, the risk of an acute coronary occlusion significantly decreased by 13–30%, depending on the coronary vessel [17].

In contrast to this, sparse information exists concerning the genesis of CTO and its regional distribution in terms of recanalization. In some publications, soft plaque rupture during acute coronary syndrome (ACS) with rapid thrombotic occlusion followed by its organization is described as the main cause of CTO and only a few appear to derive from atheroma progression [18]. Furthermore, it seems that once thrombotic occlusion occurs the thrombus tends to disseminate retrograde from the site of occlusion to the proximal segments of the vessel with a major side branch [19]. It is known that due to increased chronic hypoxic induction of neovascularization, the affected vessel segment stays biologically active and shows a marked heterogeneity in compensatory angiogenesis with an unpredictable wide range of coronary collateral circulation [20].

3.1. Collaterals and microchannels in CTO

Successful guidewire crossing may be facilitated by the presence of intravascular microchannels, but structural changes over time with variable localization of these microvessels are not well understood in terms of CTO recanalization [21].

In a post-mortem study of 96 CTO lesions, 49% exhibited residual <99% lumen stenosis by histologic criteria despite angiographically documented total occlusions [22]. In this cohort, adventitia and intimal plaque of total occlusions were the prevalent zones of inflammation and neovascularization. Furthermore, the results revealed in CTOs of all ages a close relation between cellular inflammation and vessel wall neovascularization in terms of location and intensity with an increase in numbers of neovascular channels rather than with an increase in their size.

Munce et al. found two histological types of microvessels in a rabbit model with induced femoral occlusion: a circumferentially oriented “extravascular” and a longitudinally oriented “intravascular” one. Interestingly, extravascular vessels around the occluded artery developed to a maximum at an early time point, followed by a slow regression over time, while intravascular vessel formation within the central body of the occlusion was delayed, and these vessels became thinner and more tortuous over time. Strongly angulated connections between the intra and extravascular microvessels were constantly present, which could explain deviation of the guidewire into extravascular channels during CTO recanalization [21].

Katsuragawa et al. found different histomorphological features in CTOs with tapering of the proximal occlusion point compared to those with a blunt proximal cap [19]. A total of 80% of the tapering-type lesions had shorter occluded segments and showed small recanalized

areas with surrounding loose fibrous tissue along the occluded segment. In lesions with a blunt proximal cap, recanalization was rare, and a side branch was frequently found proximal to the occluded segment and easily entered by the guidewire, instead of the occlusion. These features influence penetration of the proximal cap and crossing of the guidewire through the occluded segment and explain why the tapering type of occlusion is favorable for angioplasty.

3.2. Remodeling in CTO

As atherosclerotic lesions develop in arteries, two types of remodeling can occur [23]. Positive remodeling is a compensatory process in which the arterial wall grows outward in an attempt to maintain a constant lumen diameter. Negative remodeling is angiographically defined as the ratio of the occluded vessel diameter to the diameter of the contiguous normal vessel <1 and was found to be the strongest predictor of failed antegrade CTO PCI [24, 25]. In negative remodeling, an early phase where fibrin-rich organizing thrombus becomes a proteoglycan-rich thrombus and a late phase where proteoglycan-rich thrombus within the CTO body is replaced by dense collagen, thus complicating antegrade wiring, were found [15].

4. Coronary collaterals

Collaterals are interarterial connections that exist during prenatal development of the coronary circulation and regress in most individuals [26]. They develop in a native occluded vessel through positive remodeling. With the low postocclusive pressure regions being interconnected by collateral vessels, pressure gradient along the occluded segment causes pulsatile shear stress and activates proliferation of vascular smooth muscle and endothelial cells. A complex interplay of actin-binding proteins, integrins and connexions, transcription factors, and mitogen-activated kinases finally leads to an increase in vascular diameter and tissue mass (positive remodeling), but still, the degree of functional restoration of blood flow capacity remains incomplete and ends at approximately 30% of maximal conductance in coronary vessels [27, 28].

The diameter of interarterial connections is usually below the spatial resolution of modern digital angiographic imaging systems ($>200\ \mu\text{m}$) and ranges between 40 and 200 μm . Most of these connecting microvessels have been observed to be located intramyocardially, and only few reach the size of coronary side branches well above 1 mm in diameter [29].

It seems that occluded coronary arteries do not exclusively determine the level of functional collateral flow capacity and that some individuals without stenotic lesions do have immediately recruitable collateral flow to prevent myocardial ischemia during a brief coronary occlusion [30]. However, in patients without well-developed pre-existing interarterial connections, collaterals require between 2 and 12 weeks to fully reach functional capacity [31]. After successful CTO PCI, collateral function usually regresses in collaterals with small diameters but has the potential to recover in case of reocclusion [32].

4.1. Classification of collaterals in CTO

In 1985, Rentrop et al. developed an angiographic grading system to rate the effect of collaterals in filling the occluded arterial segment [33]. It distinguishes four degrees of collateral recipient artery filling by radiographic contrast medium, but in CTO with well-developed, spontaneously visible collaterals, it lacks further differentiation because most collaterals are Rentrop grade 3 (complete epicardial filling by collateral vessel of the target artery). The Werner classification adds an additional parameter to describe spontaneously visible collaterals and demonstrates a close association with clinical determinants of collateral adequacy [31]. Werner et al. graded collateral connections (CC) according to the angiographic visibility: CC0: no continuous connection between donor and recipient artery, CC1: continuous, thread-like connections (≥ 0.4 mm), and CC2: continuous, small side branch-like size of the collateral throughout its course (>1 mm). These CC grades are more practical to determine interventional collaterals suitable for retrograde CTO PCI (**Figure 2**).

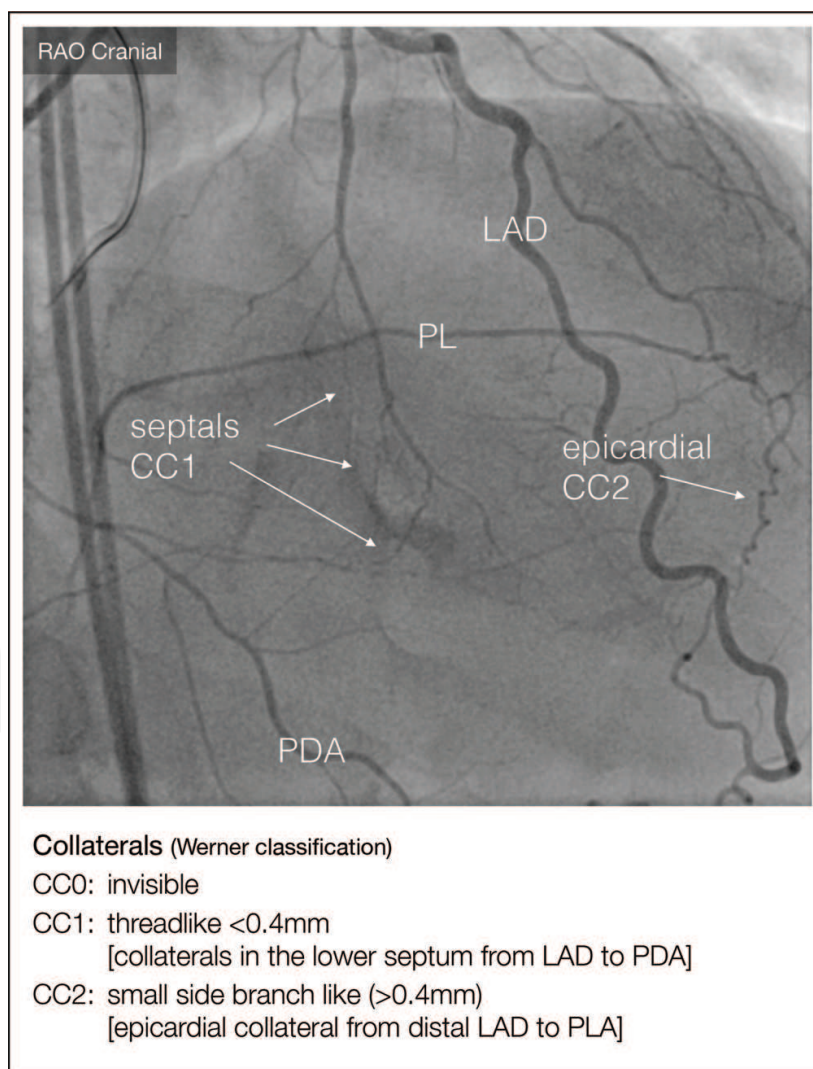


Figure 2. Interventional collaterals according to the Werner classification.

4.2. Assessment of collateral function

Generally, collateral circulation in CTO is predominantly systolic and provides only approximately 50% of antegrade coronary flow, which itself is predominantly diastolic [34]. The assessment of collateral function in CTOs has a different quality than in nonoccluded lesions. Collateral blood pressure distal of a chronic occluded vessel is assessed by placing a piezo-resistive transducer beyond the occlusion, while the antegrade flow has not yet been re-established. This can be ensured by passing occlusive microcatheters over a recanalization guidewire and then exchanged for the pressure wire [29].

4.2.1. Collateral flow index (CFI)

Intracoronary (IC) flow velocity or pressure measurements to determine collateral flow is theoretically based on the fact that velocity or perfusion pressure signals with values above central venous pressure (CVP) obtained distal to an occluded vessel originates from collaterals [35]. Measurement of such signals provides the variables for the calculation of a CFI, which expresses the amount of flow via collaterals to the vascular region of interest as a fraction of the flow via the normally patent vessel. In contrast to qualitative assessment of collaterals, such as ST-segment changes and chest pain during PCI or the degree of collateral circulation on angiogram prior to PCI, intravascular flow velocity and pressure determination precisely reflect collateral blood flow. Approximately one-third of collateral flow to the occluded area relative to the patent vessel flow is needed to prevent myocardial ischemia at rest [28]. Noteworthy, the majority of patients with MI do not have enough of the collateral flow to avoid ischemia during coronary occlusion [36] and only 10% seem to have a recruitable CFI ≥ 0.4 [36]. Insufficient collateral flow indicated by a CFI ≤ 0.25 independently predicts long-term cardiac mortality [37], and only 10% seems to have a recruitable CFI ≥ 0.4 [36]. Above that, individuals with CTOs tend to have a higher CFI than those without, and the area at risk of myocardial infarction seems to be significantly associated with CFI.

4.2.2. Fractional flow reserve in the donor artery and coronary steal

Microvascular vasodilation might lead to reduced collateral blood flow during physical or pharmacological provocation in individuals with collateral-dependent blood supply. In order to generate coronary steal, Werner et al. describes, in reference to Gould et al., the following assumption: epicardial stenosis of the donor artery causes a pressure drop proximal to the collateral origin; the collateral resistance is significant, and the microvasculature distal to the occlusion lacks a vasodilatory reserve due to being already maximally dilated [38].

Therefore, Werner et al. measured fractional flow reserve in the donor artery (FFR_D) at the origin of the collaterals in patients with CTO and recorded coronary flow velocity and pressure during recanalization. Patients with steal had more severe regional dysfunction and those with steal but without an $FFR_D < 0.8$ tended to have an impaired microvascular function. The authors concluded that coronary steal mainly occurs as a result of hemodynamically significant donor artery lesions and might have an adverse effect on the preservation of myocardial function by collaterals.

In 50 patients who successfully underwent CTO recanalization compared to 50 matched non-CTO PCI subjects, patients with CTO and an intermediate donor artery stenosis showed a low FFR_D with a high frequency of ischemia in the donor artery territory, which was often normalized by successful CTO treatment, thus suggesting recanalization of CTO as a preferred therapeutic strategy. Reference: CCI 2014.

5. Myocardial viability and left ventricular function

It is in general difficult to predict which patient with stable ischemic heart disease will receive interventional or surgical revascularization in the long term, after initially being treated with optimal medical therapy (OMT). In the occluded artery trial (OAT), late opening of infarct-related arteries (IRA) post-MI in stable patients with persistent total occlusion and no severe inducible ischemia showed no difference in rates of reinfarction, death, or severe heart failure compared to OMT [39]. Nevertheless, the results of OAT in terms of CTO have to be interpreted with caution because total occlusions in this trial were subacute (3–28 days, median 8 days) and therefore did not meet the CTO definition of at least a 3-month duration. Furthermore, patients in OAT showed a relatively normal baseline LVEF of 48% and were rather asymptomatic, whereas CTOs considered for PCI should be symptomatic or have proof of ischemia and viability [40].

An ischemic burden above 12.5% favors PCI in patients with CTO undergoing pre- and post-interventional myocardial perfusion imaging, whereas subjects with mild pre-procedural ischemia (<6.25% of LV myocardium) tend to have increased ischemic burden after PCI [41]. Another magnetic resonance imaging (MRI) study significantly revealed reduction in inducible perfusion defects and improvement in segmental myocardial viability by successful CTO PCI compared to unsuccessful revascularization [42]. Furthermore, successful CTO PCI increases hyperemic and resting myocardial blood flow with enhanced regional contractility already 24 h after the procedure [43]. Patients with an infarction and a transmural involvement < 25% assessed by MRI show significant improvements in segmental wall thickening and a reduction of mean end-systolic and end-diastolic volumes after CTO PCI [44]. Finally, the diagnostic accuracy of pre-procedural contrast enhanced MRI in patients with CTO to detect myocardial infarction and to predict improvement of myocardial function after revascularization seems to be better by using a combined viability analysis rather than focusing on the widely used transmural extent of infarction [45].

6. Coronary computed tomography angiography

Coronary computed tomography angiography (CTA) is increasingly used to diagnose CAD and shows potential in predicting the probability of procedural success and clinical benefit in CTO PCI [46, 47]. In contrast to invasive coronary angiography, CTA offers better quantification of anatomical and morphological features in occluded vessels, especially in long lesions with pronounced tortuosity, and usually visualizes distal coronary segments more

precisely [48]. There are a number of CTA characteristics in CTO lesions to predict PCI failure. Some report calcifications >50% of the cross-sectional vessel area alone [49] or in combination with an occlusion length of >15 mm to be independent predictors of unsuccessful recanalization [50], while others revealed the ratio of calcification over the cross-sectional vessel area as being predictive for procedural failure [51]. Moreover, marked vessel tortuosity at the occlusion site seems to independently predict unsuccessful guidewire crossing [24] and multiple occlusions might have an adverse effect on revascularization's outcome, as reported from the CT-Registry of Chronic Total Occlusion Revascularization (CT-RECTOR), probably due to reduced feasibility in guiding the wire through the multiple entry and exit points [46].

Conclusively, CTA features in CTO, as described above, may be applicable to assess severity of the occlusion and to predict PCI outcome in order to guide treatment decision, especially in complex lesions.

7. Imaging in CTO

CTO interventions are technically challenging due to limitations in visualizing occluded arteries by angiography. As mentioned before, ambiguous proximal CTO cap, side branch at the occlusion site, extended tortuosity, or heavy calcification with limited visibility of distal path are important angiographic features which increase procedural difficulties during CTO recanalization [7]. Multislice computed tomography (MSCT) can provide useful pre-procedural information on the dimension of vessel calcification or tortuosity along the occluded segment but does not offer direct guidance during the procedure. Intravascular ultrasound (IVUS) and optical coherence tomography (OCT) can add visual guidance during CTO PCI to improve procedure time, safety, and efficacy.

7.1. Intravascular ultrasound

In contrast to OCT, IVUS can be operated in occluded vessels throughout the whole interventional procedure. It is used to identify the best wire entry point for penetration of proximal fibrous cap or to visualize the guidewire to check intraluminal position before balloon angioplasty or stent deployment.

The IVUS probe is usually advanced into a side branch originating proximal to the occlusion to determine the vessel course within the CTO segment [52]. Standard IVUS catheters cannot generate information of the vessel distal of the occlusion, and their use is limited by the diameter and angulation of side branches [53].

Besides its antegrade applications, IVUS is used in retrograde procedures to guide retrograde guidewire crossing and reverse controlled retrograde tracking techniques such as reverse CART to improve success rate and limit complications [52]. Generally, when using the retrograde approach in longer CTO lesions, IVUS guidance can reduce the incidence of subintimal wiring with consecutive side branch loss after stenting, angiographic extravasation, coronary hematoma, and perforation [54, 55].

Furthermore, the incidence of restenosis [56] or stent thrombosis after DES implantation [57] is related to minimum stent area detected by IVUS and malapposition due to aneurysm formation after subintimal DES implantation during CTO PCI, and it can be optimized with the help of IVUS [55].

Although IVUS facilitates CTO PCI and has the potential to reduce periprocedural complications, the clinical benefit of IVUS-guided CTO PCI has not yet been proven, and further studies are needed [52].

7.2. Optical coherence tomography

OCT is more sensitive than IVUS in detecting coronary dissection during PCI and improves stent deployment or detection of acute complications. Furthermore, resolution of OCT is high enough to visualize microvessels, the different layers of the vessel wall, and even collagen concentration in coronary arteries [58].

In contrast to IVUS, conventional OCT, at the cost of penetration depth, has a 10-fold higher imaging resolution as the main advantage but is unable to generate images in completely occluded vessels and does not allow real-time intracoronary imaging for guidance of wire crossing. However, optical coherence reflectometry used in a combined OCT and radiofrequency ablation device might be able to minimize the risk of perforation and increase the crossing potential of the guidewire in CTO PCI [59].

8. Percutaneous intervention of CTO

Complication rates of CTO PCI were traditionally too high to justify these procedures and success rates were based predominantly on individual operator skills and annual case volume [60, 61]. A review of the NHLBI Dynamic Registry revealed a decrease of CTO PCI attempts from 9.6% in 1997/1998 to 5.7% in 2004 [62]. With the introduction of coronary stents, procedural success rates increased substantially and became more consistent across CTO studies [63]. In-hospital MACE and 1-year target vessel, revascularization (TVR) rates have declined by approximately 50% over the years. Patients with successful recanalization of a single-vessel CTO experience a higher 10-year survival rate compared to matched patients with a single non-CTO lesion [64].

Among the patients randomized to PCI in the Synergy between PCI with Taxus and Cardiac Surgery (SYNTAX) trial, CTO lesions were present in 24% and exhibited a low success rate of only 53% [65]. Furthermore, the presence of CTO was the single most common reason for a patient to be referred to surgery, and the prevalence of CTO was almost doubled in the CABG registry.

A metaanalysis from 18,061 CTO patients treated in dedicated high-volume CTO PCI centers and expert operators reported 77% procedural success and a 3.1% risk for MACE [6], whereas an analysis from the National Cardiovascular Data Registry revealed CTO PCI in daily practice to be successful in only 59% [66].

We have recently seen dramatic improvements in outcomes from a series of single- and multiple-operator registries with procedural success of up to 98% and MACE rates as low as 1.7% [67–70]. These results were mainly achieved through constant refinement of interventional techniques and dedicated interventional tools, ongoing knowledge exchange, and the development of standardized treatment algorithms. Most of the current CTO crossing techniques were made possible by the introduction of microcatheters and specialized guidewires. Further advances in CTO PCI will be dependent on the interplay between the development of recanalization techniques and interventional armamentarium.

8.1. Indications for CTO PCI

Indications for CTO PCI are in principle identical to the standard PCI of non-CTO lesions and are based on detailed clinical assessments (**Figure 1**). High procedural success rates in conjunction with low complication rates improve risk/benefit ratio and are paramount for the acceptance and dissemination of CTO PCI. Successful CTO recanalization has the ability to relieve angina [71], reduce ischemia [41] and the need for CABG [72], improve exercise tolerance [73], electrical stability [74], left ventricular function [44], and tolerance of future ACS [13, 75], and possibly survival [76, 77] with a similar risk compared to regular PCI of non-CTO lesions [3]. **Table 1** summarizes the rationale for CTO PCI.

Asymptomatic patients with CTO demand additional ischemia and viability testing. As described above, cardiac MRI has the ability to quantify viable myocardium and detect transmural involvement and therefore may assist in patient selection and procedural planning [78].

Based on small retrospective studies and on expert consensus, American and European guidelines recommend CTO PCI in patients with evidence for substantial ischemia in a corresponding myocardial territory when performed by an experienced operator in case of adequate clinical indications and suitable anatomy with a class-IIa, evidence level B recommendation [79, 80].

Angina relief [71]
Reduction of ischemia [41]
Improvement of exercise tolerance [73]
Improvement of left ventricular function [44]
Improvement electric stability [74]
Improved tolerance of future ACS events [75]
Reduced need for CABG [72]
Increased long-term survival in successful versus failed cases [76, 77]

Table 1. Rationale for CTO PCI [226].

8.2. Radial access for CTO PCI

Radial access is feasible for contralateral injections in CTO PCI but may be challenging when microcatheters and techniques with additional equipment are used [81, 82]. However, based on the availability of sheathless-guiding catheters with a larger interventional lumen, the radial approach has become more frequently used for both the antegrade and retrograde approach.

8.3. Procedural success in patients with CTO undergoing PCI or CABG

In the early days of interventional cardiology, CTO PCI was associated with very low success and relatively high complication rates [83–87]. This leads to a high number of patients undergoing surgery, which was also seen in the SYNTAX and the BARI (Bypass Angioplasty Revascularization Investigation) trial, where the presence of a CTO was a strong predictor for referral to CABG [4, 88].

Procedural failures during CTO are mainly due to the incapacity to pass the lesion with a guidewire, followed by failed balloon crossing, the inability to dilate the lesion, or a vessel perforation [60, 66, 89–91]. Traditional predictors for CTO PCI failure are increasing age of the occlusion, small vessel diameter, presence of calcium or a blunt stump, proximal cap ambiguity, excessive tortuosity, long occlusion length, bridging collaterals, and absent visibility of the distal vessel [72, 89, 92–95]. Furthermore, these lesions show a higher mean Multicenter CTO Registry of Japan (J-CTO) score and have collaterals that are less likely suitable for the retrograde approach [96]. However, additional angiographic features such as multivessel disease, previous CABG, and side branch at the proximal occlusion point seem not to be predictive for procedural failure with novel guidewire techniques [97].

Over time, with the improvement of both equipment such as microcatheters and dedicated guidewires with greater torque response [98] and recanalization techniques such as retrograde procedures, safe and effective CTO PCI became possible [60] and most of the prior obstacles vanished [99].

Only limited randomized data are available on the outcomes of patients with CTO undergoing CABG [100–102]. CTOs represent a difficult lesion subset also for surgical revascularization, thus leading to incomplete revascularization with 31.9% of CTOs referred for CABG not being surgically revascularized and 7.5% with occluded bypass grafts after 1 year [103]. At least one CTO is found in more than 50% of patients with CABG [1, 104].

In SYNTAX, the presence of a CTO was the strongest independent predictor of incomplete revascularization with 51% in the PCI arm and one of the major anatomic predictors for referral to CABG [105]. Interestingly, CABG enhances the progression of atherosclerosis and increases the risk for new CTOs in native coronary arteries, which itself represents an independent predictor of death, MI, and repeat revascularization in these patients [102, 103]. Moreover, long-term patency of saphenous vein grafts (SVG) is limited and is significantly lower than for second-generation DES (70 vs 90% at 5 years, respectively) [106]. Therefore, CABG might only be considered when complete arterial revascularization can be achieved,

and given the durability of LIMA-LAD grafts and superior patency of DES over SVGs to LCX or RCA, particularly in CTO cases, hybrid revascularization may represent future treatment options in selected patients [107, 108].

8.4. Predictive scores in CTO PCI

Scoring systems for CTO PCI are very helpful for case selection as well as to predict procedural efficiency and the probability for success and complications [109, 110]. The SYNTAX score, indeed, highly depends on the presence and specific features of CTO, with a single CTO contributing a substantial 10–15 points but is generally more suitable for diffused triple-vessel disease with and without involvement of the left main.

J-CTO [89] and CT-RECTOR [46] scores predict the likelihood of successful guidewire crossing within 30 minutes. The J-CTO score represents a standardized score of difficulty that predicts successful guidewire crossing within 30 minutes, is simple, easy to remember, and clinically applicable. However, the J-CTO score may be limited in some cases. The CL score considers both clinical and angiographic information, predicts success of a first antegrade attempt, and may be useful in centers where the retrograde or hybrid approach has not yet been implemented [111]. The progress CTO score includes four angiographic characteristics and should be applied when using the hybrid approach [112]. A comparison of these three scores for predicting success of CTO PCI showed a moderate performance in predicting technical outcome, with a favor for antegrade procedures [113]. A novel prediction model including age, ostial location, and collateral filling was also strongly associated with technical failure when using advanced recanalization technologies [70]. The ORA score, however, predicts technical failure by both antegrade and retrograde techniques and categorizes difficulty and success rate of CTO procedures into four groups.

Finally, the Mehran risk score is most widely used as a classic model for CIN after CTO PCI, but it is rather inconvenient in clinical practice because it was established only after contrast media exposure [114, 115].

8.5. Stents in CTO PCI

The use of bare-metal stents (BMS) after successful CTO PCI has been proven to be superior in terms of immediate angiographic success as well as long-term restenosis and reocclusion when compared with balloon angioplasty (POBA) alone [116–120]. DES in comparison to BMS shows again a significant reduction in TVR and adverse clinical events [121–126] although a trend toward a higher stent thrombosis rate was observed [127–129]. As a consequence, stent implantation following successful CTO PCI increased dramatically over time and reached nearly 100% at the turn of the millennium [130].

8.6. Bioresorbable vascular scaffolds in CTO

Bioresorbable vascular scaffolds (BVS) have potential long-term benefits compared with DES, thus being particularly reasonable in CTO [131]. A first feasibility analysis in 23 patients with

selected and simple CTO lesions demonstrated excellent 6-month and 1-year follow-up after BVS implantation, but these initial results need to be confirmed in larger studies with further long-term follow-up [132].

8.7. Relevance of the target vessel of CTO PCI

Studies have shown the prognostic importance of the anterior wall of the left ventricle [133, 134]. In accordance with these findings, successful CTO PCI is associated with an improvement in long-term survival as compared to CTO PCI failure in the subpopulation of patients with LAD CTO [76] (cohort from 1980 to 2004, overall stent use < 20%, only three patients received DES).

Results from a contemporary multinational CTO registry suggest that successful PCI of a CTO in only the LAD and the LCX, but not the RCA, is associated with improved long-term survival [135]. Over 90% of patients included in this analysis received a stent, mostly DES, which likely resulted in higher long-term patency. Due to higher anatomical complexity, the LCX is the least commonly attempted target vessel in CTO PCI with a lower rate of procedural success and a trend toward higher MACE rates [89, 95, 97, 98, 136, 137].

8.8. CTO and STEMI

Patients presenting with acute STEMI show an incidence of CTO up to 13% and tend to suffer poor immediate and long-term prognosis [94, 130, 138–147]. Several trials revealed a concurrent CTO in a non-infarct-related artery (non-IRA) as an independent predictor of short- and long-term mortality in STEMI patients undergoing primary PCI [148–150]. A metaanalysis of seven observational studies including 14,117 patients with a concurrent CTO in a non-IRA artery presenting with STEMI found a three-fold increase in mortality in both single- and multi-vessel disease cases [75]. Furthermore, concurrent CTO in a non-IRA in MVD was significantly associated with residual left ventricular ejection fraction (LVEF) early after STEMI and further decrease of LVEF in the first year after the index STEMI [13], and this seems particularly true for a CTO of the LAD [151].

The acute closure of the donor artery during STEMI leads to extensive myocardial ischemia in a two-vessel area with consecutive hemodynamic instability [144, 148, 152–155]. This is even more pronounced if the culprit vessel has impaired collateral filling itself [156].

8.9. Complete revascularization in CTO PCI

The most common reason for incomplete revascularization in PCI is the presence of a CTO [157], and incomplete revascularization associated with CTO carries a worse outcome and a higher risk of death compared with complete revascularization [158, 159]. The potential benefit of successful CTO PCI has been derived from retrospective analyses and mainly includes improvement of LVEF in preventing heart failure [160], reduction of arrhythmias, and, above all, reduction of mortality, MI, as well as the need for repeating revascularization procedures [161]. Therefore, complete revascularization strategies after the index PCI for STEMI should include CTO procedures.

The EXPLORE (Evaluating Xience and Left Ventricular Function in Percutaneous Coronary Intervention on Occlusions After ST-Elevation Myocardial Infarction) trial was the first randomized controlled trial evaluating whether patients with STEMI and concurrent CTO in a non-IRA benefit from additional CTO PCI shortly after primary PCI [151]. In agreement with earlier registry studies, EXPLORE reported a survival benefit only for successful CTO PCI of the LAD but not for the RCA or LCX [76, 135].

Migliorini et al. studied 330 high surgical risk patients undergoing PCI for unprotected left main disease (ULMD) with more than one-third having at least one CTO [162] and found the presence of a concurrent CTO of the RCA in patients undergoing PCI for ULMD to be a significant predictor for mortality. In contrast to other studies, CTO of both LAD and LCX were not found predictive of worse outcomes. The fact that RCA CTO were attempted less frequently (51%) than CTO of the other two main coronary arteries (79%) may explain the prognostic impact of the RCA in this study.

In the SYNTAX trial, incomplete revascularization was associated with a significant increase in 4-year mortality [105]. The presence of a CTO was less likely to result in complete revascularization in both the PCI and CABG arms and was the strongest independent predictor of incomplete revascularization in the PCI arm. The very low rate of complete revascularization in the PCI arm (34.3%) compared with the CABG arm (64.8%) was mostly related to CTO PCI failure in approximately 50%.

8.10. Restenosis after CTO PCI

Long subintimally placed stents may attribute to a higher restenosis rate. They are typically seen with the STAR technique [163] and are more frequent after retrograde wire crossing [164]. DES are consistently superior over BMS. Second-generation everolimus-eluting stents have lower rates of restenosis after CTO PCI compared with first-generation DES [165], and PCI of a CTO in stent restenosis shows generally a high success rate with good long-term results [166]. Many studies on restenosis after CTO PCI, however, did not have angiographic follow-up despite the fact that reocclusion can be completely silent after CTO PCI [121, 122, 129, 164, 165, 167–173].

9. Specialized CTO recanalization techniques

As described above, CTO remains one of the most difficult subsets in interventional treatment of CAD patients and is generally considered to be challenging during a revascularization approach because of high procedural complexity. With the introduction of innovative catheter-based devices and the development of standardized treatment algorithms, CTO PCI has been increasingly performed with high success and low complication rates. At this, a thorough assessment of specific lesion-related factors and the use of a systematic step-up interventional strategy contribute to lower periprocedural comorbidities with better post-procedural outcome [98, 174].

Currently, there are three major CTO crossing techniques: (1) antegrade wire escalation (AWE), (2) antegrade dissection re-entry (ADR), and (3) retrograde procedures including retrograde wire escalation (RWE) and retrograde dissection re-entry (RDR).

9.1. Antegrade techniques

9.1.1. Antegrade wire escalation

AWE is the most widely used CTO crossing technique and is appropriate for short occlusions or extended ones where a remaining microchannel is expected [174, 175]. However, AWE was found to be unlikely successful in complex lesions [176].

Classical antegrade techniques are single wire-based starting with a soft hydrophilic wire seeking for microchannels, followed by gradual escalation to harder and stiffer wires [98]. Higher penetrating force is needed in more fibrous and calcified lesions, and nonhydrophilic wires represent a good alternative for loose tissue or intimal plaque tracking [98]. However, strong angulated lesions with evidence of bridging collaterals usually exhibit a higher risk of perforation, and the use of stiffer wires with a higher tip load and penetration force in these cases should be cautious [174]. Furthermore, gradually increasing wire tip load with the goal of finding the safest wire has the potential to decrease risk of perforation [98].

When performing AWE, the guidewire is advanced to the occlusion point, advanced across the lesion, and followed by the microcatheter that adds support and increases penetration power, allows wire exchange or wire reshaping, and finally maintains position once the lesion is crossed to place an extra support wire for balloon dilatation and stenting [69]. In case of subintimal positioning, the wire is guided back into the true lumen by different techniques or withdrawn and redirected if it leaves the target vessel [174].

Parallel wire techniques facilitate re-entry of the true lumen by leaving the first wire in the subintimal space to seal the false track and act as a marker. Continued manipulation of this wire close to the distal cap should be avoided as it can cause subintimal hematoma that compresses the distal true lumen and complicate re-entry. A second penetrating wire is therefore introduced using a microcatheter, and an attempt is made at redirection into the true lumen. Double lumen microcatheters contain both a monorail and an OTW port and are ideally suited for parallel wiring techniques.

Seesaw wiring involves simultaneous use of two microcatheters and wires and has the advantage of avoiding the need for complex exchange of OTW microcatheters. Also, wires can be reshaped and their roles switched promptly.

9.1.2. Antegrade dissection re-entry

ADR techniques make intentional use of a dissection plane in the subintimal space for crossing CTOs. This concept was first introduced by Antonio Colombo who originally advanced a knuckled guidewire through the subintimal space until it spontaneously re-entered into

the distal true lumen (subintimal tracking and re-entry technique) [177]. However, high restenosis and reocclusion rates are found in extensive subintimally stented lesions [165]. Therefore, ADR should not be enforced as a first-line technique. The mini-STAR was presented as bail-out technique and includes limited subintimal tracking distances [178] associated with improved outcomes [179]. Dedicated subintimal tracking and re-entry devices such as the CrossBoss catheter and Stingray balloon allow controlled re-entry into the distal true lumen from the subintimal space [180, 181].

9.2. Retrograde techniques

As complexity rises, advanced techniques are needed to improve procedural success. The retrograde approach has the ability to significantly increase success rates, particularly in challenging lesions (**Table 2**) and has become a widely used strategy for CTO PCI during recent years [182, 183]. Retrograde crossing of the CTO against the direction of blood flow is easier due to the softer, often tapered, and less ambiguous distal cap [15]. These properties in contrast to proximal cap morphology during an antegrade approach facilitate entering the CTO body with the retrograde guidewire. Additional advantages of the retrograde approach are found in the presence of ostial occlusions, unfavorable proximal cap (blunt stump, side branch), ambiguity of the occluded segment, poor distal target or distal bifurcation [184], and good interventional collaterals in post-CABG patients and in failed antegrade cases.

Retrograde CTO PCI can be performed via several collateral pathways including transseptal collaterals [185, 186], epicardial collaterals, and SVG [187]. Intraseptal collaterals are nonepicardial vessels, representing a safe route for CTO PCI with a lower risk of rupture, pericardial effusion, and tamponade [188]. The use of microcatheters seems to dramatically reduce injury to septal channels during a transseptal retrograde approach [189] and also increases the availability of additional routes through tortuous epicardial collaterals [190]. Previously, the CART technique with its retrograde approach was limited to the transseptal pathway in

Ostial occlusion
Unfavorable proximal cap: blunt stump, side branch
Anatomic ambiguity of CTO body
Poor distal target
Distal bifurcation [184]
Good interventional collaterals
Bifurcation at distal cap
Post-CABG patients (retrograde access over bypass)
After failed antegrade attempt

Table 2. Anatomical features favoring the retrograde approach.

nearly 80% and resulted in more balloon dilatations of the septal channels and a higher perforation rate [55, 191].

An in-hospital analysis of procedural and long-term outcomes from the European multicenter ERCTO registry demonstrated increased numbers of safe and successful retrograde procedures with good long-term outcomes [192]. However, the retrograde approach also seems to be independently associated with increased risk of periprocedural complications [193]. IVUS, as described above, can serve as a useful tool for the detection of procedure-related vessel damage and subintimal wire tracking to help guide retrograde CTO PCI [55].

9.3. The hybrid approach

The hybrid algorithm depicted in **Figure 3** represents a combined strategy comprising AWE/RWE and ADR/RDR techniques (**Table 3**) [194, 195]. The fundamental principles in hybrid procedures require a special mindset and great flexibility in the approach with the ability to perceive failure modes early to quickly change strategy and to come back to abandoned strategies, if necessary. Experienced CTO operators aim for efficiency and look for multiple strategies with several options and different techniques. This skillset can be taught and transferred with implementation of the hybrid algorithm, ideally in a broader setting with operators of different experience levels to improve technical success while maintaining low complication rates. The adoption of only a few strategies will limit the patients who can be treated on the basis of coronary anatomy [82, 176, 186, 196, 197].

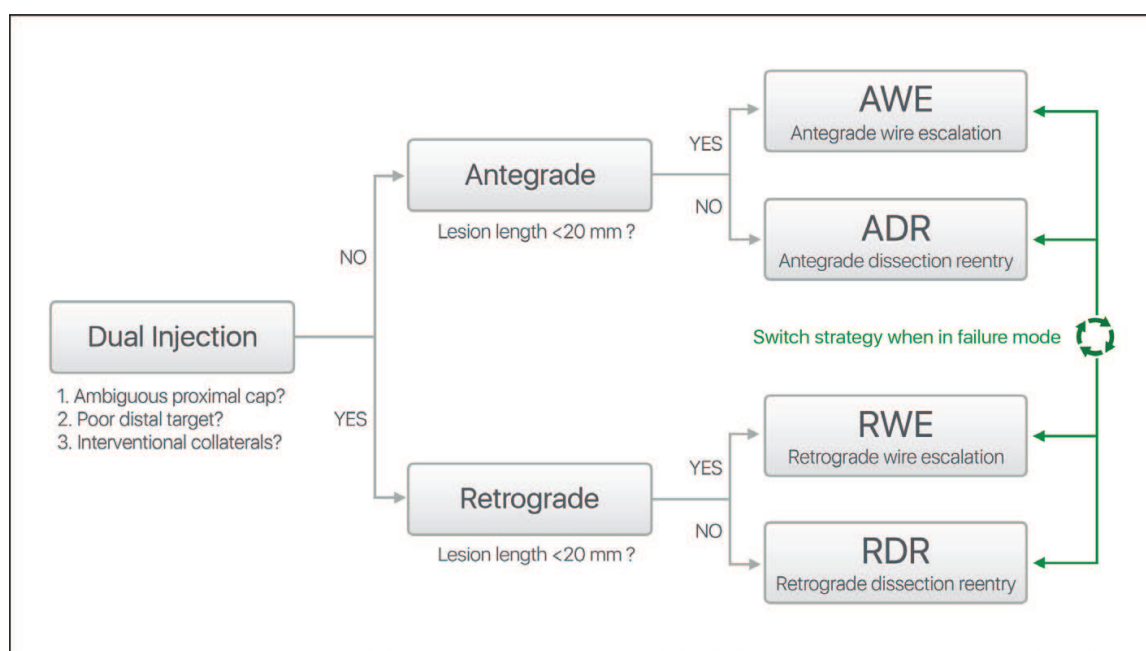


Figure 3. The Hybrid Algorithm. Adapted from Ref. [194].

Antegrade

Wire escalation facilitated by antegrade microcatheters [98]
Subintimal tracking and re-entry (STAR) [177]
miniSTAR [178]
Balloon anchoring [227]
Limited antegrade subintimal tracking (LAST) [228]
Subintimal dissection/re-entry strategies (ADR) [196]
Facilitated Antegrade Steering Technique (FAST) [180]

Retrograde

Collateral wire passage (marker wire)
Septal surfing [229]
Microcatheter-assisted retrograde wiring [69]
Rendezvous
Tip-in technique [230]
Kissing wires (antegrade and retrograde wires)
Knuckle wires
controlled antegrade and retrograde tracking and dissection (CART) [231, 191]
Confluent balloon technique [232]
Guide extensions
Externalization
Snaring

Combined antegrade and retrograde techniques

Reverse CART [69]
deflate, retract, and advance into the fenestration technique (DRAFT) [233]
IVUS guiding

Table 3. Contemporary antegrade and retrograde techniques [195].

10. Complications

CTO PCI has long been associated with high complication rates with one-third of failed CTO PCI attributable to periprocedural complications [96, 183]. The prognostic value of periprocedural MI in non-CTO PCI depends on the extent of irreversible myocardial injury and correlates well with the release of cardiac biomarkers [198, 199]. MI after successful CTO PCI has been associated with increased long-term mortality and is considered as one of the

most common yet unrecognized complications in CTO PCI [6]. However, its prognostic value remains controversial. Most of the myocardial injuries during CTO PCI are relatively limited to absent electrocardiographic or echocardiographic changes, and the prognosis in such “asymptomatic” patients is much more dependent on the procedural success. However, techniques unique to CTO PCI add to the risk of MI compared with PCI of non-CTO lesions [6, 200–203]. Hereby, periprocedural MI may occur from shearing off the collateral circulation, obstructing or dissecting the proximal epicardial artery or sidebranch[204], collateral vessel compromise, donor artery ischemia during balloon anchoring, compression of the lumen by subintimal hematoma, thrombus formation, air embolization, or perforation [193].

Altogether, the complexity of the procedure correlates with the risk of periprocedural MI. However, its pathophysiological mechanisms are considered to be multifactorial and not fundamentally different from non-CTO PCI [201, 205–210].

Classic safety equipment should be readily available in the catheter laboratory and includes transthoracic echo, coils, pericardial drains, and stent grafts. New techniques usually provoke new complications asking for specific treatment solutions [211, 212].

11. Interventional armamentarium

Technical difficulties during CTO PCI with high procedural failure rates have been lately overcome by introducing a growing number of innovative devices that address a very specific problem associated within a particular recanalization algorithm [213]. In order to perform CTO PCI successfully, it is paramount to know the availability, utilization properties, and technical limitations of each individual hardware.

11.1. Guidewires

Guidewires provide the primary and most critical piece of equipment to successfully perform CTO PCI. Innovation and repetitive iteration over the last 30 years lead to a wide range of primary, secondary, and tertiary design elements that directly influence endoluminal performance, especially in occluded lesions with specific anatomical properties [214]. At this, there is an individual demand for a specific wire spectrum during CTO recanalization with specific lesion characteristics, whereas in non-CTO PCI, usually one work horse wire serves for everything.

Tip load is measured in grams and defined by the amount of force the guidewire can create at the tip, whereas penetration power is the ability to penetrate the tissue and is defined by the ratio of tip load over tip area. CTO guidewires with tapered tips exhibit higher penetration power than their nontapered counterparts with equal tip load. Additional penetration force is generated with a microcatheter, in small vessels or tight lesions proximal to the tip, and by lateral support of the coating.

The coating, generally applied to the surface of the guidewire, can be a polymer jacket, a hydrophilic or hydrophobic film, or any combination of the above, and modifies pushability, trackability, and steerability.

The introduction of composite core dual coil guidewires with a second coil layer twisted in opposite turns around the first coil dramatically improved torque transmission and steering capabilities in tortuous arteries and opened new frontiers in CTO PCI, especially in hard calcified tortuous vessels.

Flexibility defines how well a guidewire advances around a sharp corner and is characterized by the core tapering length and the coil structure at the distal end of the wire. Gradually, long-tapered wires better follow tortuous, sharp-bended vessels but provide less support to other gear following. Shorter tapers, however, provide greater support near the tip but exhibit also greater tendency to prolaps.

Spring coils generally affect not only support, trackability, and visibility but also have an impact on the guidewire diameter and provide tactile feedback.

11.2. Microcatheters

After successful crossing of the CTO lesion with a dedicated CTO guidewire, the microcatheter is advanced past the occlusion to exchange the guidewire for a work horse wire or extra support guidewire in heavily calcified lesions of tortuous vessels, followed by balloon angioplasty and stenting. Special trapping techniques for hydrophilic wires and flushing techniques for non-hydrophilic wires are used to exchange individual microcatheters. Over the years, several microcatheters have been developed to dilate microchannels, to improve back-up support and torque transmission, and to facilitate guidewire exchange or reshaping. Furthermore, wire directability and penetration capacity can be maximized with the combined use of a microcatheter and a stiff-tapered penetration wire [215].

11.3. Angioplasty balloons

Very low profile angioplasty balloons with hydrophilic coating are available to cross tight and calcified lesions. However, with increasing use of retrograde and subintimal tracking techniques, these small balloons become less crucial to successfully cross the lesion.

11.4. Additional tools

In addition to the aforementioned devices, dedicated re-entry systems such as the Stingray balloon have been invented facilitating selected cases through controlled antegrade subintimal re-entry [216, 217]. Other novel applications and techniques are constantly being developed [218]. In complex cases, adjunctive use of several sophisticated devices may be cumbersome [219].

12. Clinical outcome data

Successful CTO PCI and improvement in survival strongly depend on the target vessel. So far, only CTO PCI of the LAD seems to be associated with improved long-term

survival [76]. From a 20-year experience of CTO PCI, Suero et al. reported improved procedural and long-term outcome [64] which was in line with more recent data from Aziz et al. who revealed CTO failure as an independent predictor of death and a higher rate of subsequent CABG (3.2 vs. 21.7%, $P < 0.001$) [140]. The result from Aziz could be confirmed by Mehran et al. (long-term clinical outcomes in 1791 patients who underwent PCI of 1852 CTOs) and Jones et al. (6996 patients underwent elective PCI for stable angina with 11.9% for CTO) who both demonstrated an association of successful CTO revascularization with reduced long-term cardiac mortality (all-cause mortality: 17.2% for unsuccessful CTO PCI vs 4.5% for successful CTO PCI [220], and 8.6 vs. 6.0%, [221] respectively) and the need for CABG surgery at a 5-year follow-up (with similar rates as Suero et al.) [220, 221]. Other studies, however, did not show a mortality benefit for successful CTO PCI compared with failed PCI [222].

In the Swedish Coronary Angiography and Angioplasty Registry (SCAAR), CTO was associated with increased overall mortality and considered to be the highest risk in patients under 60 years of age. Furthermore, the risk attributable to CTO was highest in the STEMI subgroup, and the authors reported no interaction between CTO and either diabetes or sex [223].

A metaanalysis of CTO PCI on clinical outcomes including 13 observational studies and 7288 patients with a weighted average follow-up of 6 years [77] showed a significant lower mortality, residual or recurrent angina, and subsequently CABG rate after successful CTO PCI.

Another meta-analysis of procedural effects on clinical outcomes after CTO PCI in over 12,000 patients with a mean follow-up of 3.7 ± 2.1 years [224] showed a PCI success rate of 71.2% with a significant reduction of all-cause mortality and MACE in this group. Nevertheless, successful CTO PCI was associated with a higher risk of TVR but reduction of subsequent CABG. Recently, Christakopoulos et al. reported from the largest metaanalysis, including over 28,000 patients [225] as well an improvement of clinical outcomes (mortality, MI, CABG, stroke, and angina but not TVR) after successful PCI, regardless of the revascularization technique (balloon angioplasty, BMS, or DES).

13. Ongoing randomized CTO trials

Most of the clinical outcome data of CTO interventions derives from retrospective analyses and registry data. Prospective randomized controlled trials such as the DECISION-CTO trial (Drug-Eluting Stent Implantation Versus Optimal Medical Treatment in Patients with Chronic Total Occlusion) and the EURO-CTO trial (European Study on the Utilization of Revascularization versus Optimal Medical Therapy for the Treatment of Chronic Total Coronary Occlusions) are largely missing and eagerly awaited. Other trials such as the REVASC trial investigate left ventricular function before and after successful CTO PCI.

Abbreviations

ACS	Acute coronary syndrome
ADR	Antegrade dissection and re-entry
AMI	Acute myocardial infarction
AWE	Antegrade wire escalation
BARI	Bypass Angioplasty Revascularization Investigation
BMS	Bare-metal stent
BVS	Bioresorbable vascular scaffold
CABG	Coronary aortic bypass graft
CAD	Coronary artery disease
CART	Controlled antegrade and retrograde tracking and dissection
CART	Controlled antegrade and retrograde subintimal tracking
CC	Collateral connections
CFI	Collateral flow index
CT-RECTOR	CT-Registry of chronic total occlusion revascularization
CTA	Coronary computed tomography angiography
CTO	Chronic total occlusion
CVP	Central venous pressure
DECISION-CTO	Drug-eluting stent implantation versus optimal medical treatment in patients with chronic total occlusion
DES	Drug-eluting stent
EURO-CTO	European study on the utilization of revascularization versus optimal medical therapy for the treatment of chronic total coronary occlusions
FFR _D	Fractional flow reserve in the donor artery
HF	Heart failure
IRA	Infarct related artery
ISR	In-stent restenosis
IVUS	Intravascular ultrasound
J-CTO	Multicenter CTO Registry of Japan
LAD	Left anterior descending artery
LAST	Limited antegrade subintimal tracking
LAST	Limited antegrade subintimal tracking
LCX	Left circumflex artery

LVEF	Left ventricular ejection fraction
MACE	Major adverse cardiac event
MI	Myocardial infarction
MRI	Magnetic resonance imaging
MSCT	Multislice computed tomography
MVD	Multi-vessel disease
NHLBI	National Heart, Lung, and Blood Institute
OAT	Open artery trial
OCT	Optical coherence tomography
OMT	Optimal medical therapy
PCI	Percutaneous coronary intervention
POBA	Plain old balloon angioplasty
RCA	Right coronary artery
RCT	Randomized controlled trial
RDR	Retrograde dissection and re-entry
REVASC	Recovery of left ventricular function in chronic total occluded coronary arteries
RWE	Retrograde wire escalation
SCAAR	Swedish Coronary Angiography and Angioplasty Registry
STAR	Subintimal Tracking and Re-entry
STEMI	ST-segment elevation myocardial infarction
STRAW	Subintimal TRAnscatheter withdrawal technique
SVG	Saphenous vein grafts
SYNTAX	Synergy Between PCI with Taxus and Cardiac Surgery
TIMI	Thrombolysis In myocardial infarction
TVR	Target vessel revascularization
ULMD	Unprotected left main disease

Author details

Gregor Leibundgut^{1*} and Mathias Kaspar²

*Address all correspondence to: kardiologie@mac.com

1 Department of Cardiology, University Hospital, Kantonsspital Baselland, Liestal, Switzerland

2 Department of Angiology, Kantonsspital Luzern, Luzern, Switzerland

References

- [1] Fefer P, Knudtson ML, Cheema AN, et al. Current perspectives on coronary chronic total occlusions. *J Am Coll Cardiol* 2012;59:991-997.
- [2] Råmunddal T, Hoebbers LP, Hoebbers L, et al. Chronic total occlusions in Sweden – a report from the Swedish Coronary Angiography and Angioplasty Registry (SCAAR). *PLoS One* 2014;9:e103850.
- [3] Grantham JA, Grantham JA, Marso SP, et al. Chronic total occlusion angioplasty in the United States. *J Am Coll Cardiol Interv* 2009;2:479-486.
- [4] Srinivas VS. Contemporary percutaneous coronary intervention versus balloon angioplasty for multivessel coronary artery disease: a comparison of the national heart, lung and blood institute dynamic registry and the Bypass Angioplasty Revascularization Investigation (BARI) study. *Circulation* 2002;106:1627-1633.
- [5] Christofferson RD, Lehmann KG, Martin GV, Every N, Caldwell JH, Kapadia SR. Effect of chronic total coronary occlusion on treatment strategy. *Am J Cardiol* 2005;95:1088-1091.
- [6] Patel VG, Brayton KM, Tamayo A, et al. Angiographic success and procedural complications in patients undergoing percutaneous coronary chronic total occlusion interventions: a weighted meta-analysis of 18,061 patients from 65 studies. *J Am Coll Cardiol Interv* 2013;6:128-136.
- [7] Stone GW, Kandzari DE, Mehran R, et al. Percutaneous recanalization of chronically occluded coronary arteries: a consensus document: part I. *Circulation* 2005;112:2364-2372.
- [8] Stone GW, Reifart NJ, Moussa I, et al. Percutaneous recanalization of chronically occluded coronary arteries: a consensus document: part II. *Circulation* 2005;112:2530-2537.
- [9] Hoebbers LP, Claessen BE, Dangas GD, Råmunddal T, Mehran R, Henriques JPS. Contemporary overview and clinical perspectives of chronic total occlusions. *Nat Rev Cardiol* 2014;11:458-469.
- [10] Barlis P, Kaplan S, Dimopoulos K, Tanigawa J, Schultz C, Di Mario C. An indeterminate occlusion duration predicts procedural failure in the recanalization of coronary chronic total occlusions. *Catheter Cardiovasc Interv* 2008;71:621-628.
- [11] Irving J. CTO pathophysiology: how does this affect management? *Curr Cardiol Rev* 2014;10:99-107.
- [12] Szwoch M, Ambroch-Dorniak K, Sominka D, et al. Comparison the effects of recanalisation of chronic total occlusion of the right and left coronary arteries on the autonomic nervous system function. *Kardiol Pol* 2009;67:467-474.
- [13] Claessen BEPM, van der Schaaf RJ, Verouden NJ, et al. Evaluation of the effect of a concurrent chronic total occlusion on long-term mortality and left ventricular function

- in patients after primary percutaneous coronary intervention. *J Am Coll Cardiol Interv* 2009;2:1128-1134.
- [14] Cohen HA, Williams DO, Holmes DR, et al. Impact of age on procedural and 1-year outcome in percutaneous transluminal coronary angioplasty: a report from the NHLBI Dynamic Registry. *Am Heart J* 2003;146:513-519.
- [15] Sakakura K, Nakano M, Otsuka F, et al. Comparison of pathology of chronic total occlusion with and without coronary artery bypass graft. *Eur Heart J* 2014;35:1683-1693.
- [16] Garcia S, Chadi Alraies M, Karatasakis A, et al. Coronary artery spatial distribution of chronic total occlusions: insights from a large US registry. *Catheter Cardiovasc Interv* 2016. [Epub ahead of print].
- [17] Wang JC, Normand S-LT, Mauri L, Kuntz RE. Coronary artery spatial distribution of acute myocardial infarction occlusions. *Circulation* 2004;110:278-284.
- [18] Tran P, Phan H, Shah SR, Latif F, Nguyen T. Applied pathology for interventions of coronary chronic total occlusion. *Curr Cardiol Rev* 2015;11:273-276.
- [19] Katsuragawa M, Fujiwara H, Miyamae M, Sasayama S. Histologic studies in percutaneous transluminal coronary angioplasty for chronic total occlusion: comparison of tapering and abrupt types of occlusion and short and long occluded segments. *J Am Coll Cardiol* 1993;21:604-611.
- [20] Schultz A, Lavie L, Hochberg I, et al. Interindividual heterogeneity in the hypoxic regulation of VEGF: significance for the development of the coronary artery collateral circulation. *Circulation* 1999;100:547-552.
- [21] Munce NR, Strauss BH, Qi X, et al. Intravascular and extravascular microvessel formation in chronic total occlusions a micro-CT imaging study. *JACC Cardiovasc Imag* 2010;3:797-805.
- [22] Srivatsa SS, Edwards WD, Boos CM, et al. Histologic correlates of angiographic chronic total coronary artery occlusions: influence of occlusion duration on neovascular channel patterns and intimal plaque composition. *J Am Coll Cardiol* 1997;29:955-963.
- [23] Cilla M, Peña E, Martínez MA, Kelly DJ. Comparison of the vulnerability risk for positive versus negative atheroma plaque morphology. *J Biomech* 2013;46:1248-1254.
- [24] Ehara M, Ehara M, Terashima M, et al. Impact of multislice computed tomography to estimate difficulty in wire crossing in percutaneous coronary intervention for chronic total occlusion. *J Invas Cardiol* 2009;21:575-582.
- [25] Luo C, Huang M, Li J, et al. Predictors of interventional success of antegrade PCI for CTO. *JACC Cardiovasc Imag* 2015;8:804-813.
- [26] Vo MN, Brilakis ES, Kass M, Ravandi A. Physiologic significance of coronary collaterals in chronic total occlusions. *Can J Physiol Pharmacol* 2015;93:867-871.
- [27] Schaper W. Collateral circulation: past and present. *Basic Res Cardiol* 2009;104:5-21.

- [28] Seiler C. Role (of assessment) of the human collateral circulation in (characterizing) ischemic adaptation to repeated coronary occlusion. *JAC* 1998;31:1698-1699.
- [29] Werner GS. The role of coronary collaterals in chronic total occlusions. *Curr Cardiol Rev* 2014;10:57-64.
- [30] Wustmann K, Zbinden S, Windecker S, Meier B, Seiler C. Is there functional collateral flow during vascular occlusion in angiographically normal coronary arteries? *Circulation* 2003;107:2213-2220.
- [31] Werner GS. Angiographic assessment of collateral connections in comparison with invasively determined collateral function in chronic coronary occlusions. *Circulation* 2003;107:1972-1977.
- [32] Werner GS, Werner GS, Emig U, et al. Regression of collateral function after recanalization of chronic total coronary occlusions: a serial assessment by intracoronary pressure and Doppler recordings. *Circulation* 2003;108:2877-2882.
- [33] Rentrop KP, Rentrop KP, Cohen M, et al. Changes in collateral channel filling immediately after controlled coronary artery occlusion by an angioplasty balloon in human subjects. *JAC* 1985;5:587-592.
- [34] Werner GS, Richartz BM, Gastmann O, Ferrari M, Figulla HR. Immediate changes of collateral function after successful recanalization of chronic total coronary occlusions. *Circulation* 2000;102:2959-2965.
- [35] Seiler C, Fleisch M, Garachemani A, Meier B. Coronary collateral quantitation in patients with coronary artery disease using intravascular flow velocity or pressure measurements. *JAC* 1998;32:1272-1279.
- [36] Pohl T, Pohl T, Seiler C, et al. Frequency distribution of collateral flow and factors influencing collateral channel development. Functional collateral channel measurement in 450 patients with coronary artery disease. *JAC* 2001;38:1872-1878.
- [37] Meier P, Gloekler S, Zbinden R, et al. Beneficial effect of recruitable collaterals: a 10-year follow-up study in patients with stable coronary artery disease undergoing quantitative collateral measurements. *Circulation* 2007;116:975-983.
- [38] Werner GS, Werner GS, Fritzenwanger M, et al. Determinants of coronary steal in chronic total coronary occlusions donor artery, collateral, and microvascular resistance. *J Am Coll Cardiol* 2006;48:51-58.
- [39] Hochman JS, Lamas GA, Buller CE, et al. Coronary intervention for persistent occlusion after myocardial infarction. *N Engl J Med* 2006;355:2395-2407.
- [40] Werner GS, Werner GS, Di Mario C, et al. Chronic total coronary occlusions and the occluded artery trial. A critical appraisal. *EuroIntervention* 2008;4:23-27.
- [41] Safley DM, Safley DM, Koshy S, et al. Changes in myocardial ischemic burden following percutaneous coronary intervention of chronic total occlusions. *Catheter Cardiovasc Interv* 2011;78:337-343.

- [42] Pujadas S, Pujadas S, Martin V, et al. Improvement of myocardial function and perfusion after successful percutaneous revascularization in patients with chronic total coronary occlusion. *Int J Cardiol* 2013;169:147-152.
- [43] Cheng ASH, Selvanayagam JB, Jerosch-Herold M, et al. Percutaneous treatment of chronic total coronary occlusions improves regional hyperemic myocardial blood flow and contractility. *J Am Coll Cardiol Interv* 2008;1:44-53.
- [44] Baks T, van Geuns R-J, Duncker DJ, et al. Prediction of left ventricular function after drug-eluting stent implantation for chronic total coronary occlusions. *J Am Coll Cardiol* 2006;47:721-725.
- [45] Kirschbaum SW, Kirschbaum SW, Rossi A, et al. Combining magnetic resonance viability variables better predicts improvement of myocardial function prior to percutaneous coronary intervention. *Int J Cardiol* 2012;159:192-197.
- [46] Opolski MP, Opolski MP, Achenbach S, et al. Coronary computed tomographic prediction rule for time-efficient guidewire crossing through chronic total occlusion: insights from the CT-RECTOR multicenter registry (Computed Tomography Registry of Chronic Total Occlusion Revascularization). *J Am Coll Cardiol Interv* 2015;8:257-267.
- [47] Opolski MP, Achenbach S. CT Angiography for revascularization of CTO. *JACC Cardiovasc Imag* 2015;8:846-858.
- [48] Magro M, Schultz C, Simsek C, et al. Computed tomography as a tool for percutaneous coronary intervention of chronic total occlusions. *EuroIntervention* 2010;6(Suppl G):G123-G131.
- [49] Soon KH, Soon KH, Cox N, et al. CT coronary angiography predicts the outcome of percutaneous coronary intervention of chronic total occlusion. *J Interv Cardiol* 2007;20:359-366.
- [50] Mollet NR, Hoyer A, Lemos PA, et al. Value of preprocedure multislice computed tomographic coronary angiography to predict the outcome of percutaneous recanalization of chronic total occlusions. *Am J Cardiol* 2005;95:240-243.
- [51] Cho JR, Kim YJ, Ahn C-M, et al. Quantification of regional calcium burden in chronic total occlusion by 64-slice multi-detector computed tomography and procedural outcomes of percutaneous coronary intervention. *Int J Cardiol* 2010;145:9-14.
- [52] Galassi AR, Galassi AR, Sumitsuji S, et al. Utility of intravascular ultrasound in percutaneous revascularization of chronic total occlusions: an overview. *JCIN* 2016;9:1979-1991.
- [53] Dato I, Hamilton-Craig C, Camaioni C, Porto I. Intracoronary imaging in chronic total occlusions. *Interv Cardiol* 2010;2:369-376.
- [54] Biondi-Zoccai GGL, Bollati M, Moretti C, et al. Retrograde percutaneous recanalization of coronary chronic total occlusions: outcomes from 17 patients. *Int J Cardiol* 2008;130:118-120.

- [55] Tsujita K, Tsujita K, Maehara A, et al. Intravascular ultrasound comparison of the retrograde versus antegrade approach to percutaneous intervention for chronic total coronary occlusions. *J Am Coll Cardiol Interv* 2009;2:846-854.
- [56] Sonoda S, Morino Y, Ako J, et al. Impact of final stent dimensions on long-term results following sirolimus-eluting stent implantation: serial intravascular ultrasound analysis from the sirius trial. *JAC* 2004;43:1959-1963.
- [57] Okabe T, Mintz GS, Buch AN, et al. Intravascular ultrasound parameters associated with stent thrombosis after drug-eluting stent deployment. *Am J Cardiol* 2007;100:615-620.
- [58] Giattina SD, Courtney BK, Herz PR, et al. Assessment of coronary plaque collagen with Polarization Sensitive Optical Coherence Tomography (PS-OCT). *Int J Cardiol* 2006;107:400-409.
- [59] Hoye A, Onderwater E, Cummins P, Sianos G, Serruys PW. Improved recanalization of chronic total coronary occlusions using an optical coherence reflectometry-guided guidewire. *Catheter Cardiovasc Interv* 2004;63:158-163.
- [60] Kinoshita I, Katoh O, Nariyama J, et al. Coronary angioplasty of chronic total occlusions with bridging collateral vessels: immediate and follow-up outcome from a large single-center experience. *JAC* 1995;26:409-415.
- [61] Shah PB. Management of coronary chronic total occlusion. *Circulation* 2011;123:1780-1784.
- [62] Abbott JD, Abbott JD, Kip KE, et al. Recent trends in the percutaneous treatment of chronic total coronary occlusions. *Am J Cardiol* 2006;97:1691-1696.
- [63] Prasad A, Galassi AR, Rihal CS, et al. Trends in outcomes after percutaneous coronary intervention for chronic total occlusions: a 25-year experience from the Mayo Clinic. *J Am Coll Cardiol* 2007;49:1611-1618.
- [64] Suero JA, Marso SP, Jones PG, et al. Procedural outcomes and long-term survival among patients undergoing percutaneous coronary intervention of a chronic total occlusion in native coronary arteries: a 20-year experience. *JAC* 2001;38:409-414.
- [65] Serruys PW. SYNTAX trial: chronic total occlusion subsets. Washington, DC: Cardiovascular Research Technologies; 2009.
- [66] Brilakis ES, Banerjee S, Karpaliotis D, et al. Procedural outcomes of chronic total occlusion percutaneous coronary intervention: a report from the NCDR (National Cardiovascular Data Registry). *J Am Coll Cardiol Interv* 2015;8:245-253.
- [67] Christopoulos G, Karpaliotis D, Alaswad K, et al. Application and outcomes of a hybrid approach to chronic total occlusion percutaneous coronary intervention in a contemporary multicenter US registry. *Int J Cardiol* 2015;198:222-228.
- [68] Kandzari DE, Kini AS, Karpaliotis D, et al. Safety and effectiveness of everolimus-eluting stents in chronic total coronary occlusion revascularization. *J Am Coll Cardiol Interv* 2015;8:761-769.

- [69] Tsuchikane E, Katoh O, Kimura M, Nasu K, Kinoshita Y, Suzuki T. The first clinical experience with a novel catheter for collateral channel tracking in retrograde approach for chronic coronary total occlusions. *J Am Coll Cardiol Interv* 2010;3:165-171.
- [70] Galassi AR, Boukhris M, Azzarelli S, Castaing M, Marzà F, Tomasello SD. Percutaneous coronary revascularization for chronic total occlusions: a novel predictive score of technical failure using advanced technologies. *J Am Coll Cardiol Interv* 2016;9:911-922.
- [71] Grantham JA, Jones PG, Cannon L, Spertus JA. Quantifying the early health status benefits of successful chronic total occlusion recanalization: results from the FlowCardia's Approach to Chronic Total Occlusion Recanalization (FACTOR) trial. *Circ Cardiovasc Qual Outcomes* 2010;3:284-290.
- [72] Noguchi T, Miyazaki S, Morii I, Daikoku S, Goto Y, Nonogi H. Percutaneous transluminal coronary angioplasty of chronic total occlusions. Determinants of primary success and long-term clinical outcome. *Catheter Cardiovasc Interv* 2000;49:258-264.
- [73] Finci L, Finci L, Meier B, et al. Long-term results of successful and failed angioplasty for chronic total coronary arterial occlusion. *Am J Cardiol* 1990;66:660-662.
- [74] Nombela-Franco L, Mitroi CD, Fernández Lozano I, et al. Ventricular arrhythmias among implantable cardioverter-defibrillator recipients for primary prevention: impact of chronic total coronary occlusion (VACTO Primary Study). *Circ Arrhythm Electrophysiol* 2012;5:147-154.
- [75] O'Connor SA, O'Connor SA, Garot P, et al. Meta-analysis of the impact on mortality of noninfarct-related artery coronary chronic total occlusion in patients presenting with ST-segment elevation myocardial infarction. *Am J Cardiol* 2015;116:8-14.
- [76] Safley DM, House JA, Marso SP, Grantham JA, Rutherford BD. Improvement in survival following successful percutaneous coronary intervention of coronary chronic total occlusions: variability by target vessel. *J Am Coll Cardiol Interv* 2008;1:295-302.
- [77] Joyal D, Afilalo J, Rinfret S. Effectiveness of recanalization of chronic total occlusions: a systematic review and meta-analysis. *Am Heart J* 2010;160:179-187.
- [78] Shan K, Constantine G, Sivananthan M, Flamm SD. Role of cardiac magnetic resonance imaging in the assessment of myocardial viability. *Circulation* 2004;109:1328-1334.
- [79] Levine GN, Bates ER, Blankenship JC, et al. 2011 ACCF/AHA/SCAI guideline for percutaneous coronary intervention. A report of the American College of Cardiology Foundation/American Heart Association Task Force on practice guidelines and the society for cardiovascular angiography and interventions. *J Am Coll Cardiol* 2011;58:e44-122.
- [80] Authors/Task Force Members, Windecker S, Kolh P, et al. 2014 ESC/EACTS guidelines on myocardial revascularization: the task force on myocardial revascularization of the European Society of Cardiology (ESC) and the European Association for Cardio-Thoracic Surgery (EACTS) * Developed with the special contribution of the European Association of Percutaneous Cardiovascular Interventions (EAPCI). *Eur Heart J* 2014;35:2541-2619.

- [81] Rathore S, Hakeem A, Pauriah M, Roberts E, Beaumont A, Morris JL. A comparison of the transradial and the transfemoral approach in chronic total occlusion percutaneous coronary intervention. *Catheter Cardiovasc Interv* 2009;73:883-887.
- [82] Rinfret S, Rinfret S, Joyal D, et al. Retrograde recanalization of chronic total occlusions from the transradial approach; early Canadian experience. *Catheter Cardiovasc Interv* 2011;78:366-374.
- [83] Holmes DR, Vlietstra RE, Reeder GS, et al. Angioplasty in total coronary artery occlusion. *JAC* 1984;3:845-849.
- [84] Kereiakes DJ, Selmon MR, McAuley BJ, McAuley DB, Sheehan DJ, Simpson JB. Angioplasty in total coronary artery occlusion: experience in 76 consecutive patients. *JAC* 1985;6:526-533.
- [85] Melchior JP, Meier B, Urban P, et al. Percutaneous transluminal coronary angioplasty for chronic total coronary arterial occlusion. *Am J Cardiol* 1987;59:535-538.
- [86] Stone GW, Rutherford BD, McConahay DR, et al. Procedural outcome of angioplasty for total coronary artery occlusion: an analysis of 971 lesions in 905 patients. *JAC* 1990;15:849-856.
- [87] Maiello L, Colombo A, Gianrossi R, et al. Coronary angioplasty of chronic occlusions: factors predictive of procedural success. *Am Heart J* 1992;124:581-584.
- [88] Serruys PW, Morice M-C, Kappetein AP, et al. Percutaneous coronary intervention versus coronary-artery bypass grafting for severe coronary artery disease. *N Engl J Med* 2009;360:961-972.
- [89] Morino Y, Abe M, Morimoto T, et al. Predicting successful guidewire crossing through chronic total occlusion of native coronary lesions within 30 minutes: the J-CTO (Multicenter CTO Registry in Japan) score as a difficulty grading and time assessment tool. *J Am Coll Cardiol Interv* 2011;4:213-221.
- [90] de Labriolle A, Bonello L, Roy P, et al. Comparison of safety, efficacy, and outcome of successful versus unsuccessful percutaneous coronary intervention in "true" chronic total occlusions. *Am J Cardiol* 2008;102:1175-1181.
- [91] Baykan AO, Gür M, Acele A, et al. Predictors of successful percutaneous coronary intervention in chronic total coronary occlusions. *Adv Interv Cardiol* 2016;12:17-24.
- [92] Tan KH, Sulke N, Taub NA, Watts E, Karani S, Sowton E. Determinants of success of coronary angioplasty in patients with a chronic total occlusion: a multiple logistic regression model to improve selection of patients. *Br Heart J* 1993;70:126-131.
- [93] Suzuki T, Hosokawa H, Yokoya K, et al. Time-dependent morphologic characteristics in angiographic chronic total coronary occlusions. *Am J Cardiol* 2001;88:167-9, A5-6.
- [94] Olivari Z, Rubartelli P, Piscione F, et al. Immediate results and one-year clinical outcome after percutaneous coronary interventions in chronic total occlusions: data from a multicenter, prospective, observational study (TOAST-GISE). *JAC* 2003;41:1672-1678.

- [95] Dong S, Smorgick Y, Nahir M, et al. Predictors for successful angioplasty of chronic totally occluded coronary arteries. *J Interv Cardiol* 2005;18:1-7.
- [96] Sapontis J, Christopoulos G, Grantham JA, et al. Procedural failure of chronic total occlusion percutaneous coronary intervention: insights from a multicenter US registry. *Catheter Cardiovasc Interv* 2015;85:1115-1122.
- [97] Rathore S, Matsuo H, Terashima M, et al. Procedural and in-hospital outcomes after percutaneous coronary intervention for chronic total occlusions of coronary arteries 2002 to 2008: impact of novel guidewire techniques. *J Am Coll Cardiol Interv* 2009;2:489-497.
- [98] Sumitsuji S, Inoue K, Ochiai M, Tsuchikane E, Ikeno F. Fundamental wire technique and current standard strategy of percutaneous intervention for chronic total occlusion with histopathological insights. *J Am Coll Cardiol Interv* 2011;4:941-951.
- [99] Danek BA, Karatasakis A, Karpaliotis D, et al. Effect of lesion age on outcomes of chronic total occlusion percutaneous coronary intervention: insights from a contemporary US multicenter registry. *Can J Cardiol* 2016;32:1433-1439.
- [100] Fefer P, Fefer P, Gannot S, et al. Impact of coronary chronic total occlusions on long-term mortality in patients undergoing coronary artery bypass grafting. *Interact Cardiovasc Thorac Surg* 2014;18:713-716.
- [101] Banerjee S, Master RG, Peltz M, et al. Influence of chronic total occlusions on coronary artery bypass graft surgical outcomes. *J Cardiac Surg* 2012;27:662-667.
- [102] Pereg D, Fefer P, Samuel M, et al. Long-term follow-up of coronary artery bypass patients with preoperative and new postoperative native coronary artery chronic total occlusion. *Can J Cardiol* 2016;32:1326-1331.
- [103] Pereg D, Fefer P, Samuel M, et al. Native coronary artery patency after coronary artery bypass surgery. *J Am Coll Cardiol Interv* 2014;7:761-767.
- [104] Mashayekhi K, Büttner HJ. Chronic coronary occlusions: when and how should revascularization be performed?. *Herz* 2016;41:585-590.
- [105] Farooq V, Serruys PW, Garcia-Garcia HM, et al. The negative impact of incomplete angiographic revascularization on clinical outcomes and its association with total occlusions: the SYNTAX (Synergy Between Percutaneous Coronary Intervention with Taxus and Cardiac Surgery) trial. *J Am Coll Cardiol* 2013;61:282-294.
- [106] Tatoulis J, Buxton BF, Fuller JA. Patencies of 2,127 arterial to coronary conduits over 15 years. *Ann Thorac Surg* 2004;77:93-101.
- [107] Shen L, Hu S, Wang H, et al. One-stop hybrid coronary revascularization versus coronary artery bypass grafting and percutaneous coronary intervention for the treatment of multivessel coronary artery disease: 3-year follow-up results from a single institution. *J Am Coll Cardiol* 2013;61:2525-2533.
- [108] Panoulas VF, Colombo A, Margonato A, Maisano F. Hybrid coronary revascularization. *J Am Coll Cardiol* 2015;65:85-97.

- [109] Karatasakis A, Karatasakis A, Danek BA, Danek BA, Brilakis ES, Brilakis ES. Scoring systems for chronic total occlusion percutaneous coronary intervention: if you fail to prepare you are preparing to fail. *J Thorac Dis* 2016;8:E1096-E1099.
- [110] Boukhris M, Mashayekhi K, Elhadj ZI, Galassi AR. Predictive scores in chronic total occlusions percutaneous recanalization: only fashionable or really useful? *J Thorac Dis* 2016;8:1037-1041.
- [111] Alessandrino G, Chevalier B, Lefevre T, et al. A clinical and angiographic scoring system to predict the probability of successful first-attempt percutaneous coronary intervention in patients with total chronic coronary occlusion. *J Am Coll Cardiol Interv* 2015;8:1540-1548.
- [112] Christopoulos G, Kandzari DE, Yeh RW, et al. Development and validation of a novel scoring system for predicting technical success of chronic total occlusion percutaneous coronary interventions: the PROGRESS CTO (Prospective Global Registry for the Study of Chronic Total Occlusion Intervention) score. *J Am Coll Cardiol Interv* 2016;9:1-9.
- [113] Karatasakis A, Danek BA, Karpaliotis D, et al. Comparison of various scores for predicting success of chronic total occlusion percutaneous coronary intervention. *Int J Cardiol* 2016;224:50-56.
- [114] Mehran R, Aymong ED, Nikolsky E, et al. A simple risk score for prediction of contrast-induced nephropathy after percutaneous coronary intervention: development and initial validation. *JAC* 2004;44:1393-1399.
- [115] Liu Y, Liu Y-H, Chen J-Y, et al. A simple pre-procedural risk score for contrast-induced nephropathy among patients with chronic total occlusion undergoing percutaneous coronary intervention. *Int J Cardiol* 2015;180:69-71.
- [116] Rubartelli P, Rubartelli P, Niccoli L, et al. Stent implantation versus balloon angioplasty in chronic coronary occlusions: results from the GISSOC trial. Gruppo Italiano di Studio sullo Stent nelle Occlusioni Coronariche. *JAC* 1998;32:90-96.
- [117] Rubartelli P, Verna E, Niccoli L, et al. Coronary stent implantation is superior to balloon angioplasty for chronic coronary occlusions: six-year clinical follow-up of the GISSOC trial. *JAC* 2003;41:1488-1492.
- [118] Tamai H, Tamai H, Berger PB, et al. Frequency and time course of reocclusion and restenosis in coronary artery occlusions after balloon angioplasty versus Wiktor stent implantation: results from the Mayo-Japan Investigation for Chronic Total Occlusion (MAJIC) trial. *Am Heart J* 2004;147:E9.
- [119] Claessen BE, Lotan C, Dangas GD, et al. Stents in total occlusion for restenosis prevention. The multicentre randomized STOP study. *Eur Heart J* 2000;21:1960-1966.
- [120] Rahel BM, Suttorp MJ, Laarman GJ, et al. Primary stenting of occluded native coronary arteries: final results of the Primary Stenting of Occluded Native Coronary Arteries (PRISON) study. *Am Heart J* 2004;147:e22.

- [121] Lotan C, Almagor Y, Kuiper K, Suttorp MJ, Wijns W. Sirolimus-eluting stent in chronic total occlusion: the SICTO study. *J Interv Cardiol* 2006;19:307-312.
- [122] Suttorp MJ, Laarman GJ, Rahel BM, et al. Primary Stenting of Totally Occluded Native Coronary Arteries II (PRISON II): a randomized comparison of bare metal stent implantation with sirolimus-eluting stent implantation for the treatment of total coronary occlusions. *Circulation* 2006;114:921-928.
- [123] Rahel BM, Laarman GJ, et al. Three-year clinical outcome after primary stenting of totally occluded native coronary arteries: a randomized comparison of bare-metal stent implantation with sirolimus-eluting stent implantation for the treatment of total coronary occlusions (Primary Stenting of Totally Occluded Native Coronary Arteries [PRISON] II study). *Am Heart J* 2009;157:149-155.
- [124] de Felice F, Fiorilli R, et al. 3-year clinical outcome of patients with chronic total occlusion treated with drug-eluting stents. *J Am Coll Cardiol Interv* 2009;2:1260-1265.
- [125] Shen ZJ, Garcia-Garcia HM, Garg S, et al. Five-year clinical outcomes after coronary stenting of chronic total occlusion using sirolimus-eluting stents: insights from the rapamycin-eluting stent evaluated at Rotterdam Cardiology Hospital-(Research) registry. *Catheter Cardiovasc Interv* 2009;74:979-986.
- [126] Han Y-L, Zhang J, Li Y, et al. Long-term outcomes of drug-eluting versus bare-metal stent implantation in patients with chronic total coronary artery occlusions. *Chin Med J* 2009;122:643-647.
- [127] Colmenarez HJ, Escaned J, Fernández C, et al. Efficacy and safety of drug-eluting stents in chronic total coronary occlusion recanalization: a systematic review and meta-analysis. *J Am Coll Cardiol* 2010;55:1854-1866.
- [128] Yang S-S, Tang L, Ge G-G, et al. Efficacy of drug-eluting stent for chronic total coronary occlusions at different follow-up duration: a systematic review and meta-analysis. *Eur Rev Med Pharmacol Sci* 2015;19:1101-1116.
- [129] Garcia-Garcia HM, Daemen J, Kukreja N, et al. Three-year clinical outcomes after coronary stenting of chronic total occlusion using sirolimus-eluting stents: insights from the rapamycin-eluting stent evaluated at rotterdam cardiology hospital – (RESEARCH) registry. *Catheter Cardiovasc Interv* 70:635-639.
- [130] Hoye A, van Domburg RT, Sonnenschein K, Serruys PW. Percutaneous coronary intervention for chronic total occlusions: the Thoraxcenter experience 1992-2002. *Eur Heart J* 2005;26:2630-2636.
- [131] Onuma Y, Serruys PW. Bioresorbable scaffold: the advent of a new era in percutaneous coronary and peripheral revascularization? *Circulation* 2011;123:779-797.
- [132] Vaquerizo B, Barros A, et al. Bioresorbable everolimus-eluting vascular scaffold for the treatment of chronic total occlusions: CTO-ABSORB pilot study. *EuroIntervention* 2015;11:555-563.

- [133] Elhendy A, Mahoney DW, Khandheria BK, Paterick TE, Burger KN, Pellikka PA. Prognostic significance of the location of wall motion abnormalities during exercise echocardiography. *J Am Coll Cardiol* 2002;40:1623-1629.
- [134] Henriques JPS. Primary percutaneous coronary intervention versus thrombolytic treatment: long term follow up according to infarct location. *Heart* 2006;92:75-79.
- [135] Claessen BE, Dangas GD, Godino C, et al. Impact of target vessel on long-term survival after percutaneous coronary intervention for chronic total occlusions. *Catheter Cardiovasc Interv* 2013;82:76-82.
- [136] Christopoulos G, Karpaliotis D, Wyman MR, et al. Percutaneous intervention of circumflex chronic total occlusions is associated with worse procedural outcomes: insights from a Multicentre US Registry. *Can J Cardiol* 2014;30:1588-1594.
- [137] Hasegawa T, Godino C, Basavarajaiah S, et al. Differences in the clinical and angiographic characteristics of chronic total occlusion lesions in the three major coronary arteries. *J Interv Cardiol* 2014;27:44-49.
- [138] van der Schaaf RJ, Vis MM, Sjauw KD, et al. Impact of multivessel coronary disease on long-term mortality in patients with ST-elevation myocardial infarction is due to the presence of a chronic total occlusion. *Am J Cardiol* 2006;98:1165-1169.
- [139] Moreno R, Moreno R, Conde C, et al. Prognostic impact of a chronic occlusion in a noninfarct vessel in patients with acute myocardial infarction and multivessel disease undergoing primary percutaneous coronary intervention. *J Invas Cardiol* 2006;18:16-19.
- [140] Aziz S, Stables RH, Grayson AD, Perry RA, Ramsdale DR. Percutaneous coronary intervention for chronic total occlusions: improved survival for patients with successful revascularization compared to a failed procedure. *Catheter Cardiovasc Interv* 2007;70:15-20.
- [141] Valenti R, Migliorini A, Signorini U, et al. Impact of complete revascularization with percutaneous coronary intervention on survival in patients with at least one chronic total occlusion. *Eur Heart J* 2008;29:2336-2342.
- [142] Lexis CPH, Rentrop KP, van der Horst ICC, et al. Impact of chronic total occlusions on markers of reperfusion, infarct size, and long-term mortality: a substudy from the TAPAS-trial. *Catheter Cardiovasc Interv* 2011;77:484-491.
- [143] Tajstra M, Gasior M, Gierlotka M, et al. Comparison of five-year outcomes of patients with and without chronic total occlusion of noninfarct coronary artery after primary coronary intervention for ST-segment elevation acute myocardial infarction. *Am J Cardiol* 2012;109:208-213.
- [144] Gierlotka M, Tajstra M, Gasior M, et al. Impact of chronic total occlusion artery on 12-month mortality in patients with non-ST-segment elevation myocardial infarction treated by percutaneous coronary intervention (from the PL-ACS Registry). *Int J Cardiol* 2013;168:250-254.

- [145] Mozid AM, Mozid AM, Mohdnazri S, et al. Impact of a chronic total occlusion in a non-infarct related artery on clinical outcomes following primary percutaneous intervention in acute ST-elevation myocardial infarction. *J Invas Cardiol* 2014;26:13-16.
- [146] Shi G, Shi G, He P, et al. Evaluation of the effect of concurrent chronic total occlusion and successful staged revascularization on long-term mortality in patients with ST-elevation myocardial infarction. *Sci World J* 2014;2014:756080-756089.
- [147] Lesiak M, Cugowska M, Araszkievicz A, et al. Impact of the presence of chronically occluded coronary artery on long-term prognosis of patients with acute ST-segment elevation myocardial infarction. *Cardiol J* 2016. [Epub ahead of print].
- [148] Claessen BE, Dangas GD, Weisz G, et al. Prognostic impact of a chronic total occlusion in a non-infarct-related artery in patients with ST-segment elevation myocardial infarction: 3-year results from the HORIZONS-AMI trial. *Eur Heart J* 2012;33:768-775.
- [149] Hoebbers LPC, Hoebbers LPC, Elias J, et al. The impact of the location of a chronic total occlusion in a non-infarct-related artery on long-term mortality in ST-elevation myocardial infarction patients. *EuroIntervention* 2016;12:423-430.
- [150] Watanabe H, Morimoto T, Shiomi H, et al. Chronic total occlusion in non-infarct-related artery is closely associated with increased five-year mortality in patients with ST-segment elevation acute myocardial infarction undergoing primary percutaneous coronary intervention (From the CREDO-Kyoto AMI registry). *EuroIntervention* 2017;12:e1874-e1882.
- [151] Henriques JPS, Hoebbers LP, Råmunddal T, et al. Percutaneous intervention for concurrent chronic total occlusions in patients with STEMI. *J Am Coll Cardiol* 2016;68:1622-1632.
- [152] Bataille Y, Bataille Y, Déry J-P, et al. Deadly association of cardiogenic shock and chronic total occlusion in acute ST-elevation myocardial infarction. *Am Heart J* 2012;164:509-515.
- [153] Hoebbers LP, Hoebbers LP, Vis MM, et al. The impact of multivessel disease with and without a co-existing chronic total occlusion on short- and long-term mortality in ST-elevation myocardial infarction patients with and without cardiogenic shock. *Eur J Heart Fail* 2013;15:425-432.
- [154] Claessen BEPM, Claessen BEPM, Hoebbers LP, et al. Prevalence and impact of a chronic total occlusion in a non-infarct-related artery on long-term mortality in diabetic patients with ST elevation myocardial infarction. *Heart* 2010;96:1968-1972.
- [155] Fujii T, Sakai K, Nakano M, et al. Impact of the origin of the collateral feeding donor artery on short-term mortality in ST-elevation myocardial infarction with comorbid chronic total occlusion. *Int J Cardiol* 2016;218:158-163.
- [156] Fujii T, Boukhris M, Nakano M, et al. Collateral filling efficiency of comorbid chronic total occlusion segment on short-term mortality in ST-elevation myocardial infarction. *Int J Cardiol* 2017;230:346-352.

- [157] Head SJ, Mack MJ, Holmes DR, et al. Incidence, predictors and outcomes of incomplete revascularization after percutaneous coronary intervention and coronary artery bypass grafting: a subgroup analysis of 3-year SYNTAX data. *Eur J Cardio-thorac Surg* 2012;41:535-541.
- [158] Hannan EL, Racz M, Holmes DR, et al. Impact of completeness of percutaneous coronary intervention revascularization on long-term outcomes in the stent era. *Circulation* 2006;113:2406-2412.
- [159] Hannan EL, Wu C, Walford G, et al. Incomplete revascularization in the era of drug-eluting stents: impact on adverse outcomes. *J Am Coll Cardiol Interv* 2009;2:17-25.
- [160] Shaw LJ, Berman DS, Maron DJ, et al. Optimal medical therapy with or without percutaneous coronary intervention to reduce ischemic burden: results from the Clinical Outcomes Utilizing Revascularization and Aggressive Drug Evaluation (COURAGE) trial nuclear substudy. *Circulation* 2008;117:1283-1291.
- [161] Garcia S, Sandoval Y, Roukoz H, et al. Outcomes after complete versus incomplete revascularization of patients with multivessel coronary artery disease: a meta-analysis of 89,883 patients enrolled in randomized clinical trials and observational studies. *J Am Coll Cardiol* 2013;62:1421-1431.
- [162] Migliorini A, Migliorini A, Valenti R, et al. The impact of right coronary artery chronic total occlusion on clinical outcome of patients undergoing percutaneous coronary intervention for unprotected left main disease. *J Am Coll Cardiol* 2011;58:125-130.
- [163] Godino C, Latib A, Economou FI, et al. Coronary chronic total occlusions: mid-term comparison of clinical outcome following the use of the guided-STAR technique and conventional anterograde approaches. *Catheter Cardiovasc Interv* 2012;79:20-27.
- [164] Isaaq K, Gerbay A, Terreaux J, et al. Restenosis after percutaneous coronary intervention for coronary chronic total occlusion. The central role of an optimized immediate post-procedural angiographic result. *Int J Cardiol* 2016;224:343-347.
- [165] Valenti R, Vergara R, Migliorini A, et al. Predictors of reocclusion after successful drug-eluting stent-supported percutaneous coronary intervention of chronic total occlusion. *J Am Coll Cardiol* 2013;61:545-550.
- [166] la Torre Hernandez de JM, Rumoroso JR, Subinas A, et al. Percutaneous intervention in chronic total coronary occlusions caused by in-stent restenosis. Procedural results and long term clinical outcomes in the TORO (spanish registry of chronic TOtal occlusion secondary to an occlusive in stent RestenOsis) multicenter registry. *EuroIntervention* 2016. [Epub ahead of print].
- [167] Ge L, Iakovou I, Cosgrave J, et al. Immediate and mid-term outcomes of sirolimus-eluting stent implantation for chronic total occlusions. *Eur Heart J* 2005;26:1056-1062.
- [168] Migliorini A, Moschi G, Vergara R, Parodi G, Carrabba N, Antoniucci D. Drug-eluting stent-supported percutaneous coronary intervention for chronic total coronary occlusion. *Catheter Cardiovasc Interv* 67:344-348.

- [169] Galassi AR, Tomasello SD, Costanzo L, Campisano MB, Barrano G, Tamburino C. Long-term clinical and angiographic results of sirolimus-eluting stent in complex coronary chronic total occlusion revascularization: the SECTOR registry. *J Interv Cardiol* 24:426-436.
- [170] Isaz K, Mayaud N, Gerbay A, et al. Long-term clinical outcome and routine angiographic follow-up after successful recanalization of complex coronary true chronic total occlusion with a long stent length: a single-center experience. *J Invas Cardiol* 2013;25:323-329.
- [171] Park H-J, Kim HY, Lee J-M, et al. Randomized comparison of the efficacy and safety of otarolimus-eluting stents vs. sirolimus-eluting stents for percutaneous coronary intervention in chronic total occlusion. *Circ J* 2012;76:868-875.
- [172] Rubartelli P, Petronio AS, Guiducci V, et al. Comparison of sirolimus-eluting and bare metal stent for treatment of patients with total coronary occlusions: results of the GISSOC II-GISE multicentre randomized trial. *Eur Heart J* 2010;31:2014-2020.
- [173] Kelbæk H, Helqvist S, Thuesen L, et al. Sirolimus versus bare metal stent implantation in patients with total coronary occlusions: subgroup analysis of the Stenting Coronary Arteries in Non-Stress/Benestent Disease (SCANDSTENT) trial. *Am Heart J* 2006;152:882-886.
- [174] Lim MCL. Antegrade techniques for chronic total occlusions. *Curr Cardiol Rev* 2015;11:285.
- [175] Touma G, Ramsay D, Weaver J. Chronic total occlusions – current techniques and future directions. *IJC Heart Vasc* 2015;7:28-39.
- [176] Maeremans J, Maeremans J, Walsh S, et al. The hybrid algorithm for treating chronic total occlusions in Europe. *JAC* 2016;68:1958-1970.
- [177] Colombo A, Mikhail GW, Michev I, et al. Treating chronic total occlusions using subintimal tracking and reentry: the STAR technique. *Catheter Cardiovasc Interv* 2005;64:407-411; discussion 412.
- [178] Galassi AR, Galassi AR, Tomasello SD, et al. Mini-STAR as bail-out strategy for percutaneous coronary intervention of chronic total occlusion. *Catheter Cardiovasc Interv* 2012;79:30-40.
- [179] Brilakis ES, Banerjee S. Dancing with the “STAR”: the role of subintimal dissection/re-entry strategies in coronary chronic total occlusion interventions. *Catheter Cardiovasc Interv* 2012;79:28-29.
- [180] Whitlow PL, Burke MN, Lombardi WL, et al. Use of a novel crossing and re-entry system in coronary chronic total occlusions that have failed standard crossing techniques: results of the FAST-CTOs (Facilitated Antegrade Steering Technique in Chronic Total Occlusions) trial. *J Am Coll Cardiol Intv* 2012;5:393-401.
- [181] Mogabgab O, Patel VG, Michael TT, et al. Long-term outcomes with use of the CrossBoss and stingray coronary CTO crossing and re-entry devices. *J Invas Cardiol* 2013;25:579-585.

- [182] Joyal D, Thompson CA, Grantham JA, Buller CEH, Rinfret S. The retrograde technique for recanalization of chronic total occlusions: a step-by-step approach. *J Am Coll Cardiol Interv* 2012;5:1-11.
- [183] Sabbagh El A, Patel VG, Jeroudi OM, et al. Angiographic success and procedural complications in patients undergoing retrograde percutaneous coronary chronic total occlusion interventions: a weighted meta-analysis of 3,482 patients from 26 studies. *Int J Cardiol* 2014;174:243-248.
- [184] Kotsia A, Christopoulos G, Brilakis ES. Use of the retrograde approach for preserving the distal bifurcation after antegrade crossing of a right coronary artery chronic total occlusion. *J Invas Cardiol* 2014;26:E48-E49.
- [185] Rathore S, Katoh O, Matsuo H, et al. Retrograde percutaneous recanalization of chronic total occlusion of the coronary arteries: procedural outcomes and predictors of success in contemporary practice. *Circ Cardiovasc Interv* 2009;2:124-132.
- [186] Karpaliotis D, Michael TT, Brilakis ES, et al. Retrograde coronary chronic total occlusion revascularization: procedural and in-hospital outcomes from a multicenter registry in the United States. *J Am Coll Cardiol Interv* 2012;5:1273-1279.
- [187] Brilakis ES, Brilakis ES, Banerjee S, Banerjee S, Lombardi WL, Lombardi WL. Retrograde recanalization of native coronary artery chronic occlusions via acutely occluded vein grafts. *Catheter Cardiovasc Interv* 2010;75:109-113.
- [188] Otsuji S, Otsuji S, Terasoma K, Terasoma K, Takiuchi S, Takiuchi S. Retrograde recanalization of a left anterior descending chronic total occlusion via an ipsilateral intraseptal collateral. *J Invas Cardiol* 2008;20:312-316.
- [189] Tsuchikane E, Yamane M, Mutoh M, et al. Japanese multicenter registry evaluating the retrograde approach for chronic coronary total occlusion. *Catheter Cardiovasc Interv* 2013;82:E654-E661.
- [190] Mashayekhi K, Behnes M, Valuckiene Z, et al. Comparison of the ipsi-lateral versus contra-lateral retrograde approach of percutaneous coronary interventions in chronic total occlusions. *Catheter Cardiovasc Interv* 2017;89:649-655.
- [191] Kimura M, Kimura M, Katoh O, et al. The efficacy of a bilateral approach for treating lesions with chronic total occlusions the CART (controlled antegrade and retrograde subintimal tracking) registry. *J Am Coll Cardiol Interv* 2009;2:1135-1141.
- [192] Galassi AR, Sianos G, Werner GS, et al. Retrograde recanalization of chronic total occlusions in Europe: procedural, in-hospital, and long-term outcomes from the multicenter ERCTO registry. *J Am Coll Cardiol* 2015;65:2388-2400.
- [193] Patel VG, Michael TT, Mogabgab O, et al. Clinical, angiographic, and procedural predictors of periprocedural complications during chronic total occlusion percutaneous coronary intervention. *J Invas Cardiol* 2014;26:100-105.

- [194] Brilakis ES, Grantham JA, Rinfret S, et al. A percutaneous treatment algorithm for crossing coronary chronic total occlusions. *JCIN* 2012;5:367-379.
- [195] Michael TT, Mogabgab O, Fuh E, et al. Application of the “hybrid approach” to chronic total occlusion interventions: a detailed procedural analysis. *J Interv Cardiol* 2014;27:36-43.
- [196] Michael TT, Michael TT, Papayannis A, et al. Subintimal dissection/re-entry strategies in coronary chronic total occlusion interventions. *Circ Cardiovasc Interv* 2012;5:729-738.
- [197] Rinfret S, Ribeiro HB, Nguyen CM, Nombela-Franco L, Ureña M, Rodés-Cabau J. Dissection and re-entry techniques and longer-term outcomes following successful percutaneous coronary intervention of chronic total occlusion. *Am J Cardiol* 2014;114:1354-1360.
- [198] Ricciardi MJ, Wu E, Davidson CJ, et al. Visualization of discrete microinfarction after percutaneous coronary intervention associated with mild creatine kinase-MB elevation. *Circulation* 2001;103:2780-2783.
- [199] Selvanayagam JB. Troponin elevation after percutaneous coronary intervention directly represents the extent of irreversible myocardial injury: insights from cardiovascular magnetic resonance imaging. *Circulation* 2005;111:1027-1032.
- [200] Galassi AR, Tomasello SD, Reifart N, et al. In-hospital outcomes of percutaneous coronary intervention in patients with chronic total occlusion: insights from the ERCTO (European Registry of Chronic Total Occlusion) registry. *EuroIntervention* 2011;7:472-479.
- [201] Lo N, Michael TT, Moin D, et al. Periprocedural myocardial injury in chronic total occlusion percutaneous interventions: a systematic cardiac biomarker evaluation study. *J Am Coll Cardiol Interv* 2014;7:47-54.
- [202] Kim SM, Gwon H-C, Lee HJ, et al. Periprocedural myocardial infarction after retrograde approach for chronic total occlusion of coronary artery: demonstrated by cardiac magnetic resonance imaging. *Korean Circ J* 2011;41:747-749.
- [203] Werner GS, Coenen A, Tischer K-H. Periprocedural ischaemia during recanalisation of chronic total coronary occlusions: the influence of the transcollateral retrograde approach. *EuroIntervention* 2014;10:799-805.
- [204] Paizis I, Manginas A, Voudris V, Pavlides G, Spargias K, Cokkinos DV. Percutaneous coronary intervention for chronic total occlusions: the role of side-branch obstruction. *EuroIntervention* 2009;4:600-606.
- [205] Lee S-W, Lee PH, Kang SH, et al. Determinants and prognostic significance of periprocedural myocardial injury in patients with successful percutaneous chronic total occlusion interventions. *J Am Coll Cardiol Interv* 2016;9:2220-2228.
- [206] Chen S-L, Zhang J-J, Ye F, et al. Periprocedural myocardial infarction is associated with increased mortality in patients with coronary artery bifurcation lesions after implantation of a drug-eluting stent. *Catheter Cardiovasc Interv* 2015;85(Suppl 1):696-705.

- [207] Park D-W, Kim Y-H, Yun S-C, et al. Frequency, causes, predictors, and clinical significance of peri-procedural myocardial infarction following percutaneous coronary intervention. *Eur Heart J* 2013;34:1662-1669.
- [208] Topol EJ, Yadav JS. Recognition of the Importance of embolization in atherosclerotic vascular disease. *Circulation* 2000;101:570-580.
- [209] Bhatt DL. Does creatinine kinase-MB elevation after percutaneous coronary intervention predict outcomes in 2005? *Circulation* 2005;112:906-915.
- [210] Choi J-H, Chang S-A, Choi J-O, et al. Frequency of myocardial infarction and its relationship to angiographic collateral flow in territories supplied by chronically occluded coronary arteries clinical perspective. *Circulation* 2013;127:703-709.
- [211] Brilakis ES, Karpaliotis D, Patel V, Banerjee S. Complications of chronic total occlusion angioplasty. *Interv Cardiol Clin* 2012;1:373-389.
- [212] Dash D. Complications encountered in coronary chronic total occlusion intervention: prevention and bailout. *Indian Heart J* 2016;68:737-746.
- [213] Godino C, Sharp ASP, Carlino M, Colombo A. Crossing CTOs-the tips, tricks, and specialist kit that can mean the difference between success and failure. *Catheter Cardiovasc Interv* 2009;74:1019-1046.
- [214] Buller CE. Coronary guidewires for chronic total occlusion procedures: function and design. *Interv Cardiol* 2013;5:533-540.
- [215] Brilakis ES, Pereg D, Lombardi WB, et al. Use of the stingray guidewire and the venture catheter for crossing flush coronary chronic total occlusions due to in-stent restenosis. *Catheter Cardiovasc Interv* 2010;76:391-394.
- [216] Werner GS, Werner GS. The BridgePoint devices to facilitate recanalization of chronic total coronary occlusions through controlled subintimal reentry. *Expert Rev Med Devices* 2011;8:23-29.
- [217] Brilakis ES, Badhey N, Banerjee S. "Bilateral knuckle" technique and Stingray re-entry system for retrograde chronic total occlusion intervention. *J Invas Cardiol* 2011;23:E37-E39.
- [218] Nicholson W, Harvey J, Dhawan R. E-CART (ElectroCautery-Assisted Re-enTry) of an aorto-ostial right coronary artery chronic total occlusion: first-in-man. *J Am Coll Cardiol Intv* 2016;9:2356-2358.
- [219] Garcia-Garcia HM, Kukreja N, Daemen J, et al. Contemporary treatment of patients with chronic total occlusion: critical appraisal of different state-of-the-art techniques and devices. *EuroIntervention* 2007;3:188-196.
- [220] Mehran R, Claessen BE, Godino C, et al. Long-term outcome of percutaneous coronary intervention for chronic total occlusions. *J Am Coll Cardiol Intv* 2011;4:952-961.

- [221] Jones DA, Weerackody R, Rathod K, et al. Successful recanalization of chronic total occlusions is associated with improved long-term survival. *J Am Coll Cardiol Intv* 2012;5:380-388.
- [222] Lee PH, Lee S-W, Park H-S, et al. Successful recanalization of native coronary chronic total occlusion is not associated with improved long-term survival. *J Am Coll Cardiol Intv* 2016;9:530-538.
- [223] Råmunddal T, Hoebers LP, Henriques JPS, et al. Prognostic impact of chronic total occlusions: a report from SCAAR (Swedish Coronary Angiography and Angioplasty Registry). *J Am Coll Cardiol Intv* 2016;9:1535-1544.
- [224] Khan MF, Wendel CS, Thai HM, Movahed MR. Effects of percutaneous revascularization of chronic total occlusions on clinical outcomes: a meta-analysis comparing successful versus failed percutaneous intervention for chronic total occlusion. *Catheter Cardiovasc Interv* 2013;82:95-107.
- [225] Christakopoulos GE, Christopoulos G, Carlino M, et al. Meta-analysis of clinical outcomes of patients who underwent percutaneous coronary interventions for chronic total occlusions. *Am J Cardiol* 2015;115:1367-1375.
- [226] White HD, Braunwald E. Applying the open artery theory: use of predictive survival markers. *Eur Heart J* 1998;19:1132-1139.
- [227] Fujita S, Tamai H, Kyo E, et al. New technique for superior guiding catheter support during advancement of a balloon in coronary angioplasty: the anchor technique. *Catheter Cardiovasc Interv* 2003;59:482-488.
- [228] Lombardi WL. Retrograde PCI: what will they think of next? *J Invas Cardiol* 2009;21:543.
- [229] Dautov R, Ureña M, Nguyen CM, Gibrat C, Rinfret S. Safety and effectiveness of the surfing technique to cross septal collateral channels during retrograde chronic total occlusion percutaneous coronary intervention. *EuroIntervention* 2017;12:e1859-e1867.
- [230] Vo MN, Ravandi A, Brilakis ES. "Tip-in" technique for retrograde chronic total occlusion revascularization. *J Invas Cardiol* 2015;27:E62-E64.
- [231] Surmely J-F, Tsuchikane E, Katoh O, et al. New concept for CTO recanalization using controlled antegrade and retrograde subintimal tracking: the CART technique. *J Invas Cardiol* 2006;18:334-338.
- [232] Zhang B, Zhang B, Wong A, Wong A. The confluent balloon technique for retrograde therapy of chronic total occlusion. *Catheter Cardiovasc Interv* 2011;78:60-64.
- [233] Carlino M, Azzalini L, Colombo A. A novel maneuver to facilitate retrograde wire externalization during retrograde chronic total occlusion percutaneous coronary intervention. *Catheter Cardiovasc Interv* 2017;89:E7-E12.