

We are IntechOpen, the world's leading publisher of Open Access books Built by scientists, for scientists

4,800

Open access books available

122,000

International authors and editors

135M

Downloads

Our authors are among the

154

Countries delivered to

TOP 1%

most cited scientists

12.2%

Contributors from top 500 universities



WEB OF SCIENCE™

Selection of our books indexed in the Book Citation Index
in Web of Science™ Core Collection (BKCI)

Interested in publishing with us?
Contact book.department@intechopen.com

Numbers displayed above are based on latest data collected.
For more information visit www.intechopen.com



Nerve Transfers in the Treatment of Peripheral Nerve

Injuries

Vicente Vanaclocha-Vanaclocha,

Jose María Ortiz-Criado, Nieves Sáiz-Sapena and

Nieves Vanaclocha

Additional information is available at the end of the chapter

<http://dx.doi.org/10.5772/67948>

Abstract

Successful re-innervation of proximal limb peripheral nerve injuries is rare. Axons regenerate at ~1 mm/day, reaching hand muscles by 24 months, finding them atrophied and fibrosed. Peripheral nerve injury repair is often delayed waiting for spontaneous recovery. This waiting time should not be longer than 6 months as after 18 months reinnervation will not achieve effective muscular function. When spontaneous recovery is impossible, referral too late or damage too severe, other options like a transfer from a nearby healthy nerve to the injured one must be considered. They are very successful, and the deficit in the donor site is usually minimal. The most common nerve transfers are a branch of the spinal nerve to the trapezius muscle to the suprascapular nerve, a branch of the long head of the triceps to the axillary nerve, a fascicle of the ulnar nerve to the motor branch of the biceps muscle, two branches of the median nerve to the posterior interosseous nerve and the anterior interosseous nerve to the ulnar nerve. There are many more options that can suit particular cases. Introduced in brachial plexus injury repair, they are now also applied to lower limb, to stroke and to some spinal cord injuries.

Keywords: peripheral nerve injuries, brachial plexus injuries, nerve transfers, nerve regeneration, supercharge end-to-side, nerve repair, nerve graft

1. Introduction

Peripheral nerve injuries can represent a serious problem, particularly when involving the brachial plexus. They usually induce devastating consequences and affect young people [1]. The main cause is traffic accidents.

Motor endplate degeneration starts just after a motor nerve is injured. The growth speed of the regenerating axons is ~1 mm/day [2]. The time needed for the regeneration will be proportional the distance between the injury site and the muscle endplates [3, 4]. Proximal limb peripheral nerve injuries pose severe difficulties to a successful re-innervation because of the long distance regenerating axons have to cover [3], taking up to 24 months to reach hands or feet [2, 5, 6], often finding them atrophied and substituted by fat and fibrous tissue [7–9].

Peripheral nerve injury repair is often delayed waiting for spontaneous recovery. This waiting time should be no longer than 6 months [10] as after 18 months successful re-innervation will not achieve effective muscular function [11–14].

Nerve grafts are often required [15, 16]. Unfortunately, their use is associated with worse results than direct repair [17], particularly in grafts longer than 7.2 cm [1, 18]. This occurs because the regenerating nerve fibres must cross two anastomoses instead of just one. The second anastomose site is reached much later with more fibrosis hindering the nerve fibre growth to cross it [19]. Another reason for this is that only autologous sensory nerves are used as grafts to minimize donor site deficits [20]. It has been shown that using sensory nerve grafts to repair motor nerve defects is associated with worse regeneration results than if motor nerves are repaired with motor nerve grafts [21].

Direct repair is not always possible: when there is no chance of spontaneous recovery (i.e. root avulsion), the referral is too late, the damage is too severe, the scarring at the injury site is significant, presence of large neuromas in continuity or in multilevel nerve injuries [22]. In these cases, a nerve transfer from a nearby healthy nerve is a superior option. A healthy nerve is transected and coapted to a nearby injured one. This transforms a proximal nerve injury into a distal one near the motor endplates, reducing the time required for re-innervation [10, 13]. Unfortunately, the functional improvement is at the expense of reducing the number of functioning nerves [23]. Obviously, the function lost must be less essential than the one we expect to recover [24]. They yield better results than direct nerve repairs, particularly in proximal limb injuries and when a nerve graft is needed [9, 25, 26]. With good surgical planning the deficits induced on transecting the donor nerve are minimal [13, 24].

Distal nerve transfers in proximal nerve injuries reduce the time muscles are denervated, thus improving the outcomes [24, 27]. Nevertheless, the best results are obtained with simultaneous proximal nerve injury repair and distal nerve transfers [9] as this combination re-innervates more muscles [9].

Nerve transfers offer better results than tendon transfers [28]. They preserve the original anatomical situation of muscles and tendons, allowing a much better physiological function [11, 12, 14, 22, 29, 30]. Moreover, nerve transfers can re-innervate more than one muscle and thus

recover more than one function [11, 29, 31, 32] while tendon transfers are limited to a single one [28]. Although initially introduced to repair peripheral nerve injuries, they are lately also being used in some cases of spinal cord injury (SCI) or stroke [33].

The mismatch between donor and recipient nerves is common (the first has fewer motor axons than the second). This is seldom a problem because a 20% of motor axons are enough to re-innervate the whole muscle [34, 35].

This means that each motor axon can increase up to five times the amount of muscle fibres it innervates [36].

Thus, it is possible to re-innervate a big nerve with a smaller branch but it comes at the price of courser movements [34]. A reduced number of axons can successfully re-innervate a muscle provided it is done on time [37].

Nerve transfer indications: irrecoverable proximal nerve injury (i.e. root avulsion) [38], if a long nerve graft is required (over 7.2 cm results are dismal) [1, 18], long distance between injury site and motor endplates [5], late presentation [8], very wide injury and dense scar tissue [10].

Nerve transfer contraindications: existence of a better option, time since injury over 18 months [5] and motor donor strength below Medical Research Council (MRC) grade M4 [12].

Ideal donor nerve: purely motor or sensory, containing enough axons to re-innervate the recipient muscles, its diameter is similar to the recipient nerve, requires no nerve graft, innervates expendable muscles [24, 39–41], and has synergistic function with the recipient nerve [10, 12, 13, 22, 27, 33]. The functional loss created on taking the donor should be less important than the functional recovery expected on re-innervating the recipient [24, 42]. Post-operative rehabilitation is easier when donor and recipient nerves have a synergistic action [22, 27, 32]. In the case of antagonistic action, much more post-operative re-education will be needed to recover the same amount of function [27]. The recovery of muscle power depends on the amount of motor axons provided by the donor nerve [13, 27, 35] and on the time elapsed until re-innervation happens [13, 29]. It is known that a muscle generates a normal power until about 80% of the motor axons are lost, but afterwards, there is a sharp loss [34]. Thus, it is crucial to be above this 20% [19, 27].

To allow a tension-free repair, essential for a successful recovery, the donor nerve must be transected as distally as possible and the recipient nerve as proximally as feasible [14, 15, 31].

Nerve transfer advantages: shorter distance between donor healthy nerve and denervated muscle endplates, safe supply of viable axons, usually no nerve graft needed, selection of pure motor or sensory axons, possibility to recover more than one function and no scar in the surgical field [13, 22, 27].

Nerve transfer disadvantages: a function has to be sacrificed, donor site morbidity, donor and recipient muscle co-contraction and possibility of previous donor nerve injury [27].

Donor site morbidity: shown in the spinal accessory (SAN) to suprascapular nerve (SSN) transfer. The weakness of the middle and lower part of the trapezius muscle (donor site) induces mild scapular winging in the case of good recovery of shoulder external rotation.

Co-contraction: it can be useful in the case of synergistic action between donor and recipient muscles. This is the case in the SAN to SSN transfer as the trapezius is synergistic with the supraspinatus and infraspinatus action. In most other cases it is an inconvenience [22, 24, 43, 44]. For example, in the Oberlin procedure (a fascicle of the ulnar nerve (UN) is transferred to the biceps muscle (BM) nerve branch), there is a tendency for finger flexion when attempting elbow flexion [45]. This is also the case of medial pectoral nerve (MPN) to musculocutaneous nerve (MCN) transfer in which elbow flexion is associated with shoulder adduction [45]. A more dramatic example is phrenic nerve (PHN) to radial nerve (RAN) transfer as patients must take a deep breath before attempting hand extension [44, 46]. In some cases, it is so serious that it can make the procedure useless (i.e. contralateral C₇ nerve root transfer) [43].

Previous damage to the donor nerve: it is always a possibility as muscle weakness is only clinically evident when at least 50% of the motor axons are lost [45]. It may explain the variability in the clinical outcomes [45, 47].

An adequate *post-operative rehabilitation* is a vital element in the final outcome and relies on cerebral plasticity in which neurons are assigned to new tasks [4, 48].

Initially, motor nerve transfers were the main concern. Over time it became obvious that sensory recovery is also essential as it allows a better motor control and avoids trophic ulcers [49–52]. This leads to the introduction of sensory nerve transfers [50, 52].

Nerve transfers were first used in the upper limbs but with time have also been applied to the lower limbs.

1.1. History

Balance in 1903 was the first to report a nerve transfer (SAN to facial nerve) [53] but it was Tuttle in 1913 the first to use them to repair brachial plexus injuries [54]. Vulpius and Stoffel [55] in 1920 described the use of the MPN as donor nerve [56]. Harris in 1921 reported the RAN to median nerve (MN) transfer [57]. Förster [58] in 1929 transferred the thoracodorsal (TDN) and subscapular nerves to the axillary nerve (AXN). Lurje in 1948 transferred the pectoral and TDN nerves to the MCN [59]. Seddon in 1963 described the use of the intercostal nerves (ICNs) as donor nerves [16]. Samardzic et al. in 1980 performed the first double nerve transfer, pectoral to AXN and TDN to MCN [60]. Bedeschi et al. in 1984 introduced the sensory nerve transfers [61]. Novak and Mackinnon in 1991 reported the pronator *quadratus* (PQ) to UN motor fascicle transfer in proximal ulnar nerve lesions [62]. Brandt and Mackinnon [63] in 1993 reported their experience with pectoral to MCN transfer and Oberlin et al. [64] in 1994 reported the UN to biceps muscle nerve (BMN) transfer. Ever since, many nerve transfers have been reported. Experience has settled the indications and outcomes of each of them. Mastering all of them allows adaptation to all circumstances as the ideal donor is not always available.

1.2. Types of nerve transfers

Attending to the nerves involved they can be classified as motor or sensory. The *motor transfers* aim to recover movement and to avoid subluxation (common in a denervated shoulder) [24].

The *sensory transfers* aim to recover, at least, protective sensation, avoiding skin ulcerations [52]. The sensory recovery, even if partial, will help with neuropathic pain control [12, 65].

End-to-end anastomosis: The distal stump of the donor nerve is coapted with the proximal stump of the recipient one. It is the best option for all nerve transfers, and the only successful one in motor restoration [66].

End-to-side anastomosis: The proximal end of an injured nerve is coapted to the side of a healthy one after creating an epineurial window in it [67]. The idea is that the axons of the healthy nerve create lateral sprouts that grow inside the damaged one. Although axons can travel in the epineurial space of rabbit nerves [18], in humans the epineurial window is essential to achieve axonal regeneration [68]. Sensory axons will spontaneously sprout from the healthy into the injured nerve, providing a kind of protective sensation, although it is never fully normal [11, 65, 66]. Meanwhile, donor nerve motor axons need an injury (crush or axotomy) to sprout inside an end-to-side coapted damaged nerve [66, 69]. It can be useful for sensory nerves but not for motor ones.

Reverse end-to-side or 'supercharge' end-to-side anastomosis: A healthy nerve is transected and coapted to the side of a damaged one [70]. The idea is that the axons of the healthy nerve grow inside the injured one. It provides a fast muscle re-innervation with preservation of the muscle bulk until the axons of the damaged nerve regenerate and reach their own endplates [66]. This avoids muscle atrophy while the injured nerve axons regenerate [71]. It has been used successfully in the case of anterior interosseous nerve (AIN) to motor fascicle of the UN transfer [52].

Single nerve transfer is when only one transfer is performed. *Dual nerve transfer* relates to the use of two different transfers to achieve the same function (i.e. shoulder abduction, elbow flexion, etc.).

In a *direct nerve transfer* donor and recipient nerves are coapted directly with no graft interposed. A tension-free suture is essential for a successful recovery [30].

2. Upper limb nerve transfers

The main goals of *upper limb re-innervation*, in order of importance, are as follows: (1) elbow flexion, (2) shoulder abduction and external rotation, (3) scapular stabilization, (4) elbow extension, (5) hand function and (6) sensory recovery in critical hand areas.

In *tetraplegic patients*, the most common *nerve transfers* are: *teres minor* nerve (TMN) to TLH nerve to recover elbow extension, *supinator* nerves (SNs) to PIN for hand and finger extension, ECRB to *flexor pollicis longus* nerve (FPLN) to recover thumb and index finger flexion and *brachialis* nerve branch (BCN) to AIN for thumb, index and middle finger flexion.

2.1. Scapular nerve transfers

Long thoracic nerve (LTN) damage is associated with scapular winging. To correct it one of the two branches of the *thoracodorsal nerve* (TDN) can be *coapted with the LTN* [72] (**Figure 1**). The re-innervation of the *serratus anterior* muscle (SAM) improves shoulder function [73].

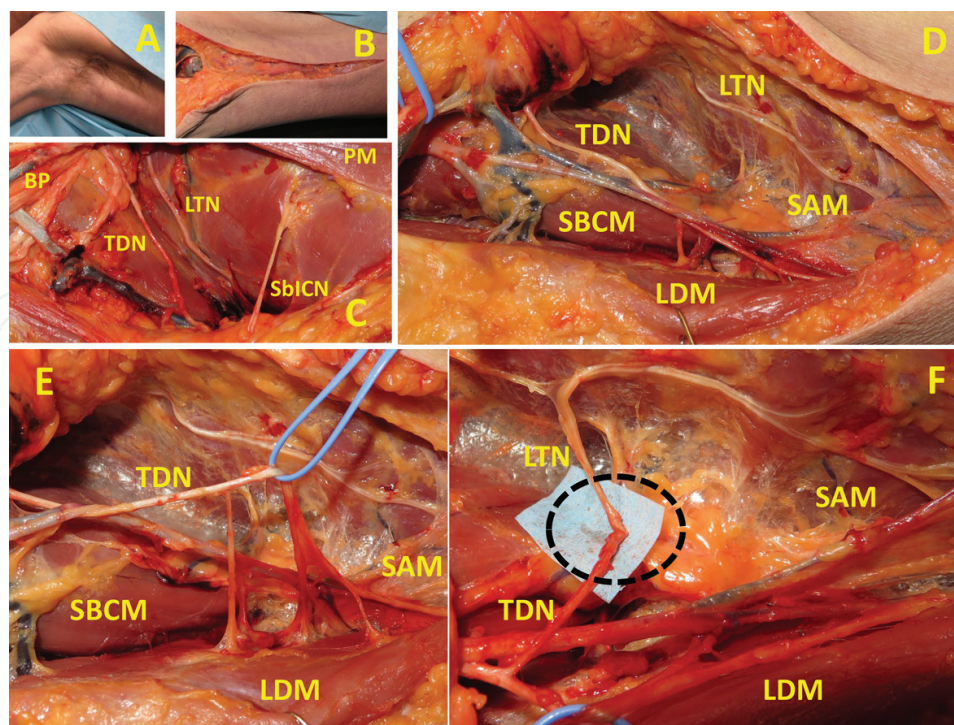


Figure 1. Thoracodorsal (TDN) to long thoracic nerve (LTN) transfer. One of the branches of the TDN is transferred to the LTN. Brachial plexus (BP), pectoralis minor muscle (PMM), sensory branch intercostal nerve (SbicN), subscapular muscle (SBCM), serratus anterior muscle (SAM), latissimus dorsi muscle (LDM).

2.2. Shoulder nerve transfers

Recovery of shoulder function is the second priority in brachial plexus injury. Shoulder abduction can be recovered with the *double nerve transfer* SAN branch for the trapezius to SSN together with TLH nerve to the AXN [45]. This dual shoulder transfers offer much better results than just one of them [17, 30].

In the *SAN to SSN transfer*, the distal branch of the SAN destined to the lower part of the trapezius muscle is transferred to the SSN, leaving the superior branches intact [38]. Results are much better with no nerve grafts interposed [17, 74]. As distal injury to the SSN can be present in addition to a more proximal brachial plexus damage, some recommend to dissect the SAN as distally as possible and to make the coaptation with the SSN as close as possible to the suprascapular notch [75, 76]. This transfer can be performed through an anterior or a posterior approach (**Figures 2 and 3**). In some, the posterior approach is better, as a smaller part of the trapezius muscle is denervated [77, 78]. Others disagree because it is technically difficult and because it cannot be done through a regular brachial plexus exploration [76], lengthening the surgical procedure [75]. The SAN should be used as a donor with caution if the *serratus anterior* muscle (SAM) is also paralysed for the risk of scapular winging [45].

First described by Lurje [79] in 1948, the *RAN to AXN transfer* was popularized by Leechavengvongs et al. [80] in 2003. There is no agreement on which is the best RAN branch to use [14, 38, 80]. Some surgeons report that, it is the TLH branch because it contains more motor axons, being the medial branch its alternative [81], but others think the opposite because

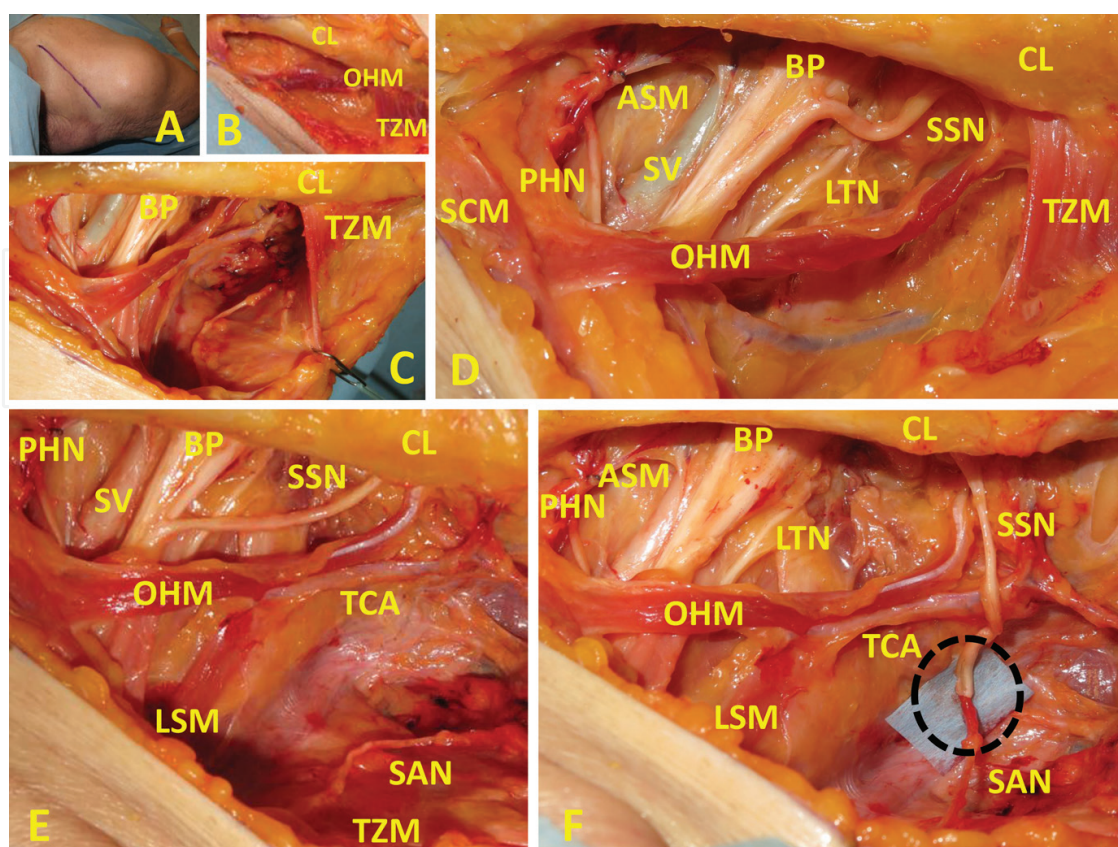


Figure 2. Spinal accessory (SAN) to suprascapular nerve (SSN) transfer (anterior approach). Sternocleidomastoid muscle (SCM), trapezius muscle (TTM), omohyoid muscle (OHM), brachial plexus (BP), anterior scalene muscle (ASM), clavicle (CL), phrenic nerve (PHN), transverse cervical artery (TCA), subclavian vein (SV), levator scapulae muscle (LSM).

as the TLH muscle inserts in the scapula it is part of the scapulohumeral joint [24] and because the medial head is longer and easier to isolate [82]. The results in shoulder abduction are good, particularly if combined with an SAN to SSN transfer [17, 38, 80]. As the recovery of shoulder external rotation is unsatisfactory [75, 83], many recommend to include the TMN in the transfer [38, 77, 80, 84]. The TLH to AXN transfer can be done through posterior to anterior approaches (Figures 4 and 5). The first one is the most widespread [85, 86], but the second is ideal if an Oberlin procedure is planned [87]. Both approaches show similar clinical outcomes [85, 87].

Other donor nerves that have been used to re-innervate the SSN and AXN are the C₃ and C₄ anterior rami [88], ICNs [89–92], TDN [60], MPN [93, 94], LTN [95], PHN [96], subscapular nerve [97], rhomboid nerve [98], ipsilateral or contralateral C₇ nerve root [99] and hypoglossal nerve [100]. They can be used but only if the SAN to SSN and TLH to AXN transfers are not possible, as their clinical outcome is unsatisfactory [17, 22].

2.3. Elbow flexion nerve transfers

This is the priority in brachial plexus injuries. First reported in 1994 [64], the *Oberlin procedure* is the transfer of the UN fascicle for the *flexor carpi ulnaris* (FCU) to the biceps muscle nerve (BMN) branch. To improve the results, some recommended a double nerve transfer adding the

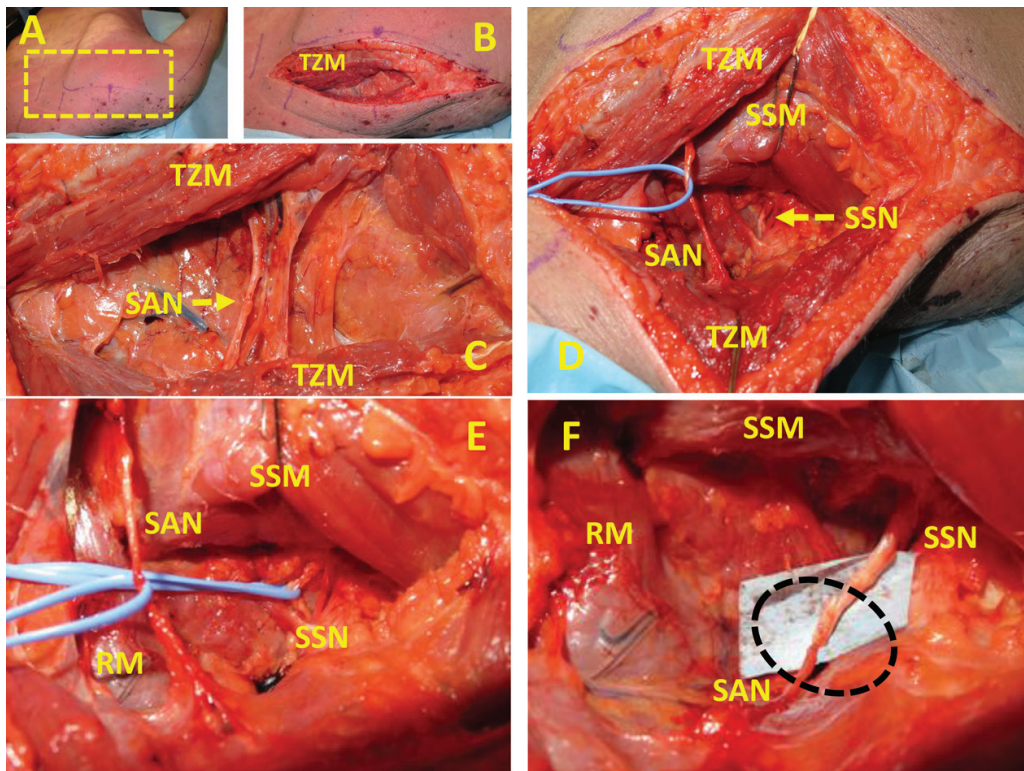


Figure 3. Spinal accessory (SAN) to suprascapular nerve (SSN) transfer (posterior approach). Trapezius muscle (TZM), supraspinatus muscle (SSM), rhomboid muscle (RM).

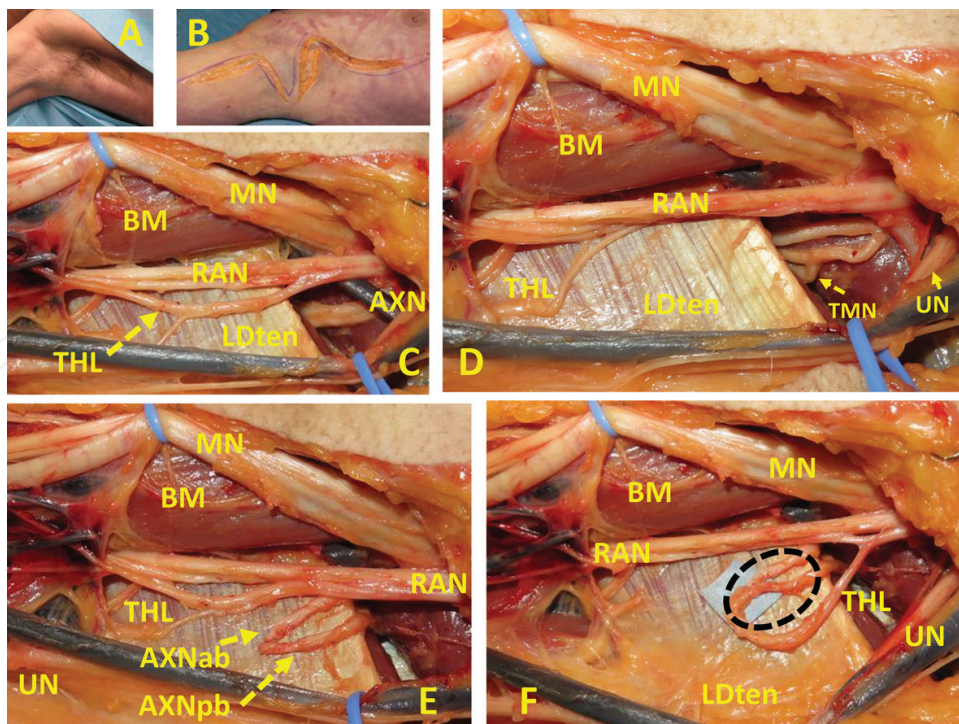


Figure 4. Radial nerve (RAN) to axillary nerve (AXN) transfer (anterior approach). Median nerve (MN), ulnar nerve (UN), triceps long head nerve branch (TLH), teres minor nerve branch (TMN), latissimus dorsi tendon (LDten), biceps muscle (BM), axillary nerve anterior branch (AXNab), axillary nerve posterior branch (AXNpb).

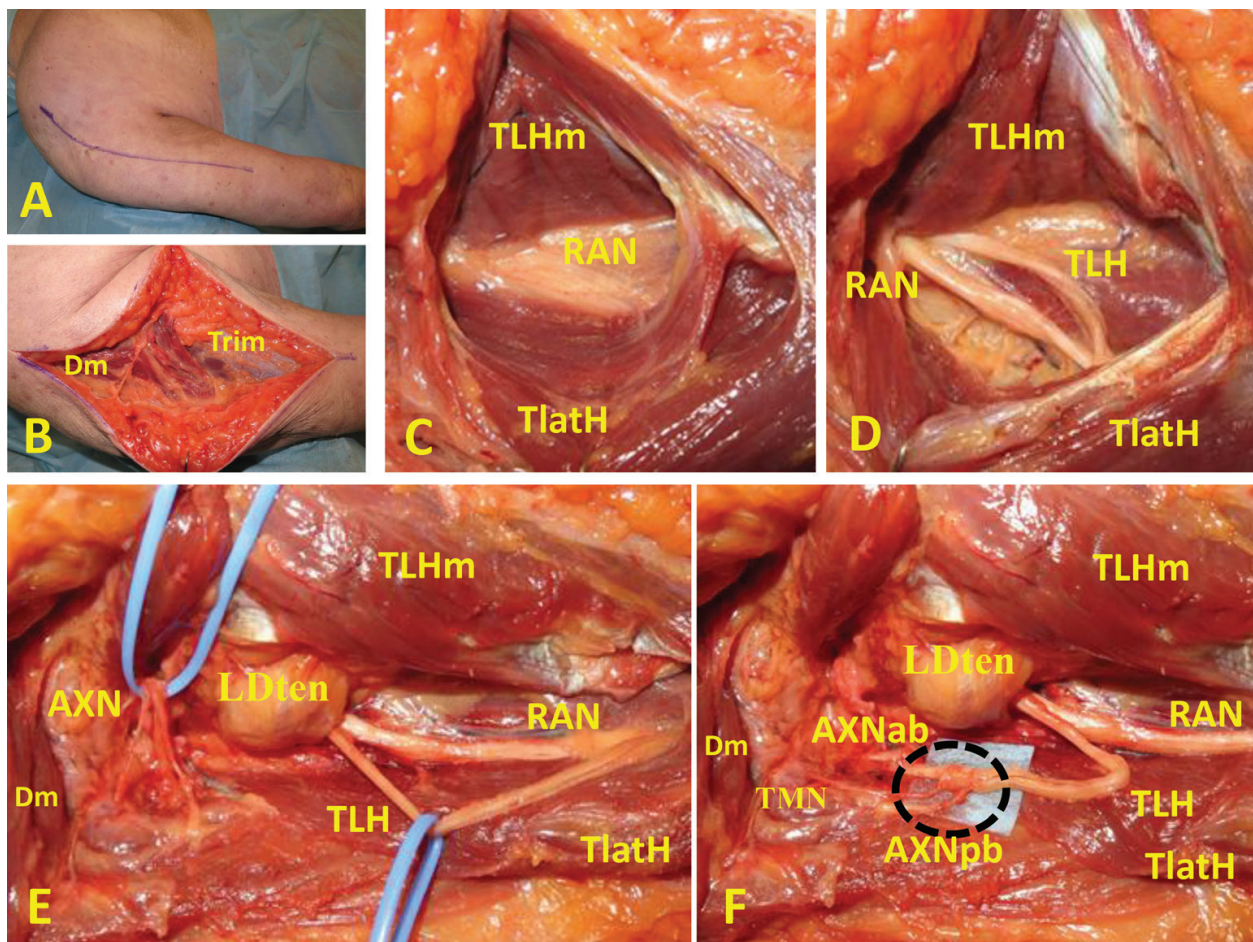


Figure 5. Radial nerve (RAN) to axillary nerve (AXN) transfer (posterior approach). Deltoid muscle (Dm), triceps muscle (Trim), triceps long head muscle (TLHm), triceps lateral head muscle (TlatH), triceps long head nerve branch (TLH), latissimus dorsi tendon (LDten), axillary nerve anterior branch (AXNab), axillary nerve posterior branch (AXNpb), teres minor nerve branch (TMN).

re-innervation of the BCM with the motor fascicle for the *flexor carpi radialis* (FCR) or the *flexor digitorum superficialis* (FDS), both from the MN [63, 101, 102] (**Figure 6**). This double transfer technique has lost popularity after two studies showed no difference in clinical outcome when compared with the Oberlin procedure [103, 104]. This procedure yields the best results provided the patient has a strong hand. Otherwise other alternatives must be considered.

ICN to MCN transfer: Two to three intercostal nerves should be transferred. The results are only fair, but can be the only choice in five root brachial plexus avulsion [105–107].

MPN to MCN transfer: Indicated in C_5 – C_6 or C_5 – C_6 – C_7 nerve root injury with preservation of pectoralis muscle (PM) function [45]. This muscle is innervated by the superior, medial and lateral pectoral nerves, allowing it to retain some function when one of its branches is used as a donor [108] (**Figure 7**). It provides acceptable results [45, 63], but often a nerve graft is needed. This impairs the clinical outcome [109].

TDN to MCN transfer: Recommended if the Oberlin procedure is not possible [110, 111]. Not advised in the case of a weak shoulder adduction or if a muscle transfer is planned.

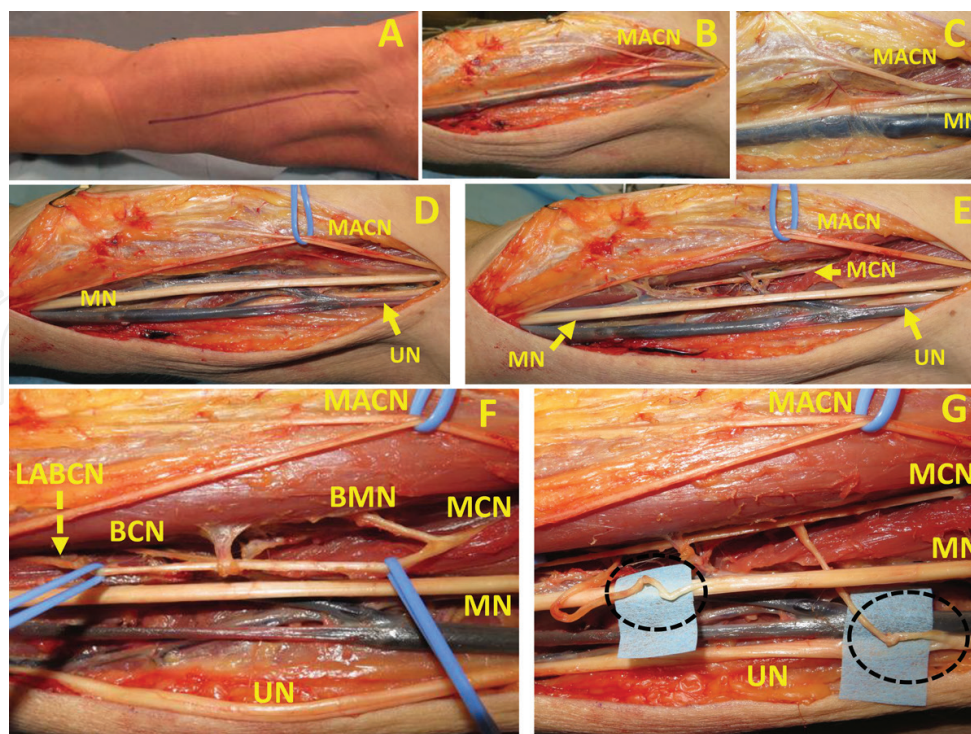


Figure 6. Dual nerve transfer ulnar nerve (UN) to biceps muscle nerve branch (BMN) and median nerve (MN) to brachialis muscle nerve (BCN) transfer. Medial antebrachial cutaneous nerve (MACN), musculocutaneous nerve (MCN), lateral antebrachial cutaneous nerve (LABCN).

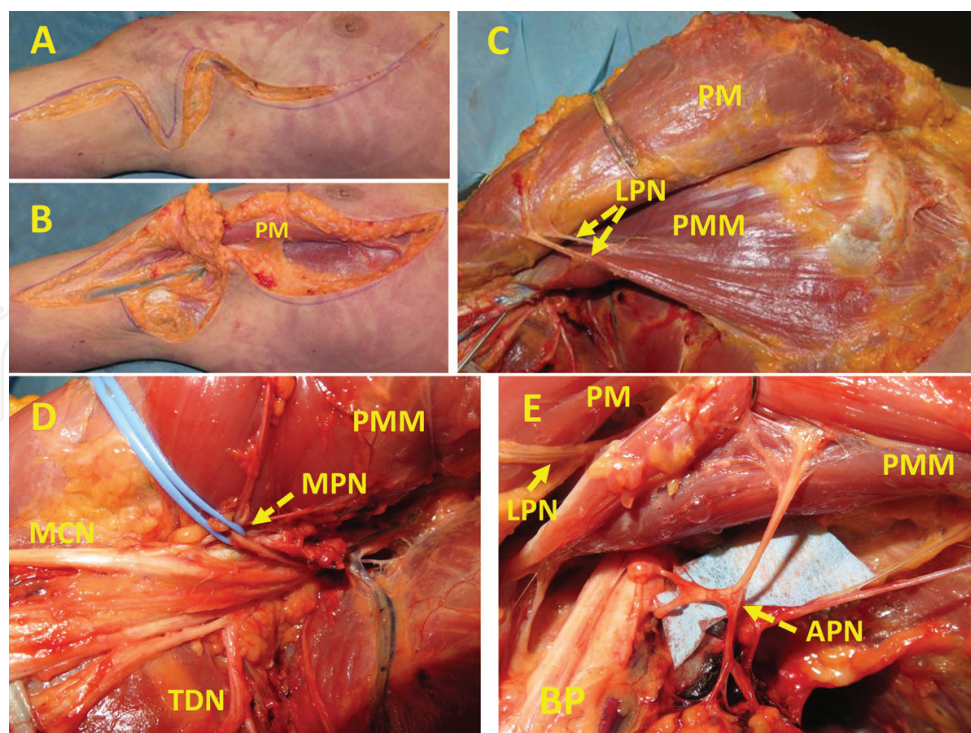


Figure 7. Medial pectoral nerve (MPN) to musculocutaneous nerve (MCN) transfer. Pectoralis major muscle (PM), pectoralis minor muscle (PMM), lateral pectoral nerve (LPN), thoracodorsal nerve (TDN), brachial plexus (BP), ansa pectoralis nerves (APN).

Other options: SAN to MCN [112, 113] and PHN to MCN [114]. Both usually need a nerve graft. None of them yield such good results as to recommend it [10].

2.4. Elbow extension nerve transfers

Although aided by gravity, there are many daily life activities that require active elbow extension (reaching overhead objects, changing from sitting to standing position, working over a table, throwing objects, changing from chair to bed in SCI patients, etc.) [115]. Restoration of elbow extension is particularly important in tetraplegia. The recipient nerve is usually the nerve branch for the TLH. The best results have been obtained by transferring the TMN to the TLH [116, 117]. Other possibilities are to re-innervate the TLH with ICNs [24, 92, 118, 119], a UN fascicle [24], the MPN [120], TDN [111], PHN [121], contralateral C₇ nerve root [122] and an RAN fascicle for the hand [123]. The results have been poor, particularly the ICNs [119].

2.5. Intercostal nerve transfers

First used by Seddon [16] in 1963 in brachial plexus repair. Only recommended when there is no other choice (i.e. C₅-T₁ brachial plexus avulsion). Harvesting them is technically demanding, requiring arterial hypotension to control the bleeding as the cautery cannot be used until the ICN is fully harvested [24]. Up to seven ICNs can be transferred. The first one was used by Durand et al. [91] in a single case. Harvesting the second one is not advised as it provides a large sensory contribution to the arm [24] (**Figure 8**). Additionally, it is technically very

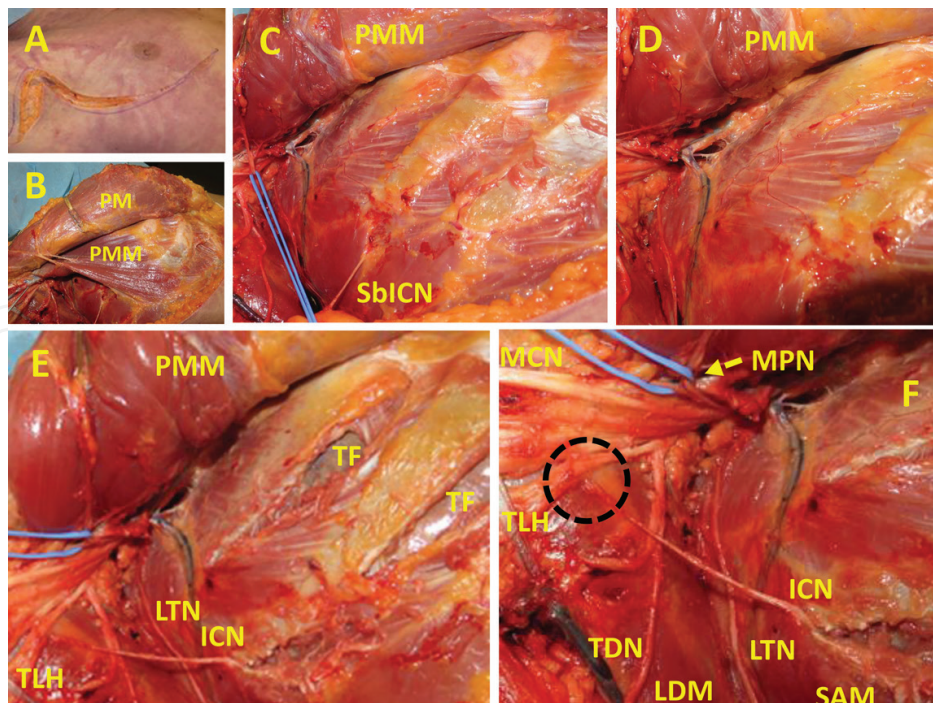


Figure 8. Intercostal nerve (ICN) to triceps long head nerve branch (TLH) of radial nerve (RA). Pectoralis major muscle (PM), pectoralis minor muscle (PMM), lateral pectoral nerve (LPN), thoracodorsal nerve (TDN), brachial plexus (BP), sensory branch intercostal nerve (SbICN), thoracodorsal nerve (TDN), long thoracic nerve (LTN), medial pectoral nerve (MPN), latissimus dorsi muscle (LDM), serratus anterior muscle (SAM), thoracic fascia (TF).

difficult to harvest and a nerve graft is always needed [24]. Usually, the third to the fifth intercostal nerves are the ones used. In women, the fourth one should be preserved to retain the nipple's area sensation. After harvesting the mean available, ICN length is 11–12 cm [124], so no nerve graft is usually needed. At least two of them per recipient nerve are needed [24, 124]. They have been used to re-innervate many nerves, like the AXN [89, 92], MCN [24, 105, 106, 124–126], TLH [92, 118, 119], TDN [89, 127] and SSN [90, 91]. Their sensory branches can be used to recover some limb sensation, ameliorating the neuropathic pain. Unfortunately, not being synergistic with the recipients nerves a long re-education must be expected [118]. Usually their harvest is not associated with any pulmonary dysfunction [24, 128].

2.6. Phrenic nerve transfers

It has been used in C₅–T₁ nerve root brachial plexus avulsion to re-innervate the MCN [106], the median nerve (MN) [129] or the RAN [46]. Unless its whole intra-thoracic segment is harvested, a nerve graft is needed [129]. The clinical results are acceptable provided there is no other choice. Patients usually need to take a breath before starting the movement with the re-innervated muscle. Post-operatively patients show a decreased pulmonary capacity that improves after 2 years [114, 130]. It is not commonly used these days.

2.7. Contralateral C₇ nerve transfer

It has been used in complete brachial plexus avulsions. It requires a long nerve graft or to shorten the humerus [122, 131], but this can be avoided crossing the donor C₇ nerve root through the C₆–C₇ disc space [132]. The targets are usually MN or MCN. Its use has been discouraged as its clinical results are poor and unreliable, the forearm and hand muscles do not get a good re-innervation and there is co-contraction of the donor and recipient limbs [24, 43]. In fact, initiating the movement often requires to start it in the contralateral normal side and there is co-contraction of the muscles of the donor and recipient sides [24]. Its value is very much disputed.

2.8. Wrist and finger extension

In the case of proximal RAN damage with an intact MN, the best choice is the *dual nerve transfer* described by Mackinnon et al. in 2007 [133]. The FDS branches (usually there are two) are coapted to the ECRB branch to recover wrist extension [134] and *the branches for the FCR and palmaris longus (PL)* are coapted *with the PIN* to recover finger extension [32, 50, 135] (**Figure 9**). This combination provides the best outcome as muscles are synergistic [29]. Contrariwise to tendon transfers, this dual nerve transfer recovers independent finger extension [11, 32, 135].

Bertelli and Ghizoni reported successful restoration of wrist extension transferring the *PQ motor branch to the ECRB* [136] (**Figure 10**). This technique is very useful but is more technically demanding than the previous one.

The pronator *teres* (PT) branch is not recommended as a donor for RAN re-innervation because pronation is essential for many daily living activities and because this muscle can be used for a tendon transfer in case the nerve transfer is unsuccessful [31, 135].

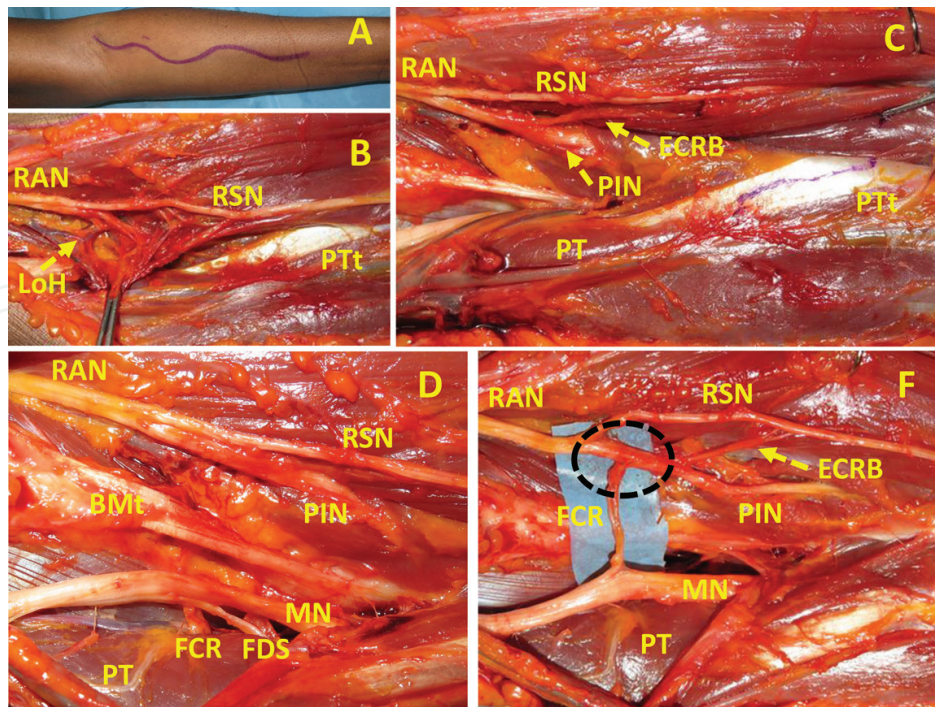


Figure 9. Flexor digitorum superficialis nerve (FDS) to extensor carpi radialis brevis (ECRB) nerve transfer and flexor carpi radialis (FCR) to posterior interosseous nerve (PIN) transfer. Radial nerve (RAN), median nerve (MN), radial sensory nerve (RSN), pronator teres muscle (PT), pronator teres tendon (PTt), lash of Henry (LoH), biceps muscle tendon (BMT).

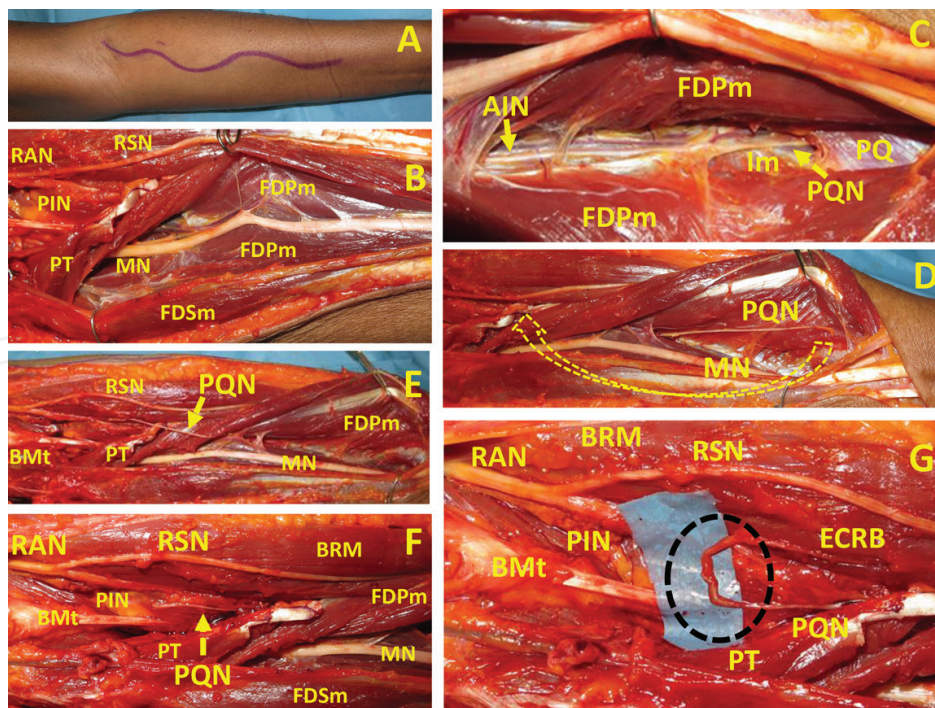


Figure 10. Pronator quadratus nerve branch (PQN) from anterior interosseous nerve (AIN) to extensor carpi radialis brevis nerve (ECRB) transfer. Pronator quadratus muscle (PQ), radial nerve (RAN), radial sensory nerve (RSN), median nerve (MN), pronator teres muscle (PT), flexor digitorum profundus muscle (FDPm), flexor digitorum superficialis muscle (FDSm), brachioradialis muscle (BRM), interosseous membrane (Im).

In C_7 - T_1 brachial plexus injuries, the shoulder and elbow mobility is preserved, but the finger movements are lost. The supinator muscle (SM) innervation is preserved as it comes from the C_6 nerve root. Thus, it is possible to coapt one or both SN branches to the PIN (**Figure 11**). This helps to recover the function of the *extensor pollicis longus* (EPL) and *extensor digitorum communis* (EDC) muscles. It is a very successful nerve transfer [137–139].

2.9. Finger flexion and median nerve hand function

The primary goal of MN recovery is to provide first and second finger pincer as well as thumb opposition [29].

Reported by Palazzi et al. [140] in 2006 the *BCN to AIN nerve transfer* is indicated in the case of C_8 - T_1 nerve root or lower brachial plexus injury with a MN dysfunction. It provides improvement in hand function [13, 141–143] but there are other transfers with better clinical results. It is recommended only if the MCN nerve is intact.

García-López et al. [144] reported a single case of *brachioradialis muscle (BRM) nerve to AIN nerve transfer* with return of finger flexion.

Thenar muscle re-innervation can be achieved coapting the *AIN terminal branch to the PQ with the MN motor thenar branch* [145]. A nerve graft is usually required [29] but it is a very effective procedure [29, 145, 146].

The *FDS, FCR and FCU branches* can all be transferred to recover AIN function [147].

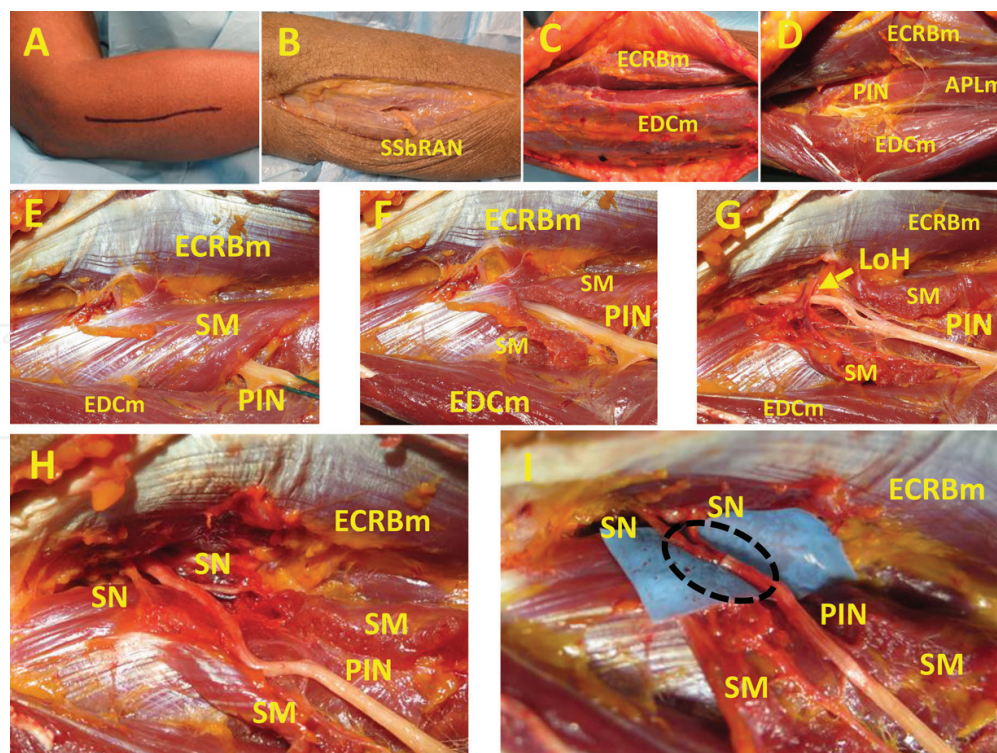


Figure 11. Supinator nerve branches (SN) to posterior interosseous nerve (PIN) transfer. Superficial sensory branch radial nerve (SSbRAN), supinator muscle (SM), extensor carpi radialis brevis muscle (ECRBm), extensor digitorum communis muscle (EDCm), lash of Henry (LoH), abductor pollicis longus muscle (APLm).

Finger flexion, particularly the thumb and index finger, can be recovered by coapting the *nerve branch for the ECRB to the AIN* [29]. One or both *SM branches can be coapted with the AIN* to recover FPL and FDP function [142]. Some have transferred both the ECRB and SM branches to the AIN to recover finger flexion [148]. The results of these techniques are very encouraging [149].

2.10. Pronation recovery

To restore active pronation, essential in many daily living activities, some have transferred the FCU nerve branch to the PT nerve [150]. Others have transferred one of the branches of the FDS to the PT nerve [40]. More recently, the nerve for the ECRB has been transferred to the PT branch [142]. This last technique has a widespread acceptance.

2.11. Ulnar nerve hand function

When the UN is damaged in the arm or more proximally, the recovery of hand intrinsic muscles is dismal [151]. The motor recovery can be improved by coapting the *AIN terminal branch for the PQ to the motor fascicle of the UN* [50, 62, 146, 152, 153] (**Figure 12**). This technique was originally described in 1997 by Wang and Zhu [146]. If this fascicle is neurotised proximally enough in the forearm, no nerve graft is needed [29]. The clinical outcome is very satisfactory [29, 62, 152]. Another possibility is a reverse end-to-side transfer, avoiding atrophy of the UN innervated hand muscles while awaiting for the native UN motor axons to regenerate [70, 71, 154]. It is very effective [29].

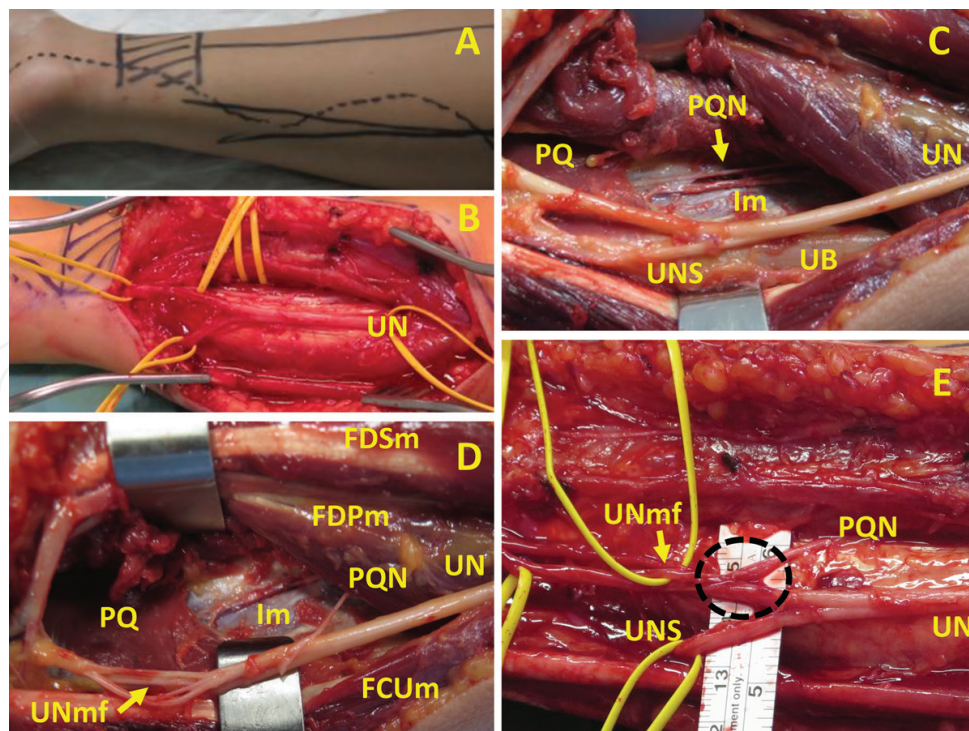


Figure 12. Pronator quadratus nerve branch (PQN) from anterior interosseous nerve (AIN) to ulnar nerve (UN) motor fascicle (UNmf) nerve transfer. Pronator quadratus muscle (PQ), interosseous membrane (Im), ulnar nerve dorsal sensory branch (UNDS), ulnar bone (UB), flexor carpi ulnaris muscle (FCUm), flexor digitorum superficialis muscle (FDSm), flexor digitorum profundus muscle (FDPm).

Transfer of the *terminal branches of the extensor digiti minimi (EDM) and the extensor carpi ulnaris (ECU) to the UN motor branch* in the forearm has been reported. In this single case, a 10-cm nerve graft had to be used and the recovery was fair [155]. It is not recommended unless there is no other option.

2.12. Nerve transfers for upper limb sensation recovery

Sensory nerve transfers sacrifice nerves that serve areas with non-critical sensation to recover it where this sense is vital (i.e. tip of the thumb and index fingers) [33, 49, 51, 61, 65]. They also help with neuropathic pain control [13, 29, 49, 156]. The donor nerve distal stump can be coapted end-to-side to a nearby sensory nerve to regain some protective sensation [14, 31, 66].

In the case of proximal MN damage, restoring the sensation in the ulnar aspect of the thumb and the radial side of the index finger is a priority to allow a useful pincer mechanism [29]. The donors are the nerves supplying less essential areas like the third web space (MN branch) the forth web space (UN branch), the dorsal sensory branch of the UN and the radial sensory nerve (RSN) [22, 29, 49, 50, 65, 157, 158]. Ducic et al. [159] in 2006 recovered the sensation of the thumb and index fingers using the radial nerve branches as donors. Bertelli and Ghizoni [158] in 2011 reported the transfer of the distal superficial radial finger nerves of the thumb and index fingers to the ulnar aspect of the thumb and the radial aspect of the index finger. Flores et al. [52] transferred the superficial ulnar nerve to the third palmar digital nerve.

In the case of proximal RAN damage, the sensation in the dorsum of the hand can be recovered by coapting the lateral antebrachial cutaneous nerve (LABCN) to the RSN [148] (**Figure 13**). At

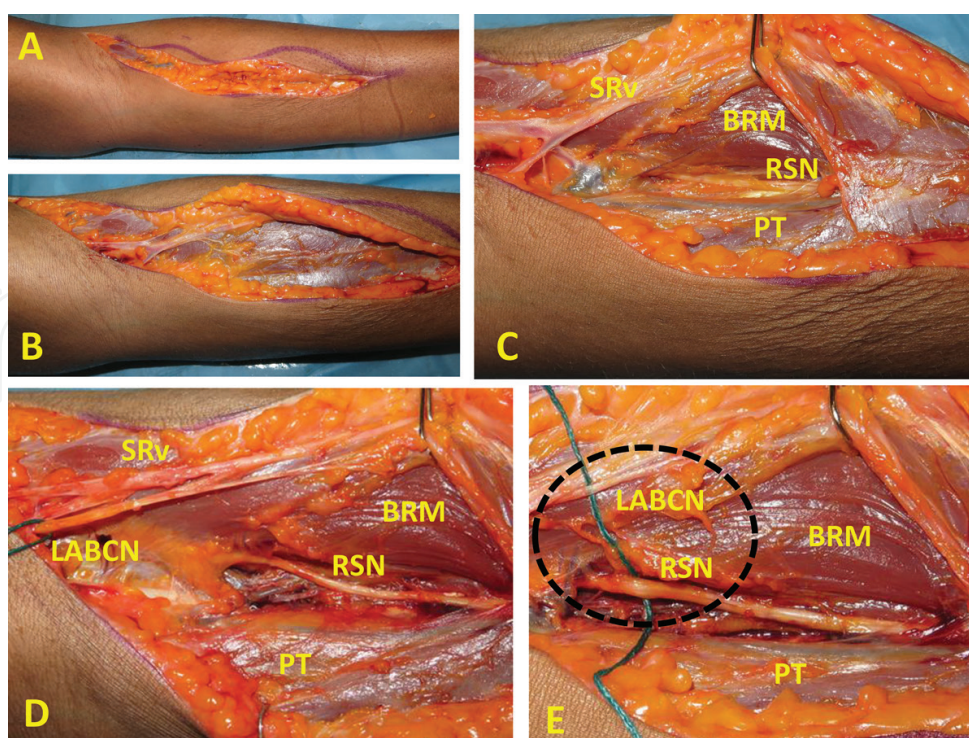


Figure 13. Lateral antebrachial cutaneous nerve (LABCN) to radial sensory nerve (RSN) transfer. Superficial radial vein (SRV), brachioradialis muscle (BRM), pronator teres muscle (PT).

the outer aspect of the elbow, both nerves run parallel to each other. The LABCN goes with the superficial radial vein and the RSN with the deep radial vessels. The LABCN is sectioned as distally as possible and coapted to the proximal part of the RSN [17].

Protective sensation in the hand ulnar innervated areas can be recovered with a sensory nerve transfer from the third web space (MN branch) [29] or from the RSN [160].

In C₇-T₁ nerve root injuries the LABCN can be coapted with the sensory fascicles of the UN in the forearm to recover the sensation in the hand [12].

3. Nerve transfers in the lower extremity

Three areas have been explored. At the proximal level, nerve transfers between the femoral (FN) and obturator (OBN) nerves; at the knee, the nerve transfers between branches of the posterior tibial nerve (PTN) and the peroneal nerve (PN); and at the foot, some sensory nerve transfers for recovery of protective sensation. There have been some attempts to recover urinary continence in spinal injured patients.

FN injuries are the most disabling as they impair the capacity of standing and walking. The anterior branch of the OBN has been successful in re-innervating the FN [119, 161, 162]. The anterior branch of the OBN is selected to preserve the primary leg adductor muscle [162]. The reverse transfer using an FN motor branch as donor to coapt it to the OBN has also been used with successful clinical outcomes [163].

PTN to PN transfer to recover foot dorsiflexion has been attempted [164-166] but the reported outcomes are inferior to the posterior tibial tendon transfer [167].

Nerve transfer from an FN branch to the pudendal nerve to recover urinary continence has been achieved in a canine neurogenic bladder model [168] but its clinical application in the human being is still pending.

4. Transfers for spinal cord injured patients

Around a 50% of the SCI involves the cervical spinal cord [30]. Tetraplegic patients suffer from a variable loss of arm and hand functions, usually asymmetrical [30]. This creates serious difficulties to perform their daily activities (transfers back and forth from the wheelchair, feeding, computer handling, self-catheterization, etc.) [169]. To recover any partial arm and/or hand function might mean an immense impact on their quality of life [170].

Nerve transfers used in SCI patients aim to recover elbow, wrist and finger extension, palmar grasp and thumb and index finger pinch and release. The nerve transfers mentioned above can also be used in these cases. The only difference is that in SCI there are three spinal cord areas [170-172]. The area above the injury will have normal spinal cord and nerves; the area of the injury will have neuronal loss and severe muscle atrophy. To recover function in this area, nerve transfers must be planned no later than 1 year after injury.

Below is the area of normal spinal cord disconnected from the rest of the central nervous system. The muscles depending from this area are not denervated, so nerve transfers can be done any time. The first area is the donor and second and third areas are the recipients. We aim to recover some functions of areas 2 and 3 transferring some nerve branches from area 1. In SCI, it is recommended to wait 12 months to give a chance for spontaneous recovery [172].

Elbow extension has been achieved by transferring the TM motor branch to the TLH [116].

Wrist and finger extension can be recovered with SN to PIN transfer [173, 174].

Thumb and index finger pinch is restored transferring the ECRB motor branch to the AIN [175, 176].

The BCM branch has been transferred to the AIN fascicle in the arm to recover FPL and FDP function [147, 177, 178].

5. Conclusions

Nerve transfers have become an essential way to repair irrecoverable peripheral nerve injuries. Mastering these techniques is essential for the peripheral nerve surgeon. The best results are obtained when patients are young; the procedure is not delayed more than 6 months after the injury, donor and recipient nerves are agonistic and when the donor nerve has no damage. Shoulder and elbow motor recovery is very successful in most patients. Hand recovery can also be achieved but results are not so good. The biggest experience is in upper limb nerve transfers. Lower limb nerve transfers have been attempted but the experience is limited and the choices few. In tetraplegic patients, we aim to recover some of the lost functions, simplifying their daily lives.

Acknowledgements

The authors thank the Department of Human Anatomy and Embryology of the Faculty of Medicine of the University of Valencia, particularly the laboratory curators Lucia and Carmina and Dr. Tomás Hernández Gil de Tejada and all personnel of the *Instituto de Medicina Legal de Valencia* for their assistance in this study.

Appendices and nomenclatures

AIN	Anterior interosseous nerve.
AXN	Axillary nerve.
BM	Biceps muscle.
BMN	Biceps muscle nerve.

BCM	Brachialis muscle.
BCN	Brachialis nerve
BRM	Brachioradialis muscle.
BRN	Brachioradialis nerve.
ECRB	Extensor carpi radialis brevis.
ECU	Extensor carpi ulnaris.
EDC	Extensor digitorum communis.
EDM	Extensor digiti minimi.
EPL	Extensor pollicis longus.
FCR	Flexor carpi radialis.
FCU	Flexor carpi ulnaris.
FDS	Flexor digitorum superficialis.
FDP	Flexor digitorum profundus.
FN	Femoral nerve.
FPLN	Flexor pollicis longus.
ICN	Intercostal nerve.
LABCN	Lateral antebrachial cutaneous nerve.
LTN	Long thoracic nerve.
MCN	Musculocutaneous nerve.
MN	Median nerve.
MPN	Medial pectoral nerve.
MRC	Medical Research Council.
OBN	Obturator nerve.
PHN	Phrenic nerve.
PIN	Posterior interosseous nerve.
PL	Palmaris longus.
PM	Pectoralis muscle.
PN	Peroneal nerve.
PQ	Pronator quadratus.
PT	Pronator teres.
PTN	Posterior tibial nerve.
RAN	Radial nerve.
RSN	Radial sensory nerve.
SAM	Serratus anterior muscle.
SAN	Spinal accessory nerve.

SAM	Serratus anterior muscle.
SCI	Spinal cord injury.
SM	Supinator muscle.
SN	Supinator nerve.
SSN	Suprascapular nerve.
TDN	Thoracodorsal nerve.
TLH	Triceps long head.
TMN	Teres minor nerve.
UN	Ulnar nerve.

Author details

Vicente Vanaclocha-Vanaclocha^{1*}, Jose María Ortiz-Criado², Nieves Sáiz-Sapena³ and Nieves Vanaclocha¹

*Address all correspondence to: vvanaclo@hotmail.com

1 Department of Neurosurgery, Hospital General Universitario, Valencia, Spain

2 Universidad Católica San Vicente Mártir, Valencia, Spain

3 Hospital 9 de Octubre, Valencia, Spain

References

- [1] Bentolila V, Nizard R, Bizot P, Sedel L. Complete traumatic brachial plexus palsy. Treatment and outcome after repair. *J Bone Joint Surg Am.* 1999 Jan;81(1):20–8.
- [2] Seddon HJ, Medawar PB, Smith H. Rate of regeneration of peripheral nerves in man. *J Physiol.* 1943 Sep 30;102(2):191–215.
- [3] Isaacs J. Treatment of acute peripheral nerve injuries: current concepts. *J Hand Surg.* 2010 Mar;35(3):491–497; quiz 498.
- [4] Dahlin LB. The role of timing in nerve reconstruction. *Int Rev Neurobiol.* 2013;109:151–64.
- [5] Finkelstein DI, Dooley PC, Luff AR. Recovery of muscle after different periods of denervation and treatments. *Muscle Nerve.* 1993 Jul;16(7):769–77.
- [6] Fu SY, Gordon T. Contributing factors to poor functional recovery after delayed nerve repair: prolonged denervation. *J Neurosci.* 1995 May;15(5):3886–95.
- [7] Kobayashi J, Mackinnon SE, Watanabe O, Ball DJ, Gu XM, Hunter DA, Kuzon WM. The effect of duration of muscle denervation on functional recovery in the rat model. *Muscle Nerve.* 1997 Jul;20(7):858–66.

- [8] Aydin MA, Mackinnon SE, Gu XM, Kobayashi J, Kuzon WM. Force deficits in skeletal muscle after delayed reinnervation. *Plast Reconstr Surg*. 2004 May;113(6):1712–8.
- [9] Bertelli JA, Ghizoni MF. Nerve root grafting and distal nerve transfers for C5-C6 brachial plexus injuries. *J Hand Surg*. 2010 May;35(5):769–75.
- [10] Ray WZ, Chang J, Hawasli A, Wilson TJ, Yang L. Motor nerve transfers: a comprehensive review. *Neurosurgery*. 2016 Jan;78(1):1–26.
- [11] Boyd KU, Nimigan AS, Mackinnon SE. Nerve reconstruction in the hand and upper extremity. *Clin Plast Surg*. 2011 Oct;38(4):643–60.
- [12] Lee SK, Wolfe SW. Nerve transfers for the upper extremity: new horizons in nerve reconstruction. *J Am Acad Orthop Surg*. 2012 Aug;20(8):506–17.
- [13] Tung TH, Mackinnon SE. Nerve transfers: indications, techniques, and outcomes. *J Hand Surg*. 2010 Feb;35(2):332–41.
- [14] Mackinnon SE, Colbert SH. Nerve transfers in the hand and upper extremity surgery. *Tech Hand Up Extrem Surg*. 2008 Mar;12(1):20–33.
- [15] Terzis J, Faibisoff B, Williams B. The nerve gap: suture under tension vs. graft. *Plast Reconstr Surg*. 1975 Aug;56(2):166–70.
- [16] Seddon HJ. Nerve grafting. *J Bone Joint Surg Br*. 1963 Aug;45:447–61.
- [17] Merrell GA, Barrie KA, Katz DL, Wolfe SW. Results of nerve transfer techniques for restoration of shoulder and elbow function in the context of a meta-analysis of the English literature. *J Hand Surg*. 2001 Mar;26(2):303–14.
- [18] McCallister WV, McCallister EL, Trumble SA, Trumble TE. Overcoming peripheral-nerve gap defects using an intact nerve bridge in a rabbit model. *J Reconstr Microsurg*. 2005 Apr;21(3):197–206.
- [19] Dvali L, Mackinnon S. Nerve repair, grafting, and nerve transfers. *Clin Plast Surg*. 2003 Apr;30(2):203–21.
- [20] Poppler LH, Davidge K, Lu JCY, Armstrong J, Fox IK, Mackinnon SE. Alternatives to sural nerve grafts in the upper extremity. *Hand (NY)*. 2015 Mar;10(1):68–75.
- [21] Nichols CM, Brenner MJ, Fox IK, Tung TH, Hunter DA, Rickman SR, Mackinnon SE. Effects of motor versus sensory nerve grafts on peripheral nerve regeneration. *Exp Neurol*. 2004 Dec;190(2):347–55.
- [22] Moore AM. Nerve transfers to restore upper extremity function: a paradigm shift. *Front Neurol*. 2014;5:40.
- [23] Gordon T, Eva P, Borschel GH. Delayed peripheral nerve repair: methods, including surgical “cross-bridging” to promote nerve regeneration. *Neural Regen Res*. 2015 Oct;10(10):1540–4.
- [24] Oberlin C, Durand S, Belheyar Z, Shafi M, David E, Asfazadourian H. Nerve transfers in brachial plexus palsies. *Chir Main*. 2009 Feb;28(1):1–9.

- [25] Chan KM, Olson JL, Morhart M, Lin T, Guilfoyle R. Outcomes of nerve transfer versus nerve graft in ulnar nerve laceration. *Can J Neurol Sci.* 2012 Mar;39(2):242–4.
- [26] Haftek J. Autogenous cable nerve grafting instead of end to end anastomosis in secondary nerve suture. *Acta Neurochir (Wien).* 1976;34(1–4):217–21.
- [27] Mackinnon SE. Donor distal, recipient proximal and other personal perspectives on nerve transfers. *Hand Clin.* 2016 May;32(2):141–51.
- [28] Ropars M, Dréano T, Siret P, Belot N, Langlais F. Long-term results of tendon transfers in radial and posterior interosseous nerve paralysis. *J Hand Surg Edinb Scotl.* 2006 Oct;31(5):502–6.
- [29] Brown JM, Mackinnon SE. Nerve transfers in the forearm and hand. *Hand Clin.* 2008 Nov;24(4):319–340 v.
- [30] Garg R, Merrell GA, Hillstrom HJ, Wolfe SW. Comparison of nerve transfers and nerve grafting for traumatic upper plexus palsy: a systematic review and analysis. *J Bone Joint Surg Am.* 2011 May 4;93(9):819–29.
- [31] Moore AM, Franco M, Tung TH. Motor and sensory nerve transfers in the forearm and hand. *Plast Reconstr Surg.* 2014 Oct;134(4):721–30.
- [32] Ray WZ, Mackinnon SE. Clinical outcomes following median to radial nerve transfers. *J Hand Surg.* 2011 Feb;36(2):201–8.
- [33] Rinker B. Nerve transfers in the upper extremity: a practical user's guide. *Ann Plast Surg.* 2015 Jun;74(Suppl 4):S222–8.
- [34] Gordon T, Yang JF, Ayer K, Stein RB, Tyreman N. Recovery potential of muscle after partial denervation: a comparison between rats and humans. *Brain Res Bull.* 1993; 30(3–4):477–82.
- [35] Lien SC, Cederna PS, Kuzon WM. Optimizing skeletal muscle reinnervation with nerve transfer. *Hand Clin.* 2008 Nov;24(4):445–54, vii.
- [36] Rafuse VF, Pattullo MC, Gordon T. Innervation ratio and motor unit force in large muscles: a study of chronically stimulated cat medial gastrocnemius. *J Physiol.* 1997 Mar 15;499(Pt 3):809–23.
- [37] Gordon T, Tyreman N, Raji MA. The basis for diminished functional recovery after delayed peripheral nerve repair. *J Neurosci.* 2011, 31 (14) 5325–34.
- [38] Bertelli JA, Ghizoni MF. Reconstruction of C5 and C6 brachial plexus avulsion injury by multiple nerve transfers: spinal accessory to suprascapular, ulnar fascicles to biceps branch, and triceps long or lateral head branch to axillary nerve. *J Hand Surg.* 2004 Jan;29(1):131–9.
- [39] Weber RV, Mackinnon SE. Bridging the neural gap. *Clin Plast Surg.* 2005 Oct;32(4):605–616, viii.
- [40] Tung TH, Mackinnon SE. Flexor digitorum superficialis nerve transfer to restore pronation: two case reports and anatomic study. *J Hand Surg.* 2001 Nov;26(6):1065–72.

- [41] Yang J, Jia X, Yu C, Gu Y. Pronator teres branch transfer to the anterior interosseous nerve for treating C8T1 brachial plexus avulsion: an anatomic study and case report. *Neurosurgery*. 2014 Oct;75(4):375–9; discussion 379.
- [42] Wong AH, Pianta TJ, Mastella DJ. Nerve transfers. *Hand Clin*. 2012 Nov;28(4):571–7.
- [43] Sammer DM, Kircher MF, Bishop AT, Spinner RJ, Shin AY. Hemi-contralateral C7 transfer in traumatic brachial plexus injuries: outcomes and complications. *J Bone Joint Surg Am*. 2012 Jan 18;94(2):131–7.
- [44] Liu Y, Xu X-C, Zou Y, Li S-R, Zhang B, Wang Y. Phrenic nerve transfer to the musculocutaneous nerve for the repair of brachial plexus injury: electrophysiological characteristics. *Neural Regen Res*. 2015 Feb;10(2):328–33.
- [45] Hems T. Nerve transfers for traumatic brachial plexus injury: advantages and problems. *J Hand Microsurg*. 2011 Jun;3(1):6–10.
- [46] Wang S, Li P, Xue Y, Zou J, Li W, Li Y. Direct coaptation of the phrenic nerve with the posterior division of the lower trunk to restore finger and elbow extension function in patients with total brachial plexus injuries. *Neurosurgery*. 2016 Feb;78(2):208–15.
- [47] Messina A, Van Zyl N, Weymouth M, Flood S, Nunn A, Cooper C, Hahn J, Galea MP. Morphology of donor and recipient nerves utilised in nerve transfers to restore upper limb function in cervical spinal cord injury. *Brain Sci*. 2016 Sep 27;6, 42; doi:10.3390/brainsci6040042.
- [48] Anastakis DJ, Chen R, Davis KD, Mikulis D. Cortical plasticity following upper extremity injury and reconstruction. *Clin Plast Surg*. 2005 Oct;32(4):617–34, viii.
- [49] Brunelli GA. Sensory nerves transfers. *J Hand Surg Edinb Scotl*. 2004 Dec;29(6):557–62.
- [50] Brown JM, Yee A, Mackinnon SE. Distal median to ulnar nerve transfers to restore ulnar motor and sensory function within the hand: technical nuances. *Neurosurgery*. 2009 Nov;65(5):966–78.
- [51] Suppaphol S, Watcharananan I, Tawonsawatruk T, Woratanarat P, Sasivongsbhakdi T, Kawinwonggowit V. The sensory restoration in radial nerve injury using the first branch of dorsal ulnar cutaneous nerve—a cadaveric study for the feasibility of procedure and case demonstration. *J Med Assoc Thai Chotmaihet Thangphaet*. 2014 Mar;97(3):328–32.
- [52] Flores LP. Distal anterior interosseous nerve transfer to the deep ulnar nerve and end-to-side suture of the superficial ulnar nerve to the third common palmar digital nerve for treatment of high ulnar nerve injuries: experience in five cases. *Arq Neuropsiquiatr*. 2011 Jun;69(3):519–24.
- [53] Ballance CA, Ballance HA, Stewart P. Remarks on the operative treatment of chronic facial palsy of peripheral origin. *Br Med J*. 1903 May 2;1(2209):1009–13.
- [54] Tuttle H. Exposure of the brachial plexus with nerve transplantation. *JAMA*. 1913;61:15–7.
- [55] Vulpius, O, Stoffel, A. *Orthopädische Operationslehre*. 2nd Edition. Stuttgart: Enke; 1920.

- [56] Meals RA, Nelissen RG. The origin and meaning of "neurotization." *J Hand Surg.* 1995 Jan;20(1):144–6.
- [57] Harris RI. The treatment of irreparable nerve injuries. *Can Med Assoc J.* 1921 Nov;11(11):833–41.
- [58] Förster, O. Die Therapie Des Shussverletzungen Der Peripheren Nerven. In: *Handbuch der Neurologie (Lewandowsky)*. Berlin: *Ergänzungsband*; 1929. p. chapter 3.
- [59] Lurje AS. On the use of N. Musculocutaneous for neurotization of N. Radialis in cases of very large defects of the latter. *Ann Surg.* 1948 Jul;128(1):110–5.
- [60] Samardzic MM, Grujicic DM, Rasulic LG, Milicic BR. The use of thoracodorsal nerve transfer in restoration of irreparable C5 and C6 spinal nerve lesions. *Br J Plast Surg.* 2005 Jun;58(4):541–6.
- [61] Bedeschi P, Celli L, Balli A. Transfer of sensory nerves in hand surgery. *J Hand Surg Edinb Scotl.* 1984 Feb;9(1):46–9.
- [62] Novak CB, Mackinnon SE. Distal anterior interosseous nerve transfer to the deep motor branch of the ulnar nerve for reconstruction of high ulnar nerve injuries. *J Reconstr Microsurg.* 2002 Aug;18(6):459–64.
- [63] Brandt KE, Mackinnon SE. A technique for maximizing biceps recovery in brachial plexus reconstruction. *J Hand Surg.* 1993 Jul;18(4):726–33.
- [64] Oberlin C, Béal D, Leechavengvongs S, Salon A, Dauge MC, Sarcy JJ. Nerve transfer to biceps muscle using a part of ulnar nerve for C5-C6 avulsion of the brachial plexus: anatomical study and report of four cases. *J Hand Surg.* 1994 Mar;19(2):232–7.
- [65] Bertelli JA. Distal sensory nerve transfers in lower-type injuries of the brachial plexus. *J Hand Surg.* 2012 Jun;37(6):1194–9.
- [66] Hayashi A, Pannucci C, Moradzadeh A, Kawamura D, Magill C, Hunter DA, Tong AY, Parsadonian A, Mackinnon SE, Myckatyn TM. Axotomy or compression is required for axonal sprouting following end-to-side neurorrhaphy. *Exp Neurol.* 2008 Jun;211(2):539–50.
- [67] Viterbo F, Amr AH, Stipp EJ, Reis FJ. End-to-side neurorrhaphy: past, present, and future. *Plast Reconstr Surg.* 2009 Dec;124(6 Suppl):e351–8.
- [68] Walker JC, Brenner MJ, Mackinnon SE, Winograd JM, Hunter DA. Effect of perineurial window size on nerve regeneration, blood-nerve barrier integrity, and functional recovery. *J Neurotrauma.* 2004 Feb;21(2):217–27.
- [69] Tos P, Colzani G, Ciclamini D, Titolo P, Pugliese P, Artiaco S. Clinical applications of end-to-side neurorrhaphy: an update. *BioMed Res Int.* 2014;2014:646128.
- [70] Kale SS, Glaus SW, Yee A, Nicoson MC, Hunter DA, Mackinnon SE, Johnson PJ. Reverse end-to-side nerve transfer: from animal model to clinical use. *J Hand Surg.* 2011 Oct;36(10):1631–9.e2.

- [71] Farber SJ, Glaus SW, Moore AM, Hunter DA, Mackinnon SE, Johnson PJ. Supercharge nerve transfer to enhance motor recovery: a laboratory study. *J Hand Surg.* 2013 Mar;38(3):466–77.
- [72] Raksakulkiat R, Leechavengvongs S, Malungpaishrope K, Uerpairojkit C, Witoonchart K, Chongthammakun S. Restoration of winged scapula in upper arm type brachial plexus injury: anatomic feasibility. *J Med Assoc Thai Chotmaihet Thangphaet.* 2009 Dec;92(Suppl 6):S244–50.
- [73] Uerpairojkit C, Leechavengvongs S, Witoonchart K, Malungpaishrope K, Raksakulkiat R. Nerve transfer to serratus anterior muscle using the thoracodorsal nerve for winged scapula in C5 and C6 brachial plexus root avulsions. *J Hand Surg.* 2009 Jan;34(1):74–8.
- [74] Terzis JK, Kostas I. Suprascapular nerve reconstruction in 118 cases of adult posttraumatic brachial plexus. *Plast Reconstr Surg.* 2006 Feb;117(2):613–29.
- [75] Bertelli JA, Ghizoni MF. Transfer of the accessory nerve to the suprascapular nerve in brachial plexus reconstruction. *J Hand Surg.* 2007 Sep;32(7):989–98.
- [76] Bertelli JA, Ghizoni MF. Results of spinal accessory to suprascapular nerve transfer in 110 patients with complete palsy of the brachial plexus. *J Neurosurg Spine.* 2016 Jun;24(6):990–5.
- [77] Colbert SH, Mackinnon S. Posterior approach for double nerve transfer for restoration of shoulder function in upper brachial plexus palsy. *Hand (NY).* 2006 Dec;1(2):71–7.
- [78] Lu J, Xu J, Xu W, Xu L, Fang Y, Chen L, Gu Y. Combined nerve transfers for repair of the upper brachial plexus injuries through a posterior approach. *Microsurgery.* 2012 Feb;32(2):111–7.
- [79] Lurje A. Concerning surgical treatment of traumatic injury of the upper division of the brachial plexus (Erb's-type). *Ann Surg.* 1948 Feb;127(2):317–26.
- [80] Leechavengvongs S, Witoonchart K, Uerpairojkit C, Thuvasethakul P. Nerve transfer to deltoid muscle using the nerve to the long head of the triceps, part II: a report of 7 cases. *J Hand Surg.* 2003 Jul;28(4):633–8.
- [81] Uerpairojkit C, Ketwongwiriya S, Leechavengvongs S, Malungpaishrope K, Witoonchart K, Mekruncharas N, Chareonwat B, Ongsiriporn M. Surgical anatomy of the radial nerve branches to triceps muscle. *Clin Anat (NY).* 2013 Apr;26(3):386–91.
- [82] Bertelli JA, Santos MA, Kechele PR, Ghizoni MF, Duarte H. Triceps motor nerve branches as a donor or receiver in nerve transfers. *Neurosurgery.* 2007 Nov;61(5 Suppl 2):333–9.
- [83] Witoonchart K, Leechavengvongs S, Uerpairojkit C, Thuvasethakul P, Wongnopsuwan V. Nerve transfer to deltoid muscle using the nerve to the long head of the triceps, part I: an anatomic feasibility study. *J Hand Surg.* 2003 Jul;28(4):628–32.
- [84] Jerome JTJ. Anterior deltopectoral approach for axillary nerve neurotisation. *J Orthop Surg Hong Kong.* 2012 Apr;20(1):66–70.

- [85] Bhandari PS, Deb P. Posterior approach for both spinal accessory nerve to suprascapular nerve and triceps branch to axillary nerve for upper plexus injuries. *J Hand Surg.* 2013 Jan;38(1):168–72.
- [86] McRae MC, Borschel GH. Transfer of triceps motor branches of the radial nerve to the axillary nerve with or without other nerve transfers provides antigavity shoulder abduction in pediatric brachial plexus injury. *Hand (NY).* 2012 Jun;7(2):186–90.
- [87] Bertelli JA, Ghizoni MF. Nerve transfer from triceps medial head and anconeus to deltoid for axillary nerve palsy. *J Hand Surg.* 2014 May;39(5):940–7.
- [88] Yamada S, Peterson GW, Soloniuk DS, Will AD. Coaptation of the anterior rami of C-3 and C-4 to the upper trunk of the brachial plexus for cervical nerve root avulsion. *J Neurosurg.* 1991 Feb;74(2):171–7.
- [89] Lykissas MG, Kostas-Agnantis IP, Korompilias AV, Vekris MD, Beris AE. Use of intercostal nerves for different target neurotization in brachial plexus reconstruction. *World J Orthop.* 2013 Jul 18;4(3):107–11.
- [90] Chu B, Hu S, Chen L, Song J. Anatomic study on intercostal nerve transfer to suprascapular nerve. *Zhongguo Xiu Fu Chong Jian Wai Ke Za Zhi Zhongguo Xiufu Chongjian Waike Zazhi Chin J Reparative Reconstr Surg.* 2012 Sep;26(9):1095–7.
- [91] Durand S, Oberlin C, Fox M, Diverrez JP, Dauge MC. Transfer of the first intercostal nerve to supra- and infraspinatus muscles: an anatomical study and report of the first case. *J Hand Surg Eur.* 2009 Apr;34(2):196–200.
- [92] Malungpaishrope K, Leechavengvongs S, Witoonchart K, Uerpairojkit C, Boonyalapa A, Janesaksrisakul D. Simultaneous intercostal nerve transfers to deltoid and triceps muscle through the posterior approach. *J Hand Surg.* 2012 Apr;37(4):677–82.
- [93] Ray WZ, Murphy RKJ, Santosa K, Johnson PJ, Mackinnon SE. Medial pectoral nerve to axillary nerve neurotization following traumatic brachial plexus injuries: indications and clinical outcomes. *Hand (NY).* 2012 Mar;7(1):59–65.
- [94] David S, Balaguer T, Baque P, Lebreton E. Transfer of pectoral nerves to suprascapular and axillary nerves: an anatomic feasibility study. *J Hand Surg.* 2010 Jan;35(1):92–6.
- [95] Narakas AO, Hentz VR. Neurotization in brachial plexus injuries. Indication and results. *Clin Orthop.* 1988 Dec;(237):43–56.
- [96] Chuang DC, Lee GW, Hashem F, Wei FC. Restoration of shoulder abduction by nerve transfer in avulsed brachial plexus injury: evaluation of 99 patients with various nerve transfers. *Plast Reconstr Surg.* 1995 Jul;96(1):122–8.
- [97] Samardzic M, Antunovic V, Joksimovic M, Bacetic D. Donor nerves in the reinnervation of brachial plexus. *Neurol Res.* 1986 Jun;8(2):117–22.
- [98] Goubier J-N, Teboul F. Transfer of the rhomboid nerve to the suprascapular nerve: An anatomical feasibility study. *Chir Main.* 2015 Sep;34(4):182–5.

- [99] Gu Y, Xu J, Chen L, Wang H, Hu S. Long term outcome of contralateral C7 transfer: a report of 32 cases. *Chin Med J (Engl)*. 2002 Jun;115(6):866–8.
- [100] Al-Thunyan A, Al-Qattan MM, Al-Meshal O, Al-Husainan H, Al-Assaf A. Hemi-hypoglossal nerve transfer for obstetric brachial plexus palsy: report of 3 cases. *J Hand Surg*. 2015 Mar;40(3):448–51.
- [101] Ray WZ, Pet MA, Yee A, Mackinnon SE. Double fascicular nerve transfer to the biceps and brachialis muscles after brachial plexus injury: clinical outcomes in a series of 29 cases. *J Neurosurg*. 2011 Jun;114(6):1520–8.
- [102] Liverneaux PA, Diaz LC, Beaulieu J-Y, Durand S, Oberlin C. Preliminary results of double nerve transfer to restore elbow flexion in upper type brachial plexus palsies. *Plast Reconstr Surg*. 2006 Mar;117(3):915–9.
- [103] Carlsen BT, Kircher MF, Spinner RJ, Bishop AT, Shin AY. Comparison of single versus double nerve transfers for elbow flexion after brachial plexus injury. *Plast Reconstr Surg*. 2011 Jan;127(1):269–76.
- [104] Martins RS, Siqueira MG, Heise CO, Foroni L, Teixeira MJ. A prospective study comparing single and double fascicular transfer to restore elbow flexion after brachial plexus injury. *Neurosurgery*. 2013 May;72(5):709–14; discussion 714–715; quiz 715.
- [105] Chuang DC, Yeh MC, Wei FC. Intercostal nerve transfer of the musculocutaneous nerve in avulsed brachial plexus injuries: evaluation of 66 patients. *J Hand Surg*. 1992 Sep;17(5):822–8.
- [106] Xiao C, Lao J, Wang T, Zhao X, Liu J, Gu Y. Intercostal nerve transfer to neurotize the musculocutaneous nerve after traumatic brachial plexus avulsion: a comparison of two, three, and four nerve transfers. *J Reconstr Microsurg*. 2014 Jun;30(5):297–304.
- [107] Moiyadi AV, Devi BI, Nair KPS. Brachial plexus injuries: outcome following neurotization with intercostal nerve. *J Neurosurg*. 2007 Aug;107(2):308–13.
- [108] Blaauw G, Slooff ACJ. Transfer of pectoral nerves to the musculocutaneous nerve in obstetric upper brachial plexus palsy. *Neurosurgery*. 2003 Aug;53(2):338–41, 342.
- [109] Samardzic M, Rasulic LG, Grujicic DM, Bacetic DT, Milicic BR. Nerve transfers using collateral branches of the brachial plexus as donors in patients with upper palsy – thirty years' experience. *Acta Neurochir (Wien)*. 2011 Oct;153(10):2009–19; discussion 2019.
- [110] Novak CB, Mackinnon SE, Tung THH. Patient outcome following a thoracodorsal to musculocutaneous nerve transfer for reconstruction of elbow flexion. *Br J Plast Surg*. 2002 Jul;55(5):416–9.
- [111] Soldado F, Ghizoni MF, Bertelli J. Thoracodorsal nerve transfer for triceps reinnervation in partial brachial plexus injuries. *Microsurgery*. 2016 Mar;36(3):191–7.
- [112] Samii A, Carvalho GA, Samii M. Brachial plexus injury: factors affecting functional outcome in spinal accessory nerve transfer for the restoration of elbow flexion. *J Neurosurg*. 2003 Feb;98(2):307–12.

- [113] Songcharoen P, Mahaisavariya B, Chotigavanich C. Spinal accessory neurotization for restoration of elbow flexion in avulsion injuries of the brachial plexus. *J Hand Surg.* 1996 May;21(3):387–90.
- [114] Gu YD, Ma MK. Use of the phrenic nerve for brachial plexus reconstruction. *Clin Orthop.* 1996 Feb;(323):119–21.
- [115] Flores LP. Results of surgical techniques for re-innervation of the triceps as additional procedures for patients with upper root injuries. *J Hand Surg Eur Vol.* 2013 Mar;38(3):248–56.
- [116] Bertelli JA, Ghizoni MF, Tacca CP. Transfer of the teres minor motor branch for triceps reinnervation in tetraplegia. *J Neurosurg.* 2011 May;114(5):1457–60.
- [117] Klika BJ, Spinner RJ, Bishop AT, Kircher MF, Shin AY. Posterior branch of the axillary nerve transfer to the lateral triceps branch for restoration of elbow extension: case report. *J Hand Surg.* 2013 Jun;38(6):1145–9.
- [118] Gao K, Lao J, Zhao X, Gu Y. Outcome after transfer of intercostal nerves to the nerve of triceps long head in 25 adult patients with total brachial plexus root avulsion injury. *J Neurosurg.* 2013 Mar;118(3):606–10.
- [119] Goubier J-N, Teboul F, Khalifa H. Reanimation of elbow extension with intercostal nerves transfers in total brachial plexus palsies. *Microsurgery.* 2011 Jan;31(1):7–11.
- [120] Flores LP. Reanimation of elbow extension with medial pectoral nerve transfer in partial injuries to the brachial plexus. *J Neurosurg.* 2013 Mar;118(3):588–93.
- [121] Flores LP, Socolovsky M. Phrenic nerve transfer for reconstruction of elbow extension in severe brachial plexus injuries. *J Reconstr Microsurg.* 2016 Sep;32(7):546–50.
- [122] Zhang C-G, Gu Y-D. Contralateral C7 nerve transfer—our experiences over past 25 years. *J Brachial Plex Peripher Nerve Inj.* 2011 Nov 23;6(1):10.
- [123] Flores LP. The radio-radial nerve transfer for elbow extension restoration in C5 to C7 nerve root injury. *Microsurgery.* 2012 Jan;32(1):55–9.
- [124] Asfazadourian H, Tramond B, Dauge MC, Oberlin C. Morphometric study of the upper intercostal nerves: practical application for neurotizations in traumatic brachial plexus palsies. *Chir Main.* 1999;18(4):243–53.
- [125] Luo P-B, Chen L, Zhou C-H, Hu S-N, Gu Y-D. Results of intercostal nerve transfer to the musculocutaneous nerve in brachial plexus birth palsy. *J Pediatr Orthop.* 2011 Dec;31(8):884–8.
- [126] Pondaag W, Malessy MJA. Intercostal and pectoral nerve transfers to re-innervate the biceps muscle in obstetric brachial plexus lesions. *J Hand Surg Eur Vol.* 2014 Jul;39(6):647–52.
- [127] Jiang Y, Wang L, Lao J, Zhao X. Comparative study of intercostal nerve transfer to lower trunk and contralateral C7 root transfer in repair of total brachial plexus injury in rats. *J Plast Reconstr Aesthetic Surg JPRAS.* 2016 May;69(5):623–8.

- [128] Giddins GE, Kakkar N, Alltree J, Birch R. The effect of unilateral intercostal nerve transfer upon lung function. *J Hand Surg Edinb Scotl.* 1995 Oct;20(5):675–6.
- [129] Xu W-D, Gu Y-D, Xu J-G, Tan L-J. Full-length phrenic nerve transfer by means of video-assisted thoracic surgery in treating brachial plexus avulsion injury. *Plast Reconstr Surg.* 2002 Jul;110(1):104–11.
- [130] Zheng M-X, Qiu Y-Q, Xu W-D, Xu J-G. Long-term observation of respiratory function after unilateral phrenic nerve and multiple intercostal nerve transfer for avulsed brachial plexus injury. *Neurosurgery.* 2012 Apr;70(4):796–801; discussion 801.
- [131] Wang S, Yiu H-W, Li P, Li Y, Wang H, Pan Y. Contralateral C7 nerve root transfer to neurotize the upper trunk via a modified prespinal route in repair of brachial plexus avulsion injury. *Microsurgery.* 2012 Mar;32(3):183–8.
- [132] Vanaclocha V, Herrera JM, Verdu-Lopez F, Gozalbes L, Sanchez-Pardo M, Rivera M, Martinez-Gomez D, Mayorga JD. Transdiscal C6-C7 contralateral C7 nerve root transfer in the surgical repair of brachial plexus avulsion injuries. *Acta Neurochir (Wien).* 2015 Dec;157(12):2161–7.
- [133] Mackinnon SE, Roque B, Tung TH. Median to radial nerve transfer for treatment of radial nerve palsy. Case report. *J Neurosurg.* 2007 Sep;107(3):666–71.
- [134] Ukrit A, Leechavengvongs S, Malungpaishrope K, Uerpairojkit C, Chongthammakun S, Witoonchart K. Nerve transfer for wrist extension using nerve to flexor digitorum superficialis in cervical 5, 6, and 7 root avulsions: anatomic study and report of two cases. *J Hand Surg.* 2009 Nov;34(9):1659–66.
- [135] Brown JM, Tung THH, Mackinnon SE. Median to radial nerve transfer to restore wrist and finger extension: technical nuances. *Neurosurgery.* 2010 Mar;66(3 Suppl Operative):75–83; discussion 83.
- [136] Bertelli JA, Tacca CP, Winkelmann Duarte EC, Ghizoni MF, Duarte H. Transfer of the pronator quadratus motor branch for wrist extension reconstruction in brachial plexus palsy. *Plast Reconstr Surg.* 2012 Dec;130(6):1269–78.
- [137] Bertelli JA, Kechele PR, Santos MA, Besen BAMP, Duarte H. Anatomical feasibility of transferring supinator motor branches to the posterior interosseous nerve in C7-T1 brachial plexus palsies. Laboratory investigation. *J Neurosurg.* 2009 Aug;111(2):326–31.
- [138] Bertelli JA, Ghizoni MF. Transfer of supinator motor branches to the posterior interosseous nerve in C7-T1 brachial plexus palsy. *J Neurosurg.* 2010 Jul;113(1):129–32.
- [139] Dong Z, Gu Y-D, Zhang C-G, Zhang L. Clinical use of supinator motor branch transfer to the posterior interosseous nerve in C7-T1 brachial plexus palsies. *J Neurosurg.* 2010 Jul;113(1):113–7.
- [140] Palazzi S, Palazzi J-L, Caceres J-P. Neurotization with the brachialis muscle motor nerve. *Microsurgery.* 2006;26(4):330–3.

- [141] Zheng X, Hou C, Gu Y, Shi Q, Guan S. Repair of brachial plexus lower trunk injury by transferring brachialis muscle branch of musculocutaneous nerve: anatomic feasibility and clinical trials. *Chin Med J (Engl)*. 2008 Jan 20;121(2):99–104.
- [142] Hsiao EC, Fox IK, Tung TH, Mackinnon SE. Motor nerve transfers to restore extrinsic median nerve function: case report. *Hand (NY)*. 2009 Mar;4(1):92–7.
- [143] Ray WZ, Yarbrough CK, Yee A, Mackinnon SE. Clinical outcomes following brachialis to anterior interosseous nerve transfers. *J Neurosurg*. 2012 Sep;117(3):604–9.
- [144] García-López A, Navarro R, Martínez F, Rojas A. Nerve transfers from branches to the flexor carpi radialis and pronator teres to reconstruct the radial nerve. *J Hand Surg*. 2014 Jan;39(1):50–6.
- [145] Vernadakis AJ, Humphreys DB, Mackinnon SE. Distal anterior interosseous nerve in the recurrent motor branch graft for reconstruction of a median nerve neuroma-in-continuity. *J Reconstr Microsurg*. 2004 Jan;20(1):7–11.
- [146] Wang Y, Zhu S. Transfer of a branch of the anterior interosseous nerve to the motor branch of the median nerve and ulnar nerve. *Chin Med J (Engl)*. 1997 Mar;110(3):216–9.
- [147] Mackinnon SE, Yee A, Ray WZ. Nerve transfers for the restoration of hand function after spinal cord injury. *J Neurosurg*. 2012 Jul;117(1):176–85.
- [148] Murphy RKJ, Ray WZ, Mackinnon SE. Repair of a median nerve transection injury using multiple nerve transfers, with long-term functional recovery. *J Neurosurg*. 2012 Nov;117(5):886–9.
- [149] Bertelli JA, Mendes Lehm VL, Tacca CP, Winkelmann Duarte EC, Ghizoni MF, Duarte H. Transfer of the distal terminal motor branch of the extensor carpi radialis brevis to the nerve of the flexor pollicis longus: an anatomic study and clinical application in a tetraplegic patient. *Neurosurgery*. 2012 Apr;70(4):1011–6; discussion 1016.
- [150] Boutros S, Nath RK, Yüksel E, Weinfeld AB, Mackinnon SE. Transfer of flexor carpi ulnaris branch of the ulnar nerve to the pronator teres nerve: histomorphometric analysis. *J Reconstr Microsurg*. 1999 Feb;15(2):119–22.
- [151] Gaul JS. Intrinsic motor recovery—a long-term study of ulnar nerve repair. *J Hand Surg*. 1982 Sep;7(5):502–8.
- [152] Haase SC, Chung KC. Anterior interosseous nerve transfer to the motor branch of the ulnar nerve for high ulnar nerve injuries. *Ann Plast Surg*. 2002 Sep;49(3):285–90.
- [153] Battiston B, Lanzetta M. Reconstruction of high ulnar nerve lesions by distal double median to ulnar nerve transfer. *J Hand Surg*. 1999 Nov;24(6):1185–91.
- [154] Barbour J, Yee A, Kahn LC, Mackinnon SE. Supercharged end-to-side anterior interosseous to ulnar motor nerve transfer for intrinsic musculature reinnervation. *J Hand Surg*. 2012 Oct;37(10):2150–9.
- [155] Tung TH, Barbour JR, Gontre G, Daliwal G, Mackinnon SE. Transfer of the extensor digiti minimi and extensor carpi ulnaris branches of the posterior interosseous nerve to restore intrinsic hand function: case report and anatomic study. *J Hand Surg*. 2013 Jan;38(1):98–103.

- [156] Leechavengvongs S, Ngamlamiat K, Malungpaishrope K, Uerpairotkit C, Witoonchart K, Kulkittiya S. End-to-side radial sensory to median nerve transfer to restore sensation and relieve pain in C5 and C6 nerve root avulsion. *J Hand Surg.* 2011 Feb;36(2):209–15.
- [157] Bertelli JA, Ghizoni MF. Nerve transfer for sensory reconstruction of C8-T1 dermatomes in tetraplegia. *Microsurgery.* 2016 Nov;36(8):637–641.
- [158] Bertelli JA, Ghizoni MF. Very distal sensory nerve transfers in high median nerve lesions. *J Hand Surg.* 2011 Mar;36(3):387–93.
- [159] Ducic I, Dellon AL, Bogue DP. Radial sensory neurotization of the thumb and index finger for prehension after proximal median and ulnar nerve injuries. *J Reconstr Microsurg.* 2006 Feb;22(2):73–8.
- [160] Xu B, Dong Z, Zhang C-G, Gu Y-D. Transfer of the radial branch of the superficial radial nerve to the sensory branch of the ulnar nerve for sensory restoration after C7-T1 brachial plexus injury. *J Plast Reconstr Aesthetic Surg JPRAS.* 2016 Mar;69(3):318–22.
- [161] Campbell AA, Eckhauser FE, Belzberg A, Campbell JN. Obturator nerve transfer as an option for femoral nerve repair: case report. *Neurosurgery.* 2010 Jun;66(6 Suppl Operative):375; discussion 375.
- [162] Tung TH, Chao A, Moore AM. Obturator nerve transfer for femoral nerve reconstruction: anatomic study and clinical application. *Plast Reconstr Surg.* 2012 Nov;130(5):1066–74.
- [163] Spiliopoulos K, Williams Z. Femoral branch to obturator nerve transfer for restoration of thigh adduction following iatrogenic injury. *J Neurosurg.* 2011 Jun;114(6):1529–33.
- [164] Giuffre JL, Bishop AT, Spinner RJ, Shin AY. Surgical technique of a partial tibial nerve transfer to the tibialis anterior motor branch for the treatment of peroneal nerve injury. *Ann Plast Surg.* 2012 Jul;69(1):48–53.
- [165] Bodily KD, Spinner RJ, Bishop AT. Restoration of motor function of the deep fibular (peroneal) nerve by direct nerve transfer of branches from the tibial nerve: an anatomical study. *Clin Anat (NY).* 2004 Apr;17(3):201–5.
- [166] Gousheh J, Arasteh E. Modified simple decompression of ulnar nerve in treatment of cubital tunnel syndrome. *World J Plast Surg.* 2012 Jan;1(1):11–5.
- [167] Ray WZ, Mackinnon SE. Nerve problems in the lower extremity. *Foot Ankle Clin.* 2011 Jun;16(2):243–54.
- [168] Ruggieri MR, Braverman AS, Bernal RM, Lamarre NS, Brown JM, Barbe MF. Reinnervation of urethral and anal sphincters with femoral motor nerve to pudendal nerve transfer. *Neurourol Urodyn.* 2011 Nov;30(8):1695–704.
- [169] Fox IK. Nerve transfers in tetraplegia. *Hand Clin.* 2016 May;32(2):227–42.
- [170] Brown JM. Nerve transfers in tetraplegia I: background and technique. *Surg Neurol Int.* 2011;2:121.
- [171] Fridén J, Gohritz A. Tetraplegia management update. *J Hand Surg.* 2015 Dec;40(12):2489–500.

- [172] Bryden AM, Hoyer HA, Keith MW, Mejia M, Kilgore KL, Nemunaitis GA. Upper extremity assessment in tetraplegia: the importance of differentiating between upper and lower motor neuron paralysis. *Arch Phys Med Rehabil*. 2016 Jun;97(6 Suppl):S97–104.
- [173] Hahn J, Cooper C, Flood S, Weymouth M, van Zyl N. Rehabilitation of supinator nerve to posterior interosseous nerve transfer in individuals with tetraplegia. *arch phys med rehabil*. 2016 Jun;97(6 Suppl):S160–8.
- [174] Bertelli JA, Ghizoni MF. Nerve transfers for elbow and finger extension reconstruction in midcervical spinal cord injuries. *J Neurosurg*. 2015 Jan;122(1):121–7.
- [175] Bertelli JA, Ghizoni MF. Nerve transfers for restoration of finger flexion in patients with tetraplegia. *J Neurosurg Spine*. 2017 Jan;26(1):55–61.
- [176] Fox IK, Davidge KM, Novak CB, Hoben G, Kahn LC, Juknis N, Ruvinskaya R, Mackinnon SE. Use of peripheral nerve transfers in tetraplegia: evaluation of feasibility and morbidity. *Hand (NY)*. 2015 Mar;10(1):60–7.
- [177] Hawasli AH, Chang J, Reynolds MR, Ray WZ. Transfer of the brachialis to the anterior interosseous nerve as a treatment strategy for cervical spinal cord injury: technical note. *Glob Spine J*. 2015 Apr;5(2):110–7.
- [178] van Zyl N, Hahn JB, Cooper CA, Weymouth MD, Flood SJ, Galea MP. Upper limb reinnervation in C6 tetraplegia using a triple nerve transfer: case report. *J Hand Surg*. 2014 Sep;39(9):1779–83.