

We are IntechOpen, the world's leading publisher of Open Access books Built by scientists, for scientists

4,800

Open access books available

122,000

International authors and editors

135M

Downloads

Our authors are among the

154

Countries delivered to

TOP 1%

most cited scientists

12.2%

Contributors from top 500 universities



WEB OF SCIENCE™

Selection of our books indexed in the Book Citation Index
in Web of Science™ Core Collection (BKCI)

Interested in publishing with us?
Contact book.department@intechopen.com

Numbers displayed above are based on latest data collected.
For more information visit www.intechopen.com



Gallbladder Cancer: Surgical Management

Adrian Bartoş, Andrei Herdean and
Dana Monica Bartoş

Additional information is available at the end of the chapter

<http://dx.doi.org/10.5772/67561>

Abstract

Gallbladder cancer represents one of the rare and highly fatal neoplastic diseases, early diagnosis and treatment being the key for an acceptable outcome. The best survival results are obtained for patients with T1-T2 stage, a radical cholecystectomy being sufficient in most of these cases. For advanced tumors, major liver resections could be necessary to obtain optimal oncological results. Although a high percentage of the patients are diagnosed with unresectable disease, the continuous progresses made in the field of surgical therapy and oncological treatment could finally improve the outcome of this neoplastic pathology.

Keywords: gallbladder cancer, surgical treatment, hepatic resection, radical colecistectomy, hepatic lymphadenectomy

1. Introduction

Biliary tract cancers are a group of neoplastic diseases that arise from the biliary epithelium. According to their localization, they are divided into: intrahepatic cholangiocarcinoma, perihilar cholangiocarcinoma, distal cholangiocarcinoma and gallbladder cancer. Gallbladder cancer represents one of the rare and highly fatal neoplastic diseases; early diagnosis and treatment are the key [1].

2. Epidemiology: risk factors

Gallbladder cancer is the fifth most common type of digestive cancer and the most frequent biliary tract cancer. The maximum incidence of this disease is reported in Chile, Bolivia and

other South-American countries [2]. Urban population presents a higher risk of developing gallbladder cancer [1]. The prognosis is a very poor one, with a 5-year overall survival rate of less than 10% [2]. During the last decade, the mortality rate has improved in developed countries, while in developing countries it is still at a high level [1]. Chronic inflammation of the gallbladder mucosa and all its predisposing factors increase the incidence of the disease. The most common risk factors for developing gallbladder cancer are: gallbladder lithiasis, old age, female sex, tobacco and alcohol abuse, multiple pregnancies, low physical activity, obesity and infectious diseases. The most common pathogens implicated in the development of gallbladder cancer are *Salmonella typhi*, *Salmonella paratyphi* and *Helicobacter* [1]. Gallstones, especially large ones, frequently associated with Mirizzi syndrome, represent the most common predisposing factor for gallbladder cancer [1]. Gallbladder polyps, the porcelain gallbladder and anatomical abnormalities of the ampulla of Vater, which causes bile reflux, are also predisposing factors. Diet is another important risk factor in the development of gallbladder cancer; increased intake of fried foods or those that cause constipation (less than one bowel movement in 6 days) increases the risk. On the other hand, in women, the intake of boiled beans, or in men, the intake of fish, lowers the incidence of gallbladder cancer. The involvement of environmental factors such as heavy metals (high levels of nickel, cadmium, manganese, copper, chromium and lead, as well as low levels of selenium or zinc) is not yet fully understood, requiring prospective studies conducted on large groups of patients [1]. Also, mutations of K-ras or p53 genes are still being studied; identifying a link between these mutations and the development of gallbladder cancer is still difficult [1].

A separate entity is represented by incidental gallbladder cancer discovered at histopathological examination of specimens resulted from cholecystectomy performed for gallbladder lithiasis [3]. These cases represent 47% of all cases of gallbladder cancer [4].

3. Pathology

Gallbladder cancer develops similar to other digestive cancers: the progression can be observed from dysplasia to infiltrative carcinoma at the level of gallbladder mucosa. The pre-neoplastic nature of gallbladder polyps is controversial, however there is some data showing the progression to adenocarcinoma. About 3–6% of the patients present with gallbladder polyps at the ultrasound examination [5]. Most of them are cholesterol polyps without any risk of becoming malignant. The risk of polyps for becoming malignant has been associated with old age, dimensions over 1 cm and the presence of a single polyp [5].

Gallbladder cancer presents most often as monocentric; multifocal forms are extremely rare. The most common localization is at the fundus of the gallbladder (60%), followed by the body (30%) and the infundibulum (10%) [5].

These tumors are considered highly aggressive since infiltrative forms are rapidly involving hepatic parenchyma, mostly segments IVb and V. Also, tumor extension can occur towards the cystic duct and its confluence with the common hepatic duct, in which case the presentation could be similar to a Klatskin tumor [6]. Malignant tumors of the gallbladder can invade

the branches of the hepatic artery or portal vein, which leads to the atrophy of the ipsilateral lobe and compensatory hypertrophy of the contralateral lobe.

The most common histological type of gallbladder malignant tumor is adenocarcinoma. The papillary form of adenocarcinoma has the best prognosis because this type of tumor tends to be noninvasive or minimally invasive [5]. However, we must not forget the other histological types, such as squamous cell or adenosquamous carcinoma, mucinous carcinoma, signet ring cell carcinoma and not least lymphomas and neuroendocrine tumors. Rare forms are represented by melanomas or secondary tumors localized at the level of the gallbladder.

Gallbladder cancer most commonly spreads directly into the surrounding organs. Step by step spreading is further enabled by thin gallbladder wall, which is formed by only one muscular layer and by the fact that the connective tissue of the gallbladder is continuous with the interlobular connective tissue of the liver [7]. This highly aggressive malignant tumor also spreads through satellite lymphatic vessels of the cystic duct to the hilar lymph nodes and further to the gastroduodenal lymph nodes, retropancreatic lymph nodes, celiac trunk lymph nodes and finally to the interaortocaval lymph nodes. Advanced cases of the disease determine enlarged lymph nodes at the level of the hepatic hilum, which erode and invade the portal vein wall, causing thrombosis and all the consequences of portal hypertension. Spreading to the peritoneum, which determines the occurrence of paraneoplastic ascites, as well as pulmonary and hepatic metastases, determine the infaust evolution of terminal cases.

4. Diagnosis

Gallbladder cancer can be diagnosed either preoperative or intraoperative during surgical treatment for another disease or after the histopathological examination of the specimen resulted from cholecystectomy for gallbladder lithiasis. The clinical signs of gallbladder cancer are not specific, which is why more than half of the cases cannot be diagnosed preoperatively. The lack of efficient screening methods for this disease also leads to the impossibility of an early diagnosis. The systematic examination of the specimens resulting from cholecystectomy improved the early diagnosis rate of this extremely aggressive neoplastic disease.

Even though clinical signs and symptoms are not specific, knowing and following them in patients suspected of having this disease is particularly important for proper management. Symptoms associated with gallbladder lithiasis or choledochal lithiasis are commonly found in the clinical presentation of gallbladder cancer. So, in symptomatic patients, abdominal pain with the character of biliary colic is a common sign, especially in cases when the cancer is diagnosed incidentally, during the treatment for an acute or chronic cholecystitis.

Jaundice and angiocholitis are also frequently seen in the clinical presentation of the gallbladder cancer [6]. In addition to jaundice, we can observe other paraneoplastic signs and symptoms like asthenia, fatigue and marked weight loss.

The physical examination of the patients reveals discomfort in the right hypochondrium, where it can also be found as a hard mass, which is poorly delimited and fixed due to tumor

invasion of surrounding organs. If gallbladder cancer is suspected, some laboratory tests and imaging examinations must be performed in order to establish a correct diagnosis.

Required laboratory tests are the usual ones and they determine mainly an extrahepatic cholestasis syndrome. Prolonged biliary stasis can also determine high levels of serum transaminases and other parameters that show liver failure. Most of the times, the laboratory findings do not establish an accurate diagnosis unless they reveal an advanced stage of disease. Biological signs of advanced disease are: anemia, low levels of serum albumin, high levels of leukocytes and extremely high alkaline phosphatase and conjugated bilirubin levels [5]. Relevant tumor markers are CEA and CA 19-9. A high level of CEA has a specificity of 90% for malignant tumors of the gallbladder, but has a low sensitivity (50%) [5] when it is used for screening because it is also elevated by benign tumors. The tumors markers have a low utility for gallbladder cancer's diagnosis but they are extremely important for the follow-up of these patients.

Imaging exams are crucial for diagnosing and staging of this disease and they usually reveal asymmetric thickness of the gallbladder wall. Since polyps or malignant tumors of the gallbladder could have similar imaging characteristics to the normal gallbladder wall, an accurate diagnosis is difficult to establish. The situation can be further complicated by a certain degree of inflammation of the gallbladder wall caused by lithiasis.

The ability of ultrasound examination to reveal this disease has been appreciably improved by employing ecoendoscopic techniques, which in some cases is even more accurate than computed tomography (CT) or magnetic resonance imaging (MRI) [6]. CT imaging with intravenously administered contrast may reveal a tumor at the level of the gallbladder, which invades hepatic parenchyma and other adjacent organs. Despite this, an accurate staging using CT is hard to achieve due to the weak sensitivity for identifying possible lymph node metastases [6]. MRI has better sensitivity for both identifying possible lymph node metastases and for revealing any invasion at the level of the adjacent hepatic parenchyma. This is best evidenced by MRI T2 sections [8].

5. Staging

Staging is a key moment in the management of patients presenting with malignant gallbladder tumors. The American Joint Committee on Cancer (AJCC) proposes the tumor-lymph nodes-metastasis (TNM) staging as follows (**Table 1**).

Complete staging is obtained by a combination of imaging: ultrasound, CT, MRI, positron emission tomography (FDG-PET) and diagnostic laparoscopy. Diagnostic laparoscopy is superior in identifying possible peritoneal spread, as well as other absolute contraindications for radical surgery. Its employment has led to a decreased rate of blind laparotomies [9].

Diagnostic laparoscopy combined with intraoperative ultrasound techniques, with or without contrast, has better sensitivity in identifying liver metastases and allows for a more precise evaluation of tumor adjacent blood vessels involvement. The invasion of adjacent organs (liver, stomach, duodenum, pancreas, colon, greater omentum and abdominal wall) can also

been revealed through laparoscopy. In case of a suspected distant metastasis, the FDG-PET examination is recommended [6].

Primary tumor (T)

TX	Primary tumor cannot be assessed
T0	No evidence of primary tumor
Tis	Carcinoma in situ
T1	Tumor invades lamina propria or muscular layer
T1a	Tumor invades lamina propria
T1b	Tumor invades muscular layer
T2	Tumor invades perimuscular connective tissue; no extension beyond serosa or into liver
T3	Tumor perforates the serosa (visceral peritoneum) and/or directly invades the liver and/or one other adjacent organ or structure, such as the stomach, duodenum, colon, pancreas, omentum, or extrahepatic bile ducts
T4	Tumor invades main portal vein or hepatic artery or invades two or more extrahepatic organs or structures

Regional lymph nodes (N)

NX	Regional lymph nodes cannot be assessed
N0	No regional lymph node metastasis
N1	Metastases to nodes along the cystic duct, common bile duct, hepatic artery and/or portal vein
N2	Metastases to periaortic, pericaaval, superior mesenteric artery and/or celiac artery lymph nodes

Distant metastasis (M)

M0	No distant metastasis
M1	Distant metastasis

Anatomic stage/prognostic groups

Stage 0	Tis	N0	M0
Stage I	T1	N0	M0
Stage II	T2	N0	M0
Stage IIIA	T3	N0	M0
Stage IIIB	T1-3	N1	M0
Stage IVA	T4	N0-1	M0
Stage IVB	Any T	N2	M0
	Any T	Any N	M1

Table 1. TNM staging (after AJCC 7th edition).

The preoperative histopathological diagnosis is not considered necessary in case of clinical or imagistic suspicion of gallbladder cancer, because during biopsy, peritoneal or biopsy tract spreading may occur. In addition, the rate of false negative results of biopsies is significant [5]. As such, a negative biopsy must not be taken into consideration.

6. Surgical treatment of gallbladder cancer

The treatment of gallbladder cancer is a multimodal one and implicates a multidisciplinary team. Needless to say, the treatment methods must be adapted both to the patient's status and the stage of the disease [3]. Surgical treatment remains the only curative alternative, but its results have been improved by the emergence of new oncologic treatments. Surgical treatment is done according to the stage of the disease and is divided in two categories: curative and palliative. It is necessary to identify the absolute contraindications for radical surgery. These are: liver metastases, peritoneal carcinomatosis, involvement of N2 lymph nodes (lymph nodes of the celiac trunk, peripancreatic lymph nodes, periduodenal lymph nodes and superior mesenteric lymph nodes) and the invasion to the lesser omentum or of greater blood vessels [9]. If at least one of the contraindications above is identified, surgery can be considered just for palliation. The invasion of adjacent organs (colon, duodenum and liver) does not represent an absolute contraindication to radical surgery; en bloc resection of the tumor and invaded organs could be performed [3].

6.1. Radical treatment: indications and prognosis

6.1.1. T1 tumors

Usually, incidentally diagnosed cancers on specimens resulting from cholecystectomy are T1a tumors. These lesions are limited to the lamina propria and the performed cholecystectomy is considered to be sufficient if obtained resection margins are negative. In cases with T1b tumors, due to the 50% 1-year survival rate [3], a follow-up on the initial intervention with a resection of IVb and V segments of the liver (**Figure 1**) and lymphadenectomy along the portal pedicle is necessary.

6.1.2. T2 tumors

For this type of tumors, simple cholecystectomy is not sufficient. Hepatic resection and loco-regional lymphadenectomy is necessary. Major hepatic resections (right hepatectomy or extended right hepatectomy) may be necessary if the invasion of the right branch of the portal vein occurs. Simple cholecystectomy performed in T2 tumors offers a 5-year survival rate of 40%, compared to an 80% 5-year survival rate for en bloc resections of the tumor [3]. Given its close anatomical relation with the gallbladder, the right branch of the portal pedicle is most susceptible to tumoral invasion. In some cases, in order to obtain negative resection margins, it is necessary to perform a bile duct resection and a biliodigestive anastomosis. Thus, an extemporaneous examination of the cystic stump is vital for certifying oncologic

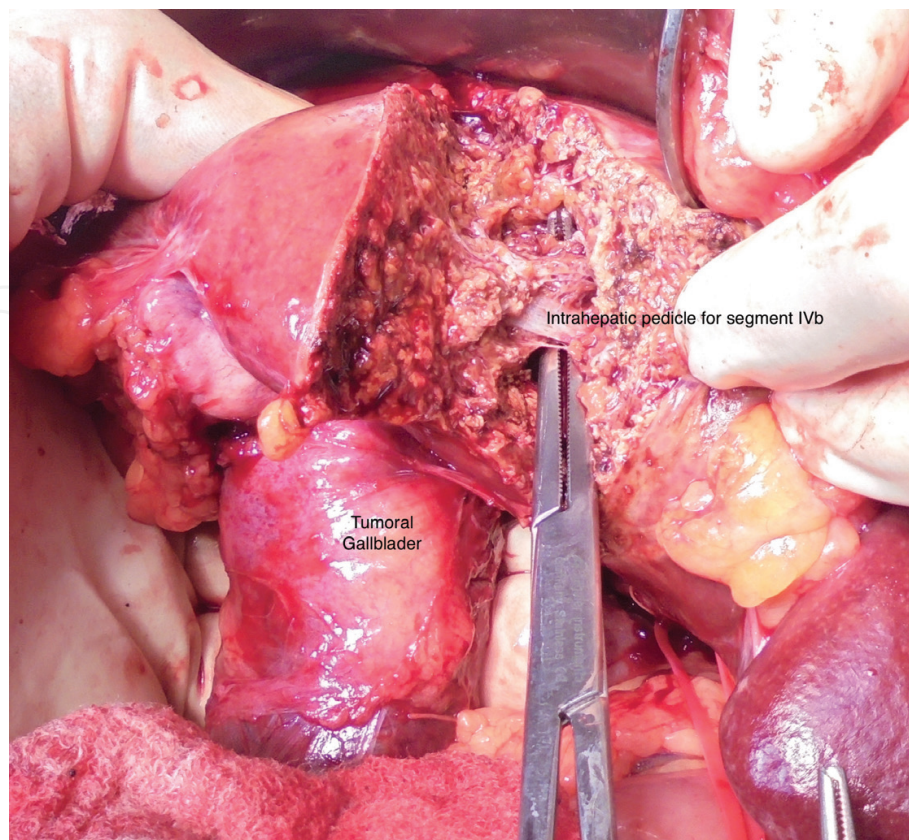


Figure 1. Resection of segment IVb-V, “in block” with the tumoral gallbladder. Dissection of the glissonian pedicles (intraoperative aspect, from the personal archive of the authors).

radicality. It is important that bile duct resection to be performed in attentively selected cases where the benefit outweighs the complication rate of the necessary biliodigestive anastomosis [1]. Lymphadenectomy is demonstrated to improve the prognosis if N1 lymph nodes are involved, whereas in patients presenting N2 lymph nodes involvement, lymphadenectomy will not bring certain benefits [3]. Thus, N2 lymph nodes involvement represents a negative factor in patient outcome.

6.1.3. T3 tumors

As in the case of T2 tumors, for T3 tumors, simple cholecystectomy is not considered sufficient from an oncological point of view. Hepatic resection and loco-regional lymphadenectomy are necessary. If adjacent organs are involved, en bloc resection is necessary due to the difficulty in distinguishing, from a macroscopic point of view, between inflamed tissue and tumor invasion. A 5-year survival rate between 30 and 50% is obtained in case of R0 resections [3].

6.1.4. T4 tumors

T4 classified tumors are in most cases unresectable without any oncologic radicality preten-tion. In this stage, the palliative surgical approach combined with chemoradiotherapy is the only therapeutic alternative [3].

6.2. Surgical technique

6.2.1. Open and laparoscopic cholecystectomy

Simple cholecystectomy is the surgical intervention whereby the gallbladder and a portion of the cystic duct are removed. This can be performed either open or by laparoscopy. Regardless of the approach, three types of cholecystectomy can be distinguished: retrograde, anterograde or bipolar. In cases presenting with T1a gallbladder tumors, simple cholecystectomy is sufficient for obtaining a radical resection. Most guidelines state that in surgical oncology, the preferred approach is the open one, but due to a substantial improvement in laparoscopic techniques, the latter have gained popularity in recent years.

Cholecystectomy is usually performed with the patient placed in a supine position with the arms abducted, the main surgeon being situated on the patient's right side. The laparotomy is usually done through a right subcostal incision. For the laparoscopic approach, multiple variants of trocar placement have been described; it is the surgeon's decision to choose the preferred method. After entering the peritoneal cavity, the first surgical step is to evaluate the local situation and to perform adhesions' dissection, for a better view of the region of interest. At the same time, the peritoneal cavity is inspected for evidence of possible associated pathologies such as peritoneal carcinomatosis or paraneoplastic ascites and to evaluate the subhepatic region.

The cholecystectomy can be performed either retrograde (with the primary dissection of the gallbladder pedicle at the level of Calot triangle) or anterograde (with primary dissection of the gallbladder from its hepatic fossa). The anterograde cholecystectomy may be useful in cases where the primary dissection of Calot triangle is difficult due to adhesions or anatomic modifications.

The most important moment in performing the cholecystectomy is the dissection of Calot triangle, where the elements of the gallbladder pedicle are located. The isolation, ligation and resection of the cystic duct and artery are performed at this level. At this point in the procedure, the prelevation of a sample from the cystic duct stump is necessary for performing the histopathological assessment of the resection margin. The next step of the procedure is the dissection of the gallbladder from its hepatic fossa using the electrocautery. Following that, the gallbladder extraction is performed through the subxiphoidian incision, with or without the enlargement of the aponeurosis. Given the high risk of spreading malignant cells into the abdominal wall, the gallbladder is extracted using an endobag.

There is at least a theoretical risk of trocar port or peritoneal tumoral recurrence. The risk of peritoneal tumor spreading is increased by the leakage of bile or calculi from the gallbladder during its dissection. For this reason, the dissection of the gallbladder from its hepatic fossa needs to be performed with increased attention in order to minimize the risk of creating breaches into the gallbladder wall. Port-site excision is to be considered in case when the diagnosis is made incidentally based on the histopathological assessment of the cholecystectomy specimen. The practice of excising port-sites is not routinely imposed as it does not modify the survival rate of these patients [10].

6.2.2. *Radical cholecystectomy*

In cases with gallbladder tumors staged over T1a, the required surgical approach is radical cholecystectomy, combined, in selected cases, with liver resections. Radical cholecystectomy is defined as the removal of the gallbladder and the hepatic parenchyma corresponding to its fossa, with a resection margin of minimum 2 cm [11]. After exposing the subhepatic region, the liver parenchyma corresponding to gallbladder fossa is marked using the electrocautery. The blood loss from transected liver parenchyma can be minimized by using recent generation surgical instruments, as well as intra-anesthetic lowering the central venous pressure. The Calot triangle dissection is performed in the same manner as for simple cholecystectomy. The specimen obtained is sent for extemporaneous histopathological assessment of the resection margins. If the margins are negative, a portal pedicle lymphadenectomy is performed. If the resection margins are positive, the resection must be completed by either resecting more liver parenchyma or by the resection of the bile duct with performing a bilio-digestive anastomosis. If it is necessary to resect more liver parenchyma, an anatomical resection of segments IVb and V is considered to be appropriate [5].

6.2.3. *Resection of segments IVb and V*

After entering the abdominal cavity through a right subcostal incision, the liver and the subhepatic region are assessed. After splitting the hepatic parenchyma to the right side of the falciform ligament, the inflow vessels to segments IVa and IVb are identified and only the vessels to segment IVb are ligated and divided, preserving segment IVa. After this, the transection of the liver parenchyma is performed and the middle hepatic vein is identified and divided in the middle of the liver. As the transection continues, the pedicle of segment V is identified, ligated and divided. A lot of attention should be given not to damage the right and left hilar structures during transection. After the specimen is removed, the hemostasis control is performed and the abdominal cavity is drained. The abdominal wall is closed in anatomical layers [5, 12].

6.2.4. *Extended liver resections*

Extended liver resections are necessary especially if the tumor is localized at the level of body or infundibulum of the gallbladder. Most frequently, it is necessary to perform an extended right hepatectomy, due to the close anatomic relation between the gallbladder and the right portal pedicle. In numerous cases, it is difficult to distinguish between inflamed tissue and tumoral invasion at the level of the right portal pedicle and it is necessary to perform the right hepatectomy to ensure a curative surgical attempt.

The right hepatectomy is defined as the removal of segments V, VI, VII and VIII of the liver. The extended right hepatectomy imply additional resection of segment IV. After entering the peritoneal cavity through a right subcostal incision (Kocher incision), the first surgical step is to mobilize the liver by cutting the falciform, right triangular and coronary ligament. After the liver is mobilized, a visual and manual assessment of the liver is mandatory. By

incising the hepato-duodenal ligament, the portal pedicle is visualized. It is crucial not to injure the left portal pedicle during dissection. By dissecting towards Calot triangle, the cystic artery and duct are isolated, ligated and divided. After the dissection at the level of the portal pedicle is made, the right branch of the hepatic artery and the right portal branch are isolated, ligated and divided to obtain a control on the blood inflow. The right hepatic duct may be ligated and sectioned by the time when liver transection is performed. Next step to be performed is the exposure of the right hepatic vein. By turning the liver to the left, a good assessment of the hepatic veins can be made, at the caval confluence. There might be some collateral veins that drain directly into the inferior vena cava and they must be carefully identified, ligated and divided. After the right hepatic vein is isolated, ligated and divided, the next step is the liver transection. This surgical step can be performed in multiple ways, with or without the use of recent generation surgical instruments. A fast way to perform liver transection is by using a Kelly clamp to crush the liver tissue and identify, ligate and divide the vasculo-biliary structures. After the transection is made, the diffuse blood loss from the liver tissue can be controlled with surgical devices such as plasma scalpel. For adjunctive hemostasis, a fibrin sealant patch may be used. After removing the right liver, an assessment of the whole surgical field is mandatory to identify any source of bleeding or bile leakage. Finally, drainage of the abdominal cavity is recommended. The abdominal wall is closed in anatomical layers [13].

6.2.5. Bile duct resection

Extrahepatic bile duct resection is necessary either if a tumoral invasion of the common bile duct is present or if at the extemporaneous histological assessment, malignant cells are revealed at the level of the cystic duct stump. Once negative margins are obtained, the continuity of the biliary tract is restored through a Roux-en-Y hepaticojejunostomy [11].

6.2.6. Lymphadenectomy

The status of the lymph nodes represents an important prognosis factor for all patients undergoing surgery for gallbladder cancer. Lymphadenectomy is mandatory in all cases of tumors staged T1b and above, even if there are no macroscopic signs of lymphatic spread. The prognosis is significantly improved in patients for which the lymphadenectomy is performed; the 5-year survival rate increases to 57%, compared to only 12% in cases where the lymphadenectomy was not performed [14]. The D1 lymphadenectomy is defined by the removal of lymph nodes situated at the level of the hepatic pedicle and the hepato-duodenal ligament (cystic artery, hepatic artery, portal vein and common bile duct) (**Figure 2**). The extended lymphadenectomy (D2) consists of extending the lymphadenectomy to the N2 classified lymph nodes: periaortic, celiac artery, superior mesenteric artery and inferior vena cava nodes. This type of lymphadenectomy should be performed in cases where this is possible without performing large scale surgical procedures, which increase the risk of postoperative complications. The only certain benefit of performing the D2 lymphadenectomy is obtaining a more accurate staging; the patient survival rate is not significantly influenced [14, 15].

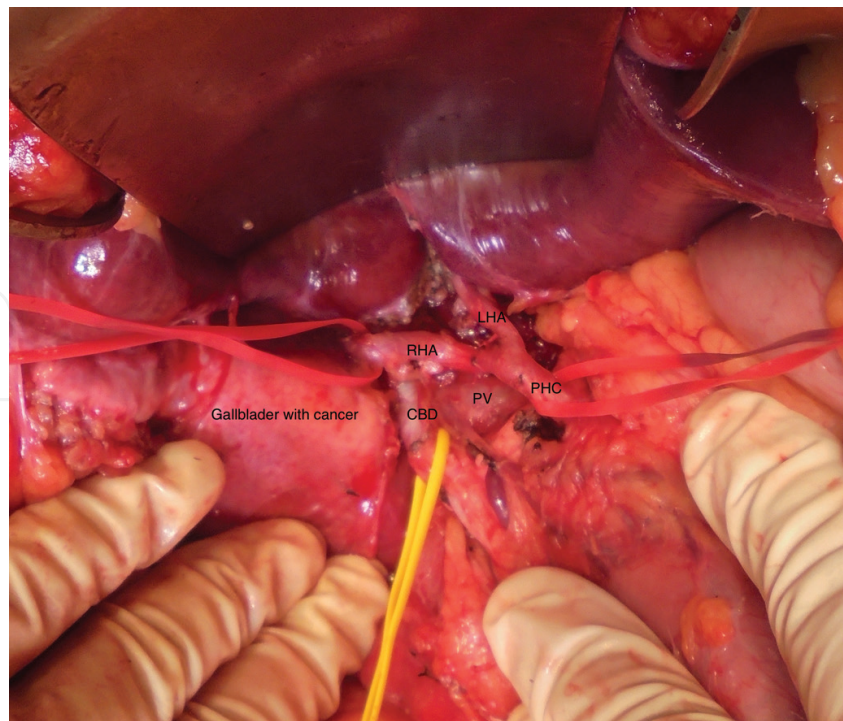


Figure 2. Lymphadenectomy along the portal pedicle. PHA, proper hepatic artery, RHA, right hepatic artery, LHA, left hepatic artery, CBD, common bile duct, PV, portal vein (intraoperative aspect, from the personal archive of the authors).

6.3. Palliative treatment

When unresectable gallbladder cancer is certain, it is important to aid the patient by applying a palliative treatment that is meant to improve the quality of life. Patients in an advanced stage of the disease are often presenting with jaundice, pruritus, pain in the upper right abdominal quadrant or bowel obstruction [12]. The optimal palliative procedure is one that provides the remission of symptoms with a minimum of risk (**Table 2**) [12]. The palliation can be performed either endoscopically or surgically, the approach depending on the biological status of the patient and the prognosis of the disease. Surgical jaundice palliation presents a higher rate of complications compared to the endoscopic approach [16].

6.3.1. Bilio-digestive anastomosis

Performing a bilio-digestive anastomosis is necessary for unresectable locally advanced tumors, which cause jaundice. In most cases, a locally advanced tumor invades the confluence of the hepatic ducts, so a Roux-en-Y hepaticojejunostomy is not viable [12]. In these situations, endoscopic drainage by transtumoral stenting or ultrasound/CT-guided external transparietohepatic biliary drainage can be the only alternative.

6.3.2. Digestive bypass

Digestive bypasses represent a method of palliation used for patients presenting with bowel obstruction caused by tumoral invasion of the duodenum or colon. If the duodenum is

Symptom	Palliative method
Jaundice	Endoscopic placement of a stent
Pruritus	Surgical bilio-digestive anastomosis
Pain	Celiac trunk alcoholization <ul style="list-style-type: none"> • Percutaneous • Ecoendoscopic • Laparoscopic
Bowel obstruction	Gastroenteroanastomosis (invasion of the duodenum) Digestive bypass (invasion of the colon)

Table 2. Palliative options for unresectable gallbladder cancer.

involved, an Omega or Roux-en-Y gastroenteroanastomosis should be performed. If the colon is involved (a rare occurrence), an internal bypass is the most frequently used method.

7. Oncological treatment

Oncological treatment supports the surgical act and is meant to improve the outcome of gallbladder cancer patients. The prognosis of this pathology is extremely poor, with a high rate of recurrence, even in patients undergoing radical surgical treatment. Thus, efficient oncological treatment is necessary in order to improve the rate of survival. There are few randomized trials conducted on patients with resectable tumors, so the efficacy of adjuvant oncological therapy cannot be well assessed. At the same time, oncological treatments can be used for palliative purposes in patients presenting unresectable tumors. The following paragraphs summarize the different types of oncological treatment.

7.1. Adjuvant treatment

Due to a high rate of recurrence, adjuvant treatment comes in the form of radiotherapy, possibly combined with chemotherapy [17]. A meta-analysis of 20 studies (6712 patients) evaluating the impact of chemotherapy, radiotherapy and their combination performed for adjuvant purposes, indicates an insignificant benefit in unselected cases. However, in cases of subgroups of patients defined as presenting an increased risk of recurrence (positive resection margins or an advanced degree of lymph node involvement), adjuvant therapy provides a positive influence on prognosis [17].

A consensus regarding the optimal adjuvant therapy has not been reached; there are multiple methods of applying this type of treatment. Due to the high risk of distant metastasis occurrence, a possible avenue of treatment can be starting with 6 months of chemotherapy, which can lead to avoiding unnecessary radiotherapy for patients that develop distant metastases (cases that would not benefit from radiotherapy anyway) [18]. In the case of patients who have positive

resection margins, combined treatment (chemotherapy and radiotherapy) is recommended. An option is to perform intraoperative radiotherapy. This is meant to improve the prognosis but there is little evidence indicating a real benefit of this treatment [19]. One advantage of intraoperative radiotherapy is the possibility of targeted administration of a high dosage of radiation directly on the tumor, while protecting the adjacent, highly radiosensitive, tissues [18].

7.2. Palliative oncological treatment

In cases of unresectable tumors (see Section 6) palliative chemoradiotherapy can be performed. In the past, the used chemotherapeutic treatment was 5-FU, Methotrexate, Mitomycin C and Doxorubicin, with a response rate of 10–20% [5]. More recently, the use of gemcitabine and oxaliplatin has improved the response rate up to 50%. On the other hand, radiotherapy has a palliative effect for locally advanced tumors (stages T3 and above) and is usually well tolerated and insures the remission of symptoms [5]. Radiotherapy is most commonly used in combination with chemotherapy.

8. Outcomes

8.1. Perioperative morbidity and mortality for radical interventions

The perioperative risk depends on the stage of the disease and the biological status of the patient. It is important to balance the risk of surgery to the risk of the untreated disease. Surgery should be performed with curable intent just when the patient is capable to support it. If the biological status of the patient does not support a radical approach it should be ameliorated preoperatively.

Gallbladder cancer surgery is accompanied by a lot of possible complications, some of them very difficult to manage. Most feared complications are: postoperative bleeding, bile leak and perihepatic abscess.

The perioperative mortality rate is significantly higher in patients with extended hepatic resections compared with those who underwent limited resections (resection of segments IVb and V), radical cholecystectomy or simple cholecystectomy [20]. An improvement in the outcome of patients underwent extended liver resection has been obtained by the progresses made in the field of surgical techniques, anesthetic and intensive care management.

Long-term outcome is extremely poor due to the high aggressive nature of this type of cancer. Only patients staged T1 have better long-term outcome, but unfortunately only approximately 10% of symptomatic patients reveals to be T1 and up to 20% from the incidentally diagnosed patients have T1 tumors.

8.2. Survival rate after radical treatment

The survival rate of patients undergoing surgery for gallbladder cancer depends of the disease's stage.

For T1a tumors, limited to the lamina propria, radical resection is obtained by simple cholecystectomy in many cases. The 5-year overall survival rate of these patients is reported to range between 97 and 99% [21].

For T1b and T2 patients, the oncologic radicality is easy to obtain by performing a liver resection including segments IVb and V, combined with lymphadenectomy at the level of the lesser omentum. The 5-year survival rate in these cases, if the appropriate surgical approach is performed, ranges between 59 and 90% [21].

For T3 and T4 tumors, it becomes challenging to balance the surgical risk of an extensive resection with the possible benefit. It is known that if a more extensive liver resection is performed, a higher rate of complications may occur. However, by recent improving of the surgical techniques, the rate of complications after major liver surgery has been improved and more extensive resections can be made with a diminished morbidity and mortality rate. The 5-year survival rate is reported to be 25% after major resections.

8.3. Survival rate for palliative treatment

Patients presenting unresectable gallbladder tumors benefit from palliative treatment to increase their quality of life. The overall survival rate is not significantly improved by palliative treatment, but there may be some benefits of chemoradiotherapy (as we discussed in Section 7.2).

8.4. Survival rate without treatment

Advanced gallbladder cancer has a very poor survival rate without any treatment even if the patient has a good performance status. The overall survival is 4.4 months for unresectable and untreated gallbladder cancers [20]. The presence of metastases at the moment of the diagnosis appeared to decrease the survival rate.

9. Future perspective

9.1. Intraoperative ultrasonography

Because preoperative imagistic staging of gallbladder cancer is difficult, the intraoperative ultrasound techniques are more and more used to obtain an accurate staging before choosing an appropriate surgical approach. The staging laparoscopy can be combined with the ultrasonographic assessment of the tumor to improve the accuracy of the diagnosis. As it is shown by a recent meta-analysis, the sensitivity of staging laparoscopy is improved when it is associated with intraoperative ultrasonography from 55.9 to 65.7% [22]. Laparoscopic ultrasonography is used for identification of liver lesions and for showing the precise location of the tumor and its relations with surrounding blood vessels. However, the intraoperative ultrasound assessment of hepatic hilum is very difficult and requires an experienced surgeon with high knowledge of liver imaging. The sensitivity of intraoperative ultrasound has been improved by the use of micro-bubble agents [23].

9.2. Navigation surgery

This new concept is being used in other surgical specialties, but in visceral surgery its usage is just at the beginning. Intraoperative navigation is a new technique that, with the use preoperative tomographic images, provides a virtual imaging of the anatomical region of interest so both the patient safety and the accuracy of the surgical procedure are improved [24].

9.3. Intraoperative fluorescence

Indocyanine is a fluorescent agent that has been used to evaluate the liver function. More recently, indocyanine is used for assessing the involvement of lymph nodes during breast and digestive surgery. In surgery of the liver, indocyanine has also been used for detecting the exact location of the tumors, the liver segmentation and biliary leakage. The role of this method is not completely understood. A disadvantage of the method is represented by the fact that only superficial tumors can be detected, due to limited depth of detected tissue [23]. There are few studies that assess the role of intraoperative fluorescence with indocyanine and further studies should be conducted to have a better view on this innovative technique.

10. Key points

- Extremely difficult early diagnosis and poor long-term outcome makes the gallbladder cancer an issue in the field of cancer management.
- Early diagnosis (T1a–b) is crucial; only a radical treatment will provide a proper long-term survival rate.
- The tumors that are staged T2 or T3 have an extremely poor prognosis, even if extended lymphadenectomies and hepatic resections are performed.
- Depending on the cancer spreading and the complications that follow, palliative oncologic treatment can be combined with certain surgical approach in cases with T4-staged tumors.
- The role of adjuvant and neoadjuvant therapies is not yet clearly established; the long-term outcome is not significantly improved by these.
- The continuous development of screening and diagnostic methods, combined with the improvement of surgical techniques due to intraoperative imaging, may lead to better outcome for the patients treated with gallbladder cancer.

Acknowledgements

Adrian Bartoş is the coordinator of this chapter.

Author details

Adrian Bartoș^{1*}, Andrei Herdean¹ and Dana Monica Bartoș^{1,2}

*Address all correspondence to: bartos.adi@gmail.com

1 Regional Institute of Gastroenterology and Hepatology, Cluj-Napoca, Romania

2 Anatomy Department, “Iuliu Hatieganu” University of Medicine, Cluj-Napoca, Romania

References

- [1] Gani F, Buettner S, Margonis G, Ethun C, Poultides G, Tran T et al. Assessing the impact of common bile duct resection in the surgical management of gallbladder cancer. *Journal of Surgical Oncology*. 2016;114(2):176–180.
- [2] Aloia T, Járufe N, Javle M, Maithel S, Roa J, Adsay V et al. Gallbladder cancer: expert consensus statement. *HPB*. 2015;17(8):681–690.
- [3] Jayaraman S, Jarnagin W. Management of gallbladder cancer. *Gastroenterology Clinics of North America*. 2010;39(2):331–342.
- [4] Desser TS, Hann LE. Ultrasound of the liver, biliary tract, and pancreas. In: Jarnagin W, Belghiti J, Blumgart L (Eds). *Blumgart’s surgery of the liver, biliary tract, and pancreas*. 5th ed. Philadelphia: Elsevier Saunders; 2012; 204–231.
- [5] Kingham TP, D’Angelica MI. Cancer of the gallbladder. In: Jarnagin W, Belghiti J, Blumgart L (Eds). *Blumgart’s surgery of the liver, biliary tract, and pancreas*. 5th ed. Philadelphia: Elsevier Saunders; 2012; 744.
- [6] Weber S, Yamane B, Fong Y. Biliary neoplasms. In: Greenfield L, Mulholland M (Eds). *Greenfield’s surgery*. 1st ed. Philadelphia: Wolters Kluwer Health/Lippincott Williams & Wilkins; 2011; 997–1003.
- [7] Winston C, Teitcher J. Computed tomography of the liver, biliary tract, and pancreas. In: Jarnagin W, Belghiti J, Blumgart L (Eds). *Blumgart’s surgery of the liver, biliary tract, and pancreas*. 1st ed. Philadelphia: Elsevier Saunders; 2012; 272–312.
- [8] Kingham TP, D’Angelica MI. Cancer of the gallbladder. In: Jarnagin W, Belghiti J, Blumgart L (Eds). *Blumgart’s surgery of the liver, biliary tract, and pancreas*. 1st ed. Philadelphia: Elsevier Saunders; 2012; 750.
- [9] Gallbladder cancer: epidemiology, risk factors, clinical features, and diagnosis [Internet]. Uptodate.com. 2016. [cited 28 December 2016]. Available from: http://www.uptodate.com/contents/gallbladder-cancer-epidemiology-risk-factors-clinical-features-and-diagnosis?source=search_result&search=gallbladder+cancer&selectedTitle=1~51

- [10] Fuks D, Regimbeau J, Pessaux P, Bachellier P, Raventos A, Manton G et al. Is port-site resection necessary in the surgical management of gallbladder cancer? *Journal of Visceral Surgery*. 2013;150(4):277–284.
- [11] Surgical management of gallbladder cancer [Internet]. Uptodate.com. 2016. [cited 28 December 2016]. Available from: http://www.uptodate.com/contents/surgical-management-of-gallbladder-cancer?source=search_result&search=Surgical+management+of+gallbladder+cancer&selectedTitle=1~150
- [12] Kakaei F, Beheshtirouy S, Nejatollahi S, Zarrintan S, Mafi M. Surgical treatment of gallbladder carcinoma: a critical review. *Updates in Surgery*. 2015;67(4):339–351.
- [13] Maithel SK, Jarnagin WR, Belghiti J. Hepatic resection for benign disease and for liver and biliary tumors. In: Jarnagin W, Belghiti J, Blumgart L (Eds). *Blumgart's surgery of the liver, biliary tract, and pancreas*. 1st ed. Philadelphia: Elsevier Saunders; 2012; 1461–1511.
- [14] Birnbaum D, Viganò L, Russolillo N, Langella S, Ferrero A, Capussotti L. Lymph node metastases in patients undergoing surgery for a gallbladder cancer. Extension of the lymph node dissection and prognostic value of the lymph node ratio. *Annals of Surgical Oncology*. 2014;22(3):811–818.
- [15] Ito H, Ito K, D'Angelica M, Gonen M, Klimstra D, Allen P et al. Accurate staging for gallbladder cancer. *Annals of Surgery*. 2011;254(2):320–325.
- [16] Buettner S, Wilson A, Margonis G, Gani F, Ethun C, Poultsides G et al. Assessing trends in palliative surgery for extrahepatic biliary malignancies: a 15-year multicenter study. *Journal of Gastrointestinal Surgery*. 2016;20(8):1444–1452.
- [17] Horgan A, Amir E, Walter T, Knox J. Adjuvant therapy in the treatment of biliary tract cancer: a systematic review and meta-analysis. *Journal of Clinical Oncology*. 2012;30(16):1934–1940.
- [18] Adjuvant treatment for localized, resected gallbladder cancer [Internet]. Uptodate.com. 2016. [cited 28 December 2016]. Available from: http://www.uptodate.com/contents/adjuvant-treatment-for-localized-resected-gallbladder-cancer?source=search_result&search=adjuvant+treatment+for+localized&selectedTitle=1%7E150
- [19] Kim W, Choi D, You D, Ho C, Heo J, Choi S. Risk factors influencing recurrence, patterns of recurrence, and the efficacy of adjuvant therapy after radical resection for gallbladder carcinoma. *Journal of Gastrointestinal Surgery*. 2010;14(4):679–687.
- [20] Jin L, Pitt S, Hall B, Pitt H. Aggressive surgical management of gallbladder cancer: at what cost?. *Journal of Surgical Research*. 2013;179(2):192.
- [21] Fairweather M, Balachandran V, D'Angelica M. Surgical management of biliary tract cancers [Internet]. Cco.amegroups.com. 2016. [cited 28 December 2016]. Available from: <http://cco.amegroups.com/article/view/12261/12690>

- [22] Tian Y, Liu L, Yeolkar N, Shen F, Li J, He Z. Diagnostic role of staging laparoscopy in a subset of biliary cancers: a meta-analysis. *ANZ Journal of Surgery*. 2016; 87:22–27.
- [23] Abo T, Nanashima A, Tobinaga S, Hidaka S, Taura N, Takagi K et al. Usefulness of intra-operative diagnosis of hepatic tumors located at the liver surface and hepatic segmental visualization using indocyanine green-photodynamic eye imaging. *European Journal of Surgical Oncology (EJSO)*. 2015;41(2):257–264.
- [24] Okamoto T, Onda S, Matsumoto M, Gocho T, Futagawa Y, Fujioka S et al. Utility of augmented reality system in hepatobiliary surgery. *Journal of Hepato-Biliary-Pancreatic Sciences*. 2012;20(2):249–253.