

We are IntechOpen, the world's leading publisher of Open Access books Built by scientists, for scientists

4,800

Open access books available

122,000

International authors and editors

135M

Downloads

Our authors are among the

154

Countries delivered to

TOP 1%

most cited scientists

12.2%

Contributors from top 500 universities



WEB OF SCIENCE™

Selection of our books indexed in the Book Citation Index
in Web of Science™ Core Collection (BKCI)

Interested in publishing with us?
Contact book.department@intechopen.com

Numbers displayed above are based on latest data collected.
For more information visit www.intechopen.com



Genital Organs-Sparing Radical Cystectomy in Female Patients with Muscle Invasive Urothelial Carcinoma of the Bladder

Hosni Khairy Salem

Additional information is available at the end of the chapter

<http://dx.doi.org/10.5772/67759>

Abstract

There has been considerable interest in urethral-sparing cystectomy and preservation of the gynecological tract to maintain continence mechanism, sexual function, and reproductive function in young patients who undergo radical cystectomy for muscle-invasive bladder cancer and this new technique gained acceptance in many centers. The issue of oncological safety of a urethra and anterior vaginal wall-sparing cystectomy in selected patients has been addressed by several authors. The chapter will discuss the following items: (I) Technique of genital-sparing radical cystectomy in female patients with muscle invasive transitional cell carcinoma of the bladder. (II) Definition and rationale of genital-sparing radical cystectomy in female patients. (III) Rational and value of urethral preservation in genital-sparing cystectomy in female patients with urothelial carcinoma. (IV) Previous reports about genital-sparing cystectomy in patients with urothelial carcinoma. (V) Value of preservation of the internal genital organs in female patients undergoing radical cystectomy.

Keywords: genital-sparing, radical cystectomy, female, transitional cell carcinoma, urinary diversion

1. Introduction

Radical cystectomy in females includes an anterior exenteration, i.e., removal of the bladder, urethra, uterus, fallopian tubes, ovaries, and anterior wall of the vagina. The oncological necessity for removal of the internal genital organs has been questioned [1].

There has been considerable interest in urethral-sparing cystectomy and preservation of the gynecological tract to maintain continence mechanism, sexual function, and reproductive

function in young patients who undergo radical cystectomy for muscle-invasive bladder cancer and gained acceptance in many centers [2–5].

The issue of oncological safety of a urethra and anterior vaginal wall-sparing cystectomy in selected patients has been addressed by several authors [2–7].

The scientific rationale of internal genital organ preservation during radical cystectomy in women was based on studies documented the low incidence of internal genitalia involvement in female bladder cancer [4–7].

With increasing survival from bladder cancer, quality of life (QOL) and quality of sexuality considered now an important end point after such type of surgery particularly in young female patients diagnosed with bladder cancer and eager to preserve fertility [4, 5].

Studies concerning genital-sparing cystectomy are few and their limitations included; few cases [4–6], retrospective [8, 9], limited long-term follow-up [4, 5, 7], incomplete functional and oncological outcome [6, 7], and finally included cases with nonorthotopic diversion [5–7, 10].

2. Technique of genital-sparing radical cystectomy in female patients with muscle invasive transitional cell carcinoma of the bladder

2.1. Preoperative assessment

History taking included; voiding and sexual function questionnaire while staging of the tumor included; clinical examination for clinical staging of the tumor and investigation like pelvic-abdominal ultrasound and CT scanning.

A thorough gynecological checkup includes a vaginal pap smear and transvaginal ultrasound. Cystoscopy was done (with biopsy from the tumor itself, bladder neck, trigone, and posterior wall) to exclude carcinoma *in situ* (CIS). Sexual function was assessed through specific questions about sexual desire (libido), orgasmic problems, and dyspareunia. Continence was assessed through voiding diary and reporting day and night continence and voiding frequency.

2.2. Preoperative preparation

Bowel preparation is started one day before the operation and consisted of two colonic return flow-enemas. All patients received prophylactic antibiotics (cephalosporin and metronidazole) 1 hour before operation and SC heparin the morning of the operation with medical leg stocking immediately preoperative.

2.3. Position and anesthesia and incision

Bilateral leg compression stocking are applied.

The patient is placed in dorsal Trendelenburg position with overextension of the pelvis to open the area between the umbilicus and the pelvis.

The preferred types of anesthesia are either general anesthesia or combined general and epidural anesthesia. A 20 French Foley catheter is introduced in the urethra and the balloon inflated to 20 cc. Sponge is introduced in the vagina. A lower midline subumbilical incision is made.

2.4. Lymphadenectomy

Bilateral pelvic lymphadenectomy is performed from the site of crossing of the ureter over the common iliac artery (proximally) to the lateral circumflex iliac vein, inguinal ligament, and node of Cloquet (distally) and from the genitofemoral nerve crossing the psoas muscle (laterally) to the bladder (medially) and including the hypogastric, presciatic, presacral, and obturator fossa nodes. If we found grossly palpable and suspicious node, we extend the margins of lymphadenectomy till paraaortic lymph nodes and consider abandoning the genital-sparing technique to standard.

2.5. Posterior dissection

Transverse or U-shaped incision is made in the peritoneum of the Cul-de-sac between the bladder and the uterus (**Figure 1**).

Dissecting the fatty and fibrovascular tissue between the uterus and the bladder as far inferiorly as the level of the cervix will be the next step (**Figure 2**).

The ureter is dissected from the iliac bifurcation proximally to the posterior bladder wall distally (juxtavesical ureter) where it is crossed by the uterine artery, which is preserved.

The ureters are clipped and transected, cut margins are sent for frozen section examination (**Figure 3**).

Lateral vesical pedicles are secured and divided. While dissecting lateral to the bladder, it is advisable to avoid injury to paravaginal tissues so that the branches of the pelvic nerve plexus

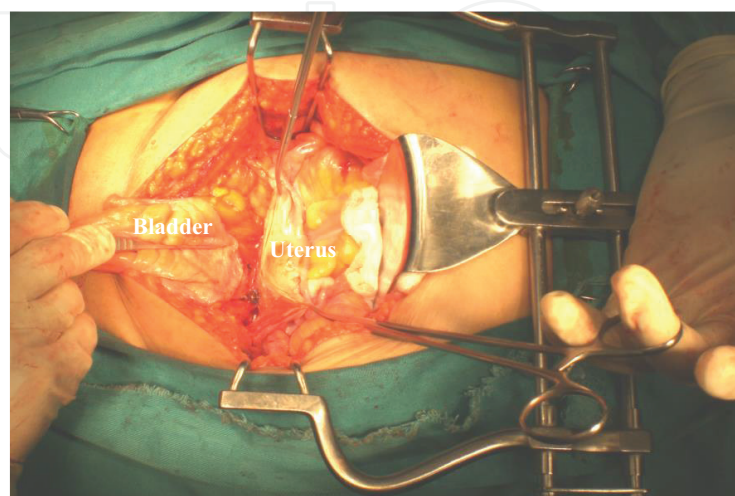


Figure 1. Urachus is divided, transverse or U-shaped incision is made in the peritoneum of the Cul-de-Sac between the bladder and the uterus.

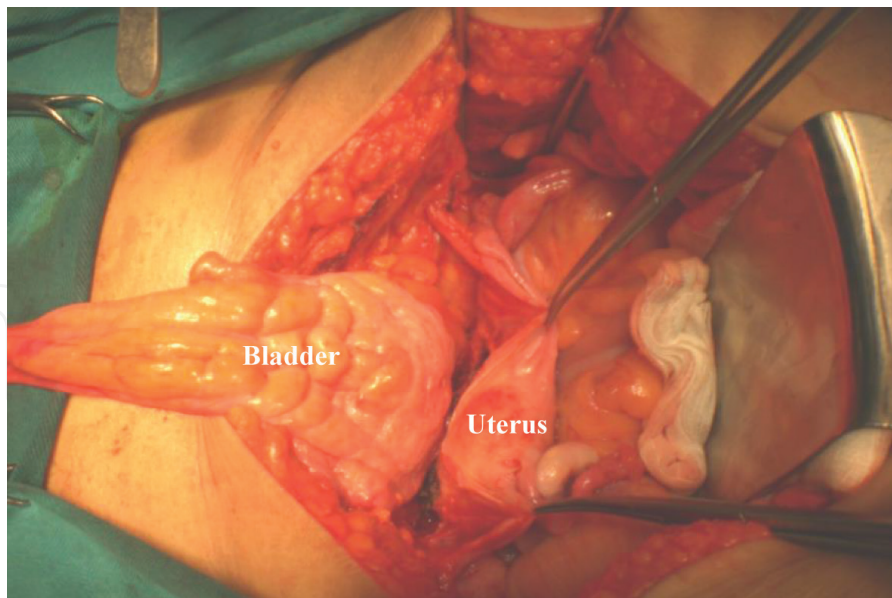


Figure 2. Dissecting the fatty and fibrovascular tissue between the uterus and the bladder as far inferiorly as possible (level of the cervix).

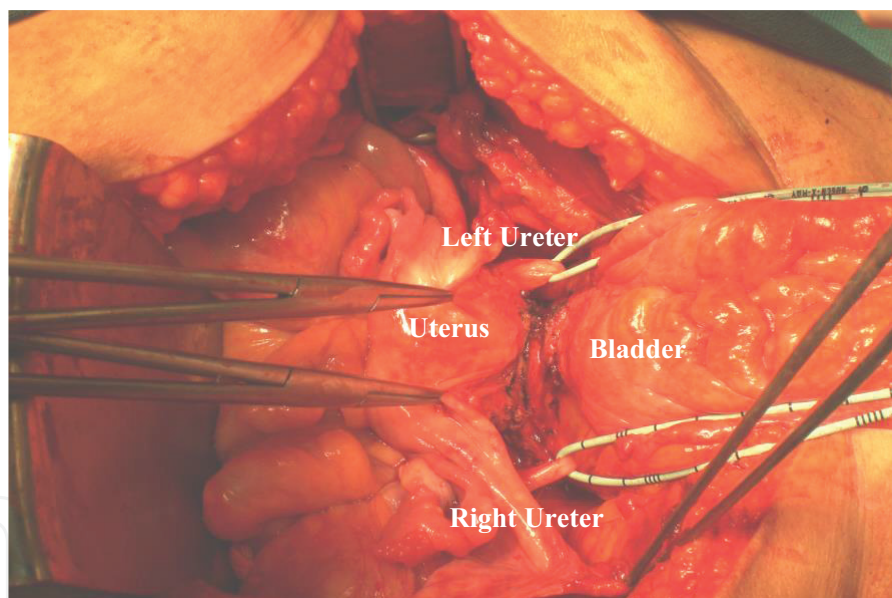


Figure 3. The ureter is dissected from the iliac bifurcation proximally to the posterior bladder wall distally (juxtavesical ureter), clipped and transected, cut margins are sent for frozen section examination.

(which course laterally to the vagina) can be preserved. Cardinal ligaments (connecting lateral surface of the cervix and the vagina to the pelvic wall) left intact.

2.6. Anterior dissection

Endopelvic fascia is incised close to the bladder neck, then we identify the vesico-urethral junction (bladder neck) by slight traction on the balloon, and putting two small sponge sticks (peanuts) on either side of the balloon (**Figure 4**).

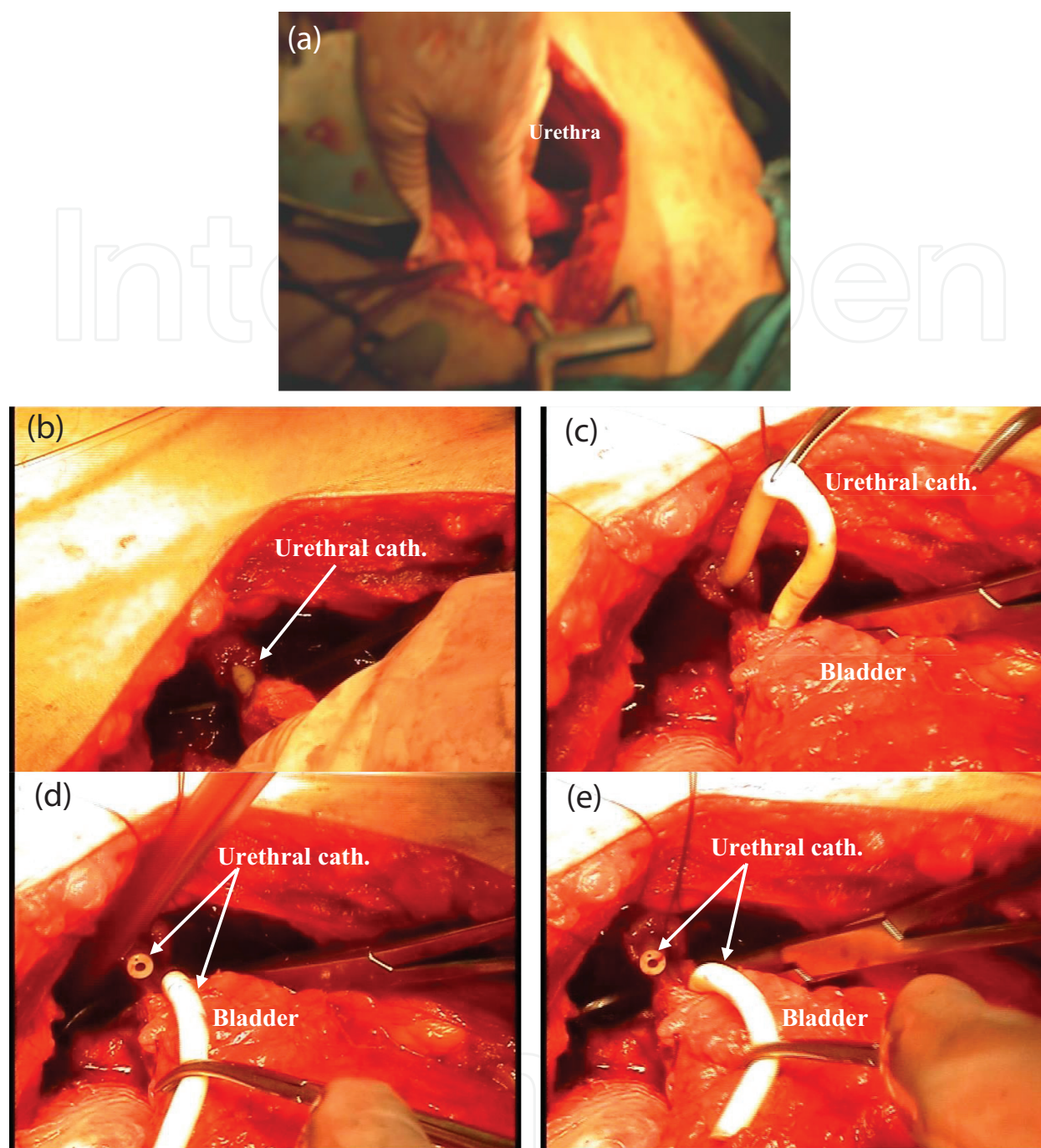


Figure 4. Endopelvic fascia incised close to the bladder neck, identify the vesicourethral junction (bladder neck). The dorsal venous complex is ligated and divided, the urethra is dissected from its attachments to the vagina and is hooked with a right angle clamp. The anterior wall of the urethra is divided sharply, the catheter pulled out, clamped proximally to prevent balloon deflation, and divided and then the posterior wall is divided. Urethral cut margins are sent for frozen section examinations.

The dorsal venous complex is ligated and divided. Ligation of the dorsal vein complex in female patients differs from male patients where other options are available to manage.

By sharp dissection, the urethra is dissected from its attachments to the vagina 0.5 cm below the bladder neck and is hooked with a right angle clamp.

The anterior wall of the urethra is divided sharply 0.5 cm below the bladder neck, the catheter pulled out, clamped proximally to prevent balloon deflation, and divided and then the posterior wall is divided with care to avoid injury of the vaginal wall.

Urethral cut margins are sent for frozen section examinations.

Care is taken not to dissect anterior and distal to the level of the transection, to ensure preservation of the pubourethral and urethropelvic ligaments, and to decrease the possibility of vaginal wall descent and pelvic prolapse.

2.7. Developing vesicovaginal and vesicourethral space

This is the most difficult and bloody part of the operation.

By gentle traction on the catheter, the bladder neck is dissected off the vaginal vault, sharp and blunt dissection continued upwards between the bladder and the vagina to connect with the previously developed posterior plane carefully without injuring the vault of the vagina and paravaginal tissues (**Figure 5**).

Six sutures of 3-0 vicryl are placed in the distal cut end of the urethra and retained for later anastomosis to the neobladder (**Figure 6**).

Alternatively, the vesicovaginal space can be developed in antegrade manner starting from above at the level of the junction between the cervix and the anterior vagina (whitish plane) (**Figure 7**).

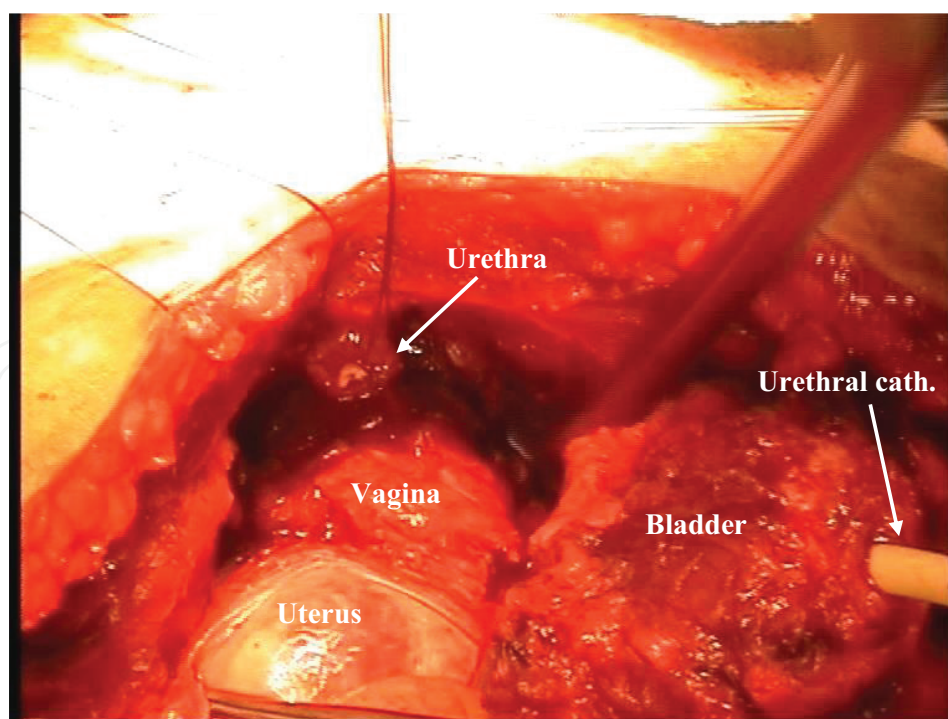


Figure 5. By gentle traction on the catheter, the bladder neck is dissected off the vaginal vault, sharp and blunt dissection continued upwards between the bladder and the vagina to connect with the previously developed posterior plane carefully.

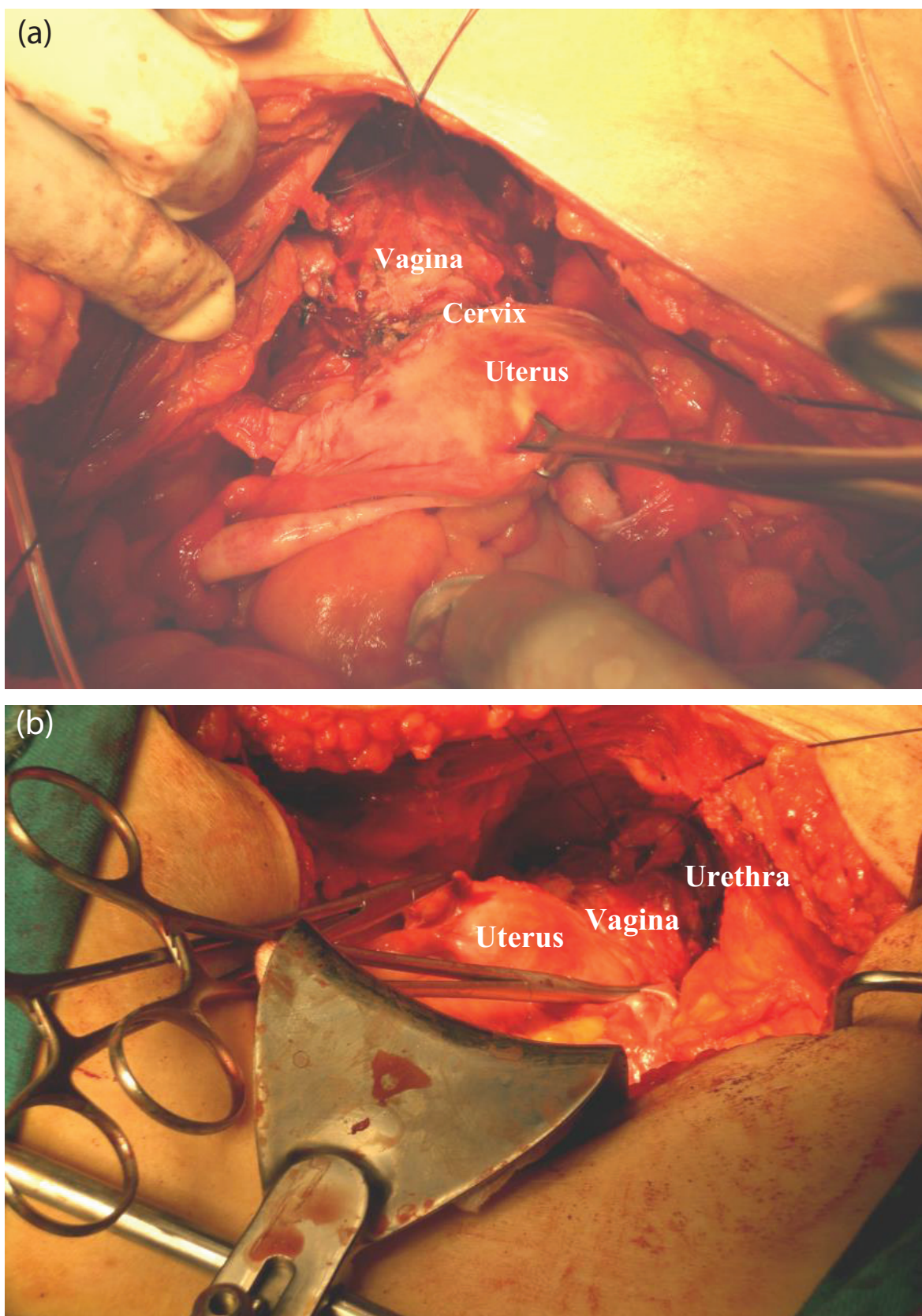


Figure 6. (a) Final picture after removal of the bladder and (b) six sutures of 3-0 vicryl are placed in the distal cut end of the urethra and retained for later anastomosis to the neobladder.

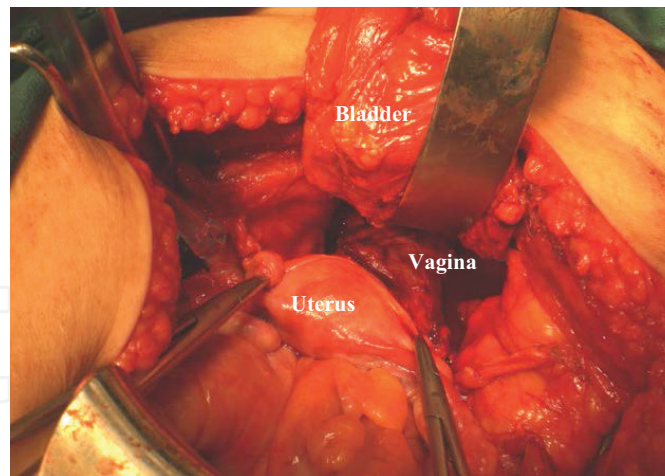


Figure 7. Alternatively, the vesicovaginal space can be developed in antegrade manner starting from above at the level of the junction between the cervix and the anterior vagina (whitish plane).

Dissection close to the vaginal wall will avoid injury to the neurovascular bundles supplying vagina, urethra, and clitoris.

2.8. Urinary diversion

A segment of 60 cm of the ileum is isolated on a vascular pedicle from a point 15–20 cm proximal to the ileocaecal junction. The bowel is detubularized and reconfigured in a W pouch.

The ureters are implanted creating serosa-lined tunnels.

The neobladder is anastomosed to the urethra using the preplaced vicryl sutures over a 20-French Foley catheter (**Figure 8**). The anastomotic site must sit broadly on the pelvic floor and should be away from the most dependent part of the reservoir. In one patient, an ileocaecal neobladder was created.

It is not essential to use a well-vascularized omental flap behind the reconstructed pouch in our cases because the preserved vagina was not opened (no suture lines).

The initial capacity was assessed by filling the bladder through the Foley catheter, and the initial capacity was approximately 120 cc after filling.

Two ureteral stents were left.

Drains are placed and the incision is closed in layers.

2.9. Postoperative care and follow up

Ureteral stent is removed 7–9 days postoperatively before discharge.

Urethral catheter is removed 2 weeks postoperatively if the pouchogram showed no extravasations.

Pouch wash with sodium bicarbonate starting from the 4th day postoperatively. Patient is advised to void by pelvic floor relaxation in sitting position at 3-hour interval day and night,

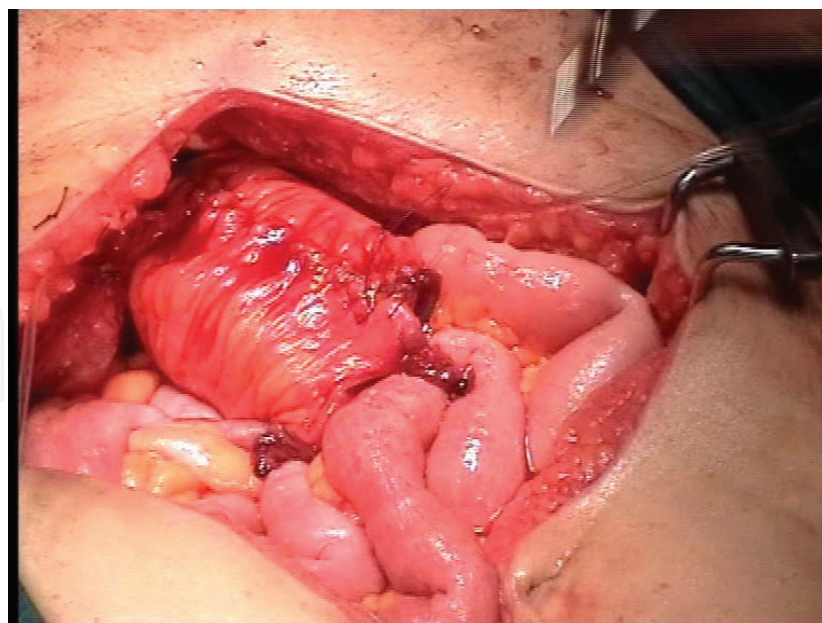


Figure 8. The final picture after fishing closure of the orthotopic pouch with poucho-urethral anastomosis.

increase the voiding intervals gradually with time (retain urine for 3–4 hours) to obtain bladder capacity of 500 cc.

Patient sexual function, voiding patterns, and continence are assessed by means of a validated questionnaire and personal interviews. Sexual function was assessed through specific questions about sexual desire (libido), orgasmic problems, and dyspareunia. Continence was assessed through voiding diary and reporting day and night continence and voiding frequency.

The patient is considered to be continent if she required not more than one pad during the night or the day. Postvoid residual urine is assessed by means of ultrasound or self-catheterization after spontaneous voiding.

Pathological examination of the specimen is done to assess the stage, grade, and lymph node status.

Follow up at 3-month interval should include: personal interviews (sexual function with three questions related to dyspareunia, vaginal lubrication and overall satisfaction), voiding patterns, continence (number of pads used), chemistry, gynecological examination, test for residual urine, and CT examination.

3. Definition and rationale of genital-sparing radical cystectomy in female patients

In the past, radical cystectomy in females included an anterior exenteration, i.e., removal of the bladder, urethra, uterus, fallopian tubes, ovaries, and anterior wall of the vagina. The reasons for removing the adnexa (in radical cystectomy in female patients) are not clear and have been questioned because bladder cancer rarely extends to these organs. The risk of internal genitalia

involvement in female cystectomy specimen was reported to be low whether primary or secondary. Uterine involvement in patients with urothelial cancer has been reported in 1/37 and in 2/40 radical cystectomy specimens in Groutz et al. and Chang et al. studies, respectively [11, 12].

In another study included more than 600, the rate of concomitant gynecological organ involvement has been reported to be 2.6% [13].

In our previous studies, we examined cystectomy specimens from 360 consecutive female patients with bladder cancer, pathologically for internal genitalia involvement. Uterine involvement was observed in one case of TCC (pT4, grade III). Uterine benign pathology was detected in 25 cases. All patients had normal ovaries regardless of tumor site or stage while the vagina was involved in 11 cases. Ten percent of the patients had urethral involvement (all had TCC). During late follow up of 50 patients (included two cases with uterine preservation, and in all cases, at least one ovary was preserved), no single ovarian or uterine recurrence was reported [14, 15].

4. Rational and value of urethral preservation in genital-sparing cystectomy in female patients with urothelial carcinoma

Urethral preservation under specific criteria of tumor site and extension is quite safe and facilitates orthotopic reconstruction with spontaneous voiding and improves the quality of life in such patients [16, 17]. Pathological studies in female radical cystectomy specimens have demonstrated that the urethra is rarely involved in the absence of bladder-neck involvement [18] or extensive carcinoma *in situ* [19]. Preservation of the distal part of the urethral will allow reconstruction of new bladder from the small intestine to be anastomosed to the preserved urethra. Follow up of those patients proved the safety of urethral preservation. This option will definitely increase the acceptance by the patients to do such type of surgery and also will increase its practice among urosurgeons [18–20].

5. Previous reports about genital-sparing cystectomy in patients with urothelial carcinoma

Preservation of the sexual function in women has not been the main goal in most studies of neobladder in women and studies concerning genital-sparing cystectomy are lacking. Only four series were reported addressing this issue; one series of open surgery in three cases of TCC [4], one series of robotic surgery in two cases of TCC [6], one series of laparoscopic surgery in one case of TCC [5], and one series of laparoscopic surgery in 13 cases of neurogenic vesical dysfunction [7]. The number of cases in these studies is limited; the follow up was very short and no report was mentioned on the oncological function in terms of local recurrence (**Table 1**).

Horenblas et al. [4] reported on sexuality preserving cystectomy in three female patients with bladder cancer, using a retrograde method. No patient had a local recurrence, and daytime and nighttime continence was reported in 66% of cases while the remainder needed intermittent catheterization. One patient developed a vaginal urinary fistula and was converted to

Reference	Horenblas et al. [4]	Menon et al. [6]	Game et al. [7]	Moinzadeh et al. [5]	Kulkarni et al. [8]	Koie et al. [9]	Salem [10]
Year	2001	2004	2007	2005	2008	2009	2008
Country	Netherlands	USA	France	USA	India	Japan	Egypt
Pathology	TCC*	TCC	Neurogenic vesical dysfunction	TCC	TCC	29: TCC 1: leiomyosarcoma	TCC
No. of cases	3	3	13	11	14 (retrospective)	30 (retrospective)	20
Genital-sparing cases	3	2	13	1	14	30	20
Technique	Open	Robotic	Laparoscopy	Laparoscopy	Open	Open	Open
Diversion	Orthotopic	Ileal conduit, W pouch, T pouch	Noncontinent trans ileal Bricker	Ileal conduit (8), Studer (2), Indiana pouch (1)	Neobladder	Neobladder (U-shaped)	W pouch (24), Le Bag (1)
Mean op. time (min.)	-	160 (cystectomy) 130 (ileal conduit) 180 (orthotopic)	325 ± 36	510	320	301	210 ± 35
Mean hospital stay	-	6.7	11.6 ± 1.9	6	-	-	11 ± 3
Mean follow-up (months)	3.5	-	7.4 ± 5.4	7.1	32.5	35.7	70
Daytime continence	66%	-	-	Excellent	7	24	70%
Nighttime continence	66%	-	-	Excellent	7	24	85%
Hypercontinence (intermittent catheterization)	33%	-	-	-ve	4	0	15%
Local recurrence	-ve	-	-	-	1	1	0%
Mean blood loss (cc)	-	100	343.1 ± 246.3	-	300-1500	983	300 ± 120

Table 1. Showing previous reports on genital-sparing cystectomy.

a continent catheterizable stoma. Vaginal lubrication and orgasmic feeling were reported to be normal after surgery.

Menon et al. [6] reported robotic-assisted radical cystectomy in three female patients, one of them was anterior exenteration and two of them genital-sparing cystectomy. No report was mentioned on the mean follow up, continence, or local recurrence.

In our previous study, we excluded the pathology of the internal genitalia by standard clinical and gynecological examination. To decrease the risk of subsequent local recurrence, we excluded patients with tumor at the trigone, posterior wall, bladder neck, and associated carcinoma *in situ*. For greater safety, we did intraoperative frozen section biopsy of the urethral surgical margin. The surgical margins were free in all patients (urethral margin, posterior bladder wall). Only in one case, there was microscopic invasion of the anterior wall (pT3a III TCC). At the last follow up, all patients are alive and well with no evidence of disease recurrence. None of these had urethral or vaginal recurrences. Seventeen (85%) patients voided spontaneously. Fourteen (70%) of them were continent day and night and three of them suffering from some form of urge or stress incontinence in the first 3 months after surgery. The remaining three patients (15%) needed regular self-catheterization (hyper continent). Median bladder capacity at the last follow up was 450 cc (350–600). Median residual urine was 100 cc (0–350). All patients were sexually active 3 months after surgery. Vaginal lubrication was reported in 16 patients. Two patients were suffering from dyspareunia. Orgasmic function was preserved in 16 patients [10].

6. Value of preservation of the internal genital organs in female patients undergoing radical cystectomy

There is no doubt that removal of the internal genitalia in premenopausal women will affect the quality of life of such patient and will cause psychological trauma especially in young patients eager to have children. With increasing survival from urologic cancer, quality of life, and quality of sexuality should be one of the main goals following radical cystectomy in female patients with bladder cancer. Hence, routine removal of the internal genitalia has to be investigated thoroughly.

Preservation of the internal gynecological organs will improve the functional outcome and will have positive impact on the quality of life after exclusion of concomitant primary or secondary gynecological malignancy by careful preoperative assessment.

6.1. The vagina

The preserved vagina will provide backing to the neobladder, prevent pouchocele formation in the dead space, provide better support to the distal urethra to prevent kinking of the urethropouch anastomosis decreasing the likelihood of hyper continence, and maintain the sexual function in women who want it particularly if nerve-sparing technique was done and vaginal lubrication was preserved. No chance of fistula formation between the vagina and the new pouch because there is no suture line in the preserved vagina.

In patients with urothelial carcinoma away from the bladder base or the bladder neck (dome and anterior wall tumors), the anterior vaginal wall may be preserved [21]. The oncological safety of preservation of the anterior vaginal wall has been proved in another study by Chen et al. in 1996 in a retrospective study at MD Anderson Cancer Center [22].

6.2. The uterus

The uterus will retain the reproductive function in this group of patients, in addition, the uterus will prevent vaginal vault or pelvic prolapse. Chang et al. [23] suggested that preservation of uterus and its supports may prevent the dead space that otherwise would be filled by small bowel which in some may produce anterior enterocele following cystectomy as was reported by Anderson et al. [24]. The uterus also plays a role in orgasmic function [25].

Removal of the uterus may be associated with psychological trauma in young sexually active women eager to have a child when future pregnancy is contemplated.

We believe that in postmenopausal women or in those who no longer desire future fertility, hysterectomy seems a reasonable adjunct to cystectomy.

6.3. The ovaries

Data concerning metastasis of bladder TCC to the ovaries are scarce and autopsy studies showed that ovarian metastasis due to TCC of the bladder ranged between 0 and 9% [26–29]. Marshall and Treiger suggested one ovary to be left to preserve the hormonal function after radical cystectomy [30], acute premature menopause (ovarian hormone deprivation) is associated with increased menopausal symptoms, ischemic heart disease, and osteoporosis risk. Prolonged hormone replacement therapy used to alleviate symptoms and minimize these risks has been associated with increased incidence of breast cancer especially if used for more than 5 years [31].

The criteria for patients selection for genital sparing include the following: single monofocal localized tumor, away from the bladder neck, trigone or posterior wall, no associated carcinoma *in situ*, patient with serum creatinine of less than 1.7 mg/dl, patient agree and able to perform self-catheterization, patient motivated for preservation of sexual function (sexually active), and no cervical or uterine abnormalities.

7. Conclusion

Here, we have described a technique of genital-sparing radical cystectomy with orthotopic neobladder in selected female patients. The technique is feasible and of low morbidity with reasonable oncological and functional outcome. Although radical cystectomy is the gold standard for female patients with bladder cancer, preservation of the internal genitalia in young sexually active women eager to have children should be considered in selected cases under strict criteria. The desire to achieve functional good results should not violate the oncological surgical principles.

Author details

Hosni Khairy Salem

Address all correspondence to: dr_hosni@yahoo.com

Urology Department, Faculty of Medicine, Kasr Alainy Hospital, Cairo University, Cairo, Egypt

References

- [1] Stein JP, Ginsberg DA and Skinner DG: Indications and technique of the orthotopic neobladder in women. *Urol Clin North Am.* 2002; 29: 725–4.
- [2] Stein JP, Grossfeld GD, Freeman JA, Esrig D, Ginsberg GA, Cote RJ et al.: Orthotopic lower urinary tract reconstruction in women using the Kock ilealneobladder: updated experience in 34 patients. *J Urol.* 1997; 158: 400–5.
- [3] Shimogaki H, Okada H, Fujisawa M, Arakawa S, Kawabata G, Kamidono S et al.: Long-term experience with orthotopic reconstruction of the lower urinary tract in women. *J Urol.* 1999; 161: 573–7.
- [4] Horenblas S, Meinhardt W, Lizerman W and Moonen LF: Sexuality preserving cystectomy and neobladder: initial results. *J Urol.* 2001; 166: 837–40.
- [5] Moinzadeh A, Gill I, Desai M, Finelli A, Falconi T and Jihad J: Laparoscopic radical cystectomy in the female. *J Urol.* 2005; 173: 1912–17.
- [6] Menon M, Hemal AK, Tewari A, Shrivastava A, Shoma AM, Abol-Ein H, et al.: Robot-assisted radical cystectomy and urinary diversion in female patients: technique with preservation of the uterus and vagina. *JACS.* 2004; 198: 386–93.
- [7] Game X, Mallet R, Guillotreau J, Berrogain N, Mouzin M, et al.: Uterus, fallopian tube, ovary and vagina-sparing laparoscopic cystectomy: technical description and results. *Eur Urol.* 2007; 51: 441–46.
- [8] Kulkarni JN, Rizni SJ, Acharya UP, Kumar KS and Tiwari P: Gynecologic-tract sparing extraperitoneal retrograde radical cystectomy with neobladder. *Int Braz J Urol.* 2008; 34: 180–90.
- [9] Koie T, Hatakeyama S, Yoneyama T, Hashimoto Y, Kamimura N, and Ohyama C: Uterus, fallopian tube, ovary, and vaginal –sparing cystectomy followed by U-shaped ileal neobladder construction for female bladder cancer patients: oncological and functional outcome. *Urol.* 2010; 75: 1499–1503.
- [10] Salem H: Functional and oncological outcome of genital-sparing radical cystectomy in female patients with muscle invasive transitional cell carcinoma (TCC) of the bladder. *JOU.* 2008; 179(4): 239. DOI: 10.1016/S0022-5347(08)60852-6.

- [11] Groutz A, Gillon G, Konichezky M, Shimonov M, Winkler H, Livne PM et al.: Involvement of internal genitalia in female patients undergoing radical, cystectomy for bladder cancer: a clinicopathologic study of 37 cases. *Int J Gynecol Cancer*. 1999; 9: 302–6.
- [12] Chang SS, Cole E, Smith JA Jr, Cookson MS: Pathological findings of gynecologic organs obtained at female radical cystectomy. *J Urol*. 2002; 168: 147–9.
- [13] Ali-el-Dein B, Abdel-Latif M, Mosbah A, Eraky I, Shabaan AA, Taha NM et al.: Secondary malignant involvement of gynecologic organs in radical cystectomy specimens in women: is it mandatory to remove these organs routinely? *J Urol*. 2004; 172: 885–7.
- [14] Hosni Salem, Akmal El-Mazny: Primary and secondary malignant involvement of gynaecological organs at radical cystectomy for bladder cancer: review of literature and retrospective analysis of 360 cases. *J Obstet Gynaecol*. 2012, 32(6):590–3. DOI: 10.3109/01443615.2012.693980.
- [15] Salem H, El-Mazny A: A clinicopathological study of gynecological organs involvement in radical cystectomy for bladder cancer. *Int J Gynecol Obstet*. 2011; 115: 188–190.
- [16] Coloby PJ, Kakizoe T, Tobisu K and Sakamoto M: Urethral involvement in female bladder cancer patients: mapping of 47 consecutive cystourethrectomy specimens. *J Urol*. 1994; 152: 1438–42.
- [17] Stenzle A, Draxl H, Posch B, Colleselli K, Falk M and Bartsch G: The risk of urethral tumors in female bladder cancer: can the urethra be used for orthotopic reconstruction of the lower urinary tract? *J Urol*. 1995; 153: 950–5.
- [18] Stein JP, Cote RJ, Freeman JA, Esrig D, Elmajian DA, Groshen S et al.: Indications for lower urinary tract reconstruction in women after cystectomy for bladder cancer: a pathological review of female cystectomy specimens. *J Urol*. 1995; 154: 1329–33.
- [19] Stein JP, Esrig D, Freeman JA, Grossfeld GD, Ginsberg GA, Cote RJ et al.: Prospective pathologic analysis of female cystectomy specimens: risk factors for orthotopic diversion in women. *Urol*. 1998; 51: 951–5.
- [20] Stenzl A, Jarolim L, Coloby P, Golia S, Bartsch G, Babjuk M et al.: Urethra-sparing cystectomy and orthotopic urinary diversion in women with malignant pelvic tumors. *Cancer*. 2001; 92: 1864–71.
- [21] Freiha FS: Open bladder surgery. In: Walsh PC, Retik AB, Stamey TA, Caghan ED, eds. *Campbell's Urology*. New York: W.B. Saunders; p. 2762, 1992.
- [22] Chen ME, Malpica A, Dinney CP and Pisters LL: Risk of urethral, vaginal and cervical involvement in patients undergoing radical cystectomy for bladder cancer: a retrospective review of patients at M.D Anderson Cancer Center. AUA Ninety-first Annual Meeting. *J. Urol*. 1996; 155: 1263 (Abstract).
- [23] Chang SS, Cole E, Cookson MS, Peterson M and Smith JA Jr.: Preservation of the anterior vaginal wall during female radical cystectomy with orthotopic urinary diversion: technique and results. *J Urol*. 2002; 168: 1442–5.

- [24] Anderson J, Carrion R, Ordorica R, Hoffman M, Arango H and Lockhart JL: Anterior enterocele following cystectomy for intractable interstitial cystitis. *J Urol.* 1998; 159: 1868–70.
- [25] Weijmar Schultz WC, Van De Wiel HB, Hahn DE and Bouma J: Psychosexual functioning after treatment for gynecological cancer: an integrative model, review of determinant factors and clinical guidelines. *Int J Gynecol Cancer.* 1992; 2: 281–90.
- [26] Babaian RJ, Johnson DE, Llamas L and Ayala AG: Metastases from transitional cell carcinoma of the urinary bladder. *Urol.* 1980; 16: 142–4.
- [27] Fetter TR, Bogaer JH, McCuskey B and Seres JL: Carcinoma of the bladder: sites of metastases. *J Urol.* 1959; 81: 746–8.
- [28] Kishi K, Hirota T, Matsumoto K, Kakizoe T, Murase T and Fujita J: Carcinoma of the bladder: a clinical and pathological analysis of 87 autopsy cases. *J Urol.* 1981; 125: 36–9.
- [29] Murphy GP: The current status of bladder cancer. *Surg Ann.* 1975; 7: 175–218.
- [30] Marshall FF and Treiger BFG: Radical cystectomy in the female patient. *Urol Clin North Am.* 1991, 18: 765–70.
- [31] Colditz GA, Hankinson SE, Hunter DJ et al.: The use of estrogens and progestins and the risk of breast cancer in postmenopausal women. *N Engl J Med.* 1995; 332: 1589–93.