

We are IntechOpen, the world's leading publisher of Open Access books Built by scientists, for scientists

4,800

Open access books available

122,000

International authors and editors

135M

Downloads

Our authors are among the

154

Countries delivered to

TOP 1%

most cited scientists

12.2%

Contributors from top 500 universities



WEB OF SCIENCE™

Selection of our books indexed in the Book Citation Index
in Web of Science™ Core Collection (BKCI)

Interested in publishing with us?
Contact book.department@intechopen.com

Numbers displayed above are based on latest data collected.
For more information visit www.intechopen.com



Pelvic Osteotomies for Developmental Dysplasia of the Hip

Chunho Chen, Ting-Ming Wang and Ken N. Kuo

Additional information is available at the end of the chapter

<http://dx.doi.org/10.5772/67516>

Abstract

Treatment of developmental dysplasia of the hip (DDH) is based on concentric reducibility of the femoral head, patient age and the status of triradiate cartilage. Patients in walking age are indicated for pelvic osteotomy to correct the dysplastic acetabulum. Salter innominate osteotomy and Pemberton osteotomy are the most widely used procedures to treat the developmental dysplasia of the hip in early childhood. Although short-term results of the pelvic osteotomies are reported well, some long-term sequelae such as coxa valga caused by Kalamchi type II osteonecrosis of the femoral head, leg length discrepancy and impingement of hip may occur.

Keywords: developmental dysplasia of the hip (DDH), Pemberton, salter, pelvic osteotomy, open reduction

1. Introduction

Developmental dysplasia of the hip (DDH) is one of the most important issues in paediatric orthopaedics which include dysplastic, subluxated or dislocated hips. The principle of the treatment is to achieve a congruent and concentrically reduced hip, eventually to prevent premature osteoarthritis of hip. Many treatment options have been developed to achieve the goal, which varied from close reduction to several kinds of combined osteotomies. The choice of treatment for DDH is age-related with consideration of specific pathologic conditions. Although the minimum age at which an acetabular osteotomy should be done is still a controversy, it is generally accepted that DDH in a child of walking age should be treated with acetabuloplasty. This chapter focuses on the Salter innominate osteotomy and Pemberton osteotomy.

2. Pelvic osteotomies

There are numerous types of pelvic osteotomies to treat the dysplastic hips. To determine which osteotomy is the most appropriate, we should consider concentric reducibility of the femoral head, patient age and the status of triradiate cartilage (**Figure 1**).

For the patients with late diagnosed DDH, the reconstructive osteotomy for dysplastic acetabulum is indicated only when the femoral head can be concentrically reduced. Salter innominate osteotomy and Pemberton osteotomy are the most commonly used procedures for children younger than 7 years old [1].

Salter osteotomy and Pemberton acetabuloplasty are common procedures for deficient acetabulum in developmental dysplasia of the hip (DDH). Salter osteotomy redirects the entire acetabulum following a complete trans-iliac osteotomy, while Pemberton acetabuloplasty modifies the shape of the acetabulum by hinging the horizontal branch of the triradiate cartilage following an incomplete osteotomy. The objectives of these two procedures are to improve the coverage of the femoral head for acetabular dysplasia.

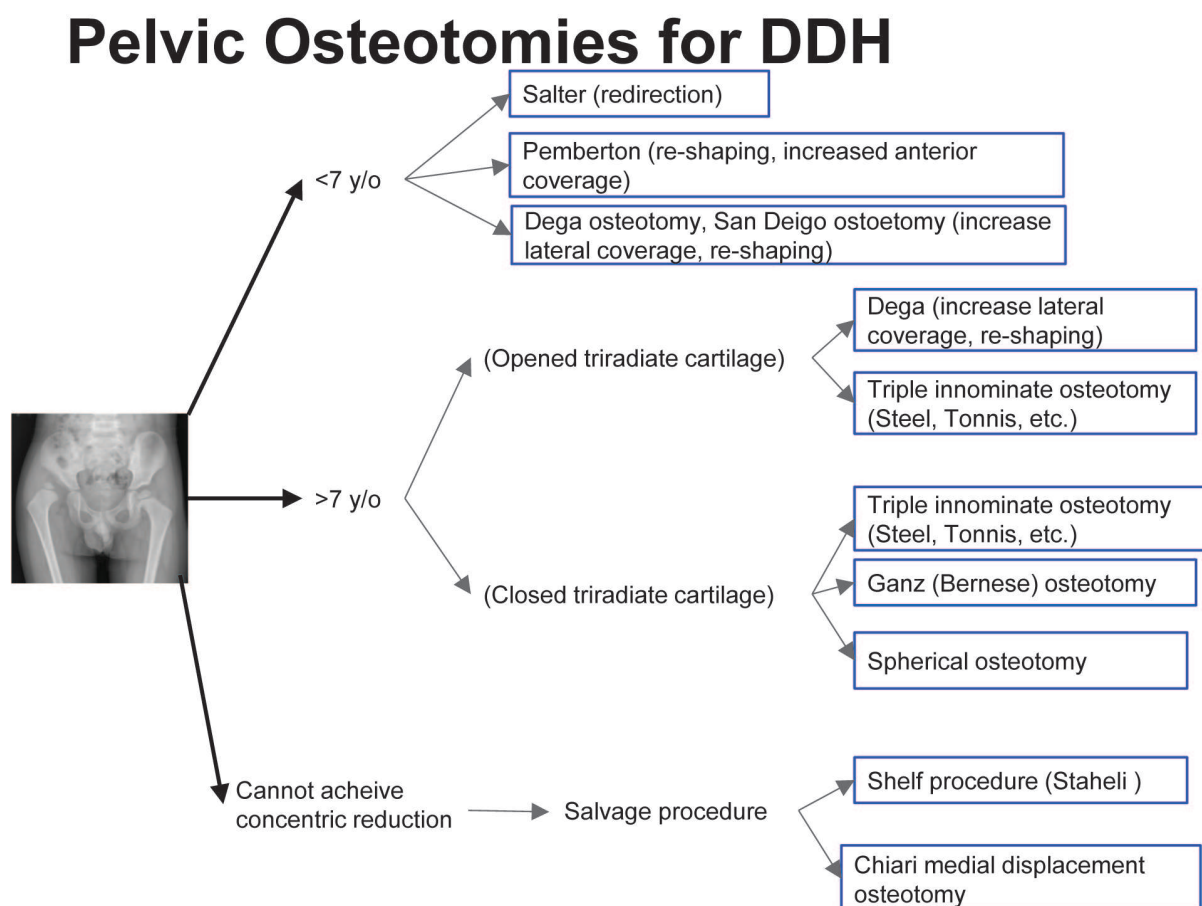


Figure 1. Various types of pelvic osteotomies for DDH are indicated depending on the reduction concentricity, patient age and the status of triradiate cartilage.

The pericapsular acetabuloplasty, described by Pemberton in 1965, is a unique type of pelvic osteotomy. Through an incomplete cut in the ilium, this procedure can redirect the acetabulum to achieve correction of acetabular dysplasia. Pemberton's original study demonstrated a high rate of satisfactory results in children younger than 7 years of age. Later some authors have obtained a good result in older children when they applied one stage Pemberton acetabuloplasty and femoral shortening as a one-stage operation [2, 3]. In addition, to obtain correction of the acetabular dysplasia that is potentially greater than that achieved with the Salter osteotomy, the Pemberton osteotomy can be performed without the use of internal fixation. The objective of the surgery is to improve the anterolateral coverage of the femoral head. Adequate containment and a stable hip allow weight bearing and osseous remodelling of the dysplastic acetabulum.

In 1961, Salter described the innominate osteotomy for stabilizing the reduced hip by redirection of the acetabulum as a unit. The procedure was accomplished by a transverse osteotomy of the ilium perpendicular to the iliac axis from just above the anterior inferior iliac spine to the sciatic notch. It was designed to preserve the acetabular shape while correcting the abnormal anterolateral facing of the acetabulum in DDH. The pubic symphysis served as a rotating hinge and the acetabulum can be redirected to cover the anterolateral deficiency in a concentrically reduced hip after the osteotomy [4]. Salter and Dubos reported 93.6% excellent or good results in patients operated from 18 months to 4 years of age with no failures in a review of 15-year follow-up on 140 patients. In the 4–10-year-old age group, the results were excellent or good in only 56.7% [5]. Thus, the Salter osteotomy is not recommended in older children. This procedure is probably the most widely used pelvic osteotomy in the treatment of DDH. In comparison with the Pemberton osteotomy, the Salter's procedure seems relatively simple. However, its proper technical execution is not easy. The most common error that leads to a catastrophic outcome is failure to achieve a concentric reduction of the hip joint before innominate osteotomy.

3. Pre-OP evaluation

Complete clinical examination is necessary before surgery including inspection of walking pattern, skin folds of thigh and gluteal creases, and physical examination of both hips including range of motion (ROM) and reducibility of the hip. The affected lower limb is shorter than the healthy side. Children may walk on their toe to compensate the discrepancy of limb length. Some children may have Trendelenburg gait. Because the thigh length is shorter in the affected side due to dislocated hip, there will be more thigh skin folds than the healthy side (**Figure 2**). However, the extra thigh folds are common normal variants, especially for the young babies, and it is not the sufficient and necessary condition of the hip dislocation. Physical examination may reveal positive Allis' sign, which is appreciated by placing both hips flexion in 90° with full flexion of the knees and comparing the height of the knees (**Figure 3**). Positive Allis' sign indicate shortening of the affected limb but does not differentiate femur or tibia as the primary cause. Galeazzi's sign is comparing the height of the knees when both hips and knees are placed in 90–90° flexion, which is specifically indicating shortening of the femur.

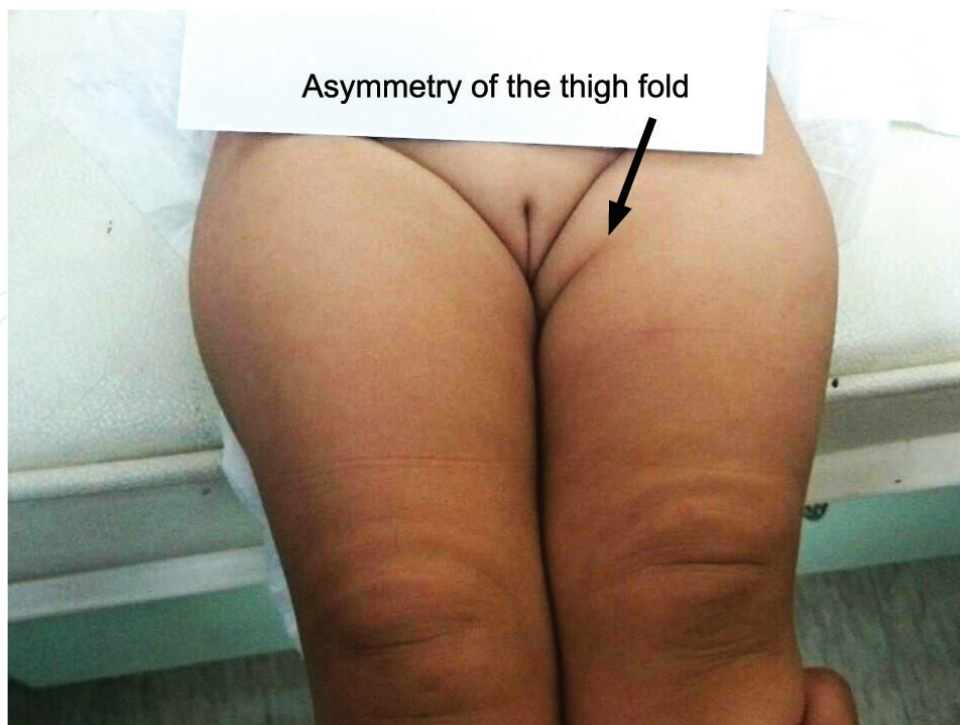


Figure 2. Asymmetry of thigh folds: With left hip dislocated, the skin fold of thigh is asymmetric due to apparent shortening of the lower limb on the left side.

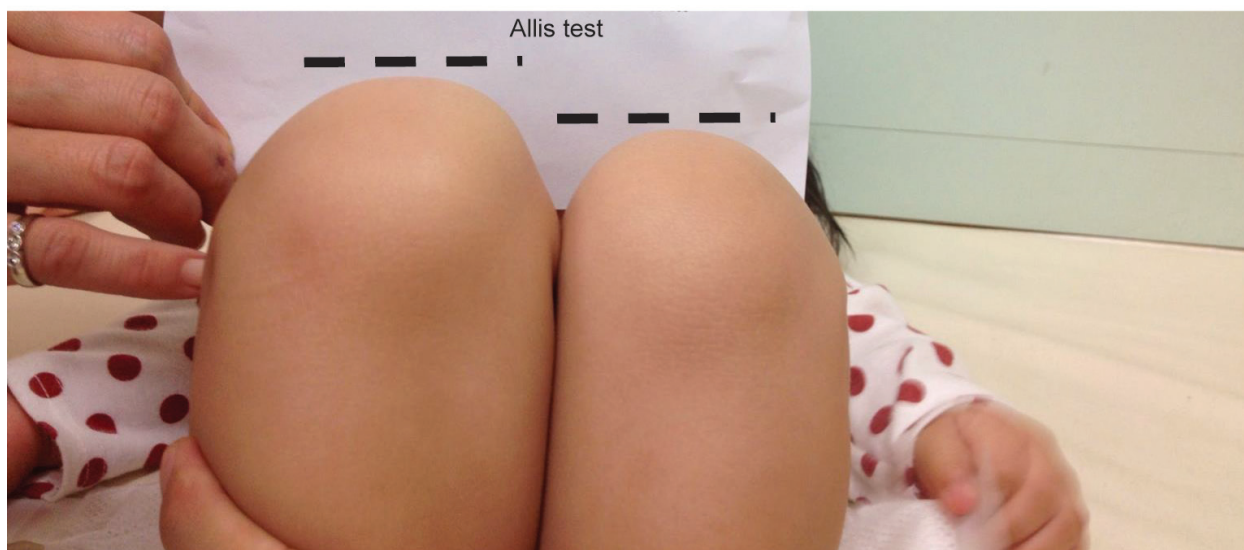

Figure 3. The affected limb is shorter than the normal side as demonstrated by different knee level when the child is lying supine on the examination table with the hips flexed 90° and knees fully flexed.

Complete radiographic examinations include a standing pelvis AP view, frog leg lateral view and false-profile radiographs to determine the severity of acetabular dysplasia and deformity of proximal femur.

Ortolani's and Barlow's test have high sensitivity and specificity under an experienced surgeon's hand. Sometimes those tests cannot be performed very well to an awake child. Usually, the tests will demonstrate clearly under general anaesthesia. Close reduction of the hip joint will be tried first after anaesthesia. The tension of hip adductor tendons should be evaluated after closed reduction of the hip joint. If adductor contracture is presented, adductor tenotomy can be done simultaneously.

Generally speaking, the children younger than 3 years old with simple dislocated hip can be treated by open reduction of hip joint and Pemberton osteotomy or Salter osteotomy alone. For those older than 3 years old, combined femoral osteotomy is often required to achieve stable reduction of the hip joint.

4. Surgical technique (open reduction of hip joint and Pemberton osteotomy)

4.1. Step 1: incision and surgical approach

- Pass the stockinette to wrap around the body and put the stockinette to the level of nipple first. It may facilitate the spica casting technique and avoid excessive manipulation of hip after surgery to prevent bone graft dislodgement or re-dislocation (**Figure 4**).
- Patient is placed in supine position and a small towel roll is placed under the ipsilateral buttock.
- Make a bikini incision just slightly medial to the iliac crest.
- Dissect the subcutaneous tissue and identify the muscle interval between the Sartorius and tensor fascia femoris muscles (**Figure 5**). The lateral femoral cutaneous nerve should be identified and protected which passes distally and laterally beneath the deep fascia in this inter-muscular interval. Retract lateral femoral cutaneous nerve medially after it is well mobilized proximally and distally.
- Expose the iliac crest. Releasing the external oblique muscle fibres on the iliac crest facilitates exposure of the cartilaginous iliac apophysis. Identify the anterior superior iliac spine.
- Hold the iliac crest by thumb and index finger to define the margin of the iliac crest and sharply incise the iliac apophysis exactly in the midline (**Figure 6**). Strip off the iliac apophysis with a periosteal elevator to expose the ilium sub-periosteally both medially and laterally. Pack gauze sponges on both inner and outer table of the ilium to facilitate sub-periosteal dissection and provide haemostasis.

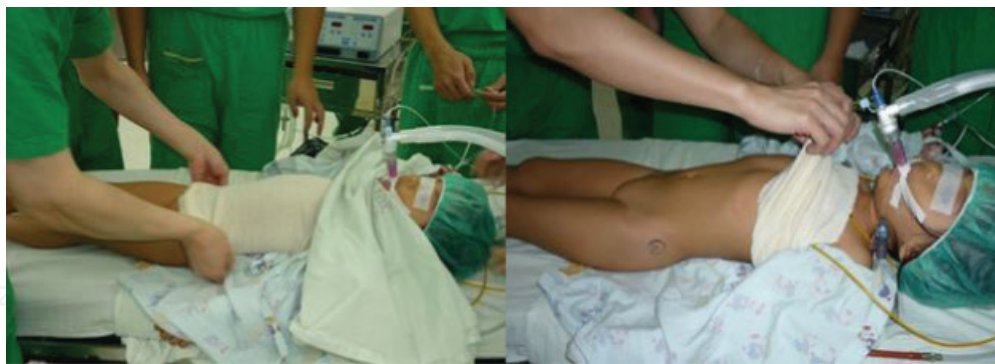

Figure 4. The stockinette is prepared and placed at the level of nipple line to facilitate the postoperative spica casting procedure.

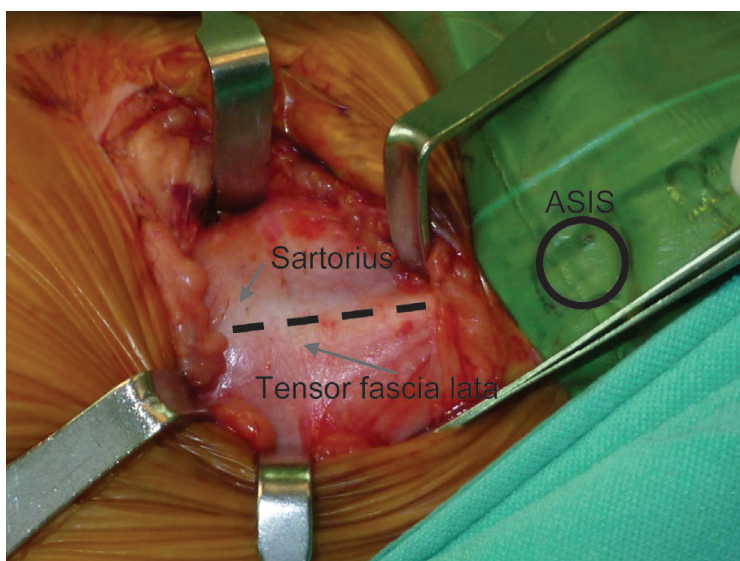


Figure 5. Identify the muscle interval between sartorius and tensor fascia lata muscles. ASIS = anterior superior iliac spine.

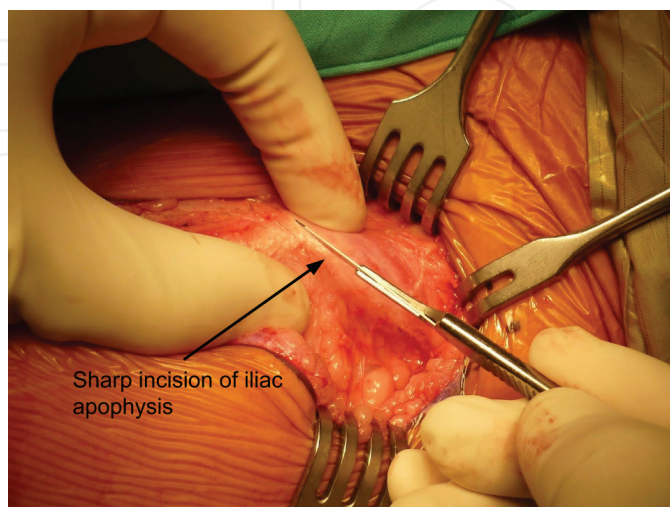


Figure 6. The iliac crest cartilaginous apophysis is split sharply, with the thumb and the index finger as the guide for thickness and direction of the iliac wing.

- The anterior inferior iliac spine (AIIS) is exposed by sub-periosteal elevation of the hip abductors from the outer cortex of the ilium.

4.2. Step 2: rectus femoris and iliopsoas identification and tenotomy

- The straight head of the rectus femoris muscle is exposed at its origin on the AIIS. The rectus femoris tendon is transected close to the anterior inferior iliac spine. A short stump is left for later tendon reattachment. Protect and preserve the ascending branch of the anterior femoral circumflex artery in the surgical field to protect the blood supply of the femoral head.
- The psoas tendon is located beneath the iliacus muscle and can be identified by blunt dissection of the iliacus muscle belly medial to the ilium at the level of the anterior pelvic rim. Tendinous part of the iliopsoas muscle is released (**Figure 7**). Care must be taken to protect the femoral neurovascular bundle, which is located immediately medial and slightly anterior to the iliacus muscle. A blunt retractor is useful in protecting the femoral neurovascular bundle in the surgical field.
- The edge of the acetabulum and the reflected head of the rectus femoris muscle are clearly identified. Find the margin of the joint capsule at the acetabular rim and expose the anterior aspect of entire joint capsule. The capsule may be redundant and adherent to the ilium as a result of femoral head dislocation. Use a periosteal elevator to strip off any soft tissue from the anterior aspect of the ilium to reveal the junction of the hip capsule and cartilaginous labrum.

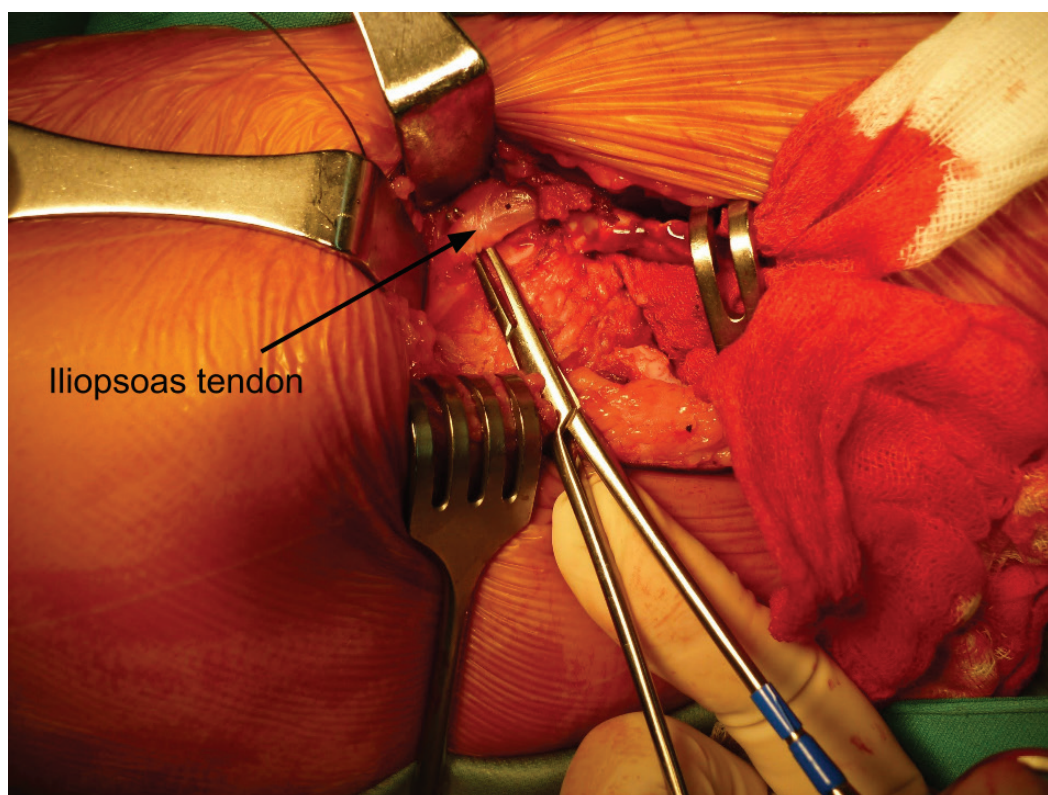


Figure 7. The iliopsoas tendon is identified at the pelvic rim, and the tendinous portion is divided, leaving the muscular portion intact.

4.3. Step 3: open reduction of dislocated hip joint and ilium osteotomy

Perform an open reduction, check hip stability, make medial and lateral cut lines and complete the osteotomy.

- For a dislocated hip, open reduction is needed. A T-shaped capsulotomy near the acetabular rim, including the upper and lower margins of the hip capsule, is done (**Figure 8**). The stem of the T-shaped capsulotomy is parallel to the femoral neck and is slightly superior to avoid a small inferior capsular flap, which may make the capsulorrhaphy difficult. The ligamentum teres are cut sharply, and all of the fibro-fatty tissues (pulvinar tissue) are removed from the true acetabulum (**Figure 9**). The transverse acetabular ligament is seated in the inferior part of the true acetabulum. The tension of the ligament is palpated by the finger and released by scissors. The tension of the ligament is tested again by palpation to confirm complete release of the transverse acetabular ligament. The remaining transverse acetabular ligament can impede complete reduction of the femoral head.
- The femoral head is gently reduced into the acetabulum under direct vision. The stability of the hip joint is checked in a neutral position as well as in abduction and internal rotation. If the hip is unstable in a neutral position but is stable in abduction and internal rotation, a Pemberton acetabuloplasty is indicated. If hip stability cannot be maintained even in abduction and internal rotation, an additional proximal femoral varus and/or rotational osteotomy should be considered.
- The gauze sponges are removed on either side of the iliac bone. All of the bleeders from the iliac wing or from the periosteum are checked. Pemberton osteotomy can begin once haemostasis is achieved. The sciatic notch is identified first with a small periosteal elevator and the adjacent soft tissue, including the sciatic nerve are protected with two small Hohmann retractors. The medial iliac cut line is outlined with the electrocautery tip. Using a small straight osteotome, begin the medial cut line about 1–1.5 cm above the superior hip joint line and curve it inferiorly and posteriorly, aiming at the sciatic notch. The cut line extends halfway to the sciatic notch and ends at the ridge of the pelvic inlet of the ilium. The lateral cut line has the same starting point as the medial cut. With the medial cut line as a reference, use the same osteotome to make the lateral cut line along the joint capsule. (**Figure 10**).
- A wider, curved osteotome is used to complete the osteotomy. The medial and lateral cut lines are connected with a curved osteotome (**Figure 11**). As this osteotomy advances, the osteotome is pushed against the distal fragment to check the degree of downward displacement. If the osteotomy site opens more than 2–3 cm that means that the distal fragment is hinging on the triradiate cartilage and there is no further advancement of the osteotome needed. If the opening is insufficient, osteotome should be advanced slightly and the amount of osteotomy opening is checked again until the opening is adequate.

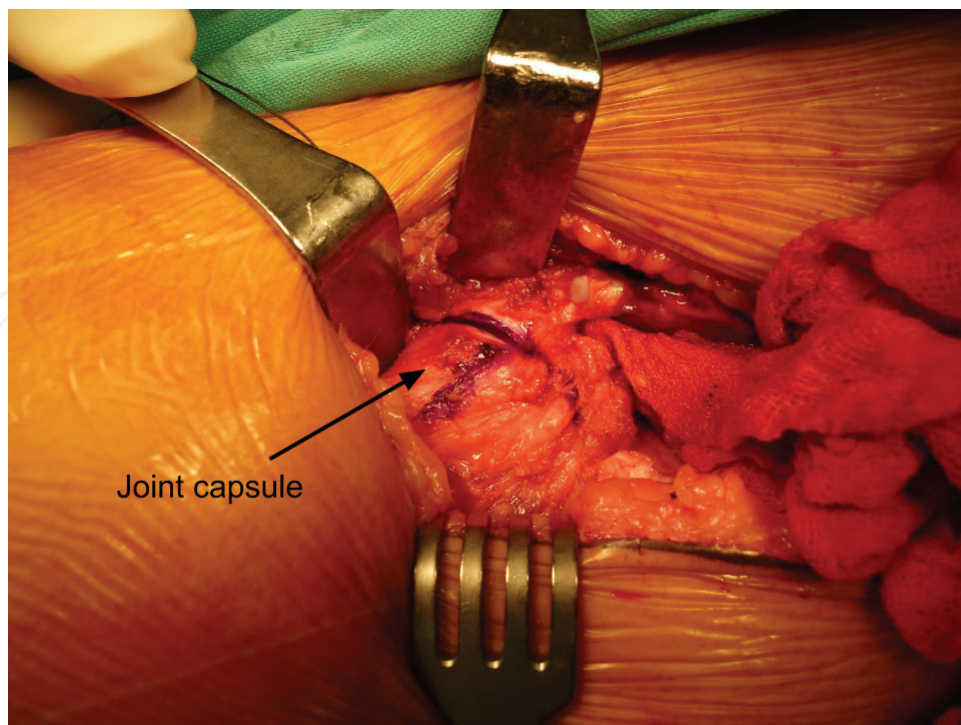


Figure 8. Capsular incision outline with the stem of the T parallel with the femoral neck.

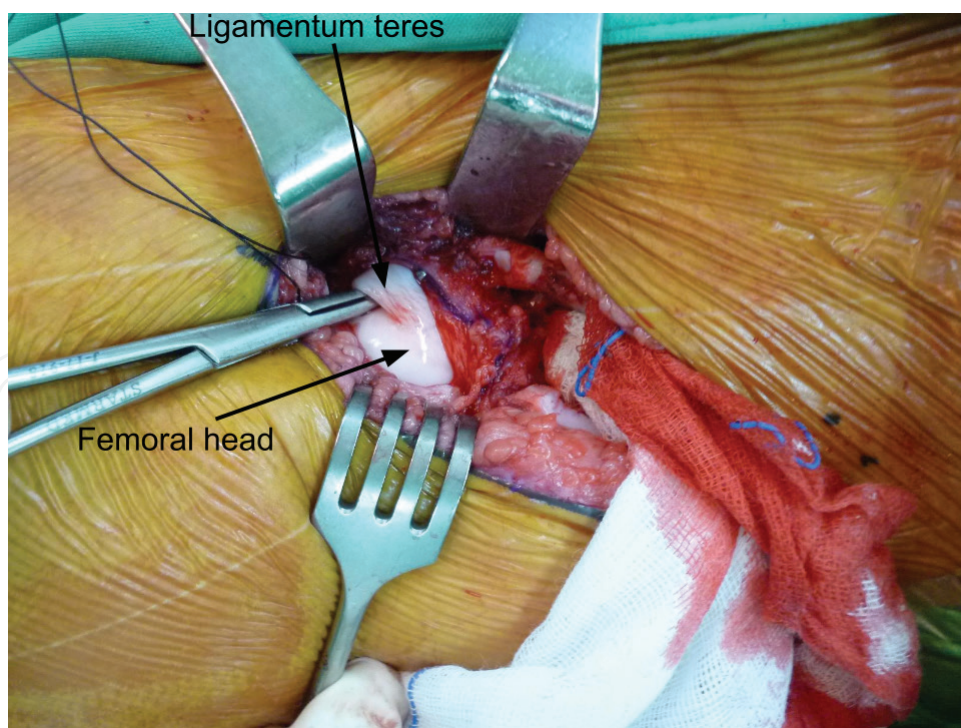


Figure 9. After T-capsulotomy, dislocated femoral head and redundant ligamentum teres are visualized.

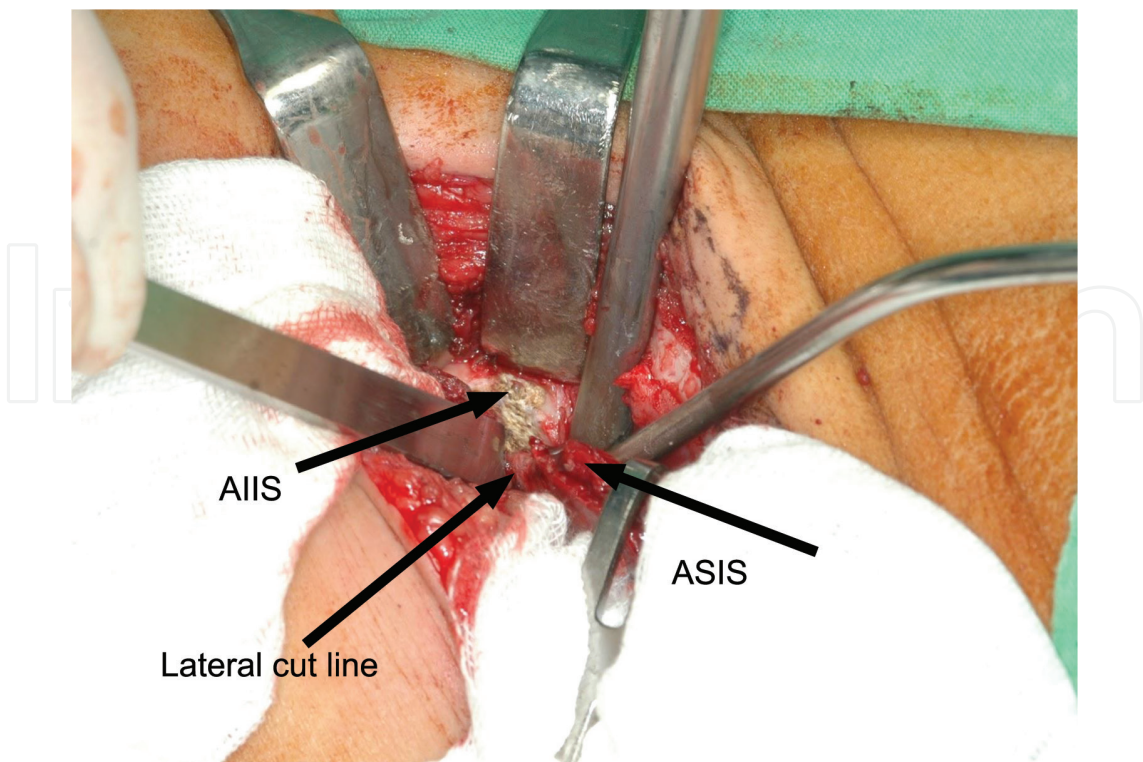


Figure 10. Lateral cut line starts between the ASIS and AIIS.

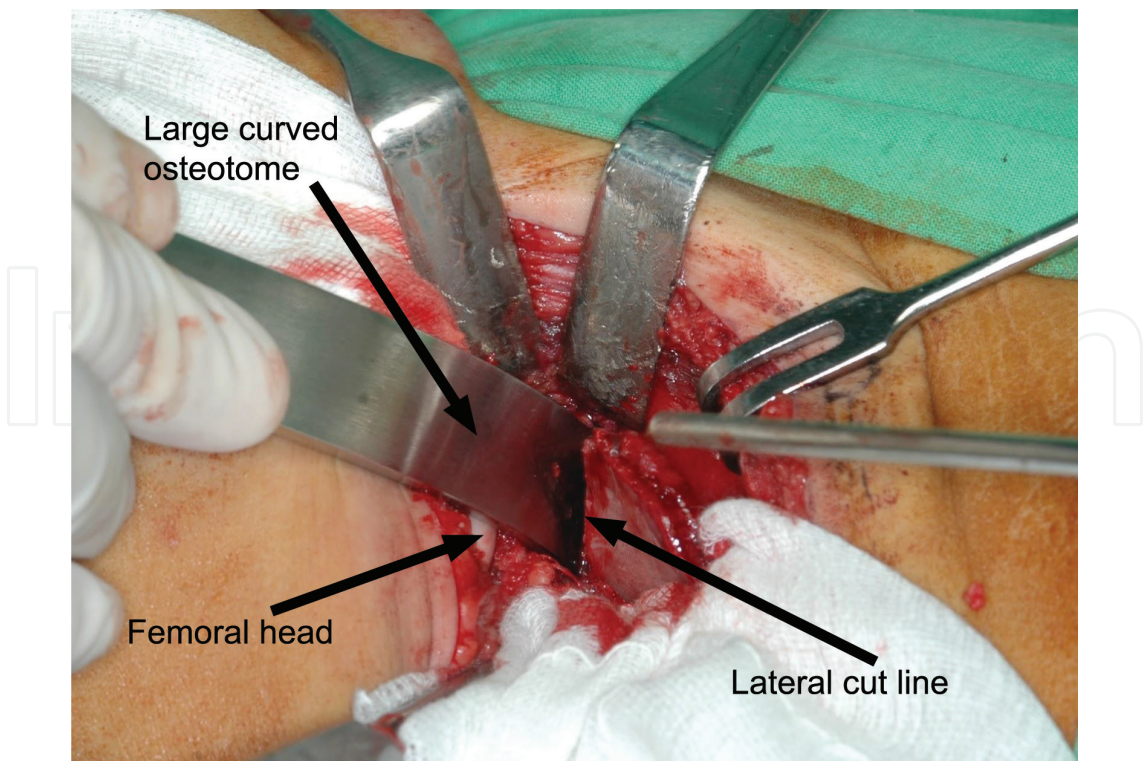


Figure 11. Complete the osteotomy with a large-curved osteotome.

4.4. Step 4: insert the bone graft

Harvest the graft, position the reduced hip joint, insert the bone graft, repair the capsule and close the wound.

- A triangular-shaped iliac crest bone graft is harvested from the iliac wing with a bone cutter or an oscillating saw.
- With the femoral head in reduced position, a towel roll is placed underneath the knee to help maintain the hip in an abducted and flexed position.
- Two towel clips are used to hold the superior and inferior osteotomy fragments, respectively. The inferior fragment is manipulated anteriorly and inferiorly to cover the femoral head. Then insert the triangularly shaped bone graft into the osteotomy opening site. Usually, when the triangular iliac bone graft is stably seated in the osteotomy site, no internal fixation is needed (**Figure 12**). If the bone graft is not stable, fixation with one or two Kirschner wires may be necessary.
- The hip capsule is repaired by bringing the two flaps of the T-capsulotomy to the acetabular flap of the capsule. The tendon of the straight head of the rectus femoris muscle is reattached to the anterior inferior iliac spine. Suture the iliac apophysis over the ilium and close the wound.

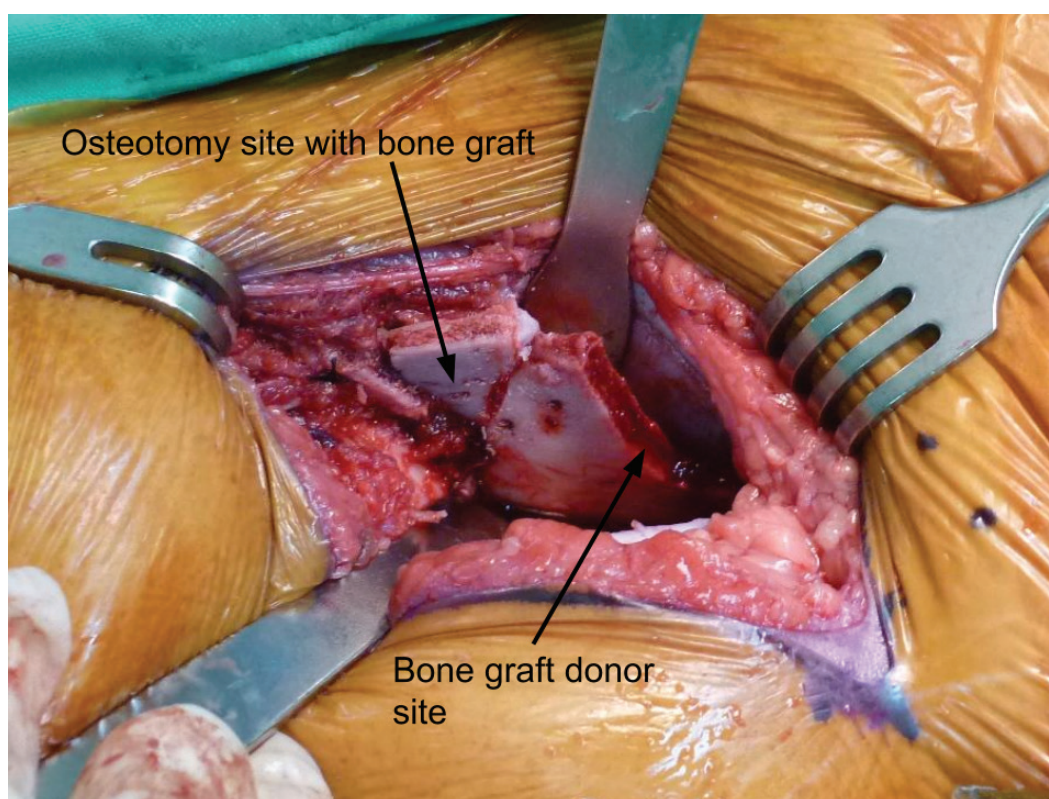


Figure 12. Bone graft is inserted after opening the osteotomy site.

4.5. Step 5: post-operative management

A hip spica cast is applied after the wound closure. Both hips are held in about 20° of flexion, 30° of abduction each, and neutral or slight internal rotation to stabilize the hip while the cast is applied. For patients undergoing a simple Pemberton osteotomy, the spica cast is worn for four weeks. For patients with combined open reduction of the hip, the spica cast is applied for 6 weeks, followed by use, for 4 weeks, of a hip abduction brace or an 'A cast' (a bilateral cylinder cast with a spreader bar, holding each hip at 30° abduction) [6, 7].

5. Surgical technique (Salter innominate Osteotomy)

5.1. Step 1: surgical approach and hip joint exploration

The same skin incision and surgical approach as previously described in this chapter for Pemberton osteotomy are used to explore the dislocated hip joint.

5.2. Step 2: innominate osteotomy

Expose the inner and outer table of the ilium sub-periosteally until sciatic notch is totally visualized. Pass an Ethibond suture with a right angled clamp through the sciatic notch and grasp the Ethibon suture with a Kelly clamp. Tie the Gigli saw with the Ethibon suture as a guide to pass through the sciatic notch (**Figure 13**). Place two Hohmann retractors or Rang retractors

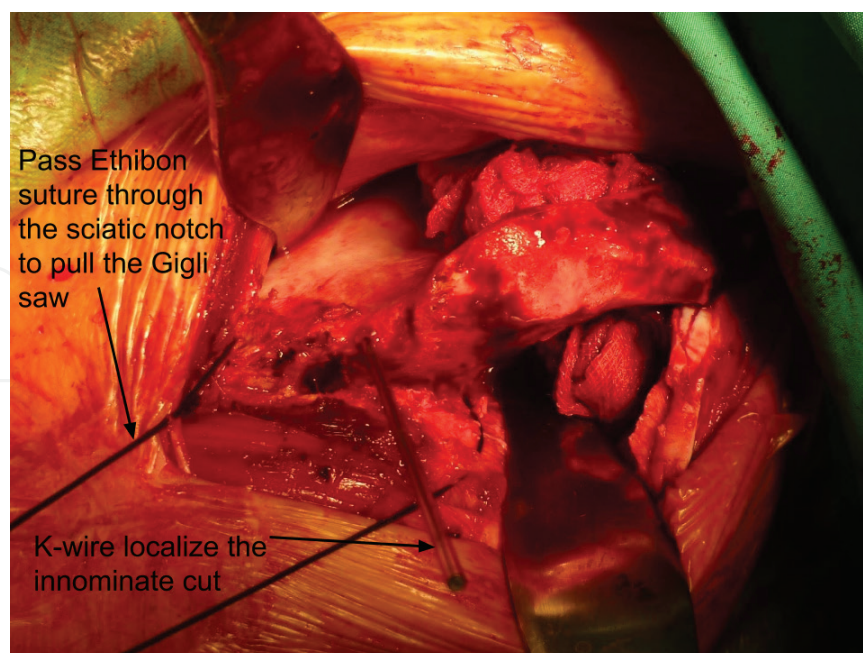


Figure 13. Both tables of the ilium are exposed sub-periosteally and place the blunt Hohmann retractor at the sciatic notch to protect the soft tissue during procedure. Passing a No. 5. Ethibon suture through sciatic notch to pull the Gigli saw can facilitate the procedure, also protect the adjacent soft tissues while passing Gigli saw.

during passage of the Gigli saw to protect the sciatic nerve. The complete osteotomy is done with Gigli saw, starting from sciatic notch and emerging in between anterior superior iliac spine and anterior inferior iliac spine.

5.3. Step 3: insert the iliac bone graft and fix with K-wires

Harvest a wedge-shaped iliac crest bone graft from the iliac wing with a bone cutter or a power saw. With the hip in frog leg position, hold the two fragments of ilium with towel clips and open the osteotomy site with distal fragment pulling towards inferior and lateral position. The distal fragment should be held as far posterior as possible to prevent fracture of the distal fragment during opening of the osteotomy site. Then insert the triangularly shaped bone graft into the osteotomy opening site. Fix the fragments and the bone graft with two or more K-wires. Confirm the pins position with intraoperative radiograph and make sure not to penetrate the hip joint. Check the stability of the hip joint and the stability of fixation with passively moving the hip joint. Carefully palpate any crepitus or clicking which may indicate the penetration of the K-wire into the hip joint.

5.4. Post-operative management

Apply the hip spica cast as previously described in this chapter for Pemberton osteotomy. The hip spica cast should be continued for 6 weeks. After removal of the spica cast, abduction brace is applied for 4 weeks. Weight bearing or walking under abduction brace is allowed (Figures 14–16).

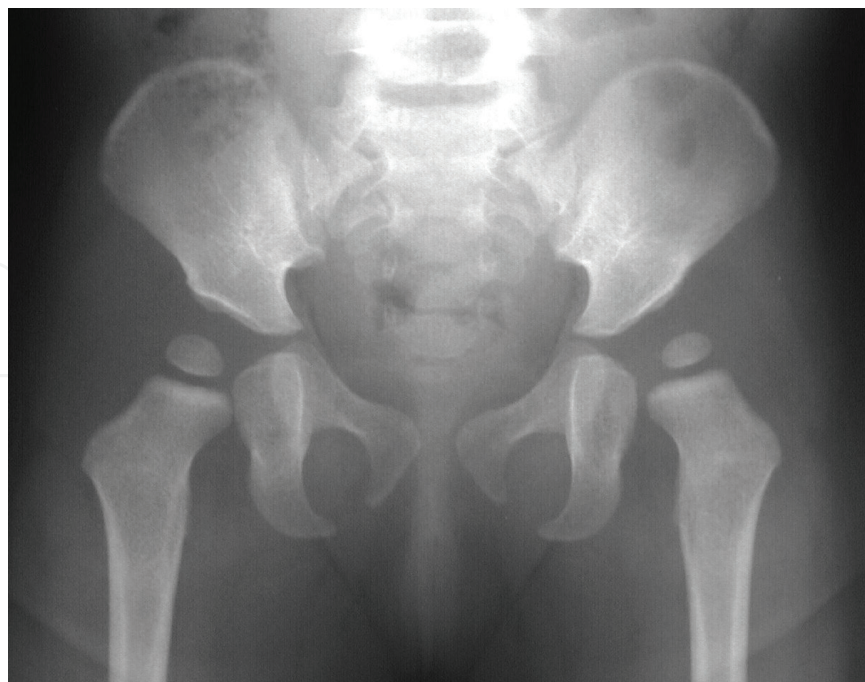


Figure 14. A 16-month-old girl with left-hip dysplasia and lateral subluxation. Note the Shenton's line is disrupted and the acetabular index is 50° in the left side.

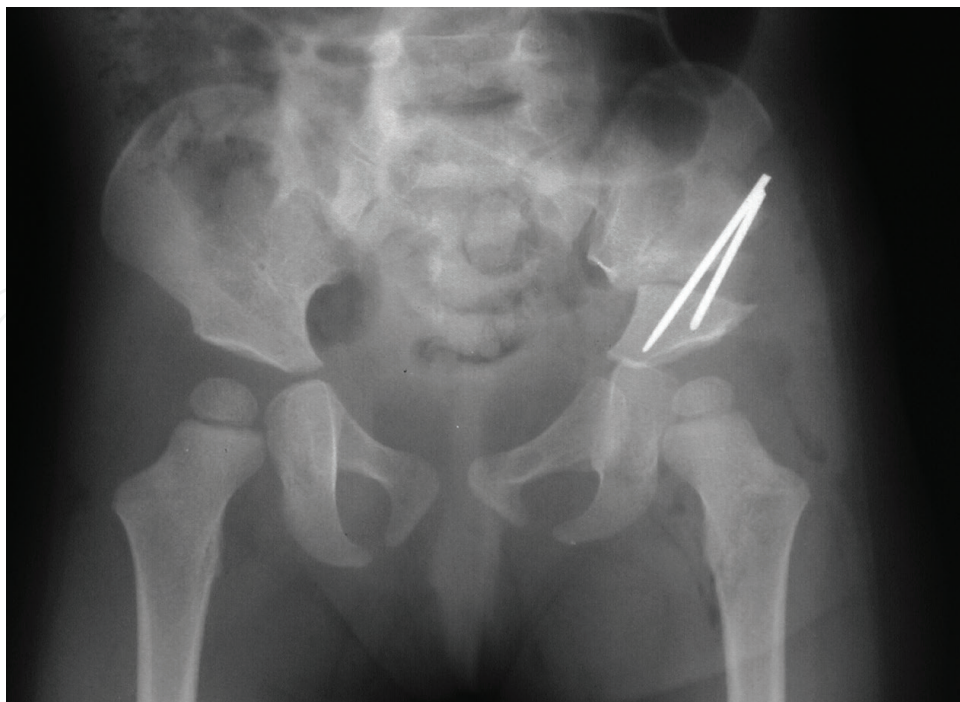


Figure 15. Radiograph after Salter Osteotomy and internal fixation with two K-wires when the patient was 22 months old. The Shenton's line is smooth in each side.

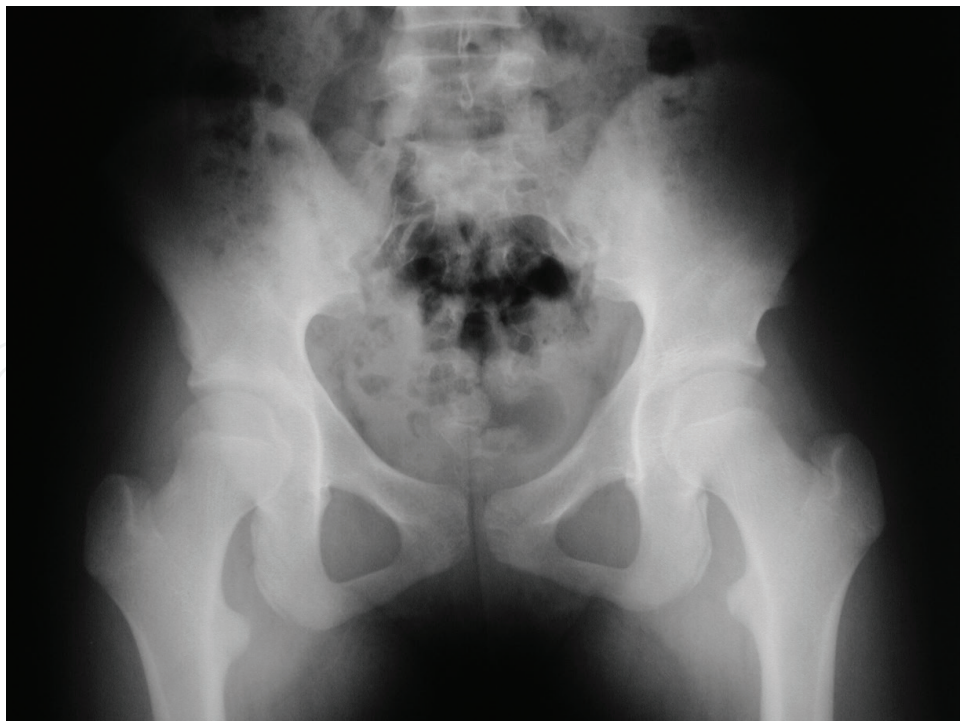


Figure 16. Final radiograph, taken when the patient was 13 years old, reveals well-developed hips. The patient was totally symptom free.

5.5. Complications

The surgeon should pay attention to every detail of the procedure to avoid the complications. Sciatic nerve injury is a devastating complication during osteotomy. The iliac wing bone cut should always be protected by the instruments such as Hohmann retractors or Rang retractors during the passage of the Gigli saw in the sciatic notch. Loss of fixation sometimes occurs if the K-wires are not placed in the appropriate position. K-wire penetration into the hip joint or even into the femoral head should be prevented by intraoperative radiographs.

6. Surgical technique (combined procedure for high dislocation in patients with developmental dysplasia of the hip)

A late presentation of DDH in patients older than 3 years old often is characterized by high dislocation and irreducible joint. It is more common that children with bilateral dislocation are brought to orthopaedic surgeon's attention at older age. They are usually in higher Tönnis grade than patients with unilateral dysplasia [8]. A combined procedure including open reduction, femoral-shortening osteotomy and an acetabular procedure is often necessary to obtain a desirable result in children of walking age who have a high-riding hip dislocation. The combined procedure with femoral shortening, although technically demanding, helps prevent excessive force that hinders concentric reduction and decreases the risk of complications related to open reduction, especially re-dislocation and osteonecrosis, which are common in older children. In case with severe dysplasia, acetabulum may be globally deficient. For the patient with globally deficient acetabulum, a careful planning of combined femoral shortening, derotation osteotomy or flexion-extension osteotomy is required to prevent posterior dislocation of the hip after surgery [9].

6.1. Step 1: surgical approach and hip joint exploration

The same skin incision and surgical approach as previously described in this chapter for Pemberton osteotomy was used to explore the dislocated hip joint.

6.2. Step 2: femoral head reducibility

Reduce the femoral head with traction and check the soft-tissue tension. If the femoral head is reducible, place it into the acetabulum under direct vision and test the hip stability in a neutral position as well as in abduction and internal rotation by pushing the femoral head in a cephalad direction. If the hip is unstable in a neutral position but is stable in abduction and internal rotation, a Pemberton acetabuloplasty is indicated. When the femoral head is not reducible or is under great tension when reduced, a femoral shortening osteotomy should be performed.

6.3. Step 3: femoral osteotomy

Start the second incision from the lower tip of the greater trochanter and extend distally. The length of the incision, usually about 5–6 cm, depends on the length of the implant used for fixation of the osteotomy site and the required amount of shortening of the femur. Expose the femoral shaft by splitting the tensor fasciae latae and elevate the vastus lateralis off the lateral inter-muscular septum, coagulating perforating branches of profundus femoris vessel as needed. Expose the greater trochanter base; make an L-shaped incision at the proximal origin of the vastus lateralis muscle (**Figure 17**). Cut and elevate the periosteum longitudinally, and insert Chandler retractors under the sub-periosteal space to expose the femoral shaft. Insert a Steinmann pin into the femoral neck perpendicular to the femoral shaft just below the greater trochanteric apophysis under fluoroscopic guidance. This pin will serve as a joystick for checking the femoral head position. Insert a second Steinmann pin in the projected distal femoral segment in the same rotation plane and perpendicular to the shaft of the femur for rotational guidance. Make another longitudinal mark on the anterior aspect of the proximal part of the shaft as an additional orientation marker for femoral rotation (**Figure 18**). Make a transverse mark with an oscillating saw on the femoral shaft at the lower level of the lesser trochanter under fluoroscopic guidance as a marker of the osteotomy site (**Figure 19**). Using a four-hole DCP (dynamic compression plate) as a template, make two pre-drilled holes at the proximal end for better fixation alignment later. Divide the bone with an oscillating saw at the previously marked site. Make sure that the periosteum is well stripped so that you can manipulate the femoral head position with the proximal Steinmann pin as a joystick.

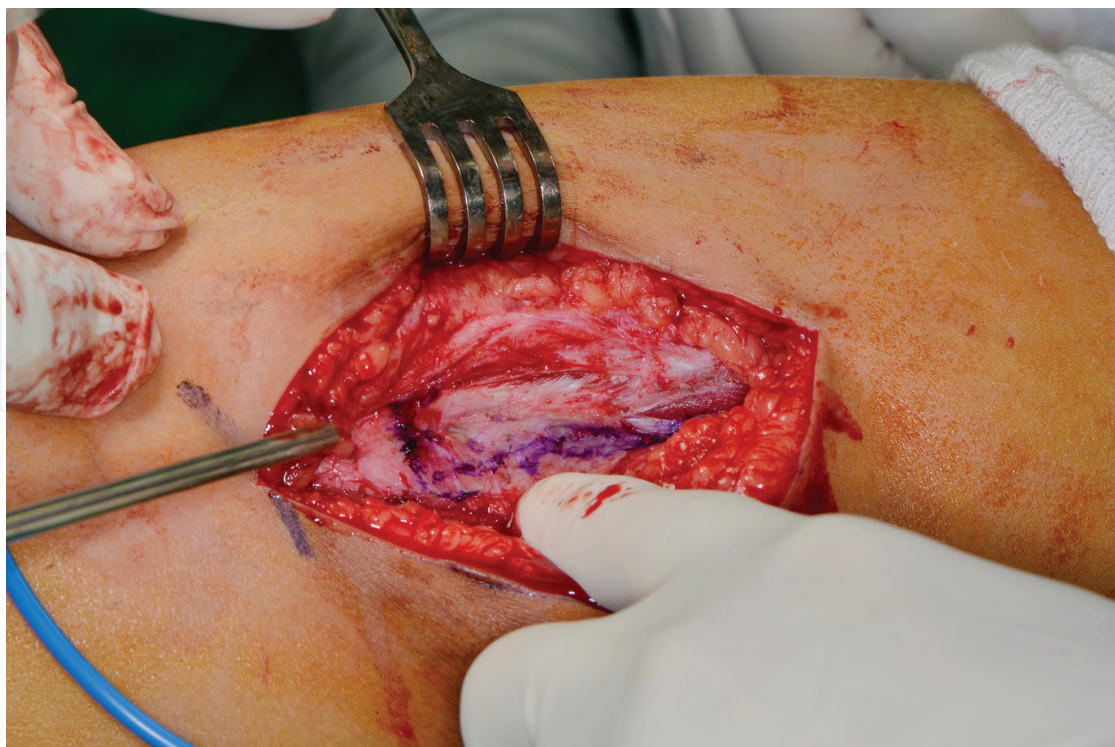


Figure 17. Marking for vastus lateralis incision.

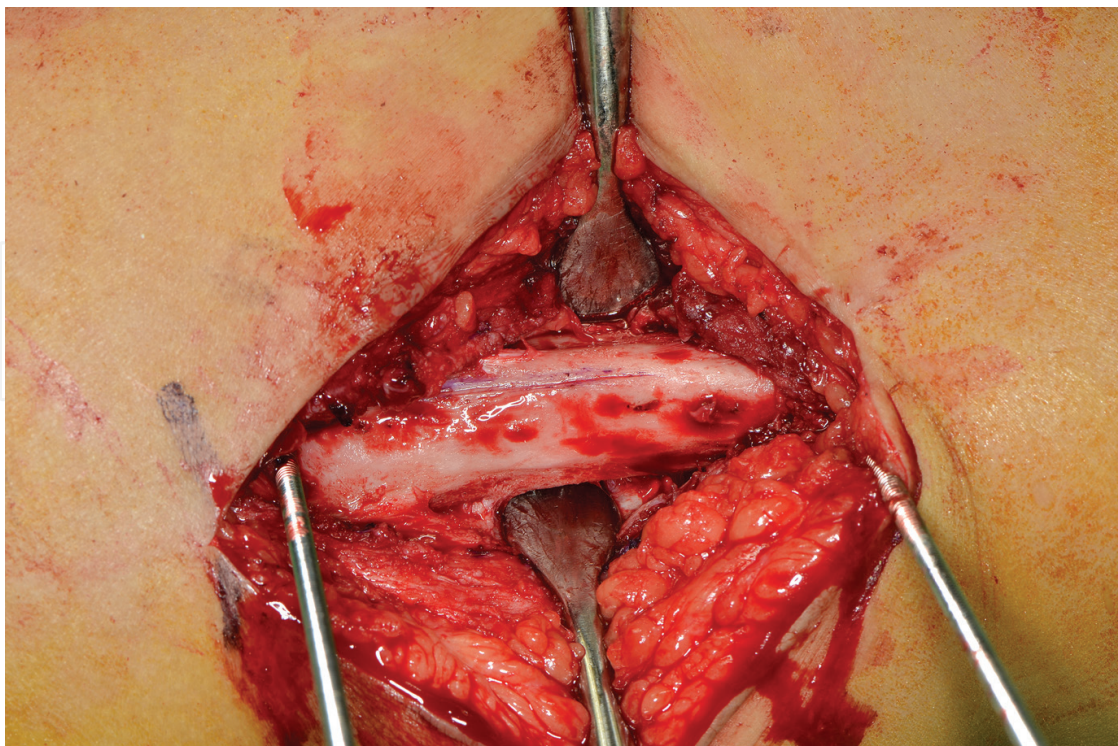


Figure 18. Insert parallel Steinman pins for rotational orientation. Marked the longitudinal rotation mark on the anterior aspect of femoral shaft.

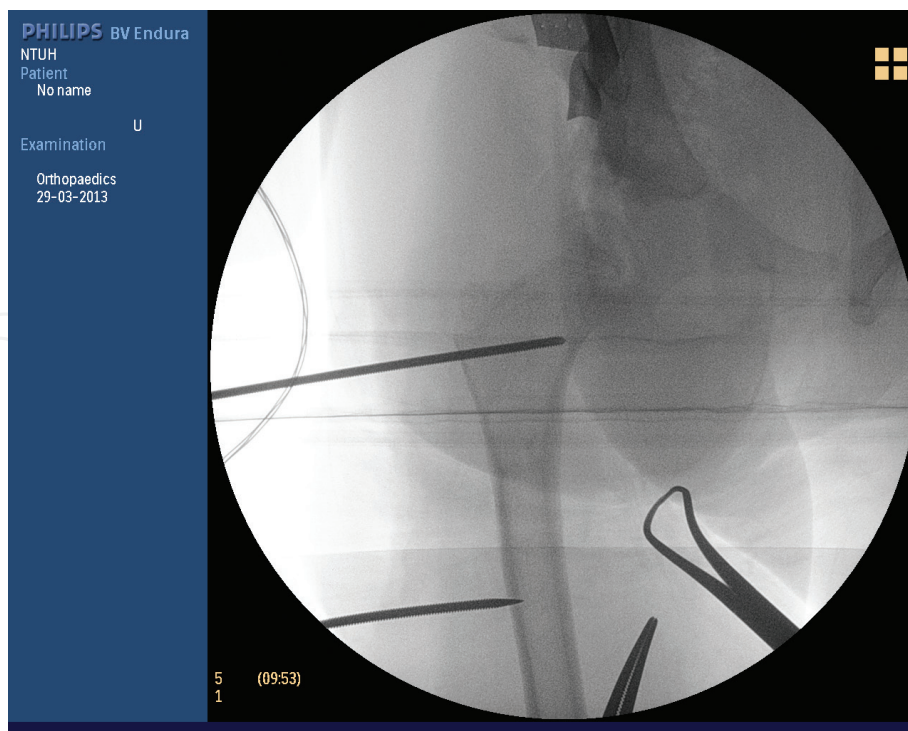


Figure 19. Fluoroscopic view showing two Steinman pins in parallel position. Marking of the osteotomy site under c-arm guided.

6.4. Step 4: hip joint stability

Manipulate the proximal Steinmann pin to reduce the femoral head under direct vision. Check the coverage of the femoral head and the stability of the reduction and assess the necessity for rotational osteotomy and pelvic osteotomy. If the femoral head cannot be reduced in a stable manner or the reduction cannot be maintained unless the proximal fragment is in internal rotation and/or abduction, an additional proximal femoral derotational osteotomy and/or varus osteotomy should be considered. Once the optimal position is achieved, have the assistance to hold the femoral head in an optimum position by holding the proximal Steinmann pin and return to the femoral shaft exposure.

6.5. Step 5: femoral shortening

Estimate the amount of shortening from the preoperative standing pelvic anteroposterior radiograph, and measure the amount of step-off at the broken Shenton line. The amount of shortening depends on the height of the dislocation; generally, 1–2 cm is required for neglected developmental dysplasia of the hip in a patient between 3 and 5 years old and 2–3 cm is required for patients between 5 and 8 years old. Holding the knee in neutral position with gentle tension, in correct rotational axis and angulation, measure the amount of overlapping. The length of overlapping of the bone ends is the amount of femoral shortening required (**Figures 20** and **21**). Resect the shortening section from the proximal end of the distal fragment of the femur (**Figure 22**). Reduce the femoral head into the acetabulum again, using the Steinmann pin as a joystick. Bring both ends of the femoral shaft together with the femoral head held in a reduced position by the assistant. Apply a pre-contoured four-hole DCP or locking plate on the reduced fragments with two holes on the proximal fragment and two holes on the distal fragment (**Figure 23**). Insert the proximal-fragment screws into the predrilled holes first. Use a reduction clamp to hold the distal segment and the plate in the desirable position. Insert the distal-fragment screws and complete the internal fixation in ideal position. Check the stability of the hip joint under direct vision, or with fluoroscopy if necessary, through the hip range of motion. At this time, the amount of rotation corrected can be seen from the relative rotation of two Steinmann pins viewed from caudally (**Figure 24**). Do not place the distal fragment in excessive external rotation if an acetabular procedure is contemplated.

6.6. Step 6: Pemberton acetabuloplasty

Perform the Pemberton osteotomy and insert the iliac bone graft as previously described in this chapter.

6.7. Post-operative management

Apply a one and a half hip spica cast with the hip in 30° of abduction, 20° of flexion and neutral to 10° of internal rotation. Remove the spica cast after 6 weeks. A hip abduction brace is then used full time for 6 weeks and at night for an additional 3 months.

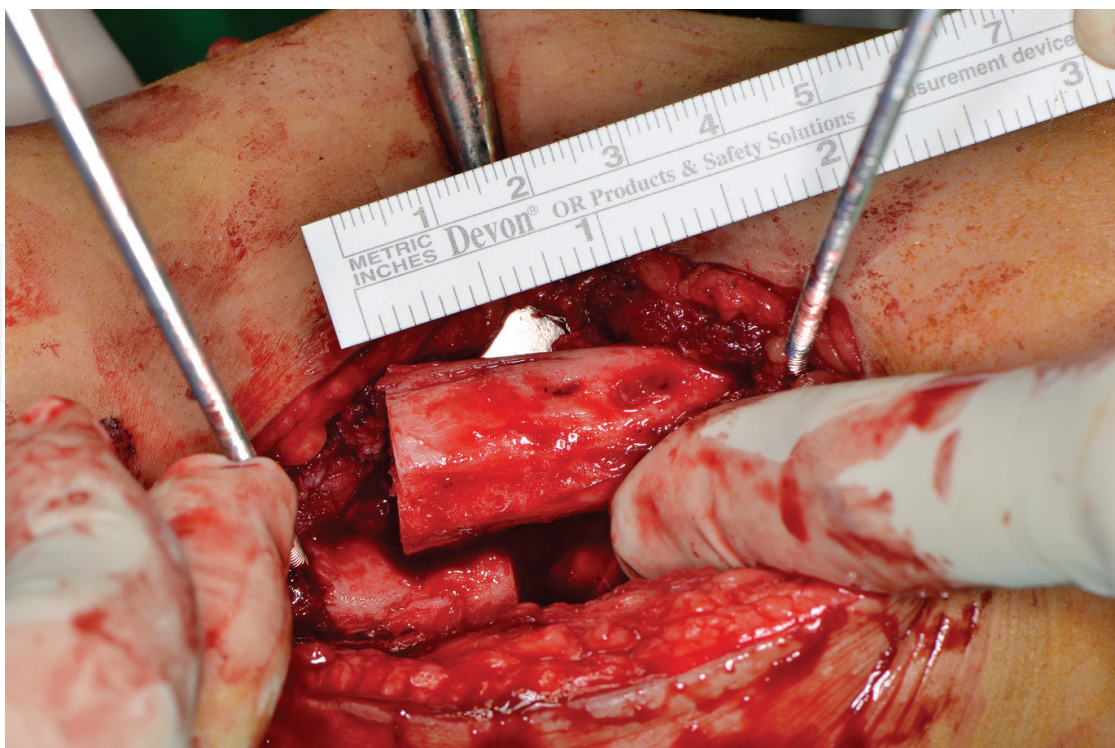


Figure 20. The amount of overlapping while the femoral head is in the reduced position is the amount of femoral shortening required.

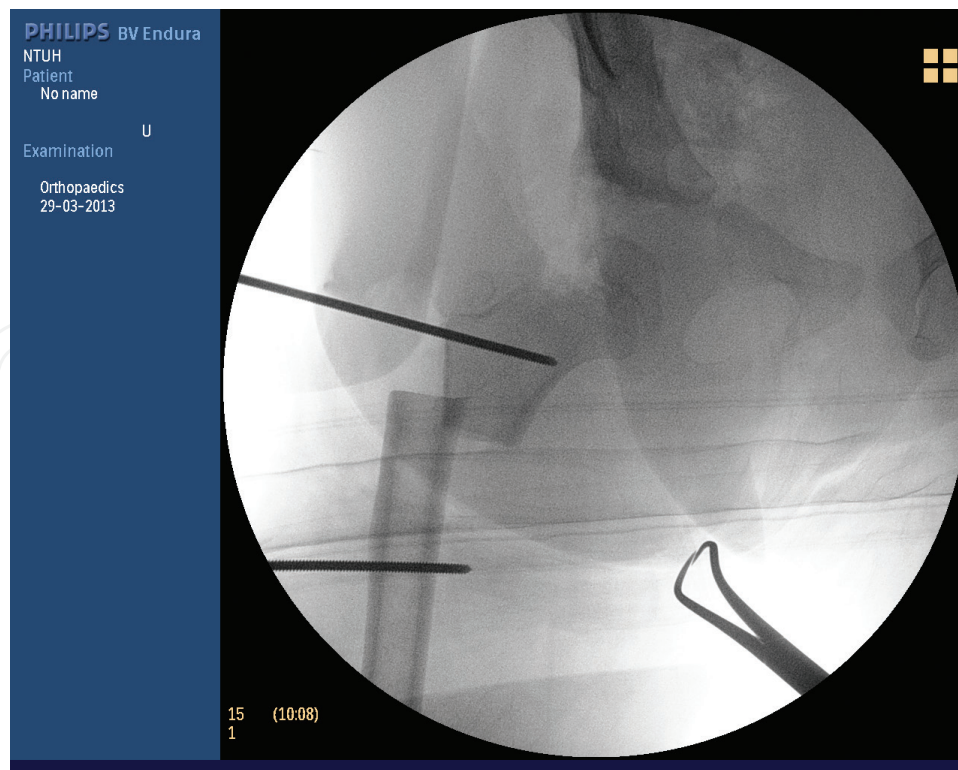


Figure 21. C-arm view shows the amount of shortening required while the femoral head is in a reduced position.

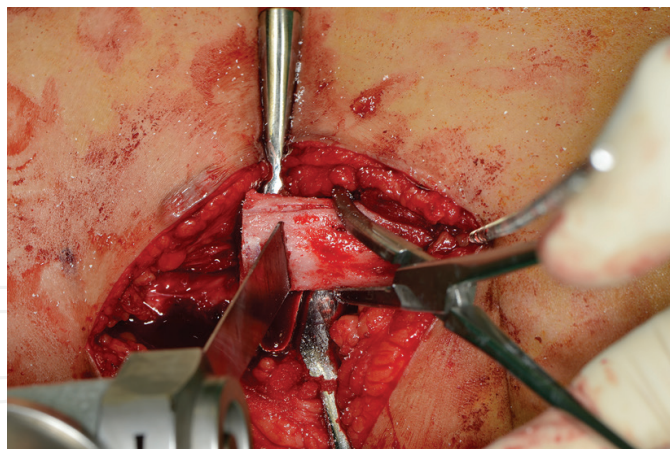


Figure 22. The fragment is removed from the proximal end of the distal fragment.

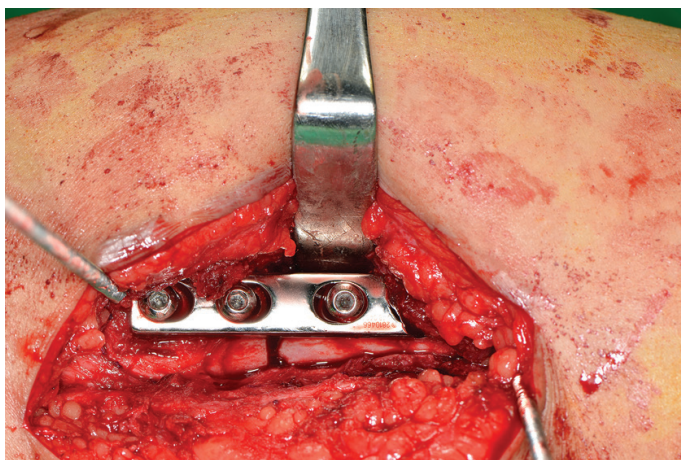


Figure 23. Both ends of femur are fixed with a four-hole dynamic compression plate. The diversion angle of two Steinman pins demonstrating external rotation of the distal fragment.

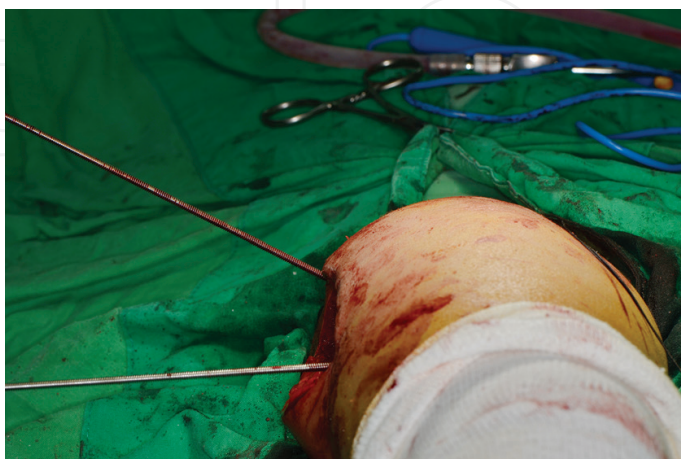


Figure 24. The diversion angle of two Steinmann pins viewing from caudally indicates the amount of external rotation (30° in this case) of the distal osteotomy.

6.8. Pitfalls and challenges

The Pemberton osteotomy is a well-established procedure and can be done safely by an experienced hand. The common complications included bleeding, infection, bone graft dislodgement, premature triradiate cartilage closure and re-dislocation. If the osteotomy is not stable enough to hold the bone graft, displacement of the graft may occur. If there is any doubt in the stability of the bone graft during operation, additional K-wire fixation for the osteotomy site through the bone graft should be done. Premature closure of the triradiate cartilage may develop if the osteotomy goes through the triradiate cartilage. But this complication is extremely rare. Re-dislocation of the hip after surgery is not a rare complication. The most common causes of re-dislocation are poor post-operative hip spica casting technique to hold the hip in reduced position, global deficiency of acetabulum, inexperienced surgeon and inadequate soft tissue release including iliopsoas tendon and transverse ligament. Excessive correction with Pemberton osteotomy may result in osteonecrosis of the femoral head and possibly femoral acetabular impingement in the future. Wu et al. have reported that with more distal femoral head positioning after pelvic osteotomy, there is a higher risk of osteonecrosis [6].

7. Long-term results

7.1. Change of hip joint anatomy

Concerns have been raised that redirection of the acetabulum with the Salter osteotomy may create an increased acetabular retroversion with improving anterior over-coverage. Acetabular retroversion or over anterior coverage has been implied as a cause of hip pain, impingement and subsequent osteoarthritis. In one study comparing long-term results of those two osteotomies, it suggested that by modifying the acetabular shape, the Pemberton osteotomy may result in an increase in anterior acetabular coverage. This in term may increase the risk of impingement [10]. Leg length discrepancy with longer leg at pathology side may be caused by coxa valga due to Kalamchi type II osteonecrosis of femoral head or trans-iliac lengthening of the pelvis [6].

7.2. Osteonecrosis of the femoral head

Osteonecrosis of the femoral head with physeal damage is not uncommon and a potentially devastating outcome following the treatment of DDH. The reported incidence of osteonecrosis has ranged from 0 to 73%. It is a severe complication that diminishes the long-term results of treatment of DDH. Although different treatment modalities have shown differences in the rates of osteonecrosis, most authors agree that an alteration of the blood supply to the femoral head resulting from treatment leads to this iatrogenic complication. It is generally accepted that the damaged blood supply of the proximal femoral epiphysis leads to osteonecrosis and the subsequent progressive deformity of the proximal femur [6]. The degree of osteonecrosis secondary to surgical treatment may range from mild epiphyseal hypoplasia to severe deformity of the femoral head depending on the location and extent of the physeal injury. Kalamchi

and MacEwen's had developed four types of osteonecrosis after treatment of DDH [11]. Group I demonstrates changes affecting the ossific nucleus, group II is characterized by lateral physeal damage, group III has central physeal damage and group IV has total damage to the femoral head and physis. Patients with severe osteonecrosis (Kalamchi type III and IV) may lead to leg length discrepancy, joint incongruity and eventually premature OA. The majority (52%) of the cases of osteonecrosis after Pemberton osteotomy in the authors institute were Kalamchi type II with typical radiographic findings (coxa valga). Immobilization of a hip with an over-corrected acetabular fragment following osteotomy or immobilization of the hip in an extremely abducted position may compromise the blood supply of the proximal femoral epiphysis. It is believed that the lateral epiphyseal branch of the medial circumflex artery may be compressed by the acetabular labrum in the superior or the posterior intra-epiphyseal groove. Coxa valga due to Kalamchi type II osteonecrosis may not only lead to leg length discrepancy. Pelvic obliquity may also cause inadequate coverage of femoral head in the affected side. The decreased contact area between the femoral head and acetabulum may eventually lead to early osteoarthritis of hip. Wu et al. analysed long-term result of 167 patients who underwent Pemberton acetabuloplasty and found that excessive distal movement of the acetabular fragment was correlated with the development of osteonecrosis. They concluded that the risk of osteonecrosis is higher in those femoral head positioned more distally after Pemberton acetabuloplasty [6].

8. Treatment of long-term sequelae

Coxa valga caused by Kalamchi type II osteonecrosis of the femoral head can be treated by varus osteotomy of proximal femur or guided growth by an eccentric transphyseal screw. Leg length discrepancy can be treated by epiphysiodesis or modulation of the longer leg, or lengthening of the shorter limb by distraction osteogenesis.

9. Conclusion

For surgeons familiar with these procedures, either the Pemberton osteotomy or the Salter osteotomy can be a safe and effective option for treating developmental dysplasia of the hip. Careful surgical release of soft-tissue contractures, complete reduction, femoral shortening if indicated and avoidance of cast immobilization with the hip in an extreme position are believed to be effective in decreasing pressure on the femoral head and reducing the prevalence of osteonecrosis. Patients should be routinely followed until skeletal maturity to watch for long-term sequelae. Those treatable conditions should be appropriately managed at the right time to improve the long-term outcome.

Acknowledgements

Parts of this chapter are reproduced from Ref. [7].

Author details

Chunho Chen^{1,2,3*}, Ting-Ming Wang^{2,3} and Ken N. Kuo^{2,3,4}

*Address all correspondence to: bacriv@gmail.com

1 Department of Orthopedic Surgery, Chiayi Christian Hospital, Chiayi, Taiwan

2 Department of Orthopedic Surgery, National Taiwan University Hospital, Taipei, Taiwan

3 School of Medicine, National Taiwan University, Taipei, Taiwan

4 Center for Evidence-Based Medicine, School of Medicine, Taipei Medical University, Taipei, Taiwan

References

- [1] Pemberton PA. Pericapsular osteotomy of the ilium for treatment of congenital subluxation and dislocation of the hip. *J Bone Joint Surg Am.* 1965;47:65–86.
- [2] Vedantam R, Capelli AM, Schoenecker PL. Pemberton osteotomy for the treatment of developmental dysplasia of the hip in older children. *J Pediatr Orthop.* 1998;18:254–8.
- [3] Wada A, Fujii T, Takamura K, Yanagida H, Taketa M, Nakamura T. Pemberton osteotomy for developmental dysplasia of the hip in older children. *J Pediatr Orthop.* 2003;23:508–13.
- [4] Salter RB. Innominate osteotomy in the treatment of congenital dislocation and subluxation of the hip. *J Bone Joint Surg Br.* 1961;43:518–539.
- [5] Salter RB and Dubos JP. The first fifteen-year personal experience with innominate osteotomy in the treatment of congenital dislocation and subluxation of the hip. *Clin Orthop.* 1974;98:72–103.
- [6] Wu KW, Wang TM, Huang SC, Kuo KN, Chen CW. Analysis of osteonecrosis following Pemberton acetabuloplasty in developmental dysplasia of the hip: long-term results. *J Bone Joint Surg Am.* 2010;92:2083–94.
- [7] Huang S-C, Wang T-M, Wu K-W, Fang C-F, Kuo KN. Pemberton osteotomy for acetabular dysplasia. *JBJS Essential Surg Tech.* 2011;94(1):1–1. DOI: 10.2106/JBJS.ST.K.00003
- [8] Wang T-M, Wu K-W, Shih S-F, Huang S-C, Kuo KN. Outcomes of open reduction for developmental dysplasia of the hip: does bilateral dysplasia have a poorer outcome? *J Bone Joint Surg Am.* 2013;95(12):1081–6. DOI: 10.2106/JBJS.K.01324.
- [9] Wang T-M, Wu K-W, Huang S-C, Huang W-C, Kuo KN. A Combined Procedure for High Dislocation in Patients with Developmental Dysplasia of the Hip. *JBJS Essential Surg Tech.* 2013;3(4):e19.

- [10] Wang C-W, Wu K-W, Wang T-M, Huang S-C, Kuo KN. Comparison of acetabular anterior coverage after Salter osteotomy and Pemberton acetabuloplasty: a long-term followup. *Clin Orthop Relat Res.* 2014;472(3):1001–9. DOI: 10.1007/s11999-013-3319-6. Epub 2013 Oct 5.
- [11] Kalamchi A, MacEwen GD. Avascular necrosis following treatment of congenital dislocation of the hip. *J Bone Joint Surg Am.* 1980;62:876–888.

IntechOpen

IntechOpen