

We are IntechOpen, the world's leading publisher of Open Access books Built by scientists, for scientists

4,800

Open access books available

122,000

International authors and editors

135M

Downloads

Our authors are among the

154

Countries delivered to

TOP 1%

most cited scientists

12.2%

Contributors from top 500 universities



WEB OF SCIENCE™

Selection of our books indexed in the Book Citation Index
in Web of Science™ Core Collection (BKCI)

Interested in publishing with us?
Contact book.department@intechopen.com

Numbers displayed above are based on latest data collected.
For more information visit www.intechopen.com



Incidental Gallbladder Cancer

Faisal Al-alem, Rafif E. Mattar, Ahmad Madkhali,
Abdulsalam Alsharabi, Faisal Alsaif and
Mazen Hassanain

Additional information is available at the end of the chapter

<http://dx.doi.org/10.5772/67654>

Abstract

Gallbladder cancer (GBC) is a rare but fatal disease with an incidence of less than 5000 new cases per year in the United States. Less than 20% of GBC cases are diagnosed preoperatively. The remaining cases are diagnosed either after laparoscopic cholecystectomy or intraoperatively. GBC is discovered incidentally during histopathology following 0.25–3.0% of laparoscopic cholecystectomies; however, this constitutes 74–92% of all GBC. The most pivotal and important step is accurate patient staging. Staging dictates disease management and treatment options and predicts survival. Because of the fatality of GBC and its poor prognosis, attempts of curative surgery are limited to localized resectable disease.

Keywords: gallbladder, cancer, incidental, adenocarcinoma

1. Introduction

Laparoscopic cholecystectomy is the most common elective operation performed worldwide. It is the standard of care for all symptomatic gallstone diseases. Gallbladder cancer (GBC) is a rare but fatal disease with an incidence of less than 5000 new cases per year in the United States. The anatomy of the gallbladder, specifically the absence of a serosal layer between it and the liver, permits the relative early invasion of GBC into the liver [1]. GBC also tends to spread both to lymph nodes and hematogenously to the peritoneal surfaces [2]. Moreover, because of its nonspecific presentation and constellation of symptoms and signs, many of which it shares with benign diseases such as biliary colic or chronic cholecystitis, GBC tends to go undiagnosed until relatively later stages [2]. Less than 20% of GBC cases are diagnosed preoperatively. The remaining cases are diagnosed either after laparoscopic cholecystectomy

or intraoperatively. These cases are categorized as “incidental GBC,” and their management is more complex and challenging.

2. Incidence and prevalence

GBC is discovered incidentally during histopathology following 0.25–3.0% of laparoscopic cholecystectomies [3–6]; however, this constitutes 74–92% of all GBC diagnoses [7, 8]. Although rare, GBC is the most common malignant disease of the biliary tract [9]. Its incidence varies greatly by geographical location, ethnicity, and socioeconomic status. This variation is likely due to differences in both environmental and genetic factors.

- *Ethnicity*: Unlike the vast majority of malignancies, GBC commonly occurs in South America, in countries such as Chile, Bolivia, and Ecuador, and in Asia, in parts of India, Pakistan, Japan, and Korea [10, 11]. Mapuche Indians in Chile exhibit the highest rate of GBC worldwide, with rates of 12.3/100,000 and 27.3/100,000 for males and females, respectively [12]. Asia is also a high-risk continent for GBC, with the highest incidence found in Indian women followed by Pakistani women [11]. GBC also occurs frequently in eastern and central Europe; however, its incidence is low in western and Mediterranean Europe, and in the United States [1].
- *Age and sex*: The incidence of GBC increases with age, especially in people older than 65 years [13]. In addition, GBC incidence in women is six times that in men [3].
- *Gallstone disease*: Gallstones represent the most important risk factor for GBC development [14]. However, the likelihood that an individual with gallbladder stones will develop cancer is as low as 0.5% [15]. The properties of the gallstones themselves play a role in the development of GBC, as different types of stones induce different patterns of mucosal irritation and chronic inflammation [16]. Stones larger than 3 cm confer 10 times higher risk of developing cancer than do smaller stones [17]. The higher prevalence of cholesterol stones in populations with high prevalence of GBC, such as American Indians, suggests that stone content may also be a contributing factor to cancer development [18].
- *Obesity*: Higher body mass index is associated with higher risk of development of gallstones [18]. However, data linking obesity to GBC are conflicting. A recent meta-analysis of 14 prospective cohort and 15 case control studies revealed that excess body weight is indeed a risk factor for GBC development [19].
- *Infection*: Infections with certain bacteria such as *Salmonella* and *Helicobacter* spp. have been linked to biliary malignancies [20, 21]. Chronic bacterial cholangitis also confers a strong risk for biliary cancer.
- *Other risk factors*: Chronic inflammatory conditions, such as primary sclerosing cholangitis, have been linked to malignant transformation. Environmental exposure to factors such as radon in mine workers [22] and tobacco [23] has also been implicated as a risk factor for GBC. Anatomical risk factors include an anomalous pancreaticobiliary duct junction, which is found in approximately 10% of patients with GBC [24]. Histologically,

GBC in such patients is of the papillary subtype [11], which is less invasive, with low metastatic potential; however, a prophylactic cholecystectomy should be considered in such patients.

The survival of these patients is largely affected by disease stage and surgical management. The 7th American Joint Committee on Cancer (AJCC) [25] reported that the five-year survival rate for patients with stage 0 (Tis) GBC is estimated to be 85%, and that it drops to 50% for patients with stage I (T1) GBC. The five-year survival rate for patients with stage II GBC is 25%, improving to 35% after extended cholecystectomy, and for patients with stage III GBC, it is 10%. In contrast, the survival rate of patients with stage IV GBC is extremely low, estimated to be less than 4%.

3. Time of identification and resection

GBC can be detected during a cholecystectomy procedure if a suspicious mass is found, or after surgery. Most these cases are diagnosed following a laparoscopic cholecystectomy for associated symptomatic gallbladder stones. This alone is a risk factor for reexploration to detect the presence of potential residual disease, which greatly alters the course of disease management. For gallbladder masses found during cholecystectomy, a specialized hepatobiliary surgeon must be consulted for proper management. If no specialized surgeon is available, cholecystectomy should be aborted, and the patient should be referred to a specialized center [26]. That being said, most cases of GBC are found postoperatively on pathological examinations. These cases require further staging workup and possible reresection depending on the disease stage. The timing of resection was not studied until recently. A multicenter retrospective cohort study that included 207 patients specifically examined the timing of reresection surgery and its effect on the patients' overall survival outcomes [27]. Patients who underwent reexploration and resection were divided into three groups on the basis of the time interval from the initial cholecystectomy to reoperation: group A (less than 4 weeks), group B (4–8 weeks), and group C (more than 8 weeks). Their findings revealed that patients who were reoperated within 4–8 weeks (group B) had the longest median overall survival (40 months) compared to that in groups A and C (17.2 and 22.4, respectively), despite having similar characteristics and tumor staging as these groups.

4. Staging of incidental GBC

The principles of oncological surgery remain constant in incidental GBC. The most pivotal and important step is accurate patient staging. Thus, a staging workup needs to be performed for each patient. GBC stage directly affects disease management and prognosis. TNM staging, which is recommended by AJCC guidelines [25], is the most commonly used staging system (Table 1). Staging dictates disease management and treatment options, and predicts survival.

Primary tumor (T)			
TX	Primary tumor cannot be assessed		
T0	No evidence of primary tumor		
Tis	Carcinoma in situ		
T1	Tumor invades lamina propria or muscular layer		
T1a	Tumor invades lamina propria		
T1b	Tumor invades muscular layer		
T2	Tumor invades perimuscular connective tissue; no extension beyond serosa or into liver		
T3	Tumor perforates the serosa (visceral peritoneum) and/or directly invades the liver and/or one other adjacent organ or structure, such as the stomach, duodenum, colon, pancreas, omentum, or extrahepatic bile ducts		
T4	Tumor invades main portal vein or hepatic artery or invades 2 or more extrahepatic organs or structures		
Regional lymph nodes (N)			
NX	Regional lymph nodes cannot be assessed		
N0	No regional lymph node metastasis		
N1	Metastases to nodes along the cystic duct, common bile duct, hepatic artery, and/or portal vein		
N2	Metastases to periaortic, pericaval, superior mesenteric artery, and/or celiac artery lymph nodes		
Distant metastasis (M)			
M0	No distant metastasis		
M1	Distant metastasis		
Stage	T	N	M
0	Tis	N0	M0
I	T1	N0	M0
II	T2	N0	M0
IIIA	T3	N0	M0
IIIB	T1-3	N1	M0
IVA	T4	N0-1	M0
IVB	Any T	N2	M0
	Any T	Any N	M1

Source: From Ref. [68].

Table 1. TNM staging for gall bladder cancer.

- **Imaging:** Transabdominal ultrasound (US) is commonly the first imaging modality used for evaluating most gallbladder diseases; however, its resolution is insufficient for GBC staging. Endoscopic US (EUS) is a method that provides high-resolution images, and consequently, accurate staging [28]. Unfortunately, EUS is an invasive procedure that carries the risk of

bleeding and bowel perforation, in addition to being uncomfortable for the patient. High-resolution US (HRUS) combines the convenience of transabdominal US with the high resolution and accuracy of EUS for GBC staging [29].

The initial imaging modality for evaluating surgical resectability and providing appropriate disease staging is generally a high-resolution contrast-enhanced sectional image with a computerized tomography (CT) scan of the chest, abdomen, and pelvis. It detects the extent of the tumor, distant metastasis, and gross lymph node involvement [30]. Although HRUS provides higher accuracy than CT does when predicting the depth of local tumor invasion [31], HRUS cannot replace the standard role of CT mainly because GBC resectability is determined not just by the tumor itself, but also by its extension into adjacent organs, vascular invasion, degree of bile duct obstruction, and the existence of metastasis [32]. CT has the added advantage of enabling evaluation of these entities, which makes it the most accurate modality for determining GBC resectability [33].

Local extension of disease can be evaluated further by magnetic resonance imaging (MRI), which provides detailed evaluation of the liver parenchyma and common hepatic duct/common bile duct, especially in patients with concomitant liver steatosis or cirrhosis. Lymph node status can also be difficult to establish preoperatively; however, abdominal CT and MRI increase the detection rate by up to 24% [34]. In terms of detecting metastatic lymph nodes in general, diffuse weighted MRI is more beneficial than multislice CT [35]. MR cholangiopancreatography using heavily T2-weighted sequences also enables the differentiation of the dilated bile duct from the adjacent tissues by producing bright signals from the fluid within the ducts [36].

In addition to these methods, 18-fluorodeoxyglucose positron emission (FDG-PET) is a technique that utilizes the hypermetabolic condition of malignant masses. It is combined with CT to produce a whole body metabolic map of glucose uptake. A previous study reported that (FDG-PET)-CT has a sensitivity of 56% for detecting omental, peritoneal, or lymphatic spread of GBC [2]. A general drawback of FDG-PET is the possibility of a false-positive result due to detection of inflammatory areas instead of a tumor, because they both have high glucose uptakes.

- **Diagnostic laparoscopy:** The use of diagnostic laparoscopy is mainly justified by the large percentage of cases that are found to have residual nonresectable disease, in the form of peritoneal disease, occult metastasis (not evident on imaging), or local invasion to the vascular structures, which render tumors unresectable. Although the relationship between the T stage of GBC and the benefit of diagnostic laparoscopy is not yet established in cholangiocarcinomas [37], most researchers suggest the use of diagnostic laparoscopy in patients with T2/3 lesions scheduled for reresection [38, 39], in order to save them the burden of a full laparotomy. A recent meta-analysis found the accuracy of diagnostic laparoscopy to be 63.9% [40]. The sensitivity of diagnostic laparoscopy in GBC was 0.642 (95% CI: 0.579–0.7). The use of intraoperative ultrasound increased the overall performance and contributed to a minor increase in the overall sensitivity. Diagnostic laparoscopy prevented unnecessary laparotomy in 27.6% of these cases, with a mortality rate of 0.09% and morbidity of 0.37%. These data indicate that staging laparoscopy prior to laparotomy, which can be performed within the same setting, is the recommended procedure for all GBC cases [41].

5. Contraindications for curative surgery

Because of the fatality of GBC and its poor prognosis, attempts of curative surgery are limited to localized resectable disease. Absolute contraindications to surgery include the presence of distant metastasis, liver metastasis, peritoneal disease, malignant ascites, and evidence of extensive nodal disease (para-aortic lymph nodes). Major vessel involvement, which is an indicator of stage IV disease, is another contraindication for curative surgery [42].

In contrast, T3 disease with direct involvement of the duodenum, colon, or liver does not preclude resectability if R0 en-bloc resection can be achieved safely [41]. It is not considered a contraindication even though it is an indicator of aggressive disease and carries the increased possibility of lymph node involvement, which results in poor survival outcomes.

Palliative options, if appropriate, might be the only justification for intervention in unresectable cases. For example, a cholecystectomy can be performed for an acutely inflamed gallbladder, or left cholodochojejunostomy for drainage in case of failure of endoscopic stenting.

6. Surgical management

Surgery is the mainstay of GBC treatment and the only curative option [43]. Surgical options are dependent on the pathological staging and may involve one or more of the adjacent organs (**Figure 1**).

For stage 0-I (T1, N0, and M0):

- Simple cholecystectomy
 - Simple cholecystectomy might be the only treatment needed in early GBC (i.e., Tis, T1a), as the risk of lymph node dissemination is low. However, great care should be exercised during the handling and mobilization of the gallbladder in order to prevent bile spillage. This is important because the bile in the gallbladder of a patient with GBC is highly contaminated with malignant cells, which increases the risk of dissemination of the cancer cells to the local areas and peritoneal cavity [44]. This concern makes open cholecystectomy the standard of care if the surgeon cannot guarantee an adequate resection with no spillage during laparoscopy [41].
 - The cystic duct resection margin is the main deterrent for further surgical intervention in T1a GBC. Tumor cell involvement of the cystic duct margin justifies reoperation and resection of the extrahepatic bile duct [43, 45]. Hepatic duct involvement suggests poor biology and is frequently associated with lymph node involvement [46]. If the margin is negative for cancer cells, cholecystectomy is sufficient and no further procedure is needed because further resection does not provide any survival benefits to these patients [47, 48].

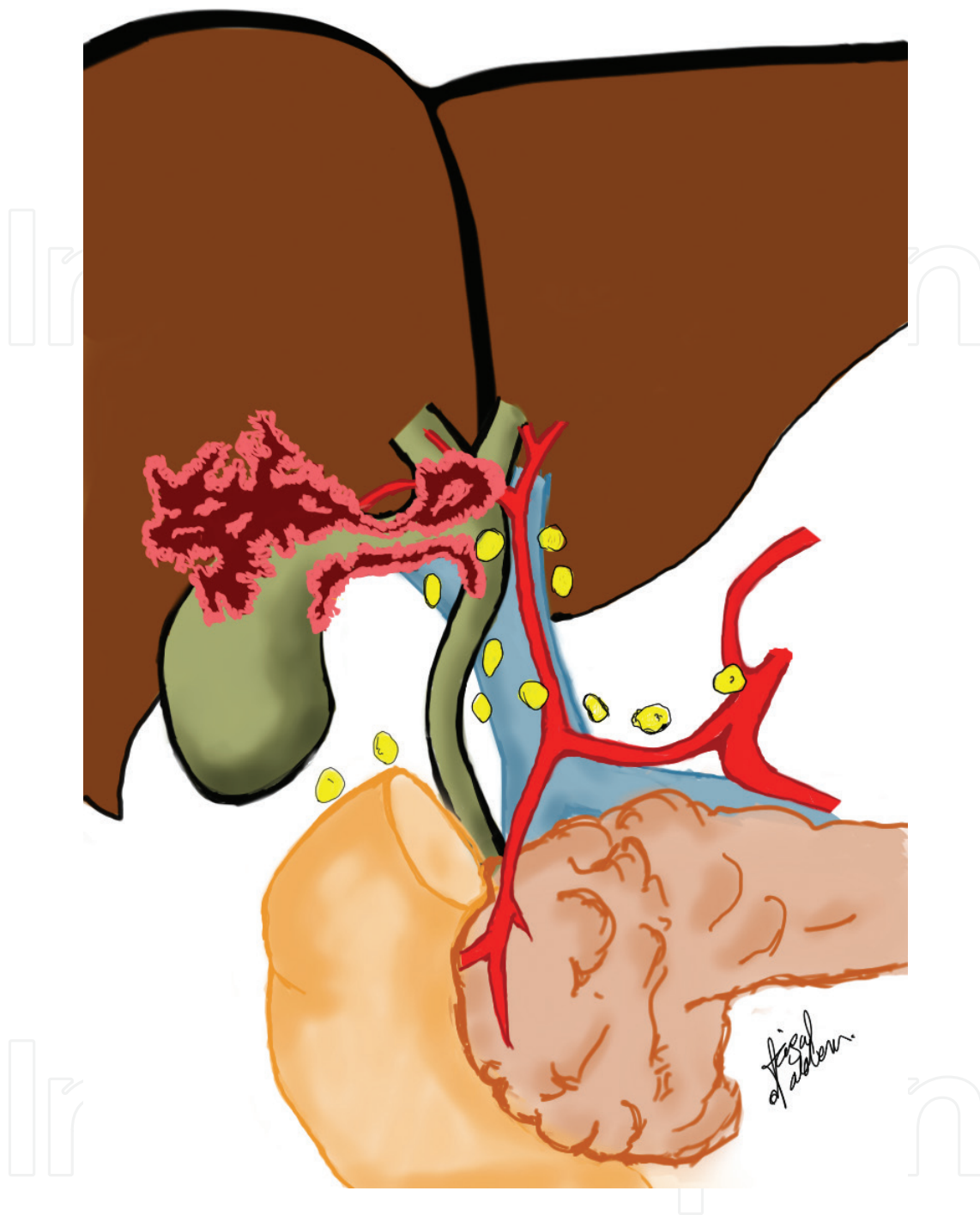


Figure 1. Schematic representation of the hilar structures including the lymph nodes groups targeted during extended cholecystectomy.

- Extended cholecystectomy and lymphadenectomy
 - The treatment strategy for incidental T1b GBC was controversial until recently. Extended cholecystectomy and lymphadenectomy improve cancer-specific survival and are recommended over cholecystectomy alone [41, 49] mainly because of the high risk of

lymph node metastasis (11.5%) in GBC T1b. The recurrence rate after simple cholecystectomy is higher than that after extended cholecystectomy (12.5 vs. 2%, respectively) [41, 50]. However, this survival benefit has been debated in the literature, and simple cholecystectomy is considered sufficient for GBC T1b, especially in eastern countries [51]. Bile duct resection is indicated in cases with a positive cystic duct margin, since recurrence occurs in 50% of these cases. However, there is no evidence to support routine bile duct resection in cases with a negative cystic duct margin.

For stage II (T2, N0, and M0), stage III (T3, N0-1, and M0):

- Extended cholecystectomy and lymphadenectomy
 - If no contraindication for curative surgery exists, extended cholecystectomy and lymphadenectomy are indicated in all cases where the GBC lesions invade the subserosal or deeper layers (T1b, T2, and T3). This recommendation is based on the high rate of vascular and perineural invasion and lymph node metastasis in these stages. An appropriate treatment would be extended cholecystectomy as follows:
 - (a) Bile duct resection

Although there is no evidence to support routine resection, it is indicated when invasion of the cystic duct margin is evident grossly or on a frozen section. Another indication is hepatoduodenal ligament invasion (GB neck tumor) as part of en bloc oncologic resection [43, 45, 51]. In these cases, complete removal of the bile duct is necessary, with further reconstruction using a Roux-en-Y hepaticojejunostomy technique.
 - (b) Extended cholecystectomy includes resection of the gallbladder bed and hepatectomy to achieve an R0 oncologic resection; a 2–3-cm margin is commonly used. Liver resection for GBC treatment ranges from partial hepatectomies (nonanatomical or anatomical resection of segments 4a and 5) to major extended hepatectomies. Anatomical resection of segments 4a and 5 is considered a good oncologic option for GBC because the cystic vein was found to drain into segment 4a (37–90%) and segment 5 (52–90%) [52, 53]. A more aggressive approach consisting of routine right extended hepatectomy that includes the caudate lobe has been proposed. However, major resection does not improve survival over nonanatomical liver resection and only increases the risk of postoperative complications [54, 55]. Furthermore, major hepatectomies are associated with higher morbidity rates than partial hepatectomies are, with no added survival benefit [56–58]. Therefore, achieving R0 with limited liver resection and fewer complications is the recommended procedure for GBC [26, 41].
 - (c) Major hepatectomies are indicated in select cases, which are encountered less frequently in incidental GBC treatment. These are cases in which an R0 resection cannot be achieved with partial hepatectomy or if the tumor is invading the main blood supply of the liver lobe [59].
 - (d) Lymphadenectomy (**Figure 1**):

Lymphatic drainage of GB follows a route starting from around the cystic duct via the portal vein/hepatic artery, into the retropancreatic and celiac/superior

mesenteric artery, and then into the para aortic area [60]. Skip lesions have also been reported, where the tumor invades celiac lymph nodes directly without hepatoduodenal lymph node involvement [61]. Regional lymph nodes of the gallbladder are defined as the nodes in the hepatoduodenal ligament, the nodes along the common hepatic artery, and the nodes cranial to the duodenal papilla on the posterior surface of the head of the pancreas [62]. Therefore, lymphadenectomy of GBC should include at least regional lymph nodes of the gallbladder [26, 41]. According to AJCC guidelines, a minimum of three lymph nodes are required for accurate nodal status evaluation, although recent studies have shown that a minimum of six lymph nodes are needed for accurate nodal evaluation [63, 64]. It is debatable whether extended lymphadenectomy (including celiac/superior mesenteric artery lymph node) as a part of routine lymph node dissection in GBC confers a survival benefit. However, studies suggest that extended lymphadenectomy ensures the removal of an adequate number of lymph nodes (more than six) and the removal of skipped lymph nodes for proper nodal staging. Therefore, extended lymphadenectomy is routinely practiced in high-volume centers [54, 61].

- Port site resections:
 - Port site resection has been proposed for lowering the chances of cancer recurrence at the site of a previous cholecystectomy. However, the use of this procedure is not supported by the evidence found in the scientific literature [41]. Port site resection does not seem to improve survival and carries a 15% risk of incisional hernia. Patients with documented port site metastasis after resection develop peritoneal disease soon after [57, 65]. Therefore, routine port site resection is not recommended [41].

For stage IV and unresectable disease:

- Patients with locally advanced GBC and unresectable disease are considered beyond the scope of curative treatment. Patients with preoperatively determined locally advanced disease (T3-4, N2) should be enrolled in clinical trials assessing neoadjuvant treatment. If these patients undergo resection, they should be enrolled in clinical trials assessing adjuvant treatment [41]. The main treatment is palliative, with the aim of ameliorating the patient's symptoms. Biliary obstruction, pain, cachexia, and infections are the usual targets for such palliative treatment. A single- or double-agent chemotherapy regimen can be added according to patient tolerance and performance status in order to provide palliation and prolong survival [26, 41].

7. Importance of postoperative pathological evaluation following laparoscopic cholecystectomy

The classical postsurgical approach is to review every tissue histopathologically in order to document any concerns regarding the diagnosis and to exclude any oncological etiology. The microscopic examination of at least three sections is recommended, especially in high incidence areas [41]. The increase in cost and pathologists' workload due to evaluation of specimens

from the most commonly performed surgery worldwide remains debatable. Yet, this practice might result in diagnosis of GBC in 0.25–3.0% of all samples evaluated [3–6]. Some studies recommend selective histological examination of the gallbladder on the basis of red flags in the perioperative period, on radiological imaging, and on macroscopic examination of the gallbladder. Thickening of the gallbladder wall and mucosal ulceration are the most common signs associated with malignancy [66, 67]. However, the evidence to support such a practice is still lacking.

8. Conclusion

GBC is a rare but fatal disease. Most cases are discovered incidentally while treating a benign disease, indicating the importance of histopathological exam after all cholecystectomies. Therapy can be multimodal yet surgical intervention is the mainstay of GBC treatment. The most pivotal and important step is accurate preoperative staging. Staging dictates disease management and treatment options and can predict survival. Due to the rarity of the disease patients should be recruited to ongoing multicentral clinical trials.

Author details

Faisal Al-alem¹, Rafif E. Mattar¹, Ahmad Madkhali¹, Abdulsalam Alsharabi¹, Faisal Alsaif¹ and Mazen Hassanain^{1,2*}

*Address all correspondence to: mhassanain@ksu.edu.sa

1 Department of Surgery, King Saud University, Riyadh, Saudi Arabia

2 Department of Oncology, McGill University Health Center, Montreal, Canada

References

- [1] Levy AD, Murakata LA, Rohrmann CA, Jr. Gallbladder carcinoma: radiologic-pathologic correlation. *Radiographics*. 2001;21(2):295–314; questionnaire, 549–55.
- [2] Rodriguez-Fernandez A, Gomez-Rio M, Medina-Benitez A, Moral JV, Ramos-Font C, Ramia-Angel JM, et al. Application of modern imaging methods in diagnosis of gallbladder cancer. *J Surg Oncol*. 2006;93(8):650–64.
- [3] Konstantinidis IT, Deshpande V, Genevay M, Berger D, Fernandez-del Castillo C, Tanabe KK, et al. Trends in presentation and survival for gallbladder cancer during a period of more than 4 decades: a single-institution experience. *Arch Surg*. 2009;144(5):441–7; discussion 7.
- [4] Yamaguchi K, Chijiwa K, Ichimiya H, Sada M, Kawakami K, Nishikata F, et al. Gallbladder carcinoma in the era of laparoscopic cholecystectomy. *Arch Surg*. 1996;131(9):981–4; discussion 5.

- [5] Duffy A, Capanu M, Abou-Alfa GK, Huitzil D, Jarnagin W, Fong Y, et al. Gallbladder cancer (GBC): 10-year experience at Memorial Sloan-Kettering Cancer Centre (MSKCC). *J Surg Oncol*. 2008;98(7):485–9.
- [6] Miller G, Jarnagin WR. Gallbladder carcinoma. *Eur J Surg Oncol*. 2008;34(3):306–12.
- [7] Yamamoto H, Hayakawa N, Kitagawa Y, Katohno Y, Sasaya T, Takara D, et al. Unsuspected gallbladder carcinoma after laparoscopic cholecystectomy. *J Hepatobiliary Pancreat Surg*. 2005;12(5):391–8.
- [8] Tantia O, Jain M, Khanna S, Sen B. Incidental carcinoma gall bladder during laparoscopic cholecystectomy for symptomatic gall stone disease. *Surg Endosc*. 2009;23(9):2041–6.
- [9] Lazcano-Ponce EC, Miquel JF, Munoz N, Herrero R, Ferrecio C, Wistuba, II, et al. Epidemiology and molecular pathology of gallbladder cancer. *CA Cancer J Clin*. 2001;51(6):349–64.
- [10] Strom BL, Soloway RD, Rios-Dalenz JL, Rodriguez-Martinez HA, West SL, Kinman JL, et al. Risk factors for gallbladder cancer. An international collaborative case–control study. *Cancer*. 1995;76(10):1747–56.
- [11] Randi G, Franceschi S, La Vecchia C. Gallbladder cancer worldwide: geographical distribution and risk factors. *Int J Cancer*. 2006;118(7):1591–602.
- [12] Surveillance, Epidemiology End-Results Program (SEER) The Four Most Common Cancers for Different Ethnic Populations 2013. Bethesda, MD: National Cancer Institute. 2013.
- [13] Portincasa P, Moschetta A, Petruzzelli M, Palasciano G, Di Ciaula A, Pezzolla A. Gallstone disease: symptoms and diagnosis of gallbladder stones. *Best Pract Res Clin Gastroenterol*. 2006;20(6):1017–29.
- [14] Hsing AW, Gao YT, Han TQ, Rashid A, Sakoda LC, Wang BS, et al. Gallstones and the risk of biliary tract cancer: a population-based study in China. *Br J Cancer*. 2007;97(11):1577–82.
- [15] Carriaga MT, Henson DE. Liver, gallbladder, extrahepatic bile ducts, and pancreas. *Cancer*. 1995;75(1 Suppl):171–90.
- [16] Shaffer EA. Gallbladder cancer: the basics. *Gastroenterol Hepatol (NY)*. 2008;4(10):737–41.
- [17] Lowenfels AB, Walker AM, Althaus DP, Townsend G, Domellof L. Gallstone growth, size, and risk of gallbladder cancer: an interracial study. *Int J Epidemiol*. 1989;18(1):50–4.
- [18] Shaffer EA. Gallstone disease: epidemiology of gallbladder stone disease. *Best Pract Res Clin Gastroenterol*. 2006;20(6):981–96.
- [19] Li L, Gan Y, Li W, Wu C, Lu Z. Overweight, obesity and the risk of gallbladder and extrahepatic bile duct cancers: A meta-analysis of observational studies. *Obesity (Silver Spring)*. 2016;24(8):1786–802.
- [20] Kumar S, Kumar S, Kumar S. Infection as a risk factor for gallbladder cancer. *J Surg Oncol*. 2006;93(8):633–9.

- [21] Gonzalez-Escobedo G, Marshall JM, Gunn JS. Chronic and acute infection of the gall bladder by *Salmonella* Typhi: understanding the carrier state. *Nat Rev Microbiol*. 2011;9(1):9–14.
- [22] Darby SC, Whitley E, Howe GR, Hutchings SJ, Kusiak RA, Lubin JH, et al. Radon and cancers other than lung cancer in underground miners: a collaborative analysis of 11 studies. *J Natl Cancer Inst*. 1995;87(5):378–84.
- [23] Jain K, Sreenivas V, Velpandian T, Kapil U, Garg PK. Risk factors for gallbladder cancer: a case–control study. *Int J Cancer*. 2013;132(7):1660–6.
- [24] Sheth S, Bedford A, Chopra S. Primary gallbladder cancer: recognition of risk factors and the role of prophylactic cholecystectomy. *Am J Gastroenterol*. 2000;95(6):1402–10.
- [25] Edge SB, Byrd DR, Compton CC, Fritz AG, Greene FL, Trotti A, et al. *AJCC Cancer Staging Manual* (7th ed): New York, NY: Springer; 2010.
- [26] Benson AB, 3rd, Abrams TA, Ben-Josef E, Bloomston PM, Botha JF, Clary BM, et al. NCCN clinical practice guidelines in oncology: hepatobiliary cancers. *J Natl Compr Canc Netw*. 2009;7(4):350–91.
- [27] Ethun CG, Postlewait LM, Le N, Pawlik TM, Buettner S, Poultsides G, et al. Association of optimal time interval to re-resection for incidental gallbladder cancer with overall survival: a multi-institution analysis from the US extrahepatic biliary malignancy consortium. *JAMA Surg*. 2017;152(2):143–149.
- [28] Akatsu T, Aiura K, Shimazu M, Ueda M, Wakabayashi G, Tanabe M, et al. Can endoscopic ultrasonography differentiate nonneoplastic from neoplastic gallbladder polyps? *Dig Dis Sci*. 2006;51(2):416–21.
- [29] Lee JS, Kim JH, Kim YJ, Ryu JK, Kim YT, Lee JY, et al. Diagnostic accuracy of transabdominal high-resolution US for staging gallbladder cancer and differential diagnosis of neoplastic polyps compared with EUS. *Eur Radiol*. 2016:1–7.
- [30] Kumaran V, Gulati S, Paul B, Pande K, Sahni P, Chattopadhyay K. The role of dual-phase helical CT in assessing resectability of carcinoma of the gallbladder. *Eur Radiol*. 2002;12(8):1993–9.
- [31] Jang JY, Kim SW, Lee SE, Hwang DW, Kim EJ, Lee JY, et al. Differential diagnostic and staging accuracies of high resolution ultrasonography, endoscopic ultrasonography, and multidetector computed tomography for gallbladder polypoid lesions and gallbladder cancer. *Ann Surg*. 2009;250(6):943–9.
- [32] Pilgrim CH, Usatoff V, Evans P. Consideration of anatomical structures relevant to the surgical strategy for managing gallbladder carcinoma. *Eur J Surg Oncol*. 2009;35(11):1131–6.
- [33] Li B, Xu XX, Du Y, Yang HF, Li Y, Zhang Q, et al. Computed tomography for assessing resectability of gallbladder carcinoma: a systematic review and meta-analysis. *Clin Imaging*. 2013;37(2):327–33.

- [34] Kokudo N, Makuuchi M, Natori T, Sakamoto Y, Yamamoto J, Seki M, et al. Strategies for surgical treatment of gallbladder carcinoma based on information available before resection. *Arch Surg*. 2003;138(7):741–50; discussion 50.
- [35] Morine Y, Shimada M, Imura S, Ikemoto T, Hanaoka J, Kanamoto M, et al. Detection of lymph nodes metastasis in biliary carcinomas: morphological criteria by MDCT and the clinical impact of DWI-MRI. *Hepatogastroenterology*. 2015;62(140):777–81.
- [36] Jung SJ, Woo SM, Park HK, Lee WJ, Han MA, Han SS, et al. Patterns of initial disease recurrence after resection of biliary tract cancer. *Oncology*. 2012;83(2):83–90.
- [37] Connor S, Barron E, Wigmore SJ, Madhavan KK, Parks RW, Garden OJ. The utility of laparoscopic assessment in the preoperative staging of suspected hilar cholangiocarcinoma. *J Gastrointest Surg*. 2005;9(4):476–80.
- [38] Tillemann EH, de Castro SM, Busch OR, Bemelman WA, van Gulik TM, Obertop H, et al. Diagnostic laparoscopy and laparoscopic ultrasound for staging of patients with malignant proximal bile duct obstruction. *J Gastrointest Surg*. 2002;6(3):426–30; discussion 30–1.
- [39] Weber SM, DeMatteo RP, Fong Y, Blumgart LH, Jarnagin WR. Staging laparoscopy in patients with extrahepatic biliary carcinoma. Analysis of 100 patients. *Ann Surg*. 2002;235(3):392–9.
- [40] Tian Y, Liu L, Yeolkar NV, Shen F, Li J, He Z. Diagnostic role of staging laparoscopy in a subset of biliary cancers: a meta-analysis. *ANZ J Surg*. 2016;87(1-2):22–27.
- [41] Aloia TA, Jarufe N, Javle M, Maithel SK, Roa JC, Adsay V, et al. Gallbladder cancer: expert consensus statement. *HPB (Oxford)*. 2015;17(8):681–90.
- [42] Yoshitomi H, Miyakawa S, Nagino M, Takada T, Miyazaki M. Updated clinical practice guidelines for the management of biliary tract cancers: revision concepts and major revised points. *J Hepatobiliary Pancreat Sci*. 2015;22(4):274–8.
- [43] Jayaraman S, Jarnagin WR. Management of gallbladder cancer. *Gastroenterol Clin North Am*. 2010;39(2):331–42.
- [44] Lee JM, Kim BW, Kim WH, Wang HJ, Kim MW. Clinical implication of bile spillage in patients undergoing laparoscopic cholecystectomy for gallbladder cancer. *Am Surg*. 2011;77(6):697–701.
- [45] Pawlik TM, Gleisner AL, Vigano L, Kooby DA, Bauer TW, Frilling A, et al. Incidence of finding residual disease for incidental gallbladder carcinoma: implications for re-resection. *J Gastrointest Surg*. 2007;11(11):1478–86; discussion 86–7.
- [46] Birnbaum DJ, Vigano L, Ferrero A, Langella S, Russolillo N, Capussotti L. Locally advanced gallbladder cancer: which patients benefit from resection? *Eur J Surg Oncol*. 2014;40(8):1008–15.
- [47] Ouchi K, Mikuni J, Kakugawa Y, Organizing Committee TtACotJSoBS. Laparoscopic cholecystectomy for gallbladder carcinoma: results of a Japanese survey of 498 patients. *J Hepatobiliary Pancreat Surg*. 2002;9(2):256–60.

- [48] Coburn NG, Cleary SP, Tan JC, Law CH. Surgery for gallbladder cancer: a population-based analysis. *J Am Coll Surg*. 2008;207(3):371–82.
- [49] Hari DM, Howard JH, Leung AM, Chui CG, Sim MS, Bilchik AJ. A 21-year analysis of stage I gallbladder carcinoma: is cholecystectomy alone adequate? *HPB (Oxford)*. 2013;15(1):40–8.
- [50] Lee SE, Jang JY, Lim CS, Kang MJ, Kim SW. Systematic review on the surgical treatment for T1 gallbladder cancer. *World J Gastroenterol*. 2011;17(2):174–80.
- [51] Miyazaki M, Yoshitomi H, Miyakawa S, Uesaka K, Unno M, Endo I, et al. Clinical practice guidelines for the management of biliary tract cancers 2015: the 2nd English edition. *J Hepatobiliary Pancreat Sci*. 2015;22(4):249–73.
- [52] Yoshimitsu K, Honda H, Kaneko K, Kuroiwa T, Irie H, Chijiwa K, et al. Anatomy and clinical importance of cholecystic venous drainage: helical CT observations during injection of contrast medium into the cholecystic artery. *AJR Am J Roentgenol*. 1997;169(2):505–10.
- [53] Suzuki M, Yamamoto K, Unno M, Katayose Y, Endo K, Oikawa M, et al. Detection of perfusion areas of the gallbladder vein on computed tomography during arterial portography (CTAP)—the background for dual S4a.S5 hepatic subsegmentectomy in advanced gallbladder carcinoma. *Hepatogastroenterology*. 2000;47(33):631–5.
- [54] Shirai Y, Wakai T, Sakata J, Hatakeyama K. Regional lymphadenectomy for gallbladder cancer: rational extent, technical details, and patient outcomes. *World J Gastroenterol*. 2012;18(22):2775–83.
- [55] Horiguchi A, Miyakawa S, Ishihara S, Miyazaki M, Ohtsuka M, Shimizu H, et al. Gallbladder bed resection or hepatectomy of segments 4a and 5 for pT2 gallbladder carcinoma: analysis of Japanese registration cases by the study group for biliary surgery of the Japanese Society of Hepato-Biliary-Pancreatic Surgery. *J Hepatobiliary Pancreat Sci*. 2013;20(5):518–24.
- [56] Butte JM, Waugh E, Meneses M, Parada H, De La Fuente HA. Incidental gallbladder cancer: analysis of surgical findings and survival. *J Surg Oncol*. 2010;102(6):620–5.
- [57] Fuks D, Regimbeau JM, Le Treut YP, Bachellier P, Raventos A, Pruvot FR, et al. Incidental gallbladder cancer by the AFC-GBC-2009 Study Group. *World J Surg*. 2011;35(8):1887–97.
- [58] D'Angelica M, Dalal KM, DeMatteo RP, Fong Y, Blumgart LH, Jarnagin WR. Analysis of the extent of resection for adenocarcinoma of the gallbladder. *Ann Surg Oncol*. 2009;16(4):806–16.
- [59] Endo I, Shimada H, Takimoto A, Fujii Y, Miura Y, Sugita M, et al. Microscopic liver metastasis: prognostic factor for patients with pT2 gallbladder carcinoma. *World J Surg*. 2004;28(7):692–6.
- [60] Shirai Y, Yoshida K, Tsukada K, Ohtani T, Muto T. Identification of the regional lymphatic system of the gallbladder by vital staining. *Br J Surg*. 1992;79(7):659–62.

- [61] Birnbaum DJ, Vigano L, Russolillo N, Langella S, Ferrero A, Capussotti L. Lymph node metastases in patients undergoing surgery for a gallbladder cancer. Extension of the lymph node dissection and prognostic value of the lymph node ratio. *Ann Surg Oncol*. 2015;22(3):811–8.
- [62] Miyazaki M, Ohtsuka M, Miyakawa S, Nagino M, Yamamoto M, Kokudo N, et al. Classification of biliary tract cancers established by the Japanese Society of Hepato-Biliary-Pancreatic Surgery: 3(rd) English edition. *J Hepatobiliary Pancreat Sci*. 2015;22(3):181–96.
- [63] Ito H, Ito K, D'Angelica M, Gonen M, Klimstra D, Allen P, et al. Accurate staging for gallbladder cancer: implications for surgical therapy and pathological assessment. *Ann Surg*. 2011;254(2):320–5.
- [64] Negi SS, Singh A, Chaudhary A. Lymph nodal involvement as prognostic factor in gallbladder cancer: location, count or ratio? *J Gastrointest Surg*. 2011;15(6):1017–25.
- [65] Maker AV, Butte JM, Oxenberg J, Kuk D, Gonen M, Fong Y, et al. Is port site resection necessary in the surgical management of gallbladder cancer? *Ann Surg Oncol*. 2012;19(2):409–17.
- [66] Wrenn SM, Callas PW, Abu-Jaish W. Histopathological examination of specimen following cholecystectomy: are we accepting resect and discard? *Surg Endosc*. 2017;31(2):586–593.
- [67] Talreja V, Ali A, Khawaja R, Rani K, Samnani SS, Farid FN. Surgically resected gall bladder: is histopathology needed for all? *Surg Res Pract*. 2016;2016:9319147.
- [68] Edge SB, Compton CC. The American Joint Committee on Cancer: the 7th edition of the AJCC cancer staging manual and the future of TNM. *Ann Surg Oncol*. 2010;17(6):1471–4.

